

We are IntechOpen, the world's leading publisher of Open Access books Built by scientists, for scientists

6,900

Open access books available

186,000

International authors and editors

200M

Downloads

Our authors are among the

154

Countries delivered to

TOP 1%

most cited scientists

12.2%

Contributors from top 500 universities



WEB OF SCIENCE™

Selection of our books indexed in the Book Citation Index
in Web of Science™ Core Collection (BKCI)

Interested in publishing with us?
Contact book.department@intechopen.com

Numbers displayed above are based on latest data collected.
For more information visit www.intechopen.com



Diffuse Large B-Cell Lymphoma

*Patrascu Ana Maria, Ionela Rotaru, Valeriu Surlin
and Stefan Patrascu*

Abstract

Diffuse large B-cell lymphoma (DLBCL) is a heterogenous class of aggressive lymphoma and is considered as the most common subtype of non-Hodgkin lymphomas (NHL). Several genetic anomalies such as point mutations, numerical alterations, and, more rarely, translocations and gene amplifications play a role in the pathogenesis of this class of B-cell lymphoma and have been related to specific histological and immunophenotypic subtypes. On the other hand, the treatment protocol in DLBCL did not witness significant changes during the last two decades. The widespread adoption of rituximab as an important adjuvant to standard chemotherapy protocol in CD20+ cases was a notable exception, which provided significant improvement in disease-free survival and overall survival, with limited toxicity. However, no less than 20% of patients diagnosed with DLBCL exhibit relapse after the initial response to R-CHOP regimen, while more than 15% of the patients exhibit primary refractory disease. This is the reason why a review of all the morphological, clinical, and therapeutic particularities of DLBCL is required.

Keywords: diffuse large B-cell lymphoma, immunohistochemistry, lymphoma, molecular diagnostics, rituximab-CHOP

1. Introduction

Non-Hodgkin lymphomas (NHL) are the most common type of lymphoma, accounting for roughly 85% of this category of lymphoid neoplasia. NHL are most commonly classified as B-cell, T-cell, and natural killer (NK) cell lymphomas, according to their cell of origin. Diffuse large B-cell lymphoma (DLBCL) is a heterogenous class of aggressive lymphoma and is considered as the most common subtype of NHL. Several genetic anomalies such as point mutations, numerical alterations, and, more rarely, translocations and gene amplifications play a role in the pathogenesis of this class of B-cell lymphoma and have been related to specific histological and immunophenotypic subtypes [1].

2. Etiopathogeny of diffuse large B-cell lymphoma

2.1 Epidemiology

The incidence of diffuse large B-cell lymphoma (DLBCL) is increasing with age, from 0.3 cases/100,000/year in those between the ages of 35 and 39 years and

26.6/100,000/year for the 80- to 84-year-old age group [2, 3]. Mean age of diagnosis is 65 years for DLBCL and between 20 and 30 years of age for primary mediastinal subtype [4].

This type of lymphoma is more common in Caucasians than African and Asian populations, while the extranodal involvement is more frequent in European and the Far East population than the American patients. The sex ratio ranges from 1.5 to 3.5/1 in favor of men [5].

2.2 Pathogeny

DLBCL originates in mature B cells in certain stages of differentiation. Various changes occur in the B cell toward its malignant transformation, which are induced by genetic mutations. During their ontogenesis, the B cells are passing in the secondary lymphoid tissues where the antigen-dependent activation occurs. The activation and amassment of B cells in the secondary lymphoid tissue lead to the creation of the germinal center, which is critically dependent on BCL-6. If certain genetic alterations occur during lymphocyte development, then the determinatives of the neoplastic changes are settled. The type of lymphoma is determined by the stage of maturation of the B cell and by the type of anomalies that are interfering with their development and differentiation [6]. More specifically, the upregulation of B-cell lymphoma-2 (Bcl-2) protein expression and the inactivation of BCL6 which in turn blocks the apoptosis have both been observed in DLBCL.

Moreover, the elevation of the nuclear factor kappa-light-chain-enhancer of activated B cells (NFkB) and the upregulation of the avian myelocytomatosis virus oncogene cellular homolog (c-Myc) expression, leading to an increase in B cell proliferation, have also been cited [7]. The signal pathways for the B-cell receptor (BCR) and the activation of NFkB and downregulation of the B-cell lymphoma-6 (Bcl-6) pathways have a special pathogenic significance in DLBCL [7].

3. Classification and standardization

3.1 Classification

DLBCL can originate from three types of cells and can be classified accordingly as germinal center DLBCL (GCB DLBCL), from the centroblasts of the germinal center; activated B-cell DLBCL (ABC-DLBCL), from the plasmablasts that are involved in the terminal differentiation of the B cells; and primary mediastinal large B-cell lymphoma (PMBCL), which derives from thymic B cells. This classification has a prognostic utility, as the activated B-cell subtype has an unfavorable evolution [8].

Apart from the cell-of-origin classification, several other classifications for non-Hodgkin lymphomas have been suggested during the last half-century, each with its own advantages and drawbacks: *Rappaport*, *Kiel*, *International Working Formulation (IWF)*, and *the Revised European-American Lymphoma classification (REAL)*. The last classification that is currently in use has been offered by the World Health Organization (WHO) in 2001 and was last revised in 2016. According to the maturation stage in which the B cell is in, and to the type of anomalies that occur during differentiation and maturation, DLBCL presents several variants and subtypes.

The World Health Organization classification of the lymphoid neoplasms has systemized DLBCL into several subtypes, each with its own morphological, clinical, and immunohistochemical particularities. The 2016 revision of the WHO classification brought several updates concerning diagnostic and prognostic factors

for DLBCL, such as the acknowledgment of the prognostic role of double-hit DLBCL-NOS, which involves the double expression of MYC and BCL2, or the newly introduced designation of DLBCL EBV+ (NOS) which is replacing the old term of “DLBCL EBV+ of the elderly” (**Table 1**) [9].

Chronic lymphocytic leukemia/small lymphocytic lymphoma
Monoclonal B-cell lymphocytosis
B-Cell prolymphocytic leukemia
Splenic marginal zone lymphoma
Hairy cell leukemia
Splenic B-cell lymphoma/leukemia, unclassifiable
Splenic diffuse red pulp small B-cell lymphoma
Hairy cell leukemia variant
Lymphoplasmacytic lymphoma
Waldenstrom macroglobulinemia
Monoclonal gammopathy of undetermined significance (MGUS), IgM
m heavy-chain disease
g heavy-chain disease
a heavy-chain disease
Monoclonal gammopathy of undetermined significance (MGUS), IgG/A
Plasma cell myeloma
Solitary plasmacytoma of bone
Extraosseous plasmacytoma
Monoclonal immunoglobulin deposition diseases
Extranodal marginal zone lymphoma of mucosa-associated lymphoid tissue (MALT lymphoma)
Nodal marginal zone lymphoma
Pediatric nodal marginal zone lymphoma
Follicular lymphoma
In situ follicular neoplasia
Duodenal-type follicular lymphoma
Pediatric-type follicular lymphoma
Large B-cell lymphoma with IRF4 rearrangement
Primary cutaneous follicle center lymphoma
Mantle cell lymphoma
In situ mantle cell neoplasia
Diffuse large B-cell lymphoma (DLBCL), NOS
Germinal center B-cell type
Activated B-cell type
T-cell/histiocyte-rich large B-cell lymphoma
Primary DLBCL of the central nervous system (CNS)
Primary cutaneous DLBCL, leg type
EBV1 DLBCL, NOS
EBV1 mucocutaneous ulcer

DLBCL associated with chronic inflammation
Lymphomatoid granulomatosis
Primary mediastinal (thymic) large B-cell lymphoma
Intravascular large B-cell lymphoma
ALK1 large B-cell lymphoma
Plasmablastic lymphoma
Primary effusion lymphoma
HHV81 DLBCL, NOS
Burkitt lymphoma
Burkitt-like lymphoma with 11q aberration
High-grade B-cell lymphoma, with MYC and BCL2 and/or BCL6 rearrangements
High-grade B-cell lymphoma, NOS
B-cell lymphoma, unclassifiable, with features intermediate between DLBCL and classical Hodgkin lymphoma

Table 1.
2016 WHO classification of mature B-cell neoplasms [9].

3.2 Variants of DLBCL and related pathologic entities

Over time, several variants and subtypes of DLBCL have been identified, according to their clinical features, localization, and morphology, which are all included in the recent REAL and WHO classifications. Extranodal DLBCL are relatively rare, accounting for 1–5% of NHL [10]. Less than 40% of DLBCL cases are originating in extranodal sites, especially in the gastrointestinal tract but also the mediastinum, bones, central nervous system (CNS), testes, and breast [11].

3.2.1 Primary mediastinal large B-cell lymphoma (PMBCL)

Roughly 10% of the total number of DLBCL is represented by PMBCL, a subtype which originates in medullary thymic B cells and affects young women, around the age of 30 and 40 years. They clinically appear as large mediastinal tumors sometimes involving the lungs and pericardium, which can lead to local compression with superior vena cava syndrome and airway obstruction. PMBCL is positive for pan-B markers, CD23 and CD30, and is negative to CD15 and sIg. BCL6, CD10, and interferon regulatory factor 4 (IRF4) can sometimes be positive [12]. Several chromosomal abnormalities can be found, such as gains in chromosomal arm 9p and 2p corresponding to JAK2 and cREL loci [13, 14]. Because of the diagnosis confusions between PMBCL and DLBCL with secondary mediastinal involvement, the reports concerning the survival rates of the two pathologic entities have been similar [15].

More recently the improvements in diagnosis of PMBCL have allowed to observe a higher survival rate of this type of lymphoma compared to DLBCL [16]. Some variants of PMBCL, which own morphologic, immunophenotypical, and molecular resemblance with the nodular sclerosis subtype of Hodgkin lymphoma, are included in the category of B-cell lymphoma, unclassifiable, with features intermediate between DLBCL and classical Hodgkin lymphoma [9, 10, 17].

3.2.2 Primary DLBCL of the central nervous system (CNS)

Only a limited number of cases (2–3%) of cerebral neoplasms are lymphomas, the most frequent of which is DLBCL. Primary DLBCL of CNS can be both

germinal center and non-germinal center, while some genetic anomalies suggest the implication of the microenvironment as a pathogenic factor [18].

The clinical manifestations usually range from neurological deficits to psychiatric symptoms, but ocular involvement, seizures, and symptoms of increased intracranial pressure can also be found [18].

3.2.3 Primary testicular lymphomas (PTL)

PTL are usually DLBCL (>80%) but can also be classified as follicular, plasmablastic, Burkitt, mantle cell, or plasmablastic lymphomas in a minority of cases. Usually this type of lymphoma is diagnosed in stages 1–2, while in advanced stages, it can also affect the central nervous system, the liver, the skin, the Waldeyer ring, and the lungs [19]. PTL displays a modified expression of adhesion molecules that can be correlated with extranodal involvement. In most cases (60–96%) the cell of origin analysis indicates the activated B-cell (ABC) pattern. Several mutations have been observed, such as MYD88 mutations in 70% of cases, rearrangements of forkhead box protein P1 (FOXP1), programmed death-ligand 1 (PDL 1), and class II MHC transactivator (CIITA), as well as inactivation mutations of beta-2 microglobulin (B2M) gene [10].

3.2.4 Primary breast lymphoma

Primary breast lymphoma is a rare form of breast cancer, with cell of origin studies usually indicating an activated B-cell pattern. The cytogenetic analysis shows multiple chromosomal anomalies, such as trisomies 3 and 18 and translocations of chromosome 18 involving IGH/MALT1 [20].

3.2.5 Primary bone lymphoma (PBoL)

PBoL is a rare type of lymphoma that is confined to the bone tissue, preponderantly affecting the middle-aged male patients. It should be differentiated from primary medullary lymphoma which, unlike PBoL, does not display cortical involvement [21]. The germinal center subtype is more common, frequently displaying BCL2, BCL6, and MYC rearrangements [10].

4. Clinical, morphologic, and cytogenetic characteristics

4.1 Clinical aspects

DLBCL patients have a wide spectrum of clinical manifestations, a frequent nodal involvement, but also, in up to 40% of cases, extranodal symptoms (skin, digestive and central nervous system, etc.). All these clinical manifestations, together with the general signs and symptoms (such as fever, weight loss, sweating) usually indicate a more aggressive phenotype. On rare occasions, the diagnosis is incidentally established when the clinical examination detects enlarged lymph nodes with no other signs or symptoms. Medullary involvement is uncommon in the early phases of the disease, as it is only found in less than 30% of cases [22].

As for the paraclinical investigations, usual blood tests consist in complete blood count, lactate dehydrogenase and uric acid determination, serology, osteomedullary biopsy, and cytologic exam of the cerebrospinal fluid. Computed tomography (CT) scan or, even better, positron emission tomography–computed tomography (PET-CT) is considered mandatory to assess the extension of the disease.

PET-CT is of great diagnostic and prognostic importance, but it is also necessary for the post-chemotherapy assessment, such that in case of negative scans at the end of chemotherapy regimen, the overall prognosis is favorable [23, 24]. The drawbacks of this technique consist of the possibility of false-positive results due to reversible thymic hyperplasia, infections, and sarcoidosis or as a consequence of hematopoietic growth factor therapy [23].

4.2 Morphologic and cytogenetic characteristics

The search for an exclusively cytologic classification of DLBCL is mostly abandoned, due to the wide observer-dependent variations in morphologic analysis and nosologic framing. The cytologic exam usually differentiates between centroblastic, immunoblastic, anaplastic, and T-cell/histiocyte-rich B-cell lymphoma.

The subtype of DLBCL is decided by the genetic anomalies that occur during B-cell differentiation and maturation process [6, 25].

Even though gene expression profiling has the best accuracy for the identification of the cell of origin in DLBCL, its numerous drawbacks—such as the diverse cellular regulating pathways, some financial limitations, etc.—make its widespread clinical use still impractical. Consequently, several surface molecules have been evaluated for the differentiation between GCB and ABC DLBCL, which prove to be consistent with gene expression profiling.

The Hans algorithm has structured DLBCL in these two main subtypes, by analyzing three essential markers: multiple myeloma 1 protein (MUM1), CD10, and bcl-6 (Figure 1). The same classification can be achieved by using the germinal center B cell-expressed transcript 1 (GCET1), CD10, BCL-6, MUM1, and FOXP1 biomarkers (the Tally and Choi algorithms) with a slightly better accuracy (Figure 2). All these algorithms are important, as the cell of origin classification tends to display a prognostic role, due to the fact that DLBCL-GCB subtype usually has a favorable prognosis compared to non-GCB subtype. To further add to the complexity of this classification, GC and ABC DLBCL subtypes also express several particularities in cell marker expression, activation pathways, and outcomes [26].

However, the detection of other cell marker expression has become a fundamental component both in establishing an accurate prognosis and in the development of an optimal therapeutic algorithm.

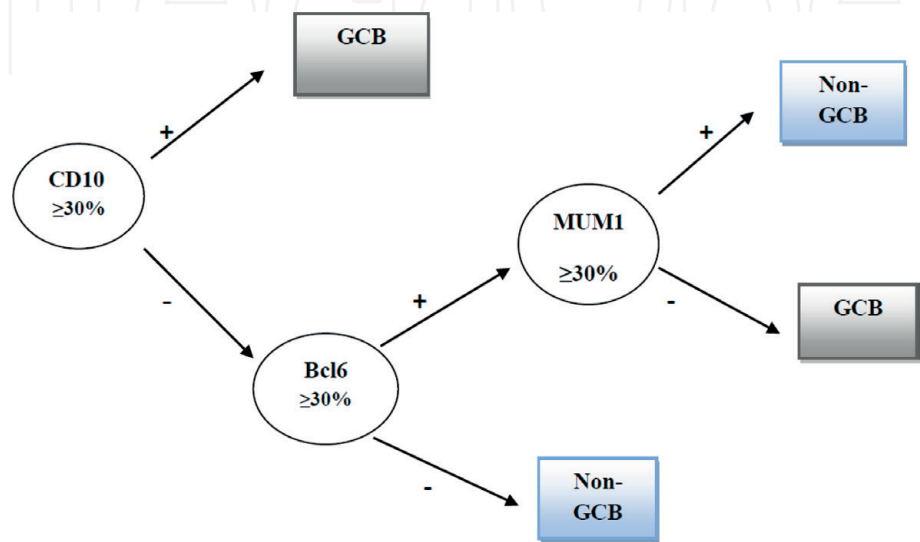


Figure 1.
Hans algorithm for DLBCL subtyping.

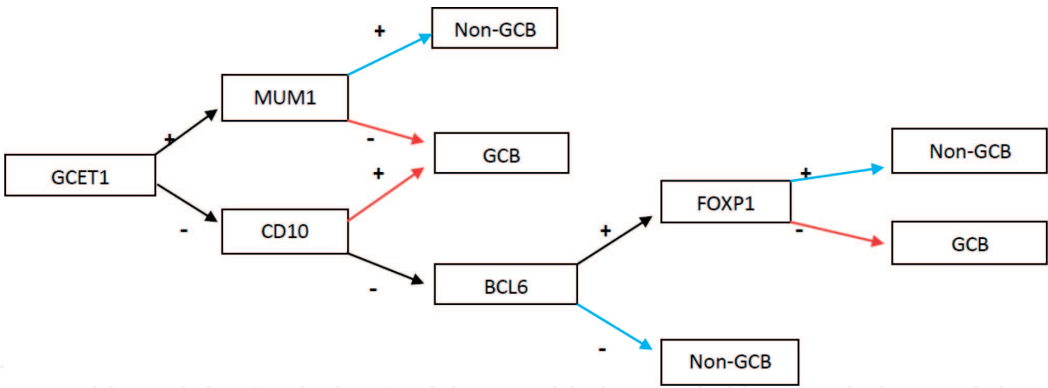


Figure 2.
Choi algorithm for DLBCL subtyping.

5. Treatment of diffuse large B-cell lymphoma

The treatment protocol in DLBCL did not witness significant changes during the last two decades. The widespread adoption of rituximab as an important adjuvant to standard chemotherapy protocol in CD20+ cases was a notable exception, which provided significant improvement in disease-free survival, overall survival, and complete remission rates, with limited toxicity. However, no less than 20% of patients diagnosed with DLBCL exhibit relapse after the initial response to R-CHOP (rituximab, cyclophosphamide, doxorubicin, vincristine, and prednisone) regimen, while more than 15% of the patients exhibit primary refractory disease [27]. All these factors required the search for alternative therapeutic regimens, such as R-CHOEP (rituximab, cyclophosphamide, doxorubicin, vincristine, etoposide, and prednisone), R-miniCHOP (adjusted short-term R-CHOP therapy), R-ACVBP (adriamycin-cytosine-vindesine-bleomycin-prednisone-rituximab), etc., that are strictly codified by several therapeutic protocols, such as the 2015 ESMO guidelines [10].

The choice for any of these regimens should be adapted to the specific clinical status of each patient, as the exact therapy depends on a number of factors, such as the stage of the disease, age, and biological status. However, despite numerous attempts, no clear recommendation has been published thus far.

The association of radiation therapy to chemotherapy offered conflicting results. While some studies showed some benefits for the combined therapy, most of the authors did not find any real advantages, especially in the case of localized disease without bulky mass [28]. There were some suggestions of a combined therapeutic algorithm, involving four R-CHOP cycles followed by either local radiation therapy or two more cycles of R-CHOP, in the case of complete remission. Armitage et al. pleaded for mandatory radiation therapy after six cycles of R-CHOP in the case of bulky disease [29]. More recently MInT (MabThera International Trial) study recommended the same therapeutic algorithm for localized bulky disease [30].

In the case of localized disease, the therapeutic protocol varies with the specific organ involvement. For primary DLBCL of the testis, R-CHOP should be associated with radiotherapy and methotrexate or intrathecal cytarabine, due to the potential risk of CNS involvement. In case of documented CNS involvement before the onset of therapy, then high-dose intravenous and intrathecal methotrexate is advised. Conversely, cytarabine should be used instead of methotrexate for lymphomatous meningitis [31]. R-CEOP can be advised for patients with an altered cardiac function.

In the case of advanced stage DLBCL, the therapeutic options varied greatly since the early 1980s. The third-generation regimens, ProMACE/CytaBOM

(cyclophosphamide, doxorubicin, etoposid, Cytosar, bleomycin, vincristine, methotrexate, prednisone) and M-BACOD (methotrexate, bleomycin, doxorubicin, cyclophosphamide, vincristine, and dexamethasone), showed no benefits for complete remission or disease-free survival when compared to CHOP. However, a lower toxicity for CHOP was observed [32].

The R-ACVBP regimen, consisting of rituximab, doxorubicin, cyclophosphamide, vindesine, bleomycin, and prednisone, for induction of remission, and consolidation with methotrexate, doxorubicin, and cyclophosphamide, was tested by the GELA (Groupe d'Etude des Lymphomes de l'Adulte) study on 379 patients. This regimen showed some advantages over the R-CHOP-21 but at the price of significantly higher toxicity [33].

Given these circumstances, there is a growing need for new therapeutic alternatives, fitted for the morphologic, immunohistochemical, and genetic profile of each patient selected for individualized treatment protocol.

The role of immunophenotype variability for the therapeutic outcome has long been the cornerstone for DLBCL management strategy, largely because the treatment of lymphomas evolves toward new therapies (immunotherapy, targeted therapy), which is made possible by analyzing the biology and the signaling pathways of this disease [34, 35]. Furthermore, a growing number of biological agents are available, varying from interferon to rituximab or radiolabeled antibodies, but also the more recent acquisitions in targeted therapy, such as ibrutinib, acalabrutinib, and daratumumab [36–38].

6. Conclusions

Despite the numerous advances and better understanding of the clinical, immunophenotypic, and genetic characteristics of DLBCL, but also in face of several breakthroughs in its treatment, the prognosis of this type of NHL has witnessed only modest improvements. The search for new biomarkers and efficient therapeutic agents in the context of future individualized treatment will be crucial in our quest for improved results.

Acknowledgements

All authors shared equal contribution to this chapter.

Conflict of interest

None.

Abbreviations

ABC DLBCL	activated B-cell DLBCL
B2M	beta-2 microglobulin
Bcl-2	B-cell receptor 2
Bcl-6	B-cell receptor 6
CIITA	class II MHC transactivator
c-Myc	avian myelocytomatosis virus oncogene cellular homolog
CNS	central nervous system

DLBCL	diffuse large B-cell lymphomas
FOXP1	forkhead box protein P1
GCB DLBCL	germinal center DLBCL
GCET1	germinal center B cell-expressed transcript 1
IRF4	interferon regulatory factor 4
MUM1	multiple myeloma 1 protein
NFkB	nuclear factor kappa-light-chain-enhancer of activated B cells
NHL	non-Hodgkin lymphoma
PDL 1	programmed death-ligand 1
PET-CT	positron emission tomography-computed tomography
PMBCL	primary mediastinal large B-cell lymphoma
PTL	primary testicular lymphomas
R-ACVBP	adriamycin-cytosan-vindesine-bleomycin-prednisone-rituximab
R-CHOP	rituximab, cyclophosphamide, doxorubicin, vincristine, prednisone
R-CHOEP	rituximab, cyclophosphamide, doxorubicin, vincristine, etoposide, and prednisone
WHO	World Health Organization

Author details

Patrascu Ana Maria¹, Ionela Rotaru¹, Valeriu Surlin² and Stefan Patrascu^{2*}

1 Department of Hematology, University of Medicine and Pharmacy of Craiova, Craiova, Romania

2 Department of Surgery, University of Medicine and Pharmacy of Craiova, Craiova, Romania

*Address all correspondence to: stef.patrascu@gmail.com

IntechOpen

© 2019 The Author(s). Licensee IntechOpen. This chapter is distributed under the terms of the Creative Commons Attribution License (<http://creativecommons.org/licenses/by/3.0>), which permits unrestricted use, distribution, and reproduction in any medium, provided the original work is properly cited. 

References

- [1] Bea S, Colomo L, Guillermo AL, Salaverria I, Puig X, Pinyol M, et al. Clinicopathologic significance and prognostic value of chromosomal imbalances in diffuse large B-cell lymphomas. *Journal of Clinical Oncology*. 2004;**22**(17):3498-3506
- [2] Tilly H, Vitolo U, Walewski J, da Silva MG, Shpilberg O, André M, et al. Diffuse large B-cell lymphoma (DLBCL): ESMO clinical practice guidelines for diagnosis, treatment and follow-up. *Annals of Oncology*. 2012;**23**(7):78-82
- [3] Morgan G, Vornanen M, Puitinen J, et al. Changing trends in the incidence of non-Hodgkin's lymphoma in Europe. Biomed Study Group. *Annals of Oncology*. 1997;**8**(Suppl 2):49-54
- [4] Siegel R, Naishadham D, Jemal A. Cancer statistics, 2013. *CA: A Cancer Journal for Clinicians*. 2013;**63**(1):11-30
- [5] Jemal A, Siegel R, Xu J, Ward E. Cancer statistics, 2010. *CA: A Cancer Journal for Clinicians*. 2010;**60**(5):277-300
- [6] Kuppers R, Dalla-Favera R. Mechanisms of chromosomal translocations in B cell lymphomas. *Oncogene*. 2001;**20**:5580-5594
- [7] Pasqualucci L et al. Hypermutation of multiple proto-oncogenes in B-cell diffuse large-cell lymphomas. *Nature*. 2001;**412**:341-346
- [8] Ng AK. Diffuse large B-cell lymphoma. *Seminars in Radiation Oncology*. 2007 Jul;**17**(3):169-175. DOI: 10.1016/j.semradonc.2007.02.002
- [9] Swerdlow SH, Campo E, Pileri SA, Harris NL, Stein H, Siebert R, et al. The 2016 revision of the World Health Organization classification of lymphoid neoplasms. *Blood*. 2016;**127**(20):2375-2390
- [10] Vitolo U, Seymour JF, Martelli M, Illerhaus G, Illidge T, Zucca E, et al. Extranodal diffuse large B-cell lymphoma (DLBCL) and primary mediastinal B-cell lymphoma: ESMO clinical practice guidelines for diagnosis, treatment and follow-up. *Annals of Oncology*. 2016;**27**:91-102
- [11] Møller MB, Pedersen NT, Christensen BE. Diffuse large B-cell lymphoma: Clinical implications of extranodal versus nodal presentation—A population-based study of 1575 cases. *British Journal of Haematology*. 2004;**124**:151-159. DOI: 10.1046/j.1365-2141.2003.04749.x
- [12] Savage KJ, Al-Rajhi N, Voss N, Paltiel C, Klasa R, Gascoyne RD, et al. Favorable outcome of primary mediastinal large B-cell lymphoma in a single institution: The British Columbia experience. *Annals of Oncology*. 2006;**1**:123-130
- [13] Bentz M, Barth TF, Bruderlein S, Bock D, Schwerer MJ, Baudis M, et al. Gain of chromosome arm 9p is characteristic of primary mediastinal B-cell lymphoma (MBL): Comprehensive molecular cytogenetic analysis and presentation of a novel MBL cell line. *Genes, Chromosomes & Cancer*. 2001;**30**:393-401. DOI: 10.1002/1098-2264(2001)9999:9999<::AID-GCC1105>3.0.CO;2-I
- [14] Joos S, Otano-Joos MI, Ziegler S, Bruderlein S, du Manoir S, Bentz M, et al. Primary mediastinal (thymic) B-cell lymphoma is characterized by gains of chromosomal material including 9p and amplification of the REL gene. *Blood*. 1996;**87**:1571-1578
- [15] Lazzarino M, Orlandi E, Paulli M, et al. Treatment outcome

and prognostic factors for primary mediastinal (thymic) B-cell lymphoma: A multicenter study of 106 patients. *Journal of Clinical Oncology*. 1997;**15**:1646-1653

[16] Todeschini G, Secchi S, Morra E, et al. Primary mediastinal large B-cell lymphoma (PMLBCL): Long-term results from a retrospective multicentre Italian experience in 138 patients treated with CHOP or MACOP-B/VACOP-B. *British Journal of Cancer*. 2004;**90**:372-376

[17] Rosenwald A, Wright G, Leroy K, Yu X, Gaulard P, Gascoyne RD, et al. Molecular diagnosis of primary mediastinal B cell lymphoma identifies a clinically favorable subgroup of diffuse large B cell lymphoma related to Hodgkin lymphoma. *The Journal of Experimental Medicine*. 2003;**198**(6):851

[18] Ferreri AJ, Blay JY, Reni M, et al. Prognostic scoring system for primary CNS lymphomas: The International Extranodal Lymphoma Study Group experience. *Journal of Clinical Oncology*. 2003;**21**:266-272

[19] Kuper-Hommel MJ, Janssen-Heijnen MLG, Vreugdenhil G, et al. Clinical and pathological features of testicular diffuse large B-cell lymphoma: A heterogeneous disease. *Leukemia & Lymphoma*. 2012;**53**:242-246

[20] Cheah CY, Campbell BA, Seymour JF. Primary breast lymphoma. *Cancer Treatment Reviews*. 2014;**40**:900-908

[21] Martinez A, Ponzoni M, Agostinelli C, et al. Primary bone marrow lymphoma: An uncommon extranodal presentation of aggressive non-Hodgkin lymphomas. *The American Journal of Surgical Pathology*. 2012;**36**:296-304

[22] NCCN Guidelines for Treatment of Non-Hodgkin Lymphoma. <http://www.nccn.org> [Accessed: December 31, 2018]

[23] Cheson BD, Pfistner B, Juweid ME, et al. Revised response criteria for malignant lymphoma. *Journal of Clinical Oncology*. 2007;**25**:579-586

[24] Juweid ME, Cheson BD. Role of positron emission tomography in lymphoma. *Journal of Clinical Oncology*. 2005;**23**(21):4577-4580

[25] Pătraşcu AM, Rotaru I, Olar L, Pătraşcu Ş, Ghiluşi MC, Neamtu SD, et al. The prognostic role of Bcl-2, Ki67, c-MYC and p53 in diffuse large B-cell lymphoma. *Romanian Journal of Morphology and Embryology*. 2017;**58**(3):837-843

[26] Martelli M, Ferreri AJ, Agostinelli C, Di Rocco A, Pfreundschuh M, Pileri S. Diffuse large B-cell lymphoma. *Journal of Hematology & Oncology*. 2013;**87**(2):146-171

[27] Laursen MB, Reinholdt L, Schönherz AA, Due H, Jespersen DS, Grubach L, et al. High CXCR4 expression impairs rituximab response and the prognosis of R-CHOP-treated diffuse large B-cell lymphoma patients. *Oncotarget*. 2019;**10**(7):717-731. DOI: 10.18632/oncotarget.26588

[28] Miller TP, Dahlberg S, Cassady JR, Adelstein DJ, Spier CM, Grogan TM, et al. Chemotherapy alone compared with chemotherapy plus radiotherapy for localized intermediate- and high-grade non-Hodgkin's lymphoma. *The New England Journal of Medicine*. 1998;**339**(1):21-26

[29] Armitage JO. How I treat patients with diffuse large B-cell lymphoma. *Blood*. 2007;**110**(1):29-36

[30] Pfreundschuh M, Kuhnt E, Trümper L, Osterborg A, Trneny M, Shepherd L, et al. CHOP-like chemotherapy with or without rituximab in young patients with good-prognosis diffuse large-B-cell lymphoma: 6-year results of an

open-label randomised study of the MabThera International Trial (MInT) Group. *The Lancet Oncology*. 2011;**12**(11):1013-1022

[31] Fletcher CD, Kahl BS. Central nervous system involvement in diffuse large B-cell lymphoma: An analysis of risks and prevention strategies in the post-rituximab era. *Leukemia & Lymphoma*. 2014;**55**(10):2228-2240

[32] Fisher RI, Gaynor ER, Dahlborg S, Oken MM, Grogan TM, Mize EM, et al. Comparison of a standard regimen (CHOP) with three intensive chemotherapy regimens for advanced non-Hodgkin's lymphoma. *The New England Journal of Medicine*. 1993;**328**(14):1002-1006

[33] Recher C, Coiffier B, Haioun C, Molina TJ, Fermé C, Casasnovas O, et al. Intensified chemotherapy with ACVBP plus rituximab versus standard CHOP plus rituximab for the treatment of diffuse large B-cell lymphoma (LNH03-2B): An open-label randomised phase 3 trial. *Lancet*. 2011;**378**(9806):1858-1867

[34] He Y, Li J, Ding N, Wang X, Deng L, Xie Y, et al. Combination of enzastaurin and ibrutinib synergistically induces anti-tumor effects in diffuse large B cell lymphoma. *Journal of Experimental & Clinical Cancer Research*. 2019;**38**(1):86. DOI: 10.1186/s13046-019-1076-4

[35] Afonso J, Pinto T, Simões-Sousa S, Schmitt F, Longatto-Filho A, Pinheiro C, et al. Clinical significance of metabolism-related biomarkers in non-Hodgkin lymphoma—MCT1 as potential target in diffuse large B cell lymphoma. *Cellular Oncology (Dordrecht)*. 2019. DOI: 10.1007/s13402-019-00426-2 [Epub ahead of print]

[36] Wu J, Zhang M, Liu D. Acalabrutinib (ACP-196): A selective second-generation BTK

inhibitor. *Journal of Hematology & Oncology*. 2016;**9**:21. DOI: 10.1186/s13045-016-0250-9

[37] Maffei R, Fiorcari S, Martinelli S, Potenza L, Luppi M, Marasca R. Targeting neoplastic B cells and harnessing microenvironment: The “double face” of ibrutinib and idelalisib. *Journal of Hematology & Oncology*. 2015;**8**:60. DOI: 10.1186/s13045-015-0157-x

[38] Salles G, Gopal AK, Minnema MC, Wakamiya K, Feng H, Schecter JM, et al. Phase 2 study of daratumumab in relapsed/refractory mantle-cell lymphoma, diffuse large B-cell lymphoma, and follicular lymphoma. *Clinical Lymphoma, Myeloma & Leukemia*. 2019;pii: S2152-2650 (18):31284-31289. DOI: 10.1016/j.clml.2018.12.013 [Epub ahead of print]