

We are IntechOpen, the world's leading publisher of Open Access books Built by scientists, for scientists

6,900

Open access books available

186,000

International authors and editors

200M

Downloads

Our authors are among the

154

Countries delivered to

TOP 1%

most cited scientists

12.2%

Contributors from top 500 universities



WEB OF SCIENCE™

Selection of our books indexed in the Book Citation Index
in Web of Science™ Core Collection (BKCI)

Interested in publishing with us?
Contact book.department@intechopen.com

Numbers displayed above are based on latest data collected.
For more information visit www.intechopen.com



Introductory Chapter: Glioma - Merciless Medical Diagnosis

Ibrahim Omerhodžić

Additional information is available at the end of the chapter

<http://dx.doi.org/10.5772/intechopen.82863>

1. Introduction

Is not this still the truth? Or, are we today, over 100 years after the first glioma operation, however, nearer to the option that we can treat, even cure, most of gliomas or at least keep the disease under control for very many years? The most frequent primary brain tumor, glioma, is still a nightmare for neurooncologists, neuropathologists, neurosurgeons, and other related professionals, but for patients and their families first of all.

If we look at the results of the papers published in the influential *Medline* database (accessed in December 2018), we will find a paper on glioma published back in 1870 [1]. For the next almost 150 years, in this base alone, we can find more than 87,000 papers on the same topic. On the other hand, in the same base only in the past 5 years, over 22,000 papers have been published having basically a story on gliomas (almost a quarter of all publications on gliomas). Does this mean that in the recent years the glioma field research has been more fruitful than ever before? Does this promise, or at least give hope, that we will find the way to put this serious disease under control?

In the USA, primary brain tumors account for about 2% of all cancers, with an overall annual incidence of 22 per 100,000 population, with nearly 80,000 new cases of which one-third will be malignant [2, 3].

The past three decades have been marked with huge enthusiasm of scientists' and professionals' efforts to bring this serious disease into the context of curable or even cured one. Brain glioma patient treatment has significantly changed over time. Undoubtedly, the architect of this fight, Hurvey Chusing, early in the twentieth century, tried to solve the problem surgically and by tumor removal from the brain. History would very soon show

that there are brain tumors for which surgery is not sufficient; for some of them, it is not the first option or treatment at all. However, gliomas have remained in focus of interest not only of neurosurgeons but of oncologists, pathologists, neuroradiologists, forensics, and other related medical and nonmedical disciplines either. Not unimportant is also the interest of pharmaceutical industry and researchers in the field of biomedical technologies in the glioma field.

2. Where we were

Expansion of new diagnostic modalities and glioma treatment, such as imaging, stereotaxic localization, and standardization of the microsurgical technique, practically started in the 1980s. These methods, however, contributed to a better, safer, and more precise glioma resection, but there was no clear confirmation of better survival. We had to hope for better adjuvant therapy effects.

Until recently, rare were prospective randomized studies confirming that the gross total resection improved the outcome. The use of 5-ALA at resection enabled the doubling of time of 6-month progression free survival (PFS) and overall survival (OS). Significant glioma treatment progress occurred with the introduction of neuronavigational (frameless) biopsy in almost routine practice, followed by analysis of a tumor sample with a series of biomarkers; so, even before entering the operating theater for tumor resection, now it is possible to have a lot of information on its nature; glioma resection can be worked out in much more detail both for low-grade glioma (LGG) and for high-grade glioma (HGG). We should have in mind that today's accepted practice is that, when frozen section shows grade III glioma, we should do the aggressive tumor resection as much as possible. For grade IV (glioblastoma), the extensive resection is also critical for outcome [4]. On the other hand, midline tumors have a poorer prognosis compared to lobar equivalents, probably for the reason that the radical resection is feasible with more difficulties [5].

With time, significant progress has been made in the treatment and strategy of glioma patient treatment. This relates particularly to malignant gliomas. A shift has been made both in treatment and in diagnostic, with an accent on ever more powerful apparatus for neuroradiological scanning, magnetic resonance (MRI) first of all. Introduction of MRI in the late 1980s revolutionized management of intracranial tumors, and advanced neuroimaging today is one of the most important prerequisites for the modern treatment of glioma. This is possible especially because of combined use of contemporary radiological modalities, particularly integration of structural, metabolic, and functional imaging, which provides optimal multifaceted information for detailed characterization of intracranial gliomas [6]. Methods of the definite confirmation of the glioma kind and grade have walked a path from classical macro- and microscopic pathohistological confirmation of tumor, through morphological-histological, to molecular and genetic diagnosis practically accepted today.

3. Where we are now

Brain glioma is infrequently also denoted as slowly growing neoplasm that is most often discovered in younger adults, and it is presented with minimal symptoms or no such symptoms at all. The World Health Organization (WHO) classification system for glial tumors offered guidelines, which can predict the disease course; treatment modalities are thus recommended [7]. Nevertheless, these guidelines are based mostly on histological diagnosis. European Association for Neuro-Oncology (EANO) also presented its guidelines [8]. Yet, histologically the same tumors may have different courses, response to therapy and eventually to outcome. Molecular markers that carry both diagnostic and prognostic information add valuable tools by redefining tumor subtypes within each WHO category. That is why these molecular biomarkers have become an integral part of tumor assessment in modern neurooncology [9]. In that sense, markers such as biomarkers (IDH mutations, promoter methylation of MGMT, chromosomal deletion of 1p/19q, mutations of EGFR and ATRX genes, and BRAF fusion) can today guide clinicians to make better decisions in some subtypes of gliomas, including anaplastic oligodendroglioma and GBM in the elderly [9, 10]. The integration of genome-wide data delineated three molecular classes of LGG, and we believe today that those without an IDH mutation were molecularly and clinically similar to GBM [11].

Significant progress has been made generally in glioma treatment with the use of modern radiotherapy ways and new chemotherapeutics. Several studies in the past decade have dealt with very promising temozolomide (TMZ) in glioma treatment. Baumert et al., in recently published randomized study results, have reported that they did not find any significant difference in outcome of the overall patient population treated with either radiotherapy alone or TMZ chemotherapy alone [12]. On the other hand, in the just published EORTC trial, randomized controlled research on phase 2 published in Lancet, van den Bent et al. have found no evidence of improved overall survival with bevacizumab (Avastin) and TMZ combination treatment versus TMZ monotherapy in patients with first recurrence of WHO grades II and III glioma, without 1p/19q codeletion [13].

A new swing in glioma treatment was the defining of a molecular genetics signature, which can predict patient's outcome with the loss of 1p and 19q in anaplastic oligodendroglioma. Specifically, such patients responded very well to procarbazine, cyclohexylchloroethylnitrosurea CCNU, and vincristine (PCV) chemotherapy or TMZ. When it comes to glioblastoma multiforme (GBM), hope was set on MGMT gene and its methylation [4].

Surgically, progress was made possible with the development and use of technological aids, first of all of neuronavigation, cortical mapping, electrocorticography, neuromonitoring, functional and intraoperative MRI, magnetoencephalography (MEG). As great hope was placed on extension of tumor resection, brain mapping in particular offered additional safety to the neurosurgeon to provide as good result as possible with maximal and today popular supratotal resection.

The current paradigm shift considers glioma management in a comprehensive perspective that takes into account the intricate connectivity of the cerebral networks. Lesions

previously considered inoperable are today more accessible and safer for resection; the surgeon has greater self-confidence and better preoperative knowledge about the tumor and can expect better result of the glioma resection itself; and patients can expect a better outcome. This is particularly important for those lesions for which neurosurgical resection and the extent of resection (EOR) is still the most important part of treatment and standard of care [14–16].

To achieve as good result as possible, somatosensory evoked potentials (SSEPs), motor evoked potentials (MEPs), visual evoked potentials (VEPs), brainstem auditory evoked potentials (BAEPs), and electrocorticography (ECoG) are used nowadays routinely during glioma surgery. For brainstem gliomas, specific mapping with direct electrical stimulation (DES), corticobulbar tract MEP monitoring, and free-running electromyography (EMG) of the various muscles innervated by the cranial nerves are also required. Awake craniotomy and intraoperative mapping of language and sensorimotor functions with DES have become standard techniques for removal of cerebral neoplasms affecting eloquent cortical areas and subcortical pathways [17].

The present data provide prognostic information for patients with pilocytic astrocytoma and confirm that age and tumor size had a significant effect on OS [18]. For patients with anaplastic astrocytic gliomas, Nayak et al. [18] have found the median overall survival 2.9 years, and 1-year OS rate was 87%. Novel therapeutics is needed in patients with tumors not amenable to resection or radiosurgery [19]. The joint efforts of neuroscientists, researchers, and clinicians have provided an unprecedented ability to localize lesions and to assess the human brain function at the microscopic, mesoscopic, and macroscopic scales [14].

4. Where we are going

Treatments and better outcomes for primary brain tumors have long lagged behind those of other tumors. Rapid advances in neurooncology, cancer and CNS immunology, and progress in genomics have created more therapeutic opportunities than ever before [2, 3]. There is no doubt that significant changes have occurred in management of glioma patients. In the past three decades, we have led to the discovery of hundreds of molecular alterations in grades II, III, and IV gliomas. Among these molecular alterations, three are particularly noteworthy, because they occur early during glioma formation, are prevalent in glioma, or are strongly associated with overall survival. Codeletion of chromosome arms 1p and 19q (1p/19q codeletion), which is associated with the oligodendroglial histologic type and with sensitivity to chemotherapy with alkylating agents. The second was mutation in either IDH1 or IDH2 gene associated with a distinctive tumor cell metabolism. The third was mutation in the promoter of TERT, which is seen in both the most aggressive human glioma (grade IV astrocytoma) and the least aggressive diffuse human glioma (grade II oligodendroglioma) [11, 18].

Pamir and his group (2017) stated that molecular subsets in hemispheric diffuse gliomas result in different tumor biology and clinical behaviors [20]. Eckel-Passow et al. [21] published significant study on a sample of 1081 gliomas, which they divided into five molecular

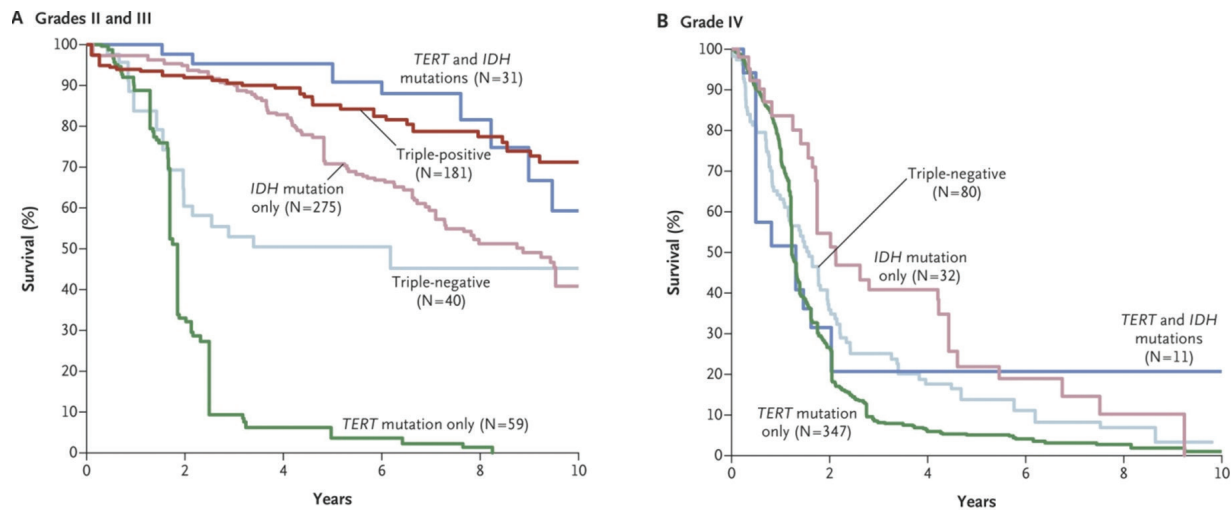


Figure 1. Overall survival in the glioma molecular groups based on 1p/19q, IDH, and TERT promoter mutations in tumors (taken from Eckel-Passow et al. [21]).

groups according to three alterations: mutations in the TERT promoter, mutations in IDH, and codeletion of chromosome arms 1p and 19q (**Figure 1**). They concluded that “the groups had different ages at onset, overall survival, and associations with germline variants, which implies that they are characterized by distinct mechanisms of pathogenesis” [21]. In favor of this, in the future, we should also incorporate alterations in ATRX, TP53, EGFR, or PTEN or other alterations that might be useful to consider in the diagnosis of glioma [11].

WHO grade I tumors and WHO grade II tumors should not be grouped together as low grade, because the two disease processes are markedly different. For patients with grade II glioma who had undergone subtotal tumor resection, Buckner and colleagues suggest combination of chemotherapy in addition to radiation therapy [22]. Opposite to the real low-grade lesions are, for example, dysembryoplastic neuroepithelial tumors are associated with continuous growth and inevitable malignant transformation. This fact supports the concept that grade II gliomas are premalignant and that the use of early aggressive surgical treatment is a very important part of their treatment pathway [18]. Al-Tamimi and Duffau’s group [23] suggest that after radical resection, the presence of foci of transformation within a background of grade II tumor does not necessarily require immediate adjuvant therapy. They suggest that a tailored approach should be used, taking into account the extent of resection, the full histopathologic and molecular profile of the tumor, and careful evaluation of the resection margins [15, 17, 23].

Speaking of high-grade glioma, despite the efforts made in research on new therapeutics, the last WHO classification of CNS tumors from year 2016 brought about some changes (**Table 1**) [7].

Demarcation of glioma borders is a subject of comprehensive research, considering that it is difficult to clearly define the line between tumor and healthy brain tissue macroscopically or with today available imaging techniques like functional MRI (fMRI), positron emission tomography (PET), spectroscopy, and diffusion tensor imaging (DTI) [6, 17, 24]. Contemporary neurophysiology plays a very important role in guidance of brain tumor surgery [17]. For tumors located in proximity to critical functional areas, the use of intraoperative electrostimulation

Other astrocytic tumors (often referred as “circumscribed gliomas”)	
WHO I	
<ul style="list-style-type: none">• Pilocytic astrocytoma	
WHO II	
<ul style="list-style-type: none">• Pleomorphic xanthoastrocytoma	
WHO III	
<ul style="list-style-type: none">• Anaplastic pleomorphic xanthoastrocytoma	
Diffuse astrocytic and oligodendroglial tumors (often referred as “diffuse gliomas”)	
WHO II	
<ul style="list-style-type: none">• Diffuse astrocytoma, IDH-mutant• Diffuse astrocytoma, IDH-wild type• Diffuse astrocytoma, NOS• Oligodendroglioma, IDH-mutant and 1p/19q-codeleted†• Oligodendroglioma, NOS	
WHO III (anaplastic)	
<ul style="list-style-type: none">• Anaplastic astrocytoma, IDH-mutant• Anaplastic astrocytoma, IDH-wild type• Anaplastic astrocytoma, NOS• Anaplastic oligodendroglioma, IDH-mutant and 1p/19q-codeleted• Anaplastic oligodendroglioma, NOS	
	WHO IV
	<ul style="list-style-type: none">• Glioblastoma, IDH-wild type• Glioblastoma, IDH-mutant• Glioblastoma, NOS• Diffuse midline glioma, H3 K27M-mutant
	Ependymal tumors
	WHO I
	<ul style="list-style-type: none">• Subependymoma• Myxopapillary ependymoma
	WHO II
	<ul style="list-style-type: none">• Ependymoma
	WHO II or III
	<ul style="list-style-type: none">• Ependymoma, RELA fusion-positive• WHO III• Anaplastic ependymoma
	Neuronal and mixed neuronal-glial tumors
	<ul style="list-style-type: none">• Diffuse leptomeningeal glioneuronal tumor
	WHO I
	<ul style="list-style-type: none">• Dysembryoplastic neuroepithelial tumor• Ganglioglioma• Gangliocytoma• Dysplastic gangliocytoma of cerebellum (Lhermitte-Duclos)
	WHO III
	<ul style="list-style-type: none">• Anaplastic ganglioglioma

IDH, isocitrate dehydrogenase; NOS, not otherwise specified; RELA, reticuloendotheliosis viral oncogene homolog A [7].
† The last WHO classification of CNS tumors brought about some changes based on molecular findings.

Table 1. Simplified and modified from WHO 2016 classification of neuroepithelial tissue tumors.

mapping (IEM) during awake craniotomy helps to maximize the extent of resection and to minimize the risk of permanent neurological morbidity, allowing a substantial increase in the survival and quality of life of patients [14, 17, 25].

5. Is there hope

Primary brain tumors remain hard and challenging work despite the progress in understanding their genetics and technological progress that enabled safe and extensive tumor resection [3, 15, 17]. As gliomas include a variety of different histological tumor types and malignancy grades, contemporary achievements in terms of molecular imaging have given us a unique

chance for a comprehensive interdisciplinary assessment of the glioma pathophysiology, with direct implications in terms of the medical and surgical treatment strategies available for patients [26]. The concept of individualized surgery in brain tumor neurosurgery, that is, specifically in neurooncology of glial tumors is actually based on the goal to provide as radical tumor resection as possible, without causing (additional) neurological deficit (**Figure 2**) [27].

Unfortunately, the prognosis of patients with grade IV malignant glioma particularly recurrent is dismal, and there is currently no effective therapy, but there are some promising agents as vaccine immunotherapy or recombinant nonpathogenic poliorhinovirus chimera (PVSRIPO) [28, 29]. Desjardins et al. have recently reported that overall survival among the patients who received PVSRIPO immunotherapy was higher at 24 and 36 months than the rate among controls [29]. Extension of surgical excision is still an important predictor of outcome. Achieving a gross total resection of the tumor without significant complication requires a thorough understanding of available surgical approaches [15, 17, 30–32]. For majority of those patients, short-course radiotherapy with concurrent and adjuvant TMZ will bring a benefit, while gain from bevacizumab is limited [13]. There have been some ideas that certain antiepileptics also have a favorable effect on the outcome with glioma patients, but these studies have not given affirmative results [33]. To provide a highly personalized medicine, we will also have to make additional effort toward molecular neuropathology [30].

What do we want to see in the future? A patient from the supposed risk group will be scanned with MRI spectroscopy, 7T MRI, or similar MRI prototype. At the level of a robot medical center, needle biopsy of tumor will be performed, which will be followed by oncogenomic characterization of lesion, with gene map reading and defining. Research in the field of stem cells also has an important place and implications in the future. By way of stem cells, a specific

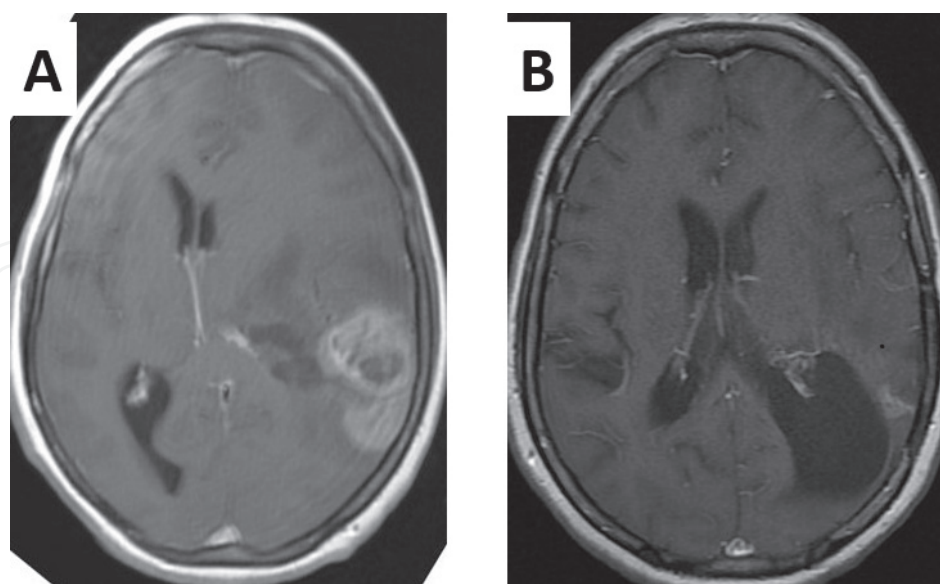


Figure 2. Contrast-enhanced axial T1 MRI scan of 54-year-old female patient with IDH-mutant glioblastoma. (A) Preoperative MRI and (B) 4 years after extensive surgical resection, followed with TMZ and radiotherapy treatment. Small part of recurrent tumor is visible 50 months after initial resection. Patient is still without any neurological deficit.

medicine will be produced, individualized for the particular patient, and in a microcapsule, it will be implanted into the brain zone affected by tumor, by way of robot surgery and injection needle. These are not at all unrealistic expectations in the next decade or two. Perhaps a bit futuristic, but it is also realistic to expect vaccination against glioma [28], that is, specific repair stem cells that will recognize the “glioma-damaged” part of the brain and thus preventively work on it, before the growth of tumor itself.

It is not too much to expect that the current generation of neurooncologists will resolve glioma problem for ever. We should bravely carry on. Time is brain.

Acknowledgements

The book is based on the research, experience, and collaboration of 55 colleagues from 10 countries around the world, from four continents. I would like to give them credit for the effort and for the benefit to the civilization, and would like to thank them very sincerely for the contribution to this small step toward resolving the enigma called brain glioma.

Author details

Ibrahim Omerhodžić

Address all correspondence to: ibrahimomerhodzic74@gmail.com

Department of Neurosurgery, Sarajevo University Clinical Center, Sarajevo, Bosnia and Herzegovina

References

- [1] Allin CM. A case of supposed glioma. Occurring in the clinic of Dr. Erskine Mason, at the New York eye and ear infirmary. Transactions of the American Ophthalmological Society. 1870;**1**(7):70-72
- [2] Ostrom QT, Gittleman H, Liao P, et al. CBTRUS statistical report: Primary brain and other central nervous system tumors diagnosed in the United States in 2010-2014. Neuro-Oncology. 2017;**19**(suppl_5):v1-v88. DOI: 10.1093/neuonc/nox158
- [3] Lapointe S, Perry A, Butowski NA. Primary brain tumours in adults. Lancet. 2018;**392**(10145):432-446. DOI: 10.1016/S0140-6736(18)30990-5
- [4] Lu VM, Jue TR, McDonald KL, Rovin RA. The survival effect of repeat surgery at glioblastoma recurrence and its trend: A systematic review and meta-analysis. World Neurosurgery. 2018;**115**:453-459.e3. DOI: 10.1016/j.wneu.2018.04.016

- [5] Waqar M, Hanif S, Rathi N, et al. Diagnostic challenges, management and outcomes of midline low-grade gliomas. *Journal of Neuro-Oncology*. 2014;**120**:389-398. DOI: 10.1007/s11060-014-1563-6
- [6] Ono Y, Chernov MF, Muragaki Y, Maruyama T, Abe K, Iseki H. Imaging of intracranial gliomas. In: Chernov MF, Muragaki Y, Kesari S, McCutcheon IE, editors. *Intracranial Gliomas. Part I—Surgery. Progress in Neurological Surgery*. Vol. 30. Basel: Karger; 2018. pp. 12-62. DOI: 10.1159/000464376
- [7] Louis DN, Perry A, Reifenberger G, et al. The 2016 World Health Organization classification of tumors of the central nervous system: A summary. *Acta Neuropathologica*. 2016;**131**(6):803-820. DOI: 10.1007/s00401-016-1545-1
- [8] Weller M, Van den Bent M, Tonn JC, et al. European Association for Neuro-Oncology (EANO) guideline on the diagnosis and treatment of adult astrocytic and oligodendroglial gliomas. *European Association for Neuro-Oncology (EANO) Lancet Oncology*. 2017;**18**(6):e315-e329. DOI: 10.1016/S1470-2045(17)30194-8
- [9] Siegal T. Clinical impact of molecular biomarkers in gliomas. *Journal of Clinical Neuroscience*. 2015;**22**(3):437-444. DOI: 10.1016/j.jocn.2014.10.004
- [10] Kirsten L, Kornblum HI. Molecular markers in glioma. *Journal of Neuro-Oncology*. 2017;**134**(3):505-512. DOI: 10.1007/s11060-017-2379-y
- [11] Brat DJ, Verhaak RGW, Aldape KD, et al. Comprehensive, integrative genomic analysis of diffuse lower-grade gliomas. *The cancer genome atlas research network. The New England Journal of Medicine*. 2015;**372**(26):2481-2498. DOI: 10.1056/NEJMoa1402121
- [12] Baumert BG, Hegi ME, van den Bent MJ, et al. Temozolomide chemotherapy versus radiotherapy in high-risk low-grade glioma (EORTC 22033-26033): A randomised, open-label, phase 3 intergroup study. *The Lancet Oncology*. 2016;**17**(11):1521-1532. DOI: 10.1016/S1470-2045(16)30313-8
- [13] Van den Bent MJ, Klein M, Smits M, et al. Bevacizumab and temozolomide in patients with first recurrence of WHO grade II and III glioma, without 1p/19q co-deletion (TAVAREC): A randomised controlled phase 2 EORTC trial. *The Lancet Oncology*. 2018;**19**(9):1170-1179. DOI: 10.1016/S1470-2045(18)30362-0
- [14] Ghinda CD, Duffau H. Network plasticity and intraoperative mapping for personalized multimodal management of diffuse low-grade gliomas. *Frontiers in Surgery*. 2017;**4**:3. DOI: 10.3389/fsurg.2017.00003
- [15] Lee RP, Foster KA, Lillard JC, et al. Surgical and molecular considerations in the treatment of pediatric thalamopeduncular tumors. *Journal of Neurosurgery. Pediatrics*. 2017;**20**(3):247-255. DOI: 10.3171/2017.4.PEDS16668
- [16] Omerhodzic I. Brain tumors in teens—how to deal with strange pathological findings. In: American Association of Neurological Surgeons (AANS), 86th Annual Scientific Meeting; April 28–May 2, 2018; New Orleans, LA, USA. Available from: https://education.aans.org/products/2018-aans-international-symposium?utm_source=email&utm_

medium=email&utm_campaign=email&utm_content=10-30-2018%20LMS&_zs=eVxPe1&_zl=AduG5#tab-product_tab_contents__51

- [17] Saito T, Tamura M, Chernov MF, Ikuta S, Muragaki Y, Maruyama T. Neurophysiological monitoring and awake craniotomy for resection of intracranial gliomas. In: Chernov MF, Muragaki Y, Kesari S, McCutcheon IE, editors. Intracranial Gliomas. Part I—Surgery. Progress in Neurological Surgery. Vol. 30. Basel: Karger; 2018. pp. 117-158. DOI: 10.1159/000464387
- [18] Nayak L, Panageas KS, Reiner AS, et al. Radiotherapy and temozolomide for anaplastic astrocytic gliomas. *Journal of Neuro-Oncology*. 2015;**123**(1):129-134. DOI: 10.1007/s11060-015-1771-8
- [19] Lee KJ, Marchan E, Peterson J, et al. Management and survival of adult patients with pilocytic astrocytoma in the National Cancer Database. *World Neurosurgery*. 2018;**112**:e881-e887. DOI: 10.1016/j.wneu.2018.01.208
- [20] Akyerli CB, Yüksel S, Can O, et al. Use of telomerase promoter mutations to mark specific molecular subsets with reciprocal clinical behavior in IDH mutant and IDH wild-type diffuse gliomas. *Journal of Neurosurgery*. 2018;**128**(4):1102-1114. DOI: 10.3171/2016.11.JNS16973
- [21] Eckel-Passow JE, Lachance DH, Molinaro AM, et al. Glioma groups based on 1p/19q, IDH, and TERT promoter mutations in tumors. *The New England Journal of Medicine*. 2015;**372**(26):2499-2508. DOI: 10.1056/NEJMoa1407279
- [22] Buckner JC, Shaw EG, Pugh SL, et al. Radiation plus procarbazine, CCNU, and vincristine in low-grade glioma. *The New England Journal of Medicine*. 2016;**374**(14):1344-1355. DOI: 10.1056/NEJMoa1500925
- [23] Al-Tamimi YZ, Palin MS, Patankar T, et al. Low-grade glioma with foci of early transformation does not necessarily requires adjuvant therapy after radical surgical resection. *World Neurosurgery*. 2018;**110**:e346-e354. DOI: 10.1016/j.wneu.2017.10.172
- [24] Verburg N, Pouwels PJ, Boellaard R, et al. Accurate delineation of glioma infiltration by advanced PET/ MR neuro-imaging (FRONTIER study): A diagnostic study protocol. *Neurosurgery*. 2016;**79**(4):535-540. DOI: 10.1227/NEU.0000000000001355
- [25] Brennum J, Engelmann CM, Thomsen JA, Skjøth-Rasmussen J. Glioma surgery with intraoperative mapping—Balancing the onco-functional choice. *Acta Neurochirurgica*. 2018;**160**(5):1043-1050. DOI: 10.1007/s00701-018-3521-0
- [26] Rofes A, Mandonnet E, Godden J, et al. Survey on current cognitive practices within the European low-grade glioma network: Towards a European assessment protocol. *Acta Neurochirurgica*. 2017;**159**(7):1167-1178. DOI: 10.1007/s00701-017-3192-2
- [27] Omerhodzic I. Posterior fossa lesions—Pathology gives surprises when you least expect them. In: World Academy of Neurological Surgery (WANS), Annual Meeting;

17-20 August 2017; Istanbul, Turkey (This work has in part been presented at the EANS Congress Athens 2016 and the WFNS Congress Istanbul 2017)

- [28] Oh T, Sayegh ET, Fakurnejad S, et al. Vaccine therapies in malignant glioma. *Current Neurology and Neuroscience Reports*. 2015;**15**(1):508. DOI: 10.1007/s11910-014-0508-y
- [29] Desjardins A, Gromeier M, Herndon JE II. Recurrent glioblastoma treated with recombinant poliovirus. *The New England Journal of Medicine*. 2018;**379**(2):150-161. DOI: 10.1056/NEJMoa1716435
- [30] Sim HW, Morgan ER, Mason WP. Contemporary management of high-grade gliomas. *CNS Oncology*. 2018;**7**(1):51-65. DOI: 10.2217/cns-2017-0026
- [31] Cikla U, Swanson KI, Tümtürk A, et al. Microsurgical resection of tumors of the lateral and third ventricles: Operative corridors for difficult-to-reach lesions. *Journal of Neuro-Oncology*. 2016;**130**:331-340. DOI: 10.1007/s11060-016-2126-9
- [32] Aghi MK, Nahed BV, Sloan AE, Ryken TC, Kalkanis SN, Olson JJ. The role of surgery in the management of patients with diffuse low grade glioma. *Journal of Neuro-Oncology*. 2015;**125**(3):503-530. DOI: 10.1007/s11060-015-1867-1
- [33] Huppold C, Gorlia T, Chinot O, et al. Does valproic acid or levetiracetam improve survival in glioblastoma? A pooled analysis of prospective clinical trials in newly diagnosed glioblastoma. *Journal of Clinical Oncology*. 2016;**34**(7):731-739. DOI: 10.1200/JCO.2015.63.6563

IntechOpen

