

# We are IntechOpen, the world's leading publisher of Open Access books Built by scientists, for scientists

6,900

Open access books available

186,000

International authors and editors

200M

Downloads

Our authors are among the

154

Countries delivered to

TOP 1%

most cited scientists

12.2%

Contributors from top 500 universities



WEB OF SCIENCE™

Selection of our books indexed in the Book Citation Index  
in Web of Science™ Core Collection (BKCI)

Interested in publishing with us?  
Contact [book.department@intechopen.com](mailto:book.department@intechopen.com)

Numbers displayed above are based on latest data collected.  
For more information visit [www.intechopen.com](http://www.intechopen.com)



---

# Intraoperative Ultrasound of the Liver: Actual Status and Indications

---

Adrian Bartoș, Ioana Iancu, Caius Breazu and Dana Bartoș

Additional information is available at the end of the chapter

<http://dx.doi.org/10.5772/intechopen.73856>

---

## Abstract

Intraoperative liver ultrasound represents an essential component in the hepatobiliary surgery arsenal, having an essential role in describing liver lesions, their topography, and loco-regional extension. It also has an important role in establishing surgical strategy, in modulating the surgeon decisions, and thus in preventing postoperative complications. This chapter tries to make a synthetic review of principal indications for using ultrasound in liver surgical treatment, underlining the liver's lesions characteristics and advantages brought by this method. Also, we wanted to underline the importance that ultrasound has for guiding the surgeon in interventional intraoperative techniques or in any anatomical liver resection. The role of enhanced contrast intraoperative ultrasound is put in front by the better diagnostic results obtained for both primary and metastatic tumors of the liver.

**Keywords:** intraoperative ultrasound, liver tumors, contrast enhanced ultrasound

---

## 1. Introduction: brief history

The main advantage of the ultrasound imaging method is the real-time visualization of the anatomy and structure of the liver lesions, allowing for the adaptation of the therapeutic decision during surgery.

The concept of intraoperative ultrasound (IOUS) was first introduced in the 60s and was used to evaluate renal lithiasis when doing nephrolithotomy. Due to the limitations of A-mode ultrasonography (difficulty in interpreting images), IOUS began to be more applicable in the surgical sphere later, in the early 80s [1], when high-frequency real-time B mode-ultrasound was introduced [2]. The use of IOUS in hepato-bilio-pancreatic surgery was emphasized for

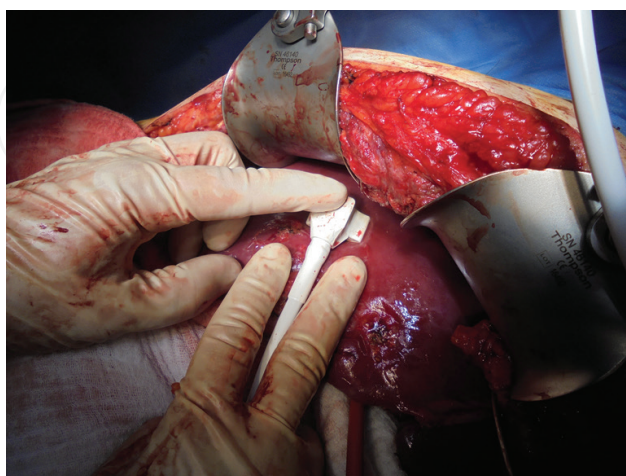
the first time in the literature in the mid-80s [3]; later, it became an exploratory technique routinely performed in specialized centers for staging liver disease and guiding surgical procedures on patients diagnosed with hepatocarcinoma on cirrhotic liver [4–7]. Studies in the 90s showed that the information provided by IOUS may modify the initial therapeutic plan in up to 53% of cases [8, 9].

Although first reports related to laparoscopic transducers used in A-mode date back to early 1964, the laparoscopic IOUS technique has been developed relatively recent [10].

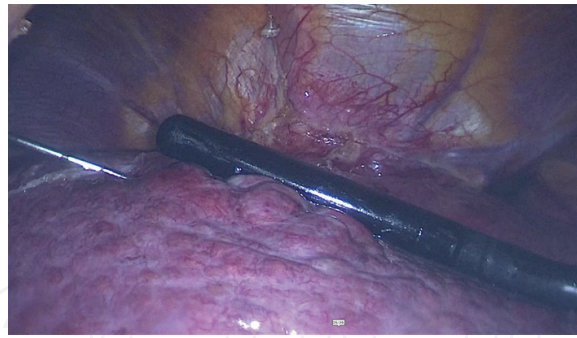
## 2. General aspects

Currently, there is a wide range of equipment for IOUS, probes of different types and shapes, adapted according to the type and localization of the lesion. Standard transducers for trans-abdominal ultrasound can also be used, but there may be some limitations on image resolution and on the large size of the transducer that do not offer optimal maneuverability [1]. Conventional transducers can be used at the beginning of the liver examination to obtain an overview of the organ anatomy [1, 11]. The transducers used in IOUS usually operate at high frequency: 7.5–10 MHz [12]. There are different shapes: linear T-shaped probes, interdigital probes, microconvex probes and more recently, T-shaped probes with trapezoidal scanning window [13]. In case of liver surgery, the ideal transducer should be a small one that can be easily manipulated in narrow spaces, with a special design to allow the probe to be held in the palm between two fingers, thus allowing the operator to have permanent contact with the surface of the liver, without omitting to scan some areas [11, 14] (**Figure 1**).

When necessary, IOUS can also be used in laparoscopic surgery, with special transducers suitable for this type of approach. Transducers used during laparoscopic surgery are either linear or curved, mounted at the end of a long, thin articulated arm, with a design that allows insertion and manipulation inside the trocar (**Figure 2**) [15].



**Figure 1.** Scanning the liver surface with a intraoperative mini-convex probe, 1–13 MHz, 65°, Hitachi Aloka Medical, Ltd., Japan (intraoperative aspect, from the personal archive of the authors).



**Figure 2.** Intraoperative laparoscopic ultrasound of the liver. HCC on cirrhotic liver. L44LA intraoperative probe, 13–2 MHz, 36 mm, Hitachi Aloka Medical, Ltd., Japan (intraoperative aspect, from the personal archive of the authors).

The possibility of performing intra-operative contrast ultrasound (CE-IOUS) is an important factor in choosing the ultrasound equipment. Nowadays, the most commonly used contrast agents are SonoVue (Gaseous sulfur hexafluoride, Bracco, Milan Italy) and Sonazoid (Gaseous perflutane, GE Healthcare, Norway/DaiichiSankyo, Japan) [11, 16–19].

In order to ensure a good examination, the ultrasound machine should be positioned in front of the main operator, the patient (the organ to be examined) being located between the surgeon and the monitor (a collinearity between operator, organ and monitor) in order to view simultaneously the ultrasound monitor and the surgical field. The ultrasound monitor should have size and resolution large enough to allow optimal remote viewing. Examination must always begin with the inspection and palpation of the liver and of the entire peritoneal cavity. These steps should not be avoided in favor of IOUS [20]. Mobilization of the liver begins with the sectioning of suspensory ligaments, thus creating enough space to manipulate the ultrasound transducer. Worth mentioning some of the artifacts that may appear on the examination of the VIIIth and IVa liver segments after the sectioning of the cavo-hepatic adhesions. Therefore, in the case of suspected lesions located in these areas (adjacent to the cavo-hepatic region), dissection at this level should be performed only after ultrasound exploration.

### 3. IOUS of the liver: benign tumors

Benign tumors can develop on a normal or steatotic liver, may be solitary or multiple, with increased echogenicity (hemangiomas, focal nodular hyperplasia) or anechogenic, with posterior acoustic strengthening (serous cysts) and distinct contours (hydatid cysts), with no vascularization or characteristic circulatory pattern; may have a mass effect on liver structures or even adjacent organs. A characteristic for benign tumors is the fact that they have elastic consistency and do not invade vascular elements [20, 21].

*Hemangiomas* are benign tumors, mostly asymptomatic, incidentally discovered. These tumors can present themselves under various echographic aspects; most commonly, are well-defined, round, hyperechoic, homogeneous, usually small (<3 cm), and may present the posterior acoustic strengthening effect [22]. As hemangiomas grow in size, they can change their echogenicity,

from homogeneous to heterogeneous, with their edges becoming irregular. These features make them more difficult to differentiate from malignant tumor formations. When surgery is indicated, IOUS has the role to localize and visualize the relationships of the hemangioma with the intrahepatic structures. The surgeon can trace the hepatic resection line outside the hemangioma, minimizing hemorrhagic risk, and preserving the healthy hepatic parenchyma to its full potential. The CE-IOUS can be useful, capturing the contrast agent by the hemangioma being most of the time characteristic. Differentiation from malignant tumor formation becomes difficult for arterial hemangiomas or for those with arterio-venous shunts [21].

For *focal nodular hyperplasia*, the central location of a fibrous scar is characteristic. This tumor appears as a well-defined lesions with variable size, usually unique, of solid consistency and inhomogeneous structure. Rarely, the central scar can be distinguished when using simple ultrasound, without contrast agent. When using CE-IOUS, in the arterial phase, there is a central filling followed by a complete capture in the venous phase. At this stage, the center of the tumor becomes hypoechoic. In the late phase, the tumor remains isogenic together with the hepatic parenchyma, which strengthens the diagnosis of benign lesion [21].

*Hepatic adenoma* appears ecographically as a well-defined solid tumor lesion; it may have an inhomogeneous structure in the presence of intratumoral hemorrhage. Doppler ultrasound does not detect a vascular signal. When using CE-IOUS, in the arterial phase, there is a centripetal and inconsistent capture; in the venous phase, a moderate washout may be noted. In the late phase, the appearance is isoechoic or hyperechoic [21].

Differentiation between focal nodular hyperplasia and hepatic adenoma is important for establishing the therapeutic indication, surgery being indicated for large adenomas, due to the risk of rupture and hemorrhage as well as due to its malignant potential.

Because sometimes it is difficult to make a benign-malignant US differentiation, intraoperative, when the situation imposes, might by necessary to make a bioptic puncture for establishing a correct diagnosis [20]. IOUS has an important guiding role, especially in the case of lesions located in the depth of the liver parenchyma, hard to reach when palpating.

*Simple hepatic cysts (biliary cysts)* are benign tumors with no malignant potential, usually asymptomatic, that can be easily diagnosed with ultrasound imaging. They are described by ultrasound as well-defined lesions with very thin walls, no Doppler signal, anechoic, with transonic content due to the liquid composition. Simple hepatic cysts have therapeutic indications only when they become symptomatic, often due to symptoms related to the mass effect they have on neighboring structures.

Percutaneous ultrasound guided treatment with cyst evacuation is often possible, but is followed by an increased risk of relapse, with the rebound of collection. In this idea, the laparoscopic surgical resection of the cystic dome is indicated. This technique is easy if the lesions are located superficially, in segments II, III, IVB, V, VI (after Couinaud) [23]. The lesions localized intraparenchymatous can be approached safely only when using IOUS [24].

Depending on the evolutionary stage, *hydatid cysts* may appear as single or multiple lesions, anechoic, with membranes and sediment inside, with thin or calcified walls. They may be multilocular or may contain multiple fluid compartments (daughter vesicles). IOUS helps the surgeon in finding the cysts and in some situations it can detect bile duct communication. These lesions



can compress the intrahepatic vessels with mass effect, signs of invasion, or embedding of these structures being absent [21]. IOUS has the same indications as in the case of simple cysts, being a real help for the surgeon, for establishing surgical tactics and for checking the radicality of the treatment (the content of the remaining cavity, residual content, multilocular abscesses, etc.) [25].

## **4. IOUS of the liver: malignant tumor**

IOUS finds its usefulness in liver surgery for both primary and secondary malignant lesions facilitating the detection, characterization of lesions and guiding the surgical procedure [26, 27]. Most studies have evaluated the role of IOUS for treatment of hepatocarcinomas and hepatic metastases due to colorectal cancer, these pathologies being considered the most common liver malignant lesions. Intraoperative detection and local treatment of these lesions may have a major impact in choosing surgical strategy [28, 29].

### **4.1. Hepatocarcinoma (HCC)**

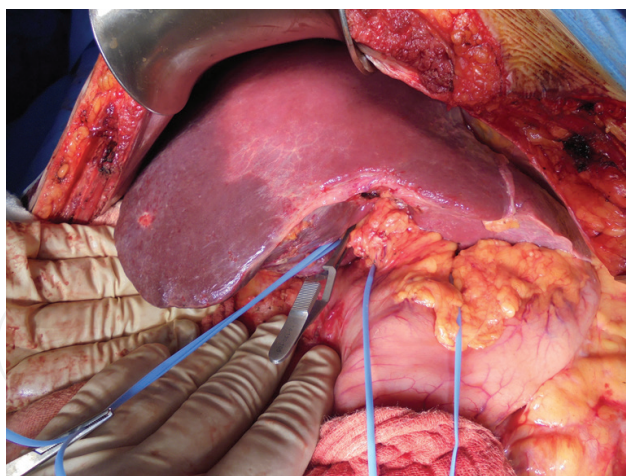
HCC is the most common primary malignancy in the liver, and is frequently associated with cirrhosis [30, 31].

Ecographically, this tumor has the appearance of a solid tumor with irregular contours, heterogeneous, uni-, or multilocular ("encephaloid form"). Typically, it invades the liver vessels, primarily the portal branches, but also the suprahepatic veins. Doppler screening usually highlights a high-speed arterial flow. Vessel distribution is irregular, disordered. CE-US shows hypercaptation in the arterial phase with a specific "washout" of contrast substance in the venous phase. In the late phase, the tumor appears as hypoechoic. This behavior is usually described in tumor nodules larger than 2 cm [21].

In the case of HCC, IOUS is superior in detecting lesions measuring less than 1 cm, preoperative MRI having a lower sensitivity and specificity for these lesions [11, 32]. It has also been shown in several studies that CE-IOUS can modify in 19–29% of the cases the initial treatment plan [33, 34]. CE-IOUS finds its usefulness especially in cirrhotic patients when it comes to differential diagnosis between malignant lesions and regenerative nodules [29, 35]. It has been demonstrated that neoangiogenesis of tumor nodules is a specific criteria for distinguishing hepatocarcinomas from dysplastic or regenerative nodules [35].

CE-IOUS has a sensitivity of 100%, a specificity between 69 and 100% and can modify the surgical strategy in up to 79% of patients [36–38], most frequently by detecting new lesions. The literature emphasizes that the filling pattern of the contrast agent in nodules found by IOUS can guide surgical resection [36]. It has also been shown that the vascular pattern of HCC visualized by using CE-IOUS has been associated with the expression of some genetic profiles, suggesting that CE-IOUS images can be used as an indicator for predicting prognosis of patients [39].

During hepatic resection, which is the standard treatment for HCC, particular attention should be paid in preserving as much hepatic parenchyma as we can, the remaining hepatic volume being an important prognostic factor for the short outcome [37, 39, 40]. Thus, local resection of the tumor formation or its ablation under IOUS guidance may be chosen to minimize the



**Figure 3.** Anatomical resection: ischemic delimitation of sixth and seventh liver segments (intraoperative aspect, from the personal archive of the authors).

volume of resected liver parenchyma, respecting the oncological resection margin. Also, in order to minimize the risk of postoperative complications (hemorrhage, necrosis of the liver parenchyma) and remote relapse (by satellite micrometastases, specific for HCC), the use of IOUS is vital in guiding anatomical resections. These involve the ultrasound identification of vascular pedicles corresponding to the affected hepatic segments and through various associated maneuvers (digital compression, injection of contrast agents) an exact delimitation of the targeted resection area can be obtained (**Figure 3**). More details will be given in the following rows, in the sub-section dedicated to the role of IOUS in guiding hepatic resections.

#### 4.2. Hepatic metastases

Despite significant advances in preoperative staging diagnostic procedures (conventional CE-US, multi-sliced CT, CE-MRI, and PET-CT), studies have shown that 10–30% of the patients with colo-rectal cancer remain with undiagnosed hepatic metastases during primary tumor surgery [41–46].

In this respect, IOUS and CE-IOUS have a special role in completing the diagnosis, in addition to the liver's palpation technique. IOUS is considered the “gold standard” in open surgery for colorectal cancer since 1980, being able to detect liver metastases that cannot be palpated intraoperatively and that have not been visualized with preoperative imaging techniques [8, 47–50].

Liver metastases have a non-characteristic echographic appearance, being circumscribed lesions with imprecise or halo delineation, with a homogeneous or heterogeneous pattern. They may be solitary (usually liver metastases from colonic neoplasms) or multiple. Their echogenicity is variable. When they are large, they can compress the bile ducts (which may appear to be dilated) and the liver vessels. As for their vascularization, they may be hypovascular (in gastric, colon, pancreatic, or ovarian cancers) with hypoechoic pattern in arterial phase and similar in the venous and late phases or hypervascular (neuroendocrine tumors, malignant melanomas, sarcomas, renal tumors, breast, or thyroids), with a hyperechoic appearance during the arterial phase, with wash out during the venous phase and hypoechoic pattern at about 30 s after the injection of the contrast substance [51].

Several studies in the literature have shown that after the surgical treatment of the primary tumor, the ultrasound of metastasis after colorectal cancer can be correlated with prognosis. Thus, Gruenberger et al. [52] demonstrated that in patients with hyperechoic ultrasound liver metastases, survival is longer than in those with the hypoechoic aspect of the lesions. This suggests that the role of IOUS is more than a diagnostic one and can be useful in establishing prognosis [53].

The CE-IOUS applied for colorectal liver metastases has an 96% accuracy, in contrast to 74 and 79%, percentages associated with pre-operative CT and MRI [34, 54]. The fact that undetected preoperative liver metastases represent the main cause of recurrent neoplasia [55] highlights the important role that IOUS has in the management of patients diagnosed with colorectal cancer. This is why routine IOUS is recommended in these patients [56].

Chemotherapy is an important, standardized element in regard with the adjuvant and neo-adjuvant therapy in colorectal cancer patients. [57, 58] Regarding hepatic metastases, good results of cytostatic treatment mean either stagnation or regression of these lesions [59, 60]. A particular situation is when liver metastases are no longer visible in CT and/or MRI performed after chemotherapy. Literature indicates that the complete, real response is found in up to 66% of cases [61, 62]. For the rest of the cases (34%), chemotherapy can affect the echogenicity of the metastases making them difficult to be identified with preoperative imaging (CT, MRI, even IOUS) [13, 33]. In these situations, CE-IOUS allows the surgeon to check areas where hepatic lesions have been described before chemotherapy [11]. The role of this technique is highlighted in many studies that have shown that only the confirmation given by the CE-IOUS in regard with the lack of lesions can be associated with a complete therapeutic response [59, 62].

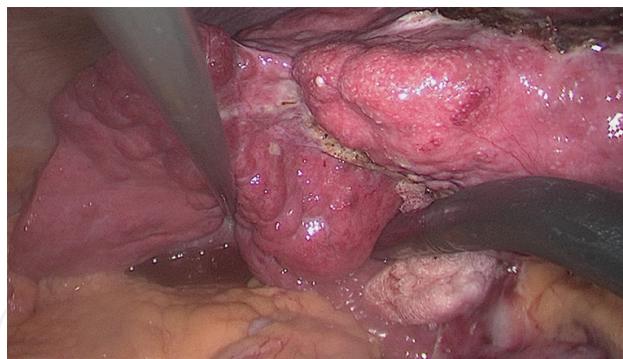Resection or ablation of all lesions is the gold standard in the treatment of colorectal liver metastases [63]. Even in patients with unresectable metastases, local ablation or combination between ablation and surgical resection of the lesions has been shown to be able to locally control the disease [64]. It is obvious that IOUS plays a major role in liver surgery for the detection and localization of metastatic lesions [28].

## 5. The role of laparoscopic approach

The laparoscopic approach and minimally invasive surgery have more and more indications and thus the role of IOUS in laparoscopic surgery has become increasingly important. Of course, laparoscopic surgery has some disadvantages in assessing the liver because the surgeon loses the advantage of palpating the structures and lesions. IOUS manages to compensate for most of these laparoscopic minuses by providing intraoperative high utility imaging with greater sensitivity in detecting liver lesions than most preoperative imaging techniques [65–69]. Intraoperative laparoscopic ultrasound (LIOUS) has a sensitivity and specificity similar to that in open surgery [69]. Several authors have suggested routine use of LIOUS in laparoscopic colorectal surgery [70] and prior to planned laparotomies for liver resections [71]. In cases where hepatic disease is known, with the help of LIOUS data, around 64% of cases could be exempted from laparotomy [71, 72].

The success of the laparoscopic approach depends primarily on the location of the lesions [73, 74]. Guiding surgical maneuvers by the use of LIOUS is possible especially in superficial tumors on the left lobe or on the anterior segments of the right lobe (hepatic segments II, III,





**Figure 4.** Laparoscopic ultrasound guided radiofrequency ablation of HCC on cirrhotic liver (intraoperative aspect, from the personal archive of the authors).

IVb, V, and VI). Direct visualization and LIOUS should be used to compensate for the impossibility of liver palpation in laparoscopic surgery [75, 76]. In the case of laparoscopically treated malignant lesions, it is important to mark by IOUS imaging the oncological resection margins, this way ensuring their tracing by minimally invasive approach. Furthermore, the completion of the treatment is possible using ablative techniques (radiofrequency, microwave). The laparoscopic approach finds its indications especially for higher-risk cirrhotic patients (altered hepatic markers, clotting disorders) with subcapsular neoplastic lesions (**Figure 4**).

With the evolution of technology and the experience of surgical teams, laparoscopic approaches to hepatectomies have become more and more used in centers of excellence. Several studies have shown that laparoscopic hepatectomy is a safe procedure and could have advantages over open surgery, translated by reduced blood loss and a shorter hospitalization stays [77, 78]. As for LIOUS, it should guarantee the same performance as the ultrasound used in conventional liver surgery. Although, LIOUS has been introduced since 1981, few studies have addressed this subject. Although reported to be a safe and accurate method [79], it is currently not routinely used in laparoscopic surgery [80], although the reliability of LIOUS in the staging of liver disease has been demonstrated to be similar to conventional IOUS [81]. Moreover, although many articles mention LIOUS as an important technique, few scientific papers described this technique [82–85].

## 6. Ultrasound-guided techniques

It has been demonstrated that making biopsies under IOUS guidance, laparoscopic or “classic,” have a high diagnostic accuracy and are considered safe procedures with possible impact on surgical management [86, 87]. For example, liver metastases detected intra-operatively and confirmed by histopathological examination as having pancreatic origin could be a contraindication for pancreatic radical surgery [58].

In terms of non-excisional treatment of hepatic tumor formations, this can also be achieved by ablative techniques, such as ethanol injection [88], RFA (coagulation necrosis induced by high-frequency alternating currents-thermal energy) [89] and MWA (same as RFA, although

MWA uses different parts of the electromagnetic spectrum) [90]. Although the elective treatment is by percutaneous approach, there are situations when both classical or laparoscopic method are indicated.

Laparoscopic approach is particularly preferred on patients who are on the waiting list for liver transplantation or for those who cannot benefit from liver resection due to comorbidities, liver cirrhosis, or hepatic dysfunction due to chemotherapy, especially when percutaneous procedures are not possible [91–93]. Indications are subcapsular lesions located in the immediate vicinity of important structures (diaphragm, stomach, and gallbladder) or difficult to approach (caudal lobe). [84, 94–96]. Moreover, these ablation techniques can be combined with hepatic resections or can be performed serially after surgical resections, improving the oncological outcome and prognosis [97–99]. In the majority of cases treated by these procedures, IOUS is used as a guidance tool and for evaluation the efficacy of the treatment and appearance of complications [94].

Multiple studies have demonstrated that IOUS-guided ablations are a safe and an effective treatment option that provides excellent local control of both primary and secondary hepatic tumor lesions [64, 94, 100–102]. Recent studies have also reported that intraoperative RFA has a local recurrence rate equivalent to that obtained from low-grade HCC surgery [11, 96] and colorectal hepatic metastases [64, 100].

## 7. Guiding liver resections

Localization of liver lesions is related to portal branches and suprahepatic veins, which are used to define segmental boundaries. Without the use of IOUS, it would probably be impossible to define correctly, anatomically, the hepatic segments and often the limits of the tumors, especially due to the existence of multiple anatomical variants [13].

Hepatic resections are known to be the standard treatment for malignant liver tumor formations, being the only procedure that provides oncological radicality [58]. Preservation of hepatic parenchyma should be a goal of the surgical team, especially in patients with cirrhotic liver, whose liver function and prognostic could be influenced by extensive resection. In these situations, IOUS plays an essential role because it allows the evaluation of the intrahepatic tumors, facilitating a limited but oncological liver resection. Thus, in modern hepatic surgery, whether HCC or colorectal liver metastases, the use of IOUS allows the realization of the so-called “radical but conservative surgery.” Thus, obtaining continuous information on the relationship between liver lesions and intrahepatic bilio-vascular structures, the surgeon can guide his resection line, respecting the Glisson pedicles, and suprahepatic veins, with the ultimate goal of preserving as much functional hepatic parenchyma as possible [11, 12, 103, 104].

IOUS is also a real help for anatomical resections. This technique involves the compression of segmental portal branches between the transducer and the operator’s fingers, resulting in a transient ischemia of the target parenchyma. This area can be marked with the electrocautery, and then the resection is made along the demarcation line [105–110].

Starting from the use of IOUS, Torzilli introduces new types of resection, such as mini-mesohepatectomy, for tumor formations located at the confluence of the cave vein with superhepatic veins [11, 12, 111]. These resections are based on the ultrasound study of the relationship between the tumor and the suprahepatic veins and the analysis of the blood flow at this level after clamping the proposed vein for resection. Evidence of an inverse flow in the peripheral portion of the compressed vein or of a collateral shunt between the clamped vein and the other superhepatic vein or cava vein will allow the ligation and segregation of the tumor-affected suprahepatic vein and the achievement of a limited resection, while maintaining the principles of oncological radicality [11, 12].

Summarizing, the use of IOUS allows the extension of surgical indications for certain liver lesions that were either considered unresectable or required major surgery [104].

## 8. Future perspectives

IOUS is still characterized by several drawbacks: it cannot detect lesions smaller than 3 mm, its accuracy is dependent on the surgeon's skill and experience, the images are 2D and there is a "blind area" of about 1 cm below the surface of the liver, which is particularly problematic in the case of small hepatic metastases due to colorectal cancer that are mainly located on the surface of the liver. Of course, associating contrast agents has greatly improved IOUS accuracy; however, the disadvantage of visualization of the lesions for a too short period of time makes this technique to be of limited applicability in guiding hepatic resections that may last between 2 and 6 h [112].

Recently, a new fluorescent approach, using indocyanine green (ICG), has been proposed to improve the intraoperative detection of neoplastic lesions [113, 114]. ICG is a non-specific molecule that allows detection of tumor tissue, but with limited specificity. The main advantage of its use is its safety and its commercial availability as a contrast substance. The imaging technique of intraoperative fluorescence using ICG was initially used for the detection of sentinel lymph nodes in patients with gastric, colon, and breast cancer [115, 116]. Several studies have shown that malign liver tumors show strong fluorescence when preoperative ICG administration is made [117, 118]. This technique is based on the fact that ICG binds to plasma proteins and together emit light with a peak wavelength of approximately 830 nm when illuminated with infrared light [119].

Initially, ICG-fluorescence imaging was limited to open surgery alone. After year 2010, as laparoscopic and robotic imaging systems with fluorescence have developed, ICG-fluorescence imaging has been extended to minimally invasive abdominal surgery, especially for the visualization of extrahepatic biliary tract anatomy (during laparoscopic/robotic cholecystectomies) [120], an approach known as fluorescence cholangiography [121]. In 2014, the use of ICG-fluorescence imaging was reported for the identification of subcapsular hepatic tumors before liver transection [122]. A new laparoscopic imaging system is starting to be used, this system overlapping pseudo-color fluorescence images with white color-light images in real-time (fusion ICG-fluorescence imaging) with the proposal to identify segmental hepatic margins and localization of liver tumors [123]. Thus, ICG has the ability to "label" bile ducts

[121, 124–126], hepatic tumors [118, 127–130], edges of liver segments [117, 131–133], this being due both to ICG fluorescence [134], and to its property to be excreted into the bile [135]. Due to the property of being eliminated for more than 6 h after intravenous injection [126, 135], ICG-fluorescence imaging can also be used to identify small biliary fistulas after hepatectomy [136].

As for ICG-fluorescence imaging sensitivity in detecting liver metastases, it varies between 69 and 100%. However, sensitivity is limited because the examination does not have the ability to detect hepatic lesions at a depth greater than 8 mm in the hepatic parenchyma. It has also been shown that this method can detect new metastatic lesions in up to 43% of cases [137]. In fact, it has been reported that ICG-fluorescence imaging can detect superficial lesions of up to 2 mm in both HCC and metastases liver disease due to colorectal cancers [127, 129].

Currently, a combination of a fluorophore, such as ICG, with an anti-tumor antibody is evaluated in preclinical studies. These new molecules could present a major advantage in the future for clinical applications that would allow the detection of tumor lesions with a higher TBR (tumor-to-background ratio between the intensity of fluorescence in tumor tissue and normal surrounding tissue). Recently, Harlaar et al. reported the first clinical trial using IRD-800CW-labeled bevacizumab for the detection of peritoneal metastases of colorectal origin [138].

## 9. Key points

- The IOUS has applications in both open or laparoscopic abdominal surgery.
- For benign hepatic tumors, IOUS has the role to localize and to visualize the relationships with the intrahepatic structures.
- For intraoperative interventional maneuvers (biopsies, ablative techniques), IOUS guidance is mandatory.
- In the case of HCC, IOUS is superior in detecting lesions measuring less than 1 cm.
- In the case of HCC, CE-IIOUS finds its usefulness especially in cirrhotic patients for the differential diagnosis between malignant lesions and regenerative nodules.
- IOUS is considered the “gold standard” in open surgery for colorectal cancer.
- CE-IIOUS allows the surgeon to check areas where hepatic metastasis have been described before chemotherapy.
- IOUS is mandatory for anatomic resections and for limited but radical hepatectomy.

## Acknowledgements

Bartoş Adrian is the coordinator of this chapter.

## Conflict of interest

The authors have no conflict of interest.

## Author details

Adrian Bartoș<sup>1\*</sup>, Ioana Iancu<sup>1,2</sup>, Caius Breazu<sup>3</sup> and Dana Bartoș<sup>1,2</sup>

\*Address all correspondence to: bartos.adi@gmail.com

1 Regional Institute of Gastroenterology and Hepatology, Surgery Department, Cluj-Napoca, Romania

2 Anatomy and Embryology Department, UMF, Cluj-Napoca, Romania

3 Regional Institute of Gastroenterology and Hepatology, ICU Department, Cluj-Napoca, Romania

## References

- [1] Kruskal JB, Kane RA. Intraoperative ultrasonography of the liver. *Critical Reviews in Diagnostic Imaging*. 1995;**36**:175-226
- [2] Makuuchi M, Torzilli G, Machi J. History of intraoperative ultrasound. *Ultrasound in Medicine & Biology*. 1998;**24**:1229-1242
- [3] Staren ED, Gambla M, Deziel DJ, et al. Intraoperative ultrasound in the management of liver neoplasms. *The American Surgeon*. 1997;**63**:591-596
- [4] Adam R, Majno P, Castaing D, et al. Treatment of irresectable liver tumors by percutaneous cryosurgery. *The British Journal of Surgery*. 1998;**85**:1493-1494
- [5] Livraghi T, Giorgio A, Marin G, et al. Hepatocellular carcinoma and cirrhosis in 746 patients: Long-term results of percutaneous ethanol injection. *Radiology*. 1995;**197**:101-108
- [6] Makuuchi M, Yamazaki S, Hasegawa H, et al. Ultrasonically guided liver surgery. *Japanese Journal of Medical Ultrasound Technology*. 1980;**7**:45-49
- [7] Solbiati L, Livraghi T, Goldberg SN, et al. Percutaneous radiofrequency ablation of hepatic metastases from colorectal cancer in 117 patients. *Radiology*. 2001;**221**:159-166
- [8] Luck AJ, Maddern GJ. Intraoperative abdominal ultrasonography. *The British Journal of Surgery*. 1999;**86**:5-16
- [9] Solomon MJ, Stephen MS, Gallinger S, et al. Does intraoperative hepatic ultrasonography change surgical decision making during liver resection? *American Journal of Surgery*. 1994;**168**:307-310



- [10] Yamakawa K, Yoshioka A, Shimizu K, et al. Laparoechography: An ultrasonic diagnosis under laparoscopic observation. *Japanese Journal of Medical Ultrasound Technology*. 1964;**2**:26
- [11] Donadon M, Costa G, Torzilli G. State of the art of intraoperative ultrasound in liver surgery: Current use for staging and resection guidance. *Ultraschall in der Medizin*. 2014;**35**:500-511
- [12] Torzilli G, Procopio F, Fabbro D. Technological requirements for ultrasound-guided liver surgery. In: Torzilli G, editor. *Ultrasound-Guided Liver Surgery*. Italia: Springer; 2014. pp. 3-14
- [13] Donadon M, Torzilli G. Intraoperative ultrasound in patients with hepatocellular carcinoma: From daily practice to future trends. *Liver Cancer*. 2013;**2**:16-24
- [14] Patel N, Roh M. Utility of intraoperative liver ultrasound. *Surgical Clinics of North America*. 2004;**84**:513-524
- [15] Horwhat JD, Gress F. Defining the diagnostic algorithm in pancreatic cancer. *Journal of the Pancreas*. 2004;**5**:289-303
- [16] von Herbay A, Westendorff J, Gregor M. Contrastenhanced ultrasound with SonoVue: Differentiation between benign and malignant focal liver lesions in 317 patients. *Journal of Clinical Ultrasound*. 2010;**38**:1-9
- [17] Trillaud H, Bruel JM, Valette PJ, Vilgrain V, Schmutz G, et al. Characterization of focal liver lesions with SonoVue®-enhanced sonography: International multicenter-study in comparison to CT and MRI. *World Journal of Gastroenterology*. 2009;**15**:3748-3756
- [18] Luo W, Numata K, Kondo M, Morimoto M, Sugimori K. Sonazoid-enhanced ultrasonography for evaluation of the enhancement patterns of focal liver tumors in the late phase by intermittent imaging with a high mechanical index. *Journal of Ultrasound in Medicine*. 2009;**28**:439-448
- [19] Imazu H, Uchiyama Y, Matsunaga K, Ikeda K, Kakutani H, et al. Contrast-enhanced harmonic EUS with novel ultrasonographic contrast (Sonazoid) in the preoperative T-staging for pancreaticobiliary malignancies. *Scandinavian Journal of Gastroenterology*. 2010;**45**:732-738
- [20] Machi J, Staren E. Intraoperative ultrasound of the liver. In: Machi J, editor. *Ultrasound for Surgeons*. Vol. 15. Philadelphia: Lippincott Williams & Wilkins; 2005. pp. 341-343
- [21] Badea R, Ioanimescu S. Ultrasound imaging of liver tumors—Current clinical applications. In: *Liver Tumors*. Vol. 5. Croatia: InTech; 2012. pp. 75-102
- [22] Kim KW, Kim TK, Han JK, et al. Hepatic hemangiomas: Spectrum of US appearances on gray-scale, power Doppler, and contrast-enhanced US. *Korean Journal of Radiology*. 2000;**1**:191-197
- [23] Couinaud C. Surgical anatomy of the liver. Several new aspects. *Chirurgie*. 1986;**112**:337-342

- [24] Mulholland M, Hussain H, Fritze D. Hepatic Cyst Disease. In: Yeo C, McFadden D, editors. Shackelford's Surgery of the Alimentary Tract. Philadelphia: Elsevier; 2013. pp. 1453-1462
- [25] Bartos A, Betea I, Bartos D. Intraoperative ultrasound: Applications in digestive surgery. *Sonography*. 2016;**1**:3-16
- [26] Nanashima A, Tobinaga S, Abo T, Kunizaki M, Takeshita H, Hidaka S, et al. Usefulness of sonazoid-ultrasonography during hepatectomy in patients with liver tumors: A preliminary study. *Journal of Surgical Oncology*. 2011;**103**:152-157
- [27] Zacherl J, Scheuba C, Imhof M, Zacherl M, Langle F, Pokieser P, et al. Current value of intraoperative sonography during surgery for hepatic neoplasms. *World Journal of Surgery*. 2002;**26**:550-554
- [28] Schulz A, Dormagen JB, Drolsum A, Bjornbeth BA, Labori KJ, Klow NE. Impact of contrast-enhanced intraoperative ultrasound on operation strategy in case of colorectal liver metastasis. *Acta Radiologica*. 2012;**53**:1081-1087
- [29] Torzilli G, Olivari N, Moroni E, Del Fabbro D, Gambetti A, Leoni P, et al. Contrast-enhanced intraoperative ultrasonography in surgery for hepatocellular carcinoma in cirrhosis. *Liver Transplantation*. 2004;**10**(2 Suppl 1):S34-S38
- [30] Yuen MF, Hou JL, Chutaputti A, Asia Pacific Working Party on Prevention of Hepatocellular Carcinoma. Hepatocellular carcinoma in the Asia Pacific region. *Journal of Gastroenterology and Hepatology*. 2009;**24**:346-353
- [31] Nagaoki Y, Hyogo H, Aikata H, Tanaka M, Naeshiro N, Nakahara T, et al. Recent trend of clinical features in patients with hepatocellular carcinoma. *Hepatology Research*. 2012;**42**:368-375
- [32] Hammerstingl R, Huppertz A, Breuer J, Balzer T, Blakeborough A. Diagnostic efficacy of gadoxetic acid (Primovist)-enhanced MRI and spiral CT for a therapeutic strategy: Comparison with intraoperative and histopathologic findings in focal liver lesions. *European Radiology*. 2008;**18**:457-467
- [33] Leen E, Ceccotti P, Moug SJ, Glen P, MacQuarrie J. Potential value of contrast-enhanced intraoperative ultrasonography during partial hepatectomy for metastases: An essential investigation before resection? *Annals of Surgery*. 2006;**243**:236-240
- [34] Bartos A, Iancu C. Tratamenteul chirurgical al cancerului colo-rectal cu metastaze hepatice rezecabile. In: Grigorescu M, Irimie A, Beuran M, editors. *Tratat de Oncologie Digestivă*. III. Bucuresti: Editura Academiei Române. 2015:425-433
- [35] Roncalli M, Roz E, Coggi G, Di Rocco MG, Bossi P, et al. The vascular profile of regenerative and dysplastic nodules of the cirrhotic liver: Implications for diagnosis and classification. *Hepatology*. 1999;**30**:1174-1178
- [36] Torzilli G, Palmisano A, Del Fabbro D, Marconi M, Donadon M, Spinelli A, Bianchi PP, Montorsi M. Contrast-enhanced intraoperative ultrasonography during surgery for hepatocellular carcinoma in liver cirrhosis: Is it useful or useless? A prospective cohort study of our experience. *Annals of Surgical Oncology*. 2007;**14**:1347-1355

- [37] Lu Q, Luo Y, Yuan CX, Zeng Y, Wu H, Lei Z, Zhong Y, Fan YT, Wang HH, Luo Y. Value of contrast-enhanced intraoperative ultrasound for cirrhotic patients with hepatocellular carcinoma: A report of 20 cases. *World Journal of Gastroenterology*. 2008;**14**:4005-4010
- [38] Wu H, Lu Q, Luo HXL, Zeng Y. Application of contrast-enhanced intraoperative ultrasonography in the decision-making about hepatocellular carcinoma operation. *World Journal of Gastroenterology*. 2010;**16**:508-512
- [39] Kaibori M, Matsui Y, Kitade H, Kwon AH, Kamiyama Y. Hepatic resection for hepatocellular carcinoma in severely cirrhotic livers. *Hepato-Gastroenterology*. 2003;**50**:491-496
- [40] Ezaki T, Yamamoto K, Yamaguchi H, Sasaki Y, Ishida T, Mori M, et al. Hepatic resection for hepatocellular carcinoma existing with liver cirrhosis. *Hepato-Gastroenterology*. 2002;**49**:1363-1368
- [41] van de Velde CJ, Boelens PG, Borrás JM, Coebergh JW, Cervantes A, Blomqvist L, et al. EURECCA colorectal: Multidisciplinary management: European consensus conference colon & rectum. *European Journal of Cancer*. 2014;**50**:e1-e34
- [42] De Greef K, Rolfo C, Russo A, Chapelle T, Bronto G, Passiglia F, et al. Multidisciplinary management of patients with liver metastases from colorectal cancer. *World Journal of Gastroenterology*. 2016;**22**:7215-7225
- [43] GI Cancer [Internet]. 2013. Available from: [www.GICancer.dk/kliniske retningslinier for kolorektal lever metastaser](http://www.GICancer.dk/kliniske_retningslinier_for_kolorektal_lever_metastaser) [Accessed: June 01, 2016]
- [44] Finlay IG, McArdle CS. Occult hepatic metastases in colorectal carcinoma. *The British Journal of Surgery*. 1986;**73**:732-735
- [45] Bonanni L, De'liguori Carino N, Deshpande R, Ammori BJ, Sherlock DJ, Valle JW, et al. A comparison of diagnostic imaging modalities for colorectal liver metastases. *European Journal of Surgical Oncology: The Journal of the European Society of Surgical Oncology and the British Association of Surgical Oncology*. 2014;**40**:545-550
- [46] Takeuchi N, Ramirez JM, Mortensen NJ, Cobb R, Whittlestone T. Intraoperative ultrasonography in the diagnosis of hepatic metastases during surgery for colorectal cancer. *International Journal of Colorectal Disease*. 1996;**11**:92-95
- [47] Machi J, Sigel B. Operative ultrasound in general surgery. *American Journal of Surgery*. 1996;**172**:15-20
- [48] Cervone A, Sardi A, Conaway GL. Intraoperative ultrasound (IOUS) is essential in the management of metastatic colorectal liver lesions. *The American Surgeon*. 2000;**66**:611-615
- [49] Elias D, Sideris L, Pocard M, de Baere T, Dromain C, Lassau N, et al. Incidence of unsuspected and treatable metastatic disease associated with operable colorectal liver metastases discovered only at laparotomy (and not treated when performing percutaneous radiofrequency ablation). *Annals of Surgical Oncology*. 2005;**12**:298-302
- [50] Larsen LP, Rosenkilde M, Christensen H, Bang N, Bolvig L, Christiansen T, et al. The value of contrast enhanced ultrasonography in detection of liver metastases from colorectal cancer: A prospective double-blinded study. *European Journal of Radiology*. 2007;**62**:302-307

- [51] Larsen LPS. Role of contrast enhanced ultrasonography in the assessment of hepatic metastases: A review. *World Journal of Hepatology*. 2010;**2**(1):8-15
- [52] Gruenberger T, Jourdan JL, Zhao J, et al. Echogenicity of liver metastases is an independent prognostic factor after potentially curative treatment. *Archives of Surgery*. 2000;**135**:1285-1290
- [53] Seifert J, Morris D. Pretreatment echogenicity of colorectal liver metastases predicts survival after hepatic cryotherapy. *Diseases of the Colon and Rectum*. 1999;**42**:43-49
- [54] Winter J, Auer AC. Metastatic malignant liver tumors: Colorectal cancer. In: Jarnagin WR, editor. *Blumgart's Surgery of the Liver, Biliary Tract and Pancreas*. 5th ed. Vol. 2. Philadelphia: Elsevier Saunders; 2012. pp. 1290-1304
- [55] Yoshidome H, Kimura F, Shimizu H, Ohtsuka M, Kato A, et al. Interval period tumor progression: does delayed hepatectomy detect occult metastases in synchronous colorectal liver metastases? *Journal of Gastrointestinal Surgery: Official Journal of the Society for Surgery of the Alimentary Tract*. 2008;**12**:1391-1398
- [56] Claudon M, Dietrich CF, Choi BI, Cosgrove DO, Kudo M, et al. Guidelines and good clinical practice recommendations for contrast enhanced ultrasound (CEUS) in the liver—Update 2012: A WFUMB-EFSUMB initiative in cooperation with representatives of AFSUMB, AIUM, ASUM, FLAUS and ICUS. *Ultrasound in Medicine & Biology*. 2013;**39**:187-210
- [57] National Comprehensive Cancer Network Guidelines version 2. 2016. Rectal Cancer; 2016. [www.ncc.org](http://www.ncc.org) [Accessed: 2017]
- [58] National Comprehensive Cancer Network Guidelines version 1. 2016. Pancreatic Adenocarcinoma; 2016. [www.ncc.org](http://www.ncc.org) [Accessed: 2017]
- [59] Joo I. The role of intraoperative ultrasonography in the diagnosis and management of focal hepatic lesions. *Ultrasonography*. 2015;**34**:246-257
- [60] Garden OJ, Rees M, Poston GJ, Mirza D, Saunders M. Guidelines for resection of colorectal cancer liver metastases. *Gut*. 2006;**55**(iii):1-8
- [61] Auer RC, White RR, Kemeny NE, Schwartz LH, Shia J. Predictors of a true complete response among disappearing liver metastases from colorectal cancer after chemotherapy. *Cancer*. 2010;**116**:1502-1509
- [62] Ferrero A, Langella S, Russolillo N, Vigano L, Lo Tesoriere R, et al. Intraoperative detection of disappearing colorectal liver metastases as a predictor of residual disease. *Journal of Gastrointestinal Surgery: Official Journal of the Society for Surgery of the Alimentary Tract*. 2012;**16**:806-814
- [63] Penna C, Nordlinger B. Surgery of liver metastases from colorectal cancer: New promises. *British Medical Bulletin*. 2002;**64**:127-140
- [64] Mulier S, Ni Y, Jamart J, Michel L, Marchal G, Ruers T. Radiofrequency ablation versus resection for resectable colorectal liver metastases: Time for a randomized trial? *Annals of Surgical Oncology*. 2008;**15**:144-157

- [65] Cuschieri A. Laparoscopic management of cancer patients. *Journal of the Royal College of Surgeons of Edinburgh*. 1995;**40**:1-9
- [66] Hunderbein M, Rau B, Schlag PM. Laparoscopy and laparoscopic ultrasound for staging of upper gastrointestinal tumors. *European Journal of Surgical Oncology*. 1995;**21**:50-55
- [67] Gouma DJ, De Wit LT, Nieveen van Dijkum E, et al. Laparoscopic ultrasonography for staging of gastrointestinal malignancy. *Scandinavian Journal of Gastroenterology. Supplement*. 1996;**218**:43-49
- [68] Goletti O, Bucciante P, Chiarugi M, et al. Laparoscopic sonography in screening metastases from gastrointestinal cancer: Comparative accuracy with traditional procedures. *Surgical Laparoscopy & Endoscopy*. 1995;**5**:176-182
- [69] Tandan VR, Asch M, Margolis M, et al. Laparoscopic vs. open intraoperative ultrasound examination of the liver: A controlled study. *Journal of Gastrointestinal Surgery*. 1997;**1**:146-151
- [70] Hartley JE, Kumar H, Drew PJ, et al. Laparoscopic ultrasound for the detection of hepatic metastases during laparoscopic colorectal cancer surgery. *Diseases of the Colon and Rectum*. 2000;**43**:320-324
- [71] Barbot DJ, Marks JH, Feld RI, et al. Improved staging of liver tumors using laparoscopic intraoperative ultrasound. *Journal of Surgical Oncology*. 1997;**64**:63-67
- [72] John TG, Greig JD, Crosbie JL, et al. Superior staging of liver tumors with laparoscopy and laparoscopic ultrasound. *Annals of Surgery*. 1994;**220**:711-719
- [73] Biertho L, Waage A, Gagner M. Hepatectomies sous laparoscopie. *Annales de Chirurgie*. 2002;**127**:164-170
- [74] Cherqui D, Husson E, Hammoud R, Malassagne B, Ste'phan F, Bensaid S, Rotman N, Fagniez PL. Laparoscopic liver resections: A feasibility study in 30 patients. *Annals of Surgery*. 2000;**232**:753-762
- [75] Gigot JF, Glineur D, et al. Laparoscopic liver resection for malignant liver tumors: Preliminary results of a multicenter European study. *Annals of Surgery*. 2003;**236**:90-97
- [76] Berends FJ, Meijer S, Prevoo W, Bonjer HJ, Cuesta MA. Technical considerations in laparoscopic liver surgery: A solid organ easily forgotten? *Surgical Endoscopy*. 2000;**15**:794-798
- [77] Nguyen KT, Laurent A, Dagher I, Geller DA, Steel J, Thomas MT, Marvin M, Ravindra KV, Mejia A, Lainas P, Franco D, Cherqui D, Buell JF, Gamblin TC. Minimally invasive liver resection for metastatic colorectal cancer: A multi-institutional, international report of safety, feasibility, and early outcomes. *Annals of Surgery*. 2009;**250**:842-848
- [78] Croome KP, Yamashita MH. Laparoscopic vs open hepatic resection for benign and malignant tumors: An updated metaanalysis. *Archives of Surgery*. 2010;**145**:1109-1118
- [79] Machi J, Johnson JO, Deziel DJ, Soper NJ, Berber E, Siperstein A, Hata M, Patel A, Singh K, Arregui ME. The routine use of laparoscopic ultrasound decreases bile duct injury: A multicenter study. *Surgical Endoscopy*. 2009;**23**:384-388



- [80] Vapenstad C, Rethy A, Langø T, Selbekk T, Ystgaard B, Hernes TA, Marvik R. Laparoscopic ultrasound: A survey of its current and future use, requirements, and integration with navigation technology. *Surgical Endoscopy*. 2010;**24**:2944-2953
- [81] Vigano` L, Ferrero A, Amisano M, Russolillo N, Capussotti L. Comparison of laparoscopic and open intraoperative ultrasonography for staging liver tumours. *The British Journal of Surgery*. 2013;**100**:535-542
- [82] Araki K, Conrad C, Ogiso S, Kuwano H, Gayet B. Intraoperative ultrasonography of laparoscopic hepatectomy: Key technique for safe liver transection. *Journal of the American College of Surgeons*. 2014;**218**:e37-e41
- [83] Silas AM, Kruskal JB, Kane RA. Intraoperative ultrasound. *Radiologic Clinics of North America*. 2001;**39**:429-448
- [84] Kim HO, Kim SK, Son BH, Yoo CH, Hong HP, Cho YK, et al. Intraoperative radiofrequency ablation with or without tumorectomy for hepatocellular carcinoma in locations difficult for a percutaneous approach. *Hepatobiliary & Pancreatic Diseases International*. 2009;**8**:591-596
- [85] Crucitti A, Danza FM, Antinori A, Vincenzo A, Pirulli PG, Bock E, et al. Radiofrequency thermal ablation (RFA) of liver tumors: Percutaneous and open surgical approaches. *Journal of Experimental & Clinical Cancer Research*. 2003;**22**(4 Suppl):191-195
- [86] Charnley RM, Sheffield JP, Hardcastle JD. Evaluation of a biopsy gun for guided biopsy of impalpable liver lesions using intraoperative ultrasound. *HPB Surgery*. 1990;**2**:265-267
- [87] Mortensen MB, Frstrup C, Ainsworth A, Pless T, Larsen M, Nielsen H, et al. Laparoscopic ultrasound-guided biopsy in uppergastrointestinal tract cancer patients. *Surgical Endoscopy*. 2009;**23**:2738-2742
- [88] Koda M, Murawaki Y, Mitsuda A, Oyama K, Okamoto K, Idobe Y, et al. Combination therapy with transcatheter arterial chemoembolization and percutaneous ethanol injection compared with percutaneous ethanol injection alone for patients with small hepatocellular carcinoma: A randomized control study. *Cancer*. 2001;**92**:1516-1524
- [89] Kim YS, Rhim H, Lim HK, Choi D, Lee MW, Park MJ. Coagulation necrosis induced by radiofrequency ablation in the liver: Histopathologic and radiologic review of usual to extremely rare changes. *Radiographics*. 2011;**31**:377-390
- [90] Iannitti DA, Martin RC, Simon CJ, Hope WW, Newcomb WL, McMasters KM, et al. Hepatic tumor ablation with clustered microwave antennae: The US Phase II trial. *HPB: The Official Journal of the International Hepato Pancreato Biliary Association*. 2007;**9**:120-124
- [91] Howard JH, Tzeng CW, Smith JK, Eckhoff DE, Bynon JS. Radiofrequency ablation for unresectable tumors of the liver. *The American Surgeon*. 2008;**74**:594-600
- [92] Seidenfeld J, Korn A, Aronson N. Radiofrequency ablation of unresectable liver metastases. *Journal of the American College of Surgeons*. 2002;**195**:378-386

- [93] Curley SA, Marra P, Beaty K, Ellis LM, Vauthey JN. Early and late complications after radiofrequency ablation of malignant liver tumors in 608 patients. *Annals of Surgery*. 2004;**239**:450-458
- [94] Machi J, Uchida S, Sumida K, Limm WM, Hundahl SA, Oishi AJ, et al. Ultrasound-guided radiofrequency thermal ablation of liver tumors: Percutaneous, laparoscopic, and open surgical approaches. *Journal of Gastrointestinal Surgery*. 2001;**5**:477-489
- [95] Ishiko T, Beppu T, Sugiyama S, Masuda T, Takahashi M, Komori H, et al. Radiofrequency ablation with hand-assisted laparoscopic surgery for the treatment of hepatocellular carcinoma in the caudate lobe. *Surgical Laparoscopy, Endoscopy & Percutaneous Techniques*. 2008;**18**:272-276
- [96] El-Gendi A, El-Shafei M, Abdel-Aziz F, Bedewy E. Intraoperative ablation for small HCC not amenable for percutaneous radiofrequency ablation in Child A cirrhotic patients. *Journal of Gastrointestinal Surgery*. 2013;**17**:712-718
- [97] Razafindratsira T, Isambert M, Evrard S. Complications of intraoperative radiofrequency ablation of liver metastases. *HPB: The Official Journal of the International Hepato Pancreato Biliary Association*. 2011;**13**:15-23
- [98] Park IJ, Kim HC, Yu CS, Kim PN, Won HJ, Kim JC. Radiofrequency ablation for metachronous liver metastasis from colorectal cancer after curative surgery. *Annals of Surgical Oncology*. 2008;**15**:227-232
- [99] Cheung TT, Ng KK, Chok KS, Chan SC, Poon RT, Lo CM, et al. Combined resection and radiofrequency ablation for multifocal hepatocellular carcinoma: Prognosis and outcomes. *World Journal of Gastroenterology*. 2010;**16**:3056-3062
- [100] Leblanc F, Fonck M, Brunet R, Becouarn Y, Mathoulin-Pelissier S, Evrard S. Comparison of hepatic recurrences after resection or intraoperative radiofrequency ablation indicated by size and topographical characteristics of the metastases. *European Journal of Surgical Oncology*. 2008;**34**:185-190
- [101] Eng OS, Tsang AT, Moore D, Chen C, Narayanan S, Gannon CJ, et al. Outcomes of microwave ablation for colorectal cancer liver metastases: A single center experience. *Journal of Surgical Oncology*. 2015;**111**:410-413
- [102] Stattner S, Jones RP, Yip VS, Buchanan K, Poston GJ, Malik HZ, et al. Microwave ablation with or without resection for colorectal liver metastases. *European Journal of Surgical Oncology*. 2013;**39**:844-849
- [103] Donadon M, Procopio F, Torzilli G. Tailoring the area of hepatic resection using inflow and outflow modulation. *World Journal of Gastroenterology*. 2013;**19**:1049-1055
- [104] Torzilli G, Procopio F. State of the art of intraoperative ultrasound in liver surgery: Current use for resection-guidance. *Chirurgia*. 2017;**112**:320-325
- [105] Torzilli G, Procopio F, Costa G. Resection guidance. In: Torzilli G, editor. *Ultrasound-Guided Liver Surgery*. Italia: Springer; 2014. pp. 117-168

- [106] Xiang C, Liu Z, Dong J, Sano K, Makuuchi M. Precise anatomical resection of the ventral part of Segment VIII. *International Journal of Surgery Case Reports*. 2014;**5**:924-926
- [107] Torzilli G, Procopio F, Palmisano A, Donadon M, Del Fabbro D. Total or partial anatomical resection of segment 8 using the ultrasound-guided finger compression technique. *HPB: The Official Journal of the International Hepato Pancreato Biliary Association*. 2011;**13**:586-591
- [108] Torzilli G, Procopio F, Palmisano A, Cimino M, Del Fabbro D. New technique for defining the right anterior section intraoperatively using ultrasound-guided finger counter-compression. *Journal of the American College of Surgeons*. 2009;**209**:e8-11
- [109] Torzilli G, Makuuchi M. Ultrasound-guided finger compression in liver subsegmentectomy for hepatocellular carcinoma. *Surgical Endoscopy*. 2004;**18**:136-139
- [110] Torzilli G, Donadon M, Cimino M, Del Fabbro D, Procopio F. Systematic subsegmentectomy by ultrasound-guided finger compression for hepatocellular carcinoma in cirrhosis. *Annals of Surgical Oncology*. 2009;**16**:1843
- [111] Torzilli G, Donadon M, Palmisano A, Del Fabbro D, Spinelli A. Back-flow bleeding control during resection of right-sided liver tumors by means of ultrasound-guided finger compression of the right hepatic vein at its caval confluence. *Hepato-Gastroenterology*. 2007;**54**:1364-1367
- [112] Peloso A, Franchi E, et al. Combined use of intraoperative ultrasound and indocyanine green fluorescence imaging to detect liver metastases from colorectal cancer. *HPB*. 2013;**15**:928-934
- [113] Uchiyama K, Ueno M, Ozawa S, Kiriya S, Shigekawa Y, Yamaue H. Combined use of contrast-enhanced intraoperative ultrasonography and a fluorescence navigation system for identifying hepatic metastases. *World Journal of Surgery*. 2010;**34**:2953-2959
- [114] Frangioni JV. In vivo near-infrared fluorescence imaging. *Current Opinion in Chemical Biology*. 2003;**7**:626-634
- [115] Noura S, Ohue M, Seki Y, et al. Feasibility of a lateral region sentinel node biopsy of lower rectal cancer guided by indocyanine green using a near-infrared camera system. *Annals of Surgical Oncology*. 2010;**17**:144-151
- [116] Murawa D, Hirche C, Dresel S, et al. Sentinel lymph node biopsy in breast cancer guided by indocyanine green fluorescence. *The British Journal of Surgery*. 2009;**96**:1289-1294
- [117] Aoki T, Yasuda D, Shimizu Y, et al. Image-guided liver mapping using fluorescence navigation system with indocyanine green for anatomical hepatic resection. *World Journal of Surgery*. 2008;**32**:1763-1767
- [118] Gotoh K, Yamada T, Ishikawa O, et al. A novel image-guided surgery of hepatocellular carcinoma by indocyanine green fluorescence imaging navigation. *Journal of Surgical Oncology*. 2009;**100**:75-79

- [119] Kikuchi M, Hosokawa K. Near-infrared fluorescence venography: A navigation system for varicose surgery. *Dermatologic Surgery*. 2009;**35**:1495-1498
- [120] Spinoglio G, Priora F, Bianchi PP, Lucido FS, Licciardello A, Maglione V, Grosso F, Quarati R, Ravazzoni F, Lenti LM. Real-time near-infrared (NIR) fluorescent cholangiography in single-site robotic cholecystectomy (SSRC): A single-institutional prospective study. *Surgical Endoscopy*. 2013;**27**:2156-2162
- [121] Ishizawa T, Bandai Y, Kokudo N. Fluorescent cholangiography using indocyanine green for laparoscopic cholecystectomy: An initial experience. *Archives of Surgery*. 2009;**144**:381-382
- [122] Kudo H, Ishizawa T, Tani K, Harada N, Ichida A, Shimizu A, Kaneko J, Aoki T, Sakamoto Y, Sugawara Y, Hasegawa K, Kokudo N. Visualization of subcapsular hepatic malignancy by indocyanine-green fluorescence imaging during laparoscopic hepatectomy. *Surgical Endoscopy*. 2014;**28**:2504-2508
- [123] Terasawa M, Ishizawa T, et al. Applications of fusion-fluorescence imaging using indocyanine green in laparoscopic hepatectomy. *Surgical Endoscopy*. 2017;**31**(12):5111-5118. DOI: 10.1007/s00464-017-5576-z
- [124] Ishizawa T, Tamura S, Masuda K, Aoki T, Hasegawa K, Imamura H, Beck Y, Kokudo N. Intraoperative fluorescent cholangiography using indocyanine green: A biliary road map for safe surgery. *Journal of the American College of Surgeons*. 2008;**208**:e1-e4
- [125] Mitsuhashi N, Kimura F, Shimizu H, Imamaki M, Yoshidome H, Ohtsuka M, Kato A, Yoshitomi H, Nozawa S, Furukawa K, Takeuchi D, Takayashiki T, Suda K, Igarashi T, Miyazaki M. Usefulness of intraoperative fluorescence imaging to evaluate local anatomy in hepatobiliary surgery. *Journal of Hepato-Biliary-Pancreatic Surgery*. 2008;**15**:508-514
- [126] Ishizawa T, Bandai Y, Ijichi M, Kokudo N. Fluorescent cholangiography illuminating the biliary tree during laparoscopic cholecystectomy. *The British Journal of Surgery*. 2010;**97**:1369-1377
- [127] Ishizawa T, Fukushima N, Shibahara J, Masuda K, Tamura S, Aoki T, Hasegawa K, Beck Y, Fukayama M, Kokudo N. Real-time identification of liver cancers by using indocyanine green fluorescent imaging. *Cancer*. 2009;**115**:2491-2504
- [128] Yokoyama N, Otani T, Hashidate H, Maeda C, Katada T, Sudo N, Manabe S, Ikeno Y, Toyoda A, Katayanagi N. Real-time detection of hepatic micrometastases from pancreatic cancer by intraoperative fluorescence imaging: Preliminary results of a prospective study. *Cancer*. 2012;**118**:2813-2819
- [129] van der Vorst JR, Schaafsma BE, Hutteman M, Verbeek FP, Liefers GJ, Hartgrink HH, Smit VT, CW Löwik, van de Velde CJ, Frangioni JV, Vahrmeijer AL. Near-infrared fluorescence-guided resection of colorectal liver metastases. *Cancer*. 2013;**119**(18):3411-3418

- [130] Ishizawa T, Masuda K, Urano Y, Kawaguchi Y, Satou S, Kaneko J, Hasegawa K, Shibahara J, Fukayama M, Tsuji S, Midorikawa Y, Aburatani H, Kokudo N. Mechanistic background and clinical applications of indocyanine green-fluorescence imaging of hepatocellular carcinoma. *Annals of Surgical Oncology*. 2014;**21**:440-448
- [131] Ishizawa T, Zuker NB, Kokudo N, Gayet B. Positive and negative staining of hepatic segments by use of fluorescent imaging techniques during laparoscopic hepatectomy. *Archives of Surgery*. 2012;**147**:393-394
- [132] Inoue Y, Arita J, Sakamoto T, Ono Y, Takahashi M, Takahashi Y, Kokudo N, Saiura A. Anatomical liver resections guided by 3-dimensional parenchymal staining using fusion indocyanine green fluorescence imaging. *Annals of Surgery*. 2015;**262**(1):105-111
- [133] Miyata A, Ishizawa T, Tani K, Shimizu A, Kaneko J, Aoki T, Sakamoto Y, Sugawara Y, Hasegawa K, Kokudo N. Reappraisal of a dye-staining technique for anatomic hepatectomy by the concomitant use of indocyanine green fluorescence imaging. *Journal of the American College of Surgeons*. 2015;**221**:e27-e36
- [134] Landsman ML, Kwant G, Mook GA, Zijlstra WG. Lightabsorbing properties, stability, and spectral stabilization of indocyanine green. *Journal of Applied Physiology*. 1976;**40**:575-583
- [135] Cherrick GR, Stein SW, Leevy CM, Davidson C. Indocyanine green: Observations on its physical properties, plasma decay, and hepatic extraction. *The Journal of Clinical Investigation*. 1960;**39**:592-600
- [136] Kaibori M, Ishizaki M, Matsui K, Kwon AH. Intraoperative indocyanine green fluorescent imaging for prevention of bile leakage after hepatic resection. *Surgery*. 2011;**150**(1):91-98
- [137] Liberale G, Bourgeois P. Indocyanine green fluoresce-guided surgery after IV injection in metastatic colorectal cancer: A systematic review. *European Journal of Surgical Oncology*. 2017;**43**:1656-1667
- [138] Harlaar NJ, Koller M, de Jongh SJ, et al. Molecular fluorescence-guided surgery of peritoneal carcinomatosis of colorectal origin: A single-centre feasibility study. *The Lancet Gastroenterology & Hepatology*. 2016;**1**:283-290