

We are IntechOpen, the world's leading publisher of Open Access books Built by scientists, for scientists

6,900

Open access books available

186,000

International authors and editors

200M

Downloads

Our authors are among the

154

Countries delivered to

TOP 1%

most cited scientists

12.2%

Contributors from top 500 universities



WEB OF SCIENCE™

Selection of our books indexed in the Book Citation Index
in Web of Science™ Core Collection (BKCI)

Interested in publishing with us?
Contact book.department@intechopen.com

Numbers displayed above are based on latest data collected.
For more information visit www.intechopen.com



Disorders of Sleep and Motor Control During the Impaired Cholinergic Innervation in Rat – Relevance to Parkinson's Disease

Jasna Saponjic, Jelena Petrovic, Jelena Ciric and Katarina Lazic

Additional information is available at the end of the chapter

<http://dx.doi.org/10.5772/62949>

Abstract

The medical profession has been generally very slow to acknowledge the importance of sleep medicine and sleep research. Disorders of sleep are related to anxiety, many mental and neurodegenerative diseases, cardiovascular and respiratory disorders, and obesity.

Our knowledge of the neural substrates of sleep/wake states and sleep-related behavior disorders regulation in health and the diseases, over more than 50 years of sleep research, is based on the experiments in animal models, pharmacotherapy, and the neuropathological studies in humans. But, we still need further work in fundamental multidisciplinary and clinical research between sleep and neurodegenerative disease investigators to understand normal and abnormal sleep, and to provide new insights into preventive or disease-altering approaches for therapy.

Our aim is to give an overview of our recent results related to the importance of thalamo-cortical cholinergic brain system in the disorders of sleep and motor control during sleep, with particular relevance to Parkinson's disease.

Keywords: sleep, motor control, the pedunculopontine tegmental nucleus (PPT), excitotoxic lesion, rat

1. Introduction

1.1. Importance of sleep research

The medical profession has been generally very slow to acknowledge the importance of sleep medicine and sleep research. The tendency to sleep less — perhaps 20% less in industrialized countries than a century ago — has serious consequences for economy and public safety. According to US National Science Foundation data, 75% of patients report sleep problems, but less than one-third were asked by their doctors about it, and one-third of American drivers admit to having nodded off behind the wheel [1]. Furthermore, the mounting body of evidence links lack of sleep to anxiety, many mental and neurodegenerative diseases [2–4], cardiovascular and respiratory disorders [5, 6], and obesity [7–9].

On the other hand, our knowledge of the neural substrates for sleep/wake states and sleep-related behavior disorders regulation in health and the diseases, over more than 50 years of sleep research, is based on the experiments in animal models, pharmacotherapy, central nervous system lesions, and the neuropathological studies in humans [2].

But, we still do not know why we sleep [10], and only further work in fundamental multidisciplinary and clinical research between sleep and neurodegenerative disease investigators is promising to enable us understand normal and abnormal sleep, and to provide new insights into preventive or disease-altering approaches for therapy.

1.2. Sleep and neurodegenerative diseases

Sleep is a complex, global and reversible behavioral state of all mammals, that is homeostatically regulated [11, 12]. It is also defined as a rapidly reversible state of immobility and reduced sensory responsiveness [12]. Still, there is no definition that has succeeded in satisfying all aspects of sleep. The failure to define sleep as a single behavior lies in several facts [11, 13]: (1) sleep is not a homogenous state, but continuum of a number of mixed states; (2) the control mechanisms of sleep are manifested at all levels of biological organization - from genes and intracellular mechanisms to the networks of neuronal populations within the central nervous system that control movement, arousal, autonomic functions, behavior and cognition; (3) the activity and interactions of these neurochemically greatly heterogeneous neuronal populations are dependent on two nested biological rhythms — the circadian rhythm of wake/sleep and about 90 minutes long periodic cycles of non-rapid-eye-movement (NREM)/ rapid-eye-movement (REM) sleep as two main sleep states [11–13].

Brain neurodegenerative diseases, like Alzheimer's (AD), and Parkinson's (PD) diseases, are devastating and rather common diseases. According to Nussbaum and Ellis [14] their prevalence is 0.5–1%; increasing to 1–3% for PD, and up to 50% for AD in ages over 69. In spite of a long knowledge of their clinical description and brain pathology (lesions of the cholinergic neurons in basal forebrain, lesions of the dopaminergic neurons in substantia nigra, etc.), they remain incurable with only limited success in temporal amelioration of their symptoms. Their symptoms are either cognitive (dementia in AD), or motor (tremor and bradykinesia in PD) or eventually both, and with age they progress to affective and cognitive deterioration as

well as autonomic and sleep related behavioral disturbances. Clinical symptoms first appear at 65–69 years on average, but there are indications that subclinical features may start many years earlier. Namely, the patients with REM sleep behavior disorder (RBD) face close to a 20% 5-year risk of developing PD or dementia, and that risk rises to more than 40% after 10 years, and exceeds 50% after 12 years.

It is well known that human development, maturation, healthy aging [15, 16], and many neurological diseases [2] are associated with profound changes in sleep/wake states distribution and with variety of the sleep-related behavioral disorders. Neurodegenerative diseases such as AD and PD involve the selective loss of specific neuronal populations within the brain. Human studies evidenced that sleep/wake cycle disturbance, as no cognitive symptom of dementia, precedes on average 3 years before the clinical diagnosis of the AD [17], and that RBD, reflecting an underlying synucleinopathy neurodegeneration, precedes as a symptom the onset of motor and cognitive disturbances by years or decades, with presence of the α – synuclein protein pathology within the REM sleep-related regulatory structures of the dorsal midbrain and pons at the onset of disease, with ascending pattern of neurodegeneration progression from brainstem to basal areas of the brain [3].

1.3. Sleep and the brain cholinergic systems

Generally, the activation state of mammalian neocortex is regulated by a complex interplay of cortical and subcortical neuronal networks. Slow EEG oscillations are present in isolated neocortical tissue, while high-frequency oscillations (β and γ frequency oscillations) are not, suggesting a dependence on subcortical impulse flow [18]. The cholinergic afferent fibers system originating in the basal forebrain plays a critical role in switching cortical activity from deactivated slow to high-frequency, activated EEG patterns. Inputs to the cortex originated in the thalamus constitute the second major system involved in regulation of the cortical activity, and the pedunculopontine tegmental nucleus (PPT - the cholinergic nucleus within the pons; the main thalamo-cortical cholinergic source of innervation) efferent fibers exert, through the thalamus, widespread control over neocortical EEG activation during waking and REM sleep. Because direct projections from the PPT reach both the basal forebrain and thalamus, this nucleus is an ideal candidate to study the integrated contributions of these two systems to regulating activation of the neocortex [18]. PPT is postulated to have important functions relevant to the regulation of REM sleep [19, 20], arousal [21–29], and various motor control systems [30–32], including breathing control [33–38]. In addition, the PPT has a central role in the REM sleep phenomenon control [39–41], and each individual REM-sleep-sign generating nucleus receives afferent inputs from PPT [28].

Degeneration of the PPT thalamo-cortical cholinergic neurons was related to RBD [42], and to the motor control impairment, including falls in PD [43, 44.] Recent PET imaging [45] and neuropathological studies [44] suggested that the neurodegeneration of thalamic cholinergic afferent projections may contribute to the PD specific motor and cognitive abnormalities [45]. Clinical studies also evidenced the beneficial effect of AChE inhibitor donepezil in 50% reduction of falls in PD patients [46], and suggested that PD is a neurodegeneration of different CNS systems [44].

Obviously, counseling and prevention of AD or PD would be highly enriched by the development of a practical, sensitive and reliable methodology for detecting those patients with RBD, or other sleep disorders who are at risk for developing AD or PD.

In this chapter we will give an overview of our results in the animal studies related to the importance of thalamo-cortical cholinergic brain system (the PPT cholinergic neurons) in the disorders of sleep and motor control during sleep, which is of particular relevance to PD.

2. Experimental procedure in the animal studies of the impaired PPT cholinergic control

2.1. The rat model of impaired PPT cholinergic innervation

In our studies we used the bilateral PPT lesioned rats as the “*in vivo*” model of the severe thalamo-cortical cholinergic neuropathology. We followed the sleep/wake states architecture and transition structure, the EEG microstructure and motor control across sleep, and all the sleep state episodes dynamics. Adult, male, Wistar rats were chronically implanted for sleep recording [47, 48]. During operative procedure for the stereotaxic implantation of the EEG and EMG electrodes the bilateral PPT lesions were performed by the stereotaxically guided microinfusion of 100 nl of 0.1 M ibotenic acid/ 0.1 M phosphate buffered saline into the PPT of each brain side [49–53].

The animals were maintained on a 12-hour light-dark cycle, and were housed at 25°C with free access to food and water, and all experimental procedures were in accordance with the EEC Directive (86/609/EEC) on the protection of animals used for experimental and other scientific purposes, and were approved by the Ethical Committee for the Use of Laboratory Animals of the Institute for Biological Research "Sinisa Stankovic", University of Belgrade (Approval N° 2-21/10).

2.2. Surgical procedure of the chronic electrodes implantation for sleep recording in rat

We implanted under ketamine/diazepam anesthesia (Zoletil 50, VIRBAC, France, 50 mg/kg; i.p.), in 2.5 months old rats, 4 epidural parietal stainless-steel screw electrodes for electroencephalographic (EEG) cortical activity recording: 2 in the motor (MCx; A/P: +1.0 mm from bregma; R/L: 2.0 mm from sagittal suture), and 2 in the sensorimotor (SMCx; A/P: -3.0 mm from bregma; R/L: 2.0 mm from sagittal suture) cortex [54]. Bilateral electromyogram (EMG) stainless steel teflon coated wire electrodes (Medwire, NY, USA) were implanted into the dorsal nuchal musculature to assess skeletal muscle activity, and a stainless-steel screw electrode was implanted in the nasal bone. All the electrode leads were soldered to a miniature connector plug (39F1401, Newark Electronics, Schaumburg, IL, USA), and the assembly was fixed to the screw electrodes and skull using acrylic dental cement (Biocryl-RN, Galenika a.d. Beograd, Serbia).

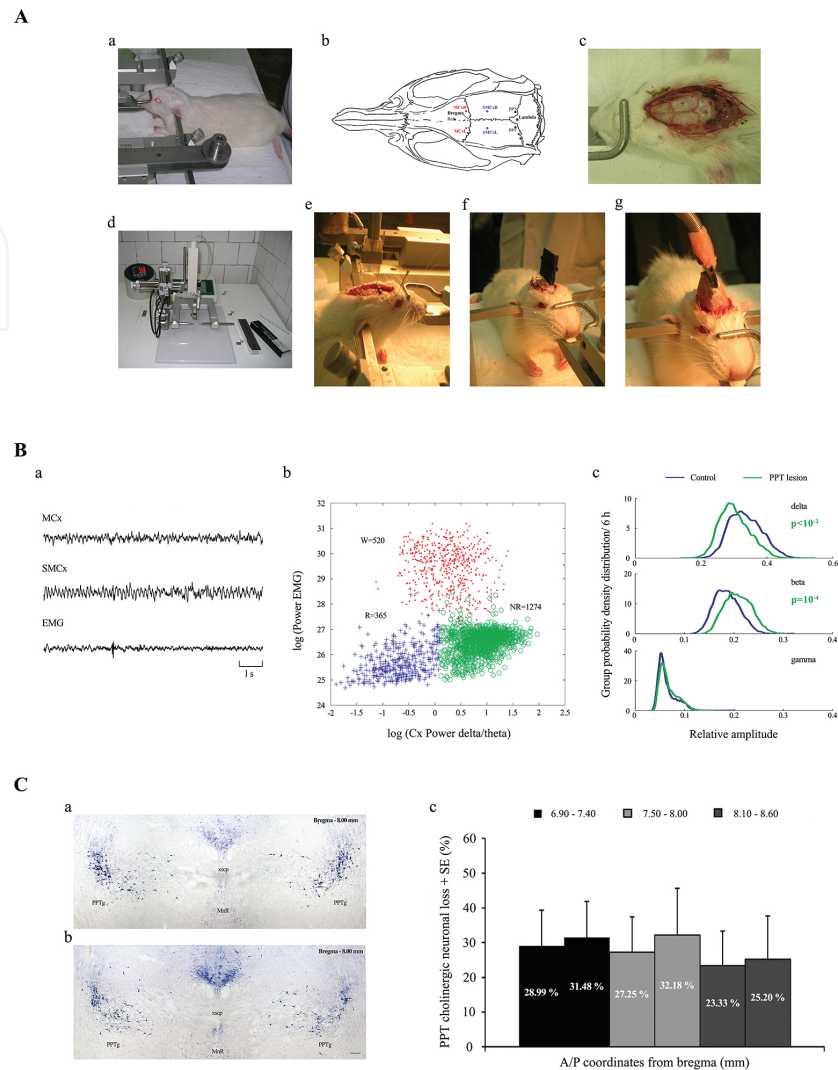


Figure 1. Schematic illustration of the experimental procedure in the animal studies of the impaired PPT cholinergic control. Operative procedure for the stereotaxic implantation of the chronic EEG and EMG electrodes for sleep recording and the stereotaxically guided microinfusion for the PPT excitotoxic lesion (**Aa-g**) with the illustrations of stereotaxic positions on the rat skull for the EEG electrodes implantation and the PPT lesions (**Ab**); Sleep recording, sleep states differentiation and analysis (**Ba-c**): the analog signals (10 s) recorded from the sensorimotor (SMCx) and motor (MCx) cortex, and EMG from dorsal nuchal muscle (**Ba**); an individual example of the final scattergram for Wake/NREM/REM differentiation during the 6 h of sleep recording. Each symbol corresponds to one 10 s epoch. W cluster – Wake 10 s epochs, dots; NR cluster – NREM 10 s epochs, circles; R cluster – REM 10 s epochs, crosses (**Bb**); and an example of the group probability density distributions of the sleep/wake state-related EEG frequency band relative amplitudes/6 h in bilateral PPT lesion vs. control, representing the EEG microstructure during NREM, with statistically significant attenuation (the left shifted green delta amplitude group distribution) and augmentation (the right shifted green beta amplitude group distribution) of the corresponding EEG relative amplitudes (**Bc**). Typical examples of the control PPT (**Ca**) and the bilateral PPT lesion (**Cb**), histologically identified by NADPH-diaphorase staining and quantified throughout the overall PPT rostro-caudal dimension (6.90 – 8.60 mm caudal from bregma), with the cholinergic neuronal loss expressed as the group mean percent difference of the NADPH-diaphorase positive cells with respect to control, taken as 100% for each stereotaxic range, and also per each brain side (**Cc**). PPTg – pedunculopontine tegmental nucleus; xscp – decussation of the superior cerebellar peduncle; MnR – median raphe nucleus. Scale bar is 200 μ m.

2.3. Excitotoxic lesion of the PPT

During surgical procedure for the EEG and EMG electrodes implantations we performed the bilateral PPT lesions (**Figure 1A**). These excitotoxic lesions were induced by the stereotaxically guided microinfusion of 0.1 M ibotenic acid (IBO)/ 0.1 M phosphate buffered saline (PBS) bilaterally into the PPT (A/P: -7.8 mm from bregma; R/L: 1.9 mm from sagittal suture; D/V: 7.0 mm from the brain surface), using a Digital Lab Standard Stereotaxic Instrument with a Hamilton syringe (1 μ l). The IBO (Sigma; pH = 7.4) concentration was chosen on the basis of previous studies [49–53, 55]. The microinfusions were introduced at a volume of 100 nl, using a single, 60 s pulse.

2.4. Sleep recording

At the end of surgical procedure, the scalp wounds were sutured and the rats were allowed to recover 13 days before their adaptation to the recording cable and plexiglass chamber (30 cm x 30 cm x 30 cm) for one day. The EEG and EMG activities were carried from the connector plug on the rat head by cable, passed through a sealed port on the recording box, and differentially recorded. Differential mode consisted of 6 inputs (left MCx, right MCx, left SMCx, right SMCx, left EMG, right EMG), each with a (+) on the left and a (–) on the right side and all with the same ground (a screw electrode implanted in the nasal bone). The activities were displayed on a computer monitor, and stored on disk for further off-line analysis (**Figure 1Ba**). After conventional amplification and filtering (0.3–100 Hz band pass; A-M System Inc. Model 3600, Carlborg, WA, USA), the analog data were digitized (sampling frequency 256/s), and recorded for 6 h, during the normal inactive circadian phase for rats (from 9 a.m. to 3 p.m.), using DataWave SciWorks Experimenter Version 8.0 (Datawave Technologies, Longmont, CO, USA).

Additionally, we have followed the impact of different anesthetized states of surgical level in all the experimental groups, during 20 min of ketamine/diazepam or pentobarbital anesthesia [52], and we recorded EEG and respiratory movements using the piezo electric strain gauge (Infant-Ped Sleepmate Technologies, Midlothain, VA).

The stability of the anesthesia was estimated on the bases of the observed loss of consciousness, muscle atonia, absence of tail-pinch, ear-pinch (analgesia) and corneal reflexes before the onset of each 20 min recording of the stable anesthetized state, and on the bases of polygraphic recording during the experimental procedure, including regular breathing pattern [52]. In all acute experiments, the anesthesia was administered at 9 a.m.

2.5. Identification and quantification of the PPT lesion

We identified the PPT lesions by NADPH - diaphorase histochemistry [56], and we quantified the PPT cholinergic cell loss using Image J 1.46 software. NADPH - diaphorase positive cells were counted in three 40 μ m thick coronal sections per each brain within an overall rostro-

caudal PPT dimension [49–53]. The number of NADPH - diaphorase positively stained cells was intended to provide an estimate of the lesion damage or the cholinergic neuronal numbers, rather than an attempt to determine the absolute numbers of cholinergic neurons within the PPT. The cholinergic neuronal loss was expressed per each brain side, and per each defined stereotaxic range, within the overall PPT rostro-caudal dimension, as the percent difference of NADPH - diaphorase positive cells versus the controls. Namely, all percent differences were expressed with respect to the mean control absolute numbers per each stereotaxic range taken as 100%. All statistical analyses for the PPT cholinergic cells number changes were done using nonparametric Mann-Whitney U two-tailed tests [49–53]. We have shown that by using a 100 nl microinfusion of 0.1 M IBO for the excitotoxic PPT lesion we induced the partial bilateral lesions of the PPT pars compacta (as dominantly cholinergic part of the PPT), and we achieved the selectivity of the lesions within the PPT limits (**Figure 1Ca,b**). We have demonstrated (**Figure 1Ca,b,c**) that the cholinergic neuronal loss induced by our methodological approach was > 20% throughout the overall rostro-caudal dimension within the each brain side [49–53].

2.6. Data analysis

Analysis of the recorded signals was conducted using original software we developed [48–53] using MATLAB 6.5 (**Figure 1Bb,c**). We applied Fourier analysis to the signals acquired throughout each 6 h recording (2160 10 s Fourier epochs), and each 10 s epoch was differentiated as Wake, NREM or REM state (**Figure 1Bb**) for further analysis of the Wake, NREM and REM related EEG relative amplitudes of all the conventional frequency bands ($\delta = 0.3\text{--}4\text{ Hz}$; $\theta = 4.1\text{--}8\text{ Hz}$; $\sigma = 10.1\text{--}15\text{ Hz}$; $\beta = 15.1\text{--}30\text{ Hz}$; $\gamma = 30.1\text{--}50\text{ Hz}$).

We particularly analyzed two distinct REM clusters that emerged within the scattergrams, and each REM 10 s epoch was differentiated, based on the EMG power, as REM with higher muscles tone (REM1) or REM with atonia (REM2). Differentiation of the Wake epochs from sleep epochs, and further differentiation of the NREM and REM/REM1/REM2 epochs was achieved using the two clusters K means algorithm (**Figure 1Bb; Figure 2A**). We improved these differentiation results by using the logarithmic values of quantities on both axes [48–53].

To analyze the sleep/wake state related EEG amplitude changes we calculated group probability density distributions of all the Wake, NREM and REM/REM1/REM2 conventional EEG frequency bands relative amplitudes over 6 h, using the Probability Density Estimate (PDE) routine supplied with MATLAB 6.5 (**Figure 1Bc; Figure 2B**). In order to eliminate any influence from absolute signal amplitude variations on the recordings, we computed the relative Fourier amplitudes [48–53, 57]:

$$(RA)_b = \frac{\sum_b \text{Amp}}{\sum_{tot} \text{Amp}}, b = \{\delta, \theta, \sigma, \beta, \gamma\}. \quad (1)$$

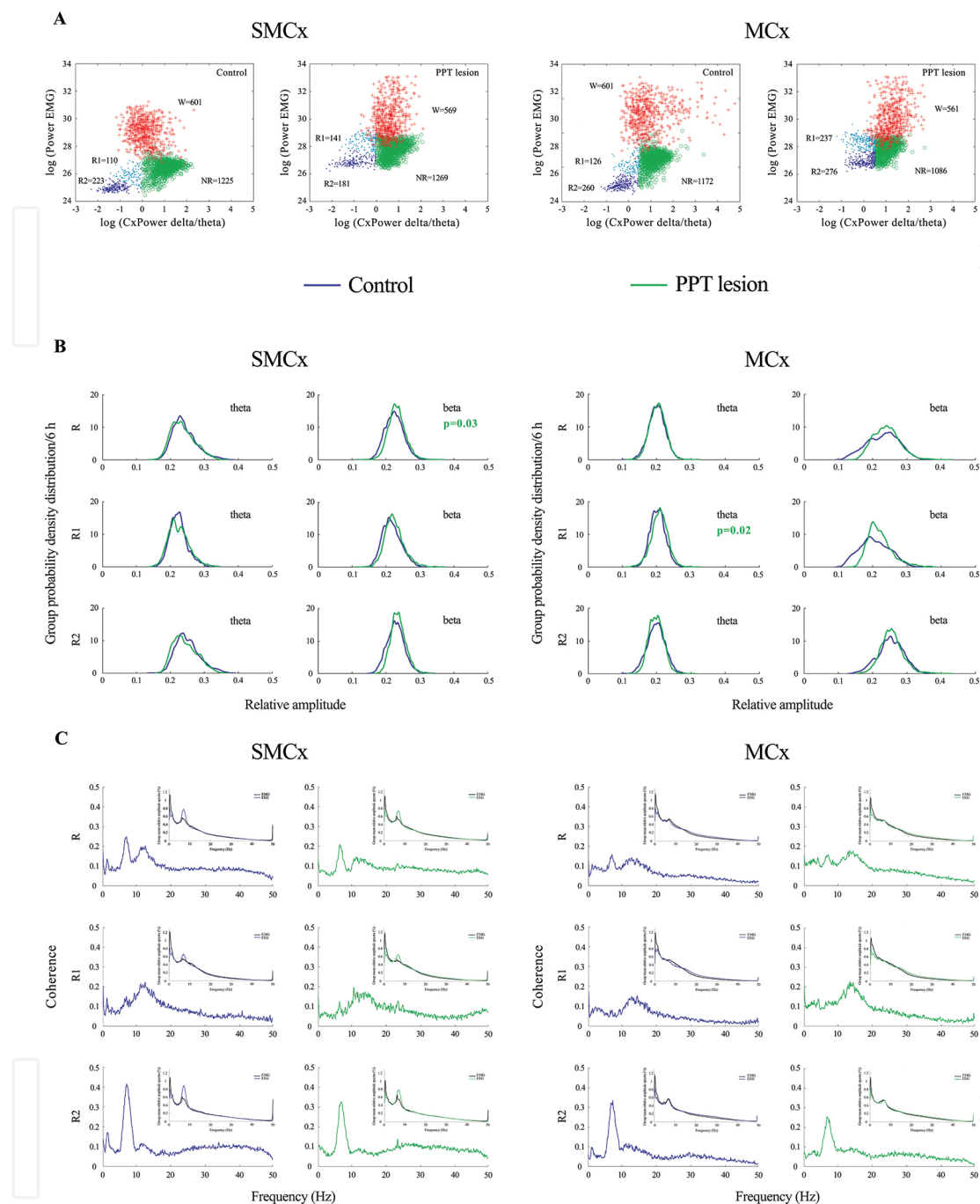


Figure 2. Topography of the REM sleep alterations following the PPT lesion. Examples of the final scattergrams for the Wake/NREM/REM/REM1/REM2 differentiation within the sensorimotor (SMCx) and motor (MCx) cortex during 6 h of sleep recordings (A) of the control (Control) and bilaterally PPT lesioned rat (PPT lesion). In all scattergrams the Wake 10 s epochs (W cluster, crosses) are transferred to these final scattergrams from the preceding Wake/Sleep differentiations. NR cluster, circles – NREM 10 s epoch; R1, R2, clusters, dots – REM1, REM2 10 s epochs (A); REM/REM1/REM2 EEG microstructure within the SMCx and MCx cortex of the control (Control, blue line) and bilaterally PPT lesioned rat (PPT lesion, green line); p values correspond to the statistically significant Mann-Whitney U two-tailed comparisons (B); REM/REM1/REM2 group coherence spectra between the SMCx or MCx EEGs and the dorsal nuchal muscle EMGs of the control (Control, blue line) and bilaterally PPT lesioned rat (PPT lesion, green line) with the inserts of their corresponding group mean relative amplitude EEG and EMG spectra used for the corticomuscular coherence analysis (C).

For each sleep/wake state and each frequency band, PDE analysis was performed on the ensembles of relative amplitudes by pooling measured values $(RA)_b$ from all animals belonging to a specific experimental group (**Figure 1Bc**; **Figure 2B**; **Figure 3A**; **Figure 4Ac**; **Figure 4Bc**).

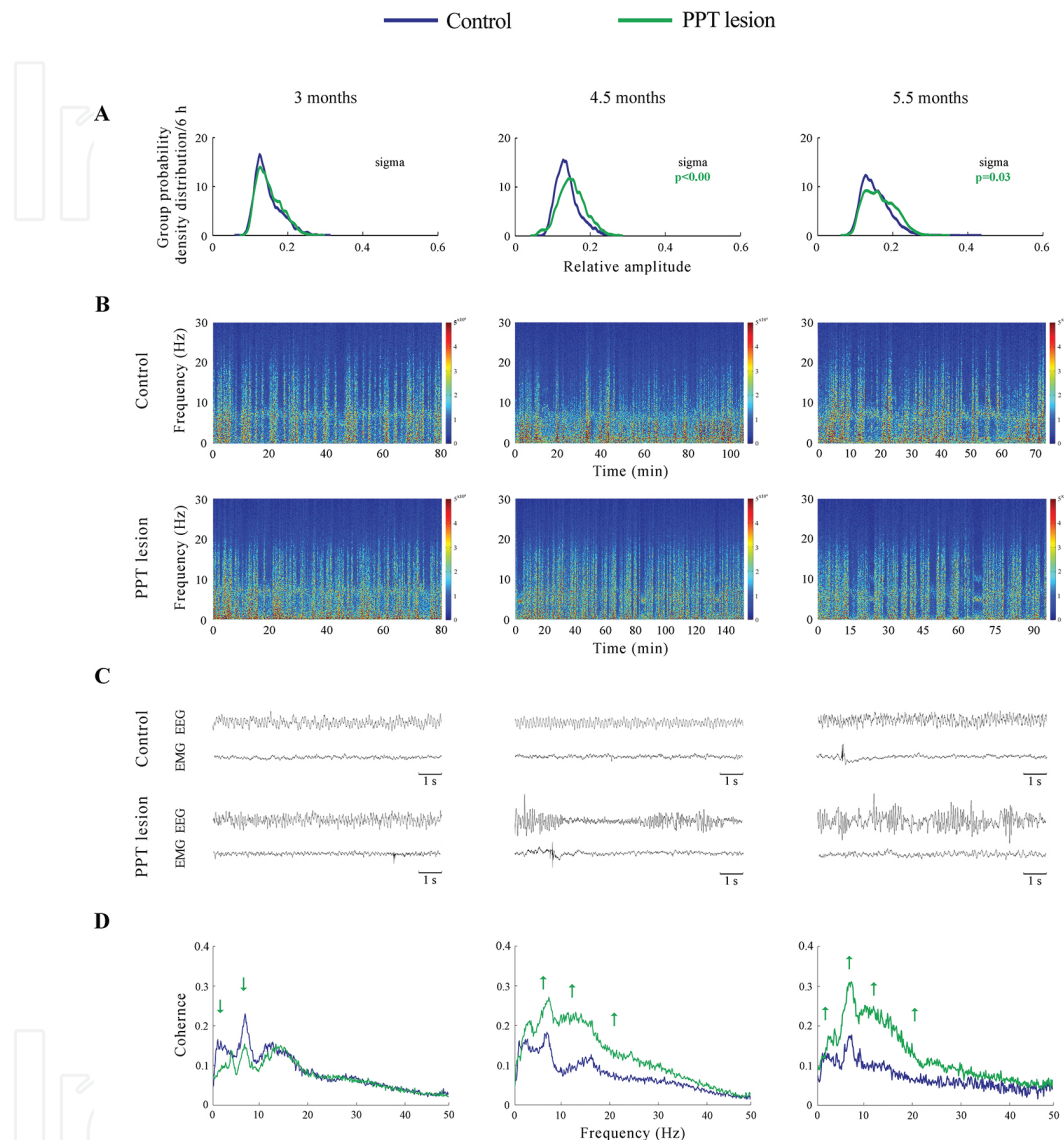


Figure 3. Differing impact of aging on the EEG microstructure during REM sleep in the PPT lesioned rats vs. control rats at the onset (3 months), and at two last (4.5 months and 5.5 months) aging follow-up periods. The group probability density distributions of the EEG sigma relative amplitude/6 h during REM sleep depict the age related augmentation of the REM sigma amplitude within the motor cortex (MCx) in the PPT lesioned rats vs. control rats (the right shifted green distributions) - p values correspond to the obtained significant results of Mann-Whitney U two-tailed tests (**A**). Individual examples of the MCx REM spectrograms across the overall aging follow up period during the bilateral PPT lesions vs. controls (**B**), with their typical 10 s analog EEG and EMG signals during REM (**C**) used for the construction of REM spectrograms as well as for the corticomuscular coherence analysis during REM. For all REM spectrograms the EEG 10 s epochs during REM were extracted and concatenated in the same order as they occurred in a real-time domain during the whole 6 h sleep of each rat, and at each time during aging follow up period. The group mean coherence spectra between the MCx EEG and the dorsal nuchal muscle EMG during REM in the bilateral PPT lesions vs. controls (**D**). Aging consistently increased the MCx delta, theta, sigma and beta drives during the bilateral PPT lesion (green arrows).

Additionally, we have analyzed the Wake, NREM and REM/REM1/REM2 corticomuscular coherences (CMCs) separately for each experimental group, each state, and for all the conventional EEG frequency bands (**Figure 2C**; **Figure 3D**), using the SMCx or MCx EEG, and the EMG of the dorsal nuchal muscles [51, 53, 57]. CMC values were calculated using the “cohere” routine of the MATLAB 6.5 Signal Processing Toolbox. It actually computes the magnitude squared coherence between signals x (EEG) and y (EMG) as:

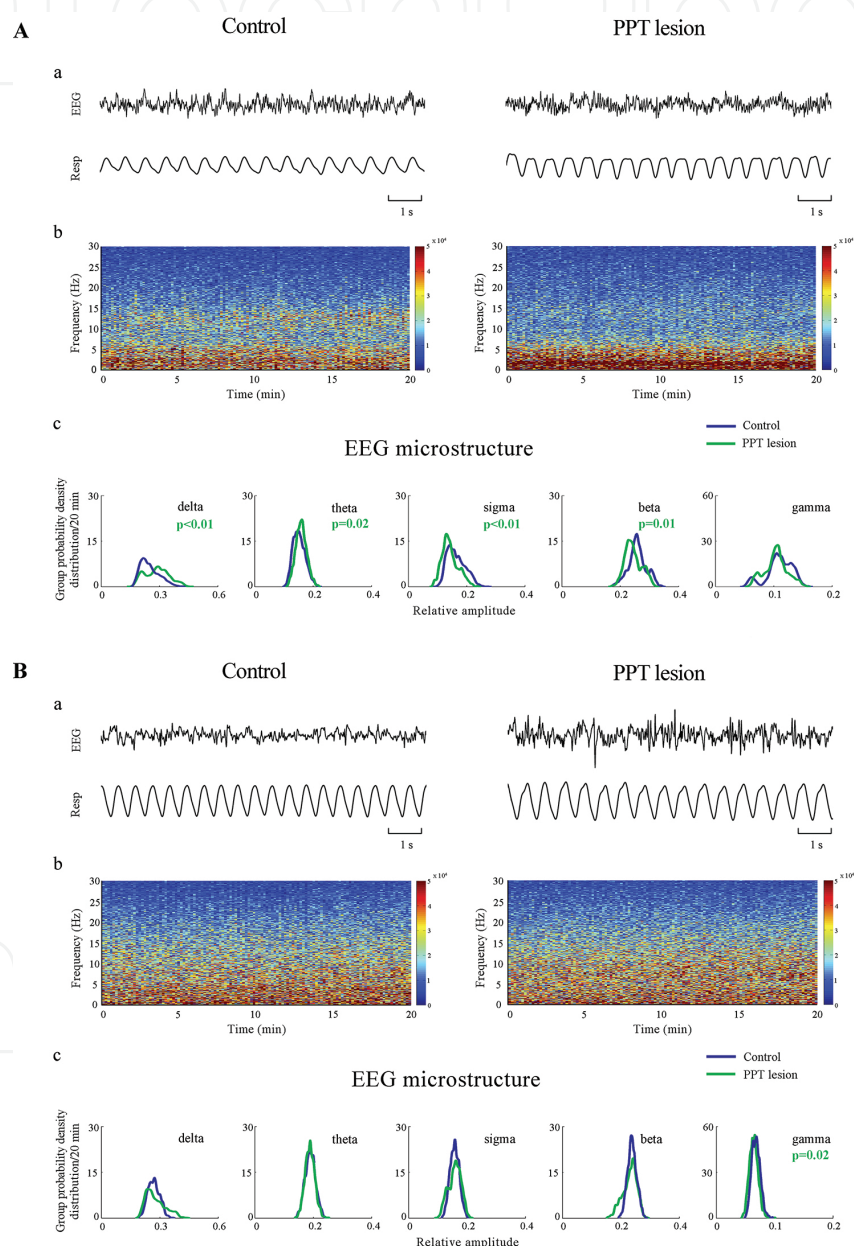


Figure 4. Impact of ketamin/diazepam (A) and pentobarbital (B) anesthetic regimens at surgical level on EEG microstructure and respiratory pattern in the bilaterally PPT lesioned rat vs. control rat. Individual examples of the analog 10 s EEG and respiratory signals (a), as well as their EEG spectrograms (b) and the group EEG microstructure during 20 min of stable anesthetized state (c) in the bilaterally PPT lesioned vs. control rats. The p values correspond to the statistically significant Mann-Whitney U two-tailed comparisons.

$$C_{xy}(f) = \frac{|P_{xy}(f)|^2}{P_{xx}(f)P_{yy}(f)} \quad (2)$$

where $P_{xy}(f)$ stands for the cross spectrum of x and y , while $P_{xx}(f)$ and $P_{yy}(f)$ denote the power spectra of the two signals. All P_{xy} , P_{xx} and P_{yy} values were determined for every 10 s of each 6 h recording, and for each frequency within the overall 0.3 - 50 Hz range, with 0.1 Hz resolution.

Namely, previously identified Wake/NREM/REM/REM1/REM2 EEG and EMG 10 s epochs were concatenated and pooled within each experimental group of rats. Then, the CMC spectra were calculated for every 60 min of Wake and NREM, and for every 30 min of REM/REM1/REM2, using 10 s FFT epochs for the MATLAB “cohere” routine, resulting in 0.1 Hz frequency resolution. Then, the CMC values within each conventional frequency band (δ , θ , σ , β , γ) were averaged for each spectrum, and finally their means were calculated from the collection of all available CMC spectra, for each state.

We have also drawn the REM sleep EEG spectrograms (Figure 3B) or the EEG spectrograms of distinct anesthetized states at surgical level (**Figure 4Ab**, **Figure 4Bb**) using the same Fourier analysis parameters: a 10 s Fourier epoch, resulting in 0.1 Hz y-axis frequency resolution; a 10 s moving Fourier epoch step, yielding the same x-axis time resolution.

For the respiratory pattern time-domain analysis during anesthesia, the respiratory signal was passed through a 0.5–5 Hz band pass filter to remove baseline drift and attenuate the high frequency noise and we used our originally developed analysis for breath detection, differentiation, and the quantification of the eupnea, bradypnea/apnea and sigh breath-to-breath intervals within the respiratory pattern. All the details for the respiratory pattern analysis are explained elsewhere [52].

For the statistical analysis of PDE/6 h and CMC/6 h we calculated the relative amplitude means for Wake and NREM per each 60 min, and for REM/REM1/REM2 per each 30 min. Further, we employed the Kruskal-Wallis ANOVA and Mann-Whitney U two-tailed tests for the statistical analysis of all group means over 6 h: the group mean durations of Wake, NREM, and REM/REM1/REM2; the group mean number and group mean duration of Wake, NREM and REM/REM1/REM2 episodes; the group means of Wake, NREM and REM/REM1/REM2 EEG relative amplitudes for all frequency bands; and the group CMC means of Wake, NREM and REM/REM1/REM2. In all cases the differences were considered statistically significant for $p \leq 0.05$.

3. Disorders of sleep and motor control in the rat model of Parkinson's disease cholinergic neuropathology

Our studies in the rat model “*in vivo*” demonstrated that the severe PPT cholinergic neuronal loss (the severe thalamo-cortical cholinergic control impairment) did not change the sleep/wake states architecture, but disturbed the sleep/wake state transitions structure and augmented cortical activation during all sleep/wake states [49]. Beside the “tonically” increased

Wake/REM and REM/Wake transitions, the bilateral PPT lesion was expressed from the onset (14 days following lesion) as a generalized Wake, NREM and REM beta amplitude augmentation, which was sustainable for 5 weeks. This effect was followed from the onset by the NREM delta attenuation and REM gamma augmentation. In addition, there was the Wake delta attenuation from 21 days after the PPT lesion [49].

Furthermore, our studies have shown for the first time that the bilateral PPT cholinergic neuronal loss in rat was differently expressed in sensorimotor vs. motor cortex (**Figure 2A, B**), and the differing EEG microstructure and transition structure, particularly within the motor cortex and during NREM and REM sleep are the hallmarks of lesion [50]. Moreover, the bilateral PPT lesion increased a likelihood of the emergence of two REM sleep states [51], particularly within the motor cortex (**Figure 2A**): REM1 (REM without atonia, or “sigma coherent REM”), and REM2 (REM with atonia, or “theta coherent REM”). Namely, aside from the differential total EMG power of the dorsal nuchal musculature (**Figure 2A**), REM1 and REM2 have the topographically distinct EEG microstructures (**Figure 2B**) and cortical locomotor drives (**Figure 2C**) from the sensorimotor and motor cortices to dorsal nuchal muscles. These PPT lesion induced alteration of the cortical drives are commonly expressed as the impaired theta and sigma cortico-muscular coherences [51]. Although the bilateral PPT lesion altered both cortical drives during both REM states [51], its impact was more severe during REM2 state (healthy REM, REM with atonia), and more severely through the sensorimotor cortical drive (there were the impaired theta, sigma, beta and gamma cortico-muscular coherences). These results indicate the simultaneous breakdown of the PPT cholinergic direct ascending thalamo-cortical control, and the indirect descending control of the REM sleep atonia regulatory circuitry, for the emergence of two differential REM states following the bilateral PPT lesion in rats [51].

We have also demonstrated the age-related and topographically specific EEGs and cortical drives alterations during sleep in the PPT lesioned rats (**Figure 3**). The hallmark of earlier aging onset in the PPT lesioned rats vs. physiological controls was the augmented EEG sigma amplitude within the motor cortex during REM (**Figure 3A, B, C**), as the unique pathological phenomenon [53]. Beside this EEG microstructure disorder during REM sleep, we have evidenced for the first time the altered cortical drives as the hallmarks of the earlier aging onset during severely impaired PPT cholinergic control (**Figure 3D**). This compensatory and aging induced plasticity was differently expressed through the sensorimotor cortical drive alterations, but it was broadly and commonly expressed through the motor cortical drive alterations during all the sleep/wake states [53]. Namely, during severely impaired PPT thalamo-cortical innervation aging consistently increased the motor cortical delta, theta, sigma and beta drives during NREM and REM sleep (**Figure 3D**).

Furthermore, we have shown that distinct anesthetic regimens at surgical level were expressed differently in the bilaterally PPT lesioned rats (the rat model of cholinergic PD neuropathology) vs. physiological controls (**Figure 4A, B**) in terms of the EEG microstructure, respiratory pattern, and post-anesthesia sleep [52]. Namely, the ketamine/diazepam anesthesia induced more alterations in the EEG microstructure and respiratory pattern (**Figure 4A**) than did the pentobarbital anesthesia (**Figure 4B**) in the PPT lesioned rats vs. physiologi-

cal controls [52]. Although the ketamine/diazepam anesthesia at surgical level induced the apneustic breathing pattern in the PPT lesioned rats, the equal time to establish an anesthetized state in the PPT lesioned rats vs. control rats, and the long-term post-anesthesia suppressive effect on the augmented cortical activation during NREM (the augmented beta and theta amplitudes during NREM as a hallmarks of the PPT lesion), suggested the ketamine/diazepam anesthesia as potentially more beneficial both for anesthesia induction and post-anesthesia sleep in the surgical procedures of elderly, Parkinson's and Alzheimer's patients.

4. Discussion

Our studies have shown that the sleep/wake states related disturbances were topographically differently expressed within the sensorimotor and motor cortex in terms of their EEG microstructure and transitions structure, particularly during NREM and REM sleep, in the rat model of severely impaired PPT cholinergic thalamo-cortical innervation [49, 50]. Moreover, we have evidenced the emergence of two REM sleep states in the bilateral PPT lesioned rats, differential with regard to the total EMG power, the topographically distinct EEG microstructures and the sensorimotor and motor cortical drives to the dorsal nuchal muscles. These altered cortical drives were commonly expressed during both REM states, as the impaired beta oscillation drive [51]. In addition, the sensorimotor cortical drive was altered more severely during "healthy" REM (REM with atonia, theta REM) than during the emerged pathological REM (REM without atonia, sigma REM).

It is well known that the output of the basal ganglia (the efferents from globus pallidus internus and substantia nigra pars reticulata) is sent primarily to thalamus and from there to the frontal cortex, forming the partially closed cortico-basal ganglia loop. PPT, as the main source of thalamo-cortical cholinergic innervation, monosynaptically innervates the substantia nigra and to less extent the globus pallidus internus [58], but through its descending cholinergic efferents indirectly promotes REM sleep atonia [59–61]. Therefore, the degeneration of PPT cholinergic neurons could underlie the motor symptoms in patients with PD and RBD [59]. Since the PPT may be severely affected by PD pathology, it is regarded as a promising target for therapeutic deep-brain stimulation [59].

However, our understanding of the PPT role in PD pathogenesis is limited by the lack of a suitable model of PPT cholinergic neuronal degeneration. All animal models [62–65], the toxic and transgenic animal models, have their own specificities and limitations that must be carefully taken into consideration when choosing the model to be used, and when interpreting the results. For example, recent studies [66, 67] demonstrated different results within the PPT, as a consequence of the substantia nigra dopaminergic neuronal loss caused by 6-OHDA or Lactacystin: mostly non-cholinergic PPT neuronal loss [67] vs. mostly PPT cholinergic loss [66]. We have overviewed our results in the animal model of severe PPT cholinergic neuropathology (the rat model of PD cholinergic neuropathology) to provide new insights into the importance and relevance of thalamo-cortical cholinergic system regulatory role in sleep and motor control in PD.

Acknowledgements

This work was supported by Serbian Ministry of Education, Science and Technological Development Grant OI 173022.

Author details

Jasna Saponjic*, Jelena Petrovic, Jelena Ciric and Katarina Lazic

*Address all correspondence to: jasnasap@ibiss.bg.ac.rs; jasnasaponjic@yahoo.com

University of Belgrade, Department of Neurobiology, Institute for Biological Research - Sinisa Stankovic, Belgrade, Serbia

References

- [1] Nature Editorial. Waking up to the importance of sleep. *Nature*. 2005;437:1207. DOI: 10.1038/4371207a
- [2] Boeve BF, Silber MH, Saper CB, Ferman TJ, Dickson DW, Parisi JE, Benarroch EE, Ahlskog JE, Smith GE, Caselli RC, Tippman-Peikert M, Olson EJ, Lin SC, Young T, Wszolek Z, Schenck CH, Mahowald MW, Castillo PR, Del Tredici K, Braak H. Pathophysiology of REM sleep behaviour disorder and relevance to neurodegenerative disease. *Brain*. 2007;130:2770–2788. DOI: 10.1093/brain/awm056
- [3] Whitwell JL, Weigand SD, Shiung MM, Boeve BF, Ferman TJ, Smith GE, Knopman DS, Petersen RC, Benarroch EE, Josephs KA, Jack CR Jr. Focal atrophy in dementia with Lewy bodies on MRI: a distinct pattern from Alzheimer's disease. *Brain*. 2007;130:708–719. DOI: 10.1093/brain/awl388
- [4] Raggi A, Ferri R. Sleep disorders in neurodegenerative diseases. *Eur J Neurol*. 2010; 17:1326–1338. DOI: 10.1111/j.1468-1331.2010.03034.x.
- [5] Maria B, Sophia S, Michalis M, Charalampos L, Andreas P, John ME, Nikolaos SM. Sleep breathing disorders in patients with idiopathic Parkinson's disease. *Respir Med*. 2003;97:1151–1157. DOI: 10.1016/S0954-6111(03)00188-4
- [6] McKay LC, Janczewski WA, Feldman JL. Sleep-disordered breathing after targeted ablation of preBötzinger complex neurons. *Nat Neurosci*. 2005;8:1142–1144. DOI: 10.1038/nn1517

- [7] Kok SW, Overeem S, Visscher TLS, Lammers GJ, Seidell JC, Pijl H, Meinders AE. Hypocretin deficiency in narcoleptic humans is associated with abdominal obesity. *Obes Res.* 2003;11:1147–1154. DOI: 10.1038/oby.2003.156
- [8] Resta O, Foschino Barbaro MP, Bonfitto P, Giliberti T, Depalo A, Pannacciulli N, de Pergola G. Low sleep quality and daytime sleepiness in obese patients without obstructive sleep apnoea syndrome. *J Intern Med.* 2003;253:536–543. DOI: 10.1046/j.1365-2796.2003.01133.x
- [9] Sakurai T. Roles of orexin/hypocretin in regulation of sleep/wakefulness and energy homeostasis. *Sleep Med Rev.* 2005;9:231–241. DOI: 10.1016/j.smrv.2004.07.007
- [10] White DP. The pathogenesis of obstructive sleep apnea - Advances in the past 100 years. *Am J Respir Cell Mol Biol.* 2006;34:1–6. DOI: 10.1165/rcmb.2005-0317OE
- [11] Pace-Schott EF, Hobson JA. The neurobiology of sleep: genetics, cellular physiology and subcortical networks. *Nat Rev Neurosci.* 2002;3:591–605. DOI: 10.1038/nrn895
- [12] Siegel JM. Do all animals sleep? *Trends Neurosci.* 2008;31:208–213. DOI: 10.1016/j.tins.2008.02.001
- [13] Hobson JA, Pace-Schott EF. The cognitive neuroscience of sleep: neuronal systems, consciousness and learning. *Nat Rev Neurosci.* 2002;3:679–693. DOI: 10.1038/nrn915
- [14] Nussbaum RL, Ellis CE. Alzheimer's Disease and Parkinson's Disease. *N Engl J Med.* 2003;348:1356–1364. DOI: 10.1056/NEJM2003ra020003
- [15] Garcia-Rill E, Charlesworth A, Heister D, Ye M, Hayar A. The developmental decrease in REM sleep: the role of transmitters and electrical coupling. *Sleep.* 2008;31:673–690. DOI:
- [16] Dijk DJ, Groeger JA, Stanley N, Deacon S. Age-related reduction in daytime sleep propensity and nocturnal slow wave sleep. *Sleep.* 2010;33:211–223. DOI:
- [17] Simic G, Stanic G, Mladinov M, Jovanov-Milosevic N, Kostovic I, Hof PR. Does Alzheimer's disease begin in the brainstem? *Neuropathol App Neurobiol.* 2009;35:532–554. DOI: 10.1111/j.1365-2990.2009.01038.x
- [18] Dringenberg HC, Olmstead MC. Integrated contributions of basal forebrain and thalamus to neocortical activation elicited by pedunculo pontine tegmental stimulation in urethane-anesthetized rats. *Neuroscience.* 2003;119:839–853. DOI: 10.1016/S0306-4522(03)00197-0
- [19] Lu J, Sherman D, Devor M, Saper CB. A putative flip-flop switch for control of REM sleep. *Nature.* 2006;441:589–594. DOI: 10.1038/nature04767
- [20] McCarley RW, Hobson JA. Neuronal excitability modulation over the sleep cycle: a structural and mathematical model. *Science.* 1975;189:58–60. DOI: 10.1126/science.1135627

- [21] Bringmann A. Different functions of rat's pedunculo pontine tegmental nucleus are reflected in cortical EEG. *Neuroreport*. 1995;6:2065–2068. DOI:
- [22] Bringmann A. Nicotine affects the occipital theta rhythm after lesion of the pedunculo pontine tegmental nucleus in rats. *Neuropsychobiology*. 1997;35:102–107. DOI: 10.1159/000119399
- [23] Datta S. Evidence that REM sleep is controlled by the activation of brain stem pedunculo pontine tegmental kainate receptor. *J Neurophysiol*. 2002;87:1790–1798. DOI: 10.1152/jn.00763.2001
- [24] Datta S, Spoley EE, Patterson EH. Microinjection of glutamate into the pedunculo pontine tegmentum induces REM sleep and wakefulness in the rat. *Am J Physiol Regul Integr Comp Physiol*. 2001;280:R752–R759. DOI:
- [25] Datta S, MacLean RR. Neurobiological mechanisms for the regulation of mammalian sleep-wake behavior: reinterpretation of historical evidence and inclusion of contemporary cellular and molecular evidence. *Neurosci Biobehav Rev*. 2007;31:775–824. DOI: 10.1016/j.neubiorev.2007.02.004
- [26] Datta S, Siwek DF. Excitation of the brain stem pedunculo pontine tegmentum cholinergic cells induces wakefulness and REM sleep. *J Neurophysiol*. 1997;77:2975–2988. DOI:
- [27] Kleiner S, Bringmann A. Nucleus basalis magnocellularis and pedunculo pontine tegmental nucleus: control of slow EEG waves in rats. *Arch Ital Biol*. 1996;134:153–167. DOI:
- [28] Rye DB. Contributions of the pedunculo pontine region to normal and altered REM sleep. *Sleep*. 1997;20:757–788. DOI:
- [29] Vertes RP. Brainstem control of the events of REM sleep. *Prog Neurobiol*. 1984;22:241–288. DOI: 10.1016/0301-0082(84)90020-0
- [30] Inglis WL, Allen LF, Whitelaw RB, Latimer MP, Brace HM, Winn P. An investigation into the role of the pedunculo pontine tegmental nucleus in the mediation of locomotion and orofacial stereotypy induced by D-amphetamine and apomorphine in the rat. *Neuroscience*. 1994;58:817–833. DOI: 10.1016/0306-4522(94)90459-6
- [31] Saper CB, Loewy AD. Projections of the pedunculo pontine tegmental nucleus in the rat: evidence for additional extrapyramidal circuitry. *Brain Res*. 1982;252:367–372. DOI: 10.1016/0006-8993(82)90404-8
- [32] Takakusaki K, Habaguchi T, Saitoh K, Kohyama J. Changes in the excitability of hindlimb motoneurons during muscular atonia induced by stimulating the pedunculo pontine tegmental nucleus in cats. *Neuroscience*. 2004;124:467–480. DOI: 10.1016/j.neuroscience.2003.12.016

- [33] Lydic R, Baghdoyan HA. Pedunculo pontine stimulation alters respiration and increases Ach release in the pontine reticular formation. *Am J Physiol.* 1993;264:R544–R554. DOI:
- [34] Radulovacki M, Pavlovic S, Saponjic J, Carley DW. Modulation of reflex and sleep related apnea by pedunculo pontine tegmental and intertrigeminal neurons. *Respir Physiol Neurobiol.* 2004;143:293–306. DOI: 10.1016/j.resp.2004.02.012
- [35] Saponjic J, Radulovacki M, Carley DW. Respiratory pattern modulation by the pedunculo pontine tegmental nucleus. *Respir Physiol Neurobiol.* 2003;138:223–237. DOI: 10.1016/j.resp.2003.08.002
- [36] Saponjic J, Cvorovic J, Radulovacki M, Carley DW. 2005. Serotonin and noradrenaline modulate respiratory pattern disturbances evoked by glutamate injection into pedunculo pontine tegmentum of anesthetized rats. *Sleep.* 2005;28:560–570. DOI:
- [37] Saponjic J, Radulovacki M, Carley DW. Injection of glutamate into the pedunculo pontine tegmental nuclei of anesthetized rat causes respiratory dysrhythmia and alters EEG and EMG power. *Sleep Breath.* 2005;9:82–91. DOI: 10.1007/s11325-005-0010-5
- [38] Saponjic J, Radulovacki M, Carley DW. Modulation of respiratory pattern and upper airway muscle activity by the pedunculo pontine tegmentum: Role of NMDA receptors. *Sleep Breath.* 2006;10:195–202. DOI 10.1007/s11325-006-0075-9
- [39] Datta S. Neuronal activity in the peribrachial area: relationship to behavioral state control. *Neurosci Biobehav Rev.* 1995;19:67–84. DOI: 10.1016/0149-7634(94)00043-Z
- [40] Datta S. Cellular basis of pontine ponto-geniculo-occipital wave generation and modulation. *Cell Mol Neurobiol.* 1997;17:341–365. DOI:
- [41] Garcia-Rill E. 1991. The pedunculo pontine nucleus. *Prog Neurobiol.* 1991;36:363–389. DOI: 10.1016/0301-0082(91)90016-T
- [42] Kotagal V, Albin RL, Müller MLTM, Koeppe RA, Chervin RD, Frey KA, Bohnen NI. Symptoms of rapid eye movement sleep behavior disorder are associated with cholinergic denervation in Parkinson disease. *Ann Neurol.* 2012;7:560–568. DOI: 10.1002/ana.22691
- [43] Bohnen NI, Müller MI, Koeppe RA, Studenski SA, Kilbourn MA, Fey KA, Albin RL. History of falls in Parkinson disease is associated with reduced cholinergic activity. *Neurology.* 2009;73:1670–1676. DOI: 10.1212/WNL.0b013e3181c1ded6
- [44] Bohnen NI, Albin RL. The cholinergic system and Parkinson disease. *Behav Brain Res.* 2011;221:564–573. DOI: 10.1016/j.bbr.2009.12.048
- [45] Kotagal V, Müller MLTM, Kaufer DI, Koeppe RA, Bohnen NI. Thalamic cholinergic innervation is spared in Alzheimer disease compared to parkinsonian disorders. *Neurosci Lett.* 2012;514:169–172. DOI: 10.1016/j.neulet.2012.02.083

- [46] Chung KA, Lobb BM, Nutt JG, Horak F. Cholinergic augmentation in frequently falling subjects with Parkinson's disease. *Mov Disord.* 2009; 24(Suppl 1):S259. DOI:
- [47] Saponjic J, Radulovacki M, Carley DW. Monoaminergic system lesions increase post-sigh respiratory pattern disturbance during sleep in rats. *Physiol Behav.* 2007;90:1–10. DOI: 10.1016/j.physbeh.2006.08.019
- [48] Saponjic J, Petrovic J, Kalauzi A, Ciric J, Lazic K, Radulovacki M, Carley DW. Sleep-state related EEG amplitude distribution in the rat model of cortical cholinergic innervation disorder. *Sleep Biol Rhythms.* 2013;11:105–115. DOI: 10.1111/sbr.12011
- [49] Petrovic J, Ciric J, Lazic K, Kalauzi A, Saponjic J. Lesion of the pedunculopontine tegmental nucleus in rat augments cortical activation and disturbs sleep/wake state transitions structure. *Exp Neurol.* 2013;247:562–571. DOI: 10.1016/j.expneurol.2013.02.007
- [50] Petrovic J, Lazic K, Ciric J, Kalauzi A, Saponjic J. Topography of the sleep/wake states related EEG microstructure and transitions structure differentiates the functionally distinct cholinergic innervation disorders in rat. *Behav Brain Res.* 2013;256:108–118. DOI: 10.1016/j.bbr.2013.07.047
- [51] Petrovic J, Lazic K, Kalauzi A, Saponjic J. REM sleep diversity following the pedunculopontine tegmental nucleus lesion in rat. *Behav Brain Res.* 2014;271:258–268. DOI: 10.1016/j.bbr.2014.06.026
- [52] Lazic K, Petrovic J, Ciric J, Kalauzi A, Saponjic J. Impact of anesthetic regimen on the respiratory pattern, EEG microstructure and sleep in the rat model of cholinergic Parkinson's disease neuropathology. *Neuroscience.* 2015;304:1–13. DOI: 10.1016/j.neuroscience.2015.07.020
- [53] Ciric J, Lazic K, Petrovic J, Kalauzi A, Saponjic J. Age-related disorders of sleep and motor control in the rat models of functionally distinct cholinergic neuropathology. *Behav Brain Res.* 2016;301:273–286. DOI: 10.1016/j.bbr.2015.12.046
- [54] Paxinos G, Watson C. *The Rat Brain in Stereotaxic Coordinates*, 5th ed., Elsevier Academic Press, San Diego, USA; 2005. DOI:
- [55] Inglis WL, Semba K. Discriminable excitotoxic effects of ibotenic acid, AMPA, NMDA and quinolinic acid in the rat laterodorsal tegmental nucleus. *Brain Res.* 1997;755:17–27. DOI: 10.1016/S0006-8993(97)00101-7
- [56] Paxinos G, Watson C, Carrive P, Kirkcaldie M, Ashwell KWS. *Chemoarchitectonic Atlas of The Rat Brain*, 2nd ed. Academic Press, London, UK; 2009. DOI:
- [57] Ciric J, Lazic K, Petrovic J, Kalauzi A, Saponjic J. Aging induced cortical drive alterations during sleep in rats. *Mech Ageing Dev.* 2015;146–148:12–22. DOI: 10.1016/j.mad.2015.03.002
- [58] Krause V, Wach C, Sudmeyer M, Ferrea S, Schnitzler A, Pollok B. Cortico-muscular coupling and motor performance are modulated by 20 Hz transcranial alternating

- current stimulation (tACS) in Parkinson's disease. *Front Hum Neurosci*. 2014;7:1–10. DOI: 10.3389/fnhum.2013.00928
- [59] Peever J, Luppi PH, Montplaisir J. Breakdown in REM sleep circuitry underlies REM sleep behavior disorder. *Trends Neurosci*. 2014;37:279–288. DOI: 10.1016/j.tins.2014.02.009
- [60] Kristeva R, Patino L, Omlor W. Beta-range cortical motor spectral power and cortico-muscular coherence as a mechanism for effective corticospinal interaction during steady-state motor output. *NeuroImage*. 2007;36:785–792. DOI: 10.1016/j.neuroimage.2007.03.025
- [61] Salenius S, Avikainen S, Kaakkola S, Hari R, Brown P. Defective cortical drive to muscle in Parkinson's disease and its improvement with levodopa. *Brain*. 2002;125:491–500. DOI: 10.1093/brain/awf042
- [62] Bezard E, Przedborski S. A tale on animal models of Parkinson's disease. *Mov Disord*. 2011;26:993–1002. DOI: 10.1002/mds.23696
- [63] Blandini F, Armentero MT, Martignoni E. The 6-hydroxydopamine model: news from the past. *Parkinsonism Relat Disord*. 2008;14 Suppl 2:S124–129. DOI: 10.1016/j.parkrel-dis.2008.04.015
- [64] Blandini F, Armentero MT. Animal models of Parkinson's disease. *FEBS J*. 2012;279:1156–1166. DOI: 10.1111/j.1742-4658.2012.08491.x
- [65] Duty S, Jenner P. Animal models of Parkinson's disease: a source of novel treatments and clues to the cause of the disease. *Br J Pharmacol*. 2011;164:1357–1391. DOI: 10.1111/j.1476-5381.2011.01426.x
- [66] Pienaar IS, Harrison IF, Elson JL, Bury A, Woll P, Simon AK, Dexter DT. An animal model mimicking pedunculopontine nucleus cholinergic degeneration in Parkinson's disease. *Brain Struct Funct*. 2015;220:479–500. DOI: 10.1007/s00429-013-0669-5
- [67] Pienaar IS, van de Berg W. A non-cholinergic neuronal loss in the pedunculopontine nucleus of toxin-evoked parkinsonian rats. *Exp Neurol*. 2013;248:213–223. DOI: 10.1016/j.expneurol.2013.06.008

