

# We are IntechOpen, the world's leading publisher of Open Access books Built by scientists, for scientists

6,900

Open access books available

186,000

International authors and editors

200M

Downloads

Our authors are among the

154

Countries delivered to

TOP 1%

most cited scientists

12.2%

Contributors from top 500 universities



WEB OF SCIENCE™

Selection of our books indexed in the Book Citation Index  
in Web of Science™ Core Collection (BKCI)

Interested in publishing with us?  
Contact [book.department@intechopen.com](mailto:book.department@intechopen.com)

Numbers displayed above are based on latest data collected.  
For more information visit [www.intechopen.com](http://www.intechopen.com)



---

# Natural Orifice Transluminal Endoscopic Surgery of the Gastrointestinal Tract

---

Abdulzahra Hussain

Additional information is available at the end of the chapter

<http://dx.doi.org/10.5772/60552>

---

## Abstract

**Research Focus** - NOTES is a new technique that faces numerous challenges. Current technology, training and research activities are conducted to make it a safe and effective minimal access technique.

**Research Methods Used** - This chapter is based on the current evidence of published NOTES studies. Medline search is conducted through November to December 2014, including English literatures only. The search words are NOTES, natural orifice transluminal endoscopic surgery, hybrid NOTES and hybrid natural orifice transluminal endoscopic surgery; additional search words are specific for the titles like NOTES gastric, NOTES oesophageal, NOTES biliary, NOTES cholecystectomy, NOTES pancreatic, NOTES small bowel, NOTES colorectal and NOTES appendectomy. Animal and human studies are selected after 2008. Small studies are excluded unless they report a novel approach or a new procedure.

**Results/Findings of the Research** - There is development in the technology by installing new platforms, instruments and closure devices to add more safety and security. There is also development in training and research activities across the continents; a number of NOTES procedures are performed safely on human beings including cholecystectomy, appendectomy, peritoneoscopy, POEM and other procedures. Feasibility studies are conducted on animal and human cadaver models including numbers of complex procedures.

**Main Conclusions and Recommendations** - NOTES is evolving and gaining popularity. The growth rate however is slowed by challenges of the need for an ideal working platform and closure devices that are easy to use, cheap and time effective, in addition to the dedicated effective training.

**Keywords:** Upper GI NOTES, Lower GI NOTES, Oesophageal NOTES, Gastric NOTES, Duodenal NOTES, Liver NOTES, Pancreatic NOTES, Splenic NOTES

---

## 1. Introduction

Modern endoscopy began in 1805, when Phillip Bozzini first used a system to visualise the inside of the rectum and bladder through a mirror, a candle and a double-lumen ureteral catheter. The first source of inner light was invented by Bruck [1]. In 1878, Maximilian Carl-Friedrich Nitze introduced the first working cystoscope that contained a prismatic lens system and a channel through which you could insert a ureteral catheter, conducted in collaboration with Joseph Leiter [2]. Diagnostic methods of gastrointestinal tract have been evolving using flexible endoscopy. Dimitrij Oscarovic Ott (1855–1929) can undoubtedly be called the true pioneer of laparoscopy, especially of natural orifice transluminal endoscopic surgery (NOTES). In 1901 already he performed abdominal examinations via a transvaginal (Tv) access calling this procedure ‘ventroscopy’ [3]. In 1954 Hopkins made a crucial development by the idea of incorporating the light into scopes using the concept of multiple lenses separated by a room of air. Hopkins could never make the fibrescope, and it was a South African, Basil Hirschowitz, who made the first flexible fiberoptic gastroscope using Hopkins’s idea [4]. Endoscopic retrograde cholangiopancreatography (ERCP) which was developed in 1968 and endoscopic ultrasound (EUS) in the 1980s are important milestones. With the development of sophisticated flexible scopes, it became feasible to conduct certain diagnostic and therapeutic GI procedures. Anthony Kalloo in 2000 reported the first peritoneoscopy on pigs [5]. Gastrointestinal (GI) NOTES is a further development in the minimal access surgery (MAS). It has been received by surgical community with scepticism similar to what happened with the first laparoscopic cholecystectomy (LC) when Muhe introduced it for the first time to the German Surgical Society in 1985. In 2004 Rao and Reddy performed the first transgastric (Tg) appendectomy [6]. In 2012, authors considered that rigid standard laparoscopy provided better organ visualisation, better lesion detection and better biopsy capability than the transgastric (Tg) and transrectal (Tr) NOTES approaches [7], and that is expected as NOTES still undergo refining and development which should push for more efforts to overcome these challenges. In spite of uncertainty, GI NOTES proved itself for a number of procedures that are applied in elective and emergency settings with significant contribution to improve the care and attained a high level of patient satisfaction and most importantly a great scale of safety and efficacy. The GI NOTES is gaining popularity but at slower rate compared to LC. It has been limited to the university institutions and big teaching tertiary centres across Europe, America and Asia. Nevertheless, large series are reported on human beings. Many centres are conducting feasibility studies on animals as well as cadavers and patients. Several obstacles are preventing the wide applications of NOTES. Of these is the need for advanced endoscopic and laparoscopic skills, infrastructure setting, funding and local health authority approval and health systems bureaucracy. Germany reports the highest number of human NOTES procedures in the Europe, while the USA is the leading state in the American continent.

## 1.1. Challenges to NOTES

### 1.1.1. Experience

The NOTES main tool is a flexible scope and unstable working platform. Preliminary endoscopic, and to less degree laparoscopic, experience is a pre-request for conducting NOTES procedures. An excellent endoscopic experience is crucial in conducting NOTES procedures [8]. A study from Germany showed endoscopic experience was the strongest influencing factor, whereas laparoscopic skills had limited impact on the performance of NOTES surgeons with previous endoscopic experience [9]. This can be explained by the ability of the endoscopist to adapt for movement and to perform procedure using unstable and flexible platform. Reputable institutions are organising training courses for NOTES, and a good example is Strasbourg in France. Training on animal models is providing opportunity of operating on living subjects and increasing the confidence of performing the procedure on patients [10]. An example of the training model is the endoscopic–laparoscopic interdisciplinary training entity (ELITE) used in Germany. One of the important issues in training is the willingness and interest of the junior surgeons to adapt NOTES in their institutions.

### 1.1.2. Governance, regulations and training

Extensive training is required for surgeons to overcome the vision–motion difficulty before they can perform NOTES safely and effectively [11]. Different bodies are sponsoring NOTES training in the USA, Europe, South America and Asia. NOSCART and EAES are leading the research, training and development of NOTES. In 2005, the American Society of Gastrointestinal Endoscopy (ASGE) and the Society of American Gastrointestinal Endoscopic Surgeons (SAGES) formed the Natural Orifice Surgery Consortium for Assessment and Research (NOSCART) and published the NOTES white paper [12, 13]. In Europe, the New European Surgical Academy (NESA) founded the NOS (Natural Orifice Surgery) working group, which is exploring another surgical route, the TransDouglas (Td) one. The NOS/SLO group is an interdisciplinary working group of the NESA. Its goal is to develop surgical procedures using the natural openings of the human body and “scarless” operations [14]. There are similar scientific bodies in South America like Brazilian group and also in Asia like Japanese, Chinese and Indian NOTES groups. The Virtual Transluminal Endoscopic Surgical Trainer (VTEST (TM)) is being developed as a platform to train for NOTES procedures and innovate NOTES tools and techniques [15]. Different tools are used in NOTES training courses. These include operating on animal models with an acceptable grade of satisfaction. One of such tool is the endoscopic–laparoscopic interdisciplinary training entity. A study has shown the constructing validity for the ELITE model which seems to be well suited for the training of NOTES as a new surgical technique [16].

### 1.1.3. Funding

The rising costs of healthcare are forcing all parties to consider both the medical risks/benefits and the economic efficiency of proposed tools and therapies [17]. Funding is required for research and for setting of the infrastructure to perform NOTES procedures on animals and

patients. NOTES surgery needs extra cost for the instruments. The endoscopic closure devices, the working platforms and scope are very expensive compared to the classical laparoscopic instrumentations. Funding is a problem in the current era, and the leading teaching centres across America and Europe can afford it. The collaboration with businesses and industries has resulted in huge budget of funds to the NOTES research. For example, by 2009 Olympus has donated \$1.25 million supporting NOTES activities in the USA [18]. Ethicon offered similar support and funding for NOSCART research in the USA. The Center for Integration of Medicine and Innovative Technology's (CIMIT) investment in NOTES research will top \$3 million overall, making CIMIT the largest financial sponsor of this technology worldwide [19].

#### *1.1.4. Pressure of common acute and elective surgical take*

Undertaking NOTES procedures in addition to the common surgical workload is adding a practical challenge. However, this can be resolved by dedicated time for specific NOTES activities. It is expected that NOTES will be a separate and distinguished speciality for the gastrointestinal surgeons.

#### *1.1.5. Bureaucracy of health systems*

It is not a surprise that the first reported NOTES procedure of appendicectomy was from the Hyderabad group in India which has less bureaucratic health system compared to Europe and the USA. The bureaucracy because of high grade of concerns about safety of any new technique or intervention. While this is a healthy issue, sometimes it defers innovations and frustrates surgeons who are trying to bring in reality and clinical practice new ideas and approaches. NOTES is not an exception to be rejected as a new method. In order to install NOTES technique, one would need extra efforts to pass through the hurdles that built up across modern health systems. In the UK we are much behind the fellow Europe states like Germany as far as NOTES is concerned. This may also be explained by less popularity of the technique in the UK. South London's Surrey University, Guildford, held the first ever NOTES training course in 2008. In the UK, there is no specific body to support NOTES research like NOSCART in the USA or the NESA group of Europe.

#### *1.1.6. Public opinion*

As expected a study of 1006 patients demonstrated public's interest in these new techniques and thus gave further support to continued research and development in this area [20]. The Swanstrom group from the USA reported that majority of the patients surveyed (56%) would choose NOTES for their cholecystectomy [21]. It is not surprising that patients would choose an approach that provides excellent cosmetic and clinical outcomes with high safety profile [22]. Surgical societies are committed to work towards perfection, and NOTES is the ultimate approach for the management of a number of surgical conditions and provides extra benefits of minimal access techniques.

#### *1.1.7. Septic complications*

NOTES is not different from classical surgery of possible risk of infection. Intravenous antibiotics in addition to topical Betadine or chlorhexidine have effectively reduced microbial



burden in both gastric and colonic mucosa in porcine model [23]. The common Tg and Tv routes are compared in animal models, and authors concluded that without gastric or vaginal lavage and antibiotic peritoneal irrigation, the Tg procedure has a higher infection rate than the Tv access. After antiseptic preparation, the bacterial load significantly decreased in the Tg group, which seems as safe as the sterile Tv approach [24]. However, in a study of 40 patients who underwent Roux-En-Y gastric bypass (RYGBP), contamination of the peritoneal cavity does occur with Tg endoscopic peritoneoscopy (TEP), but this does not lead to an increased risk of infectious complications [25]. Another study of 130 patients who underwent Tg NOTES showed that the risk of bacterial contamination secondary to peroral and Tg access is clinically insignificant [26]. Pure Tg endoscopic surgery results in less perioperative inflammatory response than laparoscopy in the early postoperative phase [27]. In a review of literature by the Darzi group, UK showed that recommendation requiring no preoperative preparation can be made for the Tg approach. Antiseptic irrigation is recommended for Tv (grade C) NOTES access, as is current practice [28].

#### *1.1.8. Intraoperative NOTES complications*

The management of intraoperative NOTES complications could be challenging. Adequate experience is therefore necessary to recognise and treat them to avoid morbidity and mortality and to minimise conversion to hybrid NOTES or open technique. Effective management of NOTES complications however is reported, for example, bleeding complications and splenic laceration [29]. For intestinal perforation, the case may be different. Authors found that small intestinal injuries are difficult to localise with currently available flexible endoscopes and accessories. Endoscopic clips, however, may be adequate for closure of small bowel lacerations if the site of injury is known [30]. A study has shown that urinary bladder injury occurring during NOTES can be successfully managed via a NOTES approach using currently available endoscopic accessories [31].

### **1.2. Principles of NOTES**

#### *1.2.1. Indications*

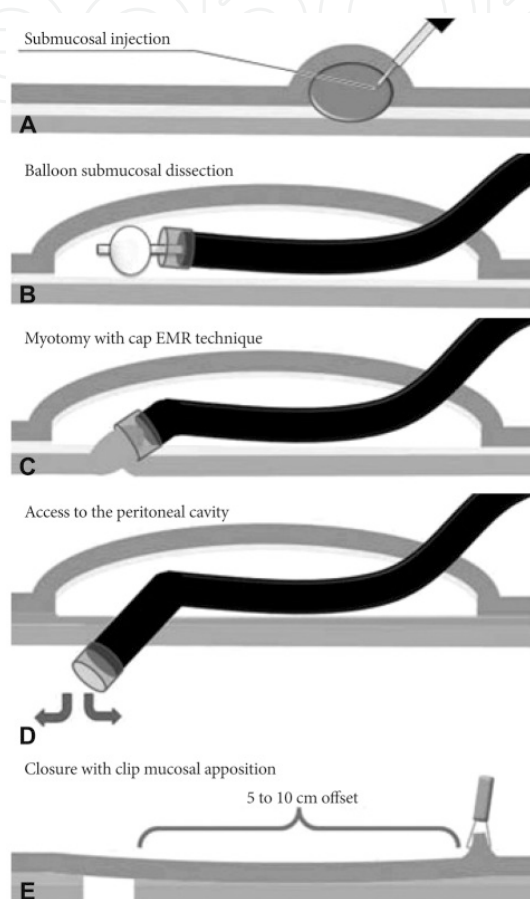
NOTES approach is indicated in a variety of conditions across surgical specialities, not only gastrointestinal tract but also urology, gynaecology and thoracic field. NOTES indications could be an emergency or elective which is the majority. This chapter is concentrating on upper GI NOTES.

#### *1.2.2. Access*

##### *1.2.2.1. Major sites for access*

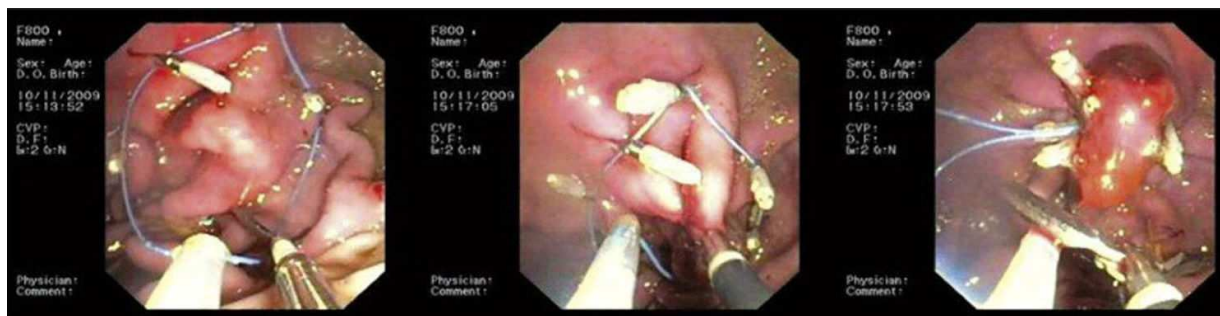
1. Transgastric (Tg): The first human NOTES procedure was performed using Tg route. The experimental studies proved ultrasonography-guided access through the stomach to be feasible and safe without iatrogenic complications [32]. There are two challenges in the Tg route: the closure and the abdominal contamination and septic complications. The ideal

Tg access closure is expected to be easy, effective, cheap and less time consuming. Tg NOTES peritoneoscopy and the gastrotomy can be closed by deploying a 2-sided ECM occluder on animal model [33]. The results indicated that closure of gastrotomy by Eagle Claw VIII could withstand higher endoluminal pneumatic bursting pressure than endoclips [34]. Submucosal approach is a new and promising technique for the development of NOTES [35] (see Figure 1).



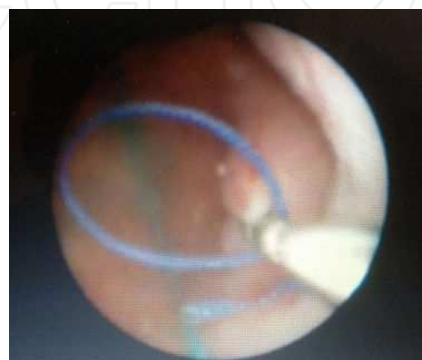**Figure 1.** Submucosal tunnel technique is used (Lee SHI et al. 2012)

The Tg access closure is provided by different techniques including clips (over-the-scope clip), sutures, etc. [36, 37]. There are different closure methods in literature, but safety is shown in one of animal studies at least comparable to the classical laparoscopy procedure [38]. A novel gastric closure device, the loop-anchor purse-string (LAPS) closure system, had been described [39]. If hybrid technique is used, then laparoscopic stapler can be applied to the gastric access [40]. A multilayer extracellular matrix (ECM) occluder is assessed on animals, and it was safe and effective [41]. A loop and clip [KING closure], (see figure 2), [42] and QUEEN closure are other methods [43]. Self-approximating transluminal access technique (STAT) and implantation of a cellular matrix in the STAT tunnel are the two methods that have shown safety and efficacy on animal model [44]. There has been a method of testing support closure with T-tags and Padlock-G-clips over OVESCO OTS-clips and standard endoscopic clips [45].



**Figure 2.** KING closure, loop and clip by Ryska O et al. 2012

2. Transvaginal (Tv): A recent meta-analysis confirmed high safety profile with this technique [46]. Infectious complications and the closure are the two important areas in this approach. A recent study of 102 Tv NOTES procedure reported only one case of infection following appendicectomy [47], which is comparable to the laparoscopic approach for similar pathology. Closure of the Tv access can be easier than Tg one [48]. Simple suturing under direct vision is the norm.
3. Transrectal (Tr): Animal studies have shown safety and efficacy [49]. The flexible endoscopic stapler is an effective device for the safe closure of a colon access, which in this feasibility study was equivalent to other well-established techniques [50]. Closure of Tr viscerotomy using end-to-end (EEA) circular stapler technique is feasible, easy to perform and histologically comparable to suture closure through a TEO platform. It may offer an attractive alternative for NOTES segmental colectomies and endoscopic resections [51]. The colostomy was closed by occlusion loop-and-clip (KING closure) technique [52]. To access the retroperitoneal space, significant challenges locating identifiable landmarks were faced mostly transrectally and improved in transgastric prone position [53].
4. Transvesical (Tve): Many animal studies have reported feasibility of NOTES procedures through the urinary bladder [54, 55]. Still there are no significant clinical applications on patients because of the challenging access closure and also because of the specimen delivery. J Bhullar et al. from Providence and medical centre, USA, used Vicryl loop for bladder access closure on a porcine model [56], (figure 3).

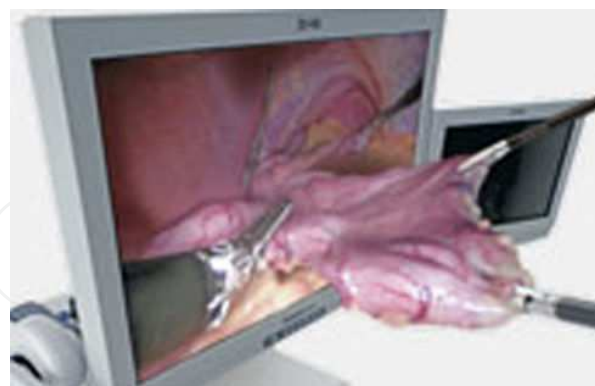

**Figure 3.** Vicryl loop closure of transvesical access (J Bhullar et al. 2012)



### 1.2.3. Instrumentation

Developing interfaces that are both intuitive and simple to use is crucial for NOTES dissemination [57]. The minimally invasive cardiac surgery (MICS) robot [58] is another step towards optimisation of the NOTES technique and to address the problems of optics, flexibility and the comfortable and adequate exposure. Abdominal navigation and accessing the pancreas was investigated on animals, and based on its success, pancreas resection was performed. A prototype multitasking platform “EndoSAMURAI” with the use of a biosimulation model and ex vivo porcine stomach was reported [59], (figure 5). There are new ancillary instruments like forceps, and training on using them is continuing [60]. The SPIDER platform is a sterile and disposable device that contains 4 working channels (2 flexible instrument delivery tubes positioned laterally and 2 rigid channels superiorly and inferiorly to accommodate an endoscope or any of the shelf rigid surgical instruments) [61]. This device has addressed some of the technical problems, and it is relatively expensive which limits its wide use. Authors concluded that the new manual handling system (MHS) is fully capable of achieving payload transport during a NOTES operation. The system is intuitive and easy to use. It dramatically decreases collateral trauma in the natural access point and can advantageously reduce the overall duration of a procedure [62]. The 3D display system is a great step in optics development. At least 34 systems are developed, for example, Aesculap’s EinsteinVision (see Figure 4). This is in current use for laparoscopy and has the potential to improve the vision and anatomy at challenging NOTES procedures [63]. The Direct Drive Endoscopic System (DDES; Boston Scientific, Natick, MA) is a flexible laparoscopic multitasking platform that consists of a 55-cm steerable guide sheath that houses 3 lumens extending from a rail-based platform with interchangeable 4-mm instruments [64], (figure 6). Incisionless Operating Platform (IOP) is another flexible scope used for NOTES procedures including cholecystectomy [65].



**Figure 4.** Aesculap’s EinsteinVision® system

### 1.2.4. Anaesthesia

There are three main issues when using transoral access to perform upper GI NOTES procedures: The first one is to intubate via transnasal route to spare the oral space for NOTES flexible scope, the second issue is to position the patient according to the type of procedure, and the

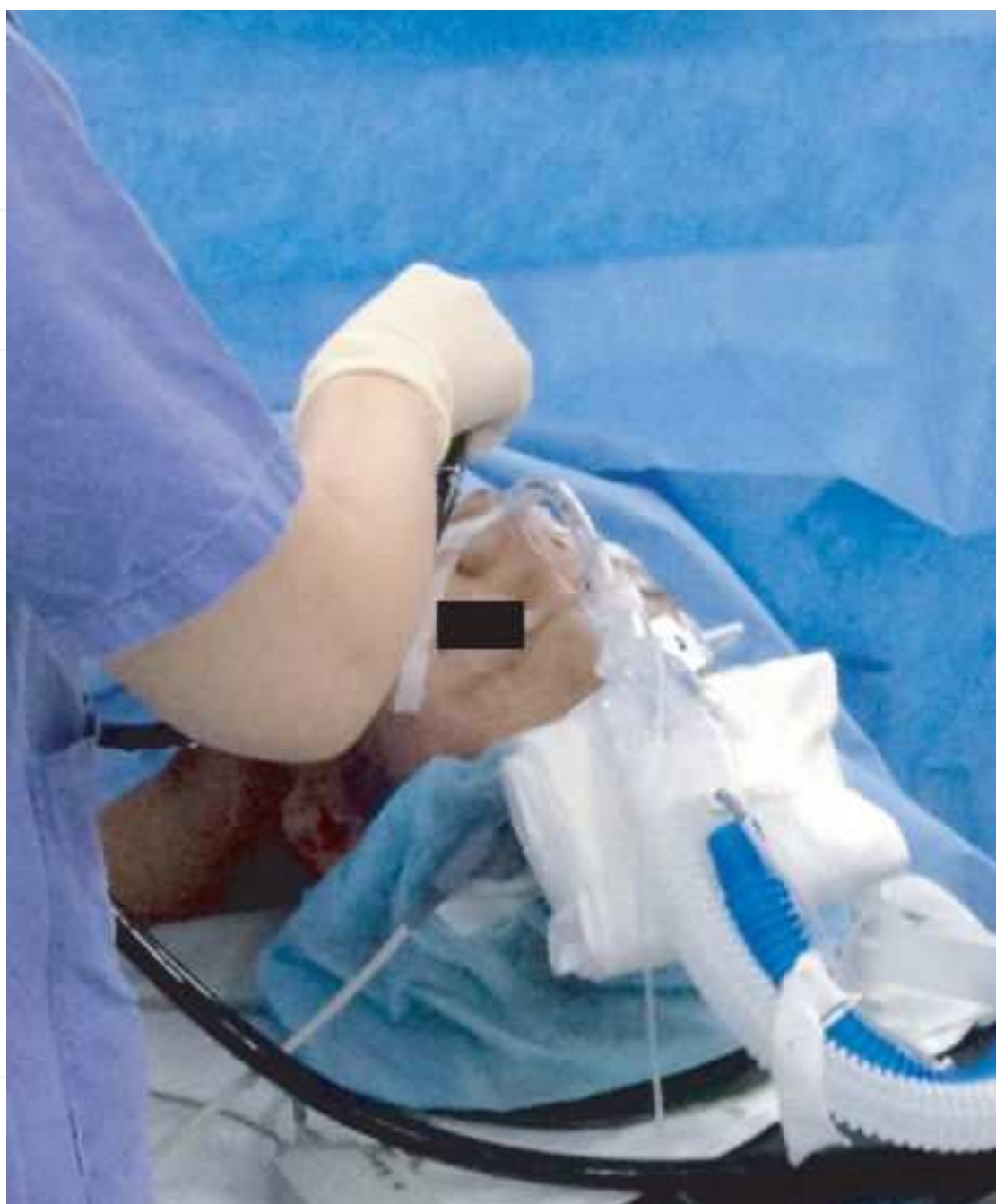

**Figure 5.** EndoSAMURAI platform, Yasuda K et al. 2014



**Figure 6.** Direct Drive Endoscopic System (DDES), S Shaik et al. 2010

third point is to monitor ETCO<sub>2</sub> [66], (figure 7). For other NOTES accesses, transnasal intubation is not necessary. Anaesthetic technique can be different from laparoscopic surgery. The effect of pneumoperitoneum may be not different; both techniques will have pneumoperitoneum if it is abdominal NOTES procedure. POEM procedure, for example, does not need pneumoperitoneum [67, 68]. Any patient that cannot tolerate pneumoperitoneum because of cardiopulmonary disease is not a candidate for NOTES procedure. Cardiorespiratory physiology is affected by laparoscopic procedure mainly because of pneumoperitoneum. However, the non-inferiority of NOTES compared to the laparoscopy is demonstrated from reported studies, although the evidence is limited by a number of researches [69]. When administering anaesthetic care to a patient undergoing NOTES, anaesthesiologists should closely monitor the patient's position as well as ETCO<sub>2</sub> to minimise the incidence of mediastinal emphysema and pneumomediastinum and to ensure early detection of pneumoperitoneum-related respiratory and hemodynamic changes [70].



**Figure 7.** Transnasal intubation in upper GI NOTES. The patient was placed in the supine position and intubated via a nasal RAE™ tracheal tube. The endoscopic operator stood near the head of the patient and inserted the endoscope via the mouth (Ji Hyeon Lee et al. 2014)

#### *1.2.5. Setting*

NOTES units are part of surgical departments whether upper or lower GI, gynaecology and urology units. These units are usually located in well-established teaching hospitals. Theatre facilities are available for minimal access approach. Staffs are trained in NOTES, and they are familiar with the preparation and assistance.

### *1.2.6. Expertise*

NOTES experience is crucial for the quality and safety of this intervention. The current guidelines advise to run through milestones of animal studies, cadaveric and live subject experimental and pilot projects. Once the learning curve is achieved after a number of procedures, NOTES can be performed under strict governance system. This has been achieved in a number of US and European states.

### *1.2.7. Complications*

All minimal access surgery serious complications are those of organ injury due to suboptimal exposure that results from bad technique. It is anatomical and visual hallucination. This is to be avoided to provide the high grade of safety. Industries, related professionals and surgeons are striving to address all the issues that preclude safety.

## **2. Upper GI NOTES**

### **2.1. Oesophagus NOTES**

A number of oesophageal NOTES procedures are conducted safely on patients. Oesophageal discontinuity, which is a very complex procedure, is performed using a modification of NOTES [71]. The peroral endoscopic myotomy (POEM) for lower oesophageal conditions like achalasia has been performed on animals and patients with great success. NOSCART has recently produced its white paper about the milestones of the POEM technique and the current opinion about the indications and quality and safety [72]. Distal oesophageal spasm that can progress to achalasia is another indication for POEM [73]. In 2002, Smith et al. found that the endoscopic stapling technique for the treatment of Zenker diverticulum results in a statistically significant shorter operative time, hospital stay and time to resume oral feedings compared with the standard open technique [74]. Transoesophageal approach to posterior mediastinum has been reported on animal models [75]. Transoesophageal, anterior spinal NOTES reported lymph node resection, vagotomy, thoracic duct ligation, thymectomy, biopsy of the lung and pleura, epicardial coagulation, saline injection into the myocardium, pericardial fenestration and anterior thoracic spine procedures [76]. Exposure of the GOJ and placement of an anti-reflux prosthesis via a hybrid NOTES procedure were feasible, despite some complications [77]. Transluminal oesophago-oesophageal anastomosis was feasible on animal model [78]. Transoesophageal thoracic NOTES are a growing field. Diagnostic procedures have been well described. Closure of the oesophageal access is managed by different approaches including stenting [79].

### **2.2. Gastric NOTES**

Gastric resection and specimen extraction through the upper GI route are reported by authors [80]. On animal models, a gastrojejunostomy was feasible with a 4-cm length using an anastomosing metal stent. After gastrotomy formation using a needle knife, a jejunotomy was

then performed in the gastric cavity, which was followed by deployment of an anastomosing metal stent under fluoroscopic guidance [81]. Also on porcine model, combined NOTES and single trocar sleeve gastrectomy is feasible in a porcine model [82]. Through Tv NOTES gastrectomy for gastric submucosal tumours, with the assistance of two transabdominal ports, “oncologically acceptable” partial gastrectomy was successfully performed [83].

The hybrid NOTES technique is a combined method, including the advantages of both laparoscopic resection and endoscopic resection for gastric subepithelial tumours (SETs) [84]. After a 40-mm submucosal tunnel was created using an endoscopic submucosal dissection technique, in TGP, balloon dilation of a serosal puncture and intraperitoneal exploration were performed; in EFTR, a full-thickness incision and snaring resection were performed. Closure of the mucosal incision was performed by endoclips [85].

Hybrid sleeve gastrectomy (SG) and delivery of the specimen by transoral remnant extraction (TORE) are feasible and avoid port complications [86]. A study of 136 patients showed that Tv hybrid NOTES SG technique can be performed, but there is still a need for additional trocars through the abdominal wall [87]. Combined use of laparoscopy and NOTES enabled gastric pull-up without cervical and thoracic incisions [88]. NOTES omental repair of gastric perforation appears comparable to that of laparoscopy [89]. Hybrid NOTES resection of gastric gastrointestinal stromal tumour (GIST) was successfully reported on patients [90].

### 2.3. Duodenal NOTES

Currently, there is scarce of literatures on duodenal NOTES. This is because of rarity of duodenal pathologies that benefits from NOTES. Peritoneoscopy is actively used to assess upper GI tract including the duodenum [91]. This approach is feasible in selected series of patients [92].

### 2.4. Liver NOTES

Continued development of NOTES techniques may further alter the approaches to the biliary tract, liver and pancreas [93]. On animal models intraoperative NOTES-EUS is feasible to assess liver lesions [94]. Liver biopsy was performed successfully without any bleeding, and adequate samples were obtained in animal cases [95]. Using the Erbe Jet2 water-jet system, transanal and transvaginal wedge hepatic resection was successfully performed [96]. Tr liver resection and delivery of specimen were feasible and safe without problem of the rectal access [97]. Another study reported an animal liver wedge resection using MASTER robot [98]. Human cases of liver resection were reported as well. A combined laparoscopic Tv approach was used. Four 5-mm trocars were used. The liver parenchyma was divided using the harmonic scalpel, whereas the left hepatic vein was transected using the laparoscopic Tv vascular stapler. The specimen was placed in an Endobag and extracted transvaginally [99]. Complex liver surgery like hepatico-jejunostomy, major hepatic resection and transplantation is unlikely to be introduced at this stage due to the current limitations of the technique.



## 2.5. Pancreas NOTES

It is technically possible by EUS-guided NOTES procedures to achieve a systematic anterior and posterior access for NOTES transgastric peritoneoscopy and direct pancreatic endoscopic procedures [100]. Peripancreatic abscess can be managed by transgastric endoscopy and debridement with successful outcome, which provides great benefits of minimal access approach [101, 102]. NOTES cystogastrostomy for pancreatic pseudocyst management included endoscopic ultrasound (EUS)-guided puncture of the stomach just below the gastroesophageal (GOJ) junction to gain access to the pseudocyst, guidewire placement and then dilatation with a balloon to 18–20 mm. Endoscopic necrosectomy and debridement were performed, followed by transoral surgical anastomosis under endoscopic visualisation with the SurgAssist™ SLC 55 (Power Medical Interventions, Langhorne, PA) using 4.8-mm stapler [103]. A robotic platform to perform complex distal pancreatectomy on animal model was described [104].

## 2.6. Spleen NOTES

To dissect the upper end of the gastrosplenic ligament and the marginal region between the left diaphragm and upper pole of the spleen, a flexible single-channel endoscope was introduced into the peritoneal cavity simultaneously with the use of a rigid laparoscope. This is also providing the benefits of water-jet lens cleaning, effective suction and better visualisation in dissection of all splenic attachments and ligaments [105]. Hybrid splenectomy is performed on animal models without major complications indicating safety and feasibility [106]. Tv visualisation of the spleen and standard dissection of attachments were feasible, and splenectomy was completed using Tv stapling of the splenic hilum which is safely performed on patient [107].

## 2.7. Biliary NOTES

A comparison of the surgical errors during electrosurgery gallbladder dissection establishes that the NOTES procedure, while still new, is not inferior to the established laparoscopic cholecystectomy procedure [108]. NOTES cholecystectomy is the commonest upper GI procedure performed on patients. More than 3000 procedures are reported by now. Largest series of more than 2653 cases is from Germany [109]. Only 15% of NOTES cholecystectomy is performed in the USA. Two recent review studies showed increasing number of NOTES cholecystectomy [110, 111]. NOTES peritoneoscopy for accurate diagnosis and staging of intra-abdominal cancers is already in clinical use. Peritoneoscopy can accurately assess hepato-pancreatic-biliary malignancy and lymph node status [112].

## 2.8. Bariatric Surgery NOTES

Authors reported combined Tv and abdominal variant of SG on humans [113]. On animal models, hybrid NOTES SG is reported [114, 115]. The procedure was performed on humans using hybrid technique [116]. Roux-En-Y GBP was very challenging procedure and needed development of NOTES instruments to make it safe, feasible and time-effective operation.

Trials on human cadavers concluded feasibility, but long operative time mainly because of the lack of proper instrumentation resulting in insufficient tissue traction, countertraction and instrument manipulation complicated several steps during the procedure [117]. There are human series of hybrid NOTES RYGBP for obesity [118]. NOTES gastric band procedure was reported on a patient [119].(see table 1).

Authors	Year	Reference	Operation	Human subjects	Animal subjects
Spaun GO et al.	2010	[134]	Transcervical Heller's myotomy	Yes	Yes
Swanstrom et al.	2010	[135]	Oesophageal mobilisation	Yes	Yes
Welhelm et al.	2010	[77]	Anti-reflux surgery	No	Yes
Swanstrom et al.	2011	[136,137,72]	Endoscopic myotomy	Yes	No
Rieder et al.	2011	[138,74]	Zenker diverticulectomy	No	Yes
Ishimaru et al.	2011	[139]	Gastric pull through for oesophageal atresia	No	Yes
Turner et al.	2011	[140]	Closure of oesophageal access site	No	Yes
Turners et al.	2011	[141,79]	Stent closure of oesophageal access site	No	Yes
Rolanda et al.	2011	[142]	Peroral oesophageal segmentectomy	No	Yes
Cho et al.	2011	[143]	Resection of early gastric cancer	Yes	No
Abe et al.	2009	[144]	Gastric submucosal tumour resection	Yes	No
Nau et al.	2011	[118]	Staging pancreatic mass	Yes	No
			Hybrid gastric bypass	Yes	No
			Pure gastric bypass	Yes	No
Chiu et al.	2010	[145]	Tg gastrojejunostomy	No	Yes
Campos et al.	2010	[146]	Tg drainage of abdominal abscess	Yes	No
Cahill et al.	2009	[147]	Tv gastric lymph node mapping	No	Yes
Luo et al.	2012	[148]	Tg gastrojejunostomy	No	Yes
Ikeda et al.	2011	[149]	Gastric full-thickness resection	No	Yes
Lacey et al.	2009	[150,112,87]	Hybrid sleeve gastrectomy	Yes	No
Michalik et al.	2011	[117]	Hybrid gastric band	Yes	No
Branco et al.	2011	[151]	Transvesical peritoneoscopy, liver biopsy, appendix manipulation	Yes	No
Truong et al.	2012	[152]	Hybrid liver resection	Yes	No
Shi et al.	2011	[153]	Pure liver resection	No	Yes
Lehman et al.	2014	[122]	Cholecystectomy	Yes	No

Authors	Year	Reference	Operation	Human subjects	Animal subjects
			Peritoneum	Yes	No
			Gastric surgery	Yes	No
			Liver surgery	Yes	No
Bakker OJ et al.	2012	[101,102]	Tg pancreatic necrosectomy	Yes	No
Pallapothu et al.	2011	[103]	Cystogastrostomy	Yes	No
Targarona et al.	2009	[107]	Tv splenectomy	Yes	No

**Table 1.** Important upper GI NOTES procedures

### 3. Lower GI NOTES

#### 3.1. Small bowel NOTES

Small intestinal anastomosis was performed in a porcine intestinal Tr NOTES model using two robotic arms and a camera inserted through the proctoscope and a rectal anterior wall incision [120]. NOTES gastroenterostomy with a biflanged lumen-apposing stent was reported recently by collaboration of French and US centres. The procedure was feasible and safe with only one minor complication [121]. This has the potential to treat variable distal gastric pathology by this type of NOTES anastomosis.

#### 3.2. Appendicectomy

The first human NOTES procedure was Tg appendicectomy performed by Rao and Reddy in 2004 in India. Many cases were reported after that [122, 123]. German registry showed that more than 6% [182 cases] of human NOTES procedure was appendicectomy done by Tg and Tv routes. Not only slim patients but also morbidly obese patients benefited from NOTES appendicectomy [124]. A 5-mm trocar was inserted through the umbilicus and a 5-mm telescope was placed. A 12-mm trocar and a 5-mm grasper were inserted separately through the posterior fornix of the vagina under laparoscopic guidance. The appendix was divided with an endoscopic stapler through the Tv 12-mm trocar and removed from the same trocar [125].

#### 3.3. Colonic NOTES

Pure NOTES resection and anastomosis of the large bowel were feasible, and the colorectal anastomosis was achieved using circular stapler [126]. Early clinical series of transanal TME with laparoscopic assistance (n = 72) were promising, with overall intraoperative and postoperative complication rates of 8.3% and 27.8%, respectively, similar to laparoscopic TME [127]. NOTES TME was feasible and safe in this series of patients with mid- or low rectal tumours [128]. Transanal full-thickness circumferential rectal and mesorectal dissections were per-

formed, and a colorectal anastomosis was performed using a circular stapler with a single stapling technique. During the transanal approach, the gastrotomy was closed using four endoscopic clips [129]. On large series of human cadavers, transanal NOTES rectosigmoid resection with TME was feasible and demonstrates improvement in specimen length and operative time with experience. Transrectal retrograde rectosigmoid dissection was achieved in all attempts and showed numbers of lymph nodes similar to the laparoscopic group [130, 131]. A transrectal endoscopic device was used for optic assistance, colon dissection, ileum section and specimen retrieval. Transrectal MA-NOS total colectomy was assisted by three laparoscopic ports: A 12-mm port is used as the terminal ileostomy site [132]. Hybrid Tv resection of descending colon was feasible on animal model. Only one 5-mm transumbilical port was added for safety [133]. Long-segment Hirschsprung’s disease was managed by NOTES. Authors reported the technique, which starts by a rectal mucosectomy 0.5 cm proximal to the dentate line and extending proximally to the level of the intraperitoneal rectum. Three cannulas were inserted through the muscular sleeve into the abdominal cavity. After colonic mobilisation, the ganglionic distal bowel segment was pulled through the anus and resected and the colo-anal anastomosis was created [134], (see table 2).

Authors	Year	Reference	Operation	Human subjects	Animal subjects
Demura et al.	2013	[119]	Small bowel anastomosis	No	Yes
Barthet M et al.	2015	[120]	Gastroenterostomy	Yes	No
Lehman et al.	2014	[122]	Appendicectomy	Yes	No
Bernhardt J et al.	2012	[125]	Sigmoid colectomy	No	Yes
Chouillard et al.	2014	[127]	TME	Yes	No
Park SJ et al.	2013	[128]	Rectosigmoid resection	No	Yes
Telem DA et al.	2013	[129]	TME [cadavers]	Yes	No
Lacy AM et al.	2012	[131]	Hybrid total colectomy	Yes	No
Alba mesa et al.	2012	[132]	Descending colon resection	No	Yes
Li N et al.	2013	[133]	Hirschsprung’s segment resection	Yes	No

**Table 2.** Important lower GI NOTES procedures

4. Further research

NOTES is evolving and refinement of the technique is warranted for feasibility, safety, operative time effectiveness and practicality. Three hot areas are expected to be the focus for further research:

1. Development of technology: this includes instruments, optics and working platforms.

2. Exploration of practicality of NOTES application in complex abdominal procedures and new fields like thoracic and retroperitoneal procedures.
3. Training: NOTES needs an advanced endoscopic and minimal access skills. Surgeons who already attended this level are those who are leading NOTES research in the respected academic institutions in the USA, Europe and Asia. What is needed is to organise an effective and specific dedicated training programme to produce NOTES trained surgeons. NOTES is expected to be an independent specialty that works to meet patient's expectation by making the most use of modern surgery and technology.

## 5. Conclusions

NOTES is gaining interest and popularity among surgeons. Many new procedures are reported as feasibility studies on animal models. Other procedures are starting to establish itself in clinical practice like NOTES cholecystectomy, appendicectomy and peritoneoscopy. Tv and Tg access routes are the commonest and closure technique is evolving to achieve a high degree of safety and effectiveness. Many new clinical procedures are introduced and currently are at experimental level. Development of the technology and instrumentation, effective training and support are expected to push NOTES further towards its long track of refinement and milestone journey towards an accepted and well-established standard technique.

## Author details

Abdulzahra Hussain<sup>1,2\*</sup>

Address all correspondence to: [abdulzahra.hussain@nhs.net](mailto:abdulzahra.hussain@nhs.net)

1 Upper GI Surgeon at Airedale Hospital NHS Foundation Trust, Keighley, Bradford, UK

2 Honorary Senior Lecturer, King's College Medical School, London, UK

## References

- [1] Lau WY, Leow CK, Li AK. History of endoscopic and laparoscopic surgery. *World J Surg.* 1997;21(4):444-453.
- [2] José FN. and Angel C.. NOTES, MANOS, SILS and other new laparoendoscopic techniques. *World J Gastrointest Endosc.* 2012; 4(6): 212-7.
- [3] Hatzinger M1, Fesenko A, Sohn M. The first human laparoscopy and NOTES operation: Dimitrij Oscarovic Ott (1855-1929). *Urol Int.* 2014;92(4):387-91.



- [4] <http://www.baus.org.uk/Resources/BAUS/Documents/10-hopkins.pdf>. Date of access 13/11/2014.
- [5] Kalloo AN<sup>1</sup>, Singh VK, Jagannath SB, Niiyama H, Hill SL, Vaughn CA, Magee CA, Kantsevov SV. Flexible transgastric peritoneoscopy: a novel approach to diagnostic and therapeutic interventions in the peritoneal cavity. *Gastrointest Endosc.* 2004 ; 60(1):114-7.
- [6] Hussain A, Mahmood H. NOTES: current status and expectations. *European Surgery.* 2008; 40(4):176-186.
- [7] Von Renteln D<sup>1</sup>, Gutmann TE, Schmidt A, Vassiliou MC, Rudolph HU, Caca K. Standard diagnostic laparoscopy is superior to NOTES approaches: results of a blinded randomized controlled porcine study. *Endoscopy.* 2012;44(6):596-604.
- [8] Auyang ED, Santos BF, Enter DH, Hungness ES, Soper NJ. Natural orifice transluminal endoscopic surgery (NOTES<sup>®</sup>): a technical review. *Surg Endosc.* 2011;25(10): 3135-48
- [9] Gillen S<sup>1</sup>, Gröne J, Knödgen F, Wolf P, Meyer M, Friess H, Buhr HJ, Ritz JP, Feussner H, Lehmann KS. Educational and training aspects of new surgical techniques: experience with the endoscopic–laparoscopic interdisciplinary training entity (ELITE) model in training for a natural orifice transluminal endoscopic surgery (NOTES) approach to appendectomy. *Surg Endosc.* 2012;26(8):2376-82.
- [10] Song S, Itawi EA, Saber AA. Natural orifice transluminal endoscopic surgery (NOTES). *J Invest Surg.* 2009;22(3):214-7.
- [11] Cassera MA<sup>1</sup>, Zheng B, Spaun GO, Swanström LL. Optimizing surgical approach for natural orifice transluminal endoscopic procedures. *Surg Innov.* 2012;19(4):433-7.
- [12] Rattner D, Kalloo AN, The SAGES/ASGE working group on natural orifice transluminal endoscopic surgery ASGE/SAGES working group on natural orifice transluminal endoscopic surgery. *Surg Endosc.* 2005;20(2):329–33.
- [13] Rattner D. Introduction to NOTES white paper. *Surg Endosc.* 2006;20(2):185.
- [14] <http://www.nesacademy.org/projects.html>. Date of access 03/12/2014.
- [15] Dargar S<sup>1</sup>, Solley T, Nemani A, Brino C, Sankaranarayanan G, De S. The development of a haptic interface for the Virtual Transluminal Endoscopic Surgical Trainer (VTEST). *Stud Health Technol Inform.* 2013;184:106-8.
- [16] Gillen S, Fiolka A, Kranzfelder M, Wolf P, Feith M, Schneider A, Meining A, Friess H, Feussner H. Training of a standardized natural orifice transluminal endoscopic surgery cholecystectomy using an ex vivo training unit. *Endoscopy.* 2011;43(10): 876-81.

- [17] Schwaitzberg SD<sup>1</sup>, Hawes RH, Rattner DW, Kochman ML. Novel challenges of multi-society investigator-initiated studies: a paradigm shift for technique and technology evaluation. *Surg Endosc*. 2013;27(8):2673-7.
- [18] <http://www.endonurse.com/news/2009/07/olympus-donates-250-000-to-notes-research.aspx>. Date of access 03/12/2014.
- [19] <http://www.cimit.org/programs-notes.html>. Date of access 25/12/2014.
- [20] Chow A<sup>1</sup>, Purkayastha S, Dosanjh D, Sarvanandan R, Ahmed I, Paraskeva P. Patient reported outcomes and their importance in the development of novel surgical techniques. *Surg Innov*. 2012;19(3):327-34.
- [21] Swanstrom LL<sup>1</sup>, Volckmann E, Hungness E, Soper NJ. Patient attitudes and expectations regarding natural orifice translumenal endoscopic surgery. *Surg Endosc*. 2009;23(7):1519-25.
- [22] Fei YF, Fei L, Salazar M, Renton DB, Hazey JW. Transvaginal surgery: do women want it. *J Laparoendosc Adv Surg Tech A*. 2014;24(10):676-83.
- [23] Ryou M<sup>1</sup>, Hazan R, Rahme L, Thompson CC. An ex vivo bacteriologic study comparing antiseptic techniques for natural orifice translumenal endoscopic surgery (NOTES) via the gastrointestinal tract. *Dig Dis Sci*. 2012;57(8):2130-6.
- [24] Yang QY<sup>1</sup>, Zhang GY, Wang L, Wang ZG, Li F, Li YQ, Ding XJ, Hu SY. Infection during transgastric and transvaginal natural orifice transluminal endoscopic surgery in a live porcine model. *Chin Med J (Engl)*. 2011;124(4):556-61.
- [25] Memark VC<sup>1</sup>, Anderson JB, Nau PN, Shah N, Needleman BJ, Mikami DJ, Melvin WS, Hazey JW. Transgastric endoscopic peritoneoscopy does not lead to increased risk of infectious complications. *Surg Endosc*. 2011;25(7):2186-91.
- [26] Nau P<sup>1</sup>, Ellison EC, Muscarella P Jr, Mikami D, Narula VK, Needleman B, Melvin WS, Hazey JW. A review of 130 humans enrolled in transgastric NOTES protocols at a single institution. *Surg Endosc*. 2011;25(4):1004-11.
- [27] Georgescu I<sup>1</sup>, Saftoiu A, Patrascu S, Silosi I, Georgescu E, Surlin V. Perioperative inflammatory response in natural orifice translumenal endoscopic surgery. *Surg Endosc*. 2013;27(7):2551-6.
- [28] Sodergren MH<sup>1</sup>, Pucher P, Clark J, James DR, Sockett J, Matar N, Teare J, Yang GZ, Darzi A. Disinfection of the access orifice in NOTES: evaluation of the evidence base. *Diagn Ther Endosc*. 2011;(2011):245175. doi: 10.1155/2011/245175.
- [29] Fyock CJ<sup>1</sup>, Kowalczyk LM, Gupte AR, Forsmark CE, Wagh MS. Complications during natural orifice translumenal endoscopic surgery: endoscopic management of splenic laceration and hemorrhage. *J Laparoendosc Adv Surg Tech A*. 2011;21(1):39-43.

- [30] Fyock CJ1, Forsmark CE, Wagh MS. Endoscopic management of intraoperative small bowel laceration during natural orifice transluminal endoscopic surgery: a blinded porcine study. *Surg Tech A*. 2011;21(6):525-30.
- [31] Fyock CJ1, Parekattil SJ, Atalah H, Su LM, Forsmark CE, Wagh MS. The NOTES approach to management of urinary bladder injury. *JLS*. 2011;15(3):285-90.
- [32] Donatsky AM. Assessing transgastric natural orifice transluminal endoscopic surgery prior to clinical implementation. *Dan Med J*. 2014;61(8):B4903.
- [33] Sanz AF1, Hoppo T, Witteman BP, Brown BN, Gilbert TW, Badylak SF, Jobe BA, Nieponice A. In vivo assessment of a biological occluder for NOTES gastrotomy closure. *Surg Laparosc Endosc Percutan Tech*. 2014;24(4):322-6.
- [34] Liu L1, Chiu PW, Teoh AY, Lam CC, Ng EK, Lau JY. Endoscopic suturing is superior to endoclips for closure of gastrotomy after natural orifices transluminal endoscopic surgery (NOTES): an ex vivo study. *Surg Endosc*. 2014 ;28(4):1342-7.
- [35] Lee SH1, Cho WY, Cho JY. Submucosal endoscopy, a new era of pure natural orifice transluminal endoscopic surgery (NOTES). *Clin Endosc*. 2012;45(1):4-10.
- [36] Sanz AF, Hoppo T, Witteman BP, Brown BN, Gilbert TW, Badylak SF, Jobe BA, Nieponice A. In vivo assessment of a biological occluder for NOTES gastrotomy closure. *Surg Laparosc Endosc Percutan Tech*. 2014;24(4):322-6.
- [37] Sun G, Yang Y, Zhang X, Li W, Wang Y, Zhang L, Tang P, Kong J, Zhang R, Meng J, Wang X. Comparison of gastrotomy closure modalities for natural orifice transluminal surgery: a canine study. *Gastrointest Endosc*. 2013;77(5):774-83.
- [38] Guarner-Argente C1, Beltrán M, Martínez-Pallí G, Navarro-Ripoll R, Martínez-Zamora MÀ, Córdova H, Comas J, De Miguel CR, Rodríguez-D'Jesús A, Almela M, Hernández-Cera C, Lacy AM, Fernández-Esparrach G. Infection during natural orifice transluminal endoscopic surgery peritoneoscopy: a randomized comparative study in a survival porcine model. *J Minim Invasive Gynecol*. 2011;18(6):741-6.
- [39] Romanelli JR1, Desilets DJ, Chapman CN, Surti VC, Lovewell C, Earle DB. Loop-anchor purse-string closure of gastrotomy in NOTES(R) procedures: survival studies in a porcine model. *Surg Innov*. 2010;17(4):312-7.
- [40] Dostalík J, Gunková P, Gunka I, Mazur M, Mrazek T. Laparoscopic gastric resection with natural orifice specimen extraction for postulcer pyloric stenosis. *Wideochir Inne Tech Malo Inwazyjne*. 2014; 9(2): 282–285.
- [41] Sanz AF1, Hoppo T, Witteman BP, Brown BN, Gilbert TW, Badylak SF, Jobe BA, Nieponice A. In vivo assessment of a biological occluder for NOTES gastrotomy closure. *Surg Laparosc Endosc Percutan Tech*. 2014;24(4):322-6.
- [42] Ryska O, Martinek J, Filipkova T, Dolezel R, Juhasova J, Motlik J, Zavoral M, Ryska M. Single loop-and-clips technique (KING closure) for gastrotomy closure after

transgastric ovariectomy: a survival experiment. *Wideochir Inne Tech Malo Inwazyjne*. 2012 ;7(4):233-9.

- [43] Hookey LC, Khokhotva V, Bielawska B, et al. The Queen's closure: a novel technique for closure of endoscopic gastrotomy for natural-orifice transluminal endoscopic surgery. *Endoscopy*. 2009;41(2):149–53.
- [44] Gopal J1, Pauli EM, Haluck RS, Moyer MT, Mathew A. Intramural acellular porcine dermal matrix (APDM)-assisted gastrotomy closure for natural orifice transluminal endoscopic surgery (NOTES). *Surg Endosc*. 2012;26(8):2322-30.
- [45] Azadani A1, Bergström M, Dot J, Abu-Suboh-Abadia M, Armengol-Miró JR, Park PO. A new in vivo method for testing closures of gastric NOTES incisions using leak of the closure or gastric yield as endpoints. *J Laparoendosc Adv Surg Tech A*. 2012 ; 22(1):46-50.
- [46] Sodergren MH1, Markar S, Pucher PH, Badran IA, Jiao LR, Darzi A. Safety of transvaginal hybrid NOTES cholecystectomy: a systematic review and meta-analysis. *Surg Endosc*. 2014; (26) [Epub ahead of print].
- [47] Wood SG1, Panait L, Duffy AJ, Bell RL, Roberts KE. Complications of transvaginal natural orifice transluminal endoscopic surgery: a series of 102 patients. *Ann Surg*. 2014;259(4):744-9.
- [48] Zornig C1, Mofid H, Siemssen L, Wenck CH. Transvaginal access for NOTES. *Chirurg*. 2010;81(5):426-30.
- [49] Kono Y1, Yasuda K, Hiroishi K, Akagi T, Kawaguchi K, Suzuki K, Yoshizumi F, Inomata M, Shiraishi N, Kitano S. Transrectal peritoneal access with the submucosal tunnel technique in NOTES: a porcine survival study. *Surg Endosc*. 2013;27(1):278-85.
- [50] Sodergren M1, Clark J, Beardsley J, Bryant T, Horton K, Darzi A, Teare J. A novel flexible endoluminal stapling device for use in NOTES colotomy closure: a feasibility study using an ex vivo porcine model. *Surg Endosc*. 2011;25(10):3266-72.
- [51] Diana M1, Leroy J, Wall J, De Ruijter V, Lindner V, Dhumane P, Mutter D, Marescaux J. Prospective experimental study of transrectal viscerotomy closure using transanal endoscopic suture vs. circular stapler: a step toward NOTES. *Endoscopy*. 2012 ;44(6):605-11.
- [52] Ryska O1, Filípková T, Martínek J, Dolezel R, Juhás S, Juhásová J, Zavoral M, Ryska M. [Transrectal hybrid NOTES versus laparoscopic cholecystectomy--a randomized prospective study in a large laboratory animal] *Rozhl Chir*. 2011;90(12):695-700.
- [53] Moran EA1, Bingener J, Murad F, Levy MJ, Gostout CJ. The challenges with NOTES retroperitoneal access in humans. *Surg Endosc*. 2011;25(4):1096-100.

- [54] Bin X1, Bo Y, Dan S, Okhunov Z, Ghiraldi E, Huiqing W, Friedlander J, Liang X, Yinghao S, Kavoussi LR. A novel transvesical port for natural orifice transluminal endoscopic surgery. *J Endourol*. 2012;26(3):219-23.
- [55] Jeong CW1, Oh JJ, Abdullajanov M, Yeon J, Lee HE, Jeong SJ, Hong SK, Byun SS, Lee SB, Kim HH, Lee SE. Pure transvesical NOTES uterine horn resection in swine as an appendectomy model. *Surg Endosc*. 2012;26(2):558-64.
- [56] Bhullar JS, Subhas G, Gupta A, Jacobs MJ, Decker M, Silberberg B, Mittal VK. Transvesical NOTES: survival study in porcine model. *JSLs*. 2012;16(4):606-11.
- [57] Kranzfelder M1, Schneider A2, Fiolka A2, Koller S2, Wilhelm D2, Reiser S2, Meining A2, Feussner H2. What do we really need? Visions of an ideal human-machine interface for NOTES mechatronic support systems from the view of surgeons, gastroenterologists, and medical engineers. *Surg Innov*. 2014;(23). pii: 1553350614550720. [Epub ahead of print].
- [58] Thakkar S1, Awad M2, Gurram KC3, Tully S4, Wright C4, Sanan S4, Choset H4. A novel, new robotic platform for natural orifice distal pancreatectomy. *Surg Innov*. 2014(15). pii: 1553350614554232. [Epub ahead of print].
- [59] Yasuda K, Kitano S, Ikeda K, Sumiyama K, Tajiri H. Assessment of a manipulator device for NOTES with basic surgical skill tests: a bench study. *Surg Laparosc Endosc Percutan Tech*. 2014;24(5):e191-5.
- [60] Addis M1, Aguirre M, Frecker M, Haluck R, Matthew A, Pauli E, Gopal J. Development of tasks and evaluation of a prototype forceps for NOTES. *JSLs*. 2012;16(1):95-104.
- [61] Villamizar N1, Pryor AD. SPIDER and flexible laparoscopy: the next frontier in abdominal surgery. *Surg Technol Int*. 2010 ;20:53-8.
- [62] Midday J1, Nelson CA, Oleynikov D. Improvements in robotic natural orifice surgery with a novel material handling system. *Surg Endosc*. 2013;27(9):3474-7.
- [63] <http://www.bbraun.com>. Date of access 21/12/2014.
- [64] Sohail N Shaikh and Christopher C Thompson. Natural orifice transluminal surgery: Flexible platform review. *World J Gastrointest Surg*. 2010;27; 2(6): 210-6.
- [65] Swanström L, Swain P, Denk P. Development and validation of a new generation of flexible endoscope for NOTES. *Surg Innov*. 2009;(16):104-10.
- [66] Ji Hyeon Lee, Chan Jong Chung, Seung Cheo Lee, Ho Jin Shin. Anesthetic management of transoral natural orifice transluminal endoscopic surgery: two cases report. *Korean J Anesthesiol*. 2014;67(2):148-52.
- [67] Schaefer M. Natural orifice transluminal endoscopic surgery (NOTES): implications for anesthesia. *F1000 Med Rep*. 2009;1:80. doi: 10.3410/M1-80.



- [68] Phalanusitthepha C, Inoue H, Ikeda H, Sato H, Sato C, Hokierti C. Peroral endoscopic myotomy for esophageal achalasia. *Ann Transl Med.* 2014;2(3):31.
- [69] Grabowski JE, Talamini MA. Physiological effects of pneumoperitoneum. *J Gastrointest Surg.* 2009;13(5):1009-16.
- [70] Pucher P1, Sodergren MH, Alkhusheh M, Clark J, Jethwa P, Teare J, Yang GZ, Darzi A. The effects of natural orifice transluminal endoscopic surgery (NOTES) on cardiorespiratory physiology: a systematic review. *Surg Innov.* 2013;20(2):183-9.
- [71] Chang ET1, Ruhl DS, Kenny PR, Snizek JC. Endoscopic management of esophageal discontinuity. *Head Neck.* 2014;(1). doi: 10.1002/hed.23883 [Epub ahead of print].
- [72] Modayil R, Savides T, Scott DJ, Swanstrom LL, Vassiliou MC. Per-oral endoscopic myotomy white paper summary. NOSCART POEM White Paper Committee, Stavropoulos SN, Desilets DJ, Fuchs KH, Gostout CJ, Haber G, Inoue H, Kochman ML, *Gastrointest Endosc.* 2014;80(1):1-15.
- [73] Achem SR1, Gerson LB. Distal esophageal spasm: an update. *Curr Gastroenterol Rep.* 2013;15(9):325.
- [74] Smith SR1, Genden EM, Urken ML. Endoscopic stapling technique for the treatment of Zenker diverticulum vs standard open-neck technique: a direct comparison and charge analysis. *Arch Otolaryngol Head Neck Surg.* 2002;128(2):141-4.
- [75] Woodward TA, Jamil LH, Wallace MB. Natural orifice trans-luminal endoscopic surgery in the esophagus. *Gastrointestinal Endoscopy Clinics of North America.* 2010;20(1):123-138.
- [76] Magno p, Khashab MA, Mas M, Giday SA, Buscaglia JA, Shin EJ, Dray X, and Kalloo AN. Natural orifice transluminal endoscopic surgery for anterior spinal procedures. *Minim Invasive Surg.* 2012;2012: 365814. doi: 10.1155/2012/365814.
- [77] Wilhelm D1, Meining A, Schneider A, Von Delius S, Preissel A, Sager J, Fiolka A, Friess H, Feussner H. NOTES for the cardia: antireflux therapy via transluminal access. *Endoscopy.* 2010;42(12):1085-91.
- [78] Ishimaru T1, Iwanaka T, Hatanaka A, Kawashima H, Terawaki K. Transluminal esophageal anastomosis for natural orifice transluminal endoscopic surgery: an ex vivo feasibility study. *J Laparoendosc Adv Surg Tech A.* 2012;22(7):724-9.
- [79] Brian G Turner, Denise W Gee. Natural orifice transesophageal thoracoscopic surgery: A review of the current state. *World J Gastrointest Endosc.* 2010; 2(1):3-9.
- [80] Dostalík J1, Gunková P2, Gunka I3, Mazur M2, Mrazek T1. Laparoscopic gastric resection with natural orifice specimen extraction for postulcer pyloric stenosis. *Wideochir Inne Tech Malo Inwazyjne.* 2014;9(2):282-5.
- [81] Yi SW1, Chung MJ, Jo JH, Lee KJ, Park JY, Bang S, Park SW, Song SY. Gastrojejunostomy by pure natural orifice transluminal endoscopic surgery using a newly de-

- signed anastomosing metal stent in a porcine model. *Surg Endosc.* 2014;28(5):1439-46.
- [82] Elazary R1, Schlager A2, Khalaileh A2, Mintz Y2. Laparoscopic sleeve gastrectomy with transgastric visualization: another step toward totally NOTES procedures. *Surg Innov.* 2014;21(5):464-8.
- [83] Nakajima K1, Takahashi T1, Yamasaki M1, Kurokawa Y1, Miyazaki Y1, Miyata H1, Takiguchi S1, Mori M1, Doki Y1. [Transvaginal natural orifice transluminal endoscopic surgery partial gastrectomy: initial clinical experience] *Nihon Geka Gakkai Zasshi.* 2013;114(6):303-7.
- [84] Heo J1, Jeon SW. Hybrid natural orifice transluminal endoscopic surgery in gastric subepithelial tumors. *World J Gastrointest Endosc.* 2013;16;5(9):428-32.
- [85] Lee SH1, Kim SJ, Lee TH, Chung IK, Park SH, Kim EO, Lee HJ, Cho HD. Human applications of submucosal endoscopy under conscious sedation for pure natural orifice transluminal endoscopic surgery. *Surg Endosc.* 2013;27(8):3016-20.
- [86] Dotai T1, Coker AM, Antozzi L, Acosta G, Michelotti M, Bildzukewicz N, Sandler BJ, Jacobsen GR, Talamini MA, Horgan S. Transgastric large-organ extraction: the initial human experience. *Surg Endosc.* 2013;27(2):394-9.
- [87] Buesing M1, Utech M, Halter J, Riege R, Saada G, Knapp A. [Sleeve gastrectomy in the treatment of morbid obesity. Study results and first experiences with the transvaginal hybrid NOTES technique] *Chirurg.* 2011;82(8):675-83.
- [88] Ishimaru T1, Iwanaka T, Kawashima H, Terawaki K, Kodaka T, Suzuki K, Takahashi M. A pilot study of laparoscopic gastric pull-up by using the natural orifice transluminal endoscopic surgery technique: a novel procedure for treating long-gap esophageal atresia (type a). *J Laparoendosc Adv Surg Tech A.* 2011;21(9):851-7.
- [89] Moran EA1, Gostout CJ, McConico AL, Michalek J, Huebner M, Bingener J. Assessing the invasiveness of NOTES perforated viscus repair: a comparative study of NOTES and laparoscopy. *Surg Endosc.* 2012;26(1):103-9.
- [90] Mori H1, Kobara H, Kobayashi M, Muramatsu A, Nomura T, Hagiike M, Izuishi K, Suzuki Y, Masaki T. Establishment of pure NOTES procedure using a conventional flexible endoscope: review of six cases of gastric gastrointestinal stromal tumors. *Endoscopy.* 2011;43(7):631-4.
- [91] Alford C, Hanson R. Evaluation of a transvaginal laparoscopic natural orifice transluminal endoscopic surgery approach to the abdomen of mares. *Vet Surg.* 2010;39(7):873-8.
- [92] Hyder Q1, Zahid MA, Ahmad W, Rashid R, Hadi SF, Qazi S, Haider HK. Diagnostic transgastric flexible peritoneoscopy: is pure natural orifice transluminal endoscopic surgery a fantasy? *Singapore Med J.* 2008;49(12):e375-81.

- [93] Potter K1, Swanstrom L. Natural orifice surgery (NOTES) and biliary disease, is there a role? *J Hepatobiliary Pancreat Surg.* 2009;16(3): 261-5.
- [94] Fyock CJ, Kirtane TS, Forsmark CE, Wagh MS. Intraoperative NOTES endosonography and identification of mock hepatic lesions. *Surg Laparosc Endosc Percutan Tech.* 2012;22(1):e1-4.
- [95] Tagaya N1, Kubota K. NOTES: approach to the liver and spleen. *J Hepatobiliary Pancreat Surg.* 2009;16(3):283-7.
- [96] Shi H1, Jiang SJ, Li B, Fu DK, Xin P, Wang YG. Natural orifice transluminal endoscopic wedge hepatic resection with a water-jet hybrid knife in a non-survival porcine model. *World J Gastroenterol.* 2011;17(7):926-31.
- [97] Ohdaira T1, Endo K, Abe N, Yasuda Y. Transintestinal hepatectomy performed by hybrid NOTES using a customized X-TRACT Tissue Morcellator with an electrifiable round cutter. *J Hepatobiliary Pancreat Surg.* 2009;16(3):274-82.
- [98] Phee SJ1, Ho KY, Lomanto D, Low SC, Huynh VA, Kencana AP, Yang K, Sun ZL, Chung SC. Natural orifice transgastric endoscopic wedge hepatic resection in an experimental model using an intuitively controlled master and slave transluminal endoscopic robot (MASTER). *Surg Endosc.* 2010;24(9):2293-8.
- [99] Truong T1, Arnaoutakis D, Awad ZT. Laparoscopic hybrid NOTES liver resection for metastatic colorectal cancer. *Surg Laparosc Endosc Percutan Tech.* 2012;22(1):e5-7.
- [100] Saftoiu A1, Bhutani MS, Vilmann P, Surlin V, Uthamanthil RK, Lee JH, Bektas M, Singh H, Ionut D, Gheonea, Pactrascu S, Gupta V, Katz MH, Fleming JB. Feasibility study of EUS-NOTES as a novel approach for pancreatic cancer staging and therapy: an international collaborative study. *Hepatogastroenterology.* 2013;60(121):180-6.
- [101] Wang XW, Fan CQ, Wang L, Guo H, Xie X, Zhao GC, Zhao XY. Transoralgastric gastroscopic debridement for peripancreatic abscess: a special case report. *Hepatogastroenterology.* 2011;58(110-111):1801-4.
- [102] Endoscopic transgastric vs surgical necrosectomy for infected necrotizing pancreatitis: a randomized trial. Bakker OJ, Van Santvoort HC, Van Brunschot S, Geskus RB, Besselink MG, Bollen TL, Van Eijck CH, Fockens P, Hazebroek EJ, Nijmeijer RM, Poley JW, Van Ramshorst B, Vleggaar FP, Boermeester MA, Gooszen HG, Weusten BL, Timmer R; Dutch Pancreatitis Study Group. *JAMA.* 2012;07(10):1053-61.
- [103] Pallapothu R1, Earle DB, Desilets DJ, Romanelli JR. NOTES(®) stapled cystgastrostomy: a novel approach for surgical management of pancreatic pseudocysts. *Surg Endosc.* 2011;25(3):883-9.
- [104] Thakkar S, Awad M, Gurram KC, Tully S, Wright C, Sanan S, Choset H. A novel, new robotic platform for natural orifice distal pancreatectomy. *Surg Innov.* 2014;(15). pii: 1553350614554232 [Epub ahead of print].

- [105] Tomikawa M<sup>1</sup>, Akahoshi T, Kinjo N, Uehara H, Hashimoto N, Nagao Y, Kamori M, Kumashiro R, Maehara Y, Hashizume M. Rigid and flexible endoscopic rendezvous in spatium peritonealis may be an effective tactic for laparoscopic megasplenectomy: significant implications for pure natural orifice transluminal endoscopic surgery. *Surg Endosc.* 2012; 26(12): 3573-9.
- [106] Tagaya N<sup>1</sup>, Kubota K. NOTES: approach to the liver and spleen. *J Hepatobiliary Pancreat Surg.* 2009;16(3):283-7.
- [107] Targarona EM, Gomez C, Rovira R, Pernas JC, Balague C, Guarner-Argente C, Sainz S, Trias M. NOTES-assisted transvaginal splenectomy: the next step in the minimally invasive approach to the spleen. *Surg Innov.* 2009;16(3):218-22.
- [108] Nemani A<sup>1</sup>, Sankaranarayanan G, Olasky JS, Adra S, Roberts KE, Panait L, Schwaitzberg SD, Jones DB, De S. A comparison of NOTES transvaginal and laparoscopic cholecystectomy procedures based upon task analysis. *Surg Endosc.* 2014;28(8): 2443-51.
- [109] Lehmann KS<sup>1</sup>, Zornig C, Arlt G, Butters M, Bulian DR, Manger R, Burghardt J, Runkel N, Pürschel A, Köninger J, Buhr HJ. [Natural orifice transluminal endoscopic surgery in Germany : Data from the German NOTES registry.] *Chirurg.* 2014; (5) [Epub ahead of print].
- [110] A Hussain. Upper GI natural orifice transluminal endoscopic surgery: what is new? *European Surgery.* 2014; 46(1): 3-11.
- [111] Sodergren MH<sup>1</sup>, Markar S, Pucher PH, Badran IA, Jiao LR, Darzi A. Safety of transvaginal hybrid NOTES cholecystectomy: a systematic review and meta-analysis. *Surg Endosc.* 2014;26 [Epub ahead of print].
- [112] Yasuda K<sup>1</sup>, Kitano S. Lymph node navigation for pancreatic and biliary malignancy by NOTES. *J Hepatobiliary Pancreat Sci.* 2010;17(5):617-21.
- [113] Chouillard EK<sup>1</sup>, Al Khoury M, Bader G, Heitz D, Elrassi Z, Fauconnier A. Intercontinental Society of Natural Orifice, Endoscopic, Laparoscopic Surgery (i-NOELS), Poissy, France. Combined vaginal and abdominal approach to sleeve gastrectomy for morbid obesity in women: a preliminary experience. *Surg Obes Relat Dis.* 2011;7(5): 581-6.
- [114] Elazary R, Schlager A, Khalaileh A, Mintz Y. Laparoscopic sleeve gastrectomy with transgastric visualization: another step toward totally NOTES procedures. *Surg Innov.* 2014;21(5):464-8.
- [115] Mintz Y, Horgan S, Savu MK, Cullen J, Chock A, Ramamoorthy S, Easter DW, Talamini MA. Hybrid natural orifice transluminal surgery (NOTES) sleeve gastrectomy: a feasibility study using an animal model. *Surg Endosc.* 2008;22(8):1798-802.

- [116] Fischer LJ, Jacobsen G, Wong B, Thompson K, Bosia J, Talamini M, Horgan S. NOTES laparoscopic-assisted transvaginal sleeve gastrectomy in humans--description of preliminary experience in the United States. *Surg Obes Relat Dis*. 2009;5(5):633-6.
- [117] Hagen ME1, Wagner OJ, Swain P, Pugin F, Buchs N, Cadeddu M, Jamidar P, Fasel J, Morel P. Hybrid natural orifice transluminal endoscopic surgery (NOTES) for Roux-en-Y gastric bypass: an experimental surgical study in human cadavers. *Endoscopy*. 2008;40(11):918-24.
- [118] Nau P, Anderson J, Yuh B, Muscarella P Jr, Christopher Ellison E, Happel L, Narula VK, Melvin WS, Hazey JW. Diagnostic transgastric endoscopic peritoneoscopy: extension of the initial human trial for staging of pancreatic head masses. *Surg Endosc*. 2010 ;24:1440-6.
- [119] Michalik M, Orlowski M, Bobowicz M, Frask A, Trybull A. The first report on hybrid NOTES adjustable gastric banding in human. *Obes Surg*. 2011;21:524-7.
- [120] Demura Y, Ishikawa N, Hirano Y, Inaki N, Matsunoki A, Watanabe G. Transrectal robotic natural orifice transluminal endoscopic surgery (NOTES) applied to intestinal anastomosis in a porcine intestine model. *Surg Endosc*. 2013; 27(12): 4693-701.
- [121] Barthet M, Binmoeller KF, Vanbiervliet G, Gonzalez JM, Baron TH, Berdah S. Natural orifice transluminal endoscopic surgery gastroenterostomy with a biflanged lumen-apposing stent: first clinical experience (with videos). *Gastrointest Endosc*. 2015 ; 81(1):215-8.
- [122] Tian Y, Wu SD, Chen YH, Wang DB. Transvaginal laparoscopic appendectomy simultaneously with vaginal hysterectomy: initial experience of 10 cases. *Med Sci Monit*. 2014;10(20):1897-901.
- [123] Lehmann KS1, Zornig C, Arlt G, Butters M, Bulian DR, Manger R, Burghardt J, Runkel N, Pürschel A, Königer J, Buhr HJ. [Natural orifice transluminal endoscopic surgery in Germany: Data from the German NOTES registry.] *Chirurg*. 2014 Jul 5 [Epub ahead of print].
- [124] Yagci MA1, Kayaalp C1, Ates M1. Transvaginal appendectomy in morbidly obese patient. *Case Rep Surg*. 2014;2014:368640. doi: 10.1155/2014/368640.
- [125] Knuth J, Heiss MM, Bulian DR. Transvaginal hybrid-NOTES appendectomy in routine clinical use: prospective analysis of 13 cases and description of the procedure. *Surg Endosc*. 2014;28(9):2661-5.
- [126] Bernhardt J, Köhler P, Rieber F, Diederich M, Schneider-Koriath S, Steffen H, Ludwig K, Lamadé W. Pure NOTES sigmoid resection in an animal survival model. *Endoscopy*. 2012;44(3):265-9.
- [127] Emhoff IA1, Lee GC, Sylla P. Transanal colorectal resection using natural orifice transluminal endoscopic surgery (NOTES). *Dig Endosc*. 2014 Jan;26(1):29-42.



- [128] Chouillard E, Chahine E, Khoury G, Vinson-Bonnet B, Gumbs A, Azoulay D, Abdalla E. Notes total mesorectal excision (TME) for patients with rectal neoplasia: a preliminary experience. *Surg Endosc* 2014;28; (11):3150-7.
- [129] Park SJ, Lee KY, Choi SI, Kang BM, Huh C, Choi DH, Lee CK. Pure NOTES rectosigmoid resection: transgastric endoscopic IMA dissection and transanal rectal mobilization in animal models. *J Laparoendosc Adv Surg Tech A*. 2013;23(7):592-5.
- [130] Telem DA, Han KS, Kim MC, Ajari I, Sohn DK, Woods K, Kapur V, Sbeih MA, Perretta S, Rattner DW, Sylla P. Transanal rectosigmoid resection via natural orifice transluminal endoscopic surgery (NOTES) with total mesorectal excision in a large human cadaver series. *Surg Endosc*. 2013;27(1):74-80.
- [131] Rieder E1, Spaun GO, Khajanchee YS, Martinec DV, Arnold BN, Smith Sehdev AE, Swanstrom LL, Whiteford MH. A natural orifice transrectal approach for oncologic resection of the rectosigmoid: an experimental study and comparison with conventional laparoscopy. *Surg Endosc*. 2011;25(10):3357-63.
- [132] Lacy AM, Saavedra-Perez D, Bravo R, Adelsdorfer C, Aceituno M, Balust J. Minilaparoscopy-assisted natural orifice total colectomy: technical report of a minilaparoscopy-assisted transrectal resection. *Surg Endosc*. 2012;26(7):2080-5.
- [133] Alba Mesa F, Amaya Cortijo A, Romero Fernandez JM, Komorowski AL, Sanchez Hurtado MA, Sanchez Margallo FM. Totally transvaginal resection of the descending colon in an experimental model. *Surg Endosc*. 2012;26(3):877-81.
- [134] Li N, Zhang W, Yu D, Sun X, Wei M, Weng Y, Feng J. NOTES for surgical treatment of long-segment hirschsprung's disease: report of three cases. *J Laparoendosc Adv Surg Tech A*. 2013;23(12):1020-3.
- [135] Spaun GO, Dunst CM, Arnold BN, Martinec DV, Cassera MA, Swanström LL. Transcervical heller myotomy using flexible endoscopy. *J Gastrointest Surg*. 2010;14:1902-9.
- [136] Swanstrom LL, Dunst CM, Spaun GO. Future applications of flexible endoscopy in esophageal surgery. *Gastrointest Surg*. 2010;14 Supple 1:S127-32.
- [137] Swanstorm LL, Rieder E, Duns CM. A stepwise approach and early clinical experience in peroral endoscopic myotomy for the treatment of achalasia and esophageal motility disorders. *J Am Coll Surg*. 2011;213:751-6.
- [138] Rieder E, Martine DV, Duns CM, Sandstorm LL. Flexible endoscopic Zenkers diverticulotomy with a novel bipolar forceps: a pilot study and comparison with needle-knife dissection. *Surg Endosc*. 2011;25:3273-8.
- [139] Ishimaru T, Iwanaka T, Kawashima H, Terawaki K, Kodaka T, Suzuki K, Takahashi M. A pilot study of laparoscopic gastric pull-up by using the natural orifice transluminal endoscopic surgery technique: a novel procedure for treating long-gap esophageal atresia (type a). *J Laparoendosc Adv Surg Tech A*. 2011;21:851-7.

- [140] Turner BG, Kim MC, Gee DW, Dursun A, Mino-Kenudson M, Huang ES, Sylla P, Rattner DW, Brugge WR. A prospective, randomized trial of esophageal submucosal tunnel closure with a stent versus no closure to secure a transesophageal natural orifice transluminal endoscopic surgery access site. *Gastrointest Endosc.* 2011;73:785-90.
- [141] Turner BG, Cosigner S, Kim MC, Mino-Kenudson M, Ducharme RW, Surti VC. Stent placement provides safe esophageal closure in thoracic NOTES (TM) procedures. *Surg Endosc.* 2011; 25:913-8.
- [142] Rolanda C, Silva D, Bronco C, Madeira I, Macedo G, Correia-Pinto J. Peroral esophageal segmentectomy and anastomosis with single transthoracic trocar: a step forward in thoracic NOTES. *Endoscopy.* 2011;43:14-20.
- [143] Cho WY, Kim YJ, Cho JY, Bok GH, Jin SY, Lee TH, Kim HG, Kim JO, Lee JS. Hybrid natural orifice transluminal endoscopic surgery: endoscopic full-thickness resection of early gastric cancer and laparoscopic regional lymph node dissection - 14 human cases. *Endoscopy.* 2011;43:134-9.
- [144] Abe N, Takeuchi H, Yanagida O, Masaki T, Mori T, Sugiyama M, Atomi Y. Endoscopic full-thickness resection with laparoscopic assistance as hybrid NOTES for gastric submucosal tumor. *Surg Endosc.* 2009;23:1908-13.
- [145] Chiu PW, Wai Ng EK, Teoh AY, Lam CC, Lau JY, Sung JJ. Transgastric endoluminal gastrojejunostomy: technical development from bench to animal study (with video). *Gastrointest Endosc.* 2010;71:390-3.
- [146] Campos JM, Evangelista LF, Neto MP, Pagnossin G, Fernandes A, Ferraz AA, Ferraz EM. Transluminal endoscopic drainage of abdominal abscess due to early migration of adjustable gastric band. *Obes Surg.* 2010;20:247-50.
- [147] Cahill RA, Asakuma M, Perretta S, Dallemagne B, Marescaux J. Gastric lymphatic mapping for sentinel node biopsy by natural orifice transluminal endoscopic surgery (NOTES). *Surg Endosc.* 2009;23 :1110-6.
- [148] Luo H, Pan Y, Min L, Zhao L, Li J, Leung J, Xue L, Yin Z, Liu X, Liu Z, Sun A, Li C, Wu K, Guo X, Fan D. Transgastric endoscopic gastroenterostomy using a partially covered occluder: a canine feasibility study. *Endoscopy.* 2012;44:493-8.
- [149] Ikeda K, Sumiyama K, Tajiri H, Yasuda K, Kitano S. Evaluation of a new multitasking platform for endoscopic full-thickness resection. *Gastrointest Endosc.* 2011;73:117-22.
- [150] Lacy AM, Delgado S, Rojas OA, Ibarzabal A, Fernandez-Esparrach G, Taura P. Hybrid vaginal MA-NOS sleeve gastrectomy: technical note on the procedure in a patient. *Surg Endosc.* 2009;23:1130-7.
- [151] Branco F, Pini G, Osório L, Cavadas V, Versos R, Gomes M, Authoring R, Correia-Pinto J, Lima E. Transvesical peritoneoscopy with rigid scope: feasibility study in human male cadaver. *Surg Endosc.* 2011;25:2015-9.

- [152] Truong T, Arnaoutakis D, Awad ZT. Laparoscopic hybrid NOTES liver resection for metastatic colorectal cancer. *Surg Laparosc Endosc Percutan Tech.* 2012;22:e5-7.
- [153] Shi H, Jiang SJ, Li B, Fu DK, Xin P, Wang YG. Natural orifice transluminal endoscopic wedge hepatic resection with a water-jet hybrid knife in a non-survival porcine model. *World J Gastroenterol.* 2011;17:926-31.

IntechOpen

IntechOpen