

# We are IntechOpen, the world's leading publisher of Open Access books Built by scientists, for scientists

6,900

Open access books available

186,000

International authors and editors

200M

Downloads

Our authors are among the

154

Countries delivered to

TOP 1%

most cited scientists

12.2%

Contributors from top 500 universities



WEB OF SCIENCE™

Selection of our books indexed in the Book Citation Index  
in Web of Science™ Core Collection (BKCI)

Interested in publishing with us?  
Contact [book.department@intechopen.com](mailto:book.department@intechopen.com)

Numbers displayed above are based on latest data collected.  
For more information visit [www.intechopen.com](http://www.intechopen.com)



---

# **Evidence-Based Treatment of Chronic Subdural Hematoma**

---

Jehuda Soleman, Philipp Taussky,  
Javier Fandino and Carl Muroi

Additional information is available at the end of the chapter

<http://dx.doi.org/10.5772/57336>

---

## **1. Introduction**

Chronic subdural hematoma (cSDH) is one of the most frequent neurosurgical entities caused by head trauma. Since cSDH affects mainly elderly patients and the population continues to age, it has become a common neurosurgical disease seen by both general and specialized health-care practitioners. Despite the increasing prevalence of cSDH, class I studies, and evidence regarding the management of this disease is lacking. We provide an overview of the epidemiology, pathophysiology and etiology of cSDH and discuss several controversial aspects of its management; including indication and timing of surgery, steroid treatment, the effectiveness of anti-epileptic prophylaxis, comparative effectiveness of various techniques for surgical evacuation, the timing of postoperative resumption of anticoagulant medication, and protocols for mobilization following evacuation of cSDH. Complications of surgical evacuation such as recurrent hematoma, postoperative epilepsy, brain injury and/or iatrogenic intracerebral bleeding due to hematoma evacuation, drainage insertion or irrigation, and ways to avoid them are also discussed. As the incidence of cSDH is expected to increase and most treatment aspects lack clear consensus, further large prospective studies are needed. For this reason, a randomized, prospective study evaluating one aspect of the management of cSDH is currently in progress at our institution.

## **2. Definition**

A chronic subdural hematoma (cSDH) is defined as chronic ( $\geq 3$  weeks) intracranial bleeding between the dura mater (which adheres to the skull), and the arachnoid mater (which envelops

the brain). The underlying cause of cSDH is usually traumatic tearing of the bridging veins which connect the brain surface with the dura mater.[1].

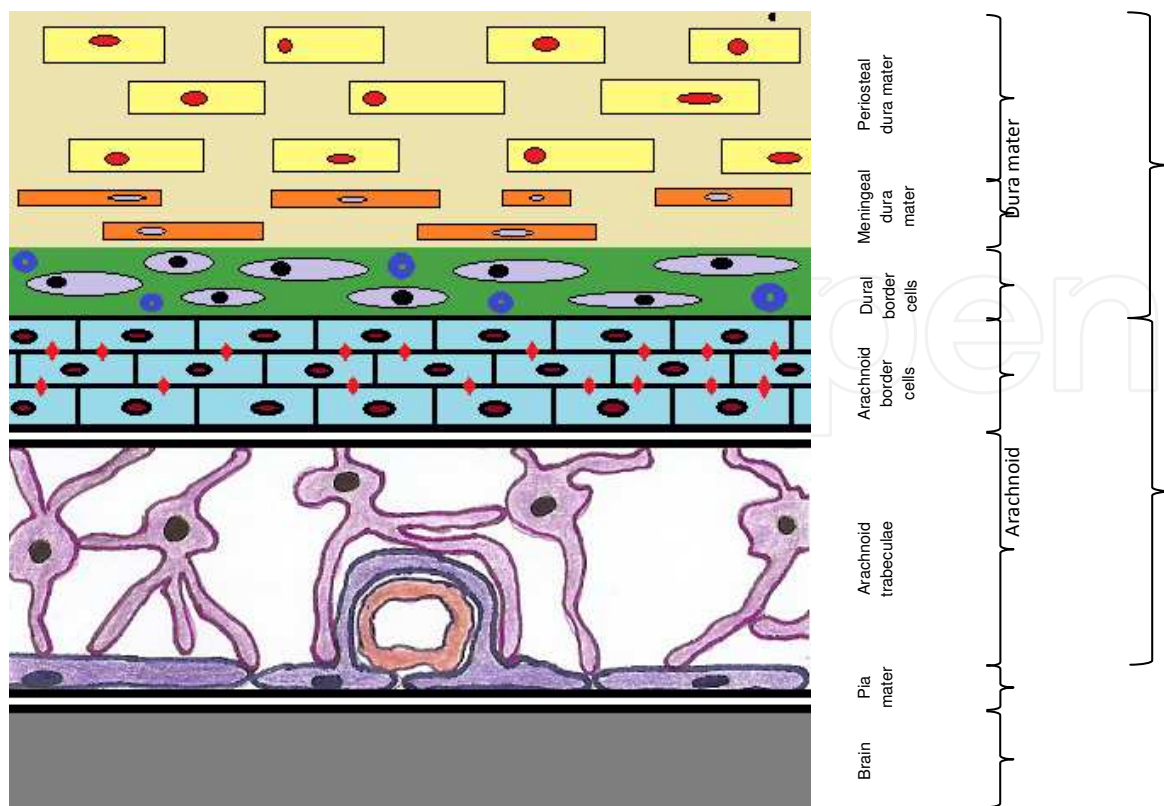
### 3. Epidemiology

The incidence of cSDH is estimated at 1.7-18 per 100'000 people, rising up to 58 per 100'000 people in patients above the age of 65 [1-4]. The average age of patients with cSDH is approximately 63 years old [5]. As the population continues to mature, incidence is expected to double by the year 2030 [6, 7]. A large demographic study found the prevalence of cSDH in patients older than 65 to be significantly higher (69% vs. 31%) [8]. In addition, men are more frequently affected than women (64% vs. 33%). In 77% of the cases, the patient has suffered a fall in the past and 41% of the patients were either treated with oral anticoagulants or platelet aggregation inhibitors. The reported recurrence rates range from 2.3% to 33% [8-11]. The most common risk factors are: advanced age, alcohol abuse, seizures, cerebrospinal fluid (CSF) shunts, coagulopathies, blood thinners, and patients at risk for falling (e.g. hemiplegia). In 20-25% of the cases, cSDHs are bilateral [5]. cSDH remains one the most frequent diagnoses in neurosurgical practice.

### 4. Pathophysiology

The entity of cSDH was first described by Virchow in 1857 [12]. He named it “pachymeningitis haemorrhagica interna”, recognizing its inflammatory and hemorrhagic elements [12]. Interestingly, the subdural space is a virtual space which does not exist in healthy individuals, as the dura and arachnoid are tethered by a layer of dural border cells (DBC)[1, 7, 13, 14]. The DBC is characterized by a paucity of tight junctions and an enlarged extracellular space containing amorphous material [7, 14] (Figure 1).

With increasing brain atrophy, the arachnoid is pulled away from the dural layer, which remains attached to the skull. The resultant force stretches the DBC layer and the veins traversing it (bridging veins). Any minor additional force can cause these veins to tear, causing a leakage of blood into the DBC and creating an acute SDH. Therefore, the majority of cSDHs are caused by an undiagnosed trivial head injury, primarily in patients with brain atrophy. This trauma leads to a minor acute SDH. Today, it is widely accepted that cSDHs are a result of the failure of small acute SDH to heal. Following the initial trauma and development of a cSDH, fibrin deposition occurs, followed by organization, enzymatic fibrinolysis and liquefaction of the hematoma. The blood in the subdural space triggers an inflammatory response. After approximately two weeks, an inner (cortical) and outer (dural) neomembrane is formed inside the DBC layer through dural collagen synthesis and fibroblast spread [1, 15, 16]. Ingrowth of fragile neocapillaries into the neomembranes of the hematoma can lead to further microbleeds within the subdural space [1]. Less commonly, the SDH may result from arterial ruptures (20-30%), hemorrhage into an existing subdural hygroma or spontaneously, mostly influenced by anticoagulants or antiplatelet therapy [1, 17, 18].



**Figure 1.** Schematic representation of the ultrastructure of the meninges (adapted from Haines and Santarius et al [7, 14]. The dura mater is composed of fibroblasts and large amounts of collagen. The arachnoid barrier cells are supported by a basement membrane and bound together by numerous tight junctions (red diamonds). The dural border cell layer (green) is formed by flattened fibroblasts with no tight junctions and no intercellular collagen. It is therefore a relatively loose layer positioned between the firm dura matter and arachnoid. The subdural space is a potential space that can form within the dural border cell layer. The bridging veins passing through the dural border cell layer are a potential source of bleeding.

The factors responsible for the maintenance or enlargement of cSDH over time are still ambiguous. It is most likely influenced by multiple factors, which vary from case to case. Over the years, several theories have been debated:

- a. “Osmotic theory”: The initial acute hematoma resorbs through fibrinolysis and the remaining resorption products within the subdural space lead to an elevated osmotic gradient. Due to the osmotic pressure, CSF follows the osmotic gradient and drifts into the subdural space, leading to an expansion of the hematoma [19, 20].
- b. “Oncotic theory”: Due to the low oncotic pressure inside the hematoma capsule, blood permeates from the dural vessels into the subdural space, leading to an expansion of the hematoma [16].
- c. “Microbleeds theory”: As they lack a muscle layer and pericytes, the neocapillaries forming inside the neomembrane are fragile. This leads to repeated microhemorrhaging into the subdural space and expansion of the hematoma [1, 7, 21].

- d. “Anticoagulant and profibrinolytic theory”: Under normal circumstances capillary leaks are stopped by blood clots. However, the neomembrane surrounding the SDH is saturated with profibrinolytic and anticoagulation factors. Different studies have shown acceleration of fibrinolysis [22], high levels of tissue plasminogen activator [23, 24], and high concentration of fibrin degradation products within the subdural fluid. All these factors obviate hemostasis within the subdural hematoma.
- e. “Inflammatory and growth factors theory”: Inflammation leads to high concentrations of vascular endothelial growth factor (VEGF) within the subdural fluid. VEGF receptor subtype I was seen in the cells of the neomembrane. These factors within the hematoma lead to an increased promotion of the ongoing angiogenesis and hyperpermeability in cSDHs. Since VEGF increases the permeability of capillaries, it contributes directly to the expansion of the hematoma [25-27].

As stated above, current evidence suggests that the maintenance or enlargement of cSDH is caused by multiple factors. The stimulus is probably a mixture of the “microbleed theory”, the “anticoagulant and profibrinolytic theory”, and the “inflammatory and growth factors theory”. These theories are currently accepted, while the “osmotic-” and “oncotic theory” has been largely abandoned [1, 7, 28, 29].

## 5. Etiology/risk factors

### *Trauma*

The most common cause of cSDH is a traumatic event, mostly a minor head trauma. In most large series, approximately two thirds of the patients have suffered one [2, 30]. Reports exist of cSDHs due to birth trauma in neonates [2, 31].

### *Advanced age*

The elderly are at risk, firstly due to brain atrophy, whereby the bridging veins are stretched and have become more fragile. Secondly, older people tend to fall more often and suffer minor head traumas. Lastly, with increasing age, the incidence of blood thinner administration rises leading to increased risk for hemorrhage.

### *Chronic Alcoholism*

Alcoholism is well known to be associated with cSDH. The reason for the greater propensity of patients with chronic alcohol addiction for hematoma formation is unknown. Yet, higher trauma rate, brain atrophy, and coagulopathy (secondary to liver malfunction), most definitely play a major role in cSDH development in these patients.

### *Gender*

Men, from all age groups, suffer disproportionally higher rates of cSDH than women [2, 7, 32]. The underlying reasons for this discrepancy are not known but may be because they are more likely to suffer trauma [2].

### *Coagulopathy*

Coagulopathies, including therapeutic anticoagulation and antiplatelet therapy, are known contributors to the pathogenesis of cSDH. Medical conditions include: sepsis, hepatic failure, all forms of hemophilia, disseminated intravascular coagulation, and renal dialysis [2, 5].

### *Intracranial hypotension*

Intracranial hypotension, as a result of overshunting after placement of a ventriculoperitoneal (VP) shunt, or CSF leak (iatrogenic or spontaneous) are less common causes of cSDH. Overshunting results in increased retraction of the bridging veins, leading to a higher likelihood of hematoma formation. Subdural hematomas may result in up to 8% of the patients shunted for normal-pressure hydrocephalus [33]. Since the introduction of adjustable-pressure valves, successful management of shunt-related cSDHs has been reported [34, 35]. Even with adjustable-pressure valves, intracranial hypotension resulting from overshunting is still a significant problem. The most common causes of a CSF leak leading to cSDH are traumatic or postoperative CSF fistulas, lumbar puncture or drainage, iatrogenic or disease-induced dehydration or spontaneous events [36]. Overall, it is a very rare condition.

### *Other causes*

Other rare causes of spontaneous subdural hematomas have been described: vascular malformation (e.g. cerebral aneurysms and arterial venous-malformation) [37, 38], benign (e.g. convexity meningiomas) and malignant tumors [39-41], carcinomatosis/sarcomatosis meningiosa, and infections (e.g. meningitis and tuberculosis) [5].

## **6. Classifications**

A *clinical* classification of cSDH was presented by Markwalder in 1981 [42]:

- grade 0: asymptomatic
- grade 1: alert, oriented, mild symptoms (e.g. headache)
- grade 2: drowsy or disoriented, variable neurological deficits (e.g. hemiparesis)
- grade 3: stupor but responds to stimuli, severe focal signs (e.g. hemiplegia)
- grade 4: coma, flexes/extends to pain

This grading system is used to pre- and postoperatively evaluate the clinical course of the patient.

Other scores frequently used for follow-up evaluation of cSDH patients include the Glasgow Coma Scale (GCS) [43], the Glasgow Outcome Score [44], and the modified Rankin scale (mRS) [45].



A *radiological* classification of the internal architecture of the hematoma, corresponding to possible stages in the natural history of cSDH, was suggested by Nakaguchi and colleagues in 2001 [9, 46]:

- Homogeneous type was defined as a hematoma exhibiting homogeneous high-density.
- Laminar type was defined as a subtype of the homogeneous type with a thin high-density layer along the inner membrane.
- Separated type was defined as a hematoma containing two components with different densities with a clear boundary between them; that is, a lower density component located above a higher density component.
- Trabecular type was defined as a hematoma with inhomogeneous contents and a high-density septum running between the inner and outer membrane on a low-density to isodense background

This scale can be helpful in predicting the recurrence rate based on the internal architecture of the hematoma as seen on computerized tomography. Recurrence rate was shown to be lower in the homogeneous and trabecular type [46].

## 7. Clinical presentation

Injuries associated with cSDHs tend to be minor, without any accompanying severe brain injury. The accumulation of blood within the subdural space occurs slowly, over an extended period (weeks-months), and under comparatively low pressure [7]. The coexistence of brain atrophy, in most cases, and the slow formation and expansion of the hematoma, allows the hematoma to reach a large size without triggering neurologic symptoms. Symptoms arise when the pressure caused by the hematoma leads to a compression of the cortex that cannot be tolerated or compensated anymore. In selected cases these symptoms manifest in a dramatic and acute fashion (e.g. coma) and might even lead to death. Acute deterioration can occur with small changes in hematoma volume when significant mass effect is already present. It is also not unusual for acute deterioration to occur secondary to acute bleeding within the subdural space, with a preexisting cSDH.

Therefore patients with cSDH can be asymptomatic, have very mild symptoms such as headache, nausea, vomiting, vertigo, fatigue, confusion, gait disturbance, mental deterioration, limb weakness, incontinence, or language difficulties (e.g. word-finding difficulties), or present with acute and grave symptoms such as hemiplegia, seizures, or coma (Table 1).

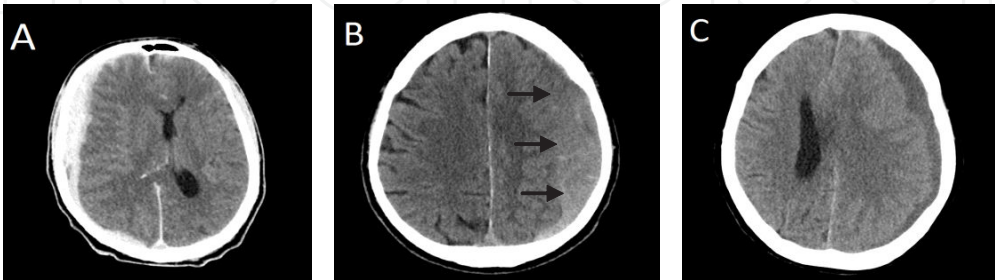## 8. Diagnostic work-up

After assessing the patient's history - including previous falls, minor head injuries, onset and course of clinical symptoms, cardiovascular disease, coagulopathies, medication, alcohol or

general symptoms (frequent)	mild symptoms (frequent)	severe/acute symptoms (rare)
headache	confusion	hemiplegia
fatigue	gait disturbance	aphasia
nausea/vomiting	mental deterioration	seizure
vertigo	language difficulties	coma
	limb weakness	
	incontinence	

**Table 1.** Clinical presentation of patients with cSDH

drug abuse - and completing the physical examination and blood work-up, brain imaging should be conducted to reach a diagnosis. Computed tomography (CT) is the most important imaging method in the initial evaluation of cSDHs [36, 47]. The best diagnostic signal is a crescent-shaped iso- to hypodens extra-axial collection on CT. Typically, the hematoma is spread over the whole effected hemisphere [48]. In addition to the enhancement of encapsulating membranes, those leading to septation within the collection may be seen [48]. The hematoma density varies depending on the stage of hematoma evolution. An acute SDH (<3 days old; hyperdens on native CT), progresses over  $\pm$ 3 weeks to a subacute SDH [3 days to 3 weeks old; isodens on native CT) and finally to a cSDH ( $\geq$ 3 weeks old, hypodens on native CT) (Figure 2) [48]. Mixed hematomas containing acute, subacute and chronic shares are often present. Special attention should be paid to isodens subacute SDH since it might be missed on the initial scan. Magnetic resonance imaging (MRI) is more accurate than CT; hematoma thickness can be measured reliably, as isodense and small cSDHs are easier to identify. In almost all cases, hematoma membranes are detected on an MRI, but only 27% are discovered on CT scans [47]. Nevertheless, CT is still preferred for the diagnosis of cSDH as it is cheaper, more accessible, and faster. MRI, when available, is useful in delineating the exact margins of the cSDH and determining the internal hematoma structures [47]. Table 2 summarizes CT and MRI findings in cSDH.



**Figure 2.** CT images with an acute SDH, <3 days old, hyperdens (A), subacute SDH, 3 days to 3 weeks old, isodens (B), and cSDH, >3 weeks old, hypodens (C)



CT	
Native CT	Iso - or hypodens
Contrast CT	Inward displacement of enhancing cortical vessels Enhancement of dura and membranes
MRI	
T1 WI	Isointense to CSF if chronic (no active/acute rebleeds) Hypointens with active/acute rebleeds or elevated proteins
Contrast T1 WI	Peripheral and/or dural enhancement Delayed scans show contrast diffusion into cSDH
T2 WI	Variable, depending on evolution stage Isointense to CSF if chronic (no active/acute rebleeds) Hypointens with active/acute rebleeds
FLAIR	Hyperintens to CSF Most sensitive sequence to detect cSDH
DWI	Variable signal

*T1 WI: T1 weighted imaging, T2 WI: T2 weighted imaging, FLAIR: FLAIR, DWI: diffusion weighted imaging*

**Table 2.** Characteristic findings of cSDH on CT and MRI, adapted from Osborn et al. [48]

9. Management

The decision to evacuate a cSDH is influenced by both the clinical presentation of the patient and the radiographic appearance of the lesion. An asymptomatic patient with a small cSDH is often best observed clinically and radiologically, in a carefully monitored setting. Although the size of a cSDH may play a role in the decision to perform surgery, absolute cutoffs sizes do not exist. Moreover, spontaneous resolution of cSDH with significant thickness has been reported - only in a small number of case series, in elderly patients (>70 years) with brain atrophy and without clinical or radiographic evidence of increased intracranial pressure [49, 50]. Other conservative treatments using ACE inhibitors or corticosteroids were reviewed, but justification for treatment using ACE inhibitors or steroids has largely been theoretical, and further research is clearly warranted. It is generally accepted that in the presence of neurologic symptoms and radiologic findings, patients should undergo surgical evacuation. The paucity of quality data from well-designed studies makes it difficult to identify the most effective surgical approach for cSDH. While surgical drainage is well-recognized as an effective treatment of cSDH [6, 7], multiple standard surgical techniques exist. These include burr hole craniostomy (BHC), twist drill craniostomy (TDC) and craniotomy. TDC produces a small opening of 10mm to the skull, while BHC enables a larger opening of 30mm [1]. During a craniotomy, a substantial piece of bone (>30mm) is removed and, following the hematoma evacuation, is replaced and fixed to the skull defect [1, 11].

## a. Surgical Management

### *Indication for surgery*

It is generally accepted that a patient presenting with neurologic symptoms and a radiologically proven cSDH, should undergo immediate surgical evacuation. Clearly, an asymptomatic patient showing no evidence of brain compression and/or midline shift on radiographic films is best managed conservatively and observed in a carefully monitored setting. A surgical approach is advised only if significant changes in neurologic status occur. Management of patients with cSDH leading to brain compression and/or midline shift, but lacking neurologic symptoms is very controversial. To our knowledge, no studies evaluating conservative vs. operative management in this group of patients exist. Widely used cutoffs for the indication of surgical evacuation (even in asymptomatic patients) are cSDH with maximum hematoma thickness exceeding that of the skull; or greater than 1cm [5]. An evidence-based hematoma cutoff size for the indication of operative treatment does not exist.

### *Craniotomy*

Craniotomy was the treatment of choice for cSDH until the mid-1960s. Craniotomy exposes the largest portion of the brain and thus provides the surgeon with the most expansive operative space. It is however the most invasive of the treatment options, with the longest operating time, the largest amount of blood loss and the most postoperative complications. In 1964, Svien and Gelety published a series comparing craniotomy and BHC for the treatment of cSDH [51]. Patients treated with BHC showed lower recurrence rates and better functional outcomes than those who underwent a craniotomy. Two meta-analyzes comparing BHC, TDC and craniotomy showed similar results [11, 52]. Even though class I studies comparing these three surgical methods do not exist, the primary treatment for cSDH remains BHC, while craniotomy is considered a second-tier remedy [1, 11, 53]. Most surgeons nowadays would agree that craniotomy should only be considered if subdural collection reaccumulates, solid or calcified hematoma occur, the brain fails to expand and obliterate the subdural space, or numerous thick membranes are present [1, 7, 11, 36].

### *Twist drill craniostomy*

TDC can be performed bedside under local anesthesia, making it an attractive treatment option, especially in polymorbid patients who are poor surgical candidates. A closed drainage system is placed at time of surgery to allow continuous drainage and promote postoperative brain expansion [1]. TDC is probably most effective in cases where the blood is almost completely liquefied and no membranes are present [1]. The morbidity and mortality of TDC seems to be similar or even superior to BHC [1, 11], however TDC is associated with significant higher recurrence rates than BHC [1, 7, 11]. In addition, there is a theoretical increased risk of contamination when performed at the bedside.

### *Burr hole Craniostomy*

BHC is probably the treatment most frequently implemented for cSDH [1, 7, 54, 55]. Based on reviews by Weigel et al. and Laga et al., BHC seems to be the most efficient method as

it balances a low recurrence rate against morbidity and mortality better than TDC and craniotomy [7, 11, 52].

Although BHC is the treatment of choice for cSDH in most neurosurgical departments and is performed frequently, many controversies and questions concerning the operational techniques and postoperative management still remain unanswered. In fact, it is quite astonishing that so few class I studies (Table 3) attempting to resolve these controversies and questions have been conducted over the past decades. The preferred operational technique (TDC, BHS vs. craniotomy), number of burr holes (one vs. two), role of intraoperative hematoma irrigation, localization of drainage (subdural vs. subperiosteal), and postoperative management have all been studied, yet studies with class I evidence are lacking, making evidence-based treatment and recommendations very difficult.

#### *Other surgical methods*

Various other surgical methods have been published, mostly within the limits of single retrospective studies or case reports. Among the methods described are: use of a tissue plasminogen activator in addition to TDC [56], minimally invasive hematoma evacuation using hollow screws [57], subduro-peritoneal shunt in infants [58], in older patients, and for recurrent cSDH [59], small craniotomy and endoscopic hematoma removal [60], replacement of the hematoma with oxygen via percutaneous subdural tapping [61], carbon dioxide insufflation in addition to BHC and closed-system drainage [62], embolization of middle meningeal artery in refractory cSDH [63-66], and implantation of an ommaya reservoir for repeated punctures and aspiration of subdural fluid [67, 68].

In order for these various techniques to be adopted as standard treatments for cSDH, further well-designed and comparative studies are necessary.

#### *Comparison of the various operational techniques*

The vast majority of studies comparing TDC, BHC and craniotomy have been small single-center retrospective studies (class II or III evidence) [1].

In their meta-analysis from 2003, Weigel et al. showed that TDC and BHC are safer and more efficient than craniotomy. Craniotomy and BHC have lower recurrence rates than TDC. They concluded that BHC has the best cure to complication ratio and is superior to TDC in the treatment of recurrences (type B recommendation) [11].

Ducruet et al. concluded in their meta-analysis from 2012, that TDC produces the best outcome and lowest complication rates as compared to BHC and craniotomy, while BHC results in lower mortality and recurrence rates than TDC or craniotomy (type C recommendation) [1]. Their recommendation is to observe small and asymptomatic cSDH, while large and symptomatic cSDH should be managed primarily with TCD or BHC. For high-risk surgical candidates with unseptated hematomas, the treatment of choice should be bedside TCD, while a craniotomy should be performed in cSDHs with significant membranes.

In conclusion, according to the current knowledge and based on the two stated meta-analyses, BHC results in the best cure to complication ratio in most patients. In high-risk surgical

patients, bedside TDC using local anesthesia might be the best treatment, while cSDH with significant membranes, acute shares, multiple recurrences, or calcification are best evacuated by craniotomy. As class I evidence-based studies and type A recommendations are lacking, further prospective randomized multi-center studies are needed.

Classes of Evidence	
Class I	Evidence provided by one or more well-designed randomized controlled clinical studies.
Class II	Evidence provided by one or more well-designed clinical studies such as prospective open, case–control studies, etc.
Class III	Evidence provided by expert opinion, non-randomized historical controls, or case reports of one or more patients.
Strength of recommendation	
Type A	Strong recommendation, based on class I evidence or overwhelming class II evidence when circumstances preclude randomized clinical trials.
Type B	Recommendation based on class II evidence.
Type C	Recommendation based on strong consensus of class III evidence.
(Classes of evidences and strength of recommendations adopted from the guidelines of the American Academy of Neurology and Weigel et al. 2012 [11, 69])	

**Table 3.** Overview of evidence-based criteria.

### *Number of burr holes*

While performing BHC, some surgeons prefer a single burr hole while others use two. There is no conclusive evidence to support either approach. Taussky et al. demonstrated that patients treated with a single burr hole have significantly higher recurrence rates, longer hospitaliza- tion, and more wound infections [10]. On the other hand, two different studies suggested no significant difference regarding recurrence, complications, mortality or outcome in patients treated with two burr holes as compared to one [70, 71]. A recent meta-analysis summarizing five retrospective cohort studies of 355 double BHC and 358 single BHC in 631 patients suggests that single BHC is as good as double BHC in evacuating chronic subdural hematoma and is not associated with a higher revision rate compared to double BHC (class III evidence) [72].

### *Irrigation*

The role of irrigation after concluding the burr holes is still unclear. Four class III and one class II evidence publications have evaluated the role of irrigation in BHC, while one class III evidence study investigated the effect in TDC. Three publications (class III evidence) compared BHC, with and without irrigation; all studies found no significant difference in recurrence rates [73-75]. Two studies report on the use of continuous inflow and outflow irrigation. Ram et al. reported fewer recurrences in the irrigation group, yet significance was not achieved, due to

low recurrence numbers [1/19 vs. 4/18] (class II evidence) [76]. In a retrospective study, Hennig et al. found significantly lower recurrence rates in patients treated with inflow outflow drainage compared to BHC with intraoperative irrigation and postoperative closed system drainage, BHC with intraoperative irrigation only, and craniotomy (class III evidence) [77]. In TDC, a significantly reduced rate was shown when using intraoperative irrigation (class III evidence) [78]. The use of irrigation had no impact on mortality or morbidity, both in BHC and TDC [77, 78].

#### *Use of closed-system drainage*

A survey conducted in 2008 in Great Britain showed that most surgeons did not insert closed-system drainage after operative treatment of chronic subdural hematoma [54]. However, a Canadian survey in 2005 showed that most surgeons in Canada utilize closed-system drainage [55]. Practices in many centers around the world changed after Santarius et al. published the results of their randomized controlled trial, which demonstrated a significant benefit in recurrence, mortality and discharge outcome for patients with subdural drain placement after BHC using two burr holes [6]. The placement of closed-system drainage is deemed to be standard in the operative treatment of cSDH with BHC and is considered a type A recommendation.

#### *Drainage localization*

Even though the insertion of a subdural drainage is considered safe, its proximity to the surface of the brain and the fact that it is inserted through a small burr hole make complications such as brain injury, intracranial bleeding, epilepsy, and subdural infection or empyema still possible. Consequently, a less invasive method - the insertion of a subperiosteal drainage - was proposed by some surgeons [3, 79-81]. Multiple studies have been published lately comparing the recurrence and complication rates of subperiosteal (or subgaleal) drainage with subdural drainage. Studies evaluating this novel method by Gazzeri et al. and Zumofen et al. showed similar recurrence and complication rates as with subdural drainage [3, 81]. Bellut et al. published results on the direct comparison of subdural and subperiosteal drainage. They found no statistical difference in recurrence or complication rates, although a tendency towards fewer complications in the subperiosteal group, and less recurrences in the subdural group was noted [79]. They recommend the usage of subperiosteal drainage in patients over 80 years of age or in those with predictable high risk for complications (type C recommendations) [79]. A recently published prospective randomized single-center study comparing BHC with subdural drainage and BHC with subgaleal drainage - 25 patients each - showed no recurrence at 6 months in either group, however, the overall outcome at 6 months was significantly better in the subperiosteal group (type B recommendation) [80]. Despite the prospective and randomized setting of this study, it was not sufficiently powered and the number of patients included was small (25 in each group). Definitive conclusions based on existing publications cannot be drawn and further large prospective studies are therefore warranted. In our institution, a prospective randomized trial has been initiated and this matter is presently being investigated. We aim to collect a sample size of 150 patients in each group (power of 80%) to demonstrate the difference in recurrence rates and overall outcome ( $\alpha < 0.05$ ), (www.clinicaltrials.gov, Identifier: NTC01869855).



### *Mobilization of patients following BHC*

Mobilization following surgical treatment of cSDH is an important aspect of postoperative care, especially since most patients are older and more susceptible to complications of immobility such as pneumonia, deep venous thrombosis and pulmonary embolism [1]. On the other hand, delayed mobilization might promote brain expansion and thus prevent recurrence of cSDH [82, 83]. Studies on this topic have reached mixed conclusions about the influence of patient mobilization on cSDH recurrence. Two prospective, randomized studies have concluded that recurrence rates after BHC are independent of patients' post-operative position (class I evidence) [84, 85]. In contrast, one prospective randomized study showed a statistically higher recurrence rate in patients mobilized immediately after surgery, although only one recurrence led to repeat surgery (class I evidence) [82]. In terms of complications due to postoperative immobilization, Kurabe et al. [84] showed significantly higher complication rates, while Abouzari et al. found no difference [82]. Due to the heterogeneity of these studies, making comparisons and conclusions are difficult. Even though Abouzari et al. [82] and Kurabe et al. [84] both employed similar surgical methods, the mean age of patients differed by approximately 20 years (77.3 years vs. 56.5 years), which may have influenced the differences in recurrence and medical complication rates observed.

### *Conclusion - surgical treatment of cSDH based on the available literature*

In summary, defining the optimal and best known evidence-based treatment of cSDH is quite difficult, since most studies provide class III evidence leading to type C recommendations. Based on current knowledge, the following recommendations can be made (Table 4):

1. The preferred surgical method seems to be BHC since it produces the best cure to complication ratio in most patients (type C recommendation).
2. In high-risk surgical patients, bedside TDC under local anesthesia might be the best treatment (type C recommendation).
3. cSDH with significant membranes, acute shares, multiple recurrences, or calcification are best evacuated by craniotomy (type C recommendation).
4. Single BHC is as good as double BHC and is not associated with a higher revision rate compared to double BHC (type C recommendation).
5. The use of irrigation has no impact on mortality or morbidity, its role in avoiding recurrence is unclear (type C recommendation).
6. The placement of closed-system drainage after BHC leads to significantly lower recurrence rates (type A recommendation).
7. Subperiosteal (subgaleal) drainage is as good as subgaleal drainage (type C recommendation).
8. Immediate postoperative mobilization might lead to higher recurrence rates but might also prevent medical complications caused by immobilization (type A recommendation exists for both early and late mobilization).



## **b. Conservative Management**

Although, surgical drainage is well recognized as an effective treatment of cSDH and is usually the treatment of choice, numerous reports have described spontaneous resorption of cSDH [7, 86]. In addition, therapy with corticosteroids and ACE-inhibitors was reviewed by different authors, showing good results [87-90]. Two surveys among neurosurgeons, one in Canada and one in the United Kingdom and the Republic of Ireland, found that conservative management is seldom practiced [54, 55], probably due to the poorer outcomes and prolonged hospital stay. Conservative management is reserved for asymptomatic cases, patients refusing surgical treatment or those with a high perceived operation risk [7, 91, 92]. Still, multi-centered prospective studies are needed to evaluate the efficacy of conservative treatment options in patients with cSDH.

### *Corticosteroids*

Tissue plasminogen activator activity, interleukin-6 and -8, and VEGF expression were shown to be inhibited by corticosteroids [7, 93-95]. Since these inflammation and angiogenesis factors play a role in the pathophysiology of cSDH, corticosteroids have been proposed as a therapy for cSDH [7, 23, 24, 96]. Few systematic studies evaluating the role of corticosteroids in the treatment of cSDH have been published. Glover et al. showed that corticosteroids inhibit the growth of neomembranes in cSDH [97]. In 1970, Benders work group retrospectively analyzed 100 patients treated for cSDH without surgery. They concluded that since the introduction of corticosteroids, the incidence of successful treatment by medical means is higher and patients show excellent recovery [87]. Decaux et al. reported two cases successfully treated with corticosteroids [88]. A retrospective study comparing conservative treatment with corticosteroids and surgical treatment using TDC and closed drainage system was conducted by Delgado-Lopez et al. [89]. Patients with a Markwalder score of 1 or 2 (n=101) were treated with corticosteroids (Dexamethasone® 4mg TID for 48 to 72 hours), while patients with a Markwalder score of 3-4 (n=19) were treated surgically. Of the patients treated with corticosteroids, surgery was avoided in 2/3 of the cases and 96% showed a favorable outcome, compared to 93% in the surgical group. Duration of hospitalization was shorter in the corticosteroids group (6 vs. 8 days). Medical complications, mainly mild hyperglycemic impairments caused by corticosteroids, occurred in 27.8%. The authors concluded that corticosteroids are a feasible and safe option in the management of cSDH, and were able to cure or improve the condition of two thirds of the patients. A recently published review of the literature showed that secondary intervention rate lies between 3 and 28%, lethality rate ranged from 0 to 13%, and good outcome was seen in 83-100%. Hyperglycemia occurred more often in patients treated with corticosteroids, while in two studies one case of gastrointestinal bleeding was observed. All five observational studies suggest that corticosteroids might be beneficial in treatment of cSDH [98].

However, well designed studies that support or refute the use of corticosteroids in cSDH are lacking. Although the few existing studies show promising results, the rationale for using corticosteroids is still based on theory, and more research into their treatment of cSDH is warranted [7, 89].

### *Angiotensin converting enzyme-inhibitors*

Hypothesizing that hyperangiogenesis plays a role in the pathogenesis of cSDH, Weigel et al. analyzed the recurrence rates of surgically treated cSDH, in patients with and without concurrent treatment of hypertension with angiotensin converting enzyme (ACE) inhibitors [90]. The recurrence rate between the two was significant: 5% in patients taking, and 18% in those not taking ACE-inhibitors. Moreover, VEGF levels were significantly lower in the hematomas of patients taking ACE inhibitors. The authors conclude that ACE-inhibitor treatment for hypertension might lower the risk of recurrence in patients undergoing surgery and possibly even lower the risk of development of cSDH, through their antiangiogenic mechanism. To the best of our knowledge, there are no further publications studying the role of ACE-inhibitors in the treatment of cSDH, or comparing them to surgical treatment. Therefore, the impact and potential of ACE-inhibitors in the treatment of cSDH remains to be determined.

### *Other conservative methods*

Several authors have described spontaneous resorption of cSDH, while conducting a “wait and watch” or “wait and scan” regime [49, 86]. One small study described successful treatment in 95% of cases using Mannitol 20%, leading to no sequelae, recurrence, or complications at follow-up [92]. A recent study by Kageyama et al. showed promising results using tranexamic acid - an antifibrinolytic drug - for conservative treatment of cSDH. Treated solely with tranexamic acid, all 18 patients in their cohort displayed hematoma resolution without progression or recurrence at follow-up [99]. Further investigation of the natural healing course of cSDH and various conservative treatment options is needed.

## **10. Anticoagulation therapy in patients with cSDH**

Neurosurgeons are faced increasingly with issues involving the treatment of anticoagulated patients [1, 100]. Especially in patients with cSDH - where up to 43% are anticoagulated and in whom anticoagulants were shown to increase the risk for development (up to 42.5 times) - the correct handling of anticoagulation therapy before, during and after surgery has become a major concern [8, 101].

### *Reversal of anticoagulation*

Although class I evidence comparing outcome of patients undergoing surgical evacuation of cSDH with and without reversal of anticoagulant medication are not available, there is a consensus that patients presenting with cSDH while on anticoagulation therapy require a rapid reversal [1, 102]. The risk of hematoma expansion or complications during potential neurosurgical interventions would otherwise be too high.

In cases where immediate reversal is not critical, vitamin K can be used for a more gradual change of international normalized ratio (INR) [102]. Urgent reversal of oral anticoagulation (e.g. warfarin) is usually accomplished using fresh frozen plasma (FFP) transfusion, pro-

thrombin complex concentrate (PCC) or recombinant Factor VIIa (rFVIIa) [103-106]. To avoid INR rebound, vitamin K should always be given adjuvant to FFP, PCC and rFVIIa [107]. In the case of reversal using FFP, the required volume can promote fluid overload in patients with cSDH, as these often present with cardiac or renal impairment [1, 103]. In addition, transfusion-related lung injury (TRALI) is an underestimated but feared complication caused by blood product transfusions such as FFP [108]. PCC exists as a 3-factor PCC (containing factor II, IX, and X, e.g. Uman Complex DI® and Profilnine SD®) or a 4-factor PCC (containing factor II, XII, IX, and X, e.g. Beriplex® and Kcentra®). While 4-factor PCC was shown to be effective in emergency reversal of oral anticoagulation irrespective of the starting INR, 3-factor PCC should be restricted to patients presenting with an INR < 4.0 (type C recommendation) [109]. The most feared complication of PCC is thrombosis and although it has been suggested that this risk might be less with the 3- than the 4-factor PCC, there is no study confirming this [109]. The role of rFVIIa remains unclear, due to the known and relative frequent side-effects, such as deep vein thrombosis and pulmonary embolism, and high costs of this new drug [104, 105, 110]. A comparison of FFP, rFVIIa and PCC treatment for intracranial hemorrhaging showed that rapid reversal of oral anticoagulants using rFVIIa and PCC is more effective than FFP. In addition, rFVIIa is considerably more expensive and might have greater risk of INR rebound than PCC [107].

We therefore recommend that patients presenting with cSDH while on anticoagulation should be rapidly reversed using PCC adjuvant to vitamin K (type C recommendation, class III evidence) (Table 4). Alternatively, in institutions where PCC is not available FFP should be applied.

#### *Timing of resumption of anticoagulant therapy*

The timing of resumption of anticoagulant therapy in patients treated surgically for cSDH must be chosen cautiously. The increased risk of thromboembolic complications due to prolonged discontinuation of anticoagulation must be balanced carefully against the increased risk of hemorrhage if oral anticoagulation is commenced soon after surgery. There is little empirical evidence to support a definitive decision on when to restart oral anticoagulation in these patients. Still, a few studies addressing this issue do exist [111-115]. Yeon et al. (in a prospective design) and Kawamata et al. (in a retrospective design), both showed that resumption of anticoagulation within 3 days is safe and does not lead to higher risk of recurrent cSDH or intracranial bleeding (type B recommendation) [113, 114]. On the other hand, Foster et al. showed in their retrospective series that early postoperative treatment with low-molecular-weight heparin or oral anticoagulation may affect reoperation rate and lead to a poorer outcome (type C recommendations) [112]. In 2013, Chari et al. conducted a meta-analysis; they reported a lower bleeding risk (11% vs. 22%) and paradoxically, a higher thromboembolism risk (2.2% vs. 0%) when anticoagulation was restarted, as opposed to a prolonged discontinuation [111]. They stated that no conclusions can be drawn from their data, due to the small cohort group (67 patients in 3 studies).

The indication for anticoagulation is an additional important factor when considering reinstating treatment. It is clear that patients with a mechanical heart valve require anticoagulation due to the high risk of thromboembolic complications. The decision is more complex

for atrial fibrillation, requiring a balance between the risk of recurrence and a thromboembolic event. Chari et al. recommend comparing two validated scores: the HAS-BLED (hypertension, abnormal renal/liver function, stroke, bleeding history or predisposition, labile INR, elderly, drugs/alcohol concomitantly) score - assessing bleeding risk under anticoagulation - and the CHA<sub>2</sub>DS<sub>2</sub>-VASc (congestive heart failure, hypertension, age  $\geq 75$  years (doubled), diabetes mellitus, stroke (doubled), vascular disease, age 65–74 years, sex) score - evaluating the thromboembolic risk without anticoagulation - to determine risk on a patient-by-patient basis [104, 111, 116, 117]. The two scores may correlate in terms of risk/year and consideration of which score is higher might help in the decision making.

A definitive recommendation on when to restart oral anticoagulation after surgical evacuation of cSDH cannot be made. Based on the literature available, oral anticoagulation can be reinstated 72 hours after surgery, particularly in patients with a high thromboembolic risk (type B recommendation, class II evidence). A comparison of the HAS-BLED score and the CHA<sub>2</sub>DS<sub>2</sub>-VASc score might be helpful when deciding whether to restart anticoagulation in patients with atrial fibrillation (type C recommendation, class III evidence) (Table 4).

## 11. Antiplatelet therapy in patients with cSDH

As with oral anticoagulation, antiplatelet therapy in patients with cSDH presents a significant neurosurgical challenge. Patients seem to be at greater risk for development of cSDH while on these medications [101, 118]. However, it remains unclear if the recurrence rate is affected by antiplatelet therapy [1, 101, 112, 118].

### *Reversal of antiplatelet therapy*

Even though there is no definitive evidence for the discontinuation of antiplatelet therapy prior to surgical evacuation of cSDH, most surgeons prefer to discontinue and convert antiplatelet therapy before surgery. The most effective way for reversing antiplatelet therapy is discontinuing the drug for 7 days. Aspirin inhibits the platelet enzyme cyclooxygenase irreversibly, meaning that as long as aspirin is administered, all thrombocytes in the blood system are non-functional and aggregation is inhibited for the entire platelet lifespan [119]. The period therefore required for total recovery of platelet function after the last administration of aspirin is their 7 day lifespan [119]. Platelet transfusion and desmopressin application have also been described as methods to reverse antiplatelet therapy, yet they are controversial and have not been analyzed rigorously with regards to cSDH [1, 119, 120].

Since evidence is still lacking, we recommend case-by-case management for patients on antiplatelet drugs presenting with cSDH. Generally, in patients with minor symptoms, antiplatelet therapy should be discontinued for 7 days, while meticulous clinical and radiologic follow-up is warranted. Platelets could be administered during surgery for patients undergoing emergency procedures (Table 4).

### *Timing of resumption of antiplatelet therapy*

Little evidence exists to determine the optimal timing of postoperative resumption of antiplatelet therapy in patients surgically treated for cSDH. Several studies have produced contro-



versial results on recurrence risk. Two studies showed no significant difference in recurrence of hematoma in patients who did or did not receive antiplatelet agents preoperatively [112, 121], while a further study found a significant difference in recurrence rate [101]. Therefore, evidence-based recommendations on when to reinstate antiplatelet agents cannot be made. Case-by-case management is advised until further prospective studies produce evidence-based recommendations (Table 4).

## 12. Anticonvulsant therapy in patients with cSDH

The efficacy and indication of antiepileptic drugs (AED) in patients presenting with symptomatic cSDH has been debated without reaching a consensus on its use [1, 122]. The reported seizure rate in patients treated surgically for cSDH varies from 2.3% to 17% [123, 124], and affects 1% to 23.4% of individuals postoperatively [123, 125]. Two studies showed no significant differences in seizure rate secondary to the prophylactic administration of AEDs [124, 126]. They concluded that AED morbidity outweighs the benefits except in patients at high risk for seizures, like alcoholics. Another study found a significant increase in morbidity and mortality in patients with cSDH and new-onset seizures. They therefore recommend the administration of AED for a period of six months following diagnosis of cSDH [127]. Grobelny et al. found that preoperative AED prophylaxis might reduce the incidence of postoperative seizures in patients treated with BHC [123]. Yet neither pre- or postoperative seizures, nor the decision to initiate AED prophylaxis had a significant effect on outcome [123]. Chen et al. reported a higher postoperative seizure rate in patients with mixed-density cSDH on preoperative CT, and in those with left unilateral cSDH. They therefore propose the use of prophylactic AED in these patients [128].

Further investigation of this topic is necessary prior to establishing definitive recommendations. The indication of AEDs in cSDH patients such as duration of AED therapy, adverse effects of administered AEDs, and efficacy of various AEDs should all be studied through prospective randomized studies.

Until more data is available, AED prophylaxis should be considered for patients with cSDH at high risk for seizures, such as those presenting with seizures, alcoholics and patients with significant underlying brain injury [1] (type C recommendation). In general, the surgeon must balance the potential benefit against possible secondary morbidity of AED administration (Table 4).

## 13. Postoperative complications, recurrence rates and outcome

### *Complications*

Complications after surgical treatment of cSDH include [5]:

Subject	Recommendation	Type	Studies
<b>Surgical method</b>	<ul style="list-style-type: none"> <li>• BHC – “first choice” in most patients</li> <li>• TDC – in surgical high-risk patients</li> <li>• Craniotomy – “last choice”, with acute shares, significant membranes, multiple recurrences, calcification</li> </ul>	B and C	Weigel et al. [11] Santarius et al. [7] Lega et al. [52] Ducruet et al. [1]
<b>Amount of burr holes</b>	One or two (both equivalent)	C	Taussky et al. [10] Han et al. [70] Kansal et al. [71] Belkhair et al. [72]
<b>Irrigation</b>	Safe Might lead to less recurrence especially in TDC	B and C	Ram et al. [76] Hennig et al. [77] Aoki et al. [78]
<b>Drainage insertion</b>	Yes	A	Santarius et al. [6]
<b>Drainage location</b>	Subperiosteal (recurrence rate same as subdural, fewer complications)	B	Kaliaperumal et al. [80] Bellut et al. [79] Zumofen et al. [81] Gazzeri et al. [3]
<b>Postoperative mobilization</b>	None Studies in favor of early and late mobilization	A	Abouzari et al. [82] Kurabe et al. [84]
<b>Reversal of anticoagulation</b>	Rapid reversal using PCC and Vitamin K	C	Woo et al. [107]
<b>Resumption of anticoagulation</b>	After 72 hours in high-risk patients In atrial fibrillation compare HAS-BLED score and CHA <sub>2</sub> DS <sub>2</sub> -VAsC score	B C	Kawamata et al. [113] Yeon et al. [114] Chari et al. [111]
<b>Reversal of antiplatelets</b>	Discontinuation 7 days prior to surgery In urgent cases platelet transfusion or desmopressin	C	Mascarenhas et al. [119] Ranucci et al. [120]
<b>Resumption of antiplatelets</b>	No recommendations; case-by-case management	C	Forster et al. [112] Rust et al. [101] Torihashi et al. [121]
<b>Antiepileptic drugs</b>	None, except in high-risk patients (e.g. alcoholics) or presenting with seizure	C	Ducruet et al. [1] Hirakawa et al. [125] Grobelny et al. [123]

**Table 4.** Summary of recommendations based on the available literature



- Failure of brain to re-expand and/or reaccumulation of blood in the subdural space (leading to recurrent cSDH) [0-30%) [129]
- Seizures (including status epilepticus) (1-23%) [123, 125]
- Intracerebral hemorrhage (0.7-5%, especially in patients over 75 years of age, in rapid decompression of hematoma; 1/3 of the patients die and 1/3 are severely disabled) [5, 129-131]
- Postoperative infections (e.g. wound infection, subdural empyema) (2%) [129]
- Tension pneumocephalus (0-10%) [129, 132, 133]

All complications are more common in elderly, polymorbid, and enervated patients [5]. However, a recent retrospective study evaluating the outcome in patients over 65 years of age who were treated surgically for cSDH, concluded that despite higher rates of anticoagulation and multimorbidity, surgical treatment in elderly patients is safe [134]. Patients above the age of 85 show lower recurrence rates, yet carry a greater risk for complications (e.g. acute SDH) and should be monitored meticulously [134].

Intraoperative imaging, such as intraoperative MRI or CT, might be a useful tool for early detection of surgical complications and drainage malposition and allows for their treatment within the same procedure.

#### *Recurrence rates*

Recurrence represents the most common complication following surgical treatment of cSDH, with a median incidence of 15% reported in the literature (range 0%-30%) [8, 129, 135, 136]. Recurrence ensues mainly in hematomas containing a solid or organized clot which cannot be sufficiently cleared by BHC or TDC; or due to the lack of brain expansion after removal of the hematoma resulting in a renewed hemorrhage [129]. Many risk factors for recurrence in surgically treated cSDH have been investigated over the last decades. Although results have been inconsistent, many factors including age, alcoholism, cerebral atrophy, anticoagulation or antiplatelet use, poor performance status on admission, poor GCS and GOS, bilateral cSDH, hematoma width, midline displacement postoperatively, air collection in hematoma cavity, septum formation or multiple membranes in the hematoma cavity, higher hematoma density on CT, hematoma with laminar and separated architecture, and conclusion of BHC or TDC without drainage placement are thought to be associated with higher recurrence rates [12, 46, 82, 121, 129, 135, 137, 138]. The only proven factor leading to lower recurrence rates is the intraoperative placement of a closed system drainage (class I evidence) [6].

#### *Outcome*

Morbidity and mortality rates in surgically treated patients with cSDH depends mostly on the surgical technique, the patients' age and co-morbidities [1, 6, 11, 129, 134]. The overall favorable outcome after surgical treatment of cSDH in the literature is reported to be 72-89%, with younger patients generally achieving better outcomes compared to older ones [6, 11, 129, 134, 139]. Worsening neurologic status following drainage of cSDH is estimated at 4% and overall mortality after surgical treatment of cSDH is 0-8% [5]. In their meta-analysis, Weigel et al

reported a morbidity of 3%, 3.8%, and 12.3% in patients treated with TDC, BHC and craniotomy respectively. In a further meta-analysis, Ducruet et al. identified morbidity rates of 2.5% in patients treated with TDC, 9.3% in patients treated with BHC and 3.9% in patients treated with craniotomy, while the mortality rates in patients treated with TDC, BHC, and craniotomy were 5.1%, 3.7% and 12.2% respectively. Ramachandran et al. reported a favorable outcome in 66% of patients >60 years vs. 79% in patients between the age of 40 and 60, and 74% in patients <40 years. Borger et al. compared the outcome of 322 surgically treated patients over the age of 65; an overall positive outcome based on Karnofsky performance status (KPS) was seen in 83% of the patients between the age of 65 and 74 years, in 68% of the patients between the age of 75 and 84 years, and in 55% of patients between the age of 85 and 94 years. In their study, mortality rates in patients between the age of 65 and 74 years, 75 and 84 years, and 85 and 94 years were 1.7%, 3.6%, and 3.8% respectively.

## 14. Conclusion

Chronic SDH represents one of the most frequent entities in neurosurgical patients and a common cause of traumatic brain injury. Since the population will continue to age over the next decades and cSDH primarily affects elderly patients, an increase in incidence rate is expected. cSDH is therefore one of the most significant neurosurgical issues confronting us today. While it is clear that cSDH is mainly caused by minor head trauma, the pathophysiological mechanisms of its maintenance and enlargement over time remain debatable. Neomembranes with fragile neocapillaries forming around the hematoma, inflammation leading to production of VEGF and profibrinolytic and anticoagulation factors produced within the hematoma fluid are elements hypothesized to promote re-bleeding and SDH growth. Clinical presentation varies from general and mild symptoms (e.g. headache, fatigue) to severe symptoms (e.g. hemiparesis, coma). Head CT plays a major role in the initial evaluation of cSDH, because it confirms the diagnosis accurately and hematoma age can be estimated.

The management of cSDH remains controversial. Amazingly, only a few studies with class I evidence evaluating management protocols and surgical techniques exist. Currently, there are several ongoing randomized controlled trials which might provide more clarity for the management and treatment of cSDH. These studies are summarized in Table 5. It is generally accepted that in the presence of neurologic symptoms and radiologic findings, patients should undergo surgical evacuation. Yet the role of conservative treatment (e.g. "wait and scan", corticosteroids, ACE-inhibitors) in asymptomatic patients or in patients presenting with mild symptoms remains unclear. The preferred surgical method seems to be BHC since it produces the best cure to complication ratio in most patients. Yet many questions such as the correct surgical method (BHC vs. TCD and craniotomy), the superiority of two burr holes over one, placement of subdural or subperiosteal drainage, the efficacy of hematoma irrigation, and timing of postoperative mobilization are still insufficiently clarified. The intraoperative placement of closed system drainage for the prevention of recurrence is the only evidence-based recommendation that can be made. Prospective multicenter studies providing type A recommendations for these questions are much needed.

Rationale	Study design	Status	Anticipated number of patients	ClinicalTrail.gov ID
Evaluation of the recurrence rate of cSDH after placing a subperiosteal drainage compared to a subdural drainage	PR	R	400	NCT01869855
Evaluation of the recurrence rate of cSDH after placing a subdural drainage compared to no drainage placement	PR	NYR	260	NCT01785797
Evaluation of the role of CT scanning in the postoperative follow-up after surgical treatment of cSDH	PR, SB	R	400	NCT01624545
To assess whether continued aspirin treatment increases the risk of cSDH in mild head trauma patients 50 years and older who present with negative head CT	PR, DB	NYR	100	NCT01470040
To assess whether treatment with an ACE-inhibitor for 3 months after surgical evacuation of cSDH will decrease the risk of recurrence compared to placebo	PR, DB, Placebo	R	120	NTC00915928
Evaluation of the recurrence rate of cSDH in patients treated postoperatively for 2 months orally with corticosteroids compared to placebo	PR, DB, Placebo	NYR	400	NCT01380028
Evaluation of the recurrence rate of cSDH after placing an active subperiosteal drainage compared to a passive subdural drainage and continuous irrigation	RNR	NYR	950	NCT01930617
PR: prospective randomized, RNR: retrospective non-randomized, SB: single blinded, DB: double blinded, R: recruiting, NYR: not yet recruiting				

**Table 5.** Summary of ongoing clinical trials evaluating management and treatment of cSDH

In patients with minor symptoms, antiplatelet therapy should be discontinued for 7 days, and anticoagulation converted solely with vitamin K, accompanied by meticulous clinical and radiologic follow-up. For those needing emergency surgery, antiplatelet therapy must be discontinued and platelets could be administered during the procedure. In patients receiving anticoagulants, rapid conversion should be carried out using PCC or FFP, adjuvant to vitamin K. Little evidence exists to determine the optimal timing of postoperative resumption of antiplatelet or anticoagulation therapy. Therefore, case-by-case decision making is necessary. In patients with atrial fibrillation, a comparison of the HAS-BLED score and the CHA<sub>2</sub>DS<sub>2</sub>-VASc score might be helpful when deciding whether to restart anticoagulation. AED prophyl-

laxis should be considered only in patients at high risk for seizures (e.g. patients presenting with seizure, alcoholics and patients with significant underlying brain injury).

Overall favorable outcome after surgical treatment is described at 72-89%. Mortality rate is estimated at 0-8%. The most frequent surgical complications are: recurrence (15%), seizure (11%), tension pneumocephalus (5%), intracerebral hematomas (2.5%), and infections (2%).

## Author details

Jehuda Soleman<sup>1</sup>, Philipp Taussky<sup>1,2</sup>, Javier Fandino<sup>1</sup> and Carl Muroi<sup>\*</sup>

\*Address all correspondence to: [carl.muroi@ksa.ch](mailto:carl.muroi@ksa.ch)

1 Department of Neurosurgery, Kantonsspital Aarau, Aarau, Switzerland

2 Department of Neurosurgery, University of Utah, Salt Lake City, Utah, USA

## References

- [1] Ducruet AF, Grobelny BT, Zacharia BE, Hickman ZL, DeRosa PL, Anderson K, et al. The surgical management of chronic subdural hematoma. *Neurosurg Rev.* 2012 Apr; 35(2):155-69; discussion 69.
- [2] Chen JC, Levy ML. Causes, epidemiology, and risk factors of chronic subdural hematoma. *Neurosurg Clin N Am.* 2000 Jul;11(3):399-406.
- [3] Gazzeri R, Galarza M, Neroni M, Canova A, Refice GM, Esposito S. Continuous subgaleal suction drainage for the treatment of chronic subdural haematoma. *Acta Neurochir (Wien).* 2007;149(5):487-93; discussion 93.
- [4] Kudo H, Kuwamura K, Izawa I, Sawa H, Tamaki N. Chronic subdural hematoma in elderly people: present status on Awaji Island and epidemiological prospect. *Neurol Med Chir (Tokyo).* 1992 Apr;32(4):207-9.
- [5] Greenberg MS. Chronic subdural hematoma. *Handbook of Neurosurgery.* 7th ed. New York, New York: Thieme; 2010. p. 899-902.
- [6] Santarius T, Kirkpatrick PJ, Ganesan D, Chia HL, Jalloh I, Smielewski P, et al. Use of drains versus no drains after burr-hole evacuation of chronic subdural haematoma: a randomised controlled trial. *Lancet.* 2009 Sep 26;374(9695):1067-73.
- [7] Santarius T, Kirkpatrick PJ, Kolias AG, Hutchinson PJ. Working toward rational and evidence-based treatment of chronic subdural hematoma. *Clin Neurosurg.* 2010;57:112-22.

- [8] Baechli H, Nordmann A, Bucher HC, Gratzl O. Demographics and prevalent risk factors of chronic subdural haematoma: results of a large single-center cohort study. *Neurosurg Rev.* 2004 Oct;27(4):263-6.
- [9] Nakaguchi H, Tanishima T, Yoshimasu N. Factors in the natural history of chronic subdural hematomas that influence their postoperative recurrence. *J Neurosurg.* 2001 Aug;95(2):256-62.
- [10] Taussky P, Fandino J, Landolt H. Number of burr holes as independent predictor of postoperative recurrence in chronic subdural haematoma. *Br J Neurosurg.* 2008 Apr; 22(2):279-82.
- [11] Weigel R, Schmiedek P, Krauss JK. Outcome of contemporary surgery for chronic subdural haematoma: evidence based review. *J Neurol Neurosurg Psychiatry.* 2003 Jul;74(7):937-43.
- [12] Virchow R. Das Hämatom der Dura Mater. *Verh Phys Med Ges Würzburg.* 1857(7): 134-42.
- [13] Frederickson RG. The subdural space interpreted as a cellular layer of meninges. *Anat Rec.* 1991 May;230(1):38-51.
- [14] Haines DE, Harkey HL, al-Mefty O. The "subdural" space: a new look at an outdated concept. *Neurosurgery.* 1993 Jan;32(1):111-20.
- [15] Drapkin AJ. Chronic subdural hematoma: pathophysiological basis for treatment. *Br J Neurosurg.* 1991;5(5):467-73.
- [16] Sajanti J, Majamaa K. High concentrations of procollagen propeptides in chronic subdural haematoma and effusion. *J Neurol Neurosurg Psychiatry.* 2003 Apr;74(4):522-4.
- [17] Gennarelli TA, Thibault LE. Biomechanics of acute subdural hematoma. *J Trauma.* 1982 Aug;22(8):680-6.
- [18] Maxeiner H, Wolff M. Pure subdural hematomas: a postmortem analysis of their form and bleeding points. *Neurosurgery.* 2002 Mar;50(3):503-8; discussion 8-9.
- [19] Gardner W. Traumatic subdural hematoma with particular reference to the latent interval. *Arch Neurol Psychiatr* 1932(27):847-58.
- [20] Zollinger R GR. Traumatic subdural hematoma, an explanation of the late onset of pressure symptoms. *JAMA.* 1934(103):245-9.
- [21] Yamashima T, Yamamoto S, Friede RL. The role of endothelial gap junctions in the enlargement of chronic subdural hematomas. *J Neurosurg.* 1983 Aug;59(2):298-303.
- [22] Labadie EL, Glover D. Local alterations of hemostatic-fibrinolytic mechanisms in re-forming subdural hematomas. *Neurology.* 1975 Jul;25(7):669-75.



- [23] Katano H, Kamiya K, Mase M, Tanikawa M, Yamada K. Tissue plasminogen activator in chronic subdural hematomas as a predictor of recurrence. *J Neurosurg.* 2006 Jan;104(1):79-84.
- [24] Fujisawa H, Ito H, Saito K, Ikeda K, Nitta H, Yamashita J. Immunohistochemical localization of tissue-type plasminogen activator in the lining wall of chronic subdural hematoma. *Surg Neurol.* 1991 Jun;35(6):441-5.
- [25] Hohenstein A, Erber R, Schilling L, Weigel R. Increased mRNA expression of VEGF within the hematoma and imbalance of angiopoietin-1 and -2 mRNA within the neomembranes of chronic subdural hematoma. *J Neurotrauma.* 2005 May;22(5):518-28.
- [26] Suzuki K, Takano S, Nose T, Doi M, Ohashi N. Increased concentration of vascular endothelial growth factor (VEGF) in chronic subdural hematoma. *J Trauma.* 1999 Mar;46(3):532-3.
- [27] Weigel R, Schilling L, Schmiedek P. Specific pattern of growth factor distribution in chronic subdural hematoma (CSH): evidence for an angiogenic disease. *Acta Neurochir (Wien).* 2001 Aug;143(8):811-8; discussion 9.
- [28] Weir B. The osmolality of subdural hematoma fluid. *J Neurosurg.* 1971 Apr;34(4):528-33.
- [29] Weir B. Oncotic pressure of subdural fluids. *J Neurosurg.* 1980 Oct;53(4):512-5.
- [30] Sambavian M. An overview of chronic subdural hematoma: Experience with 2300 surgical cases. *Surg Neurol.* 1997(47):418-22.
- [31] French BN DA. Infantile chronic subdural hematoma of posterior fossa diagnosed by computerized tomography. Case report. *J Neurosurg.* 1977(47):949-52.
- [32] Kudo H KK, Izawa I. Chronic subdural hematoma in elderly people : Present status on Awaji Island and epidemiological prospect. *Neurol Med Chir (Tokyo).* 1992(32):207-9.
- [33] Weiner HL CS, Cohen H. Current treatment of normal-pressure hydrocephalus: Comparison of flow-regulated and differential-pressure shunt valves. *Neurosurgery.* 1995(37):877-84.
- [34] Dietrich U LC, Sprick C. Subdural hematoma in a case of hydrocephalus and macrocrania. Experience with a pressure-adjustable valve. *Childs Nerv Syst.* 1987(3):242-4.
- [35] Kamano S NY, Imanishi T. Management with a programmable pressure valve of subdural hematomas caused by ventriculoperitoneal shunt: Case report. *Surg Neurol.* 1991(35):381-3.
- [36] Markwalder TM. Chronic subdural hematomas: a review. *J Neurosurg.* 1981 May;54(5):637-45.



- [37] Kotwica Z PL. The association of arteriovenous malformation, aneurysm and chronic subdural hematoma. Case report. *Zentralbl Neurochit.* 1986(47):158-60.
- [38] Pozzatti E TF, Gaist G. Chronic subdural haematoma from cerebral arteriovenous malformation. *Neurochirurgia.* 1986(29):61-2.
- [39] Cinalli G ZM, Carteret M. Subdural sarcoma associated with chronic subdural hematoma. Report of two cases and review of the literature. *J Neurosurg.* 1997(86):553-7.
- [40] Popovic EA LM, Scheithauer BW. Mast cell-rich convexity meningioma: Case report and review of the literature. *Surg Neurol.* 1994(42):8-13.
- [41] Tanaka N YM, Jimbo M. Meningioma associated with chronic subdural hematoma and meningotheelial call cluster within the hematoma capsule- case report. *Neurol Med Chir (Tokyo).* 1994(34):176-9.
- [42] Markwalder TM, Steinsiepe KF, Rohner M, Reichenbach W, Markwalder H. The course of chronic subdural hematomas after burr-hole craniostomy and closed-system drainage. *J Neurosurg.* 1981 Sep;55(3):390-6.
- [43] Teasdale G, Jennett B. Assessment of coma and impaired consciousness. A practical scale. *Lancet.* 1974 Jul 13;2(7872):81-4.
- [44] Jennett B, Bond M. Assessment of outcome after severe brain damage. *Lancet.* 1975 Mar 1;1(7905):480-4.
- [45] Rankin J. Cerebral vascular accidents in patients over the age of 60. II. Prognosis. *Scott Med J.* 1957 May;2(5):200-15.
- [46] Chon KH, Lee JM, Koh EJ, Choi HY. Independent predictors for recurrence of chronic subdural hematoma. *Acta Neurochir (Wien).* 2012 Sep;154(9):1541-8.
- [47] Senturk S, Guzel A, Bilici A, Takmaz I, Guzel E, Aluclu MU, et al. CT and MR imaging of chronic subdural hematomas: a comparative study. *Swiss Med Wkly.* 2010 Jun 12;140(23-24):335-40.
- [48] Osborn AG BS, Salzman KL, Katzman GL, Provenzale J, Castillo N, Heldlund GL, Illner A, Harnsberger HR, Cooper JA, Jones BV, Hamilton BE editor. *Diagnostic Imaging Brain.* 1st ed. Salt Lake City, Utha, USA: Amirsys; 2004.
- [49] Goksu E, Akyuz M, Ucar T, Kazan S. Spontaneous resolution of a large chronic subdural hematoma: a case report and review of the literature. *Ulus Travma Acil Cerrahi Derg.* 2009 Jan;15(1):95-8.
- [50] Parlato C, Guarracino A, Moraci A. Spontaneous resolution of chronic subdural hematoma. *Surg Neurol.* 2000 Apr;53(4):312-5; discussion 5-7.
- [51] Svien HJ, Gelety JE. On the Surgical Management of Encapsulated Subdural Hematoma. A Comparison of the Results of Membranectomy and Simple Evacuation. *J Neurosurg.* 1964 Mar;21:172-7.

- [52] Lega BC, Danish SF, Malhotra NR, Sonnad SS, Stein SC. Choosing the best operation for chronic subdural hematoma: a decision analysis. *J Neurosurg.* 2010 Sep;113(3):615-21.
- [53] Horn EM, Feiz-Erfan I, Bristol RE, Spetzler RF, Harrington TR. Bedside twist drill craniostomy for chronic subdural hematoma: a comparative study. *Surg Neurol.* 2006 Feb;65(2):150-3; discussion 3-4.
- [54] Santarius T, Lawton R, Kirkpatrick PJ, Hutchinson PJ. The management of primary chronic subdural haematoma: a questionnaire survey of practice in the United Kingdom and the Republic of Ireland. *Br J Neurosurg.* 2008 Aug;22(4):529-34.
- [55] Cenic A, Bhandari M, Reddy K. Management of chronic subdural hematoma: a national survey and literature review. *Can J Neurol Sci.* 2005 Nov;32(4):501-6.
- [56] Neils DM, Singanallur PS, Wang H, Tracy P, Klopfenstein J, Dinh D, et al. Recurrence-free chronic subdural hematomas: a retrospective analysis of the instillation of tissue plasminogen activator in addition to twist drill or burr hole drainage in the treatment of chronic subdural hematomas. *World Neurosurg.* 2012 Jul;78(1-2):145-9.
- [57] Krieg SM, Aldinger F, Stoffel M, Meyer B, Kreutzer J. Minimally invasive decompression of chronic subdural haematomas using hollow screws: efficacy and safety in a consecutive series of 320 cases. *Acta Neurochir (Wien).* 2012 Apr;154(4):699-705; discussion
- [58] Aoki N. Chronic subdural hematoma in infancy. Clinical analysis of 30 cases in the CT era. *J Neurosurg.* 1990 Aug;73(2):201-5.
- [59] Probst C. Peritoneal drainage of chronic subdural hematomas in older patients. *J Neurosurg.* 1988 Jun;68(6):908-11.
- [60] Rodziewicz GS, Chuang WC. Endoscopic removal of organized chronic subdural hematoma. *Surg Neurol.* 1995 Jun;43(6):569-72; discussion 72-3.
- [61] Takeda N, Sasaki K, Oikawa A, Aoki N, Hori T. A new simple therapeutic method for chronic subdural hematoma without irrigation and drainage. *Acta Neurochir (Wien).* 2006 May;148(5):541-6.
- [62] Kubo S, Takimoto H, Nakata H, Yoshimine T. Carbon dioxide insufflation for chronic subdural haematoma: a simple addition to burr-hole irrigation and closed-system drainage. *Br J Neurosurg.* 2003 Dec;17(6):547-50.
- [63] Ishihara H, Ishihara S, Kohyama S, Yamane F, Ogawa M, Sato A, et al. Experience in endovascular treatment of recurrent chronic subdural hematoma. *Interv Neuroradiol.* 2007 Mar 15;13 Suppl 1:141-4.
- [64] Mandai S, Sakurai M, Matsumoto Y. Middle meningeal artery embolization for refractory chronic subdural hematoma. Case report. *J Neurosurg.* 2000 Oct;93(4):686-8.

- [65] Mino M, Nishimura S, Hori E, Kohama M, Yonezawa S, Midorikawa H, et al. Efficacy of middle meningeal artery embolization in the treatment of refractory chronic subdural hematoma. *Surg Neurol Int.* 2010;1:78.
- [66] Takahashi K, Muraoka K, Sugiura T, Maeda Y, Mandai S, Gohda Y, et al. (Middle meningeal artery embolization for refractory chronic subdural hematoma: 3 case reports). *No Shinkei Geka.* 2002 May;30(5):535-9.
- [67] Laumer R, Schramm J, Leykauf K. Implantation of a reservoir for recurrent subdural hematoma drainage. *Neurosurgery.* 1989 Dec;25(6):991-6.
- [68] Sato M, Iwatsuki K, Akiyama C, Kumura E, Yoshimine T. Implantation of a reservoir for refractory chronic subdural hematoma. *Neurosurgery.* 2001 Jun;48(6):1297-301.
- [69] Hallett M, Litvan I. Evaluation of surgery for Parkinson's disease: a report of the Therapeutics and Technology Assessment Subcommittee of the American Academy of Neurology. The Task Force on Surgery for Parkinson's Disease. *Neurology.* 1999 Dec 10;53(9):1910-21.
- [70] Han HJ, Park CW, Kim EY, Yoo CJ, Kim YB, Kim WK. One vs. Two Burr Hole Craniostomy in Surgical Treatment of Chronic Subdural Hematoma. *J Korean Neurosurg Soc.* 2009 Aug;46(2):87-92.
- [71] Kansal R, Nadkarni T, Goel A. Single versus double burr hole drainage of chronic subdural hematomas. A study of 267 cases. *J Clin Neurosci.* 2010 Apr;17(4):428-9.
- [72] Belkhair S, Pickett G. One versus double burr holes for treating chronic subdural hematoma meta-analysis. *Can J Neurol Sci.* 2013 Jan;40(1):56-60.
- [73] Kuroki T, Matsumoto M, Kushida T, Ohtsuka T, Uchino M, Nishikawa H. Nontraumatic subdural hematoma secondary to dural metastasis of lung cancer: case report and review of the literature. *No Shinkei Geka.* 1994 Sep;22(9):857-62.
- [74] Matsumoto K, Akagi K, Abekura M, Ryujin H, Ohkawa M, Iwasa N, et al. Recurrence factors for chronic subdural hematomas after burr-hole craniostomy and closed system drainage. *Neurol Res.* 1999 Apr;21(3):277-80.
- [75] Suzuki K, Sugita K, Akai T, Takahata T, Sonobe M, Takahashi S. Treatment of chronic subdural hematoma by closed-system drainage without irrigation. *Surg Neurol.* 1998 Sep;50(3):231-4.
- [76] Ram Z, Hadani M, Sahar A, Spiegelmann R. Continuous irrigation-drainage of the subdural space for the treatment of chronic subdural haematoma. A prospective clinical trial. *Acta Neurochir (Wien).* 1993;120(1-2):40-3.
- [77] Hennig R, Kloster R. Burr hole evacuation of chronic subdural haematomas followed by continuous inflow and outflow irrigation. *Acta Neurochir (Wien).* 1999;141(2):171-6.

- [78] Aoki N. Subdural tapping and irrigation for the treatment of chronic subdural hematoma in adults. *Neurosurgery*. 1984 May;14(5):545-8.
- [79] Bellut D, Woernle CM, Burkhardt JK, Kockro RA, Bertalanffy H, Krayenbuhl N. Subdural drainage versus subperiosteal drainage in burr-hole trepanation for symptomatic chronic subdural hematomas. *World Neurosurg*. 2012 Jan;77(1):111-8.
- [80] Kaliaperumal C, Khalil A, Fenton E, Okafo U, Kaar G, O'Sullivan M, et al. A prospective randomised study to compare the utility and outcomes of subdural and subperiosteal drains for the treatment of chronic subdural haematoma. *Acta Neurochir (Wien)*. 2012 Nov;154(11):2083-8; discussion 8-9.
- [81] Zumofen D, Regli L, Levivier M, Krayenbuhl N. Chronic subdural hematomas treated by burr hole trepanation and a subperiosteal drainage system. *Neurosurgery*. 2009 Jun;64(6):1116-21; discussion 21-2.
- [82] Abouzari M, Rashidi A, Rezaii J, Esfandiari K, Asadollahi M, Aleali H, et al. The role of postoperative patient posture in the recurrence of traumatic chronic subdural hematoma after burr-hole surgery. *Neurosurgery*. 2007 Oct;61(4):794-7; discussion 7.
- [83] Choudhury AR. Avoidable factors that contribute to complications in the surgical treatment of chronic subdural haematoma. *Acta Neurochir (Wien)*. 1994;129(1-2):15-9.
- [84] Kurabe S, Ozawa T, Watanabe T, Aiba T. Efficacy and safety of postoperative early mobilization for chronic subdural hematoma in elderly patients. *Acta Neurochir (Wien)*. 2010 Jul;152(7):1171-4.
- [85] Nakajima H, Yasui T, Nishikawa M, Kishi H, Kan M. The role of postoperative patient posture in the recurrence of chronic subdural hematoma: a prospective randomized trial. *Surg Neurol*. 2002 Dec;58(6):385-7; discussion 7.
- [86] Voelker JL. Nonoperative treatment of chronic subdural hematoma. *Neurosurg Clin N Am*. 2000 Jul;11(3):507-13.
- [87] Bender MB, Christoff N. Nonsurgical treatment of subdural hematomas. *Arch Neurol*. 1974 Aug;31(2):73-9.
- [88] Decaux O, Cador B, Dufour T, Jegou P, Cazalets C, Laurat E, et al. (Nonsurgical treatment of chronic subdural hematoma with steroids: two case reports). *Rev Med Interne*. 2002 Sep;23(9):788-91.
- [89] Delgado-Lopez PD, Martin-Velasco V, Castilla-Diez JM, Rodriguez-Salazar A, Gala-cho-Harriero AM, Fernandez-Arconada O. Dexamethasone treatment in chronic subdural haematoma. *Neurocirugia (Astur)*. 2009 Aug;20(4):346-59.
- [90] Weigel R, Hohenstein A, Schlickum L, Weiss C, Schilling L. Angiotensin converting enzyme inhibition for arterial hypertension reduces the risk of recurrence in patients

with chronic subdural hematoma possibly by an antiangiogenic mechanism. *Neurosurgery*. 2007 Oct;61(4):788-92; discussion 92-3.

- [91] Kurti X, Xhumari A, Petrela M. Bilateral chronic subdural haematomas; surgical or non-surgical treatment. *Acta Neurochir (Wien)*. 1982;62(1-2):87-90.
- [92] Suzuki J, Takaku A. Nonsurgical treatment of chronic subdural hematoma. *J Neurosurg*. 1970 Nov;33(5):548-53.
- [93] Coleman PL, Patel PD, Cwikel BJ, Rafferty UM, Sznycer-Laszuk R, Gelehrter TD. Characterization of the dexamethasone-induced inhibitor of plasminogen activator in HTC hepatoma cells. *J Biol Chem*. 1986 Mar 25;261(9):4352-7.
- [94] Gao T, Lin Z, Jin X. Hydrocortisone suppression of the expression of VEGF may relate to toll-like receptor (TLR) 2 and 4. *Curr Eye Res*. 2009 Sep;34(9):777-84.
- [95] Liu Z, Yuan X, Luo Y, He Y, Jiang Y, Chen ZK, et al. Evaluating the effects of immunosuppressants on human immunity using cytokine profiles of whole blood. *Cytokine*. 2009 Feb;45(2):141-7.
- [96] Frati A, Salvati M, Mainiero F, Ippoliti F, Rocchi G, Raco A, et al. Inflammation markers and risk factors for recurrence in 35 patients with a posttraumatic chronic subdural hematoma: a prospective study. *J Neurosurg*. 2004 Jan;100(1):24-32.
- [97] Glover D, Labadie EL. Physiopathogenesis of subdural hematomas. Part 2: Inhibition of growth of experimental hematomas with dexamethasone. *J Neurosurg*. 1976 Oct;45(4):393-7.
- [98] Berghauer Pont LM, Dirven CM, Dippel DW, Verweij BH, Dammers R. The role of corticosteroids in the management of chronic subdural hematoma: a systematic review. *Eur J Neurol*. 2012 Nov;19(11):1397-403.
- [99] Kageyama H, Toyooka T, Tsuzuki N, Oka K. Nonsurgical treatment of chronic subdural hematoma with tranexamic acid. *J Neurosurg*. 2013 Aug;119(2):332-7.
- [100] Cartmill M, Dolan G, Byrne JL, Byrne PO. Prothrombin complex concentrate for oral anticoagulant reversal in neurosurgical emergencies. *Br J Neurosurg*. 2000 Oct;14(5):458-61.
- [101] Rust T, Kiemer N, Erasmus A. Chronic subdural haematomas and anticoagulation or anti-thrombotic therapy. *J Clin Neurosci*. 2006 Oct;13(8):823-7.
- [102] Hanley JP. Warfarin reversal. *J Clin Pathol*. 2004 Nov;57(11):1132-9.
- [103] Lankiewicz MW, Hays J, Friedman KD, Tinkoff G, Blatt PM. Urgent reversal of warfarin with prothrombin complex concentrate. *J Thromb Haemost*. 2006 May;4(5):967-70.



- [104] Lin J, Hanigan WC, Tarantino M, Wang J. The use of recombinant activated factor VII to reverse warfarin-induced anticoagulation in patients with hemorrhages in the central nervous system: preliminary findings. *J Neurosurg.* 2003 Apr;98(4):737-40.
- [105] Mayer SA, Brun NC, Begtrup K, Broderick J, Davis S, Diringer MN, et al. Recombinant activated factor VII for acute intracerebral hemorrhage. *N Engl J Med.* 2005 Feb 24;352(8):777-85.
- [106] Vigue B, Ract C, Tremey B, Engrand N, Leblanc PE, Decaux A, et al. Ultra-rapid management of oral anticoagulant therapy-related surgical intracranial hemorrhage. *Intensive Care Med.* 2007 Apr;33(4):721-5.
- [107] Woo CH, Patel N, Conell C, Rao VA, Faigeles BS, Patel MC, et al. Rapid Warfarin Reversal in the Setting of Intracranial Hemorrhage: A Comparison of Plasma, Recombinant Activated Factor VII, and Prothrombin Complex Concentrate. *World Neurosurg.* 2012 Dec 5.
- [108] Bux J. Transfusion-related acute lung injury (TRALI): a serious adverse event of blood transfusion. *Vox Sang.* 2005 Jul;89(1):1-10.
- [109] Makris M, Van Veen JJ. Three or four factor prothrombin complex concentrate for emergency anticoagulation reversal? *Blood Transfus.* 2011 Apr;9(2):117-9.
- [110] Mayer SA, Brun NC, Begtrup K, Broderick J, Davis S, Diringer MN, et al. Efficacy and safety of recombinant activated factor VII for acute intracerebral hemorrhage. *N Engl J Med.* 2008 May 15;358(20):2127-37.
- [111] Chari A, Clemente Morgado T, Rigamonti D. Recommencement of anticoagulation in chronic subdural haematoma: a systematic review and meta-analysis. *Br J Neurosurg.* 2013 Jul 8.
- [112] Forster MT, Mathe AK, Senft C, Scharrer I, Seifert V, Gerlach R. The influence of pre-operative anticoagulation on outcome and quality of life after surgical treatment of chronic subdural hematoma. *J Clin Neurosci.* 2010 Aug;17(8):975-9.
- [113] Kawamata T, Takeshita M, Kubo O, Izawa M, Kagawa M, Takakura K. Management of intracranial hemorrhage associated with anticoagulant therapy. *Surg Neurol.* 1995 Nov;44(5):438-42; discussion 43.
- [114] Yeon JY, Kong DS, Hong SC. Safety of early warfarin resumption following burr hole drainage for warfarin-associated subacute or chronic subdural hemorrhage. *J Neurotrauma.* 2012 May 1;29(7):1334-41.
- [115] Zingale A, Chibbaro S, Florio A, Distefano G, Porcaro S. Management of chronic subdural hematoma in patients treated with anticoagulation. *J Neurosurg Sci.* 1999 Dec; 43(4):277-84.
- [116] Olesen JB, Lip GY, Lindhardsen J, Lane DA, Ahlehoff O, Hansen ML, et al. Risks of thromboembolism and bleeding with thromboprophylaxis in patients with atrial fi-



brillation: A net clinical benefit analysis using a 'real world' nationwide cohort study. *Thromb Haemost*. 2011 Oct;106(4):739-49.

- [117] Pisters R, Lane DA, Nieuwlaar R, de Vos CB, Crijns HJ, Lip GY. A novel user-friendly score (HAS-BLED) to assess 1-year risk of major bleeding in patients with atrial fibrillation: the Euro Heart Survey. *Chest*. 2010 Nov;138(5):1093-100.
- [118] Lindvall P, Koskinen LO. Anticoagulants and antiplatelet agents and the risk of development and recurrence of chronic subdural haematomas. *J Clin Neurosci*. 2009 Oct;16(10):1287-90.
- [119] Mascarenhas L. Illustration of the impact of antiplatelet drugs on the genesis and management of chronic subdural hematoma. *Neurochirurgie*. 2012 Feb;58(1):47-51.
- [120] Ranucci M, Nano G, Pazzaglia A, Bianchi P, Casana R, Tealdi DG. Platelet mapping and desmopressin reversal of platelet inhibition during emergency carotid endarterectomy. *J Cardiothorac Vasc Anesth*. 2007 Dec;21(6):851-4.
- [121] Torihashi K, Sadamasa N, Yoshida K, Narumi O, Chin M, Yamagata S. Independent predictors for recurrence of chronic subdural hematoma: a review of 343 consecutive surgical cases. *Neurosurgery*. 2008 Dec;63(6):1125-9; discussion 9.
- [122] Ratilal BO, Pappamikail L, Costa J, Sampaio C. Anticonvulsants for preventing seizures in patients with chronic subdural haematoma. *Cochrane Database Syst Rev*. 2013;6:CD004893.
- [123] Grobelny BT, Ducruet AF, Zacharia BE, Hickman ZL, Andersen KN, Sussman E, et al. Preoperative antiepileptic drug administration and the incidence of postoperative seizures following burr hole-treated chronic subdural hematoma. *J Neurosurg*. 2009 Dec;111(6):1257-62.
- [124] Ohno K, Maehara T, Ichimura K, Suzuki R, Hirakawa K, Monma S. Low incidence of seizures in patients with chronic subdural haematoma. *J Neurol Neurosurg Psychiatry*. 1993 Nov;56(11):1231-3.
- [125] Hirakawa K, Hashizume K, Fuchinoue T, Takahashi H, Nomura K. Statistical analysis of chronic subdural hematoma in 309 adult cases. *Neurol Med Chir (Tokyo)*. 1972;12(0):71-83.
- [126] Rubin G, Rappaport ZH. Epilepsy in chronic subdural haematoma. *Acta Neurochir (Wien)*. 1993;123(1-2):39-42.
- [127] Sabo RA, Hanigan WC, Aldag JC. Chronic subdural hematomas and seizures: the role of prophylactic anticonvulsive medication. *Surg Neurol*. 1995 Jun;43(6):579-82.
- [128] Chen CW, Kuo JR, Lin HJ, Yeh CH, Wong BS, Kao CH, et al. Early post-operative seizures after burr-hole drainage for chronic subdural hematoma: correlation with brain CT findings. *J Clin Neurosci*. 2004 Sep;11(7):706-9.

- [129] Gelabert-Gonzalez M, Iglesias-Pais M, Garcia-Allut A, Martinez-Rumbo R. Chronic subdural haematoma: surgical treatment and outcome in 1000 cases. *Clin Neurol Neurosurg.* 2005 Apr;107(3):223-9.
- [130] Ogasawara K, Kosshu K, Yoshimoto T, Ogawa A. Transient hyperemia immediately after rapid decompression of chronic subdural hematoma. *Neurosurgery.* 1999 Sep; 45(3):484-8; discussion 8-9.
- [131] Diaz P, Maillo A. (Intracerebral hemorrhage following chronic subdural hematoma evacuation: report of two cases and review of the literature). *Neurocirugia (Astur).* 2003 Sep;14(4):333-6; discussion 7.
- [132] Caron JL, Worthington C, Bertrand G. Tension pneumocephalus after evacuation of chronic subdural hematoma and subsequent treatment with continuous lumbar sub-arachnoid infusion and craniostomy drainage. *Neurosurgery.* 1985 Jan;16(1):107-10.
- [133] Lavano A, Benvenuti D, Volpentesta G, Donato G, Marotta R, Zappia M, et al. Symptomatic tension pneumocephalus after evacuation of chronic subdural haematoma: report of seven cases. *Clin Neurol Neurosurg.* 1990;92(1):35-41.
- [134] Borger V, Vatter H, Oszvald A, Marquardt G, Seifert V, Guresir E. Chronic subdural haematoma in elderly patients: a retrospective analysis of 322 patients between the ages of 65-94 years. *Acta Neurochir (Wien).* 2012 Sep;154(9):1549-54.
- [135] Ohba S, Kinoshita Y, Nakagawa T, Murakami H. The risk factors for recurrence of chronic subdural hematoma. *Neurosurg Rev.* 2013 Jan;36(1):145-9; discussion 9-50.
- [136] Rohde V, Graf G, Hassler W. Complications of burr-hole craniostomy and closed-system drainage for chronic subdural hematomas: a retrospective analysis of 376 patients. *Neurosurg Rev.* 2002 Mar;25(1-2):89-94.
- [137] Delgado PD, Cogolludo FJ, Mateo O, Cancela P, Garcia R, Carrillo R. (Early prognosis in chronic subdural hematomas. Multivariate analysis of 137 cases). *Rev Neurol.* 2000 May 1-15;30(9):811-7.
- [138] Yamamoto H, Hirashima Y, Hamada H, Hayashi N, Origasa H, Endo S. Independent predictors of recurrence of chronic subdural hematoma: results of multivariate analysis performed using a logistic regression model. *J Neurosurg.* 2003 Jun;98(6):1217-21.
- [139] Ramachandran R, Hegde T. Chronic subdural hematomas--causes of morbidity and mortality. *Surg Neurol.* 2007 Apr;67(4):367-72; discussion 72-3.

