

We are IntechOpen, the world's leading publisher of Open Access books Built by scientists, for scientists

6,900

Open access books available

186,000

International authors and editors

200M

Downloads

Our authors are among the

154

Countries delivered to

TOP 1%

most cited scientists

12.2%

Contributors from top 500 universities



WEB OF SCIENCE™

Selection of our books indexed in the Book Citation Index
in Web of Science™ Core Collection (BKCI)

Interested in publishing with us?
Contact book.department@intechopen.com

Numbers displayed above are based on latest data collected.
For more information visit www.intechopen.com



Photodynamic Therapy for Non-Melanoma Skin Cancer

Cintia Teles de Andrade, Natalia Mayumi Inada,
Dora Patricia Ramirez,
Vanderlei Salvador Bagnato and Cristina Kurachi

Additional information is available at the end of the chapter

<http://dx.doi.org/10.5772/55242>

1. Introduction

Skin cancer shows the highest incidence worldwide, among all cancer types, and is mainly classified in melanoma and non-melanoma subtypes.

Clinical evaluation through dermatoscopy is a widely performed practice, and it is a noninvasive technique that uses magnification to allow better visualization of the structures immediately below the skin surface. This examination provides morphological criteria for distinguishing various lesions types.

Histopathology is considered the gold standard for diagnosis of skin cancer and other dermal disorders. These two exams together, as well as the location and extent of the injury will determine the choice of treatment.

Treatments such as surgical excision, cryotherapy, topical application of imiquimod cream and 5-fluorouracil cream, and radiotherapy are commonly chosen based on the depth and extension of the lesions. Limitations and side-effects of the conventional therapies motivate the development of other techniques. Photodynamic therapy (PDT) is presented as an alternative treatment for basal cell carcinoma (BCC).

PDT has proven to be effective with an excellent cosmetic outcome in the treatment of superficial BCC (sBCC), and recently published guidelines state that PDT can be an effective and reliable treatment option for the treatment of thin nodular BCC (nBCC), and actinic keratosis (AK) [1]. It is a technically simple noninvasive procedure that offers patients at least equal efficacy and a high level of satisfaction and other cosmetic outcome when compared with cryotherapy and topical treatments [2].

The term *field cancerisation* or *field effect* is frequently used to describe extensive UV damage with recurrent, multiple AK, and the presence of a tissue with genetically altered cells is a risk factor for cancer development, representing an indication for topical PDT [3].

Our group has extensive experience in clinical PDT in various areas of medicine as in gynecology [4], infectious disease [5], and in particular in dermatology [6-7], and in this chapter will be discussed the advantages and indications of the PDT for non-melanoma skin cancer and others conditions.

2. Basic principles

Photosensitized oxidations have been of interest to chemists and biologists since Raab's discovery that microorganisms are killed by light in the presence of oxygen and sensitizing dyes [1].

The mechanism of action of photosensitizers is divide in two different types and generally involves direct oxidation by hydrogen peroxide (H_2O_2), superoxide anion radical ($O_2^{\bullet-}$) and hydroxyl radical ($\bullet OH$) (Type I reaction) of biological targets (membranes, proteins, and DNA), as well as oxidation mediated by singlet oxygen (1O_2) that is mainly formed through energy transfer from triplet states to molecular oxygen (Type II reaction) [8-10].

The generation of Reactive Oxygen Species (ROS), in both types I or II, are dependent on the uptake of a photosensitizing dye, often a haematoporphyrin derivative, by the tumor or other abnormal target tissue, the subsequent irradiation of the tumor with visible light of an appropriate wavelength, and the presence of molecular oxygen [10]. An adequate concentration of molecular oxygen is also needed for tissue damage. If any one of these components is absent, there is no photodynamic response, and the overall effectiveness therefore requires careful planning of both tissue photosensitization and light dosimetry.

PDT response is induced by more than one cellular mechanism. A photosensitiser can directly target the tumor cells, inducing necrosis or apoptosis (Figure 1) [11]. Alternatively, tumor necrosis can be induced by damaging its vasculature [12].

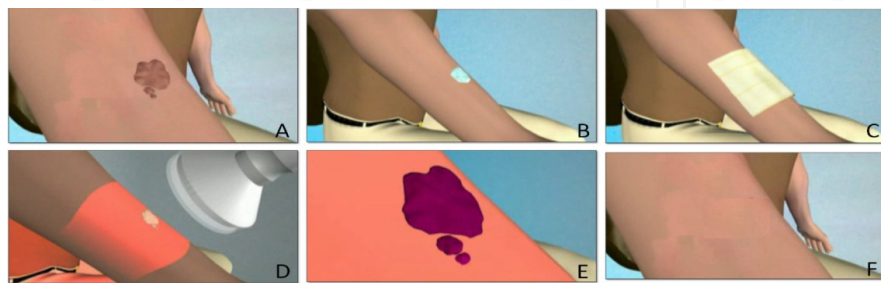


Figure 1. Treatment procedure for topical PDT. A) Skin cancer lesion; B) Cream application (MAL or ALA); C) Occlusion of the lesion; D) Illumination; E) Inflammation and tecidual necrosis; F) Curative

3. Photosensitizers

The photosensitizers are by definition any substance capable of making an organism, a cell or a substance photosensitive, with the photo-excitation of several types of molecules through energy transfer processes. Porphyrins, chlorines, phthalocyanines are the three main groups of studied photosensitizers (PSs). Porphyrins are the most frequently used PSs, but its systemic administration shows an important adverse factor in Dermatology. Due to the high accumulation and slow drug clearance from the skin, porphyrins lead to prolonged photosensitization of the organism after application [13]. The commercially available compounds promote a patient photosensitization that lasts for 4-6 weeks. These PDT patients must avoid sun exposure during this period, otherwise skin burns can be induced. This is the major drawback for indication of PDT in Dermatology.

The development of an ideal PDT sensitizer is still a major challenge since several characteristics must be contemplated. Main characteristics are: a) photo-excitation with red-infrared light; b) low dark toxicity; c) high stability; d) rapid clearance from the body; e) high affinity to abnormal cells (selectivity), and f) high rate of ROS production.

The main reactions observed with biological molecules are lipid peroxidation (cholesterol), cycloaddition (2 +2)-protein (reaction with tryptophan) and Diels-Alder reactions upon molecules in the genetic code (guanine). Porphyrin derivatives are indeed interesting molecules. Compounds such as porphyrins and chlorins, have the characteristics suitable for use in PDT due to the high molar extinction coefficients, high absorptivities in the region of the "therapeutic window" (600-800 nm) and with high quantum yields of singlet oxygen production.

PDT can also be performed with topical use of 5-aminolevulinic acid (5-ALA) or by its ester methyl-aminolevulinate (MAL), which are both precursors in the biosynthesis of protoporphyrin IX (PpIX), a native photosensitizing compound that accumulates in the cells. Protoporphyrin IX (PpIX) has absorption peaks at 505, 540, 580 and 630 nm.

These compounds must be stored in the form of hydrochloride (R-NH₃Cl), since in its neutral form rapidly suffers degradation. Studies including a few with 5-year follow-up, have shown that ALA and MAL-PDT are comparable to other modalities in the treatment of superficial lesions considering their efficacy and with equivalent or superior cosmetic outcomes [14-15]. ALA and MAL are not photosensitizers, they are precursors of endogenous PpIX (Figure 2).

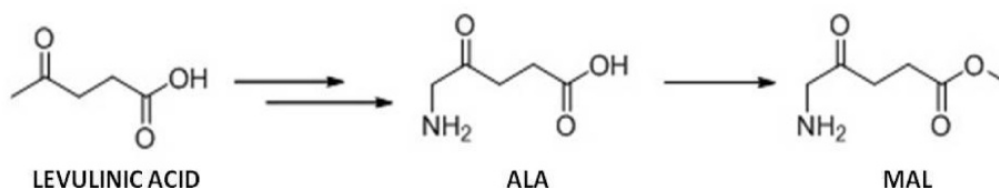


Figure 2. Molecular structures of the PpIX precursors.

The fundamental difference between ALA and its methyl ester (MAL) is the more hydrophobic character of the MAL. Thus, MAL can better penetrate through the cell membranes and more easily reaches the deepest epidermal layers. However, the biosynthesis of protoporphyrin IX production from MAL is slightly more time consuming because of the need of hydrolysis of this compound.

Chlorin is a photosensitizer indicated in the cases of PDT using *i.v.* medication. It is derived from natural or synthetic tetrapyrroles, and an important feature is their strong light absorption in the spectral region usually above 660 nm. A significant advantage of PDT using chlorins is the reduced duration of cutaneous photosensitivity as compared with other photosensitizers [16].

Recently, eight new chlorins with amphiphilic properties were synthesized from PpIX. Biological studies of some of these new chlorins indicate the great potential of these compounds as photosensitizers in PDT [17].

4. Dosimetry

Distinct light sources can be used for PDT. For therapy, the tissue must be irradiated with light at appropriate wavelengths (within the absorption spectrum of porphyrins). The porphyrins exhibit a very typical absorption spectrum with the highest peak at approximately 405 nm, called the Soret-band. Other lower absorption peaks, the Q-bands, are centered at 510, 545, 580 and 630 nm. The absorption band at 630 nm is preferentially used for irradiation since light at the red spectrum results in a higher skin penetration. Lasers and incoherent light sources (lamps, light-emitting-diode – LED – lamps and, intense pulsed light – IPL) have been used. When endoscopic applications are necessary, the activating light has to be delivered through optical fibers, and laser systems are the best option for this purpose. For dermatological application, incoherent light sources are more attractive, due to the possibility of distinct emission geometries and comparable lower cost [18-20].

The therapeutic efficacy of PDT involves administration to the patient of a photosensitizer or a pro-drug, a waiting time to allow adequate concentration of the sensitizer molecules in the tumor, and irradiation of the target tissue with a proper wavelength to activate the photosensitizer generating cytotoxic products, mainly the singlet-oxygen. To trigger cell death, a minimum number of singlet-oxygen molecules have to be produced. The minimal energy dose required to achieve the irreversible tissue damage, resulting in tumor necrosis, is called the threshold dose.

The energy dose is given in Joules per centimeter square (J/cm^2), that is the amount of energy delivered to the tissue per unit area. Light intensity is measured in Watts (W) and corresponds to the energy per unit of time. One W corresponds to 1 J per 1 second. Irradiance is measured in Watts per centimeter square (W/cm^2), representing the light power delivered to the tissue surface [19, 21-22]. A simple relationship between light dose (D), irradiance (I) and time (t) is:

$$D=I.t \quad (1)$$

Energy doses delivered for the treatment of basal cell carcinoma and other dermal conditions are in the range of 40-150 J/cm² and with irradiances of 40-150 mW/cm². The PDT illumination of a BCC lesion of 2 cm of diameter, for example, may be of 8 to 20 minutes, depending on the chosen irradiation parameters.

5. Clinical results

Nonmelanoma skin cancer is the most frequent one in the world population. Currently, therapeutic options are surgical resection, electrocoagulation, curettage, cryotherapy, immunomodulating agents, cytotoxic agents, chemotherapy, PDT, among others. PDT is a noninvasive technique with excellent cosmetic outcome, well tolerated by patients and with good healing results, when used for the initial stages of cancer lesions. Different studies show the technique effectiveness for BCC (Figure 3 and 4), presenting curative rates ranging from 52.2% to 100% [7, 23-28].

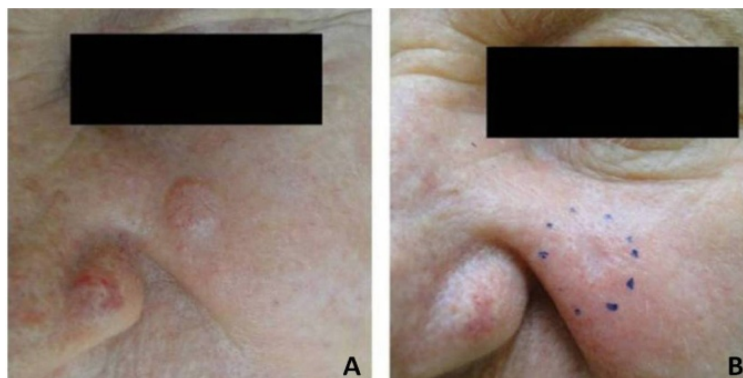


Figure 3. Nodular BCC before (A) and 30 days after (B) PDT, treated with MAL 20% in 2 sessions and dose of 100J/cm²

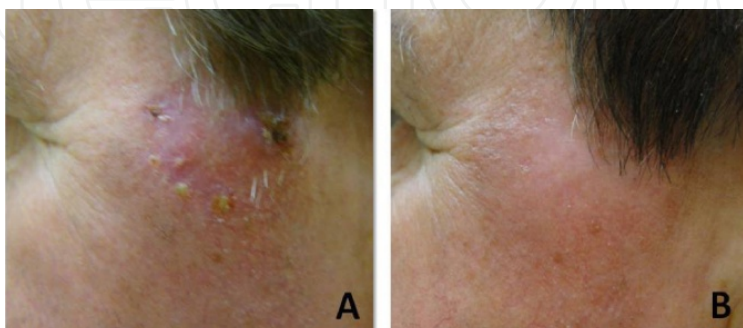


Figure 4. Superficial BCC before (A) and 30 days after (B) PDT, treated with MAL 20% in 2 sessions and dose of 100J/cm²

Wolf et al., (1993), in their study treated 70 different lesions – superficial BCC, actinic keratosis (AK), nodular-ulcerative BCC, squamous cell carcinoma (SCC) and melanoma – using ALA cream, with dose of 30J/cm² for superficial BCC and AK and 100 J/cm²-300 J/cm² for other lesions. Results at 12 months showed complete response for AK, 36 of 37 superficial BCC lesions showed good responses, 5 of 6 SCC, 8 cutaneous metastases of malignant melanoma were therapeutic failures and other lesions showed a partial response after treatment [23]. In the study by Calzavara (1994), which also included several lesions (AK, BCC, nodular BCC, pigmented BCC and SCC), all treated with ALA 20%, there were complete response in 100% for BCC and AK cases, decreasing to 80% in nodular lesions. Other treated lesions exhibited low curative rate when evaluated 30 days after treatment. These curative rates decreased to 86.9% in BCC and 50% in nodular BCC in the clinical follow-up done for 29 months [27]. According to the study of Souza et al., (2009), after evaluating 20 patients (showing difficulties, impediment high risk or rejection of surgical procedure) with BCC and Bowen's disease (BD) treated with ALA 20%, irradiated at wavelength of 630 nm and doses of 100 to 300 J/cm², showed that, after 1 session, presented curative rates of 91.2% at three months and 57.7% at sixty months [7].

Horn et al., (2003), treated 94 patients with 108 superficial, nodular and mixed BCC lesion with difficult to treatment (resulting scars from reconstructive surgery extensive, interfering with normal function of eyelids or lips, or postoperative infections), finding complete response after 3 months in 92% of superficial BCC and 87% of nodular BCC. The cosmetic outcome was evaluated as excellent or good by investigators in 76% of the lesion after 3 months follow-up, increasing to 85% at 12 months and 94% at 24 months follow-up [29].

A recent study comparing CO₂ laser ablation *versus* PDT in immunocompetent patients with multiple AK concluded that both treatments were effective in reduction of AK, but PDT seems to be superior in terms of reduction of the affected area and overall satisfaction by patients and clinicians [30].

Foley et al., (2009), conducted a double-blind and placebo-controlled study in primary lesion of nodular BCC (up to 5 mm in depth) in two medical centers. MAL was used at concentration of 160 mg/g cream or placebo cream, with three hours of occlusion. The light source applied was in the range of 570-670 nm, with an irradiance of 50-200 mW/cm² and dose of 75 J/cm². In total, 131 patients with 150 lesions were included in the study, 66 patients with 75 lesions were treated with MAL cream and 65 patients with 75 lesions with placebo cream. The treatment was developed in cycles. The first cycle was conducted in two sessions, with one week interval between sessions. If the response was partial (≤50% reduction in greatest diameter) after 3 months follow-up, the second cycle was initiated with two more sessions with one week interval, and monitoring the patient for six months. If the answer was not complete, the responsible medical team indicated the patient for surgical procedure. The complete response after 6 months follow-up, with MAL was of 73% (55/75 lesions) versus 27% (20/75 lesions) with placebo. The response decreases in larger lesion (≥ 10mm in diameter and ≥ 1mm of baseline depth). The cosmetic outcome of the lesions treated with MAL-PDT was good or excellent in 98% of the cases [24].

Caekelberg et al., (2009), observed the PDT result after 6 months in 90 patients with superficial BCC of approximately diameter 10 mm. The complete response rate was of 88.1% with cosmetic outcome qualified as excellent in 96.25% of patients [25].

Interesting results were achieved in the study of Surrenti et al., (2008), where they evaluated the PDT response in nodular and superficial BCC. In this study, 118 lesions were treated in 69 patients, located at the chest, face, head, neck and limbs. Superficial BCC were diagnosed in 94 lesions and 24 showed nodular BCC lesions, confirmed by histology. Complete response was obtained in 84/94 (89.4%) at superficial BCC, and in 12/23 (52.2%) at nodular BCC, when evaluated at 30 days after the second session. The cosmetic outcome was evaluated as excellent in 83% of cases and good in the remaining 17% of the cases [28].

Szeimies et al., (2008), compared PDT with surgery to treat superficial BCC between 8-20 mm size, in 196 patients with 234 lesions. The lesions treated with MAL 160 mg/g, in two sessions, showed a curative rate of 92.2% compared to 99.2% of the lesions treated with surgery, when assessed after 3 months of treatment. After 12 months, the cosmetic outcome was considered by the investigator as good or excellent in 92.8% of patients treated with PDT versus 51.2% of patients treated with surgery. The recurrence was 9.3% in comparison with 0% for lesions treated with PDT and surgery, respectively [26]. In nodular BCC treatment curative rates, after three months, of 91% with PDT versus 98% with surgery were obtained. After 12 months, 96% of lesions treated with surgery showed complete response compared to the 83% of the lesions treated with PDT. This study was performed on 97 patients with 105 lesions, all confirmed by histopathology [31].

In a recent study, (2012), was compared PDT with surgery, in 72 patients with 94 lesions superficial and nodular BCC with a maximum 3 mm thick. The patients were separated into two groups according to their choice of treatment, being 48 lesions treated with PDT and 46 with surgery. After 3 months, the curative rate was 95.83 % with PDT versus 95.65% with surgery. The recurrence rate was, after 12 months, 4.16% for PDT compared to 4.34% for surgery [32].

Basset-Seguin et al., (2008) presented results comparing PDT with cryotherapy in 118 patients. The authors used PDT protocol with MAL and two sessions separated by 7 days. The complete clinical response, after 3 months of treatment, was of 97% with cryotherapy versus 95% with PDT. Comparing the cosmetic outcome, they obtained excellent and good response in 54% versus 93% with cryotherapy and PDT, respectively [33].

Another multicenter study made by Aguilar et al., (2010), compared imiquimod and PDT with surgery in the treatment of 54 Bowen's disease lesions (63%) and 32 superficial BCC lesions (37%). After 24 months, the curative rate was of 97.5% for surgery, 89.5% for PDT, and 87.5% for imiquimod. The surgery cost was approximately twice the value when compared to PDT [34].

The differences between the curative results obtained in the different studies is mainly due to the distinct treatment protocols: a) different lesion selection criteria (diameter, length, thickness, site, previous treatment); b) no standardization of the pre-PDT procedures (shaving, curettage, scarification); c) distinct drugs (ALA, MAL); d) different cream incubation times (2, 3 and 4

hours); e) distinct irradiation parameters; f) number of sessions; g) different treatment evaluation times (1, 3 or 6 months) and time to evaluate recurrence (6 months, 1, 3, 5 or 10 years) [35]. However, thicker lesions and nodular BCC present lower curative rates when compared to superficial BCC [26, 28, 33, 35]. Furthermore, pretreatment procedures as shaving or curettage [29], and multiple sessions [15, 36] can increase positive response to PDT [35].

PDT may present some adverse reactions such as photosensitivity, infection, erythema, edema, pain, among others [24, 37]. In topical PDT, the photosensitive drug is localized in lesion and consumed after irradiation. Reports of local photosensitivity after treatment are scarce, and when present, are present in the following 24 hours after irradiation. The systemic PDT, on the other hand, has a longer photosensitivity time [23]. Infection is a complication that almost does not occur due to the proven action of PDT for microbiological control [37]. However, some factors may predispose to this occurrence, such as, diabetes, peripheral vascular disease, and others. In a study by Wolfe et al., (2007), 700 AK lesions were treated with PDT and only 4 cases of cellulitis were reported, but easily controlled by antibiotic therapy [38]. Changes in pigmentation, hyper and hypopigmentations, are reported in literature as approximately 1% of all adverse reactions [37]. The pain may be present during irradiation or within 7 days after treatment. In the study by Morton et al., (2001), only one third of patients treated had pain qualified between moderate and severe [39]. In the experiment by Ibbotson et al., (2011), during 9 years, different lesions were treated with topical PDT, 16% of patients showed severe pain and 50% moderate pain [37]. In a multicenter, randomized, controlled and open study, comparing PDT with surgery it was found that for PDT, 37/100 (37%) of patients had an adverse reaction versus 14/96 (14,6%) of patients treated with surgery. For PDT, photosensitivity reaction, which includes sensations of discomfort, burning and erythema was the most frequent, these reactions were of mild to moderate intensity and easily treated. For surgery, the more expected reaction was infection, that occurred in 5 of the 14 patients and requiring the use of systemic antibiotics for two weeks [26].

PDT can be associated with other treatment techniques, such as surgery, as described by Willey et al., (2009). In this study, surgical resection was associated with PDT with 20% ALA for recurrence prevention. The PDT protocol consisted of an hour of inoculation and illumination with a light source with wavelength at 417 nm during 1000 seconds (irradiance of 10 mW/cm²). The PDT cycles were repeated every 1-2 months for two years. In the first year after first PDT session, average reduction of lesions appearance was around 80%, reaching values of 95% reduction by the end of the second year [40].

The recurrence of BCC lesions when treated with traditional techniques has been estimated of 36% after one year of treatment, 61% after two years and 18% after 6 to 10 years of treatment [41]. For PDT, several studies have been published assessing the lesion recurrence after 1 to 5 [7, 15, 33, 42-43], 6 and 10 years of treatment [44].

In the clinical study done by Souza et al., (2009), the treated patients were monitored (or followed) for 60 months. The lesion recurrence was presented in 11/26 lesions (42.3%), the recurrence depending on the lesion types were of 2/5 for nodular BCC, 2/6 for superficial BCC and 7/15 to Bowen's disease [7].

According to Basset-Seguin et al., (2008), recurrence after 5 years of PDT in 103 superficial BCC, using MAL, was of 22%, all present in the first three years after treatment. This rate is comparable with the one obtained in patients treated with cryotherapy [33]. In the study by Mosterd et al., (2008), 83 nodular BCC were treated with 20% ALA-PDT and fractionated irradiation with a total dose of 150J/cm². A recurrence rate of 30.3% were obtained after 3 years. In this study, the thicknesses of 78 lesions were measured and an increased failure risk was present in thicker lesions, over 1.3 mm (42.2%), when compared to the thinner ones (15.5%) [42]. In a study by Rhodes et al., (2004), 53 nodular BCC, treated with MAL-PDT, a recurrence rate of 14% was observed after 5 years of treatment. A recurrence in 5/40 lesions treated with one PDT session and 2/9 treated with two PDT sessions, occurring especially in the first two years of treatment. When compared with surgery, the recurrence rate decreases to 4% [31]. Similar results were reported in a study of Szeimies et al., (2008), with recurrence rates for PDT of 9.3% and 0% for surgery, in a follow-up of 12 months [24].

Another study evaluating 157 BCC lesions (111 superficial BCC, 40 nodular BCC and 6 histology missing) in 90 patients treated with two sessions of MAL-PDT, recurrence rates estimated of 7% in the first 3 months, 19% in 6 months, 27% in 12 months and 31% in 24 months after treatment were obtained. When comparing recurrence rates at 12 months of nodular and superficial BCC the rates were of 28% versus 13%, respectively [43].

Christensen et al, (2009), classified 60 BCC (24 nodular BCC e 36 superficial BCC), according to size, as smaller than 1 cm, between 1-2 cm and larger than 2 cm. All lesions were curetted and DMSO was applied at the site for 5 min, then 20% ALA cream was applied and kept in position for 3 hours. PDT procedure was performed in one or two sessions. After 6 years follow up, 43/53 (81%) of lesions still showed complete response. Five patients were excluded for presenting partial response to treatment in the first three months and two patients died at the onset of follow-up period from causes unrelated to study. The recurrences were present before three years, with two thirds of these presented in the first 12 months. The average age of the patients with recurrence was of 76 y.o. for men and 77 for women. Considering lesion size, no statistical difference was observed because only one lesion measured more than 2 cm [45]. The follow up of 10 years, showed an overall curative rate of 75%, 60% for lesions treated with one session and 81% for two sessions, all recurrence cases were presented in the first three years [44].

Multiple factors have been associated with recurrence in the different studies. Few sessions are associated with high recurrence rates. One PDT session is the major factor for treatment failure [33, 44, 46]. In the study by Soler et al., (2001), 33 lesions presented recurrence, 29 of them treated with a single session and four treated with two sessions [46]. Similar data were found by Christensen et.al., (2009), where 43/53 lesions remained disease-free; 68% after one treatment session and 91% after two treatment session [45].

Size and thickness are factors that also affect lesion recurrence. The study by Mosterd et al., (2008), presented recurrence rates of 42% in the lesions with $\geq 1,3$ mm thickness, and of 15.5% for lesions $\leq 1,3$ mm. Horn et al., (2003), showed an increased recurrence associated with lesion size when evaluated 24 months after treatment. Lesions of 0-15 mm presented 4% recurrence, increasing to 16% in lesions of 16-30mm and greater than 30mm, 33% [29].

Author and type of study	Treatment Procedure	Study size	Result
Soler et al., (2001) Retrospective study [46]	MAL 160 mg/g	Total: 310 lesion	3 mo, Complete Response
	Preparation prior PDT:	131 sBCC	91% sBCC
	Debulking procedure was performed on all nodular.	82 nBCC \leq 2mm thickness	93% nBCC thin
		86 nBCC \geq 2mm thickness	86% nBCC thick
Horn et al., (2003) Open-label study [29]			11% Recurrence at 35 mo
	MAL 160 mg/g cream	Total:108 lesions	3 mo, Complete Response
	Pre-PDT procedure in nodular lesions:	49 sBCC	92% sBCC
	Shaving.	52 nBCC	87% nBCC
		7 mixed BCC	57% mixed BCC
Basset –Seguin et al., (2008) Randomized, comparative, multicenter study [33]			9% Recurrence at 12 mo
			18% Recurrence at 24 mo
	MAL cream	Total 201 lesions	3 mo, Complete response
	Preparation pre-PDT:	103 sBCC with PDT	97% PDT
	Surface debridement	98 sBCC with cryotherapy	95% Cryotherapy
Szeimies et al., (2008) multicentre, randomised, controlled, open study [26]			Recurrence at 5 years
			22% PDT
			20% Cryotherapy
	MAL 160 mg/g cream	Total 196 lesions	3 mo Complete response
	Preparation pre-PDT:	100 sBCC with PDT	92.2% PDT
Christensen et al., (2009) and (2012) Prospective study study [44-45]			99.2% Surgery
			Recurrence at 12 mo
			9.3% PDT
			0% Surgery
	ALA 20%	Total:60 lesion	3 mo, Complete response
Lindberg-Larsen et al., (2012) Retrospective study [43]	DMSO 99%	24 sBCC	92% total lesion
	Preparation pre-PDT: curettage	36 nBCC	72 mo, Complete response
			81% total lesion
			120mo, Complete response
			75% total lesion
Cosgarea et al., (2012) prospective, comparative, controlled, clinical study [32]	MAL 160 mg/g	Total: 157 lesion	3 mo Complete response
	Preparation pre-PDT:	111 sBCC	93% lesion
	Superficial lesions were debrided.	40 nBCC	Recurrence at 12 mo:
	Nodular lesions were curetted	6 unknown	nBCC 28%
Cosgarea et al., (2012) prospective, comparative, controlled, clinical study [32]			sBCC 13%
	ALA 20% cream	Total 94 sBCC	3 mo Complete response
	Preparation pre-PDT: remove scales and crusts of lesion surface	48 lesions with PDT	95.83% PDT
		46 lesions with Surgery	95.65% Surgery

Author and type of study	Treatment Procedure	Study size	Result
			Recurrence at 12 mo
			4.16% PDT
			4.34% Surgery

Table 1. Study results of topical PDT for non melanoma skin cancer

A higher recurrence rate is also present at nodular BCC, when compared to the superficial BCC [43, 46]. Age can be a factor that increases the lesion recurrence treated with PDT, other potential factors are gender and lesion site [43].

6. Non-oncological and off-label pdt applications in dermatology

PDT is already approved for the treatment of actinic keratosis and basal cell carcinoma. Off-label uses for PDT have been indicated for several dermatological conditions such as photo-damaged skin, scleroderma, warts, cutaneous leishmaniosis, psoriasis, cutaneous T-cell lymphoma and acne [20, 47]. Infectious disease has the potential to become one of the main indications of PDT in Dermatology. The microbiological control of bacteria, fungi and protozoa in infected lesions has been presented [48-51]. Onychomycosis is one of the new indications, where PDT presents good results even in cases where the antifungal systemic therapy failed (Paula-da-Silva, A. et al., Fast elimination of onychomycosis by hematoporphyrin derivative-photodynamic therapy. Accepted by Photodiagnosis and Photodynamic Therapy on December 2012).

7. Final considerations

PDT is a noninvasive technique, with few potential adverse reactions, that presents good curative rates and excellent cosmetic outcome. It may be chosen as a first option for patients with small lesions of nonmelanoma skin cancer, especially the ones in complex sites for surgical resection or in high risk patients.

PDT protocols and customized dosimetry for each target skin lesion still need to be defined. The development of new PDT drugs and delivery systems has the potential of increasing the curative rates of the present protocols. Instrumentation of light sources designed to adapt the emission geometry to the anatomical site characteristics is also important to improve PDT performance in cancer treatment.

The local treatment of infected lesions and cosmetics are PDT indications that have been fastly increasing. New protocols and drugs have been investigated, as well as new light devices developed, making PDT in Dermatology an exciting and growing field.

Author details

Cintia Teles de Andrade^{1*}, Natalia Mayumi Inada¹, Dora Patricia Ramirez^{1,2},
Vanderlei Salvador Bagnato¹ and Cristina Kurachi¹

*Address all correspondence to: cintya_teles@yahoo.com.br

1 Biophotonics Laboratory, Institute of Physics of São Carlos – University of São Paulo (USP), São Paulo, Brazil

2 PPGBiotec, Federal University of São Carlos (UFSCAR), São Paulo, Brazil

References

- [1] Braathen, L. R, Szeimies, R. M, Basset-seguin, N, Bissonnette, R, Foley, P, Pariser, D, et al. Guidelines on the use of photodynamic therapy for nonmelanoma skin cancer: An international consensus. *J Am Acad Dermatol.* (2007). Jan;, 56(1), 125-43.
- [2] Lehmann, P. Methyl aminolaevulinate-photodynamic therapy: a review of clinical trials in the treatment of actinic keratoses and nonmelanoma skin cancer. *Brit J Dermatol.* (2007). May;, 156(5), 793-801.
- [3] Braakhuis BJMTabor MP, Kummer JA, Leemans CR, Brakenhoff RH. A genetic explanation of Slaughter's concept of field cancerization: Evidence and clinical implications. *Cancer Res.* (2003). Apr 15;, 63(8), 1727-30.
- [4] Inada, N. M. da Costa MM, Guimaraes OCC, Ribeiro ED, Kurachi C, Quintana SM, et al. Photodiagnosis and treatment of condyloma acuminatum using 5-aminolevulinic acid and homemade devices. *Photodiagn Photodyn.* (2012). Mar;, 9(1), 60-8.
- [5] Bagnato, V. S, Kurachi, C, Ferreira, J, Sankarankutty, A. K, & Zucoloto, S. de Castro e Silva O. New photonic technologies for the treatment and diagnosis of hepatic diseases: an overview of the experimental work performed in collaboration, between Physics Institute of Sao Carlos and Ribeirao Preto Faculty of Medicine of the University of Sao Paulo. *Acta Cir Bras.* (2006). Suppl , 1, 3-11.
- [6] Souza, C. S, Felicio, L. B, Arruda, D, Ferreira, J, Kurachi, C, & Bagnato, V. S. Systemic photodynamic therapy as an option for keratoacanthoma centrifugum marginatum treatment. *J Eur Acad Dermatol Venereol.* (2009). Jan;, 23(1), 101-2.
- [7] Souza, C. S. Felicio LBA, Ferreira J, Kurachi C, Bentley MVB, Tedesco AC, et al. Long-term follow-up of topical aminolaevulinic acid photodynamic therapy diode laser single session for non-melanoma skin cancer. *Photodiagn Photodyn.* (2009). Sep-Dec;6(3-4):207-13., 5.

- [8] Halliwell, B. Protection against tissue damage in vivo by desferrioxamine: what is its mechanism of action? *Free Radic Biol Med.* (1989). , 7(6), 645-51.
- [9] Foote, C. S. Mechanisms of Photosensitized Oxidation- There Are Several Different Types of Photosensitized Oxidation Which May Be Important in Biological Systems. *Science.* (1968). , 162(3857), 963.
- [10] Lam, M, Oleinick, N. L, & Nieminen, A. L. Photodynamic therapy-induced apoptosis in epidermoid carcinoma cells- Reactive oxygen species and mitochondrial inner membrane permeabilization. *J Biol Chem.* (2001). Dec 14;; 276(50), 47379-86.
- [11] Oleinick, N. L, Morris, R. L, & Belichenko, T. The role of apoptosis in response to photodynamic therapy: what, where, why, and how. *Photoch Photobio Sci.* (2002). Jan;; 1(1), 1-21.
- [12] Henderson, B. W, & Dougherty, T. J. How Does Photodynamic Therapy Work. *Photochem Photobiol.* (1992). Jan;; 55(1), 145-57.
- [13] Morton, C. A, Brown, S. B, Collins, S, Ibbotson, S, Jenkinson, H, Kurwa, H, et al. Guidelines for topical photodynamic therapy: report of a workshop of the British Photodermatology Group. *Brit J Dermatol.* (2002). Apr;; 146(4), 552-67.
- [14] Fotinos, N, Campo, M. A, Popowycz, F, Gurny, R, & Lange, N. aminolevulinic acid derivatives in photomedicine: Characteristics, application and perspectives. *Photochem Photobiol.* (2006). Jul-Aug;; 82(4), 994-1015.
- [15] Rhodes, L. E, De Rie, M. A, Leifsdottir, R, Yu, R. C, Bachmann, I, Goulden, V, et al. Five-year follow-up of a randomized, prospective trial of topical methyl aminolevulinate photodynamic therapy vs surgery for nodular basal cell carcinoma. *Arch Dermatol.* (2007). Sep;; 143(9), 1131-6.
- [16] Taber, S. W, Fingar, V. H, Coots, C. T, & Wieman, T. J. Photodynamic therapy using mono-L-aspartyl chlorin e(6) (Npe6) for the treatment of cutaneous disease: A phase I clinical study. *Clin Cancer Res.* (1998). Nov;; 4(11), 2741-6.
- [17] De Oliveira, K. T. Silva AMS, Tome AC, Neves MGPMS, Neri CR, Garcia VS, et al. Synthesis of new amphiphilic chlorin derivatives from protoporphyrin-IX dimethyl ester. *Tetrahedron.* (2008). Sep 8;; 64(37), 8709-15.
- [18] Babilas, P, Schreml, S, Landthaler, M, & Szeimies, R. M. Photodynamic therapy in dermatology: state-of-the-art. *Photodermatol Photo.* (2010). Jun;; 26(3), 118-32.
- [19] Pottler, R, Krammer, B, Baumgartner, R, & Stepp, H. Photodynamic Therapy with ALA: A clinical handbook. first ed. Europa: RCS Publishing; (2006).
- [20] Issa MCAManela-Azulay M. Photodynamic therapy: a review of the literature and image documentation. *An Bras Dermatol.* (2010). Jul-Aug;; 85(4), 501-11.

- [21] Svaasand, L. O, Wyss, P, Wyss, M. T, Tadir, Y, Tromberg, B. J, & Berns, M. W. Dosimetry model for photodynamic therapy with topically administered photosensitizers. *Laser Surg Med.* (1996). , 18(2), 139-49.
- [22] Wilson, B. C, Patterson, M. S, & Lilge, L. Implicit and explicit dosimetry in photodynamic therapy: a new paradigm. *Laser Med Sci.* (1997). Fal,, 12(3), 182-99.
- [23] Wolf, P, Rieger, E, & Kerl, H. Topical Photodynamic Therapy with Endogenous Porphyrins after Application of 5-Aminolevulinic Acid- an Alternative Treatment Modality for Solar Keratoses, Superficial Squamous-Cell Carcinomas, and Basal-Cell Carcinomas. *J Am Acad Dermatol.* (1993). Jan,, 28(1), 17-21.
- [24] Foley, P, Freeman, M, Menter, A, Siller, G, Azhary, R. A, Gebauer, K, et al. Photodynamic therapy with methyl aminolevulinate for primary nodular basal cell carcinoma: results of two randomized studies. *Int J Dermatol.* (2009). Nov,, 48(11), 1236-45.
- [25] Caekelbergh, K, Nikkels, A. F, Leroy, B, Verhaeghe, E, Lamotte, M, & Rives, V. Photodynamic Therapy Using Methyl Aminolevulinate in the Management of Primary Superficial Basal Cell Carcinoma: Clinical and Health Economic Outcomes. *J Drugs Dermatol.* (2009). Nov,, 8(11), 992-6.
- [26] Szeimies, R. M, Ibbotson, S, Murrell, D. F, Rubel, D, Frambach, Y, De Berker, D, et al. A clinical study comparing methyl aminolevulinate photodynamic therapy and surgery in small superficial basal cell carcinoma (8-20 mm), with a 12-month follow-up. *J Eur Acad Dermatol.* (2008). Nov,, 22(11), 1302-11.
- [27] Calzavarapinton, P. G. Repetitive Photodynamic Therapy with Topical Delta-Aminolevulinic-Acid as an Appropriate Approach to the Routine Treatment of Superficial Nonmelanoma Skin Tumors. *J Photoch Photobio B.* (1995). Jul,, 29(1), 53-7.
- [28] Surrenti, T, & De Angelis, L. Di Cesare A, Fargnoli MC, Peris K. Efficacy of photodynamic therapy with methyl aminolevulinate in the treatment of superficial and nodular basal cell carcinoma: an open-label trial. *Eur J Dermatol.* (2007). Sep-Oct,, 17(5), 412-5.
- [29] Horn, M, Wolf, P, Wulf, H. C, Warloe, T, Fritsch, C, Rhodes, L. E, et al. Topical methyl aminolaevulinate photodynamic therapy in patients with basal cell carcinoma prone to complications and poor cosmetic outcome with conventional treatment. *Brit J Dermatol.* (2003). Dec,, 149(6), 1242-9.
- [30] Scola, N, Terras, S, Georgas, D, Othlinghaus, N, Matip, R, Pantelaki, I, et al. A randomized, half-side comparative study of aminolevulinate photodynamic therapy versus CO(2) laser ablation in immunocompetent patients with multiple actinic keratoses. *Br J Dermatol.* (2012). Jun 18.
- [31] Rhodes, L. E, De Rie, M, Enstrom, Y, Groves, R, Morken, T, Goulden, V, et al. Photodynamic therapy using topical methyl aminolevulinate vs surgery for nodular basal

- cell carcinoma- Results of a multicenter randomized prospective trial. *Arch Dermatol.* (2004). Jan; 140(1), 17-23.
- [32] Cosgarea, R, Susan, M, Crisan, M, & Senila, S. Photodynamic therapy using topical aminolaevulinic acid vs. surgery for basal cell carcinoma. *J Eur Acad Dermatol.* (2012). no-no., 5.
- [33] Basset-seguin, N, Ibbotson, S. H, Emtestam, L, Tarstedt, M, Morton, C, Maroti, M, et al. Topical methyl aminolaevulinate photodynamic therapy versus cryotherapy for superficial basal cell carcinoma: a 5 year randomized trial. *Eur J Dermatol.* (2008). Sep-Oct; 18(5), 547-53.
- [34] Aguilar, M, De Troya, M, Martin, L, Benitez, N, & Gonzalez, M. A cost analysis of photodynamic therapy with methyl aminolevulinate and imiquimod compared with conventional surgery for the treatment of superficial basal cell carcinoma and Bowen's disease of the lower extremities. *J Eur Acad Dermatol.* (2010). Dec; 24(12), 1431-6.
- [35] Fantini, F, & Greco, A. Del Giovane C, Cesinaro AM, Venturini M, Zane C, et al. Photodynamic therapy for basal cell carcinoma: clinical and pathological determinants of response. *J Eur Acad Dermatol.* (2011). Aug; 25(8), 896-901.
- [36] Haller, J. C, Cairnduff, F, Slack, G, Schofield, J, Whitehurst, C, Tunstall, R, et al. Routine double treatments of superficial basal cell carcinomas using aminolaevulinic acid-based photodynamic therapy. *Brit J Dermatol.* (2000). Dec; 143(6), 1270-4.
- [37] Ibbotson, S. H. Adverse effects of topical photodynamic therapy. *Photodermatol Photo.* (2011). Jun; 27(3), 116-30.
- [38] Wolfe, C. M, Hatfield, K, & Cognetta, A. B. Jr. Cellulitis as a postprocedural complication of topical 5-aminolevulinic acid photodynamic therapy in the treatment of actinic keratosis. *J Drugs Dermatol.* (2007). May; 6(5), 544-8.
- [39] Morton, C. A, Whitehurst, C, Mccoll, J. H, & Moore, J. V. MacKie RM. Photodynamic therapy for large or multiple patches of Bowen disease and basal cell carcinoma. *Arch Dermatol.* (2001). Mar; 137(3), 319-24.
- [40] Willey, A, Mehta, S, & Lee, P. K. Reduction in the Incidence of Squamous Cell Carcinoma in Solid Organ Transplant Recipients Treated with Cyclic Photodynamic Therapy. *Dermatol Surg.* (2010). May; 36(5), 652-8.
- [41] Rowe, D. E, Carroll, R. J, & Day, C. L. Long-Term Recurrence Rates in Previously Untreated (Primary) Basal-Cell Carcinoma- Implications for Patient Follow-Up. *J Dermatol Surg Onc.* (1989). Mar; 15(3), 315-28.
- [42] Mosterd, K. Thissen MRTM, Nelemans P, Kelleners-Smeets NWJ, Janssen RLLT, Broekhof KGME, et al. Fractionated 5-aminolaevulinic acid-photodynamic therapy vs. surgical excision in the treatment of nodular basal cell carcinoma: results of a randomized controlled trial. *Brit J Dermatol.* (2008). Oct; 159(4), 864-70.

- [43] Lindberg-larsen, R, Solvsten, H, & Kragballe, K. Evaluation of Recurrence After Photodynamic Therapy with Topical Methylaminolaevulinate for 157 Basal Cell Carcinomas in 90 Patients. *Acta Derm-Venereol.* (2012). , 92(2), 144-7.
- [44] Christensen, E, Mork, C, & Skogvoll, E. High and sustained efficacy after two sessions of topical 5-aminolaevulinic acid photodynamic therapy for basal cell carcinoma: a prospective, clinical and histological 10-year follow-up study. *Brit J Dermatol.* (2012). Jun;, 166(6), 1342-8.
- [45] Christensen, E, Skogvoll, E, Viset, T, Warloe, T, & Sundstrom, S. Photodynamic therapy with 5-aminolaevulinic acid, dimethylsulfoxide and curettage in basal cell carcinoma: a 6-year clinical and histological follow-up. *J Eur Acad Dermatol.* (2009). Jan;, 23(1), 58-66.
- [46] Soler, A. M, Warloe, T, Berner, A, & Giercksky, K. E. A follow-up study of recurrence and cosmesis in completely responding superficial and nodular basal cell carcinomas treated with methyl 5-aminolaevulinate-based photodynamic therapy alone and with prior curettage. *Brit J Dermatol.* (2001). Sep;, 145(3), 467-71.
- [47] Garcia-zuazaga, J, Cooper, K. D, & Baron, E. D. Photodynamic therapy in dermatology: current concepts in the treatment of skin cancer. *Expert Rev Anticanc.* (2005). Oct;, 5(5), 791-800.
- [48] Jori, G, Fabris, C, Soncin, M, Ferro, S, Coppellotti, O, Dei, D, et al. Photodynamic therapy in the treatment of microbial infections: Basic principles and perspective applications. *Laser Surg Med.* (2006). Jun;, 38(5), 468-81.
- [49] Jori, G. Photodynamic therapy of microbial infections: State of the art and perspectives. *J Environ Pathol Tox.* (2006).
- [50] Maisch, T, Szeimies, R. M, Jori, G, & Abels, C. Antibacterial photodynamic therapy in dermatology. *Photoch Photobio Sci.* (2004). , 3(10), 907-17.
- [51] Zeina, B, Greenman, J, Purcell, W. M, & Das, B. Killing of cutaneous microbial species by photodynamic therapy. *Brit J Dermatol.* (2001). Feb;, 144(2), 274-8.