

We are IntechOpen, the world's leading publisher of Open Access books Built by scientists, for scientists

6,900

Open access books available

185,000

International authors and editors

200M

Downloads

Our authors are among the

154

Countries delivered to

TOP 1%

most cited scientists

12.2%

Contributors from top 500 universities



WEB OF SCIENCE™

Selection of our books indexed in the Book Citation Index
in Web of Science™ Core Collection (BKCI)

Interested in publishing with us?
Contact book.department@intechopen.com

Numbers displayed above are based on latest data collected.
For more information visit www.intechopen.com



To Graft or Not to Graft? Evidence-Based Guide to Decision Making in Oral Bone Graft Surgery

Bernhard Pommer¹, Werner Zechner¹, Georg Watzek¹ and Richard Palmer²

¹*Department of Oral Surgery, Vienna Medical University*

²*Department of Restorative Dentistry, King's College London*

¹*Austria*

²*UK*

1. Introduction

Rehabilitation of the incomplete dentition by means of osseointegrated implants represents a highly predictable and widespread therapy. Advantages of oral implant treatment over conventional non-surgical prosthetic rehabilitation involve avoidance of removable dentures and tooth structure conservation of the remaining dentition. Implant placement necessitates sufficient bone quantity as well as bone quality, that may be compromised following tooth loss or trauma. Sufficient alveolar bone to host implants of 10 mm in length and 3-4 mm in diameter has been traditionally regarded as minimum requirements to allow bone-demanding implant placement. Three-dimensional bone morphology, however, may not permit favourable implant positioning. In the age of prosthetic-driven implant treatment, bone grafting procedures may be indicated not exclusively due to lack of bone volume, but to ensure favourable biomechanics and long-term esthetic outcome. A vast variety of treatment modalities have been suggested to increase alveolar bone volume and thus overcome the intrinsic limitations of oral implantology. Although success rates of various bone graft techniques are high, inherent disadvantages of augmentation procedures include prolonged treatment times, raised treatment costs and increased surgical invasion associated with patient morbidity and potential complications. Therefore, treatment tactics to obviate bone graft surgery are naturally preferred by both patients and surgeons. Non-grafting options, such as implants reduced in length and diameter or the use of computer-guided implant surgery, may on the other hand carry the risk of lower predictability and reduced long-term success. To graft or not to graft? – that is the question clinicians are facing day-to-day in oral implant rehabilitation.

Decision making in evidence-based implant dentistry involves diagnostic and therapeutic uncertainties, clinicians' heuristics and biases, patients' preferences and values, as well as cost considerations (Flemmig & Beikler, 2009). The evidence-based approach to oral healthcare emerged during the 1990s and was implemented in therapeutic decision making with the aim of maximizing the potential for successful patient care outcomes. The present book chapter offers an evaluation of implant treatment options in partially and completely edentulous patients to guide clinicians' decision making based on scientific evidence in contemporary literature. Therapeutic alternatives indicated for specific treatment situations

are compiled and indications as well as limitations are outlined. Clinical investigations and systematic reviews comparing alternative bone graft techniques as well as trials comparing bone augmentation to non-grafting options are discussed. To allow for indirect comparison, studies using conventional implants (≥ 10 mm in length) as a reference standard (Griffin & Cheung, 2004) are also embraced. The highest level of evidence supporting therapeutic decisions is given using the Oxford 2011 Levels of Evidence classification system (Table 1). However, no down- or upgrading due to methodological study quality was performed, as the system was primarily used to indicate the presence (or absence) of (randomized) controlled trials on various treatment options.

LoE	Study design
1	Systematic review of randomized trials or n-of-1 trials
2	Randomized trial or observational study with dramatic effect
3	Non-randomized controlled cohort/follow-up study
4	Case-series, case-control studies, or historically controlled studies
5	Mechanism-based reasoning

Table 1. Level of evidence (LoE) classification system for treatment benefits according to the Oxford Centre for Evidence-Based Medicine (Howick et al., 2011)

Evidence on treatment options involving bone graft surgery was gained from recent systematic reviews and meta-analyses (Aghaloo & Moy, 2007; Att et al., 2009; Bernstein et al., 2006; Chao et al., 2010; Chiapasco et al., 2006, 2009; Donos et al., 2008; Emmerich et al., 2005; Esposito et al., 2009, 2010; Graziani et al., 2004; Jensen & Terheyden, 2009; Pjetursson et al. 2008; Rochietta et al., 2008; Stellingsma et al., 2004; Tan et al., 2008; Waasdorp & Reynolds, 2010) and supplemented by an electronic MEDLINE literature search (last search on 1st August 2011). Likewise, evidence on non-grafting treatment alternatives, i.e. short, tilted or zygomatic implants, was sought (Aparicio et al., 2008; Att et al., 2009; Del Fabbro et al., 2010; Esposito et al., 2005; Hagi et al., 2004; Jung et al., 2009; Kotosovilis et al., 2009; Pommer et al., 2011; Renouard & Nisand, 2006; Stellingsma et al., 2004).

2. Surgical techniques

This chapter addresses the six types of alveolar ridge augmentation: onlay block grafts, guided bone regeneration, sinus floor elevation, distraction osteogenesis, interpositional grafts and alveolar ridge expansion. As the present manuscript focuses on reconstruction of vertical or horizontal alveolar deficiencies, augmentation of post-extraction sockets (ridge preservation) and bone regeneration around immediate implants or implants presenting with bone defects following peri-implantitis are not included. Subsequently, surgical techniques to avoid oral bone graft surgery are covered: short implants, parasinus al tilted implants, zygomatic implants and alveolar nerve transposition.

2.1 Onlay block grafts

Onlay bone grafts are used for external augmentation of horizontal (veneer graft) or vertical alveolar ridge deficiencies, as well as combined defects (saddle graft). Compression screws are placed to fix bone blocks to the residual alveolar crest, that should be extensively

perforated to increase blood supply to the host-graft interface (Lundgren et al., 2008). While autogenous bone is generally harvested from intra- or extraoral donor sites, the potential of allogeneic bone for onlay block grafts has also been documented (Waasdorp & Reynolds, 2010). Simultaneous implant placement can be an option only in vertical grafts, with the implants acting as osteosynthesis screws, and may carry the potential of shortening the healing phase (Chiapasco et al., 2006). The drawbacks, however, involve unpredictable graft resorption, higher risk of wound dehiscence and osseointegration failure, lower values of bone-to-implant contact and compromised implant position, thereby making the one-step procedure undesirable from a prosthetic point of view (Stellingsma et al., 2004). Implant survival and peri-implant bone levels have shown no significant differences following onlay block grafting compared to implants in native jawbone (LoE-4), however, these data include both horizontal and vertical grafts (Sbordone et al., 2009). A mean increase in horizontal and vertical dimension of 4.4 mm and 3.7 mm has been reported (Jensen & Terheyden, 2009) with rates of graft resorption of 10-50% (Chiapasco et al., 2009) and 29-42% (Bernstein et al., 2006), respectively (Figure 1a), dependent on the choice of bone harvest site. Complications involve wound dehiscence and total graft loss (Figure 1b) in 3.3% and 1.4%, respectively (Chiapasco et al., 2009). Controversy over the inclusion of barrier membranes to cover onlay grafts occurs from their potential negative effects in the event of wound dehiscence, as membrane exposure may result in passage of infectious agents along the membrane into the healing site (Bernstein et al., 2006). As true for all techniques of external bone augmentation, incidence of dehiscences is related to the ability to provide tension-free primary flap closure in cases of significant addition of graft volume.

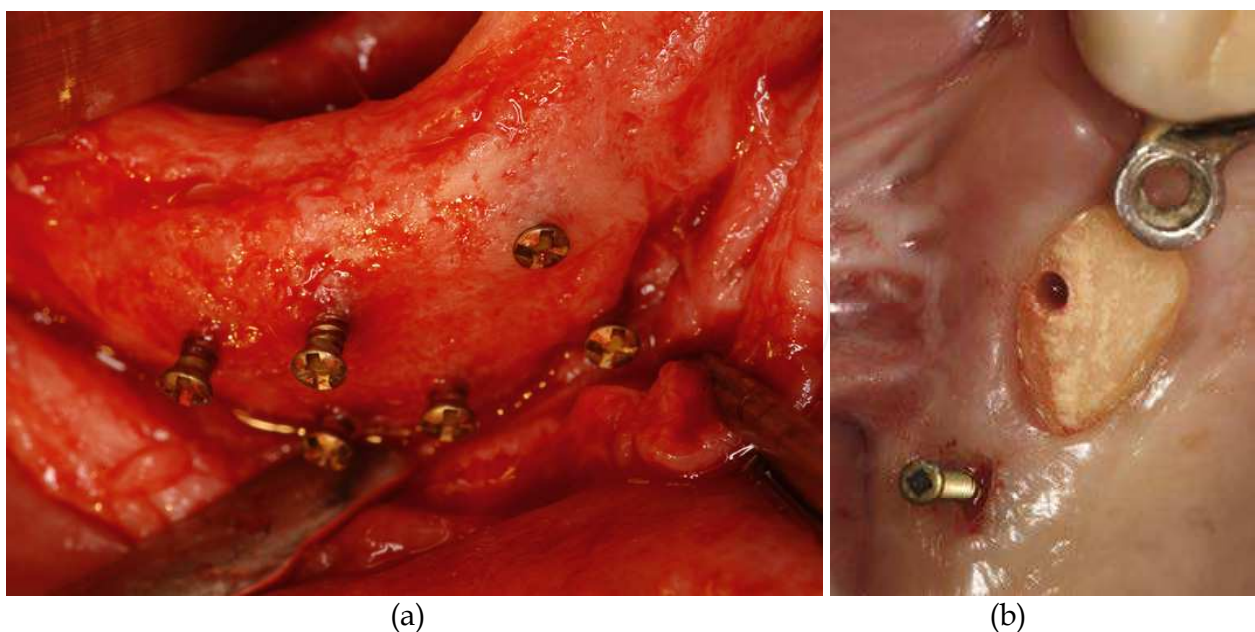


Fig. 1. Onlay block grafts: amount of graft resorption can be seen on fixation screws (a), graft loss following wound dehiscence (b) [pictures by Georg Watzek* and Thomas Bernhart*]

2.2 Guided bone regeneration

The concept of guided bone regeneration implies the use of cell-occlusive membranes for space provision over a vertical or horizontal defect, promoting the ingrowth of osteogenic cells while preventing migration of undesired cells from the overlying soft tissue (Block & Haggerty, 2009). Space maintenance by various particulate graft materials and the use of resorbable (Figure 2), non-resorbable as well as titanium-reinforced membranes has been described, while no indications regarding the choice of simultaneous vs. delayed implant placement have yet been defined (Chiapasco et al., 2006). No differences in implant survival rates following guided bone regeneration could be found (LoE-3) compared to implants in native jawbone, while observed significant differences in marginal bone resorption (1.4 mm vs. 1.2 mm) may not be of clinical relevance (Zitzmann et al., 2001). Mean increase in horizontal and vertical dimensions of 2.6 mm and 3.6 mm, respectively, has been reported (Jensen & Terheyden, 2009) with up to 40% of initial bone gain undergoing resorption thereafter (Chiapasco et al., 2009). Failures are mainly related to premature membrane exposure that has been seen in up to 38% of cases (Block & Haggerty, 2009) and may lead to infection and eventually partial or total loss of regenerated bone.

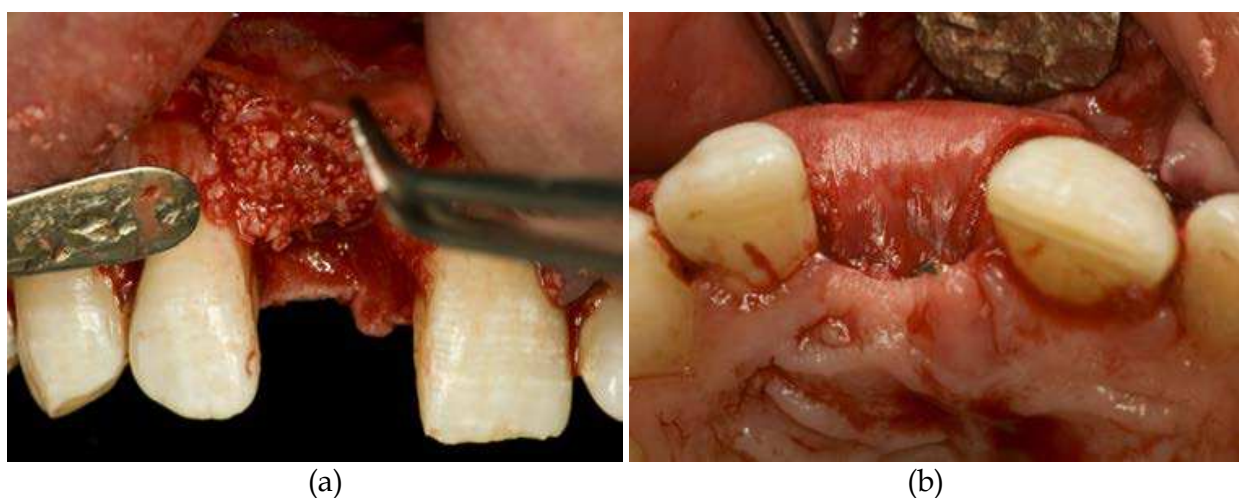


Fig. 2. Guided bone regeneration in the anterior maxilla using particulate graft material (a) and a resorbable membrane to increase horizontal ridge width (b) [pictures by Thomas Bernhart*]

2.3 Sinus floor elevation

Internal augmentation of the maxillary sinus to compensate for sinus pneumatization is based on the principle of guided bone regeneration using the sinus membrane as a natural barrier. Bone formation to allow osseointegration of delayed or simultaneously placed implants is initiated by coronal displacement of the maxillary sinus membrane with or without addition of bone (substitute) material. Membrane elevation is accomplished either via the lateral sinus wall (Figure 3), as described by Boyne in the 1960s, or via a transcrestal approach to the antrum, as described by Summers in the 1990s (Pjetursson et al., 2008). No significant difference in implant survival (LoE-3) could be found in sinus grafted bone vs. native jawbone (Graziani et al., 2004). The most frequent complication is the iatrogenic perforation of the sinus membrane in 10-20% of lateral approaches on average (Chiapasco et al., 2009; Pjetursson et al., 2008). Lateral sinus grafting can, however, be completed in a vast

majority of cases by closing the perforation with resorbable materials. The main disadvantages of transcresal elevation techniques are the uncertain diagnosis of membrane perforations and the lack of possibilities of repair (Pommer et al., 2009). Significantly greater bone graft heights (11.8 mm vs. 3.5 mm, 79 patients, LoE-3) have been obtained using the lateral vs. transcresal approach (Zitzmann & Schärer, 1998), yet recent modifications to the osteotome-technique, such as membrane elevation by inflation of a balloon catheter and the use of hydraulic or gel pressure, have shown the potential to accomplish greater elevation heights despite the minimally invasive approach (Pommer & Watzek, 2009). Postoperative sinusitis may occur at a mean rate of 3% and 1% following lateral and transcresal augmentation, respectively (Pjetursson et al., 2008; Tan et al., 2008). Spread of infection to intracranial structures via the cavernous sinus is a rare yet serious complication. Total graft loss has been recorded at a mean rate of 2% in lateral sinus floor augmentation (Pjetursson et al. 2008).

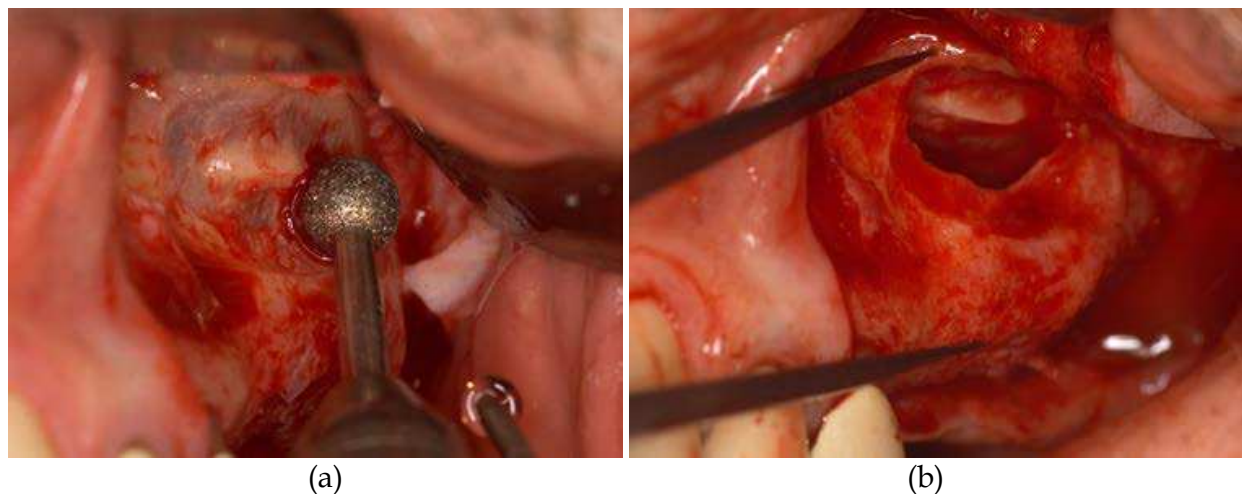


Fig. 3. Sinus floor augmentation via a lateral approach (a) to gain sufficient bone height (b) for implant placement in the posterior maxilla [pictures by Werner Zechner*]

2.4 Distraction osteogenesis

Distraction osteogenesis relies on the biologic phenomenon that new bone fills in the gap defect created when two bone segments are slowly separated under tension. One week after osteotomy and distractor placement (latency period) distraction of segments is advanced at a rate of 0.5-1 mm per day until the desired separation is reached (Figure 4). A consolidation period of 5 days per mm space created should be respected before device removal and implant placement (Bernstein et al., 2006). Despite inherent disadvantages (need for daily activation, compromised speech, eating and appearance) the procedure offers unique possibilities: vertical bone gain of 3-20 mm may be accomplished without the use of graft material and additional mucosal grafting is obviated as the soft tissue follows bone distraction (Chiapasco et al., 2006). However, complications include partial relapse of initial bone height (8%), change of distraction vector (8%), basal bone or segment fracture (3%), fracture of distraction device (2%), incomplete distraction (2%), transient paresthesia (2%) and total failure in 1% of cases on average (Chiapasco et al., 2009). Distraction osteogenesis does generally not allow correction of narrow ridges, which may only be possible by overdistracting of the segment and secondary height reduction until adequate bone width is

obtained. Overcorrection may, however, give rise to surrounding tissue tears or ischemia (Bernstein et al., 2006).

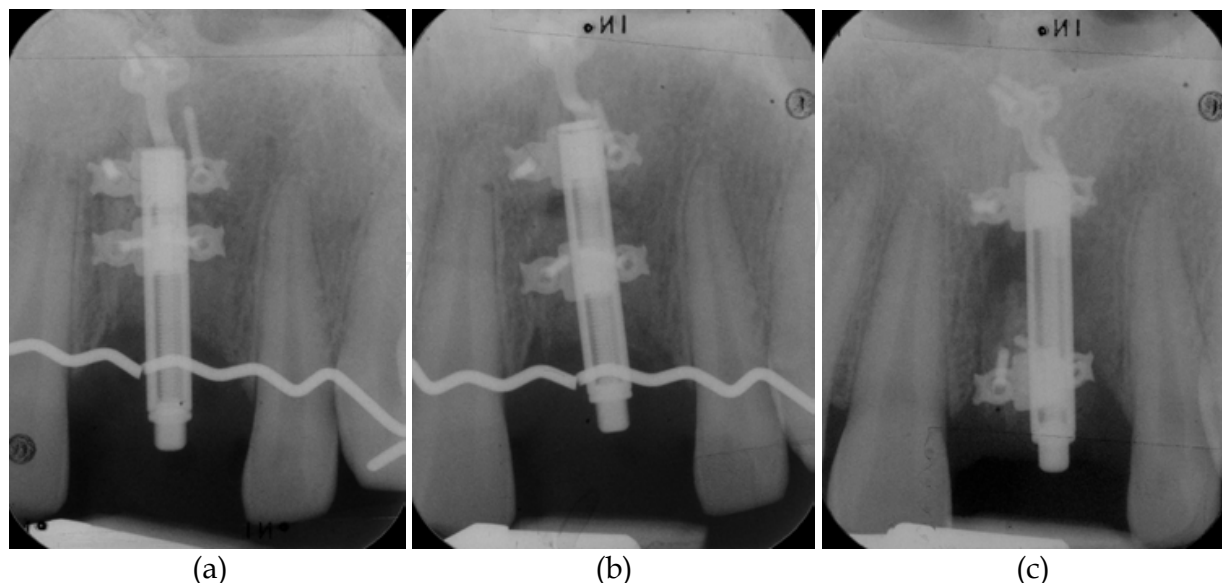


Fig. 4. Distraction osteogenesis in the anterior maxilla: (a) latency phase after distractor placement, (b) distraction phase, (c) consolidation phase after desired separation is reached [pictures by Georg Watzek* and Thomas Bernhart*]

2.5 Interpositional grafts

Just as distraction osteogenesis, interpositional bone grafts (also known as sandwich grafts) are exclusively used for treatment of vertical defects (Block & Haggerty, 2009). By contrast, the osteotomized bone segment is not distracted but initially secured in its final position using osteosynthesis plates. Surgical techniques in the mandible (frequently using bone substitute materials to augment the gap) show large differences to those in the edentulous maxilla, where interpositional autologous grafts are placed after Le Fort I osteotomy and maxillary down-fracture (Chiapasco et al., 2006). Wound dehiscences in 4% of mandibular grafts compare to overall complication rates of up to 10% following Le Fort I osteotomies in the maxilla including postoperative sinusitis (3%), wound dehiscence (3%), partial graft loss (3%), midpalatal fracture (2%) and total graft failure in 1% on average (Chiapasco et al., 2009). Rare complications involve massive hemorrhage and blindness. Due to unpredictable bone resorption and plate removal at implant placement, one-stage procedures are generally not preferred in both maxillary and mandibular interpositional grafting (Att et al., 2009).

2.6 Alveolar ridge expansion

Alveolar ridge expansion (also known as bone splitting technique) represents the horizontal equivalent to vertical distraction or interpositional grafting. Following crestal osteotomy the buccal cortex is gently expanded against the lingual plate using osteotomes of increasing diameters to allow implants to be placed in between (Figure 5). The residual gap created may be filled with graft material but seems to undergo spontaneous ossification (Chiapasco

et al., 2006). Bone splitting of knife-edge ridges is only possible if the buccal and lingual cortices are separated by spongy bone. Gain in horizontal bone width has been found to average 4 mm (Holzclaw et al., 2010) while malfracture of the buccal plate has been reported in 4-22% of cases (Sohn et al., 2004; Jensen et al., 2009). Due to the lower bone density and thinner cortical plates success rates may certainly be higher in the maxilla. No significant differences (LoE-4) in implant survival and peri-implant bone levels have been observed following alveolar ridge expansion compared to conventional implant placement (Danza et al., 2009), however, there is a paucity of data with regard to the stability of initial bone volume as well as marginal bone resorption in reaction to the surgical trauma of expansion.

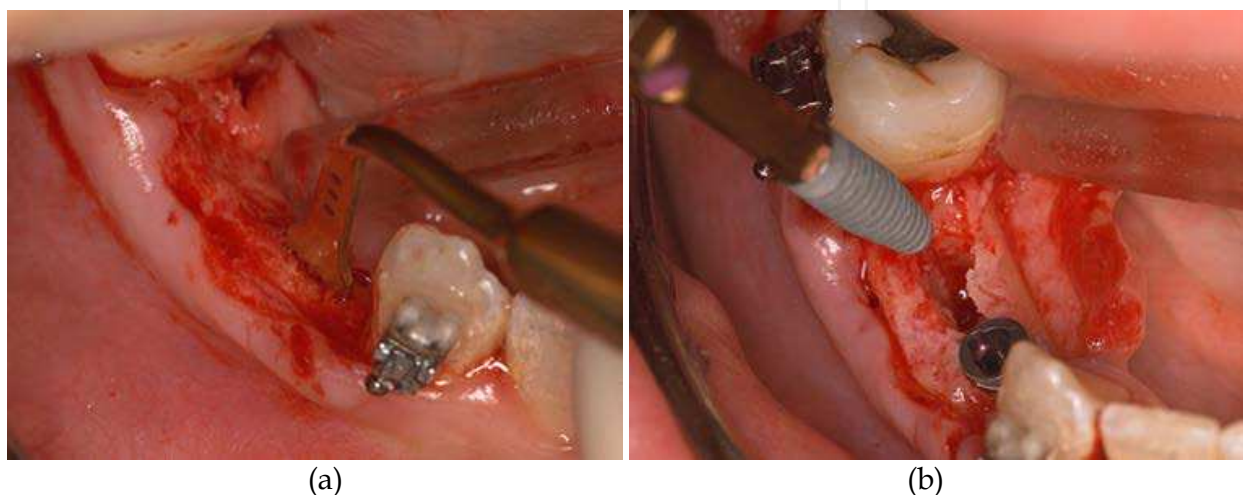


Fig. 5. Alveolar ridge expansion in the posterior mandible: (a) crestal osteotomy using piezoelectric saw, (b) implant placement following ridge splitting [pictures by Dieter Busenlechner*]

2.7 Short implants

It has been an axiom in implant dentistry that longer implants guarantee lower failure rates, although a linear relationship between implant length and success has never been proven. While conventional dental implants of at least 10 mm in length are considered the reference standard of implant therapy (Griffin & Cheung, 2004) positive clinical results with shorter implants have increased the interest in this promising technique to avoid invasive bone graft surgery. Strategies to increase the surface area of short implants include the use of rough-surfaced implants and wider implant diameters, however, literature results support the hypothesis that implant diameter increase can not compensate for length reduction (Maló et al., 2007; Pommer et al., 2011). Short implants may be splinted to each other and/or longer implants in fixed partial dentures to enhance force distribution. A tendency of short implant failures to occur within the first year of prosthetic loading has been observed (das Neves et al., 2006) and long-term effects of peri-implant bone resorption may also differ significantly and require investigation. Meta-analyses of observational studies (LoE-3) did not reveal differences between short (7-9 mm) and conventional (≥ 10 mm) rough-surfaced implants regarding their survival (Kotsovilis et al., 2009) as well as one-year success rates (Pommer et al., 2011).

2.8 Parasinusal tilted implants

One way to avoid short implants as well as bone graft surgery is the use of tilted implants, i.e. implants with an inclination greater than 15° (up to 35°) towards the occlusal plane (Friberg, 2008). No difference (LoE-3) in early failure rates and marginal bone resorption could be found between tilted and axial implants (Del Fabbro et al., 2010). Implants in the anterior maxilla as well as pterygoid implants in the maxillary tuberosity may both be tilted (Figure 6a) to avoid the sinus cavity and allow for greater implant lengths without bone augmentation. Parasinusal tilting may further reduce the length of cantilever segments thus improving biomechanic load distribution (Block & Haggerty, 2009). With guided implant surgery, the placement of tilted implants has become not only easier and less invasive from a surgical point of view (Att et al., 2009) but also more efficient and predictable from the prosthetic viewpoint (Figure 6b). The introduction of computed tomography, implant planning software and CAD/CAM technology have undoubtedly been important achievements to provide optimal 3D implant positioning with respect to both prosthetic and anatomical parameters (Jung et al., 2009).

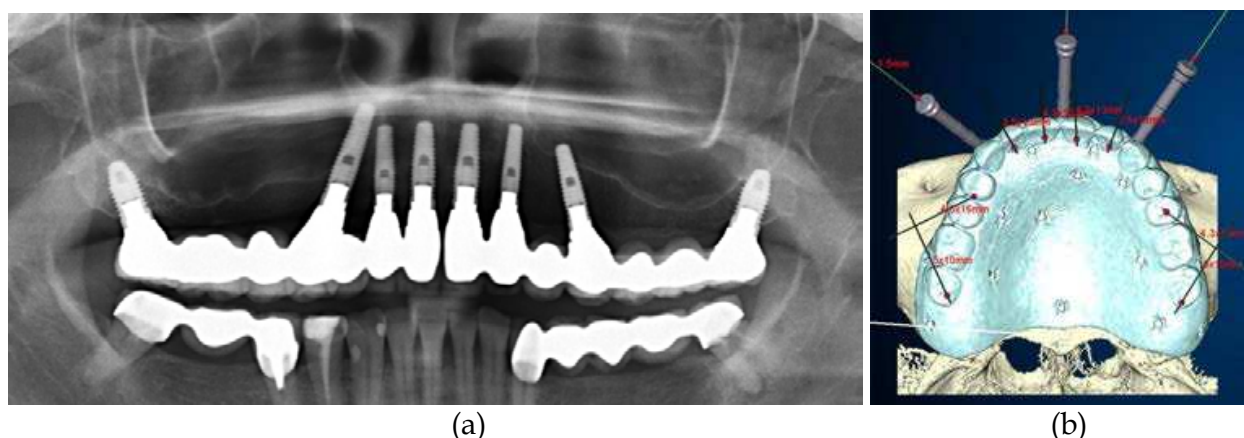


Fig. 6. Parasinusal placement of tilted implants in the atrophic maxilla (a) using CT-based implant treatment planning software (b) [pictures by Werner Zechner*]

2.9 Zygomatic implants

Zygomatic implants have mainly been used in the rehabilitation of severely resorbed or partially resected maxillae in combination with premaxillary implants as an alternative to bone grafting (Friberg, 2008). Complications involve postoperative sinusitis in up to 14% of cases as well as temporary paresthesia, epistaxis, facial and periorbital hematoma and orbital penetration (Block & Haggerty, 2009). While palatal emergence (up to 12 mm medial to the ridge) is frequent with zygomatic implants and may cause prosthetic difficulties (Att et al., 2009), their generally posterior position has been shown to cause problems with oral hygiene. Peri-implant bleeding, soft tissue hyperplasia and increased pocket depths have been recorded in up to 45% of cases (Aparicio et al., 2008) and may result in oroantral fistula formation and subsequent maxillary sinusitis (Figure 7). Recent developments such as extrasinusal placement and the use of CT-based surgical stents may help to overcome these problems, however, it should be considered that mean angular deviations of 4° using mucosa-supported templates (Jung et al., 2009; Vasak et al., 2011) may result in significantly higher imprecision at the apex of 30 to 55 mm long implants.

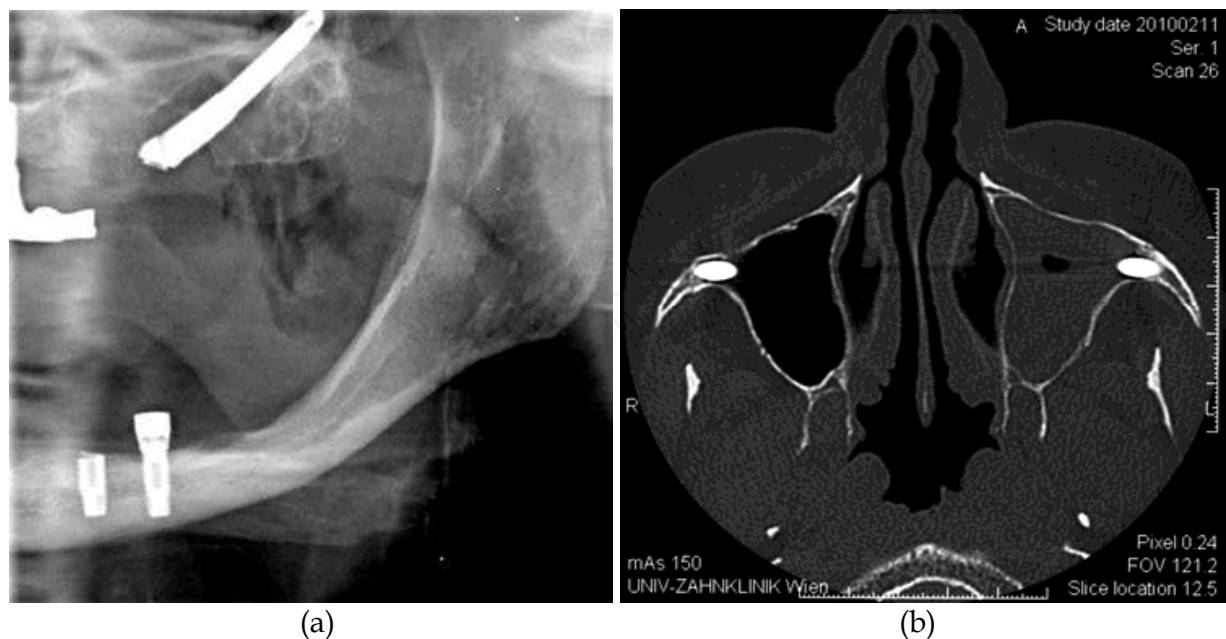


Fig. 7. Marginal bone loss around zygomatic implants (a) may lead to oroantral fistula formation and subsequent maxillary sinusitis (b) [pictures by Georg Watzek*]

2.10 Alveolar nerve transposition

Transposition of the inferior alveolar nerve consists of exposing the neurovascular bundle from a lateral approach with its release from the mandibular canal, and repositioning it laterally, allowing implants to be placed as far as the inferior border of the mandible (Block & Haggerty, 2009). Drawbacks of this procedure include a high incidence of neurosensory disturbances of up to 90%, risk of mandibular fracture and increased crown lengths associated with compromised implant esthetics (Chrcanovic & Custódio, 2009).

2.11 Comparison of surgical techniques

Table 2 provides an overview of implant survival, augmentation success and complication rates of bone graft techniques and non-grafting options reported in contemporary literature. On the basis of between-study comparison, however, it is difficult to demonstrate that one particular surgical procedure offers superior outcomes (Chiapasco et al., 2006). It remains doubtful whether any strong evidence to support treatment decisions may be produced by non-comparative follow-up investigations, that oral implant research has focused on during the last decades.

Post-extraction alveolar ridge resorption follows a predictable pattern (Cawood & Howell, 1988) changing its shape from high-well-rounded (generally not requiring bone grafts), to knife-edged (corrected by horizontal augmentation) and low-well-rounded ridges (calling for vertical grafts). It is essential to consider the initial clinical situation in this comparison, as horizontal bone grafts have been shown to be more predictable (Bernstein et al., 2006) and no surgical technique suits any given defect. Significantly greater horizontal bone gain has been reported using onlay block grafts (4.0 mm vs. 2.7 mm, 30 patients, LoE-3) vs. guided bone regeneration (Chiapasco et al., 1999). Augmentation of vertical bone height using

distraction osteogenesis has been demonstrated to yield significantly lower graft resorption prior to implant placement (0.3 mm vs. 0.6 mm, 17 patients, LoE-2) vs. onlay grafts (Chiapasco et al., 2007) as well as significantly higher implant success and lower marginal bone resorption (93% vs. 64%, 1.4 mm vs. 1.9 mm, 21 patients, LoE-2) vs. guided bone regeneration (Chiapasco et al., 2004).

Treatment option	Mean implant survival rate	Mean gain in height/width	Mean graft resorption	Mean rate of complications
Onlay block graft	89% (60-100)			
horizontal	99% (97-100)	5 mm	22%	4%
vertical	85% (76-100)	4 mm	38%	30%
Guided bone regeneration	96% (77-100)			
horizontal	98% (77-100)	3 mm	14%	40%
vertical	98% (92-100)	4 mm	n.d.	21%
Lateral sinus floor elevation	95% (60-100)	12 mm	17%	25%
Transcrestal sinus floor elevation	96% (83-100)	4 mm	18%	5%
Distraction osteogenesis	96% (88-100)	7 mm	11%	25%
Le Fort I + interpositional graft	88% (60-95)	n.d.	n.d.	12%
Mandibular interpositional graft	92% (90-95)	6 mm	13%	4%
Alveolar ridge expansion	94% (91-97)	4 mm	14%	19%
Short implants	97% (74-100)	no graft	no graft	no complications
Paranasal tilted implants	98% (89-100)	no graft	no graft	no complications
Zygomatic implants	98% (82-100)	no graft	no graft	14%
Alveolar nerve transposition	93% (88-100)	no graft	no graft	23%

Table 2. Results of systematic reviews reporting on treatment outcomes of various bone graft techniques and non-grafting options (n.d. = no data).

It does, however, seem problematic to compare implant success following different surgical techniques if both maxillary and mandibular sites are included. As conventional implants (≥ 10 mm) in native jawbone show diverging failure rates in the anterior maxilla (2.1% [CI^{95%} 1.7-2.7], n=3607), posterior maxilla (2.5% [CI^{95%} 2.0-3.0], n=4039), anterior mandible (1.1% [CI^{95%} 0.9-1.4], n=5797) and posterior mandible (1.7% [CI^{95%} 1.4-2.1], n=5640) even after 1 year of prosthetic loading (Pommer et al., 2011), it should be considered that regional differences may very well exist in grafted bone. Selection of the appropriate surgical technique should not only be based on the location in the mouth (Aghaloo & Moy, 2007) but also on complete vs. partial edentulous patient situations. The next two chapters discuss evidence on treatment decisions in complete and partial edentulism. Treatment alternatives based on the shortened arch concept, cantilever or implant/tooth-supported bridges and subperiosteal or transosteal implants are not embraced. Trials comparing different bone (substitute) materials, types of barrier membranes or fixation screws, simultaneous vs. delayed implant placement, implant macro- and microstructure, loading protocols or types of prosthetic restorations as well as uncontrolled studies are given insufficient attention.

3. Bone grafting in complete edentulism

The main goal of implant treatment in edentulous patients is to provide either fixed full-arch bridges or retention and stability to their removable dentures. Both approaches may require bone graft surgery, however, various factors such as patient age and health, surgical hazard and opposing dentition should be considered. Implant-supported rehabilitation may, on the other hand, prevent further alveolar ridge resorption and not only improve oral health and patient satisfaction, but also patients' nutritional status and quality of life in general. Nongrafting options may generally be preferred in cases of previous graft failure, general medical contraindications to bone graft surgery or to avoid maxillary sinus floor elevation in patients with prominent sinus septa or a history of chronic sinusitis.

3.1 Treatment options in the edentulous maxilla

In the severely atrophic edentulous maxilla, centripetal alveolar resorption, the presence of maxillary sinuses, nasal fossa and incisive foramen, along with low bone quality, complicate implant treatment. Insufficient bone height may be related to vertical resorption of the alveolar ridge, sinus pneumatization, or a combination of both. In cases of severe increase in interarch distance, external rather than internal bone augmentation may be indicated to avoid compromised crown-to-implant ratios as well as unfavourable deviation of implant positions towards the palate (Chiapasco et al., 2006). Treatment options in the edentulous maxilla involve onlay block grafts, guided bone regeneration, lateral sinus floor elevation, interpositional grafts in combination with Le Fort I osteotomy, parasinusal tilting and zygomatic implants (Table 3), however, a combination of graft techniques may at times be necessary to optimize implant placement from a functional and esthetic point of view (Chiapasco et al., 2006). Lateral cephalograms should be taken with the removable dentures in place in order to determine jaw relationship and estimate proper lip support (Lundgren et al., 2008). Le Fort I osteotomy may be indicated in patients with a markedly reverse jaw relationship and severe vertical deficiency, while onlay grafts may be preferred if an inverted jaw relationship is combined with a knife-edge ridge (Att et al., 2009). Grafting of the nasal floor combined with onlay blocks may be indicated in case of short vertical height of the anterior maxilla (Lundgren et al., 2008). Due to relevant patient morbidity interpositional grafts should be limited to severe cases, in which other techniques are not able to re-establish an acceptable intermaxillary relationship (Att et al., 2009). No significant difference (LoE-3) regarding implant survival could be seen following onlay block grafts vs. lateral sinus floor elevation (Wiltfang et al., 2005) as well as vs. interpositional grafts in conjunction with Le Fort I osteotomy (Lundgren et al., 2008). No significant differences (LoE-3) in bone-to-implant contacts and newly formed bone around microimplants retrieved 6-14 months after onlay vs. interpositional grafting were observed (Sjöström et al., 2006). To date, no information is available on the outcome of short implants or transcrestal sinus floor elevation in the edentulous maxilla (Att et al., 2009). No controlled studies on guided bone regeneration, zygomatic implants and parasinusal tilted implants could be identified.

3.2 Treatment options in the edentulous mandible

The atrophic edentulous mandible, by contrast, may predominantly present conditions that are compatible with implant placement. Avoidance of bone augmentation has even been suggested as long as the intraforaminal region is more than 5 mm in height and at least 6

mm in width (Keller, 1995). Bone augmentation should be limited to severely atrophic cases with the risk of fatigue mandibular fracture (Chiapasco et al., 2009). Treatment options for vertical heights <10 mm involve onlay block grafts (Figure 8), guided bone regeneration, distraction osteogenesis, interpositional grafts as well as short implants (Table 4). No significant difference (LoE-3) in early implant failure (OR 0.7 [CI^{95%} 0.2-2.4]) could be found between short (7-9 mm) and conventional (≥ 10 mm) rough-surfaced implants (Pommer et al., 2011). Significantly lower implant success (LoE-3) and more negative experience of the surgical phase was seen in interpositional grafts of the interforaminal region vs. short implants (Stellingsma et al., 2003), yet 30% of these implants were 11 mm in length and may thus not be regarded as short. No controlled studies on any other bone graft techniques could be identified.

Bone graft treatment options	Indications & Limitations	LoE
Onlay block graft	No inherent limitations	3
Guided bone regeneration	No inherent limitations	4
Lateral sinus floor elevation	No inherent limitations	3
Le Fort I + interpositional graft	Limited to severe atrophy or intermaxillary discrepancy	3
Nongrafting treatment options	Indications & Limitations	LoE
Parasinusal tilted implants	Limited by residual bone volume in premaxillary and retromolar regions	4
Zygomatic implants	Placed in conjunction with premaxillary implants	4

Table 3. Treatment options in the edentulous maxilla

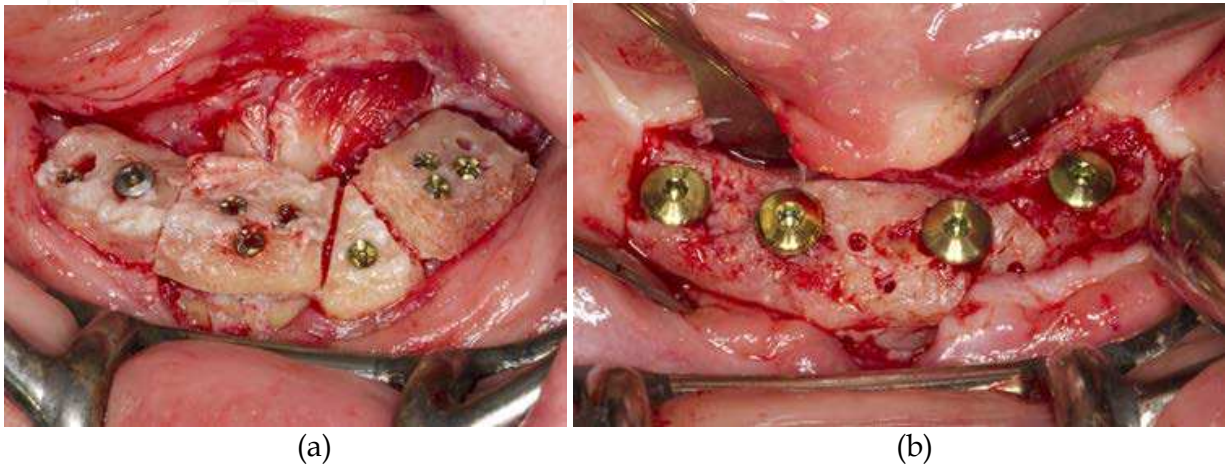


Fig. 8. Onlay bone grafting of the edentulous mandible (a) to facilitate interforaminal implant placement (b) [pictures by Markus Hof* and Gabriella Eisenmenger*]

Bone graft treatment options	Indications & Limitations	LoE
Onlay block graft	No inherent limitations	4
Guided bone regeneration	No inherent limitations	4
Distraction osteogenesis	Limited to a minimum residual bone height of 6 mm in the presence of residual alveolar width of at least 4 mm	4
Interpositional graft	Limited to a minimum residual bone height of 6 mm in the presence of residual alveolar width of at least 4 mm	3
Nongrafting treatment options	Indications & Limitations	LoE
Short implants	Indicated in cases of at least 5-7 mm bone height	3

Table 4. Treatment options in the edentulous mandible

4. Bone grafting in partial edentulism

In contrast to completely edentulous jaws, partial edentulism presents with a vast variety of dentition patterns including single-tooth and intermediate gaps as well as posterior free-end situations. Treatment decisions are therefore more complex and non-surgical alternatives may involve non-removable restorations such as fixed partial dentures, cantilever and resin-bonded bridges. Just by their presence, residual teeth may sometimes complicate treatment planning in cases of partial edentulism (Friberg, 2008). Depending on their periodontal and general condition, exceptional extraction of the residual dentition and thus transformation of partial into complete edentulism may at times prove advantageous in terms of avoiding bone graft surgery or even lowering treatment costs.

4.1 Deficient anterior maxillary sites

Bone resorption in the anterior maxilla following tooth loss occurs early (50% during the first 12 months) but mainly in the horizontal direction with most of the bone loss on the buccal aspect (Att et al., 2009). Treatment options for horizontal deficiencies involve onlay block grafts, guided bone regeneration and alveolar ridge expansion (Table 5). No significant differences (LoE-2) regarding implant survival, marginal gingiva and bone levels as well as implant esthetics (Meijndert et al., 2007) could be found between onlay block grafts vs. guided bone regeneration. Bone biopsies at implant placement revealed no differences in total bone volume and marrow connective tissue volume (Meijndert et al., 2005). No controlled study on alveolar ridge expansion in anterior maxillary sites could be identified.

Bone graft treatment options	Indications & Limitations	LoE
Onlay block graft	No inherent limitations	2
Guided bone regeneration	No inherent limitations	2
Alveolar ridge expansion	Limited to a minimum residual bone width of 4 mm	4

Table 5. Treatment options for horizontal deficiency of the anterior maxilla

In less frequent cases requiring vertical bone augmentation onlay block grafts, guided bone regeneration and distraction osteogenesis may be considered. Additional soft tissue grafts may be obviated by the use of distraction osteogenesis (Figure 9), however, ridge defects of only 1 or 2 teeth in width have been associated with higher complication rates (Jensen et al., 2002). No controlled studies on any treatment option could be identified. Short implants do not seem to represent a good option in the anterior maxilla, as increased crown lengths lead to significantly compromised implants esthetics (Chiapasco et al., 2009). Enlarged incisive foramina may at times require grafting prior to implant placement in central maxillary incisor positions (Ragheobar et al., 2010).

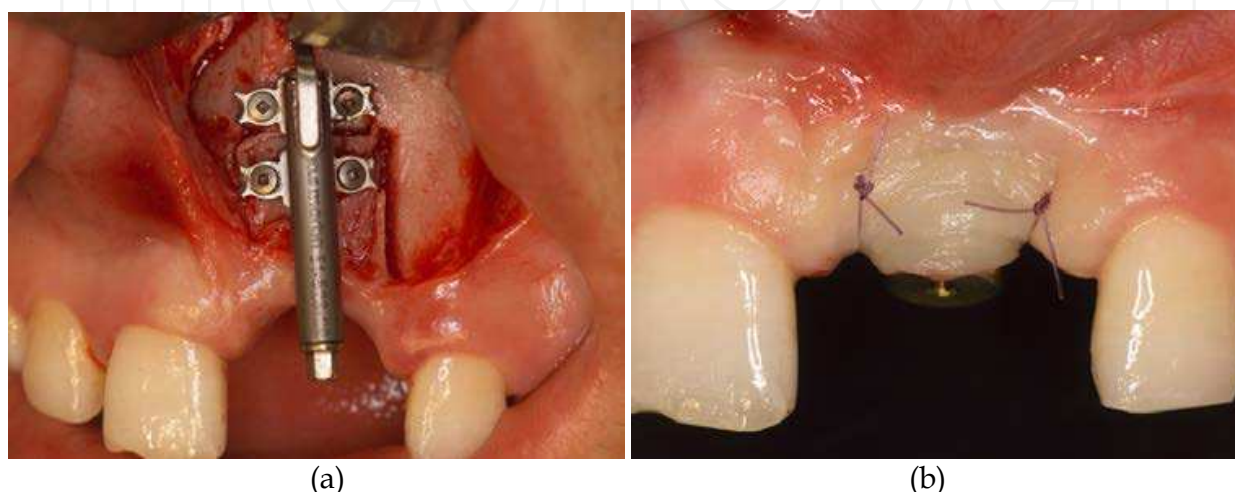


Fig. 9. Distraction osteogenesis in the vertically deficient anterior maxilla (a) to avoid additional soft tissue grafting (b) [pictures by Georg Watzek* and Thomas Bernhart*]

4.2 Deficient posterior maxillary sites

While horizontal defects are predominant in the anterior maxilla, the partial edentulous posterior maxilla presents with sufficient subantral bone width of 6 mm on average (Att et al., 2009) but residual alveolar ridge heights of less than 5 mm in 43% of cases (Lundgren et al., 1996). While short implants may not be an option in these cases, there is no evidence to recommend a minimum bone height that would contraindicate lateral or transcrestal sinus floor elevation (Chiapasco et al., 2009). Meta-regression revealed a significant trend of less implant failures in greater bone heights following lateral sinus floor elevation (Chao et al., 2010). No effect could be seen in transcrestal techniques (due to the lack of data below 4 mm), however, a minimum height of 4-6 mm is generally suggested (Tan et al., 2008). It is difficult to evaluate whether the support is offered by the graft or the native jawbone, when comparing survival rates in sinus grafted bone to those of short implants (Chiapasco et al., 2006). No significant difference (LoE-3) in early implant failure (OR 0.9 [CI^{95%} 0.7-4.2]) could be found between short (7-9 mm) and conventional (≥ 10 mm) rough-surfaced implants (Pommer et al., 2011), however, compromised crown-to-implant ratios may give rise to long-term biomechanical overload (Block & Haggerty, 2009). Conventional implants did neither show significant differences regarding implant survival (LoE-3) when compared to transcrestal sinus floor elevation, yet only 28% of simultaneous implants were placed in residual bone heights of 7-9 mm (Gabbert et al., 2009) and therefore indirect comparison was not anticipated.

Conventional implants placed following lateral sinus floor elevation (Figure 10) did not show higher survival rates (LoE-2) vs. 5 mm short implants (Esposito et al., 2011) as well as vs. 8 mm short implants placed in conjunction with transcrestal sinus floor elevation (Cannizzaro et al., 2009). No controlled studies on parasinusal tilted or zygomatic implants in the partially edentulous posterior maxilla could be found (Friberg, 2008). The application of distraction osteogenesis in the posterior maxilla is limited by the proximity of the maxillary sinus (Bernstein et al., 2006). No controlled studies on external augmentation using onlay block grafts or guided bone regeneration in the partially edentulous posterior maxilla to correct for increased interarch distance could be identified (Table 6).

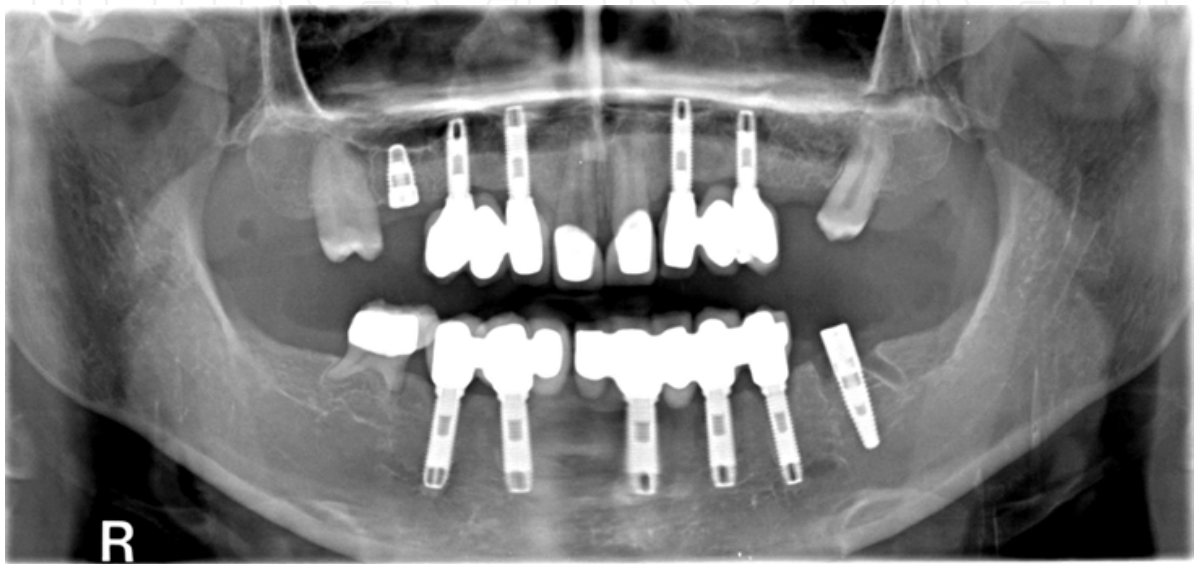


Fig. 10. Oligodontia patient showing two treatment modalities for deficient posterior maxillary sites: short implant (8 mm) without bone graft (right side) vs. sinus floor augmentation prior to the placement of longer implants (left side) [picture by Bernhard Pommer*]

Bone graft treatment options	Indications & Limitations	LoE
Onlay block graft	No inherent limitations	4
Guided bone regeneration	No inherent limitations	4
Lateral sinus floor elevation	No inherent limitations	2
Transcrestal sinus floor elevation	Residual bone height of 4-6 mm suggested	2
Nongrafting treatment options	Indications & Limitations	LoE
Short implants	Indicated in cases of at 5-7 mm bone height	2
Parasinusal tilted implants	Limited by residual bone volume in premaxillary and retromolar regions	4
Zygomatic implants	Placed in conjunction with premaxillary implants	4

Table 6. Treatment options for vertical deficiency of the posterior maxilla

4.3 Deficient anterior mandibular sites

Similar to the anterior maxilla, edentulous anterior mandibular ridges are often knife-edged in shape. Treatment options for horizontal deficiencies involve onlay block grafts, guided bone regeneration and alveolar ridge expansion (Table 7). Reduction of ridge height until adequate bone width is obtained and subsequent apical implant placement may be a non-grafting option but is associated with increased crown length and compromised implant esthetics. Compared to the anterior maxilla, however, more patients may accept an esthetic compromise. No controlled studies on any treatment option could be identified.

Bone graft treatment options	Indications & Limitations	LoE
Onlay block graft	No inherent limitations	4
Guided bone regeneration	No inherent limitations	4
Alveolar ridge expansion	Limited to a minimum residual bone width of 4 mm	4
Non-grafting treatment options	Indications & Limitations	LoE
Apical implant placement	Limited indications due to compromised implant esthetics	4

Table 7. Treatment options for horizontal deficiency of the anterior mandible

In less frequent cases requiring vertical bone augmentation onlay block grafts, guided bone regeneration, distraction osteogenesis as well as (esthetically compromised) apical implant placement may be considered. No controlled studies on any treatment option could be identified.

4.4 Deficient posterior mandibular sites

The obvious limitation of implant placement in the posterior mandible is the presence of the inferior alveolar nerve (Block & Haggerty, 2009). Due to denture-related alveolar resorption, predominantly low-well-rounded ridge shapes can be found. Treatment options for vertical deficiencies involve onlay block grafts, guided bone regeneration, distraction osteogenesis, interpositional grafts, short implants and transposition of the inferior alveolar nerve (Table 8). No significant difference (LoE-3) in early implant failure (OR 0.5 [CI^{95%} 0.1-2.3]) could be found between short (7-9 mm) and conventional (≥ 10 mm) rough-surfaced implants (Pommer et al., 2011), however, unfavourable crown-to-implant ratios may not only compromise implant esthetics but also give rise to long-term biomechanical overload (Figure 11) depending on interarch distance (Block & Haggerty, 2009). No significant

Bone graft treatment options	Indications & Limitations	LoE
Onlay block graft	No inherent limitations	2
Guided bone regeneration	No inherent limitations	4
Distraction osteogenesis	Limited to a minimum residual bone height of 6 mm	2
Interpositional graft	Limited to a minimum residual bone height of 6 mm	2
Nongrafting treatment options	Indications & Limitations	LoE
Short implants	Indicated in cases of at 5-7 mm bone height	2
Alveolar nerve transposition	Limited indications due to risk of nerve damage	4

Table 8. Treatment options for vertical deficiency of the posterior mandible

differences (LoE-2) regarding implant survival were found comparing interpositional grafts vs. 7 mm short implants (Felice et al., 2010), vs. 5 mm short implants (Esposito et al., 2011), vs. distraction osteogenesis (Bianchi et al., 2008) or vs. onlay block grafts (Felice et al., 2009). However, interpositional grafts showed significantly less gain in bone height (5.8 mm vs. 10 mm, 12 patients) vs. distraction osteogenesis (Bianchi et al., 2008), but significantly less bone resorption (0.5 mm vs. 2.8 mm, 20 patients) vs. onlay block grafts (Felice et al., 2009). No controlled studies on guided bone regeneration and inferior alveolar nerve transposition could be identified.

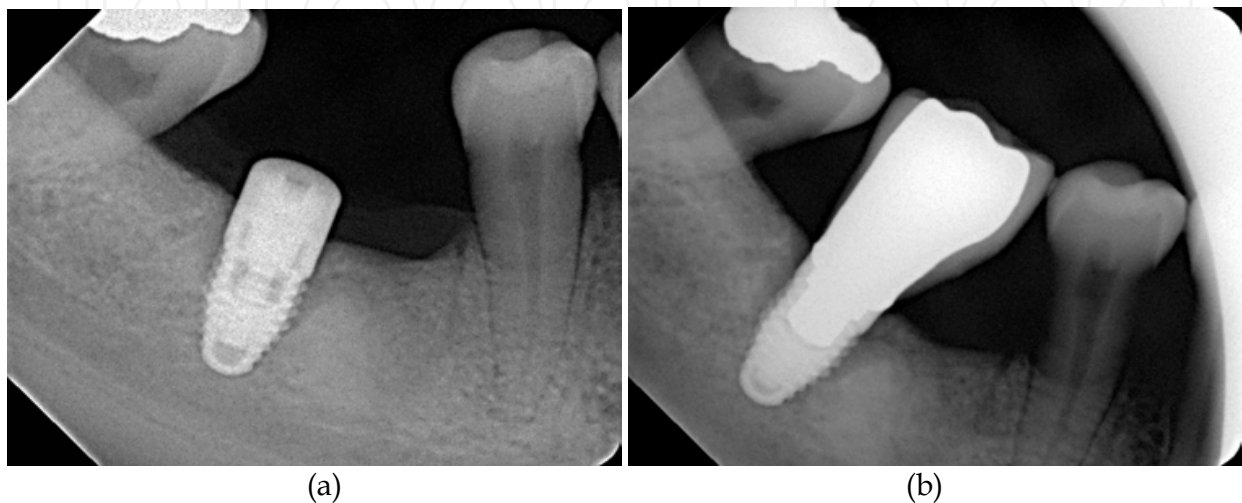


Fig. 11. Short implants (8 mm) in the posterior mandible (a) may result in compromised crown-to-implant ratios and long-term biomechanical overload (b) as well as esthetic compromise [pictures by Bernhard Pommer*]

In less frequent cases requiring horizontal bone augmentation onlay block grafts, guided bone regeneration, alveolar ridge expansion as well as ridge height reduction prior to apical placement of short implants may be considered. No significant differences (LoE-3) regarding implant success, peri-implant bone loss and implant stability could be found between buccal onlay bone grafts vs. conventional implant placement (Özkan et al., 2007). No controlled studies on any treatment option could be identified.

3. Conclusion and future research implications

Although several bone graft techniques as well as nongrafting treatment options can be considered well documented for different indications (Jensen & Terheyden, 2009), there is significant lack of comparative effectiveness research (CER) to guide decision making in oral bone graft surgery. While some surgical options have been compared in randomized (LoE-2) or non-randomized controlled trials (LoE-3), evidence on other treatment alternatives is based on between-study comparison. Even indirect comparison of study results could not provide further evidence. No long-term investigation comparing all available treatment options for any completely or partially edentulous situation could be identified. Priority may be given to procedures that appear less invasive and carry a lower risk of complications (Esposito et al., 2009).

Alveolar ridge deficiencies have traditionally been classified as horizontal (class I), vertical (class II) or combined (class III) defects (Seibert, 1983). Since the choice of surgical approach

as well as the sequence of bone healing is largely dependent on the extent of the defect (Att et al., 2009), parameters concerning the initial clinical situation should be presented in more detail. Residual bone height is routinely investigated as an influencing variable in sinus floor augmentation trials, yet may not only affect treatment outcomes but also the choice of surgical technique. Recently, a modified classification (distinguishing 9 categories) has been presented to describe the atrophy-related initial situation of the edentulous maxilla and its impact on treatment decisions illustrated (Chiapasco et al., 2008).

In comparing treatment options for horizontal and combined alveolar defects, however, it seems relevant to evaluate initial bone morphology in 2 or even 3 dimensions. Not only residual bone but also graft extent should be described in terms of volume (Chiapasco et al., 2006) to allow more accurate evaluation of treatment success and recommendation of well-defined surgical protocols according to the initial situation (Chiapasco et al., 2008). Other confounding variables to be accounted for may be patient- (age, gender, smoking, comorbidity), implant- (dimension, micro-/macrostructure, implant bed preparation technique, loading protocol) or prosthetic- (type and fixation, crown-to-implant ratio, occlusal table) or outcome-related (success criteria, radiographic imaging, implant- vs. patient-based analysis).

Meaningful comparison of treatment outcomes should include implant success, long-term marginal bone resorption as well as graft success. However, only 9% of studies on oral bone augmentation measure the amount of bone gain and its stability over time (Aghaloo & Moy, 2007). Three-dimensional radiographic imaging should be considered to evaluate horizontal grafts. Peri-implant mucosal health and pocket depths may be crucial to long-term success. However, it should be kept in mind that all these clinical and radiological measures just represent surrogate endpoints for patient-related outcomes, i.e. long-term function and esthetics. Implant esthetics are considered essential in the anterior maxilla, while their impact on treatment decisions in other jaw regions remains unclear. However, no consensus on evaluation methodology has been reached yet and esthetic indices used have shown poor correlation to subjective patients' opinion (Meijndert et al., 2007). Patient-based outcome assessment may involve overall satisfaction with treatment results (most commonly rated on visual analogue scale), patients' perception of the surgical intervention and its impact on oral health-related quality of life (OHRQoL). The Oral Health Impact Profile (OHIP) has been established as a validated instrument (Slade & Spencer, 1994), however, most studies do not evaluate OHRQoL or do not draw within-subject comparison between pre- and post-treatment conditions. Cost-efficiency analyses, in particular, may benefit substantially from OHRQoL data. Finally, outcome assessment should embrace rates of surgical as well as prosthetic complications. As characteristics of possible complications vary significantly between surgical techniques, as described in chapter 2, comparison is inherently difficult (Esposito et al., 2005) and further complicates treatment choice.

The GRADE (Grading of Recommendations, Assessment, Development and Evaluation) Working Group has focused on addressing methodological shortcomings in evidence-based health care and developing a common, sensible approach (Guyatt et al., 2011). International organisations such as the Cochrane Collaboration and World Health Organisation have provided input into the development and started using it. Treatment recommendations are based on an overall level of scientific evidence, that has been defined as the lowest evidence of all treatment outcomes that seem crucial. Outcomes are considered crucial if they are

likely to influence treatment decisions. To date no definition of crucial outcomes of implant rehabilitation has been attempted. The concept of evidence-based decision making in oral bone graft surgery seems to provide future research implications without measure.

4. Acknowledgment

We gratefully acknowledge the contributions of Professor Marco Esposito (Cochrane Oral Health Group, University of Manchester, UK), Professor Gordan H. Guyatt (GRADE Working Group, McMaster University, ON, Canada), Professor Jeremy Howick (Oxford Centre for Evidence-Based Medicine, UK), Professor Mike T. John (University of Minnesota, MN, United States), Professor Tim Newton (King's College London, UK) and Professor Michael A. Pogrel (University of California, San Francisco, CA, United States).

5. References

- Aghaloo, T.L. & Moy, P.K. (2007) Which hard tissue augmentation techniques are the most successful in furnishing bony support for implant placement?. *The International Journal of Oral & Maxillofacial Implants*, Vol.22, Suppl, (December 2007), pp. 49-70, ISSN 0882-2786
- Aparicio, C., Ouazzani, W. & Hatano, N. (2008) The use of zygomatic implants for prosthetic rehabilitation of the severely resorbed maxilla. *Periodontology 2000*, Vol.47, No.1, (June 2008), pp. 162-171, ISSN 0906-6713
- Att, W., Bernhart, J. & Strub, J.R. (2009) Fixed rehabilitation of the edentulous maxilla: possibilities and clinical outcome. *Journal of Oral and Maxillofacial Surgery*, Vol.67, No.11 (Suppl), (November 2009), pp. 60-73, ISSN 0278-2391
- Bernstein, S., Cooke, J., Fotek, P. & Wang, H.L. (2006) Vertical bone augmentation: where are we now? *Implant Dentistry*, Vol.15, No.3, (September 2006), pp. 219-228, ISSN 1056-6163
- Bianchi, A., Felice, P., Lizio, G. & Marchetti, C. (2008) Alveolar distraction osteogenesis versus inlay bone grafting in posterior mandibular atrophy: a prospective study. *Oral Surgery, Oral Medicine, Oral Pathology, Oral Radiology, and Endodontics*, Vol.105, No.3, (March 2008), pp. 282-292, ISSN 1079-2104
- Block, M.S. & Haggerty, C.J. (2009) Interpositional osteotomy for posterior mandible ridge augmentation. *Journal of Oral and Maxillofacial Surgery*, Vol.67, Suppl, (November 2009), pp. 31-39, ISSN 0278-2391
- Cannizzaro, G., Felice, P., Leone, M., Viola, P. & Esposito, M. (2009) Early loading of implants in the atrophic posterior maxilla: lateral sinus lift with autogenous bone and Bio-Oss versus crestal mini sinus lift and 8-mm hydroxyapatite-coated implants. A randomised controlled clinical trial. *European Journal of Oral Implantology*, Vol.2, No.1, (Spring 2009), pp. 25-38, ISSN 1756-2406
- Cawood, J.I. & Howell, R.A. (1988) A classification of the edentulous jaws. *International Journal of Oral and Maxillofacial Surgery*, Vol.17, No.4, (August 1988), pp. 232-236, ISSN 0901-5027
- Chao, Y.L., Chen, H.H., Mei, C.C., Tu, Y.K. & Lu, H.K. (2010) Meta-regression analysis of the initial bone height for predicting implant survival rates of two sinus elevation procedures. *Journal of Clinical Periodontology*, Vol.37, No.5, (May 2008), pp. 456-465, ISSN 0303-6979


- Chiapasco, M., Abati, S., Romeo, E. & Vogel, G. (1999) Clinical outcome of autogenous bone blocks or guided bone regeneration with e-PTFE membranes for the reconstruction of narrow edentulous ridges. *Clinical Oral Implants Research*, Vol.10, No.4, (August 1999), pp. 278-288, ISSN 0905-7161
- Chiapasco, M., Romeo, E., Casentini, P. & Rimondini, L. (2004) Alveolar distraction osteogenesis vs. vertical guided bone regeneration for the correction of vertically deficient edentulous ridges: a 1-3-year prospective study on humans. *Clinical Oral Implants Research*, Vol.15, No.1, (February 2004), pp. 82-95, ISSN 0905-7161
- Chiapasco, M., Zaniboni, M. & Boisco, M. (2006) Augmentation procedures for the rehabilitation of deficient edentulous ridges with oral implants. *Clinical Oral Implants Research*, Vol.17, Suppl 2, (October 2006), pp. 136-159, ISSN 0905-7161
- Chiapasco, M., Zaniboni, M. & Rimondini, L. (2007) Autogenous onlay bone grafts vs. alveolar distraction osteogenesis for the correction of vertically deficient edentulous ridges: a 2-4-year prospective study on humans. *Clinical Oral Implants Research*, Vol.18, No.4, (August 2007), pp. 432-440, ISSN 0905-7161
- Chiapasco, M., Zaniboni, M. & Rimondini, L. (2008) Dental implants placed in grafted maxillary sinuses: a retrospective analysis of clinical outcome according to the initial clinical situation and a proposal of defect classification. *Clinical Oral Implants Research*, Vol.19, No.4, (April 2008), pp. 416-428, ISSN 0905-7161
- Chiapasco, M., Casentini, P. & Zaniboni, M. (2009) Bone augmentation procedures in implant dentistry. *The International Journal of Oral & Maxillofacial Implants*, Vol.24, Suppl, (October 2009), pp. 237-259, ISSN 0882-2786
- Chrcanovic, B.R. & Custódio, A.L. (2009) Inferior alveolar nerve lateral transposition. *Oral and Maxillofacial Surgery*, Vol.13, No.4, (December 2009), pp.213-219, ISSN 1865-1550
- Danza, M., Guidi, R. & Carinci, F. (2009) Comparison between implants inserted into piezo split and unsplit alveolar crests. *Journal of Oral and Maxillofacial Surgery*, Vol.67, No.11, (November 2009), pp. 2460-2465, ISSN 0278-2391
- das Neves, F.D., Fones, D., Bernardes, S.R., do Prado, C.J. & Neto, A.J. (2006) Short implants - an analysis of longitudinal studies. *The International Journal of Oral & Maxillofacial Implants*, Vol.21, No.1, (January 2006), pp. 86-93, ISSN 0882-2786
- Del Fabbro, M., Bellini, C.M., Romeo, D. & Francetti, L. (2011) Tilted Implants for the Rehabilitation of Edentulous Jaws: A Systematic Review. *Clinical Implant Dentistry and Related Research*, Epub ahead of print, ISSN 1708-8208
- Donos, N., Mardas, N. & Chadha, V. (2008) Clinical outcomes of implants following lateral bone augmentation: systematic assessment of available options (barrier membranes, bone grafts, split osteotomy). *Journal of Clinical Periodontology*, Vol.35, Suppl, (September 2008), pp. 173-202, ISSN 0303-6979
- Emmerich, D., Att, W. & Stappert, C. (2005) Sinus floor elevation using osteotomes: a systematic review and meta-analysis. *Journal of Periodontology*, Vol.76, No.8, (August 2005), pp. 1237-1251, ISSN 0022-3492
- Esposito, M., Worthington, H.V. & Coulthard, P. (2005) Interventions for replacing missing teeth: dental implants in zygomatic bone for the rehabilitation of the severely deficient edentulous maxilla. *Cochrane Database of Systematic Reviews*, Vol.19, No.4, (October 2005), CD004151, ISSN 1469-493X

- Esposito, M., Grusovin, M.G., Felice, P., Karatzopoulos, G., Worthington, H.V. & Coulthard, P. (2009) Interventions for replacing missing teeth: horizontal and vertical bone augmentation techniques for dental implant treatment. *Cochrane Database of Systematic Reviews*, Vol.7, No.4, (October 2009), CD003607, ISSN 1469-493X
- Esposito, M., Grusovin, M.G., Rees, J., Karasoulos, D., Felice, P., Alissa, R., Worthington, H.V. & Coulthard, P. (2010) Interventions for replacing missing teeth: augmentation procedures of the maxillary sinus. *Cochrane Database of Systematic Reviews*, Vol.17, No.3, (March 2010), CD008397, ISSN 1469-493
- Esposito, M., Pellegrino, G., Pistilli, R. & Felice, P. (2011) Rehabilitation of posterior atrophic edentulous jaws: prostheses supported by 5 mm short implants or by longer implants in augmented bone? One-year results from a pilot randomised clinical trial. *European Journal of Oral Implantology*, Vol.4, No.1, (Spring 2011), pp. 21-30, ISSN 1756-2406
- Felice, P., Cannizzaro, G., Checchi, V., Marchetti, C., Pellegrino, G., Censi, P. & Esposito, M. (2009) Vertical bone augmentation versus 7-mm-long implants in posterior atrophic mandibles. Results of a randomised controlled clinical trial of up to 4 months after loading. *European Journal of Oral Implantology*, Vol.2, No.1, (Spring 2009), pp. 7-20, ISSN 1756-2406
- Felice, P., Pellegrino, G., Checchi, L., Pistilli, R. & Esposito, M. (2010) Vertical augmentation with interpositional blocks of anorganic bovine bone vs. 7-mm-long implants in posterior mandibles: 1-year results of a randomized clinical trial. *Clinical Oral Implants Research*, Vol.21, No.12, (December 2010), pp. 1394-1403, ISSN 0905-7161
- Friberg, B. (2008) The posterior maxilla: clinical considerations and current concepts using Brånemark System implants. *Periodontology 2000*, Vol.47, No.1, (June 2008), pp. 67-78, ISSN 0906-6713
- Flemmig, T.F. & Beikler, T. (2009) Decision making in implant dentistry: an evidence-based and decision-analysis approach. *Periodontology 2000*, Vol.50, No.1, (June 2009), pp. 154-172, ISSN 0906-6713
- Gabbert, O., Koob, A., Schmitter, M. & Rammelsberg, P. (2009) Implants placed in combination with an internal sinus lift without graft material: an analysis of short-term failure. *Journal of Clinical Periodontology*, Vol.36, No.2, (February 2009), pp. 177-183, ISSN 0303-6979
- Graziani, F., Donos, N., Needleman, I., Gabriele, M. & Tonetti, M. (2004) Comparison of implant survival following sinus floor augmentation procedures with implants placed in pristine posterior maxillary bone: a systematic review. *Clinical Oral Implants Research*, Vol.15, No.6, (December 2004), pp. 677-682, ISSN 0905-7161
- Griffin, T.J. & Cheung, W.S. (2004) The use of short, wide implants in posterior areas with reduced bone height: a retrospective investigation. *The Journal of Prosthetic Dentistry*, Vol.92, No.2, (August 2004), pp. 139-144, ISSN 0022-3913
- Guyatt, G.H., Oxman, A.D., Schünemann, H.J., Tugwell, P. & Knottnerus, A. (2011) GRADE guidelines: a new series of articles in the Journal of Clinical Epidemiology. *Journal of Clinical Epidemiology*, Vol.64, No.4, (April 2011), pp. 380-382, ISSN 0895-4356
- Hagi, D., Deporter, D.A., Pilliar, R.M. & Arenovich, T. (2004) A targeted review of study outcomes with short (\leq 7 mm) endosseous dental implants placed in partially edentulous patients. *Journal of Periodontology*, Vol.75, No.6, (June 2004), pp. 798-804, ISSN 0022-3492

- Holtzclaw, D.J., Toscano, N.J. & Rosen, P.S. (2010) Reconstruction of posterior mandibular alveolar ridge deficiencies with the piezoelectric hinge-assisted ridge split technique: a retrospective observational report. *Journal of Periodontology*, Vol.81, No.11, (November 2010), pp. 1580-1586, ISSN 0022-3492
- Howick, J., Chalmers, I., Glasziou, P., Greenhalgh, T., Heneghan, C., Liberati, A., Moschetti, I., Phillips, B., Thornton, H., Goddard, O. & Hodgkinson, M. (2011). The Oxford 2011 Levels of Evidence, Oxford Centre for Evidence-Based Medicine, 01.08.2011, Available from <http://www.cebm.net/index.aspx?o=5653>
- Jensen, O.T., Cockrell, R., Kuhike, L. & Reed, C. (2002) Anterior maxillary alveolar distraction osteogenesis: a prospective 5-year clinical study. *The International Journal of Oral & Maxillofacial Implants*, Vol.17, No.1, (January 2002), pp. 52-68, ISSN 0882-2786
- Jensen, O.T., Cullum, D.R. & Baer, D. (2009) Marginal bone stability using 3 different flap approaches for alveolar split expansion for dental implants: a 1-year clinical study. *Journal of Oral and Maxillofacial Surgery*, Vol.67, No.9, (September 2009), pp. 1921-1930, ISSN 0278-2391
- Jensen, S.S. & Terheyden, H. (2009) Bone augmentation procedures in localized defects in the alveolar ridge: clinical results with different bone grafts and bone-substitute materials. *The International Journal of Oral & Maxillofacial Implants*, Vol.24, Suppl, (October 2009), pp. 218-236, ISSN 0882-2786
- Jung, R.E., Schneider, D., Ganeles, J., Wismeijer, D., Zwahlen, M., Hämmerle, C.H. & Tahmaseb, A. (2009) Computer technology applications in surgical implant dentistry: a systematic review. *The International Journal of Oral & Maxillofacial Implants*, Vol.24, Suppl, (October 2009), pp. 92-109, ISSN 0882-2786
- Keller, E.E. (1995) Reconstruction of the severely atrophic edentulous mandible with endosseous implants: a 10-year longitudinal study. *Journal of Oral and Maxillofacial Surgery*, Vol.53, No.3, (March 1995), pp. 305-320, ISSN 0278-2391
- Kotsovilis, S., Fourmouis, I., Karoussis, I.K. & Bamia, C. (2009) A systematic review and meta-analysis on the effect of implant length on the survival of rough-surface dental implants. *Journal of Periodontology*, Vol.80, No.11, (November 2009), pp. 1700-1718, ISSN 0022-3492
- Lundgren, S., Moy, P., Johansson, C. & Nilsson, H. (1996) Augmentation of the maxillary sinus floor with particulated mandible: a histologic and histomorphometric study. *The International Journal of Oral & Maxillofacial Implants*, Vol.11, No.6, (November 1996), pp. 760-766, ISSN 0882-2786
- Lundgren, S., Sjöström, M., Nyström, E. & Sennerby, L. (2008) Strategies in reconstruction of the atrophic maxilla with autogenous bone grafts and endosseous implants. *Periodontology 2000*, Vol.47, No.1, (June 2008), pp. 143-161, ISSN 0906-6713
- Maló, P., de Araújo Nobre, M. & Rangert, B. (2007) Short implants placed one-stage in maxillae and mandibles: a retrospective clinical study with 1 to 9 years of follow-up. *Clinical Implant Dentistry and Related Research*, Vol.9, No.1, (March 2007), pp. 15-21, ISSN 1523-0899
- Meijndert, L., Raghoobar, G.M., Schüpbach, P., Meijer, H.J. & Vissink, A. (2005) Bone quality at the implant site after reconstruction of a local defect of the maxillary anterior ridge with chin bone or deproteinised cancellous bovine bone. *International Journal*

- of Oral and Maxillofacial Surgery*, Vol.34, No.8, (December 2005), pp. 877-884, ISSN 0901-5027
- Meijndert, L., Meijer, H.J., Stellingsma, K., Stegenga, B. & Raghoobar, G.M. (2007) Evaluation of aesthetics of implant-supported single-tooth replacements using different bone augmentation procedures: a prospective randomized clinical study. *Clinical Oral Implants Research*, Vol.18, No.6, (December 2007), pp. 715-719, ISSN 0905-7161
- Özkan, Y., Özcan, M., Varol, A., Akoglu, B., Uçankale, M. & Basa, S. (2007) Resonance frequency analysis assessment of implant stability in labial onlay grafted posterior mandibles: a pilot clinical study. *The International Journal of Oral & Maxillofacial Implants*, Vol.22, No.2, (March 2007), pp. 235-242, ISSN 0882-2786
- Pjetursson, B.E., Tan, W.C., Zwahlen, M. & Lang, N.P. (2008) A systematic review of the success of sinus floor elevation and survival of implants inserted in combination with sinus floor elevation. *Journal of Clinical Periodontology*, Vol.35, Suppl, (September 2008), pp. 216-240, ISSN 0303-6979
- Pommer, B., Unger, E., Sütö, D., Hack, N. & Watzek, G. (2009) Mechanical properties of the Schneiderian membrane in vitro. *Clinical Oral Implants Research*, Vol.20, No.6, (June 2009), pp. 633-637, ISSN 0905-7161
- Pommer, B. & Watzek, G. (2009) Gel-pressure technique for flapless transcrestal maxillary sinus floor elevation: a preliminary cadaveric study of a new surgical technique. *The International Journal of Oral & Maxillofacial Implants*, Vol.24, No.5, (September 2009), pp. 817-822, ISSN 0882-2786
- Pommer, B., Frantal, S., Willer, J., Posch, M., Watzek, G. & Tepper, G. (2011) Impact of dental implant length on early failure rates: a meta-analysis of observational studies. *Journal of Clinical Periodontology*, Vol.38, No.9, (September 2011), pp. 856-863, ISSN 0303-6979
- Raghoobar, G.M., den Hartog, L. & Vissink, A. (2010) Augmentation in proximity to the incisive foramen to allow placement of endosseous implants: a case series. *Journal of Oral and Maxillofacial Surgery*, Vol.68, No.9, (September 2009), pp. 2267-2271, ISSN 0278-2391
- Renouard, F. & Nisand, D. (2006) Impact of implant length and diameter on survival rates. *Clinical Oral Implants Research*, Vol.17, Suppl 2, (October 2006), pp. 35-51, ISSN 0905-7161
- Rocchietta, I., Fontana, F. & Simion, M. (2008) Clinical outcomes of vertical bone augmentation to enable dental implant placement: a systematic review. *Journal of Clinical Periodontology*, Vol.35, Suppl, (September 2008), pp. 203-215, ISSN 0303-6979
- Sbordone, L., Toti, P., Menchini-Fabris, G., Sbordone, C. & Guidetti, F. (2009) Implant survival in maxillary and mandibular osseous onlay grafts and native bone: a 3-year clinical and computerized tomographic follow-up. *The International Journal of Oral & Maxillofacial Implants*, Vol.24, No.4, (July 2009), pp. 695-703, ISSN 0882-2786
- Seibert, J.S. (1983) Reconstruction of deformed, partially edentulous ridges, using full thickness onlay grafts. Part I. Technique and wound healing. *Compendium of Continuing Education in Dentistry*, Vol.4, No.5, (September 1983), pp. 437-453, ISSN 1548-8578
- Sjöström, M., Lundgren, S. & Sennerby, L. (2006) A histomorphometric comparison of the bone graft-titanium interface between interpositional and onlay/inlay bone

- grafting techniques. *The International Journal of Oral & Maxillofacial Implants*, Vol.21, No.1, (January 2006), pp. 52-62, ISSN 0882-2786
- Slade, G.D. & Spencer, A.J. (1994) Development and evaluation of the Oral Health Impact Profile. *Community Dental Health*, Vol.11, No.1, (March 1994), pp. 3-11, ISSN 0265-539X
- Sohn, D.S., Lee, H.J., Heo, J.U., Moon, J.W., Park, I.S. & Romanos, G.E. (2010) Immediate and delayed lateral ridge expansion technique in the atrophic posterior mandibular ridge. *Journal of Oral and Maxillofacial Surgery*, Vol.68, No.9, (September 2010), pp. 2283-2290, ISSN 0278-2391
- Stellingsma, K., Bouma, J., Stegenga, B., Meijer, H.J. & Raghoobar, G.M. (2003) Satisfaction and psychosocial aspects of patients with an extremely resorbed mandible treated with implant-retained overdentures. A prospective, comparative study. *Clinical Oral Implants Research*, Vol.14, No.2, (April 2003), pp. 166-172, ISSN 0905-7161
- Stellingsma, C., Vissink, A., Meijer, H.J., Kuiper, C. & Raghoobar, G.M. (2004) Implantology and the severely resorbed edentulous mandible. *Critical Reviews in Oral Biology and Medicine*, Vol.15, No.4, (July 2004), pp. 240-248, ISSN 1045-4411
- Tan, W.C., Lang, N.P., Zwahlen, M. & Pjetursson, B.E. (2008) A systematic review of the success of sinus floor elevation and survival of implants inserted in combination with sinus floor elevation. Part II: transalveolar technique. *Journal of Clinical Periodontology*, Vol.35, Suppl, (September 2008), pp. 241-254, ISSN 0303-6979
- Vasak, C., Watzak, G., Gahleitner, A., Strbac, G., Schemper, M. & Zechner, W. (2011) Computed tomography-based evaluation of template (NobelGuide™)-guided implant positions: a prospective radiological study. *Clinical Oral Implants Research*, Epub ahead of print, ISSN 1600-0501
- Waasdorp, J. & Reynolds, M.A. (2010) Allogeneic bone onlay grafts for alveolar ridge augmentation: a systematic review. *The International Journal of Oral & Maxillofacial Implants*, Vol.25, No.3, (May 2010), pp. 525-531, ISSN 0882-2786
- Wiltfang, J., Schultze-Mosgau, S., Nkenke, E., Thorwarth, M., Neukam, F.W. & Schlegel, K.A. (2005) Onlay augmentation versus sinuslift procedure in the treatment of the severely resorbed maxilla: a 5-year comparative longitudinal study. *International Journal of Oral and Maxillofacial Surgery*, Vol.34, No.8, (December 2005), pp. 885-889, ISSN 0901-5027
- Zitzmann, N.U. & Schärer, P. (1998) Sinus elevation procedures in the resorbed posterior maxilla. Comparison of the crestal and lateral approaches. *Oral Surgery, Oral Medicine, Oral Pathology, Oral Radiology, and Endodontics*, Vol.85, No.1, (January 1998), pp. 8-17, ISSN 1079-2104
- Zitzmann, N.U., Schärer, P. & Marinello, C.P. (2001) Long-term results of implants treated with guided bone regeneration: a 5-year prospective study. *The International Journal of Oral & Maxillofacial Implants*, Vol.16, No.3, (May 2001), pp. 355-366, ISSN 0882-2786



Bone Grafting

Edited by Dr Alessandro Zorzi

ISBN 978-953-51-0324-0

Hard cover, 214 pages

Publisher InTech

Published online 21, March, 2012

Published in print edition March, 2012

Bone grafting is the surgical procedure in which new bone (bone graft) or a replacement material (graft substitute), is placed into bone fractures or bone defects to aid in healing. Bone grafting is in the field of interest of many surgical specialties, such as: orthopedics, neurosurgery, dentistry, plastic surgery, head and neck surgery, otolaryngology and others. In common, all these specialties have to handle problems concerning the lack of bone tissue or impaired fracture healing. There is a myriad of surgical techniques nowadays involving some kind of bone graft or bone graft substitute. This book gathers authors from different continents, with different points of view and different experiences with bone grafting. Leading researchers of Asia, America and Europe have contributed as authors. In this book, the reader can find chapters from the ones on basic principles, devoted to students, to the ones on research results and description of new techniques, experts will find very beneficial.

How to reference

In order to correctly reference this scholarly work, feel free to copy and paste the following:

Bernhard Pommer, Werner Zechner, Georg Watzek and Richard Palmer (2012). To Graft or Not to Graft? Evidence-Based Guide to Decision Making in Oral Bone Graft Surgery, Bone Grafting, Dr Alessandro Zorzi (Ed.), ISBN: 978-953-51-0324-0, InTech, Available from: <http://www.intechopen.com/books/bone-grafting/evidence-based-guide-to-decision-making-in-oral-bone-augmentation-surgery>

INTECH
open science | open minds

InTech Europe

University Campus STeP Ri
Slavka Krautzeka 83/A
51000 Rijeka, Croatia
Phone: +385 (51) 770 447
Fax: +385 (51) 686 166
www.intechopen.com

InTech China

Unit 405, Office Block, Hotel Equatorial Shanghai
No.65, Yan An Road (West), Shanghai, 200040, China
中国上海市延安西路65号上海国际贵都大饭店办公楼405单元
Phone: +86-21-62489820
Fax: +86-21-62489821

© 2012 The Author(s). Licensee IntechOpen. This is an open access article distributed under the terms of the [Creative Commons Attribution 3.0 License](#), which permits unrestricted use, distribution, and reproduction in any medium, provided the original work is properly cited.

IntechOpen

IntechOpen