

We are IntechOpen, the world's leading publisher of Open Access books Built by scientists, for scientists

6,900

Open access books available

185,000

International authors and editors

200M

Downloads

Our authors are among the

154

Countries delivered to

TOP 1%

most cited scientists

12.2%

Contributors from top 500 universities



WEB OF SCIENCE™

Selection of our books indexed in the Book Citation Index
in Web of Science™ Core Collection (BKCI)

Interested in publishing with us?
Contact book.department@intechopen.com

Numbers displayed above are based on latest data collected.
For more information visit www.intechopen.com



Chapter

Single-Row Rotator Cuff Repair

Amhaz Escanlar S., Jorge Mora A. and Pino Miguez J.

Abstract

Rotator cuff tears are a common cause of pain and disability among adults. Partial tears are usually treated conservatively. Complete tears might be treated conservatively in some cases; however, surgical repair is often performed in selected cases and situations where conservative treatment fails to restore function and pain relief. In addition, some patients with acute tears might be good candidates for acute surgical repair, as will be studied in this chapter. A plethora of techniques is available to repair rotator cuff tears. Among these, the surgeon faces the dilemma to choose the best treatment for the patient. Open techniques were the gold standard in the 1990s. However, the advent of arthroscopy has led the shoulder and sports surgeon community towards these. Arthroscopic rotator cuff repair has become the gold standard nowadays despite the lack of proper evidence to support this change. Furthermore, simple single-row repairs had been discarded favouring double-row techniques, yet new evidence supports the use of the former due to similar results, simplicity and cost-effectiveness. This chapter examines current evidence to help the surgeon decide between open and minimally invasive techniques and select suitable repair configurations.

Keywords: rotator, cuff, single-row, transosseous, double-row, mini-open, arthroscopy

1. Introduction

Rotator cuff tears are commonly seen in the orthopedic surgeon clinic, even more in the shoulder and elbow subspecialized professional practice. Different muscles form the rotator cuff: subscapularis, supraspinatus, infraspinatus, teres minor, and some authors also include the teres major due to its role as an internal rotator. The primary role of the rotator cuff is to stabilize the humeral head regarding the glenoid to allow the deltoid to perform the elevation of the arm. In addition, the rotator cuff externally rotates the glenohumeral joint (infraspinatus and teres minor) and contributes to internal rotation (subscapularis, assisted by the pectoralis major, teres major and latissimus dorsi) [1].

Patients with rotator cuff tears mainly complain of pain during daily living activities but also at night, when the pain can likewise interfere with proper resting. Moreover, a significant tear may impair function, limiting the active range of motion and can be the culprit of premature glenohumeral arthritis. Loss of external rotation, sometimes isolated, may appear in the onset of a posterior rotator cuff tear [1, 2].

Rotator cuff tears are expected after 60 years old. They correspond with the Neer type 3 stage and can be identified in about 20–30% of the patients in this age group. Beyond 80 years old, the ratio of patients suffering from cuff tears rises to more than 60%. However, the symptoms do not correlate with the presence of tears or even the size or retraction. Most patients do not seek advice from an orthopedic surgeon and do not demand a surgical intervention. More than half of the patients where a tear is identified will also suffer from a tear in their contralateral shoulder, especially in those older than 60 years [2–7].

1.1 Risk factors

Several risk factors have been identified concerning cuff tears. Age, as it was aforementioned, is the most significant. However, others such as smoking, hypercholesterolemia, diabetes, hypo or hyperthyroidism, trauma, scapular dyskinesia and kyphosis also play a critical role in the development and progression of cuff tears [7–15].

1.2 Classification

A plethora of classifications for rotator cuff tears has been described since the pathology became more interesting for the orthopedic community.

Neer described the evolution of rotator cuff disease in three stages. First, in individuals younger than 40 years, one can observe oedema and hemorrhage in the rotator cuff. In a second stage, the disease evolves in individuals between 40 and 60 years old, and fibrotic and tendinosis phenomena might be observed. Finally, in a third stage, usually, in patients older than 60 years, a tendon rupture is observed. Probably a fourth stage would involve rotator cuff arthropathy, with cephalad migration of the humeral head and degenerative osteoarthritis at the level of the glenoid as well as in the humeral head [15, 16].

Some authors have advocated for a classification based on tear size. Cofield in 1982 described four types of tears: small (<1 cm) medium (1–3 cm) large (3–5 cm) massive (>5 cm) [17].

Bateman also described a four-group classification based on the size: Grade 1 (<1 cm after debridement), Grade 2 (1–3 cm, after debridement), Grade 3 (<5 cm) and Grade 4 (global tear with no cuff left) [18].

Harryman described a classification based on the number of injured tendons. It is commonly accepted in Europe that a complete tear of two or more tendons should be considered massive, and concerns about reparability should arise [19].

Ellman and Gartsman introduced in 1993 a classification differentiating partial-thickness and full-thickness tears. Partial tears were classified in grade 1 (<3 mm deep, <25% thickness), grade 2 (3–6 mm, <50%) and grade 3 (>6 mm, >50%). The partial tear classification system is accepted worldwide as it helps in treatment selection, as discussed in the next section. These authors also proposed a full-thickness classification based on tear-shaped, which has been judged useful and is currently used worldwide. Five groups were described: crescent shape, L shape, Reverse L, trapezoidal shape and massive tears [20, 21].

Concerning partial tears, Snyder clarified that a distinction between articular and bursal tears is mandatory as the criteria for surgery are different.

Fox and Romeo described a specific classification for subscapularis tears in 2003. Four types were proposed: Type 1, partial thickness; Type 2, complete tear of the

upper 25%; Type 3, a complete tear of the upper 50%; Type 4, complete rupture of the subscapularis tendon [22].

Other authors prefer to classify tears about the retraction, as it can help the surgeon assess reparability before the operation. Patte described in 1990 three groups: Stage 1, where the tendon stump is adjacent to its insertion; Stage 2, with a tendon stump at the level of the humeral head; Stage 3, where the tendon is at the glenoid level or even more medial.

Patte also described a classification in the sagittal plane based on six segments: Segment 1, isolated subscapularis tear; Segment 2, isolated rotator interval tear; Segment 3, isolated supraspinatus tear; Segment 4, supraspinatus and upper one-half of the infraspinatus; Segment 5, complete supraspinatus and infraspinatus; and Segment 6, complete cuff rupture [23].

Finally, some authors prefer a classification based on tissue quality and atrophy. Currently, the classification proposed by Goutallier in 1994 is the most accepted and used. The author described stage 0, corresponding with a normal muscle. Stage 1, some fatty streaks; Stage 2, less than 50% of fatty atrophy; Stage 3, more than 50% of fat; Stage 4, fatty atrophy greater than 50% [24].

2. Treatment

The orthopedic surgeon's community has failed, to the date, to clearly identify which patients would benefit from surgical repair as the primary treatment. Most patients accept an initial attempt of conservative treatment, which is successful in most cases. They undergo a surgical rotator cuff repair if the former fails to provide pain relief and function improvement. Although this strategy is accepted worldwide, it does not provide a definitive solution for the tear, which seldom heals on its own (about 10% of small tears heal, and 10% become smaller). Tear progression is always worrisome as it may lead to non-reparability, arthritis and chronic pain. As a matter of fact, more than 50% of patients with partial tears experience a progression, which is closely correlated with the size of the index tear, and more than half of those with a full-thickness tear will suffer from an increase in the size of the tear, which may be the culprit for an increase in pain and disability. Acute traumatic tears, either in a previously asymptomatic patient or in patients with a previous history of rotator cuff disease yet compensated, with a significant loss of function, are good candidates for surgical repair without unnecessary delays [25–27].

The objective of the orthopedic surgeon, once the surgery is indicated and agreed upon by the patient, is to achieve sound fixation of the cuff to humeral tuberosities. Thorough attention to avoid gap formation is also a must. If the tendon is well fixed close to the bone, healing tissue will develop [28].

Despite some studies that show few differences in pain relief concerning tendon healing or retear, many others have identified a well-healed cuff as the main factor for improved strength and range of motion [28].

2.1 Open vs. arthroscopic

Open rotator cuff repair has been the gold standard when treating cuff tears. However, some concerns about infection and faster recovery have led shoulder surgeons to investigate the use of minimally invasive and arthroscopic technique.

Neviaser et al. retrospectively reviewed a cohort of patients who underwent anterosuperior rotator cuff repair with subscapularis involvement and found no differences in the outcomes between both modalities [29].

Hasler et al. in a prospective, randomized and long-term outcome study comparing open and arthroscopic rotator cuff repair did not document any difference either clinical or radiological. In addition, they did not find any harmful consequence due to transdeltoid mini-open approach [30].

Nazari et al. studied the effects of arthroscopic and mini-open rotator cuff repairs concerning pain and range of motion and did not find significant differences at 3, 6 and 12 months between both techniques [31].

Bayle et al. studied not only clinical outcomes but rotator cuff integrity at 1-year follow-up and did not find differences in a prospective study [32].

Fink Barnes et al. studied patient satisfaction and rotator cuff integrity in a cohort and found better results concerning integrity in the open surgery group. However, no statistical differences were found between both at the end of the study [33].

To sum up, if cost or time is an issue, open rotator cuff surgery is preferred. However, if short-term results are crucial and the patient seeks a faster return to work or sport, the arthroscopic repair is the technique of choice. The patient needs to be advised that both techniques may lead to excellent results and that the community of orthopedic surgeons cannot recommend one over the other if the factors mentioned above are not taken into account.

2.2 Repair techniques

With the advent of open and mini-open techniques, some classic repair techniques were developed. Transosseous sutures were mainly implemented, where bone tunnels are created, and sutures are placed directly through them, allowing for cuff reinsertion, as depicted in **Figure 1**.

A single-row repair is performed by means of anchors, usually one or two, with sutures integrated into them that permit cuff repair, as depicted in **Figure 2**. Single-row techniques are easier to perform arthroscopically, as well as in an open fashion.

Double-row repairs use one or two anchors in a medial row, suturing far from the tendon stump border area and a lateral row, again with one or two anchors, closer to




Figure 1.
a. and b. Transosseous repair, usually used in open surgery.




Figure 2.
a. and b. classic single-row repair with two lateral anchors.

the end of the ruptured tendon and the lateral border of the cuff footprint along the tuberosity, as it can be seen in **Figure 3**.

More recent are transosseous equivalent techniques, similar to double-row techniques yet requiring only a medial row and knotless implants laterally (without sutures passing through the tendon laterally but applying those from the medial row against the tendon) (see **Figures 4** and **5**) [28].

2.3 Single vs. double row

Single- and double-row techniques have been compared about their failure loads and gap formation. In an experimental study, Kim et al. and Ma et al. reported significant more load to failure and less gap formation in favor of double row. They also confirmed in vitro that the strain using a double row was a third of that of a single row. However, other studies, such as the one performed by Mazzoca et al., compared both without finding any difference. Finally, a meta-analysis by Hohmann et al. revealed a possible superiority in vitro regarding gap formation and load to failure yet not observed clinically in vivo. Therefore, a superiority of a technique versus the other has not been demonstrated, and the final decision belongs to the orthopedic surgeon




Figure 3.
a. and b. classic double-row configurations. Two anchors medial and two anchors lateral to the footprint with mattress sutures.




Figure 4.
On the left, a classic double row with independent sutures and anchors. On the right, the medial row sutures have been passed through the cuff, very close to the musculotendinous junction.

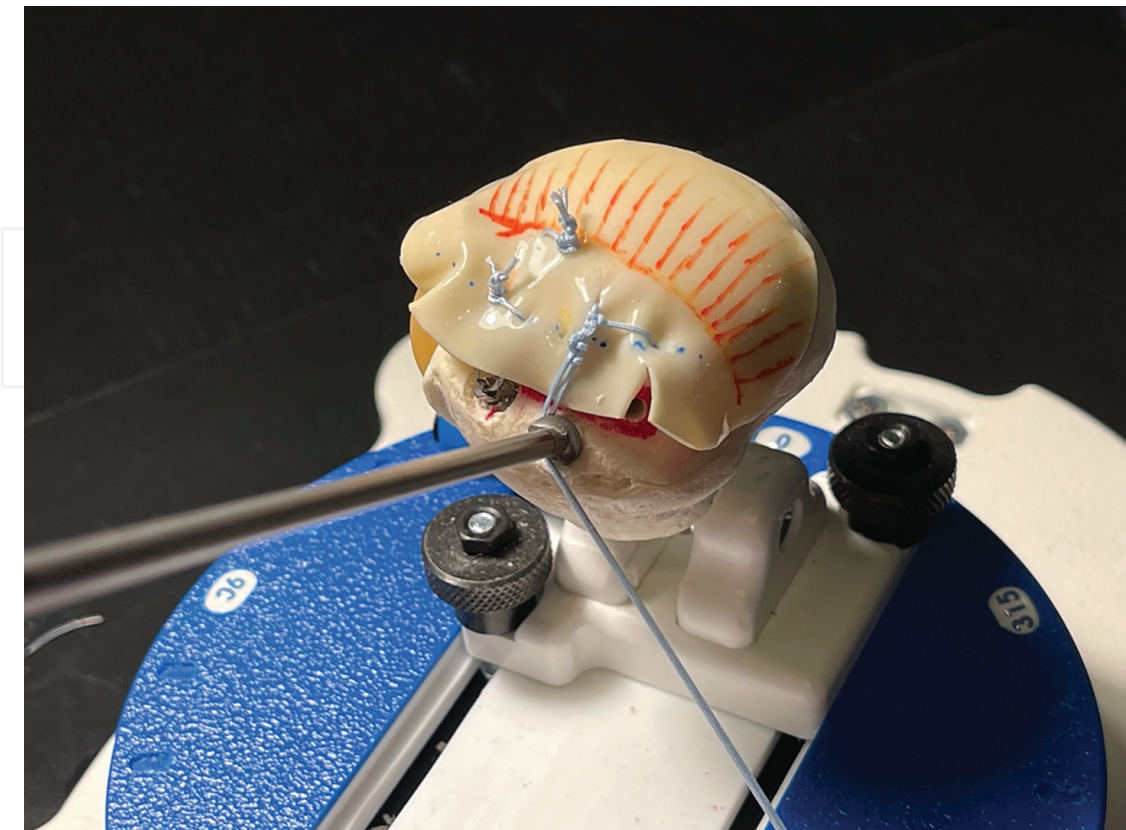


Figure 5.
The medial row mattress sutures, tied, are inserted into the bone, lateral to the footprint, by means of a knotless anchor.

who should analyze factors such as simplicity, skill, cost and time consumption when choosing the right technique for the patient [28, 34–36].

Deveci et al. and Maasse et al. reported that most studies comparing single- and double-row techniques were comparing different constructs and suture configurations, and thus the results obtained are not valid. Most studies used lateral single-row configurations either in vitro or in vivo, and very few a more medial single row avoiding unnecessary tension at the level of the repair (which is a must, especially in large and retracted tears) When a proper, more medial, single-row configuration was used, the results become similar. It is not fair to compare single-row configurations performed poorly and too lateral to modern double-row techniques, and despite that, clinically relevant results have failed to be obtained [37, 38].

2.4 Transosseous vs. single row

Transosseous repairs are of everyday use during open rotator cuff repair. The use of bony tunnels avoids anchors, which is a significant advantage concerning cost and ease of revision surgery. The former is performed either by employing guides and Kirschner wires or bone needles in the osteoporotic bone. Ahmad et al. and Park et al. compared micromotion in vitro at the footprint interface and concluded that transosseous repair minimizes strain and, therefore, would be advantageous concerning tendon to bone healing. Apreleva et al., in another experimental study, demonstrated that footprint anatomy restoration was superior when using transosseous techniques [39–42].

On the contrary, other authors such as Randelley et al. in a clinical study concluded that single-row and transosseous hardware-free repairs led to the same results concerning pain, function and retear rate at 15 months. However, transosseous repairs might be more cost-effective because they avoid the use of anchors [43].

Same principles apply to partial repairs when comparing transtendon single-row techniques versus double-row suture bridges. Zafra et al. demonstrated that partial tears might be treated with similar results using both techniques [44].

2.5 Transosseous vs. double row

Traditional transosseous repair focuses on restoring cuff footprint and applying pressure on the enthesis (against tuberosity bone). On the contrary, the traditional double row focuses on suturing the tendon medial and lateral in the footprint. Waltrip et al. compared both and demonstrated that a higher stress concentration was found in the latter at the medial anchors and suturing areas, while the former had more significant stress at the tendon to bone interface level. Forces through the tendon to bone enthesis can be beneficial, and on the contrary, forces around the anchors may explain the high recurrence rate and pull-out observed in double-row repairs [28, 45].

2.6 Transosseous equivalent vs. double row

Transosseous equivalent techniques mimic the effect created by traditional transosseous techniques utilizing lateral knotless anchors, which insert the sutures used in the medial row into the lateral cortex of the tuberosity. Hence, this technique mimics the effect of the classic techniques as it adds pressure forces that apply the tendon stump against the bone.

Siskoksy et al., in a cadaveric study, compared load to failure and gap formation using transosseous equivalent and double-row techniques. They concluded that load to failure was higher when using a transosseous equivalent construct. However, gap formation was similar between both [46]. The same conclusion was obtained by Costic et al. in a similar study in cadavers where cyclic loading was applied on the footprint [47].

Park et al. demonstrated in vitro that the pressure exerted by a transosseous equivalent is significantly higher than that observed in double rows. Nevertheless, it remains difficult to know the right amount of pressure or the ischemic effect of an excessive force on the tendon stump [48].

3. The art of the single-row technique

Not all single-row techniques are created equal. Arthroscopic rotator cuff repair emerged in the 1990s, and logically single-row constructs were the first used by shoulder and sports medicine surgeons. Initially, a unique row formed by one or two anchors (placed in the centre of the footprint or lateral to it) was used.

Not all single-row techniques are created equal. Arthroscopic rotator cuff repair emerged in the 1990s, and logically single-row constructs were the first used by shoulder and sports medicine surgeons. Initially, a unique row formed by one or two anchors (placed in the centre of the footprint or lateral to it) was used. Despite initial promising outcomes, the retear rate was undoubtedly worrisome, which explains the subsequent interest in developing double rows or transosseous equivalent techniques.

Complex and more robust suture configurations (such as the Mason-Allen technique) are complicated to replicate arthroscopically.

Simple or mattress sutures, often used arthroscopically, may not be sufficient to hold a rotator cuff with poor-quality tissue to the bone long enough to allow for proper healing. These statements led to a quest to find a better technique by adding anchors and complexity to the repairs. However, it was not until later that some surgeons started to question if a well-performed single row would be sufficient. To do so, a more medial single row started to be used with the rationale behind it that less tension on the rotator cuff would result. This is very useful in the onset of chronic and massive tears where even after proper slide liberation, tendon retraction impedes proper footprint anatomical restoration, as depicted in **Figures 6–9** [49].

Several factors may contribute to the final healing of the rotator cuff tendons to the bone. Among them, mechanical factors such as gap formation, stiffness and strength of the repair, load to failure, repair tension have already been discussed in previous sections of this chapter. However, other factors such as tendon vascularity, footprint coverage and respecting the proper biology of tendon healing are sometimes forgotten [49].

Suture bridge techniques have demonstrated in vitro superior strength, stiffness, less gap formation and more load to failure. However, this comes at the cost of vascularity disruption, high tension at the muscle to tendon junction (which may lead to a tear at this level). Transosseous equivalent techniques enhance the resistance and stability of the repair at the tendon to bone interface; nevertheless, they neglect biology as they create an ischemic environment. As a matter of fact, in vivo studies have failed to demonstrate the superiority of transosseous rotator cuff repair over single-row repair [49, 50].

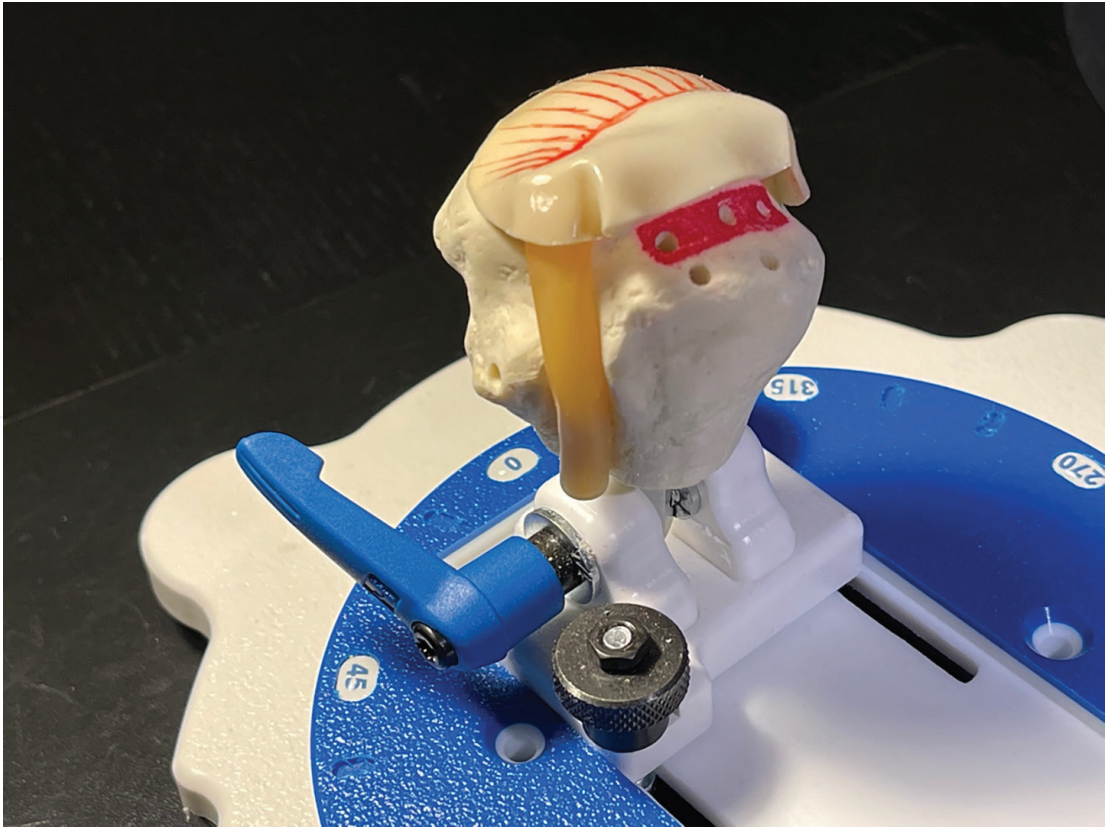


Figure 6.
Classic single row is performed with anchors in a more central or even lateral position in the footprint. Modern single row uses anchors closer to the cartilage, in a more medial position in the footprint (red area).

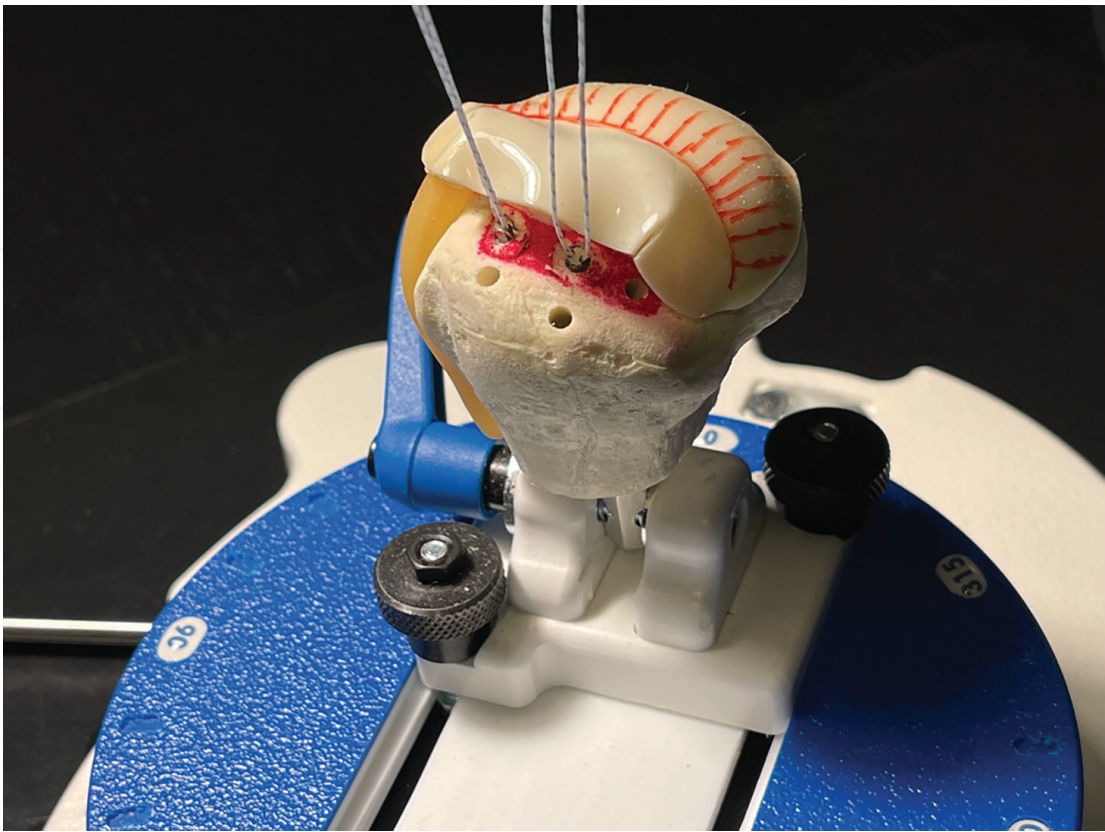


Figure 7.
The number of anchors varies between one and three depending on the size of the tear.

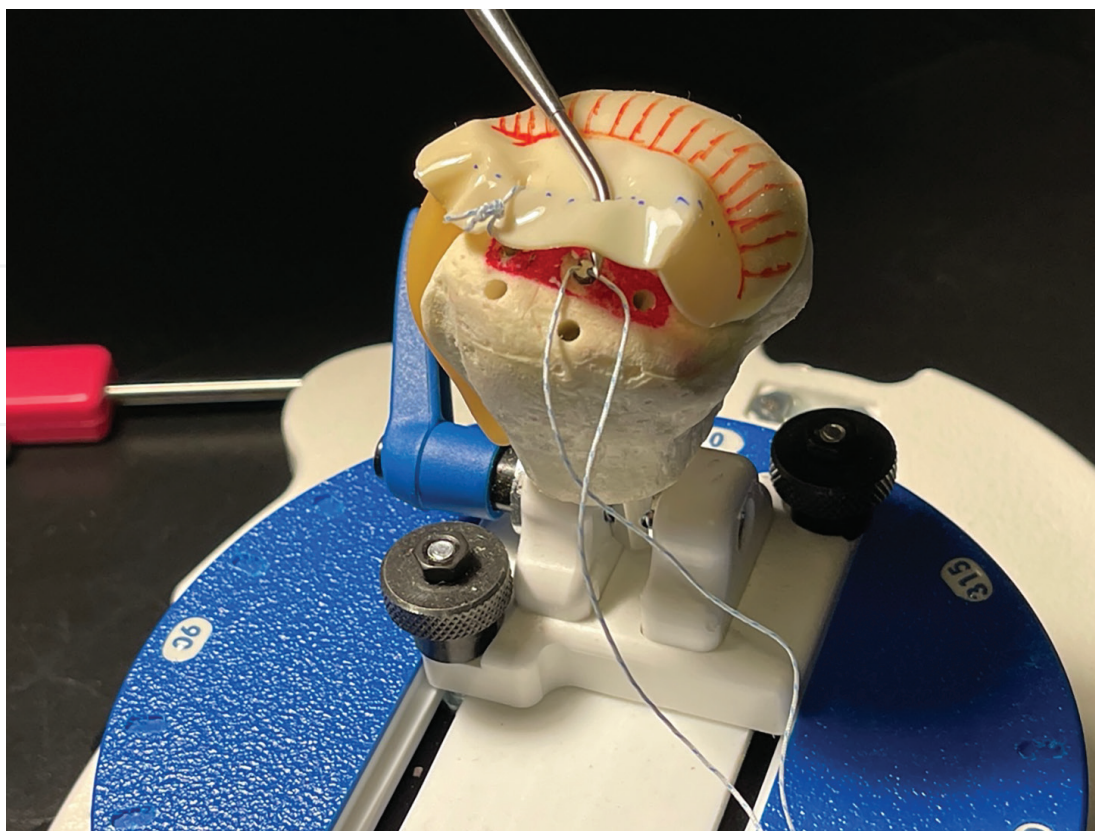


Figure 8.

A modern single-row construct uses sutures that pass about 1 cm medial to the border of the tendon stump. Thus, reducing the tension and minimizing retear rates due to excessive tension or damage to the musculotendinous junction.

In the context of a single-row repair, a more medial row may enhance biology as it adds less loading forces and respects vascularity. However, footprint non-anatomic restoration may arise as a concern. By medializing the anchors in the footprint (not medial to it), a part of the surface may stay uncovered by the tendon stump. Although the real significance of this has not been established, surgeons commonly think anatomic restoration would be superior to a 'leave it alone' strategy. To cope with this problem, creating bone marrow vents through microfracture instruments would promote the formation of a neotendon and fibrocartilage. The benefits of adding mesenchymal cells to the healing area would also increase the chances of the tendon to bone healing. Yamakado et al. concluded in a prospective randomized trial comparing suture bridge configurations and single-row (medially based) repairs that both techniques lead to the same clinical results. They found that incomplete healing was more common in single-row repairs, and on the other hand, medial cuff failure was more common in patients with bridge constructs. However, the differences were not significant from a statistical point of view [49].

Another argument favoring single-row techniques is that excessive medial sutures in the cuff may lead to a myotendinous junction tear. Despite some authors that studied the use of more medial sutures in vitro, advocating for more stability of the construct, it is accepted globally that this can be dangerous as it might come with a rupture at the level of the muscle, ending up with a tendon stump anchored to the tuberosity but without a healthy muscle able to apply traction on it. Therefore, leaving a security distance from the musculotendinous junction of 10 mm is the wiser choice [51, 52].



Figure 9.
Final modern single-row construct. Sutures are passed through the tendon far from the musculotendinous junction and far from the border. Less footprint is covered by the cuff when using this technique; however, bone marrow vents, lateral to the footprint, may provide stem cells which will develop a neotendon.

It has also been suggested that a single-row technique mimicking the Masson-Allen suture technique might increase the strength of the repair. Despite some studies confirming that these modifications of the original technique ('modified Mason Allen' or 'massive cuff suture configuration') might increase in vitro the stability of the repair (similar to the original Mason-Allen technique), they have failed to demonstrate a statistical difference or a real relevance clinically. In fact, rotator cuff repairs usually fail at the suture-tissue interface due to poor quality of the latter; therefore, the culprit might not be suture configuration. This the interest in keeping it as simple as possible [53–58].

4. Conclusions

Rotator cuff tear is a common etiology for pain, disability and loss of function that might be considered a burden for some health systems.

Conservative treatment may be adequate for a large number of patients; however, it is utterly crucial to identify patients who would benefit from an acute repair and not to neglect patients who still suffer and do not achieve a satisfactory result employing conservative methods.

The selection of the surgical technique for those patients who require a rotator cuff repair should be guided by the current evidence. It should favor methods that provide the best results for the patient while maintaining simplicity and cost-effectiveness at the proper levels. Therefore, a modern single-row technique with a more medial

anchor placement and bone marrow vents in the rotator footprint is probably the technique that balances all the factors mentioned before.

Acknowledgements

The authors would like to thank ASIS Medica for their support in the development of this study.

Conflict of interest

The authors declare no conflict of interest.

Author details

Amhaz Escanlar S.^{1*}, Jorge Mora A.² and Pino Miguez J.³

1 University Hospital Complex, Santiago de Compostela, Spain

2 Reconstructive Surgery, University Hospital Complex, Santiago de Compostela, Spain

3 Pediatric Orthopedics and Spine Surgery, University Hospital Complex, Santiago de Compostela, Spain

*Address all correspondence to: sameramhaz@gmail.com

IntechOpen

© 2022 The Author(s). Licensee IntechOpen. This chapter is distributed under the terms of the Creative Commons Attribution License (<http://creativecommons.org/licenses/by/3.0>), which permits unrestricted use, distribution, and reproduction in any medium, provided the original work is properly cited. 

References

- [1] Hantes EM, Chalatsis IG, Mpakagiannis G. Single-row versus double-row repair in rotator cuff tears. In: *Surgical Recovery*. Rijeka: IntechOpen; 2020
- [2] Fehring EV, Sun J, VanOeveren LS, Keller BK, Matsen FA 3rd. Full-thickness rotator cuff tear prevalence and correlation with function and co-morbidities in patients sixty-five years and older. *Journal of Shoulder and Elbow Surgery*. 2008 Nov-Dec;17(6):881-885. DOI: 10.1016/j.jse.2008.05.039. Epub 2008 Sep 6. PMID: 18774738.
- [3] Moosmayer S, Smith H-J, Tariq R, Larmo A. Prevalence and characteristics of asymptomatic tears of the rotator cuff: An ultrasonographic and clinical study. *The Journal of Bone and Joint Surgery British Volume*. 2009;91(2):196-200
- [4] Teunis T, Lubberts B, Reilly BT, Ring D. A systematic review and pooled analysis of the prevalence of rotator cuff disease with increasing age. *Journal of Shoulder and Elbow Surgery*. 2014;23(12):1913-1921
- [5] Yamaguchi K, Ditsios K, Middleton WD, Hildebolt CF, Galatz LM, Teefey SA. The demographic and morphological features of rotator cuff disease. A comparison of asymptomatic and symptomatic shoulders. *The Journal of Bone and Joint Surgery American Volume*. 2006;88(8):1699-1704
- [6] Abate M, Schiavone C, di Carlo L, Salini V. Prevalence of and risk factors for asymptomatic rotator cuff tears in postmenopausal women. *Menopause (New York, NY)*. 2014;21(3):275-280
- [7] Zumstein MA, Künzler M, Hatta T, Galatz LM, Itoi E. Rotator cuff pathology: State of the art. *Journal of ISAKOS: Joint Disorders & Orthopaedic Sports Medicine*. 2017;2(4):213-221
- [8] Keener JD, Galatz LM, Teefey SA, Middleton WD, Steger-May K, Stobbs-Cucchi G, et al. A prospective evaluation of survivorship of asymptomatic degenerative rotator cuff tears. *The Journal of Bone and Joint Surgery American Volume*. 2015;97(2):89-98
- [9] Pauly S, Stahnke K, Klatte-Schulz F, Wildemann B, Scheibel M, Greiner S. Do patient age and sex influence tendon cell biology and clinical/radiographic outcomes after rotator cuff repair? *The American Journal of Sports Medicine*. 2015;43(3):549-556
- [10] Milgrom C, Schaffler M, Gilbert S, van Holsbeeck M. Rotator-cuff changes in asymptomatic adults. The effect of age, hand dominance and gender. *The Journal of Bone and Joint Surgery British Volume*. 1995;77(2):296-298
- [11] Liem D, Buschmann VE, Schmidt C, Gosheger G, Vogler T, Schulte TL, et al. The prevalence of rotator cuff tears: Is the contralateral shoulder at risk? *The American Journal of Sports Medicine*. 2014;42(4):826-830
- [12] Yamamoto A, Takagishi K, Osawa T, Yanagawa T, Nakajima D, Shitara H, et al. Prevalence and risk factors of a rotator cuff tear in the general population. *Journal of Shoulder and Elbow Surgery*. 2010;19(1):116-120
- [13] Kim KC, Shin HD, Cha SM, Park JY. Repair integrity and functional outcome after arthroscopic conversion to a full-thickness rotator cuff tear: Articular-versus bursal-side partial tears. *The American Journal of Sports Medicine*. 2014;42(2):451-456

- [14] Lee TQ. Current biomechanical concepts for rotator cuff repair. *Clinics in Orthopedic Surgery*. 2013;**5**(2):89-97
- [15] Lindley K, Jones GL. Outcomes of arthroscopic versus open rotator cuff repair: A systematic review of the literature. *American Journal of Orthopedics (Belle Mead, NJ)*. 2010;**39**(12):592-600
- [16] Neer CS. Anterior acromioplasty for the chronic impingement syndrome in the shoulder: A preliminary report. *The Journal of Bone and Joint Surgery American volume*. 1972;**54**(1):41-50
- [17] Cofield RH. Subscapular muscle transposition for repair of chronic rotator cuff tears. *Surgery, Gynecology & Obstetrics*. 1982;**154**(5):667-672
- [18] Kuhn JE, Dunn WR, Ma B, Wright RW, Jones G, Spencer EE, et al. Interobserver agreement in the classification of rotator cuff tears. *The American Journal of Sports Medicine*. 2007;**35**(3):437-441
- [19] Lädermann A, Burkhart SS, Hoffmeyer P, Neyton L, Collin P, Yates E, et al. Classification of full-thickness rotator cuff lesions: A review. *EFORT Open Reviews*. 2016;**1**(12):420-430
- [20] Ellman H, Kay SP, Wirth M. Arthroscopic treatment of full-thickness rotator cuff tears: 2- to 7-year follow-up study. *Arthroscopy: The Journal of Arthroscopic & Related Surgery: Official Publication of the Arthroscopy Association of North America and the International Arthroscopy Association*. 1993;**9**(2):195-200
- [21] Ellman H. Diagnosis and treatment of incomplete rotator cuff tears. *Clinical Orthopaedics and Related Research*. 1990;**254**:64-74
- [22] Fox JA, Cole BJ, Romeo AA, Meininger AK, Williams JM, Glenn RE, et al. Articular cartilage thickness of the humeral head: An anatomic study. *Orthopedics*. 2008;**31**(3):216
- [23] Patte D. Classification of rotator cuff lesions. *Clinical Orthopaedics and Related Research*. 1990;**254**:81-86
- [24] Goutallier D, Postel JM, Bernageau J, Lavau L, Voisin MC. Fatty muscle degeneration in cuff ruptures. Pre- and Postoperative Evaluation by CT scan. *Clinical Orthopaedics and Related Research*. 1994;**304**:78-83
- [25] Mall NA, Kim HM, Keener JD, Steger-May K, Teefey SA, Middleton WD, et al. Symptomatic progression of asymptomatic rotator cuff tears: A prospective study of clinical and sonographic variables. *The Journal of Bone and Joint Surgery American volume*. 2010;**92**(16):2623-2633
- [26] Millett PJ, Warth RJ, Dornan GJ, Lee JT, Spiegl UJ. Clinical and structural outcomes after arthroscopic single-row versus double-row rotator cuff repair: A systematic review and meta-analysis of level I randomized clinical trials. *Journal of Shoulder and Elbow Surgery*. 2014;**23**(4):586-597
- [27] Gilotra M, O'Brien MJ, Savoie FH. Arthroscopic rotator cuff repair: Indication and technique. *Instructional Course Lectures*. 2016;**65**:83-92
- [28] Cole BJ, ElAttrache NS, Anbari A. Arthroscopic rotator cuff repairs: An anatomic and biomechanical rationale for different suture-anchor repair configurations. *Arthroscopy: The Journal of Arthroscopic and Related Surgery*. 2007;**23**(6):662-669
- [29] Neviaser AS, Charen DA, Cotter JM, Harrison AK, Cagle PJ, Flatow EL.

Retrospective review of open and arthroscopic repair of anterosuperior rotator cuff tears with subscapularis involvement: A single surgeon's experience. *Journal of Shoulder and Elbow Surgery*. 2020;**29**(5):893-897

[30] Hasler A, Beeler S, Götschi T, Catanzaro S, Jost B, Gerber C. No difference in long-term outcome between open and arthroscopic rotator cuff repair: A prospective, randomized study. *JSES International*. 2020;**4**(4):818-825

[31] Nazari G, MacDermid JC, Bryant D, Dewan N, Athwal GS. Effects of arthroscopic vs. mini-open rotator cuff repair on function, pain & range of motion. A systematic review and meta-analysis. *PLoS One*. 2019 Oct 31;**14**(10):e0222953. DOI: 10.1371/journal.pone.0222953. PMID: 31671101; PMCID: PMC6822715.

[32] Bayle X, Pham TT, Faruch M, Gobet A, Mansat P, Bonnevalle N. No difference in outcome for open versus arthroscopic rotator cuff repair: A prospective comparative trial. *Archives of Orthopaedic and Trauma Surgery*. 2017;**137**(12):1707-1712

[33] Barnes LA, Kim HM, Caldwell JM, Buza J, Ahmad CS, Bigliani LU, Levine WN. Satisfaction, function and repair integrity after arthroscopic versus mini-open rotator cuff repair. *Bone Joint J*. 2017 Feb;**99**(2):245-249. DOI: 10.1302/0301-620X.99B2.BJJ-2016-0055.R1. PMID: 28148668.

[34] Ma CB, Comerford L, Wilson J, Puttlitz CM. Biomechanical evaluation of arthroscopic rotator cuff repairs: Double-row compared with single-row fixation. *The Journal of Bone and Joint Surgery American Volume*. 2006;**88**(2):403-410

[35] Mazzocca AD, Millett PJ, Guanche CA, Santangelo SA, Arciero RA.

Arthroscopic single-row versus double-row suture anchor rotator cuff repair. *The American Journal of Sports Medicine*. 2005;**33**(12):1861-1868

[36] Kim DH, Elattrache NS, Tibone JE, Jun B-J, DeLaMora SN, Kvitne RS, et al. Biomechanical comparison of a single-row versus double-row suture anchor technique for rotator cuff repair. *The American Journal of Sports Medicine*. 2006;**34**(3):407-414

[37] Deveci A. What is wrong in comparison of single- and double-row repairs in rotator cuff tears? *European Journal of Orthopaedic Surgery and Traumatology*. 2019;**29**:1589-1590

[38] Maassen NH, Somerson JS. A majority of single versus double-row rotator cuff repair comparisons fail to consider modern single-row techniques: A systematic review. *JBJS Reviews*. 2020;**8**(5):e0203

[39] Park MC, Cadet ER, Levine WN, Bigliani LU, Ahmad CS. Tendon-to-bone pressure distributions at a repaired rotator cuff footprint using transosseous suture and suture anchor fixation techniques. *The American Journal of Sports Medicine*. 2005;**33**(8):1154-1159

[40] Cummins CA, Appleyard RC, Strickland S, Haen P-S, Chen S, Murrell GAC. Rotator cuff repair: An ex vivo analysis of suture anchor repair techniques on initial load to failure. *Arthroscopy: The Journal of Arthroscopic & Related Surgery: Official Publication of the Arthroscopy Association of North America and the International Arthroscopy Association*. 2005;**21**(10):1236-1241

[41] Apreleva M, Ozbaydar M, Fitzgibbons PG, Warner JJ. Rotator cuff tears: the effect of the reconstruction method on three-dimensional repair site area. *Arthroscopy*. 2002

May-Jun;18(5):519-526. DOI: 10.1053/jars.2002.32930. PMID: 11987064.

[42] Ahmad CS, Stewart AM, Izquierdo R, Bigliani LU. Tendon-bone interface motion in transosseous suture and suture anchor rotator cuff repair techniques. *The American Journal of Sports Medicine*. 2005;33(11):1667-1671

[43] Ryu RKN. Arthroscopic transosseous suture repair and single-row anchor fixation for rotator cuff lesions did not differ for pain, function, or rotator-cuff integrity at 15 months. *The Journal of Bone and Joint Surgery. American Volume*. 2017;99:1943

[44] Zafra M, Uceda P, Muñoz-Luna F, Muñoz-López RC, Font P. Arthroscopic repair of partial-thickness articular surface rotator cuff tears: Single-row transtendon technique versus double-row suture bridge (transosseous equivalent) fixation: Results from a prospective randomized study. *Archives of Orthopaedic and Trauma Surgery* [Internet]. 2020;140(8):1065-1071. Available from: <http://www.ncbi.nlm.nih.gov/pubmed/32170453>

[45] Waltrip RL, Zheng N, Dugas JR, Andrews JR. Rotator cuff repair. A biomechanical comparison of three techniques. *Am J Sports Med*. 2003 Jul-Aug;31(4):493-497. DOI: 10.1177/03635465030310040301. PMID: 12860534.

[46] Siskosky MJ, ElAttrache NS, Chu E, Tibone JE, Lee TQ. Biomechanical evaluation of the “transosseous equivalent” rotator cuff repair technique using the PushLock for lateral fixation compared to the double-row technique. In: Presented at the Annual Meeting of the American Academy of Orthopaedic Surgeons, San Diego, CA, February 14-18. 2007

[47] Costic RS, Brucker PU, Smolinski PJ, Gilbertson LG, Ro-dosky

MW. Arthroscopic double row anchor repair of fullthickness rotator cuff tear: Footprint restoration and biomechanical properties. In: Presented at the Annual Meeting of the Orthopaedic Research Society, Chicago, IL, March 19-22. 2006

[48] Park MC, ElAttrache NS, Tibone JE, Ahmad CS, Jun BJ, Lee TQ. Footprint contact biomechanics for a new arthroscopic transosseous-equivalent rotator cuff repair technique compared to a double-row technique arthroscopic rotator cuff repair. In: Presented at the Annual Meeting of the American Academy of Orthopaedic Surgeons, Chicago, IL, March 22-26. 2006

[49] Yamakado K. Two techniques for treating medium-sized supraspinatus tears: The medially based single-row technique and the suture bridge technique. *JBJS Essential Surgical Techniques*. 2021 Jun 8;11(2):e20.00004. DOI: 10.2106/JBJS.ST.20.00004. PMID: 34277130; PMCID: PMC8280021.

[50] Plachel F, Siegert P, Rüttershoff K, Thiele K, Akgün D, Moroder P, et al. Long-term results of arthroscopic rotator cuff repair: A follow-up study comparing single-row versus double-row fixation techniques. *American Journal of Sports Medicine*. 2020;48(7):1568-1574

[51] Virk MS, Bruce B, Hussey KE, Thomas JM, Luthringer TA, Shewman EF, et al. Biomechanical performance of medial row suture placement relative to the musculotendinous junction in transosseous equivalent suture bridge double-row rotator cuff repair. *Arthroscopy: The Journal of Arthroscopic and Related Surgery*. 2017;33(2):242-250

[52] Barber FA. Editorial commentary: Musculotendinous junction mattress sutures are inefficient. *Arthroscopy: The Journal of Arthroscopic and Related Surgery*. 2017;33:251-253

[53] Meisel AF, Henninger HB, Barber FA, Getelman MH. Biomechanical comparison of standard and linked single-row rotator cuff repairs in a human cadaver model. *Arthroscopy: The Journal of Arthroscopic and Related Surgery*. 2017;**33**(5):938-944

[54] Baleani M, Ohman C, Guandalini L, Rotini R, Giavaresi G, Traina F, et al. Comparative study of different tendon grasping techniques for arthroscopic repair of the rotator cuff. *Clinical Biomechanics* (Bristol, Avon). 2006;**21**(8):799-803

[55] Galatz LM, Ball CM, Teefey SA, Middleton WD, Yamaguchi K. The outcome and repair integrity of completely arthroscopically repaired large and massive rotator cuff tears. *The Journal of Bone and Joint Surgery American Volume*. 2004;**86**(2):219-224

[56] Wetzler MJ. Editorial commentary: Belt and suspenders—Linked single-row rotator cuff repair. *Arthroscopy: The Journal of Arthroscopic and Related Surgery*. 2017;**33**:945

[57] Noyes MP, Lederman E, Adams CR, Denard PJ. Triple-loaded suture anchors versus a knotless rip stop construct in a single-row rotator cuff repair model. *Arthroscopy: The Journal of Arthroscopic and Related Surgery*. 2018;**34**(5):1414-1420

[58] Noyes MP, Ladermann A, Denard PJ. Functional outcome and healing with a load-sharing rip-stop repair compared with a single-row repair for large and massive rotator cuff tears. *Arthroscopy: The Journal of Arthroscopic and Related Surgery*. 2019;**35**(8):2295-2300