

We are IntechOpen, the world's leading publisher of Open Access books Built by scientists, for scientists

6,900

Open access books available

186,000

International authors and editors

200M

Downloads

Our authors are among the

154

Countries delivered to

TOP 1%

most cited scientists

12.2%

Contributors from top 500 universities



WEB OF SCIENCE™

Selection of our books indexed in the Book Citation Index
in Web of Science™ Core Collection (BKCI)

Interested in publishing with us?
Contact book.department@intechopen.com

Numbers displayed above are based on latest data collected.
For more information visit www.intechopen.com



Transabdominal Preperitoneal (TAPP) Inguinal Hernia Repair

*Giovambattista Caruso, Giuseppe Evola,
Salvatore Antonio Maria Benfatto and Mariapia Gangemi*

Abstract

The inguinal hernia repair is one of the most frequent surgical procedures: in the world, even year, at least 20.000.000 inguinal hernia repair procedures are performed. Although the laparoscopic approach is widely recognized as a valid treatment for many diseases and some laparoscopic surgical procedures have become gold standard techniques (e. g. cholecystectomy, appendectomy, gastro-esophageal junction surgery), the minimally invasive approach for groin hernia treatment is still very controversial today, but in the last few years, it tends to become the standard practice for 1 day surgery. We present here the technique of laparoscopic Transabdominal Preperitoneal approach (TAPP). The surgical technique is described step-by-step, including surgical details and the new concept of “inverted Y” to achieve the “critical view of safety” for laparoscopic inguinal hernia repair.

Keywords: TAPP, inguinal hernia, minimally invasive surgery, transabdominal preperitoneal approach, laparoscopy

1. Introduction

Inguinal hernia repair is one of the most frequent surgical procedures performed around the world; around 20 million hernioplasties are done every year. However, although laparoscopic inguinal hernia repair was initiated more than 28 years ago, most hernioplasties are still performed with an open approach [1]. Although the laparoscopic approach is widely recognized as a valid treatment for many diseases and some laparoscopic surgical procedures have become gold standard techniques (e. g. cholecystectomy, appendectomy, gastro-esophageal junction surgery), the minimally invasive approach for groin hernia treatment is still very controversial today. The main pretexts are the higher costs, the use of general anesthesia and the possible higher rate of major complications associated with laparoscopic procedures. Another reticence related to laparoscopic approach is the greater surgical complexity linked to need to recognize a “new” anatomy of the posterior inguinal wall, which is still unusual for general surgeons. Much more the choice of laparoscopic approach (TransAbdominal PrePeritoneal (TAPP) versus Totally Extraperitoneal (TEP)) is also controversial [2]. We present herein the TAPP procedure focusing on tips and tricks for better outcomes [3].

2. Anatomy

The abdominal wall is an uneven area with natural openings and areas of weakness that can be the site of hernias formed by the externalization of a peritoneal sac that can contain viscera. The inguinal area has a complex anatomical entity, due to its configuration, it constitutes the passage of intra-abdominal elements toward the outside. This is the starting point for all hernias.

The inguinal area is the main weak point of the anterior abdominal wall and corresponds to the pectineus orifice, embryologically weakened by the passage of the spermatic cord in men (inguinal canal) and of the femoral vessels (femoral canal).

Perfect knowledge of the anatomy of the groin region is the key to treating hernias. Several works have been dedicated to this region with evidence of a natural parietal weakness. According to recent studies on the anatomy of the groin area, Fruchaud has confirmed that all inguinal hernias pass through a single parietal orifice called the myopectineal orifice delimited medially by rectus abdominis muscle, inferiorly by pectineum ligament, laterally by Psoas muscle and superiorly by Transversus Abdominis and Internal oblique muscle (Transverse arch). The inguinal ligament passes over this structure dividing it into two portions, the inguinal region above (crossed by the spermatic cord) and the crural region below (crossed by femoral vessels). It is internally covered by the transverse fascia only. Observed from inside the abdomen with the peritoneum intact, the lower part of the anterior abdominal wall is usually divided into three fossae, separated by the same number of folds or ligaments formed by different protruding structures. On the median line we identify the Urachus, also called median umbilical ligament. Lateral to the Urachus we find the lateral umbilical ligament, usually the most evident of the three folds. The ligament is a remnant of the umbilical artery, now obliterated, which leads from the iliac artery toward the navel. Finally, the outermost fold, corresponding to the inferior epigastric vessels, is the least protruding. The most common classification of the inguinal hernias still uses these three folds as landmarks. Indirect inguinal hernias are those that originate laterally to the epigastric vessels, direct inguinal hernias are those medial to them, and the supravesical hernias are those originate between the median and umbilical ligaments. Femoral hernias are located below this plane, below the iliopubic tract and through a space around the femoral sheath. On very rare occasions, obturator hernias are found, linked to a defect of the obturator membrane of the iliac bone. Through the intact parietal peritoneum, it is possible to recognize the round ligament in women and the vas deferens in men. Both proceed obliquely from the deep part of the pelvis upwards and from inside to the outside, to emerge from the abdomen through the internal inguinal orifice crossing the epigastric vessels. The transabdominal preperitoneal laparoscopic hernioplasty requires the preparation of a very large peritoneal flap. To do this, it is very important to know how to recognize and identify the extraperitoneal spaces of the pelvis. Medially, between the parietal peritoneum and the transversalis fascia, is the Retzius space, consisting of variable amount of adipose tissue. It is usually an avascular space except in the lower part where there are venous anastomoses between the epigastric, obturator and iliopubic vessels. Although the inguinal ligament is not visible, however, Cooper's ligament is visible and palpable with laparoscopic instruments even in obese subjects. This important reference point is located 1 cm medial and inferior to the origin of the epigastric vessels [4].

In males, the spermatic vessels join an obtuse angle with the deferent conduct, and also exit through the internal inguinal orifice, to form outside it, with the the fasciae and muscular fibers enveloping it, the spermatic cord.

The *Inverted Y* created with inferior epigastric vessels (superiorly), vas deferens (medially) and spermatic vessels (laterally) allows to better understand and recognize the anatomical structures.

Recognition of these elements, in fact, is the basis for understanding the technical steps for repairs all types of inguinal hernias by laparoscopy.

The inferior epigastric vessels separate the medial and lateral inguinal regions, permitting the classification of direct inguinal hernias (collapse of the transversalis fascia, medially to the epigastric vessels), and indirect (enlargement of deep inguinal ring, laterally to the epigastric vessels).

Another important anatomical landmark is the iliopubic tract, which represents the intra-abdominal view of the inguinal ligament. It extends from the anterosuperior iliac crest to the pectineum (Cooper's) ligament and separates the superior and inferior inguinal spaces. The upper portion is the point of onset of inguinal hernias (direct, indirect, mixed, supravesical). Femoral or crural hernias, as well as the obturators, originate in the lower portion of the inguinal space, below the iliopubic tract.

Identification of inverted Y elements and iliopubic tract, that passes horizontally through the deep inguinal ring at the center of the inverted Y, permit visualization of five areas (*the Five Triangles*) (**Figure 1**).

Disaster or Doom triangle, formed by vas deferens, medially, and spermatic vessels, laterally, it corresponds to the location of the external iliac vessels.

Pain triangle (or of the nerves), delimited, medially, by spermatic vessels and, laterally and superiorly, by iliopubic tract; it represents the passage of lateral cutaneous nerve of the thigh, femoral branch of the genitofemoral nerve and femoral nerve.

Triangle of Indirect hernias: correspond to the deep inguinal ring, the source of indirect hernias. It is formed by inferior epigastric vessels, medially, and by iliopubic tract inferiorly and laterally.

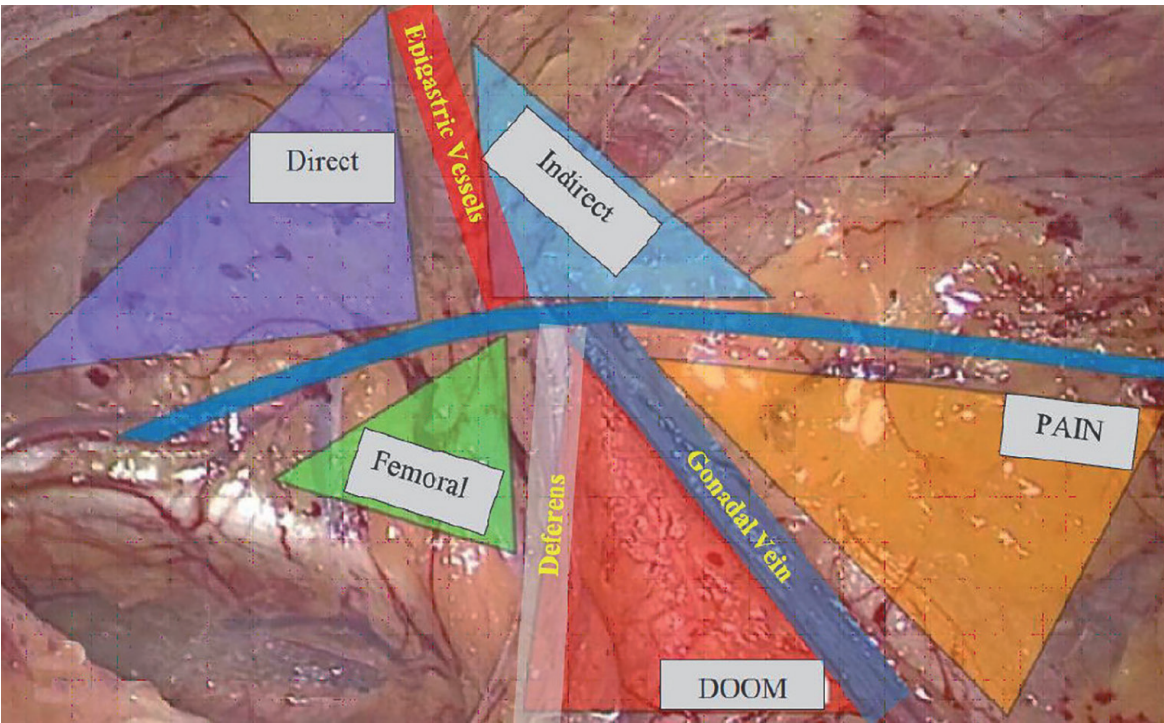


Figure 1.
The Inverted Y and the Five Triangles.

Hesselbach's triangle or direct hernias: delimited medially by lateral border of the rectus abdominis muscle, laterally by the inferior epigastric vessels, inferiorly by the iliopubic tract. It is the site of occurrence of direct hernias.

Triangle of Femoral hernias: is not a true triangle but identifies the area corresponding to the ostium of the femoral vein, delimited, at the top, by iliopubic tract, laterally by the external iliac vein, at the bottom by pectineum ligament and medially by the lacunar ligament.

This didactic way of posterior visualization of the miopectineal orifice, defining the inverted Y and the five triangles, facilitates the anatomical understanding of inguinocrural region and of all hernia defects that may occur [5].

3. Indications and contraindications

With very few exceptions the TAPP approach can be performed in theory for any hernia, even in strangulated or incarcerated cases; however, the indication depends on the surgeon's clinical judgment and skills. The best indications according to Nyhus classification are:

- Type 3 and 4 hernias
- Bilateral hernias
- Hernias in obese patients
- Hernias in subjects with intense physical activity (sport, strenuous working)
- Recurrence of hernia after open repairs.

They are very few contraindications for these procedures, such as:

- Intolerance to capnoperitoneum (severe cardiopathies or severe pneumopathies)
- Extensive intra-abdominal adhesion
- Large scrotal hernia
- After radical prostatectomy
- Strangulated or perforated hernia with intercurrent sepsis
- Severe ascites
- Recurrence of hernia after laparoscopic repair
- Pediatric patients
- Pregnancy after the second trimester
- Severe clotting disorders

4. Preoperative preparation

The patient has to be carefully prepared for the operation. The evaluation of comorbidities as well as an adequate skin preparation is mandatory. The patient has to be informed about the details of the surgical procedure and the possible negative outcomes, as the latest guidelines recommended [6].

4.1 Evaluation of the operative risk

Using ASA (American Society of Anesthetist) Score. From the point of view of comorbidities, there are no “absolute” contraindications for TAPP. The anticoagulant oral therapy is replaced by low molecular weight heparins (LMWH) and the procedure is usually performed at least 12 hours after the last LMWH dose. The new anticoagulant oral drugs (e. g. Dabigatran etexilate - Pradaxa[®]; Apixaban - Eliquis[®]; Rivaroxaban - Xarelto[®]) is stopped and replaced by LMWH at least 5 days before the procedure. Clopidogrel or ticlopidine are stopped and replaced by aspirin 5 to 7 days before the procedure and higher doses of aspirin are reduced to 75 mg/day 3 to 7 days before the procedure [7].

4.2 Skin preparation

a preoperative antiseptic shower is performed on the eve of the intervention. The hair is removed, half an hour before the surgery, from middle thorax until the upper third of the thighs using an electric barber clipper. Alcohol based solutions (Iodine or Chlorhexidine gluconate in case of iodine allergy) are used for skin preparation after anesthetic induction [8].

4.3 Urinary Catheter

Always empty the bladder to facilitate the dissection in the Retzius space and to avoid bladder injuries. In selected cases (e. g. bilateral hernia, recurrent hernia), a urinary catheter can be left throughout the surgery [6].

4.4 Patient and surgical team position

The patient is placed in the supine position, with both arms along the body and fixed to the operating table. At the start of the surgery a Trendelenburg position (15–20°) is given with lateral inclination opposite to the hernial defect. The surgical team is organized with the surgery on the contralateral side to the hernia to be repaired and the camera operator is positioned on the same side, or in the side as the hernia. The scrub nurse stands in front of the surgeon near the patient's feet. In case of bilateral inguinal hernioplasty, the surgical team switch positions when they have finished the first hernia (**Figure 2**). In case of bilateral hernioplasty it is preferable to use a column with two monitors; this is to avoid changing of the laparoscopic column between one side and the other [9].

4.5 Anesthesia

Although we have reported successful cases of laparoscopic inguinal hernioplasty under anesthesia with peridural blockade and sedation, as a general rule we prefer

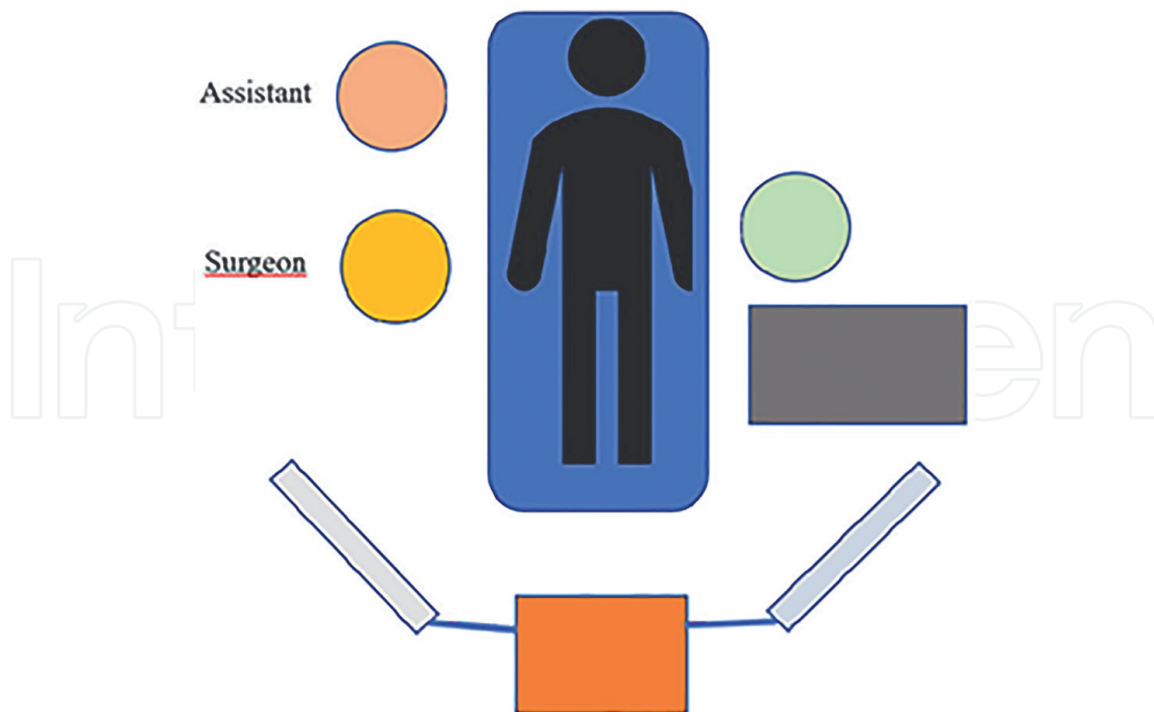


Figure 2.
Surgical team position.

general anesthesia for the patient, as muscle relaxation improves surgical maneuvers and, again, orotracheal intubation protects the airways from vomiting or regurgitation favored by increased intra-abdominal pressure. The preoperative antibiotic prophylaxis (single dose of Cefazoline 2 g during anesthetic induction) is reserved in presence of high-risk factors for wound infection based on patient (recurrence, advanced age, immune deficiency) or surgical (forecast of long surgical intervention, use of drains) factors [10].

4.6 Laparoscopic instruments

Three trocars are necessary, one of 10 mm (optical) and two of 5 mm (for the instruments), as well as common laparoscopic instruments (monopolar scissor, monopolar hook, two atraumatic fenestrated graspers, needle holder, 5 mm Endo peanut, 5 mm disposable absorbable screw type stapler device) and “open surgery” instruments (two Kelly, two Halsted, Farabeuf retractors, scissors and Hegar needle holder). A bipolar grasper and a suction-irrigation device could be also necessary. Usually we use a 30° laparoscope, but a 0° is also feasible.

5. Surgical procedure

5.1 Pneumoperitoneum and trocar placement

Although many surgeons create pneumoperitoneum with Verres needle, we prefer an open technique, using a 10 mm Hasson trocar, through an upper horizontal paraumbilical incision. This incision gives us excellent esthetic results. Under direct vision, two additional 5 mm operating trocars are placed in each flank, in a horizontal

plane with the umbilicus. It must be remembered that a small number of patients present with a contralateral hernia although not diagnosed preoperatively. This trocars position is convenient for both unilateral and bilateral hernias (**Figure 3**).

5.2 Abdominal Exploration

The aim of the laparoscopic exploration is to identify the superficial anatomical landmarks (Urachus, umbilical folds, epigastric vessels, spermatic vessels, vas deferens or uterine round ligament) and the site and type of hernia. The two “dangerous triangles”, vascular and pain triangles, must be correctly identified [2]. To perform the exploration and to ensure a good exposure of the inguinal region the position of the operating table is kept in 15° Trendelenburg with 15° lateral rotation to the side opposite the hernia (**Figure 4**).

5.3 Peritoneal incision

The TAPP procedure starts with peritoneal cut 2 cm above and 1 cm medial from the anterior superior iliac spine and continue horizontally, in medial direction to the lateral umbilical ligament (umbilical artery), then the incision continues vertically along the umbilical ligament, using the monopolar hook or scissors (**Figure 5**). This creates an “L” shape incision. After the first peritoneal cut, the CO2 pneumoperitoneum will enter into the preperitoneal space, facilitating the dissection [11].

5.4 Dissection of lower Peritoneal Flap

The aim of this step is to create a preperitoneal pocket to ensure the best positioning of the mesh. This step consists of three phases: 1) Medial dissection over the Retzius space, 2) Lateral dissection on the space of Bogros, 3) Central dissection over the site of the hernia and its hernial sac. We usually start with the medial dissection (Retzius space), dividing the conjunctive fibers in contact with the rectus abdominal

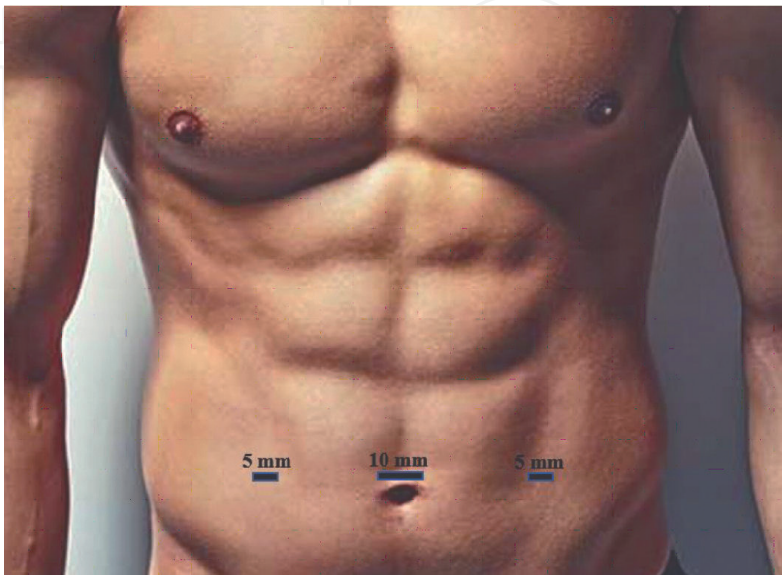


Figure 3.
Trocar's position.

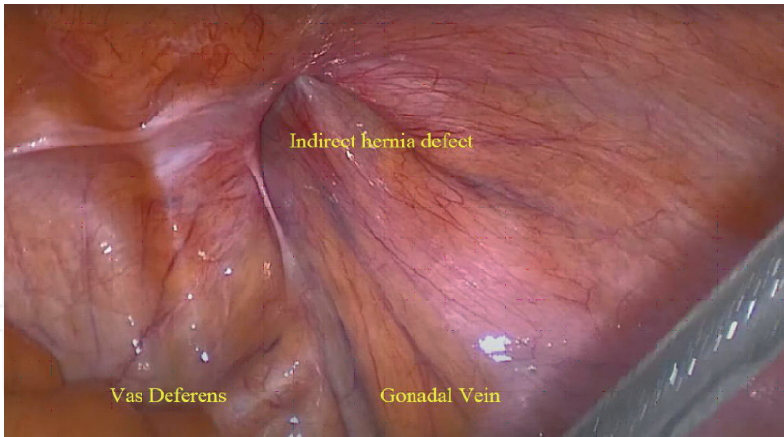


Figure 4.
The intra-abdominal view.

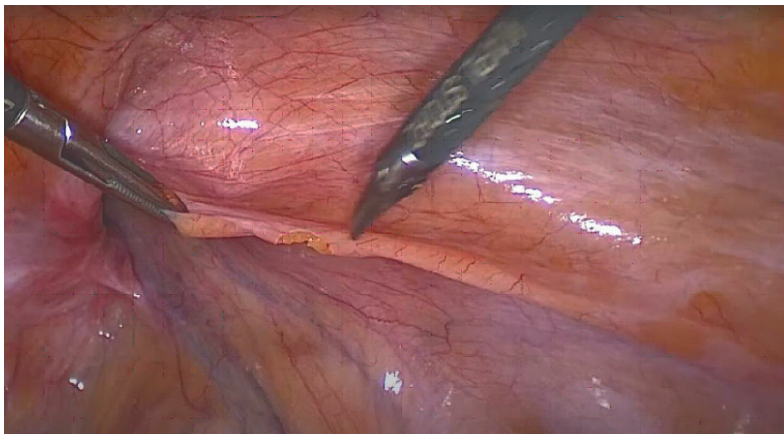


Figure 5.
Peritoneum incision.

muscle to avoid bladder injuries; this way the bladder is detached from the abdominal rectus muscles. The dissection is conducted to the pubis to expose Cooper’s ligament (**Figures 6, 7**), which we almost invariably find on dissecting 1 cm medial and 1 cm inferior to the origin of the deep epigastric vessels. Usually, in contact with the pubic bone there are several fine vessels originated from the corona mortis. We prefer to

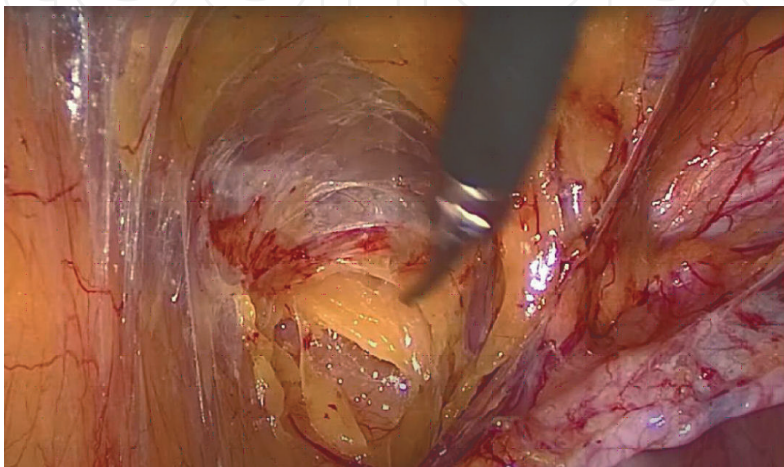


Figure 6.
Medial dissection.

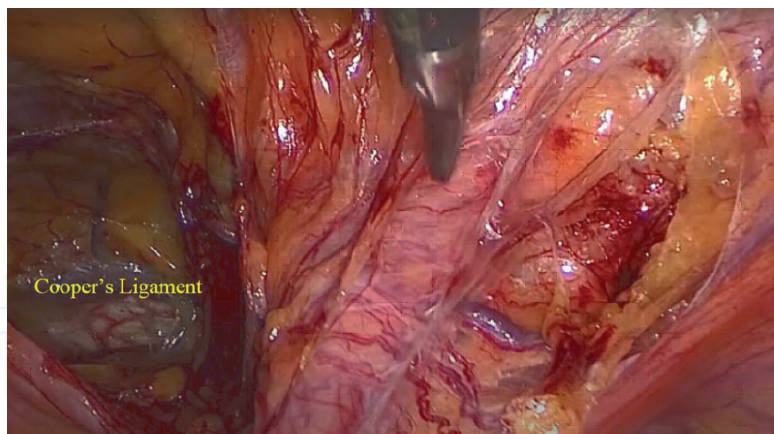


Figure 7.
Medial dissection.

coagulate them to avoid further bleeding during the dissection or mesh stapling. The dissection is then conducted laterally on the space of Bogros, tractioning the peritoneum in the medial direction, from the epigastric vessels until the spermatic vessels (**Figure 8**). The sac dissection is performed using traction contra-traction maneuvers and fine coagulation. To avoid the injuries of the ductus deferens and spermatic vessels the sac dissection always starts anteriorly (**Figures 9, 10**). To facilitate dissection of the peritoneal flap, endo peanuts can be helped. When the hernia sac is very large, we prefer to cut and leave it in situ. This avoids the risk of involuntary injury to the elements of the spermatic cord, reducing the risk of ischemic orchitis, inguino-scrotal hematoma and/or testicular atrophy. However, the incidence of inguino-scrotal seroma or “pseudo-hydrocele” is higher when this maneuver is adopted. We always check for hernia lipoma as recommended in the literature [6]. It is necessary to extend the dissection caudally to the obturator fossa to identify eventual occult obturator hernia especially in women. The preperitoneal dissection ends when the anatomic landmarks previous described are well exposed and the two dangerous triangles (vascular and of the pain) can be identified (**Figure 11**). For large parietal defects, the transversalis fascia has to be inverted and stapled to the Cooper ligament. This simple maneuver seems to decrease the postoperative seroma rate [12].

5.5 Mesh placement

One of the most issues in the laparoscopic approach to inguinal hernioplasty is the need to use a prosthetic mesh to fully cover the hernial defect and all possible herniation sites in the area. The mesh should reach at least the pubic symphysis medially and the iliopsoas muscle laterally. Inferiorly it should reach 1–2 cm below the pubis and superiorly cover the anterior abdominal wall, exceeding the hernial defect by 3–4 cm. We usually use a large “anatomical pre-shaped” (12 x 15 cm) polypropylene mesh which is inserted from the optical trocar. The prosthesis is rolled up on its long side and grasping it with the grasper at the medial end is easily introduced through the Hasson into the abdomen. The medial end of the prosthesis is brought over the Cooper. The prosthesis is then unrolled and the medial head is anchored to the Cooper with the absorbable tacking staples, taking care not to injure the “corona mortis vessels” (**Figure 12**). This first tack facilitates further unrolling of the prosthesis and its placement in the preperitoneal pocket and fixation, with the absorbable tacking staples, on the upper and medial edge, as well as at the level of the iliac

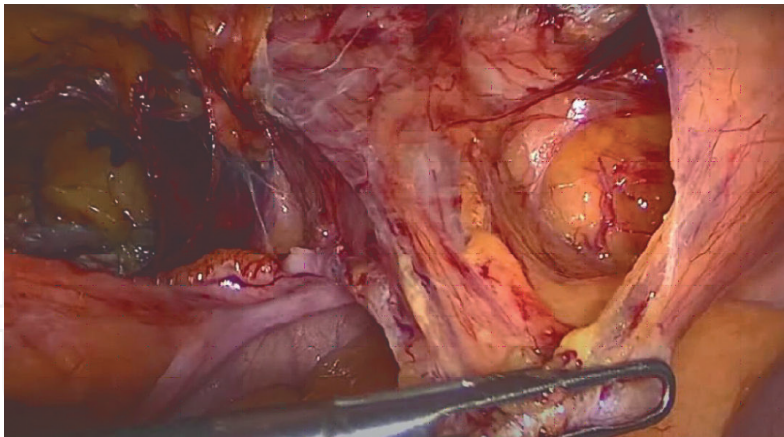


Figure 8.
Lateral dissection.

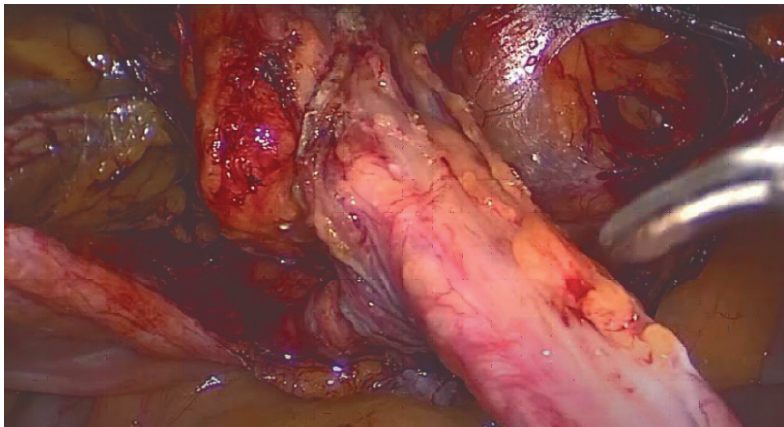


Figure 9.
Sac dissection.

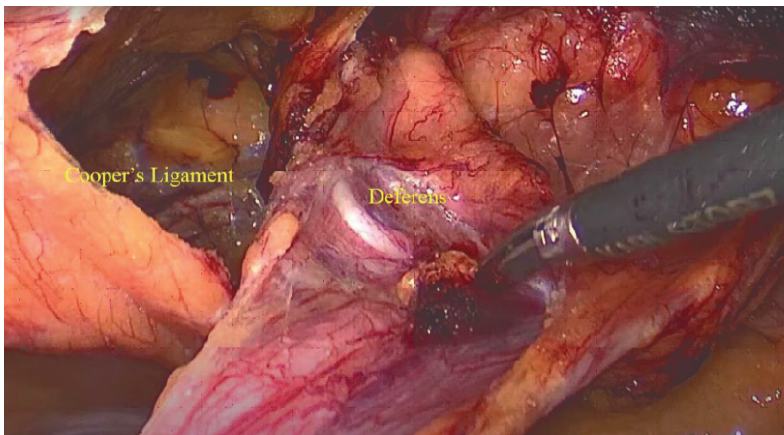


Figure 10.
Sac dissection.

spine (**Figures 13, 14**). Some alternatives to staple fixation are noted in the literature: the use of fibrin glue [13], the self-gripping mesh [14], trans parietal sutures [15], or, even, the recent no fixation technique [16]. For bilateral hernia we use two separate meshes covering the bilateral defects overlapping and stapled together on the median line; this technique is easier than the deployment of one single large mesh.

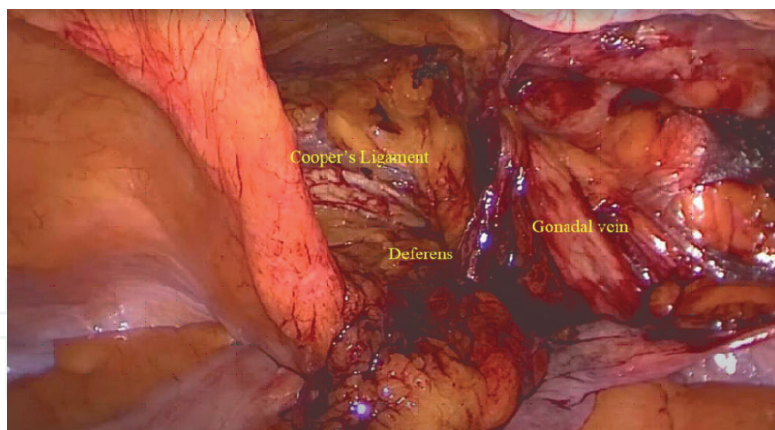


Figure 11.
Intraoperative inverted Y.




Figure 12.
Mesh fixation to Cooper's ligament.

5.6 Drainage

Some authors emphasize the role of suction-draining in decreasing postoperative seroma and hematoma rates, as the release of carbon dioxide pressure is followed by bleeding from capillaries. We use 24 hours suction-drainage for selected cases: difficult dissection, anticoagulant or antiplatelet therapy, intraoperative hemorrhage, partial hernial sac resection [17].

5.7 Peritoneal closure

Our routine is to close the peritoneal flap with the aid of helicoidal absorbable tacks. This maneuver is fast and cost-effective. Alternatively, we also close the flap with continuous suture (2–0 monofilament or 3–0 barbed suture) (**Figure 15**). Before start the peritoneal closure, we lower capnoperitoneum pressure to 8 mmHg to facilitate the approximation of the edges of the peritoneum under less tension [6, 11, 16].

5.8 Abdominal closure

After the careful examination of the peritoneal closure, the trocars are removed under laparoscopic control. The aponevrosis is closed at umbilical site with a purse

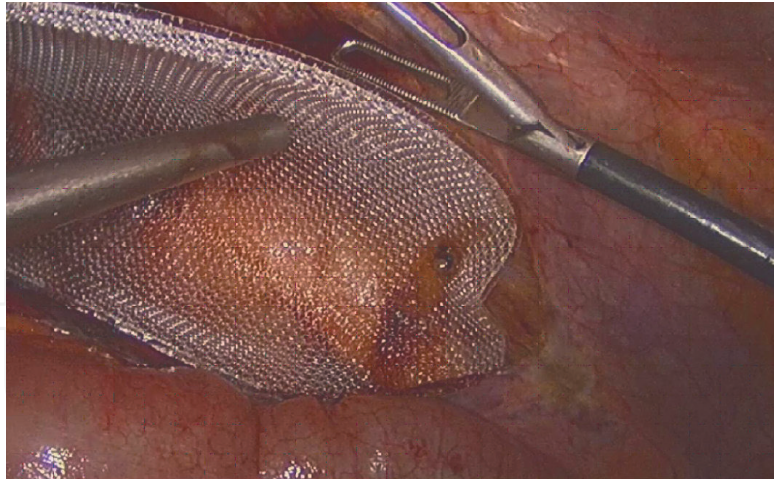


Figure 13.
Lateral fixation of the mesh.

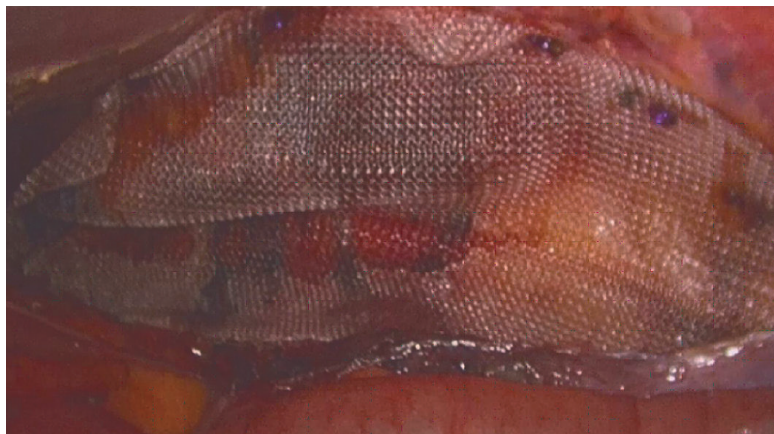

Figure 14.
Implanted mesh.

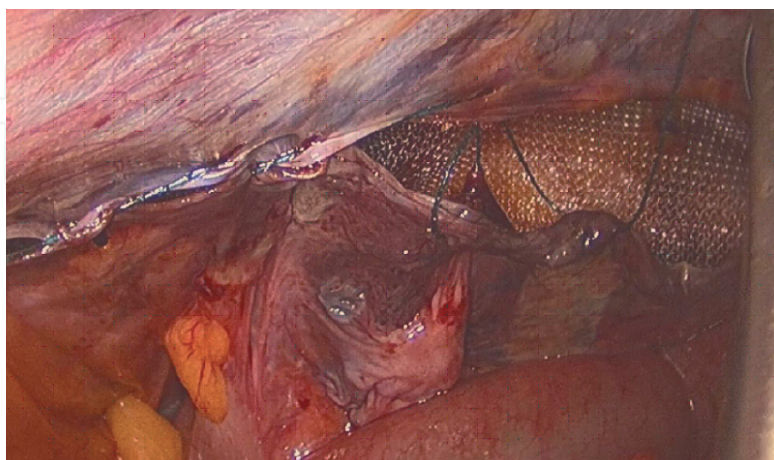


Figure 15.
Peritoneum closure.

string suture with absorbable suture. The operative wounds are infiltrated with long-acting anesthetics (Levobupivacaine) for a better control of postoperative pain. Alternatively, the laparoscopic TAP Block can be used. The skin is closed using inverted fast absorbable sutures or staples.

5.9 Intraoperative complications

Intraoperative bleeding is one of the potential complications of TAPP. The injuries of the deep epigastric vessels, the testicular artery, the gonadal veins or the corona mortis can cause abundant bleeding which, if not controllable by laparoscopy, require immediate conversion to open. Obviously, the lesion of the iliac vessels requires an immediate conversion to laparotomy for vascular control and the relative repair of the damage.

6. Postoperative management

The immediate postoperative analgesic therapy consists in Paracetamol 1000 mg \times 3/day and Ketoralac 30 mg IV \times 2/day. The urinary catheter, if placed, is removed 6 hours after surgery. As soon as the general conditions allow it, the patient is mobilized and invited to walk. The in-hospital stay is 24 hours (Day Surgery). A liquid diet is indicated 4 hours after surgery. We perform a routine thromboembolic disease prophylaxis with low molecular weight heparins (LMWH) therapy for 7 days, for all the patients. We recommend using an ice pack over the repaired groin for the first 48 hours after surgery and maintaining the use of a hernia support tensor for 4–6 weeks. At home, patients continue taking oral analgesic as necessary (Paracetamol, Ketoprofen).

Light physical activity is recommended (walking, slowly climbing one or two flights of stairs) from the first day after surgery, regular physical activity (walks and resumption of work that does not require strenuous physical exertion) is allowed from day 7 or 10, and intense physical activity only from the fourth week after surgery.

In the consulting room, we examine the patients around 7 days after surgery, then 1 month after surgery, and then every 6 months for long-term follow-up.

7. Postoperative complications

These include seromas, hematomas, postoperative chronic pain, infection of wounds, rejection or infection of the mesh, postoperative adherential syndrome, recurrences, testicular atrophy and infertility.

Seroma is the only complication more frequent in laparoscopic technique than in open repairs. While the rate of this complication is about 5.7% in the literature, we reported a 5% rate. Only in voluminous seroma is recommended the aspiration or drainage.

Hematoma is less frequent in laparoscopic hernia repair than in open repairs, with a rate of about 8% and rarely requires drainage or transfusions. In our experience, hematoma was reported in only 0.8% cases.

Chronic pain, defined as persistence of pain 3 months after the operation, is less frequent after TAPP and is related to tack stapled nerve damage. To date no cases of chronic pain in our experience.

The recurrence rate is described between 0.4 and 4.8% and correlates with the degree of experience of the surgeon. A significant and repeated increase in intra-abdominal pressure appears to be the predisposing factor for relapses. In case of recurrence, guidelines recommend open repair, however, many experienced surgeons are able to treat relapses laparoscopically without any problems.

8. Conclusion

TAPP is associated with a better immediate postoperative comfort, less chronic pain and numbness, less mesh infection, as well as a faster return to usual activities. Another advantage of the laparoscopic technique is the possibility of diagnose and to treat during the same operation the occult hernias. The disadvantages of laparoscopic procedures are longer learning curve with higher risk of complications during the first 30–50 procedures and higher direct costs (general anesthesia, laparoscopic equipment, staples); this costs can be recuperated decreasing the indirect costs: shorter hospital stay and faster return to work.

Conflict of interest

The authors declare no conflict of interest.

Author details

Giovambattista Caruso^{1*}, Giuseppe Evola², Salvatore Antonio Maria Benfatto¹ and Mariapia Gangemi³


1 SS. Salvatore Hospital Paternò (ASP Catania), Italy

2 ARNAS Garibaldi Catania, Italy

3 Policlinico Universitario Catania, Italy

*Address all correspondence to: carusogb@inwind.it

IntechOpen

© 2022 The Author(s). Licensee IntechOpen. This chapter is distributed under the terms of the Creative Commons Attribution License (<http://creativecommons.org/licenses/by/3.0>), which permits unrestricted use, distribution, and reproduction in any medium, provided the original work is properly cited. 

References

- [1] Rivas JF et al. Transabdominal preperitoneal (TAPP) inguinal hernia repair: How we do it. *Laparoscopic and Endoscopic Surgery*. 2020;**6**:1-6
- [2] Moldovanu R et al. Laparoscopic transabdominal pre-peritoneal (TAPP) for bilateral inguinal hernia. *Jurnalul de Chirurgie, Iasi*. 2010;**6**(3):373-382
- [3] Moldovanu R, Pavy G. Laparoscopic transabdominal pre-preperitoneal (TAPP) procedure – step-by-step tips and tricks. *Chirurgia*. 2014;**109**:407-415
- [4] Arregui ME. Surgical anatomy of the preperitoneal fasciae, and posterior trasversalis fasciae in the inguinal region. *Hernia*. 1997;**1**:101-110
- [5] Furtado M et al. Systemization of laparoscopic inguinal hernia repair (TAPP) based on a new anatomical concept: inverted Y and five triangles. *ABCD Arq Bras Cir Dig*. 2019;**32**(1):e1426
- [6] Bittner R, Arregui ME, Bisgaard D, Dudai M, Ferzli GS, Fitzgibbons RJ, et al. Guidelines for laparoscopic (TAPP) and endoscopic (TEP) treatment of inguinal hernia. *Surgical Endoscopy*. 2011;**25**(9):2773-2843
- [7] Joubert F, Gillois P, Bouaziz H, Marret E, Iohom G, Albaladejo P. Bleeding complications following peripheral regional anaesthesia in patients treated with anticoagulants or antiplatelet agents: A systematic review. *Anaesthesia Critical Care & Pain Medicine*. 2019;**38**(5):507-516
- [8] Tanner J, Moncaster K, Woodings D. Preoperative hair removal: A systematic review. *Journal of Perioperative Practice*. 2007;**17**(3):118-121 124-132
- [9] Petro CC, Prabhu AS. Preoperative planning and patient optimization. *The Surgical Clinics of North America*. 2018;**98**:483-497
- [10] Martin C et al. Antibiotrophylaxis in surgery and interventional medicine (adult patients). Update 2017. *Anaesthesia Critical Care & Pain Medicine*. 2019;**38**(5):549-562
- [11] Leroy J. Transabdominal preperitoneal approach (TAPP). 2001; 1(3). Available from: <https://websurg.com/en/doi/vd01en2173/>
- [12] Reddy VM, Sutton CD, Bloxham L, Garcea G, Ubhi SS, Robertson GS. Laparoscopic repair of direct inguinal hernia: a new technique that reduces the development of postoperative seroma. *Hernia*. 2007;**11**(5):393-396 Epub 2007 Jun 1
- [13] Lau H. Fibrin sealant versus mechanical stapling for mesh fixation during endoscopic extraperitoneal inguinal hernioplasty: A randomized prospective trial. *Annals of Surgery*. 2005;**242**(5):670-675
- [14] Fumagalli R et al. Self-gripping mesh versus staple fixation in laparoscopic inguinal hernia repair: A prospective comparison. *Surgical Endoscopy*. 2013;**27**(5):1798-1802
- [15] Abdelhamid MS. Transabdominal pre-peritoneal inguinal hernia repair with external fixation. *Hernia*. 2011;**15**(2):185-188 Epub 2011 Feb 11
- [16] Memon MA et al. Laparoscopic inguinal hernia repair: Transabdominal Preperitoneale (TAPP) and Totally Extraperitoneal (TEP). In: Scott-Conner

(CEH), editor. The SAGES Manual
Fundamentals of Laparoscopy,
Thoracoscopy, and GI Endoscopy. New
York: Springer; 2006:467-495

[17] Tamm C, Scheidbach H, Hampe C,
Schneider C, Köckerling F. Totally
Extraperitoneal endoscopic inguinal
hernia repair (TEP). *Surgical Endoscopy*.
2003;**17**(2):190-195