

We are IntechOpen, the world's leading publisher of Open Access books Built by scientists, for scientists

6,900

Open access books available

186,000

International authors and editors

200M

Downloads

Our authors are among the

154

Countries delivered to

TOP 1%

most cited scientists

12.2%

Contributors from top 500 universities



WEB OF SCIENCE™

Selection of our books indexed in the Book Citation Index
in Web of Science™ Core Collection (BKCI)

Interested in publishing with us?
Contact book.department@intechopen.com

Numbers displayed above are based on latest data collected.
For more information visit www.intechopen.com



Evaluation and Management of Ocular Traumas

Arzu Taskiran Comez and Mehmet Ozbas

Abstract

Ocular trauma affecting the anterior segment of the eye including conjunctiva, cornea, sclera, iris, and lens may be chemical, mechanical, or thermal. Although the eyelids and tear film layer act as a barrier for mild traumas, severe traumas need thorough evaluation and prompt management to prevent catastrophic complications, such as vision or globe loss. The initial treatment approaches to chemical injuries of the eye, abrasion, foreign body and lacerations in the conjunctiva, cornea and sclera, hyphema, secondary glaucoma, and traumatic cataract along with the examination with imaging techniques and history taking tips are going to be discussed in this chapter.

Keywords: chemical burn, perforation, foreign body, traumatic cataract, hyphema

1. Introduction

Ocular trauma is relatively common with 20% of adults having the possibility of experiencing ocular trauma during their lives [1]. It occurs most frequently in men and young people [2]. A study estimated nearly 55 million eye injuries occur annually worldwide, and approximately 1.6 million people experience vision loss due to eye trauma [3]. In developed countries, ocular trauma is a major cause of unilateral blindness [4]. Ocular trauma affecting the anterior segment including conjunctiva, cornea, sclera, iris, and lens may be chemical, mechanical, or thermal. The most common three manifestations of eye injuries are foreign bodies (34.2%), abrasions/scratches (14.9%), and chemical burns (10.4%) [5]. Although the eyelids and tear film layer act as a barrier for mild traumas, severe traumas need thorough evaluation and prompt management to prevent catastrophic complications, such as vision or globe loss. The ocular traumas resulting from workplace accidents are at the top, followed by home accidents and leisure pursuit incidents and 90% of them are accepted to be preventable with simple approaches, such as using personal protective equipment (PPE) [6–11]. Detailed history including the time, mechanism and nature of the trauma, visual acuity evaluation, examination of periocular adnexa with orbital rim palpation, eyelid and canalicular patency evaluation, assessment of eye movements and presence of diplopia, pupillary light reaction as well as assessing the shape, size and isocoria of the pupils, examination of cornea and conjunctiva for any laceration, perforation or foreign body, assessment of anterior chamber, the status of the lens, and fundus examination along with imaging techniques such as ultrasound and computerized tomography should be performed in a stepwise manner in any case of eye injury. The Birmingham Eye Trauma Terminology (BETT) system is developed by Ferenc Kuhn in 1996 to manage the confusion

between the terms and diagnosis of the mechanical globe injury [4]. The ocular trauma score (OTS) which is also proposed by Kuhn et al. in 2002, estimates the final visual outcome in a mechanically injured eye. OTS uses six variables, as initial visual acuity, globe rupture, endophthalmitis, perforating injury, retinal detachment, and afferent pupillary defect, giving points for each, then categorizing them to give an estimation of the vision at sixth month [12]. Those two scoring and the categorizing system should be used in every mechanical injury of the eye to manage the patient properly and to estimate the final visual function.

2. Chemical and thermal injuries of the eye

Chemical and thermal injuries consist of 10–22% of all ocular traumas and are emergencies that should be treated in minutes to prevent severe damage to the ocular tissues [13, 14]. While two-thirds of reported cases occur in the workplace affecting young men majorly [14] household injuries by disinfectants and cleaning solutions are common in children and women besides acid attacks in hate crimes and inadvertent exposure by car battery explosions are not rare [15]. The type of chemical involved and the exposure time are the most important information to start treatment. The ischemia in the limbal area may give a clue about the severity and the extent of the injury as well as the estimated visual function [16]. Alkalis can cause irreversible damage to the eye, in between 5 and 15 minutes, and many are considered the most common cause of ocular chemical burns [16–18]. The assessment of severity involves three factors—damage to the lids and adnexes, degree of limbal ischemia, and the degree of acute corneal stromal opacification [19].

The conjunctiva, the most exterior tissue in the eye with direct contact of the causative agent, the Tenon's capsule underlying, episclera and sclera followed by suprachoroidal space and choroid and directly cornea beginning from the epithelium down to endothelium, iris, ciliary body, lens, vitreous, and retina may be affected according to the exposure time, the nature and the type of the agent and the time from injury to initial treatment. The intraocular pressure is indirectly affected as the episcleral vessels and trabecular meshwork may be affected directly or due to ischemia.

The classification and grading of ocular chemical burns are based on the extent of involvement of the limbus, conjunctiva, and cornea [20, 21]. The main causative agents are alkalis, acids, and irritants like alcohol. Ammonia and ammonium hydroxide, sodium hydroxide, calcium hydroxide, plaster and cement, magnesium hydroxide, and lime are the alkalis. Alkalis, with their nature of being hydrophilic and lipophilic, dissolve the tissues and induce saponification of the cell membranes followed by extracellular matrix damage by thickening and shortening of collagen lamellae. The damaged cell membranes allow the alkali to deeper penetration.

Sulfuric acid found in car batteries, hydrochloric acid in swimming pool disinfectants, nitric acid in dyes, acetic acid in vinegar, trifluoroacetic acid, and hydrofluoric acid is the acidic agents. Acids cause tissue coagulation and collagen shrinkage, however, the binding of the ocular proteins to acids, creates a buffering effect, resulting in the prevention of deeper penetration of the agent. Trifluoroacetic acid and hydrofluoric acid are exceptions since they cause deeper injury by hydrogen and fluoride ions they own [22–24].

Alcohol and household detergents are irritants. Although these cause less severe injury, epithelial loss in the ocular surface including the conjunctiva and the cornea, may cause haze and result in infections.

The Roper-Hall classification is based on the limbal ischemia degree and the corneal haze and helps for grading and estimating the prognosis of the trauma (**Table 1**) [21].

Grade	Cornea	Conjunctiva/Limbus	Prognosis
I	Corneal epithelial damage	No limbal ischemia	Good
II	Corneal haze, iris details are visible	<1/3 limbal ischemia	Good
III	Total epithelial loss, stromal haze, and iris details are invisible	1/3–1/2 limbal ischemia	Guarded
IV	Opaque cornea, iris, and pupil are invisible	>1/2 limbal ischemia	Poor

Table 1.
Roper-Hall grading for ocular burns [20].

The newer classification proposed by Dua et al., [20], is based on limbal and conjunctival involvement where limbal involvement is evaluated more objectively as the number of clock hours of limbus affected, providing a better prognostic estimation than the Roper-Hall grading (**Table 2**) [20, 21, 25, 26].

According to McCulley’s classification [27], the natural clinical course of chemical eye injury can be divided into three distinct stages; 1st, an immediate phase which is the first 7 days with tissue necrosis and sloughing; 2nd, intermediate phase with host response as tissue healing and inflammation, which may result in corneal melting and ulceration, vessel re-canalization and hemorrhages, conjunctivalization and pannus formation with the function of the cytokines (**Figure 1**); 3th, as of late phase after 3 weeks, inevitable results secondary to host repair and regeneration, such as fibrovascular pannus, deep corneal vascularization, dry eye, neurotrophic keratopathy, persistent epithelial defect, and/or perforation (**Figure 2**). With this classification, the treatment can be prompted by this natural course of the disease, the management can be broadly divided into early (4–6 weeks) or late (>6 weeks) management approaches [28].

2.1 Acute stage management

Ascertaining that the vital signs are normal is a must initially. Any edema in the larynx or esophagus or stomach injury should be excluded as missing can be fatal.

In the acute stage, the removal of the agent by vigorous irrigation from the eye should be prompted urgently before assessment of the eye. Before irrigation, it is important to use titmus paper to reveal whether the agent is acid or alkali if the patient or the host cannot give a proper history. Measuring the pH of the ocular surface may not always give the correct result, but it may give an idea of whether the

Grade	Limbal involvement	Conjunctival involvement	Analog scale	Prognosis
I	0	0%	0/0%	Very good
II	3 clock hours	30%	0.1–3/1–29.9%	Good
III	>3–6 hours	>30–50%	3.1–6/31–50%	Good
IV	>6–9 hours	>50–75%	6.1–9/51–75%	Good to guarded
V	>9–<12 hours	>75–100%	9.1–11.9/75.1–99.9%	Guarded to poor
VI	Total limbus: 12 hours	Total conjunctiva: 100%	12/100%	Very poor

Table 2.
DUA classification of ocular surface burns [19].

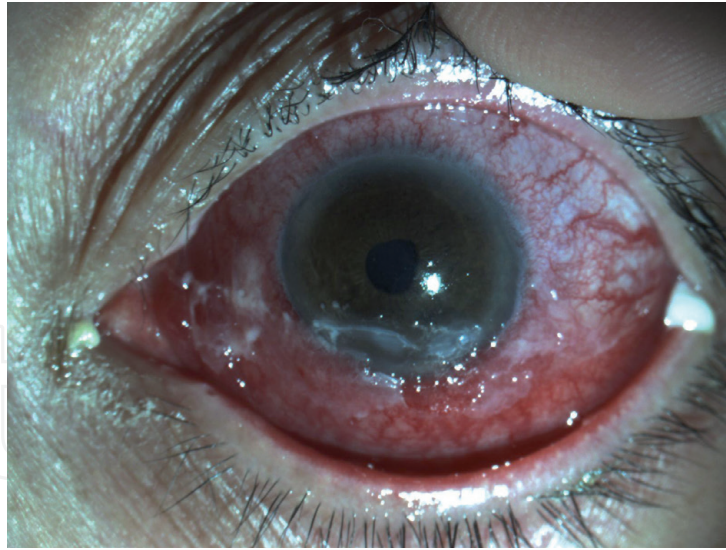


Figure 1.
Corneal ulcer, vessel recanalization and severe conjunctival hyperemia in chemical eye injury.

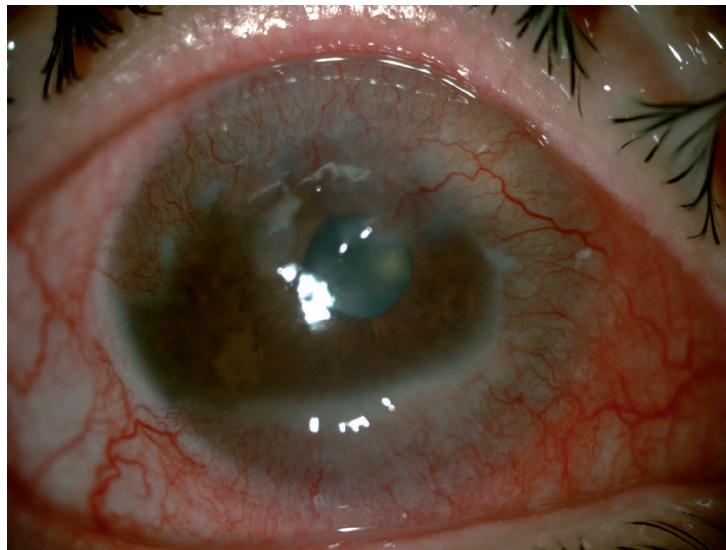


Figure 2.
Late phase of chemical injury with pannus formation, corneal vascularization, and conjunctivalization.

irrigation is properly established or whether more irrigation is needed. The change from the basal value gives some clue since the only and the best prognosis depicting treatment is irrigation of the eye. Copious irrigation with isotonic or physiologically equivalent irrigating solutions such as lactated Ringer's solution and balanced salt solution (BSS) for 30 minutes has been proposed as a more superior treatment than water as these cause less corneal edema [29]. In circumstances that those solutions are not available, irrigation with tap water may also work. Topical anesthesia, with drops, relieves the pain and blepharospasm and facilitates the complete irrigation of eyelid fornices, helps the removal of the agent, and provides neutralization of the pH of the tissues. It should be kept in mind that irrigation can decrease the ocular surface pH effectively, however, the pH of the aqueous humor may be lowered by 1.5 units only by irrigation. Some experimental animal studies relieve that anterior chamber paracentesis followed by irrigation with a buffered solution may reduce humor aqueous pH by 3 units. However, this procedure is very invasive hence endophthalmitis may occur in a severely traumatized eye and is not suggested [30, 31].

In the presence of amphoteric chelating agents, such as ethylenediaminetetraacetic acid (EDTA), Diphoterine®, hexafluorine, and Cederroth eye wash,

the neutralization occurs more rapidly, however, these solutions are not always available [32–35]. After 30 minutes of irrigation with isotonic solutions, the irrigation should be stopped for 5 minutes and the re-measurement of pH should be performed. If neutralization is still present then one may pass to the assessment of the eye.

2.1.1 Clinical evaluation

A complete examination starting from the body (any exposure to inhalant chemical), then face, periocular region, eyelids, eyelashes, conjunctiva, cornea, limbus, sclera, iris, pupil, lens, visual acuity, intraocular pressure, corneal sensation, and retina should be prompted. The eyelids may be swollen and contracted, and lagophthalmos may occur. The tear film may be affected due to inadequate closure of the eyelids as well as the destruction of the accessory lacrimal glands. The tarsal and bulbar conjunctiva should be checked for epithelial defects by fluorescein staining, and eyelid eversion with Desmarres retractors should be performed where eyelids cannot be everted easily due to edema or contraction. Both the upper and lower fornices should be checked for any remained chemical and a deep swap by a cotton bud should be performed. The cornea may be partially or totally deepithelized due to the direct contact of the chemical. The presence and degree of limbal ischemia is important as it is the most important region for corneal epithelial regeneration by stem cells. White areas in the limbal area and the extent of these pale areas in terms of clock quarters provide an estimation for the prognosis. The haze, the opacification, edema of the cornea whether it facilitates the examination of the iris, and lens should be recorded. The iris should be checked for color, vessels, atrophy, hemorrhage, necrosis, and synechia. The pupil constricting and dilating may be disabled partially or totally. Intraocular pressure may be variable due to the extent of the trabecular meshwork dysfunction, inflammation, and ischemia [36]. Phthisis may be seen as ciliary body scarring that can occur. Edema and corneal epithelium damages may obscure measurement of intraocular pressure and digital measurement may give a clue. The lens may be swollen. Retina, optic disc, and vitreous should be assessed for inflammation and hemorrhage.

2.1.2 Anti-inflammatory treatment

Suppressing inflammation with preservative-free dexamethasone 0.1% and prednisolone acetate 1% drops in the first 7–10 days is the mainstay of the treatment. Although corticosteroids suppress inflammation and inhibit the release of proinflammatory cytokines, they may impede corneal epithelization. Due to this possible side effect, tapering the frequency after the first week allowing epithelization is the main approach [37, 38].

Tetracycline inhibits the production of metalloproteinases which may lead to corneal ulcer and perforation [39]. Oral doxycycline 100 mg, minocycline 100 mg twice a day, or tetracycline 250 mg four times a day, topical tetracycline 1% suspension, or 3% ointment [40]. Sodium citrate 10% may be used for inhibiting PMNL chemotaxis [41]. Amniotic membrane transplantation may serve as a good option to accelerate epithelial healing, help to alleviate pain, and may improve final outcomes, especially in moderate chemical eye injuries [42, 43].

Commercially available devices or lyophilized and air-dried amniotic membranes (e.g., Omnigen® 500 and 2000) may also be used for the same purpose [44, 45].

Preservative-free tear substitutes, vitamin C topically 5–10% and/or orally (1–2 g/day) [46] autologous serum [47], umbilical cord serum [48], platelet-rich

plasma [49], fibronectin [50], chitosan [51], epidermal growth factors [52], heparin [53], regenerating agents (RCTA, CACICOL20) [54, 55], bandage contact lens [56], tenonplasty [57], free conjunctival autograft [58], amniotic membrane transplant [59], and sequential sector conjunctival epitheliectomy [60], may be used to promote healing process.

Mydriatic and cycloplegic agents other than adrenergic which may cause vasoconstriction and increase ischemia should be used for pain, iridocyclitis and prevent synechiae formation. Fluoroquinolones may be used as infection prophylaxis. Oral intraocular pressure-lowering agents may be more useful than topicals since trabecular meshwork may be damaged. Tenonplasty, free conjunctival flaps that may be secured to the ischemic areas is an early surgical intervention [57, 58].

2.2 Late-stage management

Eyelid reconstruction, surgical approaches for glaucoma, cataract, corneal haze, or opacification are the late-stage treatment approaches for chemically injured eyes.

Skin and oral mucosal grafts, tarsorrhaphy may be performed when eyelid closure is obscured and exposure occurred. In the case of phacomorphic glaucoma, cataract removal solely with implanting an intraocular lens in another session may be preferred. Dry eye is a common problem in all cases. Frequent lubrication with preservative-free tears and gels, punctal occlusion, mucous membrane grafts, and salivary gland transplantation are options according to the severity of the case.

Symblepharon formation may be repaired by fornix reconstruction with amniotic membrane transplantation (AMT) or oral mucosal grafts and scar release with or without Mitomycin C or 5-Fluorouracil.

In severe epithelial defects, nerve growth factor drops (cenegermin) [61], coenzyme Q10, autologous serum, AMT, mucosal, or conjunctival flaps/grafts may be used [62].

Limbal stem cell transplantation may be performed in limbal deficiency cases (Figures 3 and 4) [63].

In cases with corneal scarring, an anterior lamellar graft, deep anterior lamellar keratoplasty or penetrating keratoplasty are the procedures of choice.

In severe cases where ocular surface reconstruction is not possible, an osteo-odonto keratoprosthesis or a Boston type 2 keratoprosthesis are the only options.

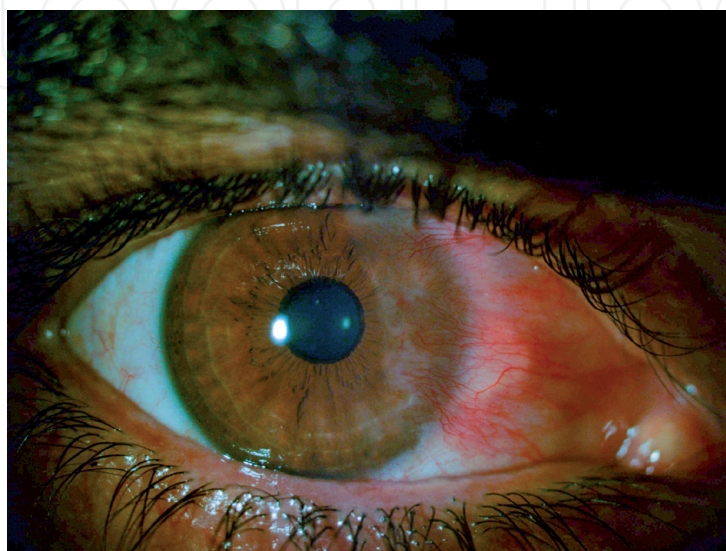


Figure 3.
Limbal cell deficiency and conjunctivalization.

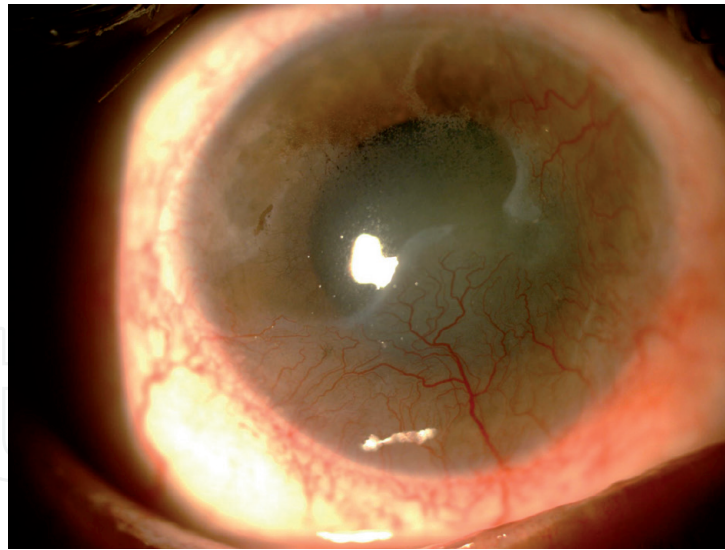


Figure 4.
Conjunctivalization with deep and superficial corneal vascularization and vessel recanalization.

3. Conjunctival abrasion, foreign body, laceration, and hemorrhage

Conjunctival abrasions and lacerations result from minor or major traumas. Work injuries affect males to a much greater degree, especially those between the ages of 17 and 30 [64–67]. A history of a work relation, recreation, insulting, and self-induced trauma like rubbing and contact lens fitting may be present. Lacrimation, light sensitivity, foreign body sensation, ocular pain, and subconjunctival hemorrhage are the main symptoms and signs. In a conjunctival abrasion epithelial cells are physically removed as stained by fluorescein dye, a visible conjunctival defect with sclera and Tenon's exposure between the wound edges may be seen in biomicroscopy with the help of fluorescein staining in a conjunctival laceration case. When conjunctival laceration is diagnosed, the conjunctiva should be examined for subconjunctival hemorrhage, foreign body, an underlying scleral laceration, or globe perforation. A bullous chemosis with subconjunctival hemorrhage may be a sign of scleral rupture while subconjunctival emphysema may be a result of a sinus fracture.

Evaluation for conjunctival laceration and/or abrasion begins with history. The time, place, and activity during the injury should be recorded. The eye examination should start with a visual acuity evaluation. If the globe is intact, the upper eyelids should be everted and fornices should be examined for any hidden foreign bodies [68]. A topical anesthetic drop may alleviate blepharospasm and help evaluation. The anterior chamber depth, pupil shape, foreign body, any inflammation or hemorrhage in the anterior chamber should be recorded.

Topical antibiotic/steroid combination drops and/or ointments or antibiotic drops with topical nonsteroidal anti-inflammatory medication may be prescribed [69–72].

In patients with anterior chamber inflammation, cycloplegia may be added. Conjunctival lacerations smaller than 10 mm heal within a week with medical therapy while in lacerations larger than 20 mm, surgical repair by tissue fibrin glue or suturing may be necessary. For the defects between 10 and 20 mm wide, a pressure patching for 24 hours with antibiotic ointment is usually adequate [73]. However, in lacerations at the horizontal plane where blinking may prevent epithelialization, and when apposition of the wound edges is not provided, then suturing by absorbable 8/0 Vicryl or fibrin glue may be performed.

Subconjunctival hemorrhage is a painless and acute accumulation of the hemorrhage between the episclera and the conjunctiva. Generally, it is a benign

disorder and can be caused by minor trauma as in contact lens users or in patients with hypertension, anticoagulant therapy, elevated venous pressure (Valsalva maneuver, coughing, vomiting) and in acute hemorrhagic conjunctivitis and may be seen during vaginal delivery in newborns [74–77].

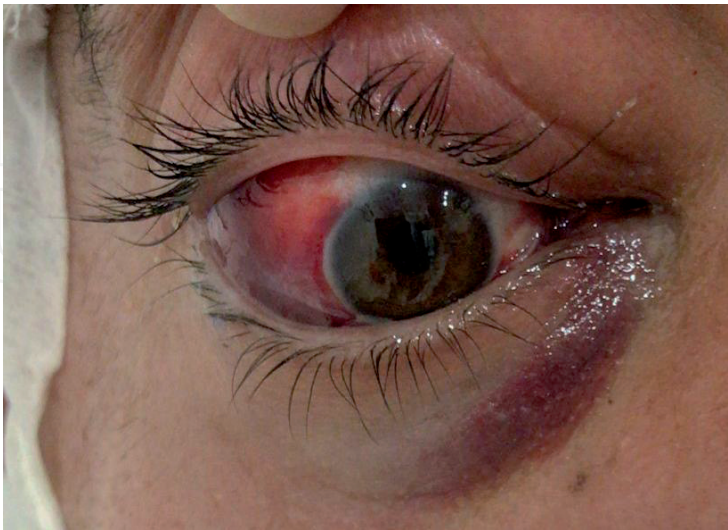

Figure 5.
Traumatic subconjunctival hemorrhage.

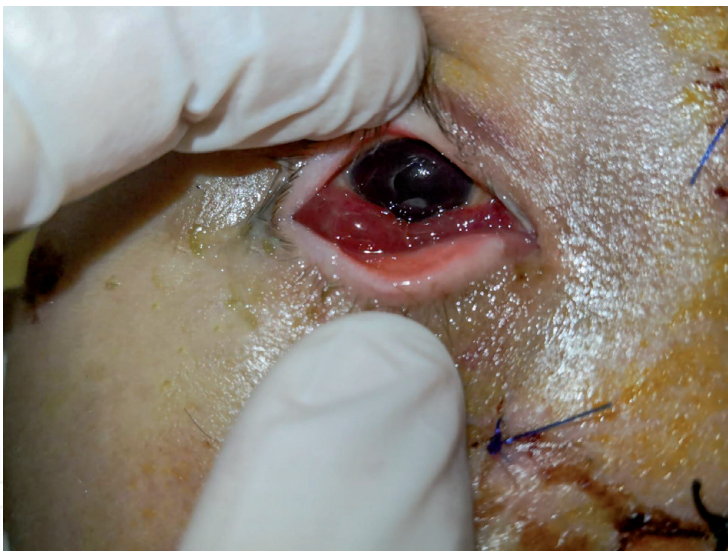

Figure 6.
Subconjunctival hemorrhage, chemosis, and enophthalmus in orbital floor fracture.

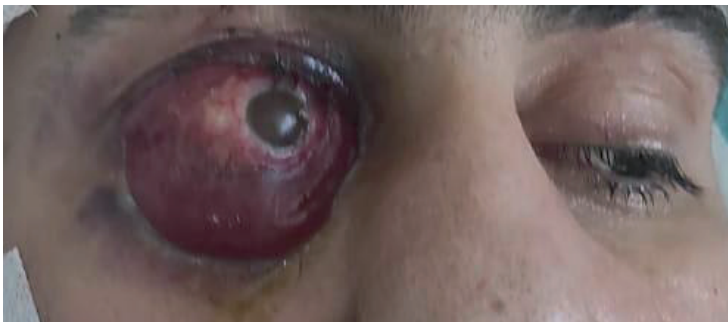

Figure 7.
Retrobulbar and subconjunctival hemorrhage in resulting in proptosis in globe injury.

Traumatic subconjunctival hemorrhage may be associated with direct trauma to the eye (**Figure 5**) and also in severe circumstances, such as open or close globe injuries, orbital traumas, and basilar skull fractures (**Figures 6 and 7**) [78]. In children, abuse should always be kept in mind in recurrent subconjunctival hemorrhage.

Although no treatment is indicated for SCH without globe perforation or foreign body, suggesting limited activity, cold compresses, teardrops, acetaminophen, or ibuprofen may relieve the discomfort and inflammation.

4. Corneal abrasion and foreign body

Eye injuries comprise 8% of the emergency cases where corneal abrasions and foreign body are the main causes with percentages of 45%, 31%, respectively [79]. Ocular injuries, including corneal foreign bodies, are generally more common in young males (**Figure 8**) [80]. Ocular foreign body sensation is the main complaint as accompanied by excessive tearing, pain, red eye, photophobia, itching, and stinging.

A thorough clinical examination in conjunction with a detailed history, the extent and the depth of the defect may be examined (**Figure 9**). Differential diagnoses include corneal foreign body, keratitis, contact lens trauma, recurrent erosion syndrome, staphylococcal marginal keratitis, infectious or inflammatory keratitis, trichiasis, keratoconjunctivitis sicca, and limbal stem cell deficiency [79]. Aslam et al. reported that 12% of corneal abrasion cases were contact lens related [81].

A missed foreign body under the eyelids may be present. Vertical linear abrasions, as recognized by fluorescein staining, are pathognomonic for a missed foreign body. It is very important to evert the upper eyelid and exam the entire fornix for any retained foreign body. The eversion may be performed by a cotton-tip applicator or Desmarres retractor under topical anesthetic drops. Although embedded foreign bodies under the lids or deep in the fornix can be removed easily by a cotton swab, forceps, or a needle tip under topical anesthesia, corneal-embedded foreign bodies need more attention as they may be penetrating all the corneal layers. These kinds of corneal foreign bodies should be removed in the operating room as they have the risk of falling into the anterior chamber. Corneal superficial

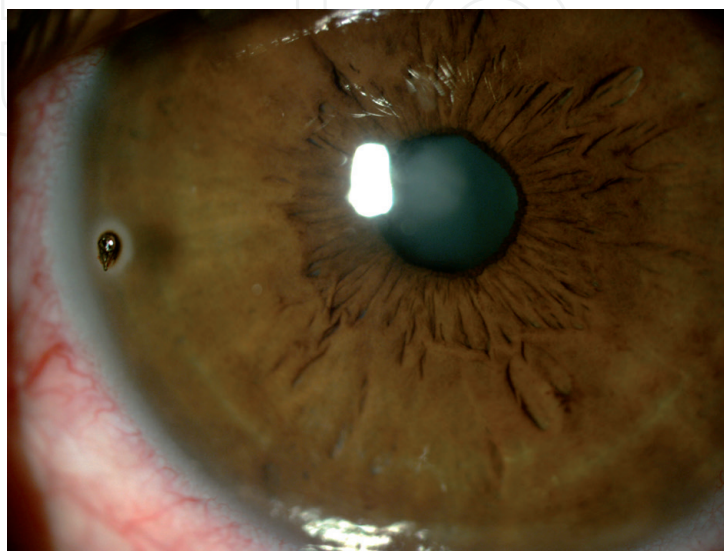


Figure 8.
Corneal foreign body.

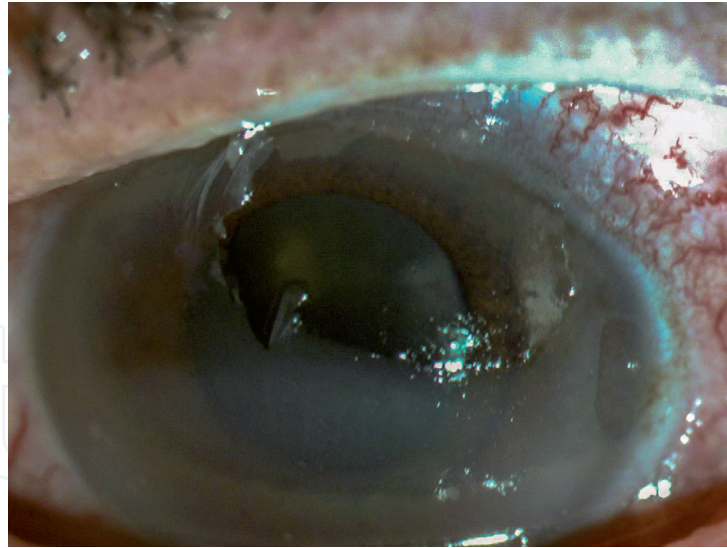


Figure 9.
Large corneal epithelial defect.

foreign bodies can be removed as conjunctival foreign bodies with the help of a 25-G needle. Rust rings resulting from iron foreign bodies may better be removed by a corneal burr. It is not rare that an intraorbital or intraocular foreign body may also be present especially in a patient with a history of high-speed metallic injury by grinders or hammering. The treatment goals are preventing superinfection, promoting epithelial regeneration, and subsiding the pain. Although an intact cornea epithelium is resistant to microorganisms and it often heals without complication, epithelial defects may result in sight-threatening keratitis. The main treatment approach is antibiotic prophylaxis with lubricating ointments or drops. In patients with contact lens history, fingernail trauma, or trauma with a plant-based organic material, topical fluoroquinolone drops four times a day, with fluoroquinolone ointment at bedtime are the choices of preference for their gram-negative organism coverage [82]. Antibiotic ointments, such as erythromycin, bacitracin, or polysporin 4–5 times a day, with antibiotic drops, such as polymyxin B and trimethoprim or fluoroquinolone four times a day, maybe prescribed in patients without contact lens history or trauma by an organic material [82].

Oral nonsteroidal anti-inflammatory drugs and topical cycloplegics may be used for pain. Topical steroidal and nonsteroidal drops should not be offered since they have corneal toxicity potential leading to obscure epithelial healing. Topical anesthesia should only be used for examination purposes and is a contraindication in corneal injury due to its delaying and masking effect of devastating complications like corneal ulcers and are toxic to epithelium [83].

Although patching was the mainstay of the treatment for corneal abrasions for a long time, recent studies emphasized that patching did not shorten healing time or decrease pain, when compared with using only antibiotic ointments [84, 85].

5. Corneal lacerations

Corneal penetrating or perforating injuries may happen in work, in recreation, and by an assault. A detailed history is necessary to estimate the severity and duration of the injury, the nature of the agent (organic or inorganic), possibility of the retained metallic body, any systemic disease that may complicate the surgery as hypertension leading to suprachoroidal hemorrhage or diabetes negatively affecting wound healing and increasing the risk of infection. The reports should be recorded

appropriately as most injuries include a possibility of a medicolegal problem. In an isolated eye injury, the corneal perforation should be evaluated by biomicroscope as the extent of the laceration, presence of any scleral laceration, prolapse of vitreous and/or uveal tissue, anterior chamber depth, presence of capsular and lens injury, and any foreign body; followed by visual acuity evaluation and pupil testing, and if possible visual field testing, along with imaging modalities, such as X-ray and computerized tomography for imaging metallic foreign bodies. B-scan ultrasonography can be helpful in normal-toned globes. A more extensive evaluation may be performed in the operating room under general anesthesia. The repair of a small corneal or scleral laceration although may be sutured with local anesthesia, local anesthesia usually accepted as a contraindication in these types of eye injuries because any pressure from the retrobulbar or peribulbar injection of the anesthetic drug may induce orbital and ocular complications. General anesthesia is the main approach in these patients. Corneal perforations are sutured by 10–0 monofilament nylon suture (**Figure 10**). Any possibilities of evisceration or enucleation of the globe due to unrepairable lacerations, optic nerve avulsion, need for lensectomy, and need for secondary interventions such as IOL implantation, vitrectomy for retinal detachment, risks as sympathetic ophthalmia, infection, hemorrhage, secondary glaucoma, corneal scarring, astigmatism, traumatic optic neuropathy, and blindness, should be informed to the patient and the patient's family members. Written informed consent should be taken from the patient if possible as well as the family members.

Perforating injuries that are small in size may be self-sealing and are observed with minimal intervention and prophylactic use of antibiotics. Patching alone, a bandage soft contact lens or tissue adhesives may help to seal a minimal leakage [86]. Any perforating injury warrants complete evaluation to exclude any foreign body presence and damage to other intraocular tissues. Sometimes a self-sealed oblique perforation, especially entering from the peripheral iris with a foreign body, may mimic partial-thickness laceration as the iris muscles contract and close the entrance region, leading to delayed diagnosis of an intraocular foreign body. The iris and the lens portion, under the corneal laceration area, should be carefully evaluated for any spot or entrance point. Taking initial cultures from the conjunctival and corneal surface before use of any prophylactic antibiotic drops or intravenous antibiotics, especially in cases with foreign body or infection risk, may help to establish a probable causative agent in case of consecutive endophthalmitis. Ophthalmic ointments should be avoided on an open eye injury and an eye shield

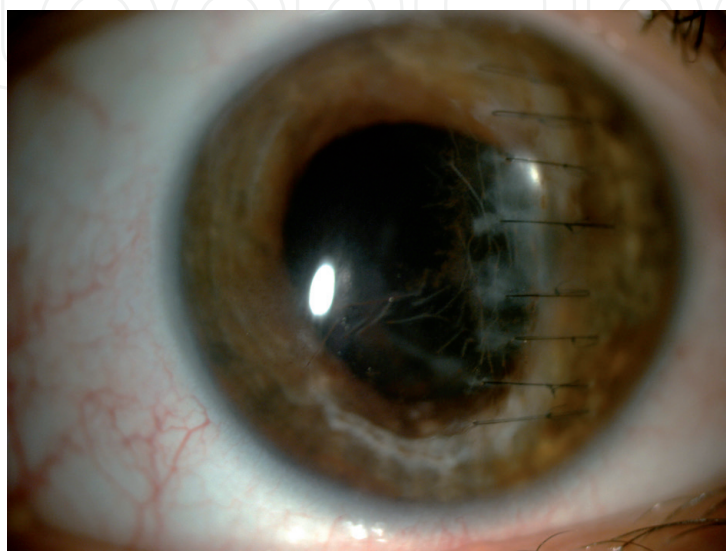


Figure 10.
Corneal perforation sutured with 10-0 monofilament nylon suture.

should cover the eye to avoid any further extrusion of ocular contents. Systemic intravenous antibiotic prophylaxis may be initiated preoperatively.

Under the anesthesia, the leakage area should be identified and an anterior chamber washing with BSS may be performed from the leakage area to clear the media and to form the anterior chamber. Injecting viscoelastic into the anterior chamber helps to provide the tonicity of the eye, enabling suturing of the wound. The limbus should initially be stitched by a 10–0 nylon suture, then the suturing should extend from anterior to posterior. About 80–90% depth of suture placement is needed to provide apposition of the wound margins as interrupted sutures. Rowsey et al. stated that most peripheral cornea should be closed first to achieve the flattest topography allowing progressive steepening as sutures progress toward the corneal apex. Longer bites of tissue with more compressive effects are desired peripherally to achieve peripheral corneal flattening [87]. Repair near the optical zone and corneal apex should consist of shorter stitches placed deep within the corneal tissue. Triangular wounds should be stitched starting from the apex and then the sides of the triangle. All knots should be buried below the level of Bowman's membrane. When extensive tissue loss has occurred, patch grafting using corneal or scleral tissue may be necessary, as well as penetrating keratoplasty or lamellar keratoplasty. Conjunctival flaps should be considered inadequate for use as a temporary measure for closing over defects of corneal tissue.

Early corneal suture removal may be indicated when sutures loosen, collect mucus, or induce vascularization. Total removal starting from the peripheral sutures to the center should be done when the wound appears healed with cicatrization. The central corneal sutures, although the timing may change according to the wound type, place, and patient's individual health status and age, maybe removed about 3 months. Peripheral corneal sutures may be removed in 1–3 months in adults and shorter as in several weeks in infants. Scleral sutures are left in place indefinitely if they are buried well with no risk of infection and symptom. Any iris tissue prolapsed from the corneal wound for longer than 24 hours, or is highly contaminated or ischemic, should be excised. Smaller and viable prolapsed iris tissues should be repositioned with the help of the viscoelastic. It is of utmost importance not to cause a cyclodialysis at this step. Iris repair may be performed with polypropylene 10–0 suture, and iris dialysis may be repaired by suturing the edge of the iris into an anatomic position at the angle.

6. Scleral laceration

The scleral laceration may be contiguous with a corneal laceration, may be localized between the limbus and the extraocular muscles (**Figure 11**), or maybe hidden in the posterior pole at the extraocular muscle insertion area. In blunt traumas, scleral rupture commonly happens at the limbus, and the equator between the muscle insertions, under the muscle insertion extending to the posterior pole [88]. A globe with scleral perforation may be hypotoned with IOP less than 5 mm Hg or maybe normal-toned when the scleral defect is occluded by tissues of a clot. The visual acuity is usually decreased to light perception or less, and the anterior chamber is shallow with intraocular and periocular hemorrhage [88, 89]. A 360-degrees peritomy and dissection of the conjunctiva and Tenon's to posterior pole to expose the complete sclera is important for direct visualization of all extraocular muscle insertions. Two conjunctival incisions perpendicular to the limbus at the 3 and 9 o'clock quadrants may help to visualize the posterior pole up to the optic nerve. In severe injuries, lid sutures provide better visualization and decrease pressure risk than with speculums. When the limbus is accomplished with the scleral perforation, the suturing should start from the limbus with deep scleral bites by interrupted

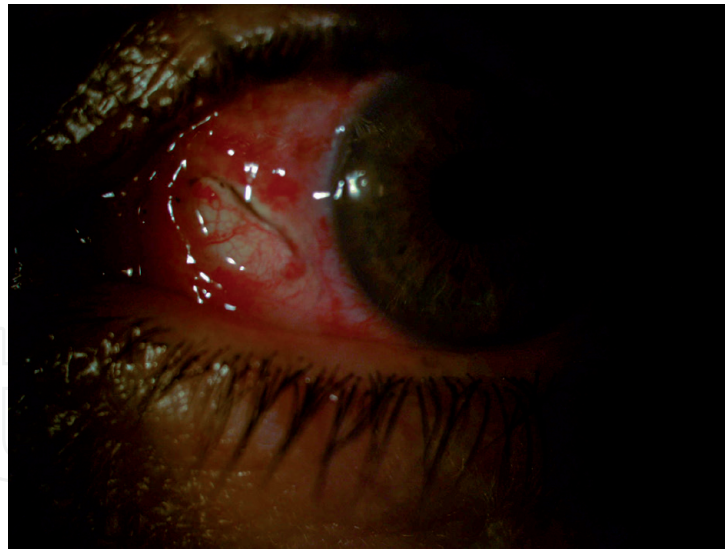


Figure 11.
Scleral laceration.

sutures using 10-0 or 9-0 nylon. Repair of a scleral laceration should proceed from an anterior to a posterior direction and in presence of a large scleral defect, a donor cadaver scleral patch graft may be used. If vitreous is prolapsed through the wound edges, it should be excised by scissor with the help of a cellular sponge, however, a vitrectomy probe is a better option for this purpose as it does not cause traction on the tissue. Generally, any prolapsed uveal tissue should be repositioned as the sclera is closed. The conjunctiva is sutured by 8-0 Vicryl at the limbus.

7. Traumatic Hyphema

Hyphemas are the accumulation of blood in the anterior chamber mostly due to penetrating or blunt traumas in the eye. (**Figure 12**) The bleeding results from the tears in the well-vascularized ciliary body and iris [90]. A fibrin clot stops the bleeding and the clot stabilizes in 4–7 days, and the fibrinolytic system resolved clot is cleared by the trabecular meshwork [91]. Trauma history, pain, and decreased vision are the most common complaints. In a patient with hyphema associated with subconjunctival hemorrhage and glob hypotonicity, a glob perforation should always be suspected [92]. Although hyphema due to intraocular tumors, leukemia, and sickle cell anemia (SSA) is rare, it should always be suspected in patients without a history of trauma or with recurrent hyphemas. Although traumatic hyphema is more common in children, in children presenting with hyphema, physical abuse should also be questioned. Orbital/cranial CT/MRI, ultrasound, and additional blood testing should be performed in those cases [93, 94].

Visual acuity, hyphema grade, intraocular pressure, and presence of corneal staining should be performed daily in the first 5 days, and after clearance of the blood, a careful gonioscopy should be performed for the presence of angle recession and any bleeding area, followed by a dilated fundus examination [92].

Hyphemas are typically graded macroscopically due to the level of accumulation of blood in the anterior chamber. Grade 0 is microhyphema with no visible layer, only with red blood cells in the anterior chamber. Grade I is blood accumulation less than 1/3 level of blood in the anterior chamber. Grade II is 1/3–1/2 of blood accumulation in the anterior chamber, and grade III is 1/2 to near-total filling of the blood in the anterior chamber. Grade IV is total hyphema, which is defined as a blackball or 8-ball hyphema [95].

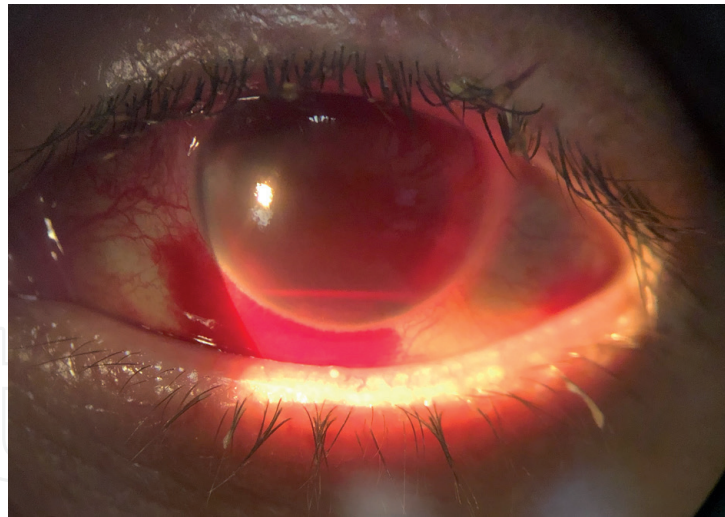

Figure 12.
Grade 1 hyphema and subconjunctival hemorrhage in blunt trauma.

Treatment modalities include initially preventing complications as intraocular pressure increases, corneal staining, and rebleeding. Although the inpatient treatment approach was commonly used in the past, recently, outpatient management has shown to be similarly effective with appropriate precautions given to the patient [96, 97].

Inpatient hospitalization may be considered in patients with uncontrolled intraocular pressure and rebleeding risk. Limited activity and eye shield should be suggested to minimize the risk of rebleeding, especially in children. The patient should sleep in a head elevated bed to provide layering of the blood in the inferior angle to clear the visual axis. High intraocular pressure is reported in 32% of patients with hyphema on the first day [92]. Any IOP >25 mm Hg especially in a patient with SSA or SSA trait, the topical beta-blocker may be prescribed. Prostaglandins may induce inflammation, alpha agonists may lead to respiratory distress and carbonic anhydrase inhibitors may result in sickling in SSA patients, so these drugs should better be avoided [98, 99]. If corneal staining with blood is present or IOP remained high after 4–7 days, then an anterior chamber lavage should be performed.

Rebleeding occasionally occurs at 4–7 days after the trauma and the grading of the hyphema is important to discriminate fresh bleeding from an old clot. Although the implication of aspirin and other NSAIDs in the rebleeding is controversial, they are commonly discontinued in hyphema [100, 101]. Cycloplegics may be used for relaxing the ciliary muscle, and by its dilation effect on the pupil, iris vessels contract, decreasing the risk of rebleeding.

Topical steroids are commonly prescribed in hyphema due to the presence of inflammation. They should be used according to the severity of the inflammation and should be discontinued in a tapered manner as complications such as glaucoma and cataracts may occur [102, 103]. Antifibrinolytic agents such as oral aminocaproic acid and tranexamic acid stabilize the clot and decrease the risk of secondary hemorrhage, however, due to some systemic side effects, it is better to hospitalize the patient when systemic use is planned [104–107]. Aminocaproic acid can be safely used in children, however, it is contraindicated in patients with thrombosis risk [108]. Tissue plasminogen activator and transcorneal oxygen therapy are used in some cases with variable results as reported in the literature [109, 110]. Anterior or posterior synechias, secondary glaucoma, and angle recession may be seen as late-term complications where the latter is reported to occur in 85% of hyphema patients and the relative risk of glaucoma is reported to be 2.21 [111].

8. Post-traumatic (secondary) glaucoma

Traumatic IOP elevation and traumatic glaucoma are complications that can result from the trabecular meshwork dysfunction, angle recession, lens displacement, lens swelling (phacomorphic glaucoma), inflammatory response to lens proteins in a case with capsular tear (phacoantigenic glaucoma), iris damage, hyphema, inflammation, anterior synechiae, vitreous hemorrhage, and topical corticosteroid use [112–115]. Ocular trauma can lead to secondary glaucoma, with a 4% risk of developing post-traumatic glaucoma. Majority of the secondary glaucoma cases (77%), resulting from closed globe injuries, whereas only 23% followed open globe injuries. The etiology of traumatic glaucoma although may differ according to the type, time, and duration of the trauma, a classification based on the timing after the trauma as reported by Bai et al., may give a basic and effective idea of the mechanism involved [116]. In the first month, inflammation, hyphema, lens dislocation, and prolonged use of potent steroids are the main causes of secondary glaucoma. Between 1 and 6 months, angle-closure glaucoma occurs due to anterior synechia and pupillary block with posterior synechia. In the late term, angle recession, siderosis may be the etiology. In patients with associated vitreous hemorrhage, ghost-cell glaucoma can be seen in 2 weeks–3 months [117].

9. Angle recession

Ocular blunt trauma can result in closed-globe injuries or open-globe injuries. In blunt trauma, compression force on the globe results in elevated pressure on the limbal area, where ciliary bodies longitudinal fibers separate from circular fibers, associated with the breakage of the vessels leading to hyphema. Angle recession is seen in 85% of traumatic hyphema and results in chronic glaucoma [111]. Cyclodialysis is relatively rare than the recession and it leads to resistant hypotony [118–121]. In an examination, a widened ciliary band is seen on the gonioscopy (**Figure 13**). The relative risk for developing glaucoma is 2:1 in patients with recessed angles. In general, studies show the risk is significantly increased when more than 180 degrees of recession exists [122]. Prostaglandins may be used after inflammation is treated due to their uveoscleral outflow increase potential.




Figure 13.
Angle recession observed as a widened ciliary band in gonioscopy.

Pilocarpine may worsen angle recession. Trabeculectomy with Mitomycin-C can be performed in patients with uncontrolled IOP with medications [123].

10. Cyclodialysis and Iridodialysis

The direct communication between the anterior chamber and the suprachoroidal space, in cyclodialysis, results in resistant hypotony. Although the dialysis portion is seen on gonioscopy as posterior to the scleral spur, in eyes with hyphema or corneal edema, it may be hard to visualize the angle. Ultrasound biomicroscopy (UBM) and anterior segment OCT may show cyclodialysis when gonioscopy is difficult [124, 125].

The medical treatment includes 1% atropine sulfate BID for 6–8 weeks to reoppose the ciliary body back to the scleral wall and normalize intraocular pressure. Surgery is another option in cases where the medical approach is inadequate. The ciliary body may be attached to the sclera either surgically or by facilitating inflammation by burn to help apposition. Direct cyclopexy [126], argon laser photocoagulation [127], trans-scleral YAG laser [128], and cryoablation [129], are other options.

In the dialysis of the iris at the root, small dialysis may be asymptomatic while in large dialysis cases, polycoria, glare, monocular diplopia warrants surgical intervention (**Figure 14**).

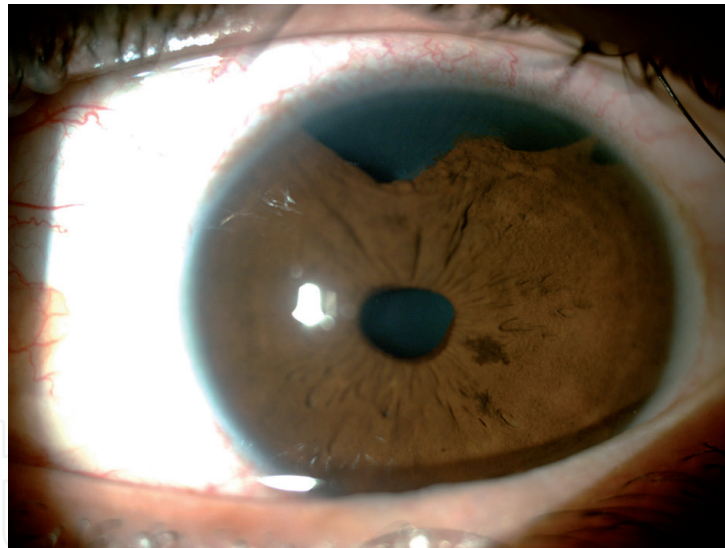


Figure 14.
Large iridodialysis between 11-o'clock and 2-o'clock quadrants.

11. Traumatic cataract

Cataracts may arise from blunt or penetrating eye traumas immediately after the injury or many years later. Lens damage is present in 30% of perforating injuries of the anterior segment of the eye [130].

If penetrating trauma is present, the use of topical medication or pressing devices that touch the eye should be avoided. Once penetrating trauma has been ruled out, ultrasound A and B may be used for further assessment of the ocular status.

Lens injury may happen in an eye trauma as direct injury of lens fibers, capsular rupture, zonular dehiscence, or all [131]. The flow of aqueous humor in the lens

causes opacity. Small capsular tears less than 2 mm may heal spontaneously but defects bigger than 3 mm occasionally result in lens opacity. Large disruptions of the lens, with the obvious release of cortical material or through-and-through lens rupture with dislocation or rupture of the lens zonules, are indications for primary lensectomy at the time of primary repair.

In blunt traumas, although the capsule may be intact, a sunflower cataract (Rosette or stellate type) may be seen (**Figure 15**). The main symptoms are vision decrease, glare, and intraocular inflammation with or without glaucoma. In these patients, the retina should carefully be examined for any tear or detachment, or hemorrhage. When it is not possible to visualize the fundus, a B scan ultrasound may be used for probable retinal pathology or vitreous hemorrhage, or a foreign body.

If the lens opacity is not at the visual axis, and the visual acuity increases with a refraction correction with no inflammation, phacodonesis, vitreous prolapse, or inflammation, observation with close follow-up is the main approach.

Phacoemulsification is the best approach in patients with cataract extraction indications. Preoperatively, any risk of phacodonesis, vitreous prolapse, and zonular dehiscence should be evaluated. If a torn capsule, a phacodonesis, or subluxation are present, phacoemulsification with the help of the capsular tension ring or capsule hooks may also be facilitated, however, combined pars plana lensectomy and vitrectomy are also may be performed. Extracapsular or intracapsular cataract extraction may be facilitated when zonular and lens instability is a problem. Primary lens implantation may be considered in any approach in an intact capsule or zonules long as there is no inflammation or infection risk. Advantages of the primary placement of intraocular lens implantation include more rapid visual rehabilitation with a single surgical procedure and one anesthetic exposure [132]. The lens may be placed in the bag, in the sulcus, in the anterior chamber, or maybe fixated to the iris or sclera. However anterior placement of IOL should be avoided in patients with corneal injury and in young patients. In patients with zonular defects, capsular tension rings should be implanted. Peripheral iridectomy may be considered in eyes where the prolapsed iris could not be repositioned and when there is a possibility of a pupillary block [133].

In children, the management of traumatic cataracts requires many measures to be taken into consideration. Firstly, the timing of the cataract extraction is important as amblyopia may develop in a short period. In children with cataract

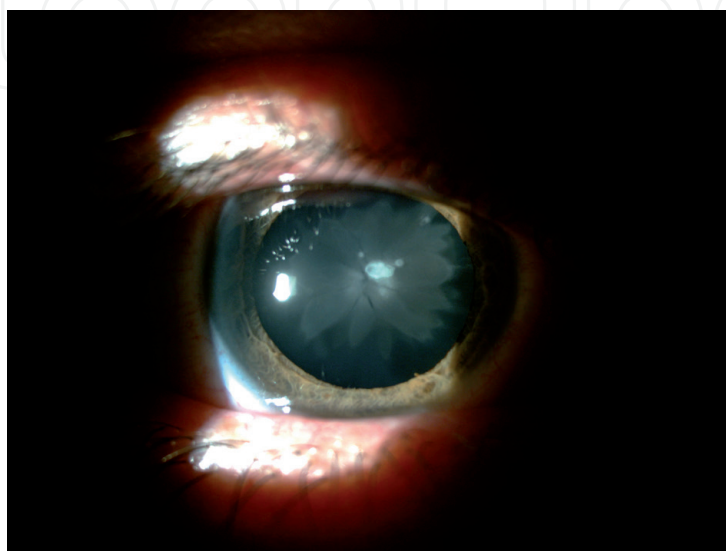


Figure 15.
Traumatic sunflower cataract.

removed, inflammation and synechia risk are more than the adults, and the risk to develop posterior capsular opacifications relatively soon after cataract removal is higher [134, 135]. For this reason, in children who will not be able to cooperate with YAG laser capsulotomy, a primary posterior capsulotomy and anterior vitrectomy are recommended at the time of cataract extraction. Another controversial aspect is the implantation of the lens in children. Although primary IOL implantation may be possible in most cases of closed globe injuries, in open-globe injuries, complicating factors such as poor visualization and difficulty in accurate IOL power calculation may delay IOL implantation as a secondary procedure [136]. Retinal detachment, macular scarring, amblyopia, and traumatic optic neuropathy may be seen in the late term either primary or secondary lens implantation. All children whether cataract extracted or not should be continued follow-up with a pediatric ophthalmologist.

In traumatic cataract cases with the lacerated cornea, the perforation should priorly be stitched or sealed before any intraocular surgery including cataract extraction or vitrectomy. Corneal lacerations are closed with 10–0 nylon sutures, with the sutures starting from the edges. The tissues should be opposed well as leakage of the humor aqueous will cause obstacles preoperatively and postoperatively. In eyes with the traumatized cornea, biometry and keratometry may not be accurately measured, hence intraocular lens calculation may be compromised. In these cases, an IOL calculation of the fellow eye and a keratometry of average value as 44 may be used.

During the surgery, the state of the anterior and posterior capsule and the zonules should always be taken into consideration. In intact capsules and zonules, standard phacoemulsification with or without the help of trypan blue dye may be performed.

In cases with the anterior capsular tear, the lens becomes pacified quickly and continuous curvilinear capsulorrhexis may not be completed, requiring completing the capsulorrhexis by Vannas scissors.

When lens zonules are injured, capsular or iris hooks may be used to secure the bag, and capsular tension rings should be implanted in zonular dialysis less than 120 degrees. Capsular tension rings should not be placed in dialysis with a posterior capsular rupture.

Most traumatic cataracts are soft as they may be easily aspirated by I/A tip or simcoe cannula. In traumatic cataract surgery, the parameters used during the surgery should be low, such as a bottle height of 60–75 cm, aspiration rate with 18–20 cc/min, and low vacuum as 180–200 mm Hg, however, it should be kept in mind that these settings may differ according to the case, the surgeon and the device used.

At the end of the surgery, a 0.3 mL of cefuroxime solution (concentration of 1.0 mg/0.1 mL) should be injected into the anterior chamber for prophylaxis. The wounds and the entrance areas should be carefully evaluated for any leakage as it may cause complications as endophthalmitis and hypotony.

12. Conclusion

In an eye injury, taking a detailed history is important to guide a proper evaluation, diagnostic approach, and treatment modality. Early and thorough identification of the affected anterior segment tissues involved will provide timely and appropriate management which will determine the final outcome for the visual function and globe integrity.

Acknowledgements

No funding.

The photos are published with the courtesy of Prof Dr. Cemil Tascioglu City Hospital, Department of Ophthalmology, Istanbul, Turkey.

Conflict of interest

The authors declare no conflict of interest.

Author details

Arzu Taskiran Comez^{1,2*} and Mehmet Ozbas³

1 Department of Ophthalmology, Canakkale Onsekiz Mart University, Canakkale, Turkey

2 Department of Ophthalmology, Prof. Dr. Cemil Tascioglu City Hospital, Istanbul, Turkey

3 Bakirkoy Dr. Sadi Konuk Training and Research Hospital Eye Clinic, Istanbul, Turkey

*Address all correspondence to: arzucomez@yahoo.com

IntechOpen

© 2022 The Author(s). Licensee IntechOpen. This chapter is distributed under the terms of the Creative Commons Attribution License (<http://creativecommons.org/licenses/by/3.0>), which permits unrestricted use, distribution, and reproduction in any medium, provided the original work is properly cited. 

References

- [1] <https://www.aao.org/eyenet/article/management-of-traumatic-cataract>
- [2] Serna-Ojeda JC et al. International Ophthalmology. 2015;**35**(4):451-458
- [3] Négrel AD, Thylefors B. Ophthalmic Epidemiology. 1998;**5**(3):143-169
- [4] Kuhn F, Morris R, Witherspoon CD. Birmingham eye trauma terminology (BETT): Terminology and classification of mechanical eye injuries. Ophthalmology Clinics of North America. 2002;**15**(2):139-143. DOI: 10.1016/s0896-1549(02)00004-4
- [5] Harris PM. Workplace Injuries Involving the Eyes, 2008. 2011; Bureau of Labor Statistics, Washington, USA. Available from: <http://www.bls.gov/opub/mlr/cwc/workplace-injuriesinvolving-the-eyes-2008.pdf>
- [6] Zakrzewski H, Chung H, Sanders E, Hanson C, Ford B. Evaluation of occupational ocular trauma: Are we doing enough to promote eye safety in the workplace? Canadian Journal of Ophthalmology. 2017;**52**(4):33842. DOI: 10.1016/j.cjco.2016.11.034
- [7] Sahraravand A, Haavisto AK, Holopainen JM, Leivo T. Ocular traumas in working age adults in Finland helsinki Ocular Trauma Study. Archives of Ophthalmology. 2005;**123**(7):9706. DOI: 10.1111/aos.13313
- [8] McGwin G, Xie A, Owsley C. Rate of eye injury in the United States. Archives of Ophthalmology. 2005;**123**(7):9706. DOI: 10.1001/archoph.123.7.970
- [9] McCarty CA, Fu CLH, Taylor HR. Epidemiology of ocular trauma in Australia. Ophthalmology. 1999;**106**(9):184752. DOI: 10.1016/S0161-6420(99)90361-5
- [10] Kuhn F, Morris R, Witherspoon CD, Mann LR. Epidemiology of blinding trauma in the United States eye injury registry. Ophthalmic Epidemiology. 2006;**13**(3):20916. DOI: 10.1080/09286580600665886
- [11] Peate WF. Work-related eye injuries and illnesses. American Family Physician. 2007;**75**:117-122
- [12] Kuhn F, Maisiak R, Mann L, Mester V, Morris R, Witherspoon C. The ocular trauma score (OTS). Ophthalmology Clinics of North America. 2002;**15**:163-166
- [13] González AB, Díaz EG, Eugenio PB, Glosa SL, editors. Atlas Urgencias en Oftalmología. Vol. I. Barcelona, Spain: E-Publishing Inc; 2009. p. 250
- [14] Quesada JM, Lloves JM, Delgado DV. Ocular chemical burns in the workplace: Epidemiological characteristics. Burns. Aug 2020;**46**(5):1212-1218. DOI: 10.1016/j.burns.2019.11.007
- [15] Beare JD. Eye injuries from assault with chemicals. The British Journal of Ophthalmology. 1990;**74**(514-8):3
- [16] Kılıç Müftüoğlu İ, Aydın Akova Y, Çetinkaya A. Clinical spectrum and treatment approaches in corneal burns. Turkish Journal of Ophthalmology. 2015;**45**:182-187
- [17] Dua SC, McCarty CA, Snibson G, Loughnan M, Sullivan L, Daniell M, et al. Management of alkali burns: An-11-year retrospective review. Ophthalmology. 2000;**107**:182935
- [18] Wagoner MD. Chemical injuries of the eye: Current concepts in pathophysiology and therapy. Survey of Ophthalmology. 1997;**41**:275313
- [19] Pfister RR, Koski J. Alkali burns of the eye: Pathophysiology and treatment. Southern Medical Journal. 1982;**75**:417-422

- [20] Dua HS, King AJ, Joseph A. A new classification of ocular surface burns. *The British Journal of Ophthalmology*. 2001;**85**:1379-1383
- [21] Roper-Hall MJ. Thermal and chemical burns. *Transactions of the Ophthalmological Societies of the United Kingdom*. 1965;**85**:631-653
- [22] McKee D, Thoma A, Bailey K, Fish J. A review of hydrofluoric acid burn management. *Plastic Surgery (Oakv)*. 2014;**22**:95-98
- [23] Dinis-Oliveira RJ, Carvalho F, Moreira R, Proenca JB, Santos A, Duarte JA, et al. Clinical and forensic signs related to chemical burns: A mechanistic approach. *Burns*. 2015;**41**:658-679
- [24] Ochlin DH, Rajasingh CM, Karanas YL, Davis DJ. Fullthickness chemical burn from trifluoroacetic acid: A case report and review of the literature. *Annals of Plastic Surgery*. 2018;**81**:528-301
- [25] Sharma N, Kaur M, Agarwal T, Sangwan VS, Vajpayee RB. Treatment of acute ocular chemical burns. *Survey of Ophthalmology*. 2018;**63**:214-235
- [26] Gupta N, Kalaivani M, Tandon R. Comparison of prognostic value of Roper Hall and Dua classification systems in acute ocular burns. *The British Journal of Ophthalmology*. 2011;**95**:194-198
- [27] McCulley J. Chemical injuries. In: Smolin G, Thoft R, editors. *The Cornea: Scientific Foundation and Clinical Practice*. Boston, MA: Little, Brown and Co.; 1987
- [28] Baradaran-Rafii A, Eslani M, Haq Z, Shirzadeh E, Huvard MJ, Djalilian AR. Current and upcoming therapies for ocular surface chemical injuries. *The Ocular Surface*. 2017;**15**:48-64
- [29] Schrage NF, Langefeld S, Zschocke J, Kuckelkorn R, Redbrake C, Reim M. Eye burns: An emergency and continuing problem. *Burns*. 2000;**26**:689-699
- [30] Paterson CA, Pfister RR, Levinson RA. Aqueous humor pH changes after experimental alkali burns. *American Journal of Ophthalmology*. 1975;**79**:414-419
- [31] Nelson JD, Kopietz LA. Chemical injuries to the eyes. Emergency, intermediate, and long-term care. *Postgraduate Medicine*. 1987;**81** (62-6):9-71 5
- [32] Alexander KS, Wasiak J, Cleland H. Chemical burns: Diphoterine untangled. *Burns*. 2018;**44**:752-766
- [33] Wiesner N, Dutescu RM, Uthoff D, Kottek A, Reim M, Schrage N. First aid therapy for corrosive chemical eye burns: Results of a 30- year longitudinal study with two different decontamination concepts. *Graefes Archive for Clinical and Experimental Ophthalmology*. 2019;**257**:1795-1803
- [34] Mathieu L, Nehles J, Blomet J, Hall AH. Efficacy of hexafluorine for emergent decontamination of hydrofluoric acid eye and skin splashes. *Veterinary and Human Toxicology*. 2001;**43**:263-265
- [35] Rihawi S, Frentz M, Reim M, Schrage NF. Rinsing with isotonic saline solution for eye burns should be avoided. *Burns*. 2008;**34**:1027-1032
- [36] Paterson CA, Pfister RR. Intraocular pressure changes after alkali burns. *Archives of Ophthalmology*. 1974;**91**:211-218
- [37] Bian F, Pelegriano FS, Henriksson JT, Pflugfelder SC, Volpe EA, Li DQ, et al. Differential effects of dexamethasone and doxycycline on inflammation and MMP production in murine

alkali-burned corneas associated with dry eye. *The Ocular Surface*. 2016; **14**:242-254

[38] Davis AR, Ali QK, Aclimandos WA, Hunter PA. Topical steroid use in the treatment of ocular alkali burns. *The British Journal of Ophthalmology*. 1997; **81**:732-734

[39] Seedor JA, Perry HD, McNamara TF, Golub LM, Buxton DF, Guthrie DS. Systemic tetracycline treatment of alkali-induced corneal ulceration in rabbits. *Archives of Ophthalmology*. 1987; **105**:268-271

[40] Dua HS, Ting DSJ, Al Saadi A, et al. Chemical eye injury: Pathophysiology, assessment and management. *Eye*. 2020; **34**:2001-2019. DOI: 10.1038/s41433-020-1026-6

[41] Pfister RR, Nicolaro ML, Paterson CA. Sodium citrate reduces the incidence of corneal ulcerations and perforations in extreme alkali-burned eyes—acetylcysteine and ascorbate have no favorable effect. *Investigative Ophthalmology & Visual Science*. 1981; **21**:486-490

[42] Clare G, Suleman H, Bunce C, Dua H. Amniotic membrane transplantation for acute ocular burns. *Cochrane Database of Systematic Reviews*. 2012; **9**:Cd009379

[43] Eslani M, Baradaran-Rafii A, Cheung AY, Kurji KH, Hasani H, Djalilian AR, et al. Amniotic membrane transplantation in acute severe ocular chemical injury: A randomized clinical trial. *American Journal of Ophthalmology*. 2019; **199**:209-215

[44] Kheirkhah A, Johnson DA, Paranjpe DR, Raju VK, Casas V, Tseng SC. Temporary sutureless amniotic membrane patch for acute alkaline burns. *Archives of Ophthalmology*. 2008; **126**:1059-1066

[45] Suri K, Kosker M, Raber IM, Hammersmith KM, Nagra PK, Ayres BD, et al. Sutureless amniotic membrane ProKera for ocular surface disorders: Short-term results. *Eye & Contact Lens*. 2013; **39**:341-347

[46] Saika S, Uenoyama K, Hiroi K, Tanioka H, Takase K, Hikita M. Ascorbic acid phosphate ester and wound healing in rabbit corneal alkali burns: Epithelial basement membrane and stroma. *Graefe's Archive for Clinical and Experimental Ophthalmology*. 1993; **231**:221-227

[47] Salman IA, Gundogdu C. Epithelial healing in experimental corneal alkali wounds with nondiluted autologous serum eye drops. *Cutaneous and Ocular Toxicology*. 2010; **29**:116-121

[48] Sharma N, Lathi SS, Sehra SV, Agarwal T, Sinha R, Titiyal JS, et al. Comparison of umbilical cord serum and amniotic membrane transplantation in acute ocular chemical burns. *The British Journal of Ophthalmology*. 2015; **99**:669-673

[49] Panda A, Jain M, Vanathi M, Velpandian T, Khokhar S, Dada T. Topical autologous platelet-rich plasma eyedrops for acute corneal chemical injury. *Cornea*. 2012; **31**:989-993

[50] Phan TM, Foster CS, Shaw CD, Zagachin LM, Colvin RB. Topical fibronectin in an alkali burn model of corneal ulceration in rabbits. *Archives of Ophthalmology*. 1991; **109**:414-419

[51] Zahir-Jouzdani F, Mahbod M, Soleimani M, Vakhshiteh F, Arefian E, Shahosseini S, et al. Chitosan and thiolated chitosan: Novel therapeutic approach for preventing corneal haze after chemical injuries. *Carbohydrate Polymers*. 2018; **179**:42-49

[52] Kim MJ, Jun RM, Kim WK, Hann HJ, Chong YH, Park HY, et al. Optimal concentration of human epidermal

growth factor (hEGF) for epithelial healing in experimental corneal alkaliwounds. *Current Eye Research*. 2001;**22**:272-279

[53] Jian-Wei L, Xiu-Yun L, Ai-Jun D. Effectiveness of heparin eye drops in paraquat-induced ocular injury. *Cutaneous and Ocular Toxicology*. 2017;**36**:377-380

[54] Cejkova J, Olmiere C, Cejka C, Trosan P, Holan V. The healing of alkali-injured cornea is stimulated by a novel matrix regenerating agent (RGTA, CACICOL20): A biopolymer mimicking heparan sulfates reducing proteolytic, oxidative and nitrosative damage. *Histology and Histopathology*. 2014;**29**:457-478

[55] Ustaoglu M, Solmaz N, Onder F. Ocular surface chemical injury treated by regenerating agent (RGTA, Cacicol20). *GMS Ophthalmology Cases*. 2017;**7**:Doc28

[56] Singh P, Tyagi M, Kumar Y, Gupta KK, Sharma PD. Ocularchemical injuries and their management. *Oman Journal of Ophthalmology*. 2013;**6**:83-86

[57] Kuckelkorn R, Redbrake C, Reim M. Tenonplasty: A new surgical approach for the treatment of severe eye burns. *Ophthalmic Surgery and Lasers*. 1997;**28**:105-110

[58] Dua HS, Miri A, Faraj LA, Said DG. Free autologous conjunctival grafts. *Ophthalmology*. 2012;**119**:2189-21e2

[59] Tamhane A, Vajpayee RB, Biswas NR, Pandey RM, Sharma N, Titiyal JS, et al. Evaluation of amniotic membrane transplantation as an adjunct to medical therapy as compared with medical therapy alone in acute ocular burns. *Ophthalmology*. 2005; **112**:1963-1969

[60] Dua HS. Sequential sectoral conjunctival epitheliectomy (SSCE). In:

Holland EJ, Mannis MJ, editors. *Ocular Surface Disease Medical and Surgical Management*. New York: Springer. 2002. p. 168-174.

[61] Mastropasqua L, Manuela L, Dua HS, D'Uffizi A, Di Nicola M, Calienno R, et al. In vivo evaluation of corneal nerves and epithelial healing after treatment with recombinant nerve growth factor for neurotrophic keratopathy. *American Journal of Ophthalmology*. 2020;**217**:278-286. DOI: 10.1016/j.ajo.2020.04.036

[62] Dua HS, Gomes JA, King AJ, Maharajan VS. The amniotic membrane in ophthalmology. *Survey of Ophthalmology*. 2004;**49**:51-77

[63] Dua HS, Miri A, Said DG. Contemporary limbal stem cell transplantation - a review. *Clinical & Experimental Ophthalmology*. 2010;**38**:104-117

[64] McGwin G Jr, Owsley C. Incidence of emergency department-treated eye injury in the United States. *Archives of Ophthalmology*. 2005;**123**(5):662-666

[65] MacEwen CJ, McLatchie GR. Eye injuries in sport. *Scottish Medical Journal*. 2010;**55**(2):22-24

[66] Forrest KY, Cali JM. Epidemiology of lifetime work-related eye injuries in the U.S. population associated with one or more lost days of work. *Ophthalmic Epidemiology*. 2009;**16**(3):156-162

[67] Blackburn J, Levitan EB, MacLennan PA, et al. A case-crossover study of risk factors for occupational eye injuries. *Journal of Occupational and Environmental Medicine*. 2012; **54**(1):42-47

[68] Banta J. *Ocular Trauma*. Edinburgh: Elsevier Saunders; 2007

[69] Meek R, Sullivan A, Favilla M, et al. Is homatropine 5% effective in reducing

pain associated with corneal abrasion when compared with placebo? A randomized controlled trial. *Emergency Medicine Australasia*. 2010;**22**(6):507-513

[70] Fraser S. Corneal abrasion. *Clinical Ophthalmology*. 2010;**4**(5):387-390

[71] Hua L, Doll T. A series of 3 cases of corneal abrasion with multiple etiologies. *Optometry*. 2010;**81**(2):83-85

[72] Turner A, Rabiou M. Patching for corneal abrasion. *Cochrane Database of Systematic Reviews*. 2006;**4**(2):CD004764

[73] Freidman NJ, Kaiser PK. The conjunctiva. In: Freidman NJ, Kaiser PK, editors. *Essentials of Ophthalmology*. Philadelphia, PA: Saunders Inc; 2007. pp. 149-159

[74] Fukuyama J, Hayasaka S, Yamada K, Setogawa T. Causes of subconjunctival hemorrhage. *Ophthalmologica*. 1990;**200**:63-67

[75] Pitts JF, Jardine AG, Murray SB, Barker NH. Spontaneous subconjunctival haemorrhage—a sign of Hypertension? *The British Journal of Ophthalmology*. 1992;**76**(5):297-299

[76] Wilson RJ. Subconjunctival hemorrhage: Overview and management. *Journal of the American Optometric Association*. 1986; **57**(3):376-380

[77] Yamagami S, Funatsu H, Usui T, Ono K, Araie M, et al. Management of subconjunctival haematoma by tissue plasminogen activator. *Clinical & Experimental Ophthalmology*. 2005;**33**:541-542

[78] King AB, Walsh FB. Trauma to the head with particular reference to the ocular signs; injuries involving the hemispheres and brain stem; miscellaneous conditions; diagnostic

principles; treatment. *American Journal of Ophthalmology*. 1949;**32**(3):379-398

[79] Wipperman JL, Dorsch JN. Evaluation and management of corneal abrasions. *American Family Physician*. 2013;**87**(2):114-120

[80] Akbaş E, Barut Selver Ö, Palamar M. Retrospective evaluation of corneal foreign bodies with anterior segment optical coherence tomography. *Turkish Journal of Ophthalmology*. 2021;**51**:265-268

[81] Aslam SA, Sheth HG, Vaughan AJ. Emergency management of corneal injuries. *Injury*. 2007;**38**:594-597

[82] Ahmed F, House RJ, Feldman BH. Corneal abrasions and corneal foreign bodies. *Primary Care: Clinics in Office Practice*. 2015;**42**(3):363-375. DOI: 10.1016/j.pop.2015.05.004

[83] Kim SJ, Flach AJ, Jampol LM. Nonsteroidal anti-inflammatory drugs in ophthalmology. *Surv Ophthalmol* 2010;**55**(2):108-33. 16. Duffin RM, Olson RJ. Tetracaine toxicity. *Annals of Ophthalmology*. 1984;**16**(9):836-838

[84] Menghini M, Knecht PB, Kaufmann C. Treatment of traumatic corneal abrasions: A three-arm, prospective, randomized study. *Ophthalmic Research*. 2013;**50**(13-8):374

[85] Flynn CA, D'Amico F, Smith G. Should we patch corneal abrasions? A meta-analysis. *The Journal of Family Practice*. 1998;**47**(4):264-270

[86] Erdey RA, Lindahl KJ, Temnycky GO, et al. Technique for application of tissue adhesive for corneal perforations. *Ophthalmic Surgery*. 1991;**22**:352-354

[87] Rowsey JJ, Hays J. Refractive reconstruction of acute eye injuries. *Ophthalmic Surgery*. 1984;**15**:569-574

- [88] Crouch ER, Williams PB. Trauma: Ruptures and bleeding. In: Tasman W, Jaeger EA, Duane S, editors. *Clinical Ophthalmology*. Vol. 4. Philadelphia, PA: Lippincott; 1993 chap 16. pp. 1-22
- [89] Kylstra JA, Larnkin JC, Runyan DK. Clinical predictors of scleral rupture after blunt ocular trauma. *American Journal of Ophthalmology*. 1993; **115**:530-535
- [90] Wilson FM. Traumatic hyphema. Pathogenesis and management. *Ophthalmology*. 1980; **87**:910
- [91] Goldberg MF. Sickled erythrocytes, hyphema and secondary glaucoma. *Ophthalmic Surgery*. 1979; **10**:17
- [92] Sankar PS, Chen TC, Grosskreutz CL, Pasquale LR. Traumatic Hyphema. *International Ophthalmology Clinics*. 2002; **42**(3):57-68. DOI: 10.1097/00004397-200207000-00008
- [93] Agapitos PJ, Noel LP, Clarke WN. Traumatic hyphema in children. *Ophthalmology*. 1987; **94**:1238-1241
- [94] SooHoo JR, Davies BW, Braverman RS, Enzenauer RW, McCourt EA. Pediatric traumatic hyphema: A review of 138 consecutive cases. *Journal of AAPOS*. 2013; **17**:565-567
- [95] Edwards WC, Layden WF. Traumatic hyphema. *American Journal of Ophthalmology*. 1973; **75**:110
- [96] Gharaibeh A, Savage HI, Scherer RW, Goldberg MF, Lindsley K. Medical interventions for traumatic hyphema. *Cochrane Database Syst Rev*. jan 2011; **19**(1):CD005431. DOI: 10.1002/14651858.CD005431.pub2. Update in: *Cochrane Database Syst Rev*. 2013; **12**:CD005431
- [97] Rocha KM, Martins EN, Melo LA Jr, Moraes NS. Outpatient management of traumatic hyphema in children: Prospective evaluation. *Journal of AAPOS*. 2004; **8**:357-361
- [98] Walton W, Von Hagen S, Grigorian R, Zarbin M. Management of traumatic hyphema. *Survey of Ophthalmology*. 2002; **47**:297-334
- [99] Al-Shahwan S, Al-Torbak AA, Turkmani S, Al-Omran M, Al-Jadaan I, Edward DP. Side-effect profile of brimonidine tartrate in children. *Ophthalmology*. 2005; **112**:2143
- [100] Gorn RA. The detrimental effect of aspirin on hyphema rebleed. *Annals of Ophthalmology*. 1979; **11**:351
- [101] Crawford JS. The effect of aspirin on rebleeding in traumatic hyphema. *Trans Am Ophthalmol Soc* 1975; **73**:357
12. Marcus M, Biedner B, Lifshitz T, et al. Aspirin and secondary bleeding after traumatic hyphema. *Annals of Ophthalmology*. 1988; **20**:157
- [102] Armaly MF. The effect of corticosteroids on intraocular pressure and fluid dynamics: I. The effect of dexamethasone in the normal eye. *Archives of Ophthalmology*. 1963; **70**:482
- [103] Goldman H. Cortisone glaucoma. *Archives of Ophthalmology*. 1962; **68**:621
- [104] Crouch ER, Frenkel M. Aminocaproic acid in the treatment of traumatic hyphema. *American Journal of Ophthalmology*. 1976; **81**:355
- [105] Kutner B, Fourman S, Brein K, et al. Aminocaproic acid reduces the risk of secondary hemorrhage in patients with traumatic hyphema. *Archives of Ophthalmology*. 1987; **105**:206
- [106] McGretrick JJ, Jampol LM, Goldberg MF, et al. Aminocaproic acid reduces the risk of secondary hemorrhage in patients with traumatic

hyphema. *Archives of Ophthalmology*. 1983;**101**:1031

[107] Uusitalo RJ, Saari MS, Aine E, Saari KM. The effect of tranexamic acid on secondary hemorrhage after traumatic hyphema. *Acta Ophthalmologica*. 1980;**58**:787

[108] Teboul BK, Jacob JL, Barsoum-Homsy M, et al. Clinical evaluation of aminocaproic acid for managing traumatic hyphema in children. *Ophthalmology*. 1995;**102**:1646-1653

[109] Kim MH, Koo TH, Sah WJ, Cung SM. Treatment of total hyphema with relatively low-dose tissue plasminogen activator. *Ophthalmic Surgery and Lasers*. 1998;**29**(9):762-766

[110] Benner JD. Transcorneal oxygen therapy for glaucoma associated with sickle cell hyphema. *American Journal of Ophthalmology*. 2000;**130**(4):514-515

[111] Girkin CA, McGwin G Jr, Long C, Morris R, Kuhn F. Glaucoma after ocular contusion: A cohort study of the United States Eye Injury Registry. *Journal of Glaucoma*. 2005;**14**:470-473

[112] De Leon-Ortega JE, Girkin CA. Ocular trauma-related glaucoma. *Ophthalmology Clinics of North America*. 2002;**15**:215-223

[113] Milder E, Davis K. Ocular trauma and glaucoma. *International Ophthalmology Clinics*. 2008;**48**:47-64

[114] Girkin CA, McGwin G Jr, Morris R, Kuhn F. Glaucoma following penetrating ocular trauma: A cohort study of the United States Eye Injury Registry. *American Journal of Ophthalmology*. 2005;**139**:100-105

[115] Sihota R, Kumar S, Gupta V, Dada T, Kashyap S, Insan R, et al. Early predictors of traumatic glaucoma after closed globe injury. *Archives of Ophthalmology*. 2008;**126**:921-926

[116] Bai HQ, Yao L, Wang DB, Jin R, Wang YX. Causes and treatments of traumatic secondary glaucoma. *European Journal of Ophthalmology*. 2009;**19**:201-206

[117] Campbell DG. Ghost cell glaucoma following trauma. *Ophthalmology*. 1981;**88**:1151-1158

[118] Viestenz A, Kuchle M. Blunt ocular trauma. Part I: Blunt anterior segment trauma. *Der Ophthalmologe*. 2004;**101**(12):1239-1257; quiz 1257-1258. DOI: 10.1007/s00347-004-1118-x 2

[119] Viestenz A, Kuchle M. Blunt ocular trauma. Part II. Blunt posterior segment trauma. *Der Ophthalmologe*. 2005;**102**(1):89-99; quiz 100-101. DOI: 10.1007/s00347-004-1137-7

[120] Sauer TC, Shingleton BJ, Hersh PS, Kenyon KR. Anterior Segment Trauma. In: Albert D, Miller J, Azar D, Young LH. (eds) *Albert and Jakobiec's Principles and Practice of Ophthalmology*. Springer, Cham. 2021. https://doi.org/10.1007/978-3-319-90495-5_325-1

[121] Canavan YM, Archer DB. Anterior segment consequences of blunt ocular injury. *The British Journal of Ophthalmology*. 1982;**66**(9):549-555

[122] Alper MG. Contusion angle deformity and glaucoma. Gonioscopic observations and clinical course. *Archives of Ophthalmology*. 1963;**69**:455-467

[123] Manners T, Salmon JF, Barron A, Willies C, Murray AD. Trabeculectomy with mitomycin C in the treatment of post-traumatic angle recession glaucoma. *The British Journal of Ophthalmology*. 2001;**85**:159-163

[124] Gentile RC, Pavlin CJ, Liebmann JM, et al. Diagnosis of traumatic cyclodialysis by ultrasound biomicroscopy. *Ophthalmic Surgery and Lasers*. 1996;**27**:97-105

- [125] Mateo-Montoya A, Dreifuss S. Anterior segment optical coherence tomography as a diagnostic tool for cyclodialysis clefts. *Archives of Ophthalmology*. 2009;**127**:109-110
- [126] Kuchle M, Naumann GO. Direct cyclopexy for traumatic cyclodialysis with persisting hypotony. Report in 29 consecutive patients. *Ophthalmology*. 1995;**102**:322-333
- [127] Naumann G, Kuchle M. Noninvasive closure of persistent cyclodialysis cleft. *Ophthalmology*. 1997;**104**:1207
- [128] Brooks AM, Troski M, Gillies WE. Noninvasive closure of a persistent cyclodialysis cleft. *Ophthalmology*. 1996;**103**:1943-1945
- [129] Krohn J. Cryotherapy in the treatment of cyclodialysis cleft induced hypotony. *Acta Ophthalmologica Scandinavica*. 1997;**75**:96-98
- [130] Muga R, Maul E. The management of lens damage in perforating corneal lacerations. *The British Journal of Ophthalmology*. 1978;**62**:784-787
- [131] Agarwal A, Kumar DA, Nair V. Cataract surgery in the setting of trauma. *Current Opinion in Ophthalmology*. 2010;**21**(1):65-70. DOI: 10.1097/icu.0b013e3283331579
- [132] Lamkin JC, Azar PT, Mead MD, et al. Simultaneous corneal laceration repair, cataract removal, and posterior chamber intraocular lens implantation. *American Journal of Ophthalmology*. 1992;**113**:626-631
- [133] Beatty RF, Beatty RL. The repair of corneal and scleral lacerations. *Seminars in Ophthalmology*. 1994;**9**(3):165-176. DOI: 10.3109/08820539409060012
- [134] Cohen KL. Inaccuracy of intraocular lens power calculation after traumatic corneal laceration and cataract. *Journal of Cataract and Refractive Surgery*. 2001;**1519-1522**
- [135] Mohammadpour M, Jafarinasab MR, Javadi MA. Outcomes of acute postoperative inflammation after cataract surgery. *European Journal of Ophthalmology*. 2007;**17**(1):20-28. DOI: 10.1177/112067210701700104
- [136] Sen P, Shah C, Sen A, Jain E, Mohan A. Primary versus secondary intraocular lens implantation in traumatic cataract after open-globe injury in pediatric patients. *Journal Cataract Refract Surg*. Dec 2018;**44**(12):1446-1453. DOI: 10.1016/j.jcrs.2018.07.061