

We are IntechOpen, the world's leading publisher of Open Access books Built by scientists, for scientists

6,900

Open access books available

185,000

International authors and editors

200M

Downloads

Our authors are among the

154

Countries delivered to

TOP 1%

most cited scientists

12.2%

Contributors from top 500 universities



WEB OF SCIENCE™

Selection of our books indexed in the Book Citation Index
in Web of Science™ Core Collection (BKCI)

Interested in publishing with us?
Contact book.department@intechopen.com

Numbers displayed above are based on latest data collected.
For more information visit www.intechopen.com



Vitrectomy in Diabetic Retinopathy

*Payal Naresh Shah, Mahesh P. Shanmugam
and Divyansh K. Mishra*

Abstract

Diabetic vitrectomy is a complicated vitreoretinal surgery due to the complex interaction of various factors. Indications of vitrectomy in diabetes patients would comprise of non-resolving vitreous haemorrhage, taut posterior hyaloid causing vitreo-papillary traction, vitreomacular traction, non-resolving macular edema due to epiretinal membrane, posterior pole tractional retinal detachment or combined retinal detachment. Pre-operative systemic evaluation, a thorough clinical evaluation with ancillary investigations like ultrasound and optical coherence tomography are important for planning the surgery. In this chapter, we would be discussing the basic principles of PVD induction, surgical steps and techniques involved in diabetic vitrectomy. Complications associated can be intraoperative or post-operative. Intra-operative complications would include corneal edema, cataract, bleeding and iatrogenic breaks. Post-operative complications can be divided into early and late, which include vitreous cavity bleeding, raised intraocular pressure, re proliferation, epiretinal membrane, cataract, glaucoma and hypotony.

Keywords: diabetic vitrectomy, proliferative diabetic retinopathy, fibrovascular membrane dissection, delamination, diabetic retinal detachment

1. Introduction

Diabetic retinopathy is one of the leading causes of blindness across the world. The estimated global prevalence of proliferative diabetic retinopathy amongst diabetic patients is 7.5%, and it is higher in type 1 compared to type 2 diabetes [1].

The first pars plana vitrectomy was performed for persistent vitreous haemorrhage in a diabetes patient by Robert Machemer in 1970 using a single port instrument called vitrectomy infusion suction cutter (VISC) [2, 3]. There has been a drastic evolutionary change in the technique of diabetic vitrectomy since then. In this chapter, we would be discussing the current indications of vitrectomy in diabetes patients, various surgical techniques and complications.

1.1 Indications of vitrectomy in diabetic retinopathy

1. Non-resolving vitreous haemorrhage (VH)
2. Dense subhyaloid haemorrhage (SHH) over the macula

3. Tractional retinal detachment (TRD) threatening or involving the fovea
4. Combined retinal detachment (CRD)
5. Vitreomacular traction (VMT) or epiretinal membrane (ERM) causing non-resolving macular edema
6. Taut posterior hyaloid causing vitreopapillary traction [4].

Surgery for extramacular TRDs is generally not advocated as vision is preserved in most cases. Patients who become symptomatic with visual complaints or metamorphopsia or if there is a progression of extramacular TRD to threaten the macula would benefit from surgery [5].

2. Pre-operative assessment

Thorough anterior segment evaluation with special attention to health of corneal epithelium, anterior and posterior synechiae, neovascularisation of angles and iris, and cataract need to be performed. Vitreous haemorrhage with dense anterior opacities in the Berger's space or significant cataracts can hinder the view behind. Thus a combined cataract surgery along with vitrectomy can be planned in these cases.

2.1 What to look for, while examining the fundus?

1. Assess the posterior hyaloid separation clinically and assess the areas of dense attachments and planes of separation in order to plan the surgery and site of initiation.
2. FVP-flat or elevated—A flat fibrovascular proliferation without hyaloid separation may be much more surgically challenging compared to an elevated proliferation with separated hyaloid.
3. Configuration of detachment—A tractional detachment is usually concave, while a convex or bullous configuration suggests a combined rhegmatogenous component.
4. Extent of TRD/CRD with FVP membranes beyond the equator and extending anteriorly—indicate that the dissection of these peripheral membranes would be difficult and if its inferior quadrants may warrant external support with a belt buckle (BB)/segmental buckle (SB) based on the extent.
5. Presence of any abnormal vitreoretinal attachments (lattice degenerations/ FVP membranes/breaks) in the periphery and midperiphery—so as to plan for an external tamponade—BB/SB.
6. Associated lesions like macular schisis (implies long standing traction) or macular hole (to plan for inverse flap ILM peeling).
7. Looking at the vascularity of the membranes—more vascular—better to consider pre-operative anti-VEGF injection to reduce the risk of bleeding.

8. Presence of sclerosed vessels would suggest thin retina with higher chances of iatrogenic damage, which one needs to be cautious about.
9. Sometimes, a subretinal bleed or subretinal gliotic (SRG) bands may be noted which also point towards a combined detachment.
10. Long standing traction over disc, papillomacular bundle or fovea—can have a guarded visual prognosis.

2.2 Ancillary investigations

2.2.1 Role of OCT

In patients with media clarity, an optical coherence tomography (OCT) scan can be of utmost value to assess the vitreomacular anatomy, extent of macular detachment, status of fovea, vitreopapillary traction, vitreomacular traction, tractional schisis, epiretinal membrane and macular edema. It can also help in identifying progression of detachment on follow-up. Patients with ERM or macular edema can also be benefited with ERM and internal limiting membrane (ILM) peeling.

Figure 1 shows pre-operative and post-operative OCT and fundus photo comparison. This is a patient with PDR with florid NVD and NVE with VMT and CME with vitreoschisis with vitreopapillary traction pre-operatively. Post-operative OCT shows resolution of all traction and edema with temporal retinal thinning.

A widefield OCT helps in better understanding of the vitreomacular anatomy in the centre as well as mid periphery. It can also help in identifying the plane of dissection and thus help planning the site of initiation [6].

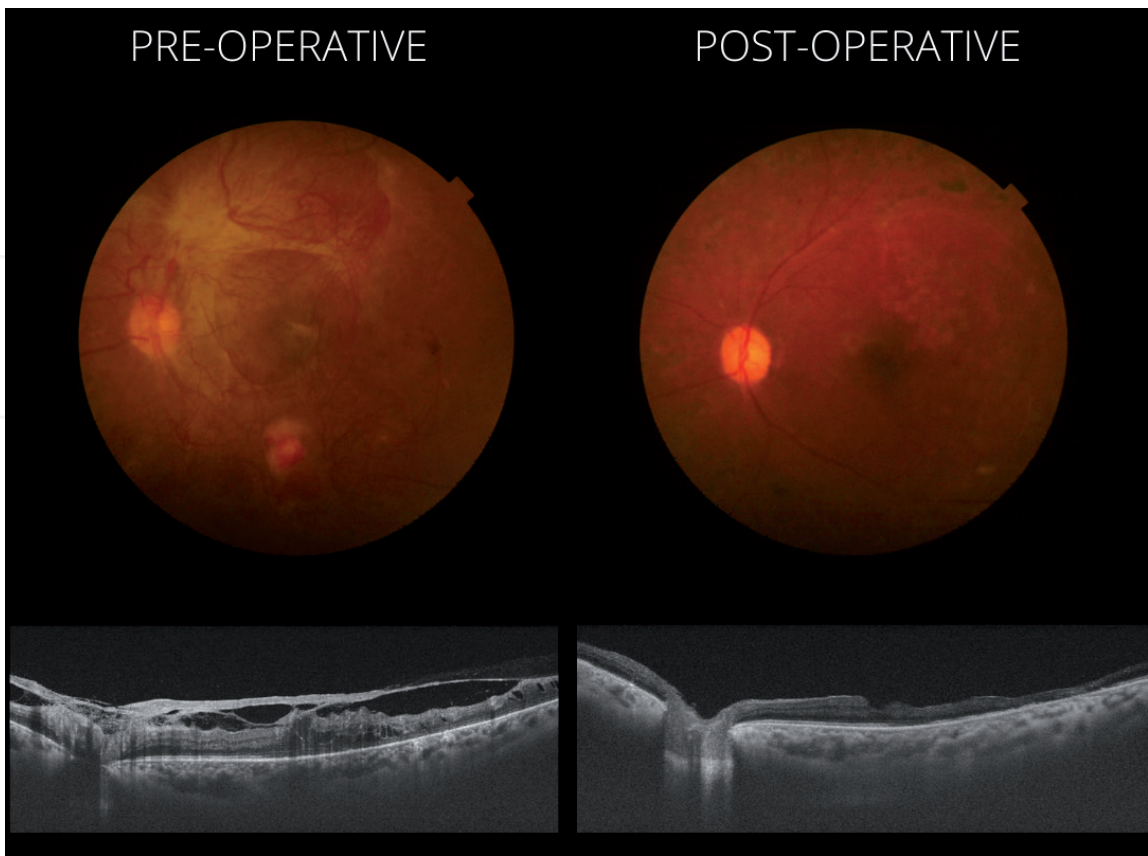


Figure 1.
Preoperative and postoperative colour fundus photograph and OCT scans of a patient with PDR with florid NVD and NVE with VMT and CME with vitreoschisis and vitreopapillary traction.

2.2.2 Role of ultrasound

In patients with dense media opacities like cataract or vitreous haemorrhage, a pre-operative ultrasound evaluation is warranted. This will help to understand the status of posterior hyaloid, location of focal attachments of posterior hyaloid onto the retina, any traction on retina, and co-existing retinal detachment. **Figure 2** shows ultrasound image of a patient with vitreous haemorrhage with subhyaloid haemorrhage with thickened and incomplete hyaloid separation.

Systemic evaluation and stabilisation of the patient is important before taking up for surgery. In patients who are on haemodialysis, a pre-operative heparin-free dialysis should be recommended in order to reduce the chances of intraoperative and post-operative bleeding.

2.2.3 Patient counselling

Besides advocating for surgery, it is very important to counsel the patient about the visual potential since despite good anatomical outcomes, in patients with long standing detachments and macular ischemia, functional outcomes may not be very satisfying. The chances of multiple surgeries due to recurrent vitreous cavity bleeds or redetachments due to repletions should be explained. Need for subsequent cataract surgery or silicon oil removal surgery should be explained clearly beforehand. Importance of good systemic control should be re-emphasised.

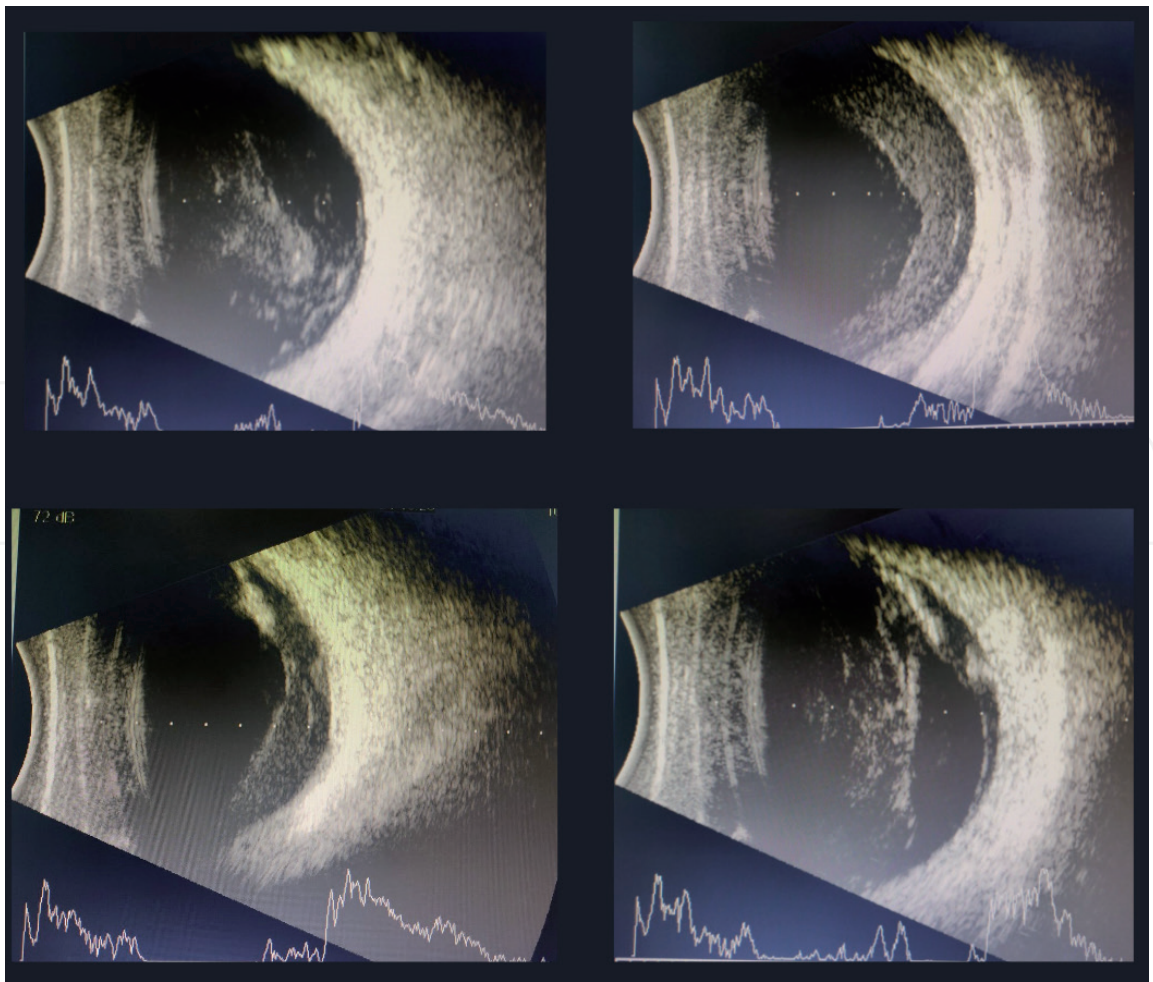


Figure 2.
Ultrasound images of a patient with vitreous haemorrhage with subhyaloid haemorrhage with thickened and incomplete hyaloid separation.

Various studies have shown that a pre-operative intravitreal anti-VEGF injection 3–14 days prior to surgery can help in controlling intra-operative bleeding [7, 8]. Nonetheless, one has to keep in mind that bleeding may occur despite an anti-VEGF injection. Some patients can develop *Crunch syndrome* after anti-VEGF injection. In these cases, TRD worsens due to development of denser fibrotic connections between the retina and overlying tissue, thus making it harder to identify tissue planes. In a retrospective review of TRD following intravitreal bevacizumab, anti-VEGF crunch developed at 5 days or more after initial IVB injection in nearly 80% of cases [9].

3. Timing of vitrectomy in diabetic vitreous haemorrhage

At the time of diabetic retinopathy vitrectomy study (DRVS), vitrectomy was performed in patients who had non-resolving vitreous haemorrhage for more than 12 months. The results of DRVS showed that eyes undergoing early vitrectomy for severe vitreous haemorrhage were more likely to have VA \geq 20/40 at 2 years and greatest benefit was seen in patients with type 1 diabetes [10]. With the evolution of better surgical techniques and instruments (MIVS), early vitrectomy is more effective in achieving better visual outcomes [11]. Usually, patients with type 1 or type 2 diabetics with VH and no underlying traction, can be observed for 1 month [12]. In the meantime, if haemorrhage improves, visible panretinal photocoagulation (PRP) or intravitreal anti-VEGF injection can be given to allow for neovascularisation to regress. In patients with visually demanding jobs, an early vitrectomy can be performed.

In patients with persistent VH, especially aphakic and pseudophakic patients with posterior capsular defect, there is an increased risk of ghost cell glaucoma and neovascular glaucoma. In these patients, anti-VEGF can be considered prior to surgery and an early vitrectomy is warranted to control IOP.

Vitreous haemorrhage can sometimes develop after panretinal photocoagulation due to contraction of the fibrous component as the vascular component of the fibrovascular membrane regresses or due to posterior vitreous detachment (PVD).

4. Surgical technique

Use of wide-angle non-contact systems would be preferred in diabetic vitrectomy as this would reduce the chances of corneal epithelial defects (since wound healing is delayed in these patients), give a better understanding of vitreous attachments and reduce the chances of iatrogenic breaks.

4.1 Diabetic vitreous haemorrhage

If the ultrasound does not show any co-existing traction or detachment, pars plana vitrectomy along with panretinal photocoagulation would suffice. Pars plana ports are made using biplanar incisions using 23/25G trocar cannula. After clearing the anterior hyaloids, a thorough core vitrectomy should be performed. Care should be taken while clearing the peripheral vitreous, as it may be difficult to distinguish between retina and blood stained vitreous. In case of dense VH, a burr hole vitrectomy can be performed in the superonasal quadrant until the retina is visualised and then further truncation of cone can be performed. If the posterior hyaloid is separated at the disc, then the PVD induction is completed if there are no focal areas of traction. If the posterior hyaloid is not separated completely or not moving freely

or causes a fluttering movement, suspect an underlying FVP. Thus the truncation of cone should be gentle and graded with a watch on underlying retina/FVP/dense vitreoretinal adhesions.

In some cases, PVD separation may not be complete and there may be subhyaloid haemorrhage (SHH). In such cases, an opening can be made in the taut hyaloid overlying the SHH using the cutter or rarely 26G needle to incise the hyaloid if it is very close to retina and the blood can be drained using cutter aspiration or flute.

Once the blood is cleared and underlying retina visualised, PVD can be completed as far anteriorly as safely possible. The aim should be to segment peripheral base of the vitreous from the any posterior hyaloid to prevent reproliferation and rebleeds. It is not mandatory to shave the vitreous base in these cases. One has to be very careful while performing vitreous base shaving in cases of VH, as the peripheral vitreous base would be harbouring the haemorrhage within itself, sometimes difficult to distinguish from the underlying retina. Also, the blood can leach from the uncut vitreous into the fluid filled vitreous cavity and can cause post-operative dispersed haemorrhage.

It is important look for any sites of blood ooze as this can give rise to post-operative rebleeds. Transient lowering of intraocular pressure (IOP) can help to identify the bleeders. Small oozes can be allowed to clot and then trimmed off with cutter, while large bleeders need immediate attention. Clots should not be pulled as they can cause rebleed. Peripheral examination by indentation to look for breaks or sites of bleeding is crucial. A 360° panretinal photocoagulation using endolaser is performed. While performing endolaser, a straight or a curved laser probe can be used. In case a straight endolaser probe is being used, care has to be taken while performing anterior laser to move away from the retina as the curvature of the globe need to be kept in mind to avoid inadvertent retinal touch. Also, exchanging instruments in both hands while performing anterior laser rather than crossing over instruments will help to avoid inadvertent lens touch. A partial or complete fluid air exchange is performed. It is important to ensure that the sclerotomy sites are not leaking and eye is not hypotonous at the end of surgery as these can also lead to dispersed vitreous cavity haemorrhage post-operatively.

In patients with coexisting macular edema or epiretinal membrane, an ERM with ILM peeling after injecting brilliant blue dye should be performed. Anti-VEGF or steroid injection [13] can also be planned at the end of surgery in such cases after partial or complete fluid air-exchange.

4.2 Diabetic retinal detachment

4.2.1 Understanding the anatomy

The fibrovascular proliferation (FVP) in a diabetic patient grows along the posterior hyaloid and causes tangential traction leading to pleatlike folds on the retina. As the posterior hyaloid starts separating from the retina, it causes an anteroposterior traction over the retina causing tractional retinal detachment. Thus the PVD creates a cone of vitreous extending from the vitreous base to the posterior pole in diabetic eyes [14]. Thus the goal of surgery would be to initially relieve the anteroposterior traction by truncating the cone and then relieve the tangential traction by dissecting the membranes. Once the detachment becomes long standing, the underlying retina becomes then and atrophic creating breaks, leading to combined retinal detachment. Sometimes, one may also notice subretinal gliotic bands (SRGs) due to long standing CRD. It may not always be possible to identify the breaks preoperatively in CRD. Bullous configuration of detachment, SRG or subretinal bleeds may be indirect indicators of CRD.

4.2.2 Principles of surgery

Thus induction of PVD in diabetics is not similar to that performed regularly. In these patients, the primary step is truncation of cone. It is important to identify an area with hyaloid separation, and this leading edge can be held as a bucket handle and go circumferentially to truncate the cone (Video 1; https://cdn.intechopen.com/public/chapter_videos/241965/VIDEO_1.mov). In areas with dense adhesions, switching the site and going forth can help. At sites where the vitreous is very densely adherent and the above technique fails, viscodissection can be utilised to help induce separation. Once the anteroposterior traction is relieved, the membranes need to be carefully dissected out using a combination of various techniques described below to relieve the tangential traction caused by the FVP.

Two basic approaches to handle the membrane dissection are *outside-in* and *inside-out* approaches. Depending on where the hyaloid is maximally separated, one would decide the approach. Although outside-in is a safer and commonly practised approach since the macula is spared, in some cases with flat and densely adherent membranes and/or where there is no PVD, an inside-out approach may be more helpful. However, it is not uncommon to encounter situations where one will require to use a combination of both these approaches depending on the hyaloid adherence. Sometimes, pockets of hyaloid separation can be noted adjacent to NVE and can be used as an initiating site.

Various techniques can be employed in the dissection of membranes as follows:

1. **Segmentation:** Involves sharp dissection of membranes using scissors or even sometimes cutter. One blade of scissors is inserted beneath the membrane after finding a cleavage plane, while the other blade lies above the membrane. One must be careful not to pinch retina in between the blades to avoid iatrogenic breaks. Initially, this technique was described using a vertical scissors, but these are no longer used after the introduction of curved scissors as they occupy lesser space. Segmentation basically isolates the membranes and does not essentially require complete removal of membranes (Video 2; https://cdn.intechopen.com/public/chapter_videos/241965/VIDEO_2.mov).
2. **Delamination:** Developed subsequently to address the issue of residual membranes after segmentation causing redetachment. Delamination involves complete removal of membranes rather than just isolating them and identifying the right plane is very important for delamination. This is the most commonly used technique to remove the proliferative membranes. Delamination can be performed using a scissors or a cutter.

In scissors delamination, after identifying the cleavage plane, both the blades are placed beneath the membrane to sever them from underlying vascular attachments. Although initially described using horizontal scissors, these are now replaced by curved scissors (Video 3; https://cdn.intechopen.com/public/chapter_videos/241965/VIDEO_3.mov).

Cutter delamination is now more commonly performed with the advent of smaller guage instruments, where the port is much closer to the tip and thus helps in better delamination. Various techniques of cutter delamination have been described [15]:

- a. **Conformal cutter delamination:** Used for rigid membranes, where the port opening is placed at the outer margin of the membrane (Video 2; https://cdn.intechopen.com/public/chapter_videos/241965/VIDEO_2.mov).
- b. **Foldback technique:** In this technique, cutter is placed on the anterior surface of the membrane and the vacuum is used to separate the membrane and

fold into the cutter, thus protecting the retinal surface. One should allow the membrane to fold up and fall back into the mouth of cutter rather than chasing the membrane into the cutter (Video 3; https://cdn.intechopen.com/public/chapter_videos/241965/VIDEO_3.mov).

- c. *Lift and shave*: With the advent of smaller guage (25 and 27G) instruments, it now enables the surgeon to complete the membrane dissection with the cutter alone. A cleavage plane is identified and then using the cutter, membranes are lifted using aspiration and cutting is used once resistance is encountered. This alternate aspiration and cutting the membranes is used to shave them off the surface [16]. Here the cutter is initially used as a pic forceps to lift the membrane and then cutting is applied to shave it off. The advantage of the smaller probes is the higher cutting rates (7000–10,000 cuts/min), which allows controlled movements with minimal movement of the retina underneath and also the port location being closer to tip enables better grasp (Video 1; https://cdn.intechopen.com/public/chapter_videos/241965/VIDEO_1.mov).
 - d. *Lawnmower technique*: In this technique cutter is used for lifting and blunt dissection, once an opening within the membranes is identified [17]. Here an opening can be made using smaller guage instruments, in the peripapillary area where there is a potential space. Although, the disadvantage would be that, if one encounters bleeding during this manoeuvre, it would be difficult to achieve haemostasis over the disc.
3. *En bloc dissection*: Although originally described as a technique where the posterior hyaloid was used to lift the membranes and remove as a single unit, there was a high risk of posterior breaks [18]. This technique is no longer used with the advent of minimally invasive vitreoretinal surgery (MIVS) due to higher chances of retinal breaks.
 4. *Bimanual dissection*: In this technique, various illuminated instruments/sources are used, so that the surgeon can use both his hands for membrane peeling. From illuminated infusion cannulas to illuminated picks [19] or chandelier assisted light source, surgeon can use forceps in the non-dominant hand to lift the membrane and scissors or picks in the dominant hand to peel the membranes. This technique is usually reserved for densely adherent diffuse/broad FVP which are usually difficult to dissect otherwise. Care should be taken not to apply undue traction while lifting the membrane by the non-dominant hand, as it can pull the retina and make the detachment more bullous/cause iatrogenic breaks. While using a chandelier light source, an additional sclerotomy can be planned at 12 or 6 o'clock position based on the surgeons' preference (Video 4; https://cdn.intechopen.com/public/chapter_videos/241965/VIDEO_4.mov).
 5. *Viscodissection*: In this technique, viscoelastic substance is injected initially into the potential space between the membranes and the retina, in cases where there are densely adherent membranes to aid in the cleavage of the plane. This technique has the risk of creating retinal breaks [20].
 6. *Perfluoro carbon liquid (PFCL) dissection*: In this technique, an opening is made in posterior hyaloid and PFCL is injected to separate the posterior hyaloid from the retina [21]. PFCL can be used as a third hand to stabilise the posterior pole in cases of CRDs or TRDs. It also helps to salvage the macula from surrounding haemorrhage and provides a counter force during membrane

peeling. One has to be cautious while using PFCL in cases of posterior breaks, where traction is not relieved as there can be a chance of subretinal PFCL migration. Also forceful jet while injecting in cases with thin atrophic retinas can cause iatrogenic breaks during injection.

4.3 Vitreoschisis or second membrane identification

Often the posterior vitreous gel splits into an anterior and a posterior leaflet [22]. One may be easily mistaken by looking at the posterior leaflet as the edge of the hyaloid near the FVP and start pulling it. It is important to identify the anterior leaflet that extends beyond the FVP sometimes as thin flimsy glistening membrane onto the surface of TRD/adjacent retina and start separating it from the retina. Once this is identified using a pic or a needle and separated, it is easier to get the right plane for further dissection. If not correctly identified, one can have multiple iatrogenic breaks, since the anterior leaflet of posterior hyaloid (also known as second membrane) is still adherent to underlying retina. Though the aetiology is uncertain, some authors believe that the split may be caused due to the bleeding from the vascular epicentres (Video 3; https://cdn.intechopen.com/public/chapter_videos/241965/VIDEO_3.mov).

In rare circumstances, where the hyaloid is very densely adherent extending till periphery, with flat broad and dense fibrovascular proliferations, one of the authors (Dr. MPS) have tried intravitreal autologous serum injection 24 hours prior to the surgery for induction of PVD with a successful outcome. In the event of any iatrogenic break in the periphery or near the vitreous base better, one can also support with BB/SB to avoid transmitted tractions from the vitreous base.

Hybrid vitrectomy: Some surgeons prefer hybrid vitrectomy using 23G trocar cannulas and 25G or 27G cutters for better membrane delamination. This has the advantage of higher cut-rate and the port site being closer to the tip of cutter helps in easier grasp of membranes [23]. Newer cutters (27G) with very high cutting rates with low vacuum can allow precise cutting in close proximity to the retina with reduced risk of breaks [24].

4.4 Special considerations in CRD

Most often, one may not be able to identify a break pre-operatively. Convex configuration of detachment, SRG, subretinal haemorrhage are indirect clues towards CRD.

1. It is important to keep in mind not to drain the subretinal fluid (SRF) from the break in case of CRD before completing the membrane dissection, as it helps to keep the retina taut. Once the SRF is drained, retina starts becoming bullous and further membrane dissection becomes very difficult.
2. Use of valved cannulas can help in cases of bullous detachments to reduce the continuous egress of fluid which increases the fluid currents inside and aggravates the bullosity.
3. It is important to finish membrane peeling before retina starts becoming bullous.
4. All attempts should be made to keep the break free from any surrounding membrane or significant blood clot to avoid late lifting of the break and recurrence.
5. Rarely, one can also support with an external segmental buckle if further dissection of membranes is not possible and the posterior traction is relieved as a last resort.

6. Once the membrane dissection is completed and clots are managed, SRF needs to be drained initially by fluid-fluid exchange to dilute the thick SRF and drain better before switching to fluid-air exchange (Video 1 ending; https://cdn.intechopen.com/public/chapter_videos/241965/VIDEO_1.mov).
7. In presence of SRGs not allowing retina to settle, a drainage retinotomy can be made to remove the SRG (Video 1 ending; https://cdn.intechopen.com/public/chapter_videos/241965/VIDEO_1.mov).

Apart from truncating the cone, identifying the right plane and second membranes, dissection of fibrovascular proliferation, another major challenge in diabetic vitrectomy is controlling the haemorrhage or clot management. Bleeding can occur from multiple sources, i.e., vascular nails during FVP dissection, edges of FVP during dissection, optic nerve head due to dense adhesion of posterior hyaloid or FVP at the disc, arcade vessels due to iatrogenic damage, edges of retinal breaks or trimmed NVEs. Despite multiple techniques to arrest the bleeding, it may sometimes be very difficult to handle these blood clots as they get densely adherent to the underlying thin retina.

4.5 Management of haemorrhage

This is one of the crucial and sometimes most challenging step during diabetic vitrectomy. Clot management should always be preferred in the fluid filled cavity, as the air would cause the clot to diffusely get adhered to the retina and will be more catastrophic. Once all the bleeders are managed, before switching to air, one can decrease the IOP to look for any residual oozing and manage accordingly. This would help to reduce post-operative bleeding.

In case of an active visible bleeder as seen from either the edge of FVP or NVEs, one can immediately cauterise them using endodiathermy. In cases where the bleeding is from a major arcade vessel, one has to be cautious to use diathermy as it may cause vascular occlusion subsequently. Light burns using endolaser probe (Power: 150–200 mW and shorter duration—100 ms) can be attempted instead. Rarely, one can also try pinching of the vessel gently using forceps as a last resort.

In case of bleeding from the disc, we cannot use diathermy or endolaser over the disc. Hence either increasing the bottle height of infusion (in case of gravity assisted infusion) or temporarily increasing the intraocular pressure may help to arrest the bleed. If nothing works, a fluid air exchange can also be tried to use air as a temporary tamponade and wait for few minutes to arrest the active bleeding. One has to be patient and may need to make repeated attempts of the above manoeuvres to achieve haemostasis. One does not have to always peel the membrane over disc, as it may bleed unstoppably if it is densely adherent and vascular. This can be circumcised or trimmed and left behind.

Not always, every blood clot needs immediate attention. Sometimes if it has clotted and is not hampering further membrane dissection, then the clot may be left alone and addressed at the end once all membranes are dissected. Small clots can be removed using flute, while larger clots may need cutter. Clots not covering the macula can be left alone if there is no surrounding break or traction if they cannot be safely removed.

4.6 Vitrectomy in tractional versus non-tractional DME

Patients with tractional macular edema in diabetes are known to benefit with vitrectomy and ERM with ILM peeling [25]. In non-tractional DME, role of

vitrectomy has been controversial. While some studies show that patients with refractory DME would benefit with vitrectomy [26], other studies have shown no significant visual improvement with ILM peeling although there may be anatomical improvement [27, 28]. Addition of intravitreal steroid along with ILM peeling in some cases of refractory DME, has shown to improve visual outcome in long-term [29].

In patients with long standing macular ischemia or FVP causing traction over fovea, sometimes a macular hole may be noted. Visual prognosis in such cases is guarded despite ILM peeling in contrast to idiopathic macular holes [30].

4.7 Choice of tamponade

In patients with vitreous or subhyaloid haemorrhage or tractional macular edema with no retinal breaks, a simple fluid air exchange would suffice in most cases. In TRD with no iatrogenic breaks, it is not required to drain the SRF using drainage retinotomy. A gas tamponade may suffice in such cases, as the SRF gets absorbed over a period of time gradually. In CRD or TRD with iatrogenic breaks, a gas or a silicon oil tamponade would be required.

5. To summarise

Step 1: After placing sclerotomy ports using valved cannulas, perform anterior and core vitrectomy.

Step 2: Relieve antero-posterior traction—identify areas of posterior hyaloid separation and complete the truncation of cone. If unable to identify, can inject triamcinolone acetonide for better identification. The leading edge of the posterior hyaloid should be held as a bucket handle and the separation should be continued circumferentially, thus separating the posterior hyaloid from the peripheral vitreous base.

Step 3: Relieve tangential traction—identify the site of initiating membrane dissection by identifying the cleavage plane and second membrane. Membranes can be dissected using segmentation or one of the delamination techniques mentioned above.

Step 4: Achieve haemostasis—vascular nails during membrane dissection can be severed using one of the above techniques. Smaller oozes can be dealt later at the end of membrane dissection, while large bleeders which would hamper visualisation should be dealt immediately during membrane dissection.

Step 5: Complete peripheral vitreous clearing.

Step 6: BBG assisted ILM peeling if planned.

Step 7: Endolaser photocoagulation—panretinal and surrounding the retinal breaks.

Step 8: Fluid air exchange and injection of endotamponade.

Step 9: Injection of anti-VEGF or steroid implant.

Step 10: Removal of ports with or without suturing the sclerotomies.

6. Complications

6.1 Intraoperative complications

1. Corneal edema: Can happen due to prolonged surgical time or raised intraocular pressure. Viscoelastic lubrication of cornea intraoperatively and optimal IOP control can help to have better view of fundus. Sometimes, corneal

epithelial debridement may be needed although slow healing in diabetic patients need to be kept in mind.

2. Cataract: This can occur preoperative/intraoperative/postoperative. Diabetic patients are known to have a higher risk and vitrectomy would further increase the risk of cataract. Sometimes intraocular lens touch or hydration of lens can further aggravate the process. With the advent of minimally invasive cataract surgery (MICS), combining cataract surgery along with vitrectomy would be a better choice in older patients with lens changes.
3. Bleeding: This is one of the most dreadful complication encountered intra-operatively in diabetic vitrectomies. Preoperative anti-VEGF injection may help to mitigate this to some extent. Use of valved cannulas also helps to some extent. Lesser exchange of instruments causes lesser IOP fluctuations. Finally, the most important cause is bleeding during dissection of FVP which has been explained above.
4. Iatrogenic breaks: These can occur usually during dissection of FVPs. If the edge of break is oozing blood, it is important to cauterise immediately to achieve haemostasis. It is important to ensure that all the posterior hyaloid and traction has been relieved from surrounding the break, as it can lead to reproliferations or recurrent detachment. Also, it is not a good idea to drain the SRF from the break before completely removing the membranes, as the retina would then start becoming bullous and make further dissection difficult. It is important to indent the periphery at the end to look for any peripheral breaks especially near the active port site.

6.2 Post-operative complications

These can be further classified as early and late post-operative complications.

6.2.1 Early

1. Vitreous cavity bleeding: Dispersed bleeding in the vitreous cavity can be noted either immediately in the post-operative period most often, or sometimes as a delayed complication. Causes in the immediate post-operative period would be inadequate haemostasis intra-operatively or continuous ooze from the sites of vascular nails, or sometimes from peripheral vitreous or sclerotomy sites and hypotony. Sometimes lowering the IOP before closing intraoperatively, can help to locate the possible sites of rebleed/ooze and can be managed appropriately [31]. Pre-operative anti-VEGF can also help to some extent. These bleeds usually resolve by themselves within 2–4 weeks and if persist for long may need a vitreous lavage.
2. Late causes of vitreous cavity bleeding can be reproliferations or inadequately lasered ischemic retina, neovascularisation of retina/iris, or rarely anterior hyaloid fibrovascular proliferation (AHF). An indirect clue to AHF proliferation can be to look for a dilated episcleral vessel. An ultrasound biomicroscopy (UBM) can help to rule out AHF proliferation. These complications can be prevented by doing an aggressive panretinal laser photocoagulation involving the anterior retina, although not always. Rarely, a patient may develop neovascular glaucoma, which may require an anti-VEGF injection along with vitreous lavage and intense laser photocoagulation involving anterior retina.

3. Raised intraocular pressure: In the early post-operative period, clogging of erythrocytes or cellular debris in the trabecular meshwork can cause raised IOP, which can be managed by topical anti-glaucoma medications or oral acetazolamide in most cases [32]. In patients with silicon oil tamponade, sometimes over-filling can cause increased IOP. In such cases, an oil tap using a 23G trocar cannula at 12 o'clock can help to reduce the IOP. Pupillary block or anterior chamber migration of oil can be other causes especially in aphakic patients. An inferior peripheral iridectomy (PI) intraoperatively before performing fluid air exchange would help to prevent pupillary block. Steroid induced ocular hypertension or worsening of pre-existing glaucoma can be other causes. Identifying the right cause and treating the underlying problem is the key to successful management. Topical aqueous suppressants would be the first line of choice, since prostaglandin analogues can aggravate cystoid macular edema and/or promote inflammation [33].
4. Suboil haemorrhage: This can happen sometimes due to persistent ooze from the vascular nails of FVP or dense attachments at disc. In most cases, they resolve by themselves and are mobile. One can wait upto 2–4 weeks for the blood to resolve.

6.2.2 Late

1. Reproliferations/redetachments: Reproliferations can develop due to residual FVP or sequestered growth factors and VEGF in the peripheral vitreous or from the edges of large retinectomies or rarely across the vitreous base as anterior hyaloid fibrovascular proliferations. Reproliferations not causing traction or detachment can be observed. Sometimes they can be managed during silicon oil removal or can be peeled under silicon oil.
2. Epiretinal Membrane: Incidence of ERM after diabetic vitrectomy is 20–50% [34]. Several studies have reported that ILM peeling during vitrectomy can help to reduce the incidence of post-operative ERM [35]. Removal of ERM can be planned along with silicon oil removal in patients with oil tamponade. ERM removal is indicated only if it causes a traction or decrease in visual acuity has been recorded which can be attributed to presence of ERM.
3. Cataract: Diabetes per se, vitrectomy, gas and oil tamponade all are known to be risk factors for faster progression of cataract. Although some surgeons prefer to perform combined cataract and vitrectomy surgery in elderly patients irrespective of lens status, doing a staged procedure can help to reduce post-operative inflammation if the view is adequate to enable vitrectomy [36].
4. Glaucoma: Causes of late glaucoma can be synechial angle closure or emulsified silicon oil blocking the trabecular meshwork or neovascular glaucoma secondary to long standing ischemia [37]. A blocked PI can cause late-onset pupillary block glaucoma. Reopening of PI by Yag laser iridotomy can help in most cases. Some patients may require multiple PIs.

Hypotony: Extensive AHF proliferation or cyclitic membranes over the ciliary body or ciliary body shutdown due to cyclophotocoagulation or anterior segment ischemia can cause persistent hypotony in some patients.

7. Poor prognostic factors

Presence of macular detachment, vitreopapillary traction, thinned out retina, sclerosed vessels, pale disc, neovascularisation of iris or NVG, macular ischemia, poor initial VA ($<5/200$) and loss of photoreceptor layers, ELM and ellipsoid zone on OCT are poor visual prognostic factors despite a successful anatomical outcome [27].

For a successful anatomic outcome, it is very important to understand the anatomy and surgical principles in a case of diabetic vitrectomy. One has to counsel the patient that visual outcomes may not always correlate with anatomical outcomes. Importance of good systemic control should always be emphasised.

Video links

1. https://cdn.intechopen.com/public/chapter_videos/241965/VIDEO_1.mov
2. https://cdn.intechopen.com/public/chapter_videos/241965/VIDEO_2.mov
3. https://cdn.intechopen.com/public/chapter_videos/241965/VIDEO_3.mov
4. https://cdn.intechopen.com/public/chapter_videos/241965/VIDEO_4.mov

Author details

Payal Naresh Shah*, Mahesh P. Shanmugam and Divyansh K. Mishra
Department of Vitreoretinal and Ocular Oncology Services, Sankara Eye Hospital,
Bangalore, India

*Address all correspondence to: n.payalshah@gmail.com

IntechOpen

© 2022 The Author(s). Licensee IntechOpen. This chapter is distributed under the terms of the Creative Commons Attribution License (<http://creativecommons.org/licenses/by/3.0>), which permits unrestricted use, distribution, and reproduction in any medium, provided the original work is properly cited. 

References

- [1] Yau JW, Rogers SL, Kawasaki R, Lamoureux EL, Kowalski JW, Bek T, et al. Meta-analysis for eye disease (META-EYE) study group. *Diabetes Care*. 2012;**35**(3):556-564
- [2] Machemer R, Buettner H, Norton EW, Parel JM. Vitrectomy: A pars plana approach. *Transactions - American Academy of Ophthalmology and Otolaryngology*. 1971;**75**(4):813-820
- [3] Machemer R, Parel JM, Buettner H. A new concept for vitreous surgery. 1. Instrumentation. *American Journal of Ophthalmology*. 1972;**73**:1
- [4] De Maria M, Panchal B, Coassin M. Update on indications for diabetic vitrectomy and management of complications. *Annals of Eye Science*. 2018;**3**(9):51
- [5] Stewart MW, Browning DJ, Landers MB. Current management of diabetic tractional retinal detachments. *Indian Journal of Ophthalmology*. 2018;**66**(12):1751-1762. DOI: 10.4103/ijo.IJO_1217_18
- [6] Mishra DK, Shanmugam MP, Ramanjulu R, Sagar P. Comparison of standard and “innovative wide-field” optical coherence tomography images in assessment of vitreoretinal interface in proliferative diabetic retinopathy. *Indian Journal of Ophthalmology*. 2021;**69**(1):99-102
- [7] Zhao XY, Xia S, Chen YX. Antivascular endothelial growth factor agents pretreatment before vitrectomy for complicated proliferative diabetic retinopathy: A meta-analysis of randomised controlled trials. *The British Journal of Ophthalmology*. 2018;**102**(8):1077-1085. DOI: 10.1136/bjophthalmol-2017-311344
- [8] Wang DY, Zhao XY, Zhang WF, et al. Perioperative anti-vascular endothelial growth factor agents treatment in patients undergoing vitrectomy for complicated proliferative diabetic retinopathy: A network meta-analysis. *Scientific Reports*. 2020;**10**:18880. DOI: 10.1038/s41598-020-75896-8
- [9] Arevalo JF, Maia M, Flynn HW Jr, Saravia M, Avery RL, Wu L, Eid Farah M, Pieramici DJ, Berrocal MH, Sanchez JG. Tractional retinal detachment following intravitreal bevacizumab (Avastin) in patients with severe proliferative diabetic retinopathy. *The British Journal of Ophthalmology*. 2008;**92**(2):213-216
- [10] Early vitrectomy for severe vitreous hemorrhage in diabetic retinopathy. Two-year results of a randomized trial. Diabetic Retinopathy Vitrectomy Study Reports 2. The Diabetic Retinopathy Vitrectomy Study Research Group. *Archives of Ophthalmology*. 1985; **103**:1644-1652
- [11] Lin L, Chen Y, Wang L, Shen L. Timing of optimal surgical intervention for vitreous hemorrhage in patients with proliferative diabetic retinopathy. 11 March 2020, PREPRINT (Version 1). DOI: 10.21203/rs.3.rs-16666/v1
- [12] El Annan J, Carvounis PE. Current management of vitreous hemorrhage due to proliferative diabetic retinopathy. *International Ophthalmology Clinics*. 2014;**54**(2):141-153
- [13] Kulkarni M, Mishra DK, Shanmugam MP. Slow-release technique of dexamethasone implant. *Acta Scientific Ophthalmology*. 2021;**4**(5): 87-89
- [14] Meredith TA, Kaplan HJ, Aaberg TM. Pars plana vitrectomy techniques for relief of epiretinal traction by membrane segmentation. *American Journal of Ophthalmology*. 1980;**89**(3):408-413

- [15] Charles S. Vitreous Microsurgery. Baltimore: Williams and Wilkins; 1981. pp. 107-120
- [16] Berrocal MH. All-probe vitrectomy dissection techniques for diabetic tractional retinal detachments: Lift and shave. *Retina*. 2018;**38**(Suppl. 1):S2-S4
- [17] Berrocal M. A minimalist approach to surgery for diabetic retinal detachment. *Retina Today*. 2014;**9**(3): 65-69
- [18] Abrams GW, Williams GA. “En bloc” excision of diabetic membranes. *American Journal of Ophthalmology*. 1987;**103**:302-308
- [19] Williams GA, Abrams GW, Mieler WF. Illuminated retinal picks for vitreous surgery. *Archives of Ophthalmology*. 1989;**107**(7):1086
- [20] Grigorian RA, Castellarin A, Bhagat N, et al. Use of viscodissection and silicone oil in vitrectomy for severe diabetic retinopathy. *Seminars in Ophthalmology*. 2003;**18**:121-126
- [21] Arevalo JF. En bloc perfluorodissection for tractional retinal detachment in proliferative diabetic retinopathy. *Ophthalmology*. 2008;**115**:e21-e25
- [22] Schwatz SD, Alexander R, Hiscott P, Gregor ZJ. Recognition of vitreoschisis in proliferative diabetic retinopathy. A useful landmark in vitrectomy for diabetic traction retinal detachment. *Ophthalmology*. 1996;**103**(2): 323-328
- [23] Khan MA, Samara WA, Hsu J, Garg S. Short-term outcomes of hybrid 23-, 25-, and 27-gauge vitrectomy for complex diabetic tractional retinal detachment repair. *Retinal Cases and Brief Reports*. 2019;**13**(3):244-247
- [24] Oellers P, Mahmoud TH. Surgery for proliferative diabetic retinopathy: New tips and tricks. *J. Ophthalmic Vis. Res.* 2016;**11**(1):93-99
- [25] Committee Diabetic Retinopathy Clinical Research Network Writing. Vitrectomy outcomes in eyes with diabetic macular edema and vitreomacular traction. *Ophthalmology*. 2010;**117**(6):1087-1093.e3
- [26] Hu XY, Liu H, Wang LN, Ding YZ, Luan J. Efficacy and safety of vitrectomy with internal limiting membrane peeling for diabetic macular edema: A meta-analysis. *International Journal of Ophthalmology*. 2018;**11**(11):1848-1855
- [27] Modarres M. Vitrectomy for diabetic macular edema; where are we? *Journal of Current Ophthalmology*. 2016;**28**(4): 161-162
- [28] Simunovic MP, Hunyor AP, Ho IV. Vitrectomy for diabetic macular edema: A systematic review and meta-analysis. *Canadian Journal of Ophthalmology*. 2014;**49**(2):188-195
- [29] Hwang S, Kang SW, Kim KT, et al. Three-year outcomes of vitrectomy combined with intraoperative dexamethasone implantation for non-tractional refractory diabetic macular edema. *Scientific Reports*. 2021;**11**:1292
- [30] Sharma T, Fong A, Lai TY, Lee V, Das S, Lam D. Surgical treatment for diabetic vitreoretinal diseases: A review. *Clinical and Experimental Ophthalmology*. 2016;**44**:340-354
- [31] Tan SZ, Dell’Aversana Orabona G, Robins JJ, Kumaran N, Wong R. “Delamination Plus”: A Technique to Reduce Immediate Postoperative Diabetic Cavity Hemorrhage. *Retina*. 2020 May 13. DOI: 10.1097/IAE.0000000000002833
- [32] Machemer R, Norton EWD. A new concept for vitreous surgery: III. Indications and results. *American*

Journal of Ophthalmology. 1972;
74:1034-1056

[33] Alm A, Grierson I, Shields MB. Side effects associated with prostaglandin analog therapy. Survey of Ophthalmology. 2008;53(Suppl. 1): S93-105

[34] Mehta A, Rana-Rahman R, Klaassen I, Rees J, Steel DH. The effect of internal limiting membrane cleaning on epiretinal membrane formation after vitrectomy for proliferative diabetic retinopathy. Ophthalmologica. 2020; **243**:426-435

[35] Michalewska Z, Bednarski M, Michalewski J, Jerzy N. The role of ILM peeling in vitreous surgery for proliferative diabetic retinopathy complications. Ophthalmic Surgery, Lasers & Imaging Retina. 2013; **44**(3):238-242

[36] Ogawa LS, Ozawa Y, Nagasaki K, Inoue M, Katsura H. Posterior synechia of the iris after combined pars plana vitrectomy, phacoemulsification, and intraocular lens implantation. Japanese Journal of Ophthalmology. 2001; **45**:276-280

[37] Branisteanu DC, Moraru AD, Maranduca MA, Branisteanu DE, Stoleriu G, Branisteanu CI, Balta F. Intraocular pressure changes during and after silicone oil endotamponade (Review). Experimental and Therapeutic Medicine. 2020;**20**(6):204