

We are IntechOpen, the world's leading publisher of Open Access books Built by scientists, for scientists

6,900

Open access books available

185,000

International authors and editors

200M

Downloads

Our authors are among the

154

Countries delivered to

TOP 1%

most cited scientists

12.2%

Contributors from top 500 universities



WEB OF SCIENCE™

Selection of our books indexed in the Book Citation Index
in Web of Science™ Core Collection (BKCI)

Interested in publishing with us?
Contact book.department@intechopen.com

Numbers displayed above are based on latest data collected.
For more information visit www.intechopen.com



Inflammatory Complication of Diverticular Disease

Luciano Dias de Oliveira Reis,

Marcos Ricardo da Silva Rodrigues,

Celso Augusto Milani Cardoso Filho,

Cassiana Franco Dias dos Reis and Alex Antonio de Paula Costa

Abstract

Diverticular disease is the most common morphological abnormality of the colon. It is increasing in prevalence proportionally to progressive aging and modern alimentary diet. The majority of the diverticular disease affects the sigmoid colon and the segmental inflammatory process can have different outcomes, from self-limited, low-grade inflammation to severe cases evolving to complications such as abscess, fistulas to different organs, free perforation and peritonitis, sepsis, intestinal obstruction, and hemorrhage. In this chapter, we will focus on a few of these complications—focal low-grade inflammation, intra-abdominal abscess, and fistulas.

Keywords: diverticular disease, diverticulitis, complicated diverticulitis, intra-abdominal abscess, sigmoid fistulas

1. Introduction

The incidence of diverticular disease (DD) has been rising in the last years, affecting 50–60% of people at the age of 60 [1, 2]. Only 20% of the patients with DD will develop symptoms, without acute inflammatory signs. Even so, the majority of them will be treated conservatively with success, but in some cases, complications such as abscess, obstruction, hemorrhage, perforation, and fistula will arise [3–5].

The majority of the diverticular disease affects the sigmoid colon. Its inflammatory process can have different outcomes, from self-limited, low-grade inflammation to severe cases evolving to abscess or perforation of the colonic wall. The perforation may have different presentations—free perforations when the colon communicates with the peritoneal cavity or can be walled off by the omentum or surrounding viscera.

Free perforation of the colon results in peritonitis and demands urgent surgical treatment.

Low-grade inflammation may cause tiny breaches and involve adjacent peritoneum, viscera, and mesentery fat, resulting in acute inflammatory reactions. Adhesion of surrounding structures will result in an inflammatory mass. Usually, it will result in walled-off infection and abscesses, which may heal with medical

treatment. Sometimes, the abscess may need to be drained surgically or aided by the radiological guide.

This inflammatory process may erode to the adhered organ and cause an internal fistula, notably the urinary bladder, but also to the small bowel, uterus, vagina or may erode through the abdominal wall resulting in an external fistula.

Also, the inflammatory reaction resulted from acute diverticulitis may result in intestinal obstruction and bleeding but these issues will be in another chapter.

2. Abscess

2.1 Abscess following acute diverticulitis

In a small number of patients with acute diverticulitis, the complication will appear. The abscess is one of the potentially hazardous complications. It may be a small phlegmon, pericolic, pelvic, or even distant. The management can be nonoperatively or surgical. Little has changed in the last decades except for the important improvement in decision-making based on the recent progress of radiological images. Clinical observation and daily examination are still the most important steps.

The majority of diverticular disease affects the sigmoid colon and the segmental inflammatory process can have different outcomes, from self-limited, low-grade inflammation to severe cases evolving to the abscess.

The success of medical management for diverticular disease depends on the patient's presentation and degree of response to treatment. The patient's presentation can be grouped into categories based on the Hinchey classification [6].

Clinical presentation, physical examination, and diagnostics studies help to group patients.

Patients with complicated diverticulitis present with different forms, from mild to severe cases. They may present as phlegmon, pericolic or distant abscesses, and peritonitis as shown in **Table 1**.

Mild disease can often be managed with diet, anti-inflammatory, antibiotics, and close observation on an outpatient basis (Hinchey 0 and Ia) but more severe cases should be hospitalized. The more severe cases are classified as Hinchey Ib and II.

Daily physical examination, laboratory blood checks, and CT scan help to follow the progression of the disease. The two most common signs of diverticulitis on CT scan are bowel wall thickening and fat stranding [7]. CT scan is so important that helps to links the clinical presentation to the modified Hinchey classification [6, 8].

Stage	Description
Modified Hinchey classification	
0	Mild clinical diverticulitis
Ia	Confined pericolic inflammation or phlegmon
Ib	Confined pericolic abscess
II	Pelvic, distant intra-abdominal or retroperitoneal abscess
III	Generalized purulent peritonitis
IV	Generalized fecal peritonitis

Table 1.
Modified Hinchey classification.

Patients Hinchey 0 and IB may be treated conservatively, even on an outpatient basis but require daily follow-up. Small perforation with pneumoperitoneum identified on CT scan in a patient with minimal symptoms has been treated conservatively on an outpatient basis. Extraluminal air alone is not an indication for emergency surgery but close monitoring is mandatory to detect treatment failure early [9].

Patients with pneumoperitoneum with virtually no symptoms may be treated conservatively on an outpatient basis (**Figure 1**). Even patients with pneumoperitoneum far away from the diverticular site may be treated conservatively (**Figure 2**).

In this case, the patient was kept in hospital for 72 hours and he was sent home asymptomatic. Patients in stages Ib and II can be managed with the combination of antibiotics, bowel rest, analgesics, and intravenous fluids. As they improve the antibiotics, fluid replacement may be offered by mouth. There are a number of papers comparing the results of many different antibiotics [7].

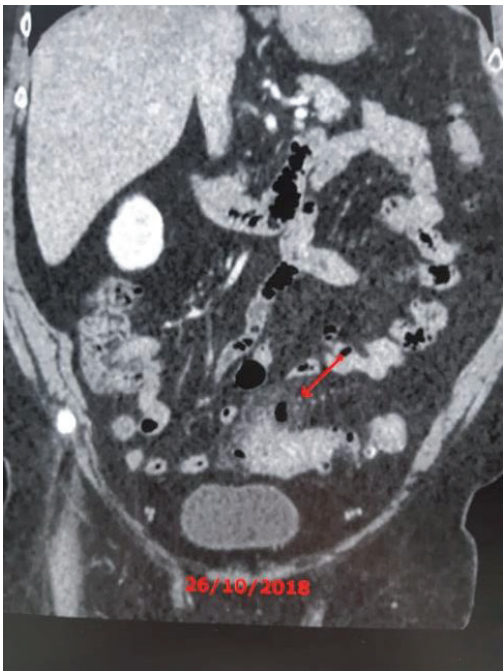


Figure 1.
Pneumoperitoneum in oligosymptomatic patient (Hinchey I).

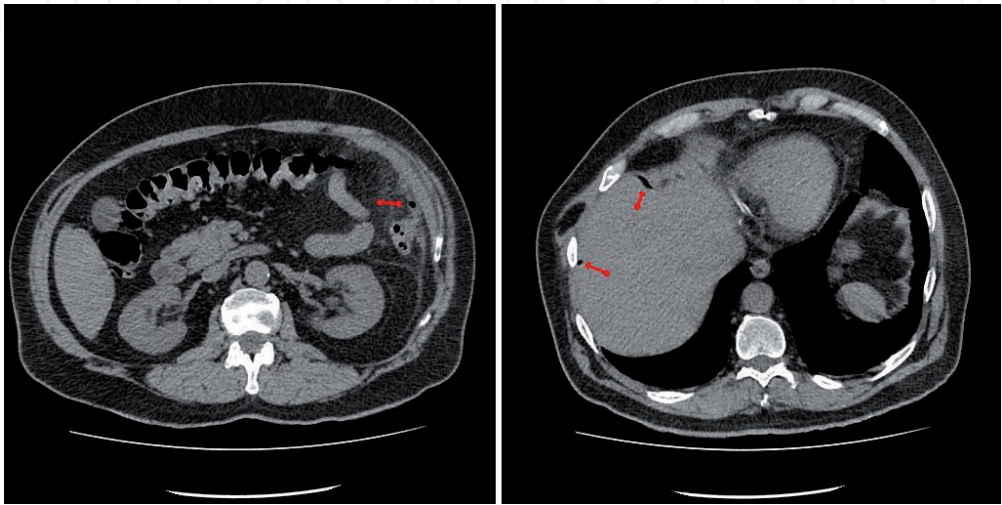


Figure 2.
Several small spots of pneumoperitoneum.

For an outpatient oral regimen, a fluoroquinolone as levofloxacin or ciprofloxacin associated with metronidazole or clindamycin is a two-drug combination. For patient on intravenous regimen, ciprofloxacin or third-generation cephalosporin is associated with metronidazole or clindamycin.

The patients should be switched from IV to oral therapy when they accept oral medicines and diet. The turning point of the transition from IV to oral medication and feeding is based on clinical improvement and it is linked to the doctor's feelings. Serial radiological studies also give important support to the physician.

According to the ASRS, Practice Parameters for sigmoid diverticulitis "radiological guided percutaneous drainage is usually the most appropriate treatment for patients with large diverticular abscess." They recommend hospitalization and IV antibiotics for these patients. If the abscess is smaller than 2 cm in diameter, it may resolve with antibiotics alone, whereas a larger abscess should be percutaneously drained [7, 10].

Some of these patients will not respond favorably to medical treatment and will develop a complication from their abscesses. How to treat pos diverticulitis abscess is debatable. This condition also can be treated clinically associated or not with percutaneous drainage. If clinical treatment fails, we must consider surgical drainage, by laparoscopy or laparotomy.

The location and size of the abscess are of importance. Siewart et al. published an interesting retrospective study comparing the outcome of abscess related to its size. They had a successful treatment in all 22 patients who were treated with antibiotics and clinical support for abscesses up to 3 cm in size [11]. Ambrosetti et al. published a prospective study and found that pelvic abscesses were more likely to require surgery if they were pelvic than mesocolic. Their recommendations were to drain all pelvic abscesses and mesocolic abscesses that were more than 5 cm in size or if no improvement after initial antibiotics [12].

Figure 3 refer to an obese patient with a large intra-abdominal abscess treated by percutaneous drainage of 200 ml of pus. The patient improved and was at the latter date submitted to sigmoid colectomy with good results.

An excellent recent systematic review (Fowler, 2021) stated the definition for the failure of nonoperative management, as a need for emergency or urgent surgery during the index admission. Other criteria were persistent or enlarging of

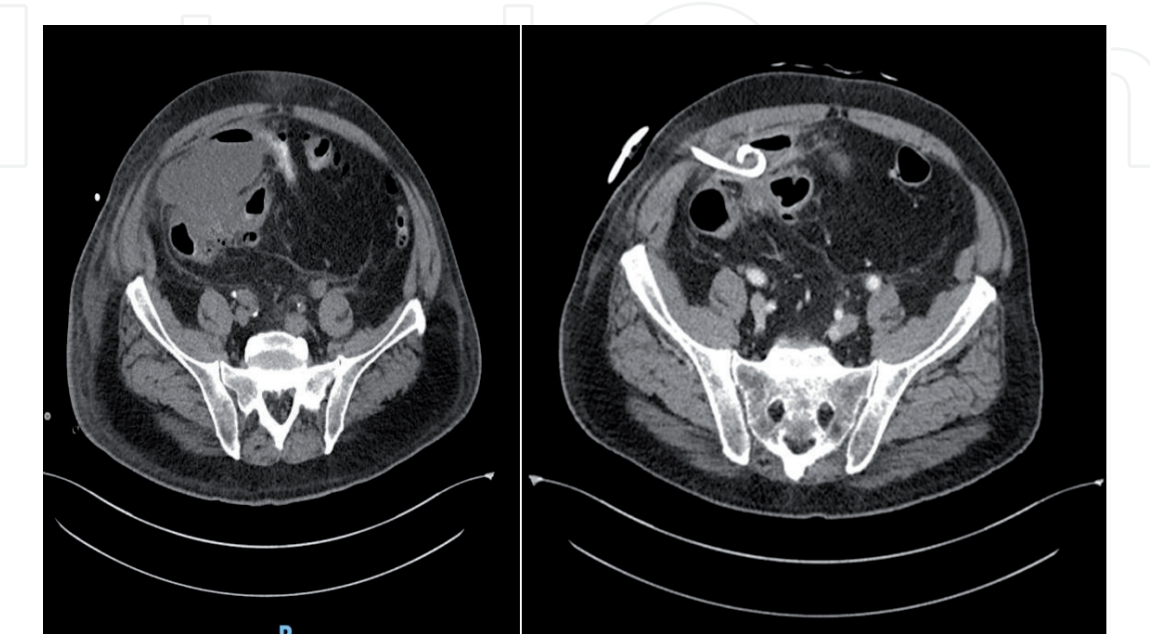


Figure 3.
Large abscess drained percutaneously under radiological guidance.

the abscess, persistent or worsening sepsis, development of complications, such as peritonitis, ileus, fistula, persistent percutaneous drainage from the percutaneous puncture site. The same study showed that the failure rate of nonoperative management, which included 38 studies ($n = 2598$), was 16.4%. In the same study, the failure rate for percutaneous drainage was 17% for pericolic and 44% for pelvic abscess [13].

After initial successful nonoperative management of diverticular abscess, expectant management with nonoperative intent is a safe long-term option with low rates of surgery [14].

When conservative treatment fails, surgery is indicated.

Sometimes, the abscess is not feasible to conservative treatment due to its inaccessibility. It may not be punctured safely. Occasionally, the abscess is intramural and cannot be drained percutaneously and a sigmoid resection is mandatory (Figures 4 and 5).

One of the criteria for failure is the recurrence of diverticulitis. The number of recurrent episodes as criteria for elective surgery is still controverted [7]. Elective operation achieves the best results. Emergency surgical procedure has a higher morbidity and mortality rate and is related to Hinchey's classification. Surgical techniques had not changed for years, and range from surgical drainage of the abscess, associated with lavage of the abdominal cavity by laparotomy or recently *via* laparoscopy and resection of the diseased colon with primary anastomosis associated or not with the protective stoma or Hartmann's procedure that is the resection of the diseased colon with the closure of distal bowel and proximal colostomy.

These operations will be discussed later in this book.

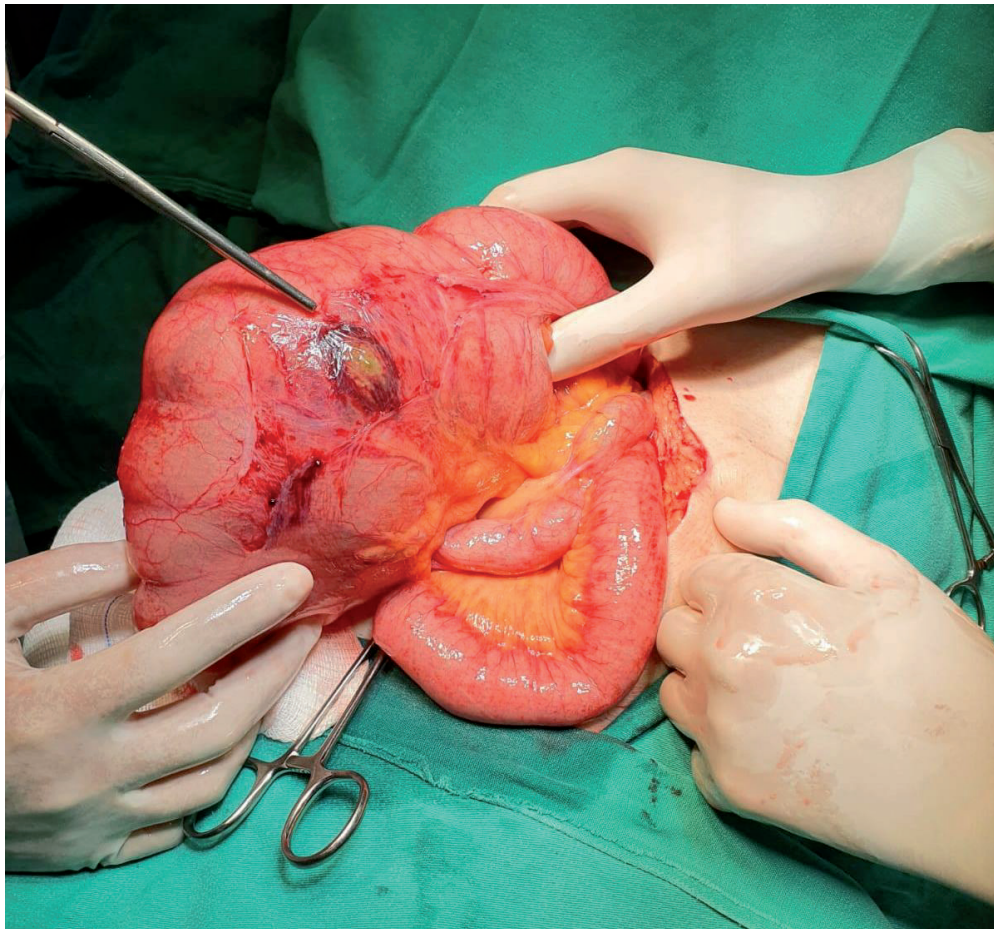


Figure 4.
Large mesocolic abscess.

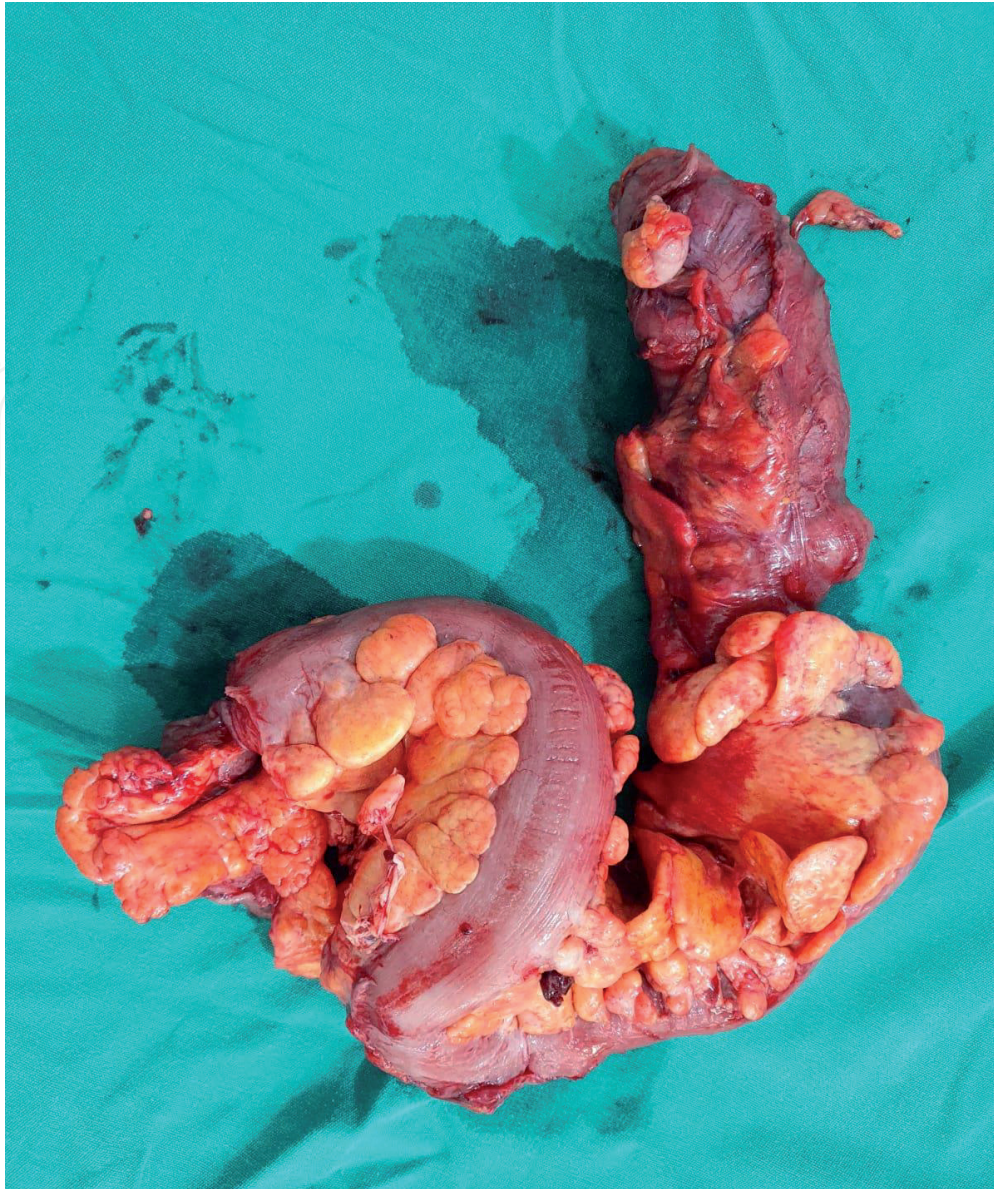

Figure 5.
Surgical removed left colon with chronic diverticulitis, with mesocolic abscess.

3. Fistulas

Chronically, the local inflammatory process can give rise to fistulas from the sigmoid to many adjacent organs. The most common etiology for colovesical fistula is a diverticular disease (40–80%) but CVF can also be found in cancer (19%), Crohn's disease, radiotherapy, or iatrogenesis [15].

Among patients with diverticulitis, only a few will develop complications as fistula [2, 3, 16, 17].

Open surgery management has been the standard treatment for these fistulas. More recently, laparoscopic surgery has shown to be an alternative and less invasive approach even though it is described to have high conversion rates up to 46.9% [2]. The American Society of Colon and Rectal Surgeons Practice Parameters recommends the laparoscopic approach when the expertise is available [5, 15].

Symptoms of the fistula depend on the organs involved. The bladder is the most common site from fistulas originating from sigmoid diverticulitis (65–69%) but is followed by vagina (25%), intestine (6%), skin (6%) [2, 6, 18], and very rarely to the appendix, tubes, and uterus.

3.1 Sigmoidvesical fistula

The pathogenesis is related to inflammation leading to perforation of the diverticulum and overt communication to a previously organ. When the adherence is to the bladder, it may erode through the bladder’s wall resulting in a sigmoid vesical fistula.

Colovesical fistula secondary to diverticulitis occurs in up to 5% of patients with complicated diverticulitis and its incidence is rising [15, 19].

Diagnosis is often based on pathognomonic signs—fecaluria, pneumaturia, and recurrent urinary infection [4, 19, 20] in a patient with a history of symptomatic diverticular disease.

Sigmoidovesical fistula is more common in elder males and in women who have been submitted to hysterectomy [5]. These observations support the theory that the body and fundus of the uterus may act as a protective barrier [15, 21]. In our recently published cases, all six patients were males [22]. Between 1999 and 2019, we had six patients with sigmoidovesical fistula. A summary of these patients is shown in **Table 2**.

All the reported patients were male. All patients treated under elective conditions (n = 3) were given primary colonic resection and anastomosis of the colon and presented uneventful recovery. The last treated patient was the only one submitted to the laparoscopic approach. In this case, intense fibrosis between the bladder and colon wall was found. The urinary bladder fistula orifice was not identified, and the bladder was not sutured. The urinary catheter was left *in situ* for 2 weeks. In all five laparotomic patients, the bladder was sutured.

Ultrasound, cystoscopy, and CT are used to confirm the diagnosis, but CT is the most accurate, showing up to 90% of sensibility, and considered the gold standard for detection of colovesical fistula [5, 23, 24]. MRI is highly sensitive but it is expensive and less accessible [15, 25]. In the last few years, CT became available in most places and was used in our recent cases (**Figure 6**).

Surgery is the method of choice for sigmoidovesical fistula. Only the unfit patient should be treated conservatively [26]. Surgery consists of removing the diseased segment of the colon, as well as the fistula, with the primary suture of the bladder defect, when identified, to prevent recurrence (**Figure 7**) [23].

Cases	Age	Symptoms	Procedures	Complications
1	70	Urinary sepsis, pneumaturia, abdominal pain, emphysema	Hartmann	X
2	65	Dysuria, pneumaturia, abdominal pain, fever	Hartmann colorectal anastomosis after 3 months	X
3	63	Recurrent crises of diverticulitis. Pneumaturia	Resection and anastomosis	X
4	38	Recurrent urinary infection, dysuria, pneumaturia, and abdominal pain	Resection and anastomosis	X
5	39	Pneumaturia, palpable mass in the hypogastrium	Hartmann colorectal anastomosis after 7 months	Partial wound dehiscence
6	56	Left lower abdominal pain, fever, pneumaturia, and foul urine	Laparoscopic resection and anastomosis	X

Table 2.
Authors’ experience with sigmoidovesical fistula.

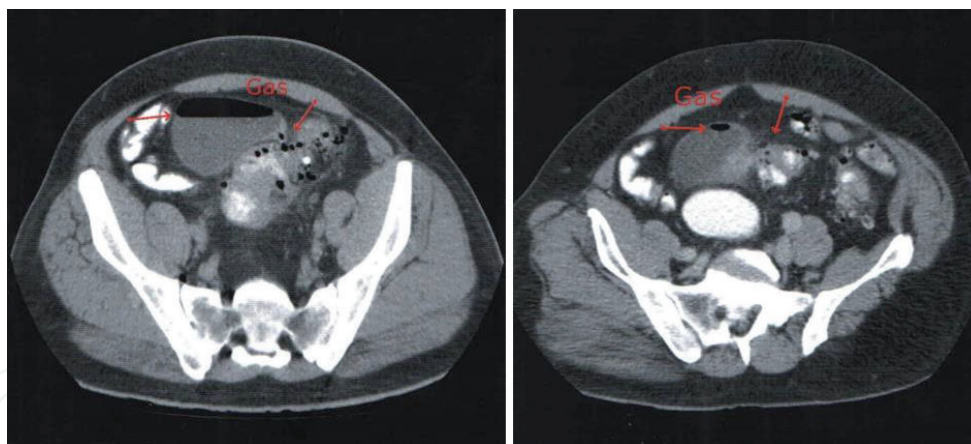


Figure 6.
Note air inside de bladder and signs of diverticulitis.

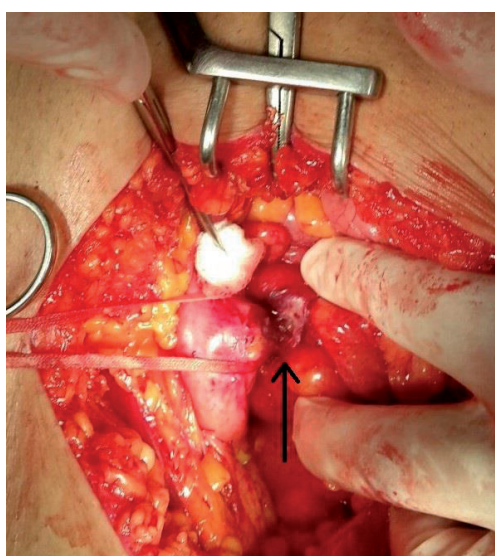


Figure 7.
Fistula tract from the sigmoid colon to the bladder.

In high-risk cases, it may not be safe to proceed to the primary anastomosis, and Hartmann's procedure is a good option [5, 23, 27]. This procedure can be performed *via* laparotomy and laparoscopy, and there are a few reports on robotic [2, 18].

The laparoscopic approach has been progressively performed [2, 6, 25]. Recent studies of laparoscopic management of complicated diverticulitis have demonstrated that under experienced hands, operation time and conversion rates are acceptable, and morbidity and mortality rates are compared with open surgery [1–3, 17, 25, 26]. Currently, the American Society of Colon and Rectal Surgeons Practice Parameters recommends a laparoscopic approach for elective colectomies when expertise is available [2, 5].

Martinolich et al. reported in 2018, the outcome of 111 patients with diverticula fistulas submitted to minimally invasive sigmoid colectomy with primary anastomosis [2]. Five patients were unfit for the method and excluded from the study. The remaining 106 underwent sigmoid colectomy with primary anastomosis with a conversion rate of 34.7%. Four of these patients had a robotic approach without conversion. They concluded that laparoscopic sigmoid colectomy for CVF is safe, with results similar to open sigmoid resection. These results are supported by other reports [1, 5].

A 14-year surgery group experience treating CVF also demonstrated similar results when open and laparoscopic approaches were compared [17]. Recent reports compared robotic to laparoscopic approaches in colectomies and also found similar results. The only significant differences were prolonged operative time and higher costs in the robotic group [18, 20, 28].

A controversial issue is the management of the bladder site of the fistula. We performed the primary suture of the bladder in all of our open cases. Some authors claim that if the fistula orifice of the bladder wall is not easily found, it may be let without suture [23, 29]. Others claim that intraoperative instillation of methylene blue may be used to limit unnecessary bladder repair [6, 29]. The suture of the bladder is more frequently described in open approaches [17] possibly because it is less technically demanding under open access and also more common when the surgery is performed by general surgeons compared to urologists [29].

3.2 Sigmoidovaginal fistula

This complication is similar to a colovesical fistula. The inflammatory diverticular process may transform into an abscess and erode to the adhered vagina.

Sigmoidovaginal fistula is a relatively modern disease, being largely absent from medical literature until half of the last century [30]. It is related to the more common practice of hysterectomy in recent years. Still, it remains relatively rare.

The majority of patients are diagnosed by a gynecologist.

A triad for diagnosis of sigmoidvaginal fistula are as follows: 1. Patient reports stool and / or flatus per vagina or persistent foul-smelling vaginal discharge and vaginitis resistant to local medical treatment; 2. Previous hysterectomy; 3. History of diverticulosis or diverticulitis [31, 32].

The colovaginal fistula begins with inflammation, which typically affecting a loop of the sigmoid colon in the left side of the female pelvis. The inflamed sigmoid colon becomes adherent to the vaginal apex, either due to the diverticular inflammation or from previous adhesive disease. Then, a small abscess can form and drain through the convenient exit site of the vagina, leading to fistula formation. The sequence of events is similar to other fistulas arising from the diseased sigmoid colon.

It is interesting that among sigmoid fistulas complicating diverticulitis, colovesical and coloenteric fistulas are more common. Occasionally, internal fistulas complicating diverticulitis may open into the appendix, uterus, or tubes [33, 34].

Sigmoid vaginal fistulas are rare and usually affect patients submitted to hysterectomy. In a group of 19 patients, the interval between patients' hysterectomy and presentation for fistulas was 19 years, with a range of 1–39 years [31]. In this study, 89.5% of patients reported stool and 36.8% flatus per vagina.

Females have the interposition of the uterus between the sigmoid colon and the bladder and it occupies the *cull de sac*, pushing the sigmoid away from the vagina. **Figure 8** are from patients submitted to hysterectomy 35 years previously showing pelvic abscess, inflamed sigmoid, and air in the vagina. In Brazil, Safatle reported three cases, all of them in females submitted to hysterectomies and the fistulous tract was found in the proximal vagina [35].

The most common etiology for sigmoidovaginal fistula is a diverticular disease (40–80%) but it may also be found in cancer, Crohn's disease, radiotherapy, or iatrogenesis [15].

Gynecological examination is mandatory. The vaginal orifice of the colovaginal fistula will be visualized in 78.9% of 19 patients in a recent report [31]. Surgical scars of laparotomy or laparoscopy for hysterectomy are commonly found. These

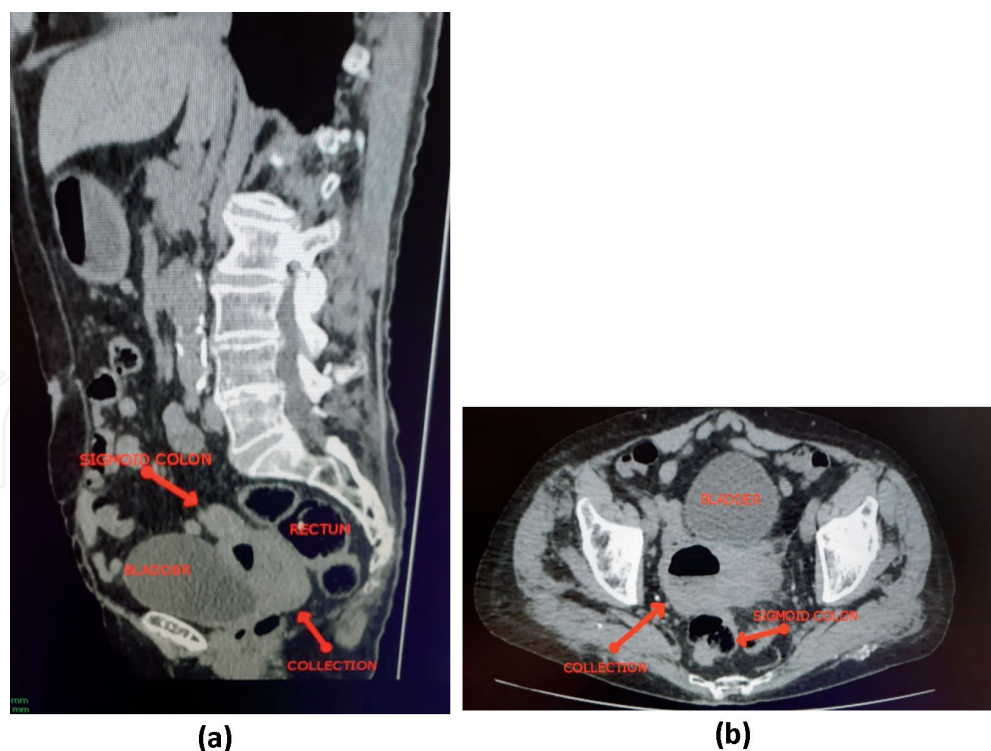


Figure 8.
Pelvic abscess with sigmoidovaginal fistula.

observations support the theory that the body and fundus of the uterus may act as a protective barrier [15, 23, 30]. Conventional fluoroscopic evaluation of the vagina, or vaginography, involves the insertion of a catheter into the vagina, with a balloon inflated to create necessary filling pressure and distention. Water-soluble contrast material should be used and barium should be avoided [36].

CT is the gold-standard method that is used to confirm the diagnosis. It is accurate, showing up to 90% of sensibility, and is considered the gold standard for the detection of sigmoid fistulas [5, 23, 26]. MRI is highly sensitive but it is expensive and less accessible [15, 25]. In the last few years, CT scan became available in most places. MRI is an excellent method to identify the fistula's tract mainly if it affects the rectum and anal sphincter [36].

Surgery is the method of choice for sigmoidovaginal fistula [31]. Only patients at high risk of perioperative morbidity and mortality should be treated conservatively [26]. Surgery consists of removing the diseased segment of the colon, as well as the fistula, with primary suture of the vaginal defect, when identified, to prevent recurrence [23]. Omentum, peritoneum, or epiploic fat are frequently used to avoid recurrence but Fallopian salpinges have been used as well [31, 37].

In high-risk cases or locally complicated cases, it may not be safe to proceed to the primary anastomosis, and Hartmann's procedure is a good option [5, 23, 27]. This procedure can be performed *via* laparotomy, laparoscopy, or potentially through robotic surgery [2, 18].

A laparoscopic approach has been increasingly favored [2, 6, 15] as mentioned before [2]. The authors concluded that laparoscopic sigmoid colectomy for sigmoid fistula is safe, with results similar to open sigmoid resection. Recent reports compared robotic versus laparoscopic approach in colectomies and also found similar results. The only significant differences were prolonged operative time and higher costs in the robotic group [18, 20]. These reports are on larger groups of patients with sigmoidovesical fistulas, but the surgical approach applies to sigmoidovaginal fistulas. We mentioned them because since fistula to the bladder is more common than to vagina, the number of patients of the former groups is statistically significant.

Occasionally, the fistula involves various organs, such as the colon, bladder, and vagina, and needs a multidisciplinary approach [38].

A controversial issue is the management of the vaginal site of the fistula. Some authors claim that if the fistula orifice of the vagina or bladder may not be easily found, it may be let without suture [23, 29, 32]. The success rate of primary repair in healthy patients is high, approaching 95% [32].

Dessole reported interposition of Fallopian salpinges in the treatment of sigmoido-vaginal fistula, secondary to vaginal hysterectomy with failure of previous repair [37].

The suture of the vagina is more frequently described in open approaches [17] possibly because it is less technically demanding under open access and also more common when the surgical procedure is performed by general surgeons [18]. Several studies have shown that long-term success seems independent of vaginal repair [31, 39, 40].

Sigmoidovaginal fistula is an unpleasant complication of diverticulitis and is increasingly common due to an aging population, it is an important presentation of which to be aware. These patients present with a triad—discharge of stool, flatus or malodorous vaginal secretion, diverticulitis, and history of hysterectomy. Surgical resection of the diseased sigmoid colon and primary anastomosis without repair of the vaginal defect is the ideal treatment. Close collaboration between gynecologists and colorectal surgeons promotes optimal care and management of this distressing condition.

3.3 Other sigmoid fistulas

Fistulas may occur from the diseased sigmoid to the Fallopian tubes, uterus, appendix, cecum, rectum, small intestine. Some coloenteric fistulas may be asymptomatic if the fistula is hermetically blocked, but they may also cause intestinal obstruction when an unsuspected fistula will be found.

Occasionally, the fistula will be driven to the skin, initially simulating a subcutaneous abscess eventually draining spontaneously, like the “empyema necessitatis,” transforming into a sigmoid cutaneous fistula (**Figure 9**). A temporary sigmoidocutaneous fistula may arise as a consequence of percutaneous drainage of an abscess. Both will require a definitive surgical procedure.

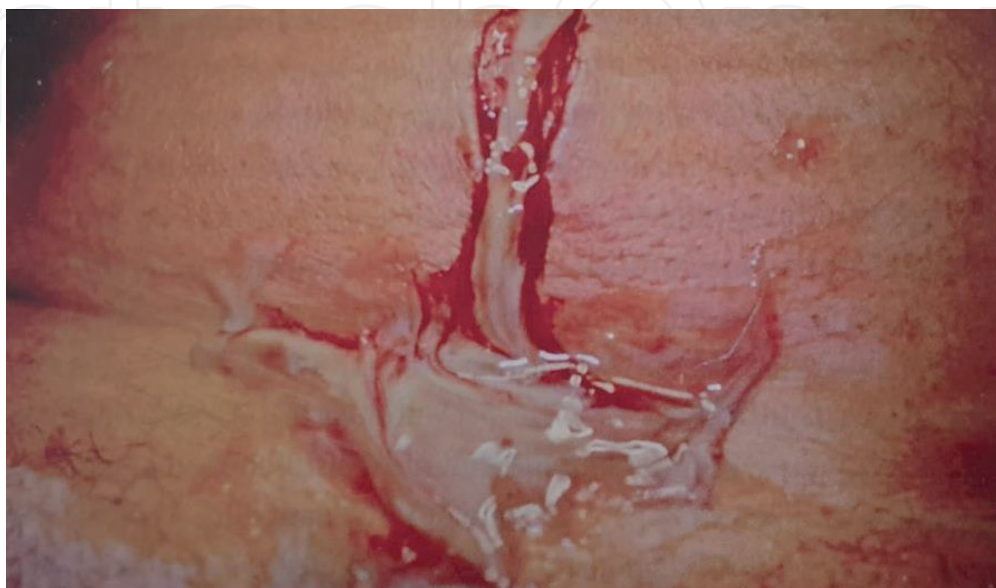

Figure 9.
Sigmoidocutaneous fistula following diverticulitis and abscess (courtesy of Enio C. Oliveira).

Fistulas to blood vessel are extremely rare but recently have been increasingly reported since some of them are secondary to vascular procedures [41]. Diverticulitis has been reported as a cause for primary sigmoidovascular fistulas associated or not with aortic aneurysms [41, 42]. The main symptom is massive bleeding, associated with vascular or diverticular symptoms. Bleeding may cause hypotension and generally is associated with sepsis due to direct contact of bowel content to the circulation. It is a dreadful complication of diverticulitis and carries a very high mortality rate. The treatment is bowel resection with or without colostomy and aortic graft replacement.

4. Conclusion

Diverticular disease may be complicated by acute inflammation, named diverticulitis. The majority of episodes of diverticulitis are mild and will be treated conservatively. Some cases will cause severe symptoms and are related to complications such as phlegmon, abscess, and fistulas. Phlegmon and abscesses may be treated conservatively but they require close observation. If it does not improve, they demand surgery. Fistulas are the undesirable complication of diverticulitis and their symptoms are directly related to the organ involved. Surgical treatment nearly always will be necessary and it includes sigmoid resection.

Author details

Luciano Dias de Oliveira Reis^{1,2,3,4*}, Marcos Ricardo da Silva Rodrigues^{2,5}, Celso Augusto Milani Cardoso Filho^{1,2,6}, Cassiana Franco Dias dos Reis^{4,7} and Alex Antonio de Paula Costa⁴

1 Brazilian College of Surgeons, Rio de Janeiro, Brazil

2 Brazilian Society of Colo-Proctology, Rio de Janeiro, Brazil

3 Brazilian Society of Digestive Endoscopy, Rio de Janeiro, Brazil

4 Hospital Nossa Senhora da Saúde, Santo Antônio da Platina, Paraná, Brazil

5 Department of Surgery, State University of Ponta Grossa, Paraná, Brazil

6 Hospital Sirio Libanes, São Paulo, Brazil

7 Coordinator of Department of Surgery, Hospital Nossa Senhora da Saúde, Santo Antônio da Platina, Paraná, Brazil

*Address all correspondence to: reisluciano@uol.com.br

IntechOpen

© 2021 The Author(s). Licensee IntechOpen. This chapter is distributed under the terms of the Creative Commons Attribution License (<http://creativecommons.org/licenses/by/3.0>), which permits unrestricted use, distribution, and reproduction in any medium, provided the original work is properly cited. 

References

- [1] Bhakta A, Tafen M, Glotzer O, Canete J, Chismark AD, Valerian BT, et al. Laparoscopic sigmoid colectomy for complicated diverticulitis is safe: Review of 576 consecutive colectomies. *Surgical Endoscopy*. Apr 2016;**30**(4):1629-34
- [2] Martinolich J, Croasdale DR, Bhakta AS, Ata A, Chismark AD, Valerian BT, et al. Laparoscopic surgery for diverticular fistulas: Outcomes of 111 consecutive cases at a single institution. *Journal of Gastrointestinal Surgery*. May 2019;**23**(5):1015-21
- [3] Cirocchi R, Cochetti G, Randolph J, Listorti C, Castellani E, Renzi C, et al. Laparoscopic treatment of C due to complicated colonic diverticular disease: A systematic review. *Techniques in Coloproctology*. 2014;**18**(10):873-85
- [4] Cochetti G, Del Zingaro M, Boni A, Cocca D, Panciarola M, Tiezzi A, et al. Colovesical fistula: Review on conservative management, surgical techniques and minimally invasive approaches. *Il Giornale di Chirurgia*. 2018;**39**(4):195-207
- [5] Feingold D, Steele RS, Lee S, Kaiser A, Boushey R, Donald Buie W, et al. Practice parameters for the treatment of sigmoid diverticulitis. *Diseases of the Colon and Rectum*. 2014;**57**:284-294
- [6] Hinchey EJ, Schaal PG, Richards GK. Treatment of perforated diverticular disease of the colon. *Advances in Surgery*. 1978;**12**:85-109
- [7] Beckham H, Whitlow CB. The medical and nonoperative treatment of diverticulitis. *Clinics in Colon and Rectal Surgery*. Aug 2009;**22**(3):156-60. doi:10.1055/s-0029-1236159
- [8] Keiser AM, Jiang JK, Lake JP, et al. The management of complicated diverticulitis and the role of computed tomography. *The American Journal of Gastroenterology*. 2005;**100**:910-917
- [9] Nascimbeni R, Amato A, Cirocchin R, Serventi A, Laghi A, Bellini M, et al. Management of perforated diverticulitis with generalized peritonitis. A multidisciplinary review and position paper. *Techniques in Coloproctology*. 2021;**25**:153-165
- [10] Rafferty J, Shellito P, Hyman NH, Buie WD. Standards Committee of American Society of Colon and Rectal Surgeons Practice parameters for sigmoid diverticulitis. *Diseases of the Colon and Rectum*. 2006;**49**(7):939-944
- [11] Siewart B, Tye G, Kruskal J, Sosna J, Opelka F. Impact of CT-guided drainage in the treatment of diverticular abscesses: Size matters. *American Journal of Roentgenology*. 2006;**186**:680-686
- [12] Amborsetti P, Chautems R, Soravia C, Peiris-Waser N, Terrier F. Long-term outcome of mesocolic and pelvic diverticular abscesses of the left colon: A prospective study of 73 cases. *Diseases of the Colon and Rectum*. 2005;**48**(4):787-791
- [13] Fowler H, Gachabayov M, Vimalachandran D, Clifford R, Orangio GR, Bergamaschi R. Failure of nonoperative management in patients with acute diverticulitis complicated by abscess: A systematic review. *International Journal of Colorectal Disease*. 2021;**36**:1367-1383
- [14] Garfinkle R, Kugler A, Pelsser V, Vasilevsky C-A, Morin N, Gordon P, et al. Diverticular abscess managed with long-term definitive nonoperative intent is safe. *Diseases of the Colon and Rectum*. 2016;**59**(7):648-655
- [15] Biffoni M, Urciuoli P, Grimaldi G, Eberspacher C, Santoro A, Pironi D, et al. Colovesical fistula complicating diverticular disease: Diagnosis and

surgical management in elderly.
Minerva Chirurgica. 2019;**74**:187-8

[16] Strati TM, Sapalidis K, Koimtzis GD, Pavlidis E, Atmatzidis S, Liavas L, et al. Sigmoido-cecal fistula: A rare case of complicated recurrent diverticulitis and a review of the literature. *American Journal of Case Reports*. 2018;**19**: 1386-1392

[17] Badic B, Leroux G, Thereaux J, Joumond A, Gancel CH, Bail JP, et al. Colovesical fistula complicating diverticular disease: A 14-year experience. *Surgical Laparoscopy, Endoscopy & Percutaneous Techniques*. 2017;**27**(2):94-97

[18] Maciel V, Lujan HJ, Plasencia G, et al. Diverticular disease complicated with colovesical fistula: Laparoscopic versus robotic management. *International Surgery*. 2014;**99**:203-210

[19] Bertelson NL, Abcarian H, Kalkbrenner KA, Blumetti J, Harrison JL, Chaundhry V, et al. *Techniques in Coloproctology*. 2018;**22**:31-36

[20] El-Haddad HM, Kassem MI, Sabry AA, Abouelfotouh A. Surgical protocol and outcome for sigmoidovesical fistula secondary to diverticular disease of the left colon: A retrospective cohort study. *International Journal of Surgery*. 2018;**56**:115-123

[21] Cavalcanti NS et al. Infecção do trato urinário de repetição por fistula enterovesical secundária a doença diverticular do colon: um relato de caso. *Jornal Brasileiro de Nefrologia*. 2013;**35**(4):341-345

[22] Reis LDO, Rodrigues M, Reis C, Mendes L, Cardoso-Filho C, Costa A, et al. Sigmoidovesical fistula complicating diverticular disease: Report of six cases. *Relato de casos Cirurgia*. 2021;**7**(3):e2654. DOI: 10.30928/2527-2039e-20212654

[23] Mendez-Pastor A, Garcia-Henriquez N. Complicated diverticulitis. *Diseases of the Colon and Rectum*. 2020;**63**:26-29

[24] Golabek T, Szymanska A, Szopinski T, et al. Enterovesical fistulae: Aetiology, imaging and management. *Gastroenterology Research and Practice*. 2013;**2013**:617967

[25] Marney L, Ho YH. Laparoscopic management of diverticular colovesical fistula: Experience in 15 cases and review of the literature. *International Surgery*. 2013;**98**:101-109

[26] Boselli C, Gemini A, Ciocchi R, Grassi V, Avenia S, Polistena A, et al. Is it safe and useful, laparoscopic peritoneal lavage in the treatment of acute diverticulitis of octogenarian patients? A multicenter retrospective observational study. *Aging Clinical and Experimental Research*. 2017; **29**(Suppl 1):83-89

[27] Reis LDOR, Lombardi OA, Reis ADO, Cardoso EH, Cardoso Filho CAM. Cirurgia de Hartmann – Analise de 41 casos em hospital de referência no Norte do Paraná. *Revista Brasileira de Coloproctologia*. 2001;**21**(1):19-22

[28] Park JS, Choi G-S, Park SI, et al. Randomised clinical trial of robot assisted versus standard laparoscopic right colectomy. *The British Journal of Surgery*. 2012;**99**:1219-1226

[29] Dolejs AJ, Penning AJ, Gusmann MJ, Fajardo AD, Holcomb BK, Robb BW, et al. Perioperative management of patients with colovesical fistula. *Journal of Gastrointestinal Surgery*. 2019;**23**: 1867-1873

[30] Tancer ML, Veridiano NP. Genital fistulas caused by diverticular disease of the sigmoid colon. *American Journal of Obstetrics and Gynecology*. 1996;**174**(5): 1547-50

- [31] Berger MB, Khandwala N, Fenner DE, Burney RE. Colovaginal fistulas – Presentation, evaluation and management. *Female Pelvic Medicine and Reconstructive Surgery*. 2016;22(5): 355-358
- [32] Siegle JC, Glasgow JÁ, Chatfield RB. Late sequelae of hysterectomy and diverticulosis: Colovaginal fistulae. *The Journal of the Oklahoma State Medical Association*. 1992;85(6):227-80
- [33] Hain JM, Sherik DG, Cleary RK. Salpingocolonic fistula secundar to diverticulitis. *The American Surgeon*. 1996;62(12):984-6
- [34] Lisbon E, Bloom RA, Verstanding A, Lax E, Lutwak E. Sigmoid-apendiceal fistula in diverticular disease. *Diagnostic Imaging in Clinical Medicine*. 1984;53(5):262-4
- [35] Safatle NF, Filardi CG, Almeida MC, Ciasca Junior DV, Saflate AM. Sigmoidovaginal fistulas. Report of 3 cases. *São Paulo Medical Journal*. 1986;104(4):221-3
- [36] VanBuren WM, Lightner AM, Kim ST, Sheedy SP, Wooley MC, Menias CO, et al. Imaging and surgical management of anorectal vaginal fistulas. *Radiographics*. 2018;38:13851401
- [37] Dessole L, Capobianco E, Noya G, Meloni GB. Interposition of fallopian salpinges in the treatment of sigmoidvaginal fistula, secondary to vaginal hysterectomy with failure of previous repair. *Archives of Gynecology and Obstetrics*. 2000;264(1):45-46
- [38] Yashi M, Muraishi O, Yuzawa M, Tokue A. A case of colo-vesico-vaginal fistula caused by sigmoid colon diverticulitis. *Hinyokika Kiyo*. 1998;44(7):513-5
- [39] Vasilevsky CA, Belliveau P, Trudel JL, Stein BL, Gordon PH. Fistulas complicating diverticulitis. *International Journal of Colorectal Disease*. 1998;13(2):57-60
- [40] Hjern F, Goldberg SM, Johansson C, Parker SC, Mellgren A. Management of diverticular fistulae to the female genital tract. *Colorectal Disease*. 2007;9(5): 438-42
- [41] Khalaf C, Houliand KC. Case report: Primary aortosigmoid fistula – A rare cause of lower gastrointestinal bleeding. *International Journal of Surgery Case Reports*. 2017
- [42] Reis LDO, Moreira RCR. Fistula aorto-sigmoideana primária - relato de um caso. *Rev bras Colo-Proct* 1989;9(3): 113-115