

We are IntechOpen, the world's leading publisher of Open Access books Built by scientists, for scientists

6,900

Open access books available

186,000

International authors and editors

200M

Downloads

Our authors are among the

154

Countries delivered to

TOP 1%

most cited scientists

12.2%

Contributors from top 500 universities



WEB OF SCIENCE™

Selection of our books indexed in the Book Citation Index
in Web of Science™ Core Collection (BKCI)

Interested in publishing with us?
Contact book.department@intechopen.com

Numbers displayed above are based on latest data collected.
For more information visit www.intechopen.com



Surgical Options for Pulmonary Valve Pathology in the Current Era

Sameh M. Said

Abstract

Pulmonary valve pathology occurs mostly in the settings of congenital heart disease whether primary or as the result of repair of a variety of congenital heart defects. Acquired pulmonary valve disorders, albeit rare, can occur in the settings of endocarditis, tumors, carcinoid syndrome, or rheumatic fever. Surgical options include repair and replacement of pulmonary valve. Several options for replacement are available, which can be tailored based on the patient's clinical profile and the primary valve pathology. In this chapter, we present the surgical options that are currently available for pulmonary valve disorders and the current outcomes.

Keywords: pulmonary valve replacement, endocarditis, carcinoid syndrome, congenital pulmonary valve stenosis, pulmonary regurgitation, bioprosthesis, mechanical prosthesis, Ozaki

1. Introduction

A variety of congenital and acquired pathologies results in pulmonary valve (PV) disease that necessitates intervention. The types of this intervention depend on the main pathology with transcatheter options such as balloon valvuloplasty and transcatheter pulmonary valve implantation gaining popularity in the current era, especially in the congenital settings to delay the need for a sternotomy or repeat surgery. Surgical options include open valvotomy for congenital pulmonary valve stenosis and pulmonary valve repair or replacement for many other pathologies. Several replacement options are available currently such as homografts, bioprostheses, and mechanical prostheses with long-term data. Other novel techniques such as intra-operative reconstruction of pulmonary valve leaflets using autologous or bovine pericardium and creation of hand-made valved conduits are being used but no long-term data are available for these techniques.

The focus of this chapter will be on discussing the several surgical options that are currently used to repair or replace the pulmonary valve and the different surgical approaches that are being used with reviewing the literature regarding outcomes. Discussion of the various pathologies involving the pulmonary valve, or the right ventricular outflow tract, is beyond the scope of this chapter.

2. Etiology of pulmonary valve disease

- Congenital
 - Primary
 - Pulmonary stenosis
 - Pulmonary atresia
 - Secondary to surgical treatment of congenital lesions
 - Pulmonary regurgitation after tetralogy of Fallot repair
 - Homograft dysfunctions:
 - Following Ross procedure
 - Homografts used for reconstruction of the right ventricular outflow tract (RVOT):
 - Pulmonary atresia
 - Complex forms of tetralogy of Fallot
 - Truncus arteriosus
- Acquired
 - Carcinoid heart disease
 - Endocarditis
 - Pulmonary artery aneurysms
 - Tumors
 - Rheumatic heart disease

3. Surgical options for pulmonary valve pathology

3.1 Open (surgical) pulmonary valvotomy

Although transcatheter pulmonary balloon valvuloplasty is becoming a gold standard for isolated congenital pulmonary valve stenosis, surgical (open) pulmonary valvotomy may be required in some cases that are most commonly associated with pulmonary annular hypoplasia (**Figure 1**). The advantage of the open technique is the ability to relieve the right ventricular outflow tract (RVOT) obstruction in a controlled fashion *via* splitting the commissures of the pulmonary valve without causing significant regurgitation. It is also useful in addressing associated pulmonary annular hypoplasia *via* the use of a concomitant transannular patch with

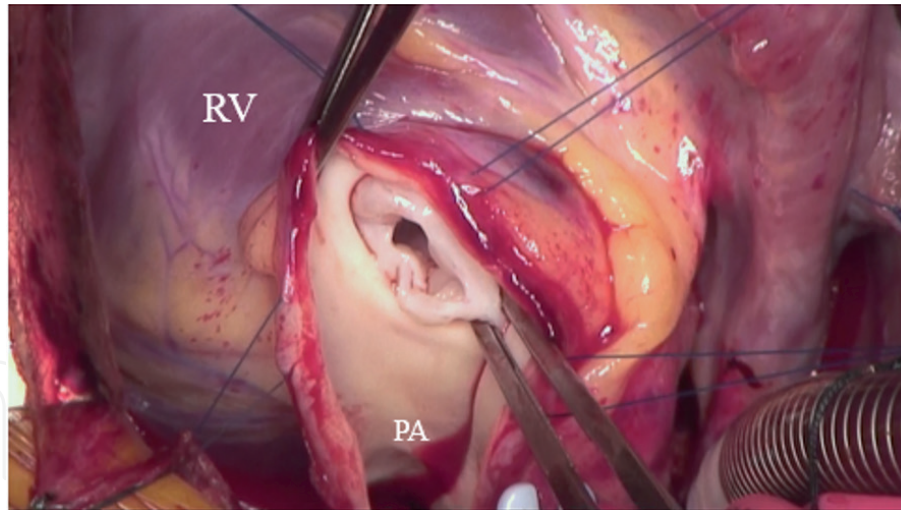


Figure 1.
Intraoperative photo in an infant with isolated congenital pulmonary valve stenosis and hypoplastic pulmonary annulus. Notice the classic bicuspid pulmonary valve with fused commissures. RV: right ventricle; PA: pulmonary artery.

or without reconstruction of a monocusp leaflet. This technique is reported to have long-term excellent results in selected patients [1].

3.2 Pulmonary valve repair

Pulmonary valve repair is possible in selected congenital or acquired cases of pulmonary regurgitation. In the patients who underwent repair of tetralogy of Fallot (TOF) *via* a transannular patch with preservation of the native pulmonary leaflets and present later with dilated pulmonary artery and free pulmonary regurgitation, it is possible to remove the part of the transannular patch and bring the remaining leaflets together anteriorly thus reconstructing the anterior commissure and creating a bicuspid pulmonary valve [2]. In a previous report of 13 patients who underwent TOF repair using a transannular patch and present for pulmonary valve replacement (PVR), it was possible to avoid a prosthesis by repairing the pulmonary valve according to the technique described above [2]. The degree of regurgitation was markedly decreased in all patients and continued during the follow-up period. It is also possible to create a new leaflet from the autologous or bovine pericardium to form a tricuspid pulmonary valve if the other remaining two leaflets are of good quality thus avoiding the use of a prosthesis/homograft.

3.3 Pulmonary valve replacement

Although most valve procedures performed annually involve the aortic and/or mitral valves, the need for pulmonary valve replacement (PVR) is increasing due to the increase in patients with congenital heart disease who survive to adulthood. Because of the improved postoperative care and long-term survival of children undergoing repair of congenital heart defects, it is reasonable to predict that the problem of young adults who have developed sequelae of pulmonary regurgitation after repair of tetralogy of Fallot or neonatal/infant interventions for pulmonary stenosis or atresia will be seen with increasing frequency. In general, most authors recommend the use of bioprostheses or homografts for PVR in children and young adults [3].

A wide variety of materials have been utilized for PVR and or reconstruction of the RVOT. The most commonly used materials include autologous or bovine

pericardium, bioprosthetic (bovine or porcine) or mechanical valves, Dacron conduits/grafts, bovine jugular veins, and homograft (aortic and pulmonary).

3.3.1 Autologous pericardial reconstruction (Ozaki)

The autologous pericardium has been used for decades to create aortic and/or pulmonary valve leaflets (one or more) and more recently has been used to create three-leaflet aortic valves *via* standardized templates (Ozaki procedure) [4]. This procedure began in the adult population but has recently widely spread to the pediatric patients with aortic valve pathology with good initial and mid-term results in some series [5].

More recently, the same procedure has been used to create three-leaflet pulmonary valves for PVR (**Figures 2A–F** and 3). Limited literatures are available for the Ozaki outcome in the pulmonary position and the majority of these are case reports using autologous pericardium [6] or bovine pericardium [7]. This was used in the setting of pulmonary artery aneurysm [8], endocarditis, and free pulmonary regurgitation after previous pulmonary valvotomy. We have utilized the Ozaki templates to create three leaflet pulmonary valves for an infant who was born with congenital pulmonary stenosis and hypoplastic annulus and in another child who underwent late repair of tetralogy of Fallot with pulmonary stenosis.

3.3.2 Valved conduits

Valved conduits used during the repair of a variety of congenital heart defects, most commonly tetralogy of Fallot with pulmonary atresia, truncus arteriosus, and Rastelli procedure for (corrected) transposition of the great arteries with pulmonary outflow tract obstruction. These conduits include homografts (aortic/pulmonary/femoral vein), xenografts (bovine jugular vein), and synthetic (Dacron

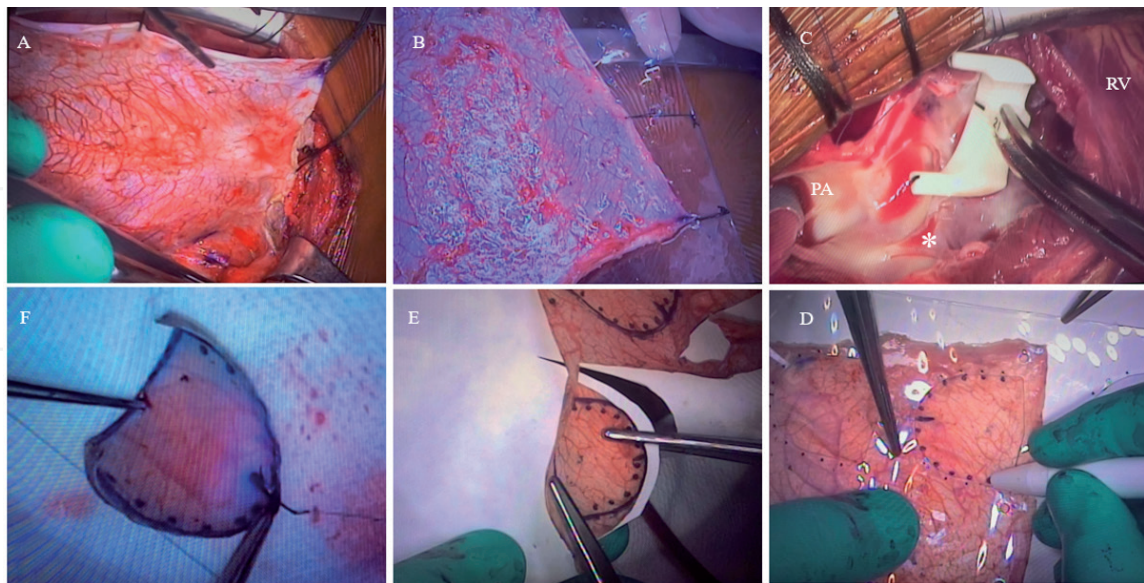


Figure 2.

Intraoperative photos demonstrating the Ozaki technique for reconstruction of a new pulmonary valve using the autologous pericardium. (A) A large sheet of the anterior pericardium is harvested once the sternotomy is performed, (B) the pericardium is then mounted on the plate provided with the Ozaki set and is treated with glutaraldehyde 0.6% for 3 minutes, (C) the main pulmonary artery and the right ventricular outflow tract are opened longitudinally and remnants of the pulmonary valve leaflets are resected and the Ozaki sizers are used to determine the size of the future pericardial leaflets and to mark the suture lines and determine the location of the commissures, (D) the pericardial leaflets are marked using the Ozaki template, (E) the leaflets are cut with scissors, and (F) suturing is begun with running polypropylene along the marked lines in the right ventricular outflow tract. RV: right ventricle.

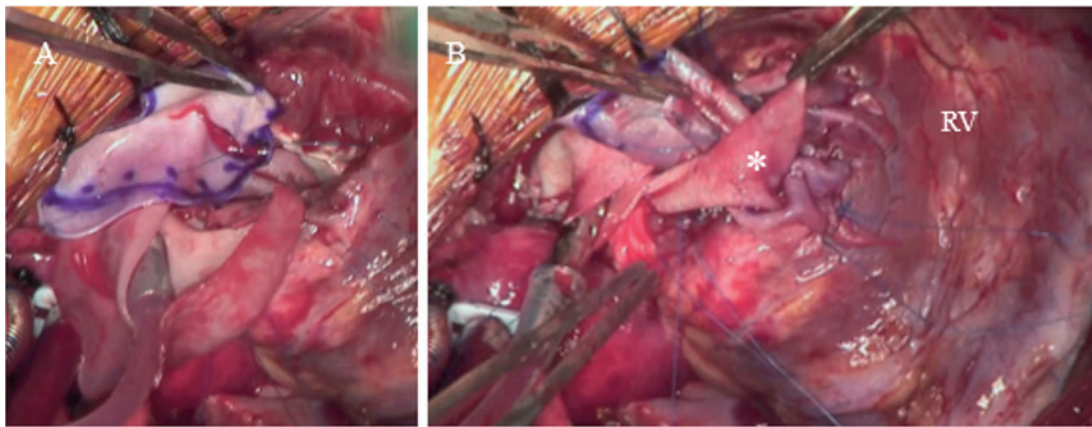


Figure 3.
Intraoperative photos showing the rest of the steps for the Ozaki reconstruction of the pulmonary valve. (A) Pericardial leaflets are sewn in with running polypropylene sutures, and (B) two leaflets along the posterior native annulus and the anterior leaflet is sewn to the undersurface of the pericardial patch (asterisk) that is used to augment the right ventricular outflow tract and the main pulmonary artery. RV: right ventricle.

conduit, expanded polytetrafluoroethylene [e-PTFE]). Several factors affect the choice of any of these valved conduits such as the age of the patient, the original pathology, previous procedure/conduit used, and availability.

3.3.3 Homografts

Homografts continued to remain the most commonly used conduits for RVOT reconstruction. A variety of these homografts have been used including aortic, pulmonary (**Figure 4**), and more recently valved femoral veins. The advantages include its availability in smaller sizes and the lack of the rigidity associated with other prostheses, which make them suitable conduits for neonates, infants, and small children. Downsides include long-term calcifications, cost, and limited availability in many countries. We reserve the use of homografts for infants and small

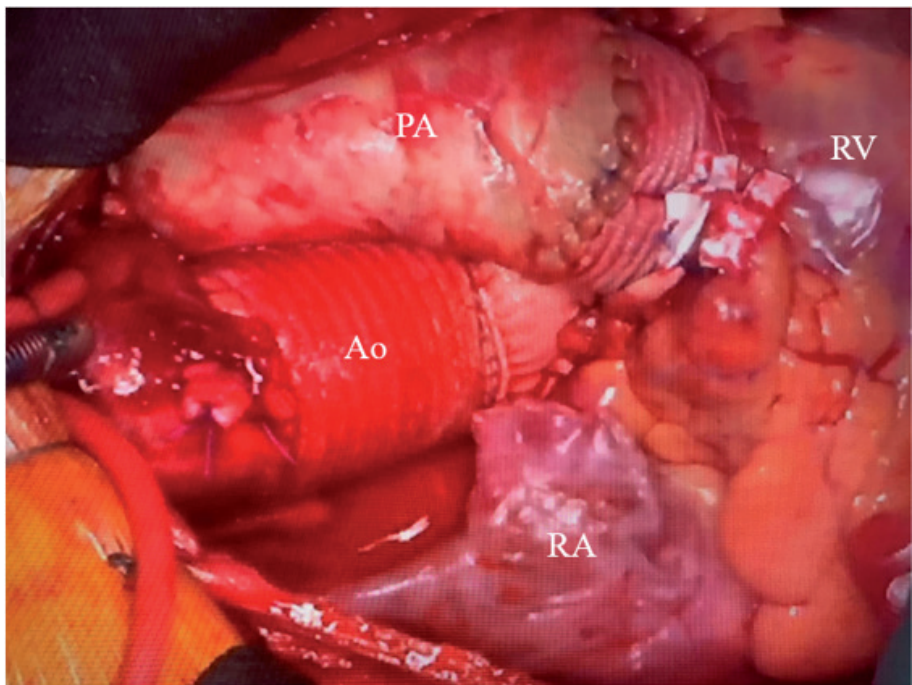


Figure 4.
Intraoperative photo for a patient who underwent a Ross procedure with a pulmonary homograft used to establish the right ventricular-to-pulmonary arterial confluence continuity. RV: right ventricle, Ao: ascending aorta, PA: pulmonary artery homograft, RA: right atrium.

children due to the absence of suitable size prostheses in this age and for those with endocarditis as well.

3.3.4 Expanded polytetrafluoroethylene (e-PTFE) (Gore-Tex) conduits

Handmade expanded e-PTFE valves have been used with good results for RVOT reconstruction. The main advantages of these handmade conduits are related to their availability and lack of calcifications or immunological reactions, which may have the potential to prolong the longevity of these conduits. Current data do not show the inferiority of these conduits to homografts or bovine jugular veins. In fact, they have good biocompatibility and there was no evidence of calcifications in excised e-PTFE valves [9]. We personally do not have experience with this technique.

3.3.5 Biological prostheses

The vast majority of children and young adults who require PVR receive a biological valve. These prostheses carry the advantage of good durability in the pulmonary position and avoidance of long-term anticoagulation.

3.3.6 Mechanical prostheses

While bioprostheses are the most commonly used prostheses for PVR, the need for repeat operation is inevitable in children and young adults with congenital heart disease and mechanical prostheses may be considered in selected clinical scenarios to minimize the risks involved with repeat operations. The operative risk of mortality increases from 2% at the first repeat sternotomy compared with 4.7% at a fourth sternotomy [10]. Furthermore, Morishita and colleagues demonstrated a fourth time sternotomy to be a predictor of resternotomy-related injury (hazard ratio, 4.31) [11].

Most of those who are considered for mechanical PVR had a congenital diagnosis and underwent multiple previous sternotomies in the past (**Figure 5**).

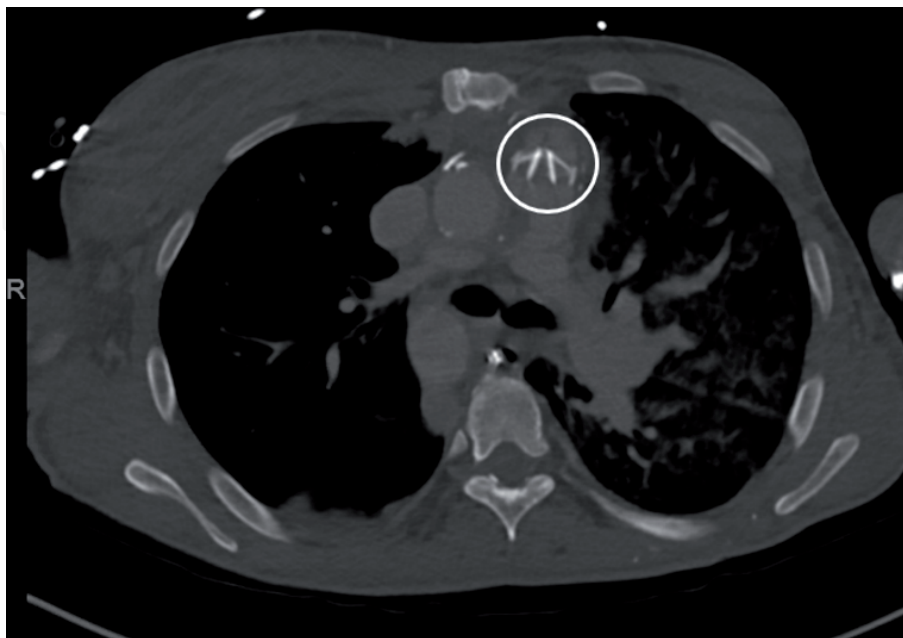


Figure 5. Computed tomography scan in a patient who underwent multiple previous sternotomies for an initial Rastelli procedure with subsequent multiple pulmonary conduits changes and has a bileaflet mechanical prosthesis in the pulmonary position (white circle).

Although mechanical prostheses are durable, the need for higher-level anti-coagulation carries its own risks, but recent reports suggest that with proper anticoagulation and careful monitoring, the risk of prosthetic thrombosis or dysfunction is low.

The issue of the performance of a mechanical prosthesis in the pulmonary position remains a matter of debate as there are no precise criteria for the selection of patients in whom this prosthesis would be well suited. We believe the ideal patient for mechanical PVR is the patient who underwent multiple previous sternotomies and/or requires anticoagulation for another reason such as a left-sided mechanical prosthesis. This patient population includes those with repaired truncus arteriosus, prior Ross procedure, and occasionally repaired tetralogy of Fallot. Other indications may include those who demonstrated poor durability of bioprostheses.

In every case where a mechanical prosthesis is considered, the ultimate treatment decision is individualized after weighing the risks of reoperation if a bioprosthesis is chosen, with the potential bleeding/thrombotic risks if a mechanical prosthesis is chosen.

4. Preoperative evaluation

Associated defects that commonly need to be addressed at the time of PVR include tricuspid valve repair, patch pulmonary arterioplasties, closure of residual shunts, and arrhythmia surgery.

Preoperative transthoracic echocardiography (TTE), computed tomography (CT) scan, or magnetic resonance imaging (MRI) are routinely performed. Cross-sectional imaging is helpful to determine the relationship of mediastinal structures especially the aorta and/or extracardiac conduits to the sternum and in assessing the pulmonary arterial anatomy. Coronary artery evaluation may be needed in certain circumstances to rule out obstructive coronary artery disease or coronary anomalies especially ones that may change the surgical plan regarding the PVR technique. Hemodynamic data from cardiac catheterization may be needed to complement other studies when there is uncertainty about the anatomy or ventricular function.

Intraoperative transesophageal echocardiography (TEE) is routinely performed before and after cardiopulmonary bypass with or without intraoperative direct pressure measurement across the right ventricular outflow tract.

5. Surgical approaches

5.1 Median (Re-do) sternotomy

Primary or repeat sternotomy has been the most commonly used approach. Technical aspects of repeat sternotomy with or without peripheral cannulation have been discussed previously [12].

5.2 Left posterolateral thoracotomy

Left posterolateral thoracotomy has been used as an alternate to sternotomy/ repeat sternotomy for PVR [13]. With the patient in the modified right lateral decubitus position, the chest is usually entered through the left fourth/fifth intercostal space. Normothermic cardiopulmonary bypass is established *via* the

femoral vessels. It is important to rule out the presence of any intracardiac shunts before proceeding with this approach. The right ventricular outflow tract and main pulmonary artery are identified, and once the pulmonary artery is incised, the PVR is proceeded as described below.

5.3 Minimally invasive left anterior thoracotomy incision

We have utilized left anterior minithoracotomy as an alternative approach to sternotomy for PVR in selected patients who required isolated PVR and in the absence of intracardiac shunts. This approach carries the advantage of being less invasive with rapid recovery, but careful patient selection is required. It is not advisable in the presence of previous pulmonary conduits, but it can be useful in cases where hostile mediastinum is encountered after multiple previous surgeries or in the presence of a large aorta in close proximity to the sternum, which increases the risk of repeat sternotomy.

We have previously published our technique that can be used in both primary and reoperative settings [14] (**Figures 6A–F and 7A and B**). In summary, the patient is positioned supine, prepped, and draped as for standard median sternotomy. A 6-cm horizontal incision is performed through the left third or fourth intercostal space. In primary operative settings, the left lung is gently retracted to expose the pericardium, which is then incised anterior to the left phrenic nerve to expose the RVOT and the main pulmonary artery. In re-operative settings, the left lung is usually adherent to the RVOT and/or the previously placed transannular patch if the pericardium was not closed after the first procedure and will need to be dissected off the main pulmonary artery and RVOT.

Cardiopulmonary bypass is established *via* the femoral vessels (open/percutaneously cannulated) at normothermia. It is important to achieve adequate right

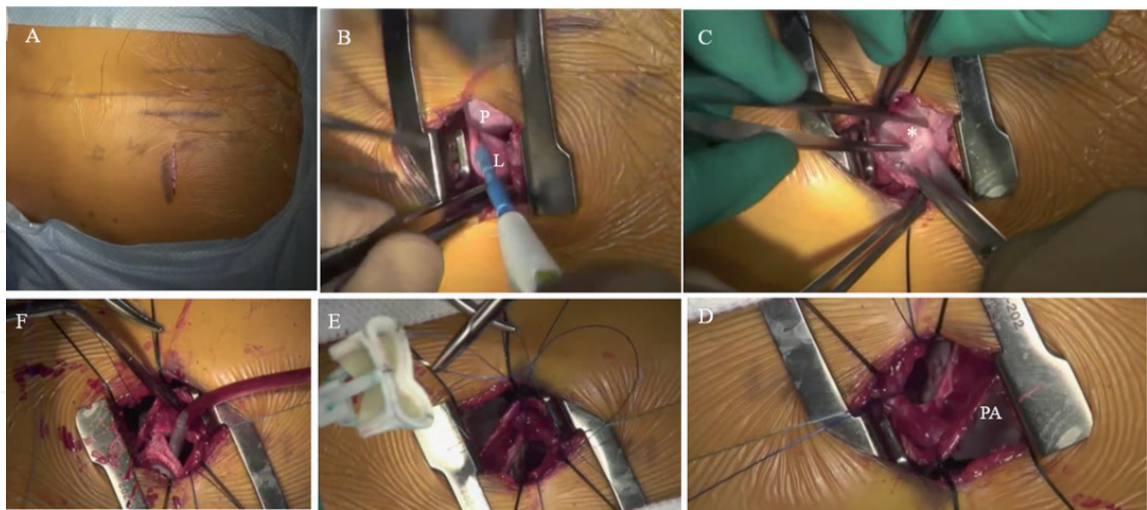


Figure 6.

Intraoperative photos demonstrating the technical steps for pulmonary valve replacement via a minimally invasive left anterior thoracotomy. (A) The patient is positioned supine and a 6-cm horizontal skin incision is created along the left parasternal border along the left third/fourth ribs, (B) the left chest is entered through the left third/fourth intercostal space, and the left lung is retracted medially to expose the pericardium or the previously placed transannular patch, (C) in reoperative settings, pleural adhesions (asterisk) need to be taken down to free the lung from the right ventricular outflow tract, (D) cardiopulmonary bypass is established via the femoral vessels and once the heart is decompressed, the main pulmonary artery/transannular patch is incised longitudinally to expose the pulmonary valve, (E) remnants of the pulmonary valve leaflets are excised, annulus is sized and a new bioprosthesis is seated along the posterior annulus using running polypropylene suture, and (F) the majority of the prosthesis is seated along the native pulmonary annulus, while the anterior portion will be secured to the pericardial patch that will be used to augment the right ventricular outflow tract. P: pericardium, L: left lung, PA: main pulmonary artery.

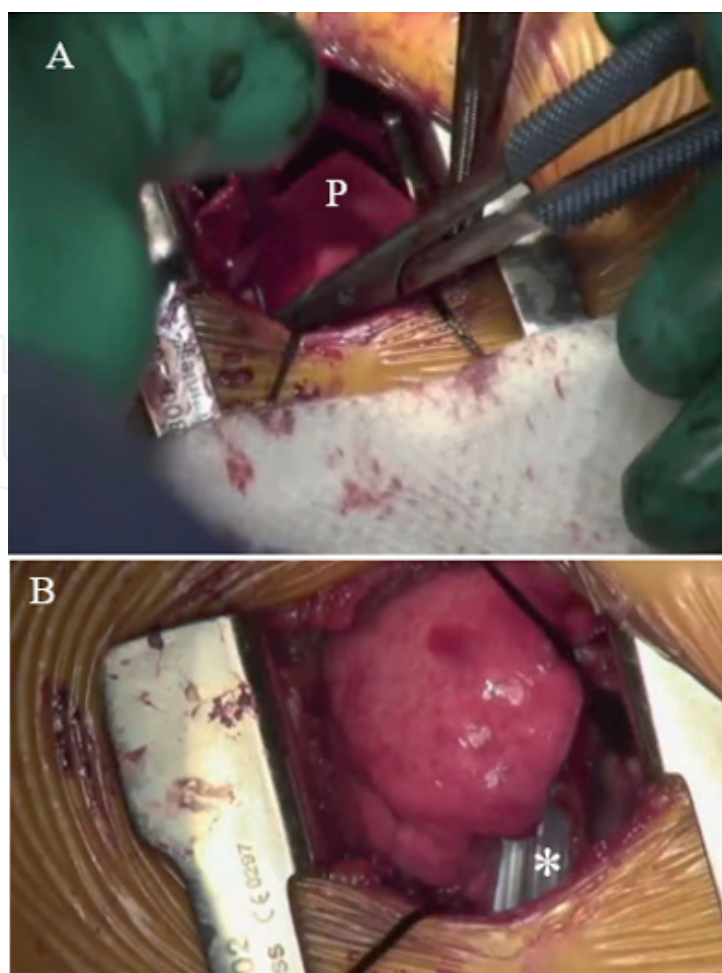


Figure 7.

Intraoperative photos showing the remaining steps in pulmonary valve replacement via a left anterior thoracotomy. (A) A pericardial patch is commonly used to complete the augmentation of the main pulmonary artery and right ventricular outflow tract and the prosthesis is sewn to the undersurface of this patch with a running polypropylene suture, and (B) once the reconstruction is completed, the patient is weaned off cardiopulmonary bypass, and a single chest tube (asterisk) is placed, and the incision is closed in layers in the standard fashion. P: pericardial patch.

heart decompression during this procedure owing to the limited exposure. Along with routine use of vacuum-assisted venous drainage, we prefer to use a multistage venous cannula that is inserted *via* the common femoral vein and advanced all the way up to the superior vena cava. A vertical incision is made along the previous transannular patch/main pulmonary artery and remnants of pulmonary valve leaflets are excised if present. The PVR is then continued as described below. The right side of the heart is then deaired, and the patient is weaned off cardiopulmonary bypass. Once TEE is satisfactory, the groin is decannulated and femoral vessels are repaired. A single chest drain is placed and both groin and chest incisions are then closed in layers. The patient is typically extubated in the operating room at the end of the procedure.

Our experience with this technique is in its early phase, but we have performed the procedure in 6 patients (the youngest at age 13 years; 4 with previous tetralogy of Fallot repair). The procedure was feasible, with no conversion to open sternotomy in any. There was no early or late mortality. One patient developed a femoral artery pseudoaneurysm during follow-up due to percutaneous cannulation and required late repair. The length of stay averaged 2 days [15]. We believe that weight more than 30 kg is necessary for satisfactory groin vessel cannulation.

6. Surgical techniques of pulmonary valve replacement

6.1 Sternal re-entry

Basics of primary or repeat sternotomy are followed. Sternal re-entry can be challenging, especially in the presence of a right-sided pathology (e.g., pulmonary hypertension, enlarged right heart structures, or extracardiac conduit). We prefer the oscillating saw for repeat sternotomy, although a craniotome can also be used.

The decision to expose the femoral vessels versus cannulating them and initiating cardiopulmonary bypass to facilitate sternotomy is individualized and is dependent on the experience of the surgeon. Groin cannulation can be performed *via* a cut down with or without percutaneous right internal jugular to superior vena cava cannulation, which allows establishing complete cardiopulmonary bypass. Special attention is made to ensure adequate antegrade perfusion and adequate venous return of the lower extremity. This may require a chimney graft on the femoral artery. Axillary artery cannulation is also an option and is preferred if concomitant aortic surgery is being performed. If it is necessary to initiate cardiopulmonary bypass before or during sternal reentry, it is important to maintain a positive central venous pressure to avoid potential air embolism, which can occur if there is inadvertent entry into the right heart in the presence of an intracardiac shunt.

The procedure can be performed with aortic and a single-venous cannulation at normothermia in the absence of concomitant cardiac pathology that needs concomitant repair. It is commonly performed on the beating heart without cardioplegic arrest in the absence of intracardiac shunts. However, a short period of aortic cross-clamping and cardioplegia may be needed in challenging cases where heavily calcified or scarred RVOT patches or conduits are present to allow safe decalcification and adequate debridement before removing the cross-clamp and completing the PVR or the new conduit placement on a beating heart.

6.2 Pulmonary valve reconstruction with autologous pericardium (pulmonary Ozaki)

The basic principle of the technique in harvesting the autologous pericardium and creating the leaflets and sewing them is similar to the Ozaki technique described for aortic valve replacement.

However, there are important anatomical differences between the aortic and pulmonary roots that required modification of the technique to facilitate exposure and leaflet placement. Three possible ways to apply this technique for pulmonary valve reconstruction are as follows:

- If the pulmonary artery and root are adequate, the main pulmonary artery can be completely transected, and the leaflets are sized with the appropriate Ozaki sizers and suture lines are marked at the native pulmonary annulus in a similar fashion to the aortic procedure. The leaflets are then sewn in a similar fashion to the aortic technique; then, the pulmonary artery continuity is re-established.
- A second strategy is to build a valved conduit with pericardial leaflets sewn inside a Dacron graft on the back table; then, the conduit is implanted in a similar fashion to a standard pulmonary conduit.
- More commonly, the patient is presented with a hypoplastic pulmonary annulus that needs to be enlarged. A longitudinal pulmonary arteriotomy is performed, and the two posterior leaflets are created along the pulmonary

annulus/RVOT. The RVOT is enlarged with a pericardial patch in a way similar to the transannular patch technique. This patch is extended up to the future sinotubular junction, and the third leaflet is then sewn to the pericardial patch and the commissures are created followed by completing the augmentation of the main pulmonary artery with the remainder of the patch.

6.3 Biological/mechanical prosthesis

6.3.1 Isolated PVR

6.3.1.1 Previous transannular patch

The most common scenario occurs with a dilated right ventricular outflow tract from the previous repair of tetralogy of Fallot with a transannular patch (**Figure 8A–D**). In the setting, the patch is opened longitudinally and stay sutures are placed on both sides. Most commonly, the incision is extended proximally into the RVOT and distally into the proximal left main branch pulmonary artery. Pathological/remnant pulmonary valve cusps are resected if present. An appropriately sized bovine pericardial patch (our preference) is then chosen and sewn distally to the proximal left main branch pulmonary artery. It is not uncommon that concomitant branch pulmonary arterioplasty is needed in these cases. The patch is sewn in with running polypropylene sutures till the proposed level of the new pulmonary prosthesis is reached.

An appropriately sized prosthesis (biological/mechanical) is chosen and is secured along the native pulmonary annulus posteriorly with running polypropylene suture (interrupted sutures with or without pledgets may be used sometimes based on the tissue quality). It is critical to avoid deep sutures along the pulmonary annulus due to the close proximity of the left main coronary artery.

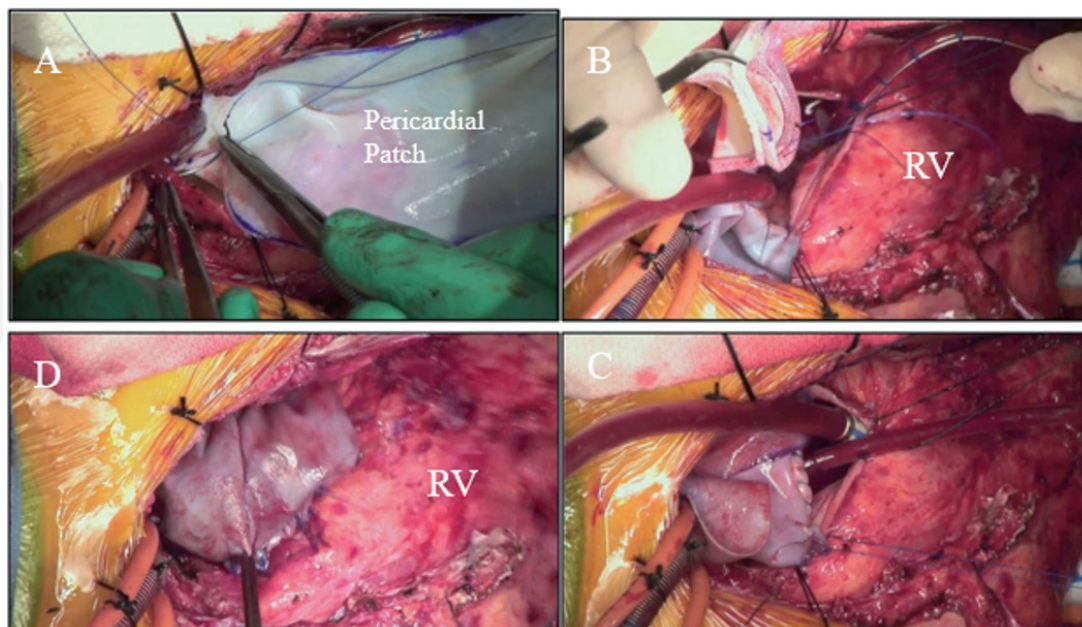


Figure 8.
 Intraoperative photos showing the most commonly used technique for pulmonary valve replacement. (A) A longitudinal incision is created along the main pulmonary artery and is extended proximally into the right ventricular outflow tract and distally usually to the proximal left main pulmonary artery. A large pericardial patch is then sutured to augment the main pulmonary artery is extended down to the level of the future prosthesis, (B) the prosthesis is secured with a running polypropylene suture along the posterior annulus, (C) the anterior portion of the sewing ring is then secured to the undersurface of the pericardial patch, (D) the remainder of the patch is trimmed and used to complete the right ventricular outflow tract reconstruction. RV: right ventricle.

In fact, in some situations, it is better to place the prosthesis more distally (between the native pulmonary annulus and the pulmonary artery bifurcation) to avoid compromising the left coronary artery. The anterior portion of the sewing ring of the prosthesis is then secured to the undersurface of the patch with a running suture. It is important to carefully think about the orientation of the prosthesis before securing it to the undersurface of the patch and especially when it is a biological one due to its larger profile that can create a higher gradient across its path if not oriented properly. The prosthesis should be tilted posteriorly toward the pulmonary bifurcation. Also, it is important to have some redundancy in the pericardial patch proximal and distal to the prosthesis to ensure no gradient is created due to a tight patch. This completes the prosthesis securement in the outflow tract. The rest of the bovine pericardial patch is then trimmed and sewn to the RVOT to complete its reconstruction.

6.3.1.2 Dilated pulmonary root with no patch

If the main pulmonary artery/outflow tract is dilated or in the presence of a pulmonary artery aneurysm, our technique is different. A transverse pulmonary arteriotomy is created, and a running or interrupted suture technique is used to secure the prosthesis similar to a standard aortic valve replacement. The pulmonary arteriotomy is then closed with a running polypropylene suture.

6.4 Valved pulmonary conduit

This is commonly used to replace a failed or dysfunctional conduit that was placed in a previous operation as a part of the initial repair of congenital heart defects such as tetralogy of Fallot with pulmonary atresia, truncus arteriosus, and post-Ross and Rastelli procedures.

It is critical to keep in mind the location of the left main coronary artery (posterior) and the left anterior descending coronary artery (lateral) in relation to the conduit especially when anatomical details are unclear in the setting of repeat

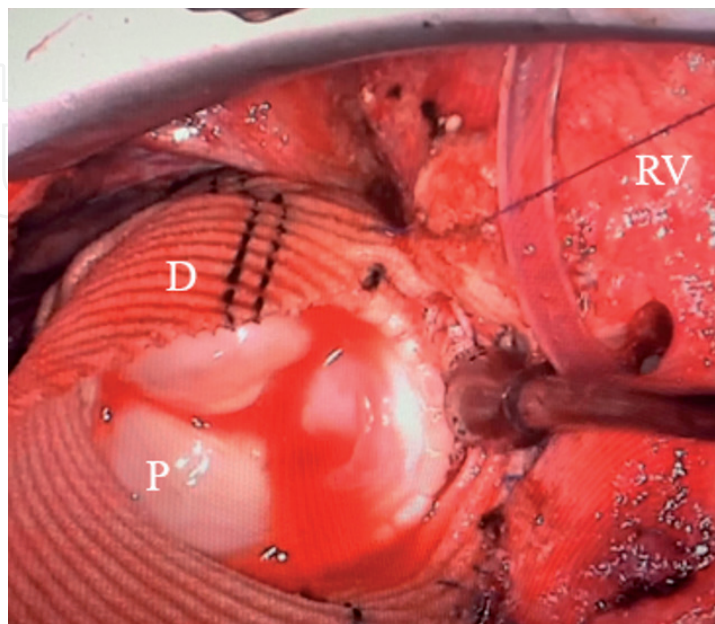


Figure 9. Intraoperative photo showing a surgically created pulmonary conduit by placing a bioprosthesis inside a Dacron tube graft which is sewn proximally and distally to the right ventricular outflow tract and the pulmonary arterial confluence respectively. RV: right ventricle, D: Dacron tube graft, P: pulmonary bioprosthesis.

operations. The conduit itself while in most cases is located to the left of the sternum, and in certain congenital heart defects, it may be immediately behind the sternum, or in the midline such as cases of the previous repair of truncus arteriosus. This may require modification of the surgical technique during reoperation or initiation of cardiopulmonary bypass *via* peripheral cannulation to avoid injury to the conduit during repeat sternotomy. The majority of these conduits (homografts) are calcified to various degrees, which may increase the difficulty during the replacement. It may also require a complete explantation of the conduit to be able to replace a new one.

We have used different techniques in these situations depending on the quality of the previous conduit and the degree of calcification present:

- A longitudinal incision is placed in the anterior aspect of the conduit, while its posterior wall is kept intact, which minimizes injury to the left main coronary artery. After adequate debridement and decalcification, the new prosthesis is placed with a roof of pericardial patch similar to the technique described in the case of the transannular patch.
- If the previous conduit was a Dacron conduit, it can be dissected from the external fibrous peel and excised. It is important to minimize dissection of the floor and preserve the thick fibrous peel to allow sturdy suture placement.
- The position of the new prosthesis is critically important. In general, we place the prosthesis distally toward the pulmonary confluence, which minimizes potential compression of the left main coronary artery. Alternatively, the prosthesis can be placed more proximally near the level of the native pulmonary annulus.
- In some scenarios, the old conduit can be completely excised, and, in these cases, there is a lack of continuity between the RVOT and the pulmonary confluence. We then create a new valved conduit using a biological/mechanical prosthesis inside a Dacron tube graft (**Figure 9**), which is then sewn proximally and distally to the RVOT and the pulmonary arterial confluence respectably.

Regarding mechanical prostheses, it is important not to oversize them even if there is enough room to place a large prosthesis. Having a mild gradient across the prosthesis (10-15 mmHg) and a higher velocity facilitate leaflet mobility in a more effective way. When the prosthesis is oversized and the gradient is quite low (<5 mmHg), then only one disk may open properly, while the other is poorly moving, which increases the risk of thrombosis.

Finally, the heart is adequately de-aired and cardiopulmonary bypass is discontinued. Post-procedure TEE is performed, and direct pressure measurements of the right ventricular and pulmonary arterial pressures are obtained.

7. Outcomes

7.1 Valved conduits

Dacron conduits create thick intimal peel that requires explantation at the time of repeat operations. Homografts and bovine jugular veins show variable degrees of durability, but early degeneration and calcifications are sometimes inevitable (**Figure 10**). Added to this is their limited availability in many countries.

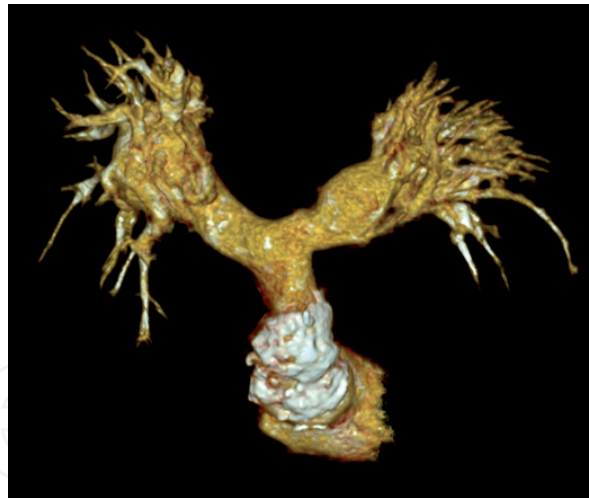

Figure 10.

Preoperative CT scan showing calcified bovine jugular vein graft in patient who underwent repeat sternotomy for pulmonary conduit replacement.

A multicenter study in Japan included 794 patients (aged 14 days to 56.8 years old) in which e-PTFE valves were used for RVOT reconstruction at 52 Japanese institutes had a mean follow-up of 3.6 years (maximum 10 years) [16]. The e-PTFE was in the form of fan-shaped valved conduits and patches with bulging sinuses. The freedom from reoperation at 10 years was 95.4% in patients with conduits and 92.3% in those with patches. No or mild pulmonary regurgitation was present in 95 and 79.6% of those with conduits and those with patches, respectively.

7.2 Biological prostheses

In general, there are conflicting reports in the literature regarding the durability of various prostheses in the pulmonary position. Bando et al. observed that 94% of homografts have good function after 5 years; however, almost 25% had evidence of moderate-to-severe calcifications (**Figure 11A and B**) [17].

Regarding bioprosthetic conduits, a failure rate of 15% of 3 years was observed in the study by Cleveland et al. and calculated that 55% would have avoided a reoperation at 5 years [18].

In the study by Batlivala et al., the authors compared bioprostheses and homograft conduits in the pulmonary position [19]. This included 254 patients aged 10–21 years old. The median follow-up was 4.4 years. Freedom from valvar dysfunction was $72\% \pm 4\%$ at 5 years and $48\% \pm 8\%$ at 10 years. Freedom from RVOT re-interventions was $90\% \pm 3\%$, and $67\% \pm 5\%$ at 5 and 10 years, respectively. No differences were present between bioprosthesis and homografts.

7.3 Mechanical prostheses

In a study from Mayo Clinic, 59 patients underwent mechanical PVR between 1965 and 2013, and no valve thrombosis was observed in the settings of adequate anticoagulation with Warfarin. The maximum follow-up in this study extended to 20 years with no reoperations related to pannus formation, paravalvular leak, endocarditis, valve thrombosis, or prosthetic dysfunction.

The range of reported thrombosis for a mechanical PVR varies from 25 to 80% [20]. These thrombotic complications were reported with bileaflet mechanical prostheses, and none was reported in those with a tilting-disk prosthesis, although literature on this topic is sparse in general. The reported complication rate of a bileaflet

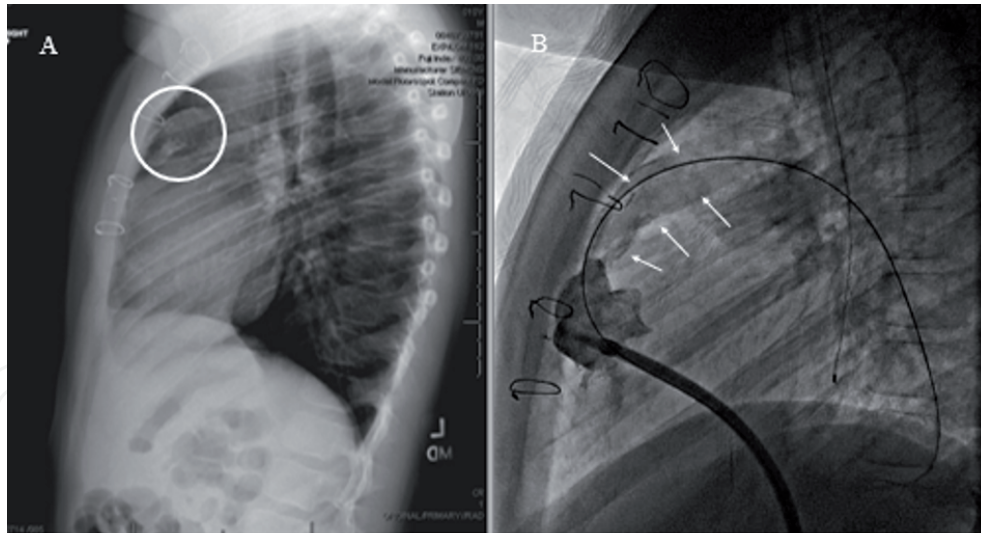


Figure 11.
Preoperative images of a patient who had previous aortic homograft placed in the right ventricular outflow tract for repair of tetralogy of Fallot with pulmonary atresia. (A) Chest X ray showing extensive and complete calcifications of the homograft pulmonary conduit (white circle), (B) which is confirmed by preoperative cardiac catheterization (multiple white arrows). Notice the close proximity of the pulmonary conduit to the back of the sternum.

prosthesis in the pulmonary position has been about 35%. The majority of these thrombotic events were observed in those who were not adequately anticoagulated with Warfarin. Taken together, the frequency of thrombosis if the patient was not maintained on Warfarin was 41% (15 of 37 prostheses failed); however, if the patient is adequately anticoagulated, the rate of thrombosis dropped to 3.5% [21, 22]. These observations are seen also in the series reported by Freling et al., which spanned 26 years and included 66 patients [23]. Actuarial freedom from reoperation was 96% at 5 years and 89% at 10 years.

A meta-analysis of 299 patients from 19 observational studies by Dunne et al. documented nonstructural deterioration and valve thrombosis rates of 1.5 and 2.2%, respectively [24]. Redo surgery was needed in 0.9%, and thrombolysis was used in 0.5%. This is the largest analysis to date and confirms the low incidence of valve dysfunction and thrombosis for mechanical prostheses in the pulmonary position.

8. Conclusions

The pulmonary valve can be affected by a variety of congenital and acquired diseases. Although repair or preservation of the pulmonary valve may be possible in certain cases, replacement is usually required whether in primary or reoperative settings based on the original, pathology affecting the pulmonary valve/RVOT.

Surgical approaches can be through (repeat) sternotomy, left posterolateral thoracotomy, or minimally invasive left anterior minithoracotomy.

Several options are available for the replacement of the pulmonary valve with or without reconstruction of the RVOT. The most commonly used options include homografts and bioprosthetic or mechanical valves. While our first choice as a prosthesis for PVR is a biological valve that facilitates subsequent transcatheter interventions (**Figure 12**), the deciding factor between any of these options depends on the patient's clinical profile especially age, original pathology/indication, prosthesis availability, and future expectations for this patient and therefore, it should be individualized. Other novel strategies such as handmade e-PTFE conduits and autologous pericardial leaflet reconstruction may be considered.

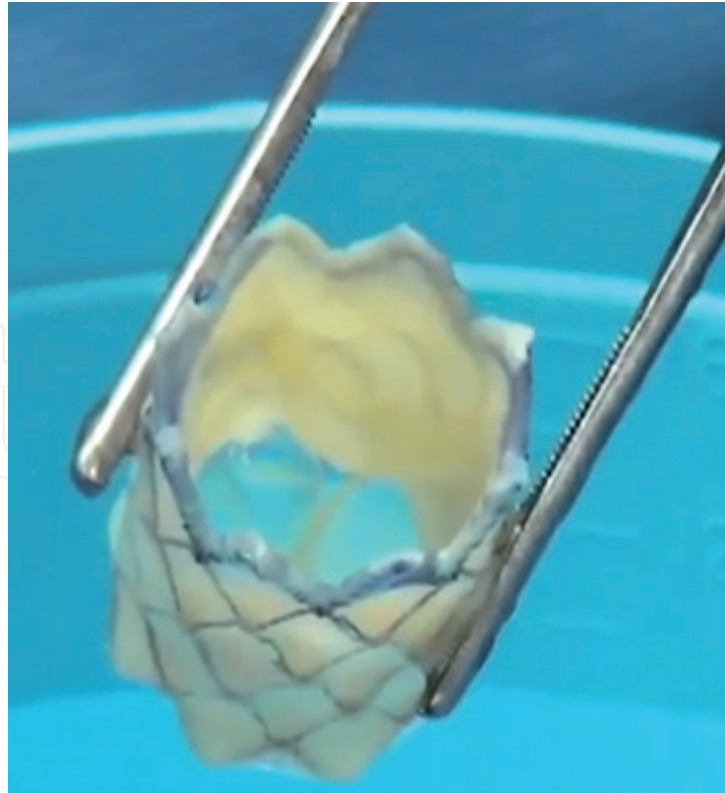


Figure 12.
Melody transcatheter valve is the most commonly used transcatheter option after failed pulmonary bioprostheses and homografts.

Although some of these conduits have long-term data in terms of durability and freedom from reintervention, literatures are limited regarding other techniques and the bottom line is we do not have the ideal pulmonary valve/conduit yet.

Conflict of interest

The author (S.M.S) is a consultant for Cryolife and Stryker.

Author details

Sameh M. Said
Division of Pediatric Cardiovascular Surgery, Masonic Children's Hospital,
University of Minnesota, Minneapolis, MN, USA

*Address all correspondence to: ssaid@umn.edu

IntechOpen

© 2021 The Author(s). Licensee IntechOpen. This chapter is distributed under the terms of the Creative Commons Attribution License (<http://creativecommons.org/licenses/by/3.0>), which permits unrestricted use, distribution, and reproduction in any medium, provided the original work is properly cited. 

References

- [1] Sekhon S, Barger PM, Abarbanell AM. Outcomes 60 years after surgical valvotomy for isolated congenital pulmonary valve stenosis. *Journal of Cardiac Surgery*. 2021;**36**:1531-1533
- [2] Said SM, Mainwaring RD, Ma M, Tacy T, Hanley FL. Pulmonary valve repair for patients with acquired pulmonary valve insufficiency. *The Annals of Thoracic Surgery*. 2016;**101**:2294-2301
- [3] Rosti L, Murzi B, Colli AM, Festa P, Redaelli S, Havelova L, et al. Mechanical valves in the pulmonary position: A reappraisal. *The Journal of Thoracic and Cardiovascular Surgery*. 1998;**115**:1074-1079
- [4] Ozaki S, Kawase I, Yamashita H, Uchida S, Nozawa Y, Takatoh M, et al. A total of 404 cases of aortic valve reconstruction with glutaraldehyde-treated autologous pericardium. *The Journal of Thoracic and Cardiovascular Surgery*. 2014;**147**:301-306
- [5] Ozaki S, Kawase I, Yamashita H, Uchida S, Takatoh M, Kiyohara N. Midterm outcomes after aortic valve neocuspidization with glutaraldehyde-treated autologous pericardium. *The Journal of Thoracic and Cardiovascular Surgery*. 2018;**155**:2379-2387
- [6] Yepez C, Rios J. Pulmonary valve reconstruction using Ozaki's technique for infective endocarditis. *European Journal of Cardio-Thoracic Surgery*. 2021;**59**(4):917-919
- [7] Baird C, Chavez M, Friedman K. Pulmonary valve reconstruction using the Ozaki leaflet reconstructive techniques. *The Annals of Thoracic Surgery*. 2021;**111**(1):e19-e21
- [8] Takahashi Y, Shibata T, Fujii H, Morisaki A, Sakon Y, Yamane K, et al. Aortic and pulmonary valve reconstruction using autologous pericardium in narrow annuli. *The Annals of Thoracic Surgery*. 2020;**109**:e13-e15
- [9] Ando M, Takahashi Y. Ten-year experience with handmade trileaflet polytetrafluoroethylene valved conduit used for pulmonary reconstruction. *The Journal of Thoracic and Cardiovascular Surgery*. 2009;**137**:124-131
- [10] Brown ML, Dearani JA, Burkhart HM. The adult with congenital heart disease: Medical and surgical considerations for management. *Current Opinion in Pediatrics*. 2009;**21**:56-61
- [11] Morishita K, Kawaharada N, Fukada J, Yamada A, Masaru T, Kuwaki K, et al. Three or more median sternotomies for patients with valve disease: Role of computed tomography. *The Annals of Thoracic Surgery*. 2003;**75**:1476-1480
- [12] Said SM, Dearani JA. Strategies for high-risk reoperations in congenital heart disease. *Seminars in Thoracic and Cardiovascular Surgery. Pediatric Cardiac Surgery Annual* 2014;**17**(1): 9-21.
- [13] Roubertie F, Henaine R, Roques X, Thambo JB. Left posterolateral thoracotomy: An alternative approach for pulmonary valve replacement. *The Annals of Thoracic Surgery*. 2014;**97**: 691-693
- [14] Said SM. Minimally invasive pulmonary valve replacement via left anterior minithoracotomy. *JTCVS Techniques*. 2020;**6**:127-129
- [15] Said SM, Marey G, Hiremath G, Aggarwal V, Kloesel B, Griselli M. Pulmonary valve replacement via left anterior minithoracotomy: Lessons

learned and early experience. *Journal of Cardiac Surgery*. 2021;**36**(4):1305-1312

[16] Miyazaki T, Yamagishi M, Maeda Y, Yamamoto Y, Taniguchi S, Sasaki Y, et al. Expanded polytetrafluorethylene conduits and patches with bulging sinuses and fan-shaped valve sin right ventricular outflow tract reconstruction: Multicenter study in Japan. *The Journal of Thoracic and Cardiovascular Surgery*. 2011;**142**:1122-1129

[17] Bando K, Danielson GK, Schaff HV, Mair DD, Julsrud PR, Puga FJ. Outcome of pulmonary and aortic homografts for right ventricular outflow tract reconstruction. *The Journal of Thoracic and Cardiovascular Surgery*. 1995;**109**:509-518

[18] Cleveland DC, Williams WG, Razzouk AJ, Trusler GA. Failure of cryopreserved valved conduits in the pulmonary circulation. *Circulation*. 1992;**86**(Suppl):II150-II153

[19] Batlivala S, Emani S, Mayer J, McElhinney DB. Pulmonary valve replacement function in adolescents: A comparison of bioprosthetic valves and homograft conduits. *The Annals of Thoracic Surgery*. 2012;**93**:2007-2016

[20] Miyamura H, Kanazawa H, Hayashi J, Eguchi S. Thrombosed St. Jude valve prosthesis on the right side of the heart in patients with tetralogy of Fallot. *The Journal of Thoracic and Cardiovascular Surgery*. 1987;**94**:148-150

[21] Kawachi Y, Masuda M, Tominaga R, Tokunaga K. Comparative study between St. Jude Medical and bioprosthetic valves in the right side of the heart. *Japanese Circulation Journal*. 1991;**55**:553-562

[22] Haas F, Schreiber C, Horer J, Kostolny M, Holper K, Lange R. Is there a role for mechanical valved conduits in the pulmonary position? *The Annals of Thoracic Surgery*. 2005;**79**:1662-1668

[23] Freling HG, Ymkje JVS, van Melle JP, Ebels T, Hoendermis E, Berger R, et al. Pulmonary valve replacement: Twenty-six years of experience with mechanical valvar prostheses. *The Annals of Thoracic Surgery*. 2015;**99**:905-910

[24] Dunne B, Xiao A, Litton E, Andrews D. Mechanical prostheses for right ventricular outflow tract reconstruction: A systematic review and meta-analysis. *The Annals of Thoracic Surgery*. 2015;**99**:1841-1847