Chapter

Accuracy and Efficacy of Ultrasound-Guided Pes Anserinus Bursa Injection

Jong Hwa Lee, Jae Uk Lee and Seung Wan Yoo

Abstract

The term "pes anserinus tendinobursitis (PATB)" is generally used to describe the inflammatory condition of pes anserinus bursa (PAB). Ultrasound (US) is widely used as a diagnostic and therapeutic tool to improve the assessment and management of joints and soft tissues. We performed the study to prove the accuracy and efficacy of US-guided injections in patients with PATB by comparing blind interventions. Forty-seven patients were randomly assigned to an US-guided and a blind injection group. The patients in the US-guided group were given injections under sonographic visualization. Otherwise, in the blind group, injections were provided in the conventional technique without any sonographic guidance. After the management, the accuracy of the injections was assessed by identifying the injectate location using the US. Treatment efficacy was evaluated using the visual analog scale (VAS) of knee tenderness. The US-guided group showed that the injectates were located at the PAB accurately in all participants, whereas the blind group revealed that the materials were found to be at the bursa side only in 4 out of 22 patients. VAS scores of the US-guided group significantly improved compared to the blind group. In conclusion, US-guided PAB injections are more accurate and efficacious than blind approaches.

Keywords: pes anserinus tendinobursitis, bursa injection, ultrasound

1. Introduction

The pes anserinus (PA), which means "Goose foot" in Latin, consists of the conjoined tendon of the sartorius, gracilis, and semitendinosus muscles. It inserts into the proximal anteromedial aspect of the tibia approximately 5 cm distal to the medial tibial joint line. Biomechanically, it provides secondary restraint against valgus forces of the knee joint [1–4]. The PA bursa (PAB) is located deep to the PA tendon and serves to reduce friction between three tendons and the deep structures including the tibia and the medial collateral ligament (MCL). Commonly, it does not communicate with the knee joint space [3].

The first description of the region in literature dates back to 1937. Moschcowitz described knee pain almost exclusively in women who complained of pain when going downstairs or upstairs, or had difficulty in getting up from a chair, or flexing their knees [5]. PA bursitis or tendinitis, or also called PA tendinobursitis (PATB), is usually used to describe the inflammatory condition of the PAB mainly caused by

repetitive friction over the bursa or by direct trauma. It can be observed in patients with rheumatoid arthritis, osteoarthritis (OA), and diabetes mellitus. The risk increases in people who are obese or have valgus knee deformity [6–8]. PATB is clinically common in obese female OA patients. The distinction between PA bursitis and tendinitis is difficult because of the proximity of the structures. In addition, its pathology remains unknown and is still controversial. However, the treatment strategy is similar for those conditions [9].

The exact prevalence of PATB is unknown. It has been reported at a wide range of levels, between 2.5 and 70% [10]. Frequently, the incidence tended to be underestimated due to difficulty in diagnosis. In a retrospective review of 509 knee MRIs obtained on 488 patients with suspected "internal derangement" at an orthopedic outpatient clinic, a 2.5% prevalence of PATB was detected [11]. Sometimes, fluid collection in semimembranosus bursa, around the collateral ligament, or meniscal cyst can make the differential diagnosis difficult. Therefore, it was suggested that fluid collection in the PA bursa accompanied by clinical symptoms such as pain in the medial side of the knee was helpful for diagnosis. In a prospective study, a total of 170 knees of 85 patients with OA were assessed with the US, and the incidence of PA bursitis was 20% [12]. They presented that PA bursitis was more common in women and at advanced ages and was observed in one of every symptomatic OA patient.

The clinical diagnosis of PATB is based on symptoms, including pain in the medial aspect of the knee when going downstairs or upstairs, morning pain and rigidity for more than 1 h, sensitivity to compression on the tendon insertion area, and occasional local edema [11]. Resolving the pain after a local anesthetic injection may also be helpful for diagnosis [12]. MRI can be useful in the diagnosis of PATB when swelling, fluid collection associated with the inflammatory process are observed as like most of the soft tissue pathologies. The exam can be a good method to detect and differentiate cystic lesion within and around the knee [13]. However, results of the image often do not allow to identify structures that are responsible for the symptoms of PATB.

2. Significance of US-guided injections

Many studies have researched the accuracy and efficacy of US-guided injections compared to blind (without a guide) techniques. Gilliland et al. [14] presented a systemic review about the efficacy of US-guided intra-articular and periarticular injection compared with anatomic standard injection using palpation/anatomic landmarks in the joints of the knee, shoulder, foot, ankle, wrist, and hand. They concluded that accuracy was improved with the use of US-guided injection and short-term outcome improvements were found in the US-guided groups. Berkoff et al. [15] reviewed the clinical utility of US-guided intra-articular knee injections in comparison with palpation-guided anatomical injections. The study suggested that US guidance significantly improved the accuracy of injection in the target joint space. The accuracy induced the improvement of clinical outcomes and cost-effectiveness.

PAB injection is usually performed by a blind method in actual clinical settings because the structure locates close to the superficial layer relative to the shoulder or knee joint. Therefore, it has not been sufficiently studied in relation to the ultrasound (US) guidance. Finnoff et al. [10] compared the accuracy of US-guided and unguided PAB injections in 24 cadaveric lower extremities specimens. The accuracy rate was 92% in the US-guided group and 17% in the unguided group. In spite of the superficial location, most unguided PAB injections failed to place the injectate within the bursa, while US-guided injection showed a high degree of accuracy. Because it was a study using cadavers, therapeutic efficacy in clinical conditions

could not be identified. The exact pathology of PATB is still not completely known, which has been studied for more than 80 years. Furthermore, the injection location to prove its effect has not been sufficiently investigated.

This study was conducted with the aim of assessing the accuracy of US-guided PAB injections and evaluating the clinical outcomes of the efficacy of injection by comparing them to blind injections. The study also examined whether the location of injectate could suggest the main source of pain.

3. Methods and materials

3.1 Participants

Patients who were clinically diagnosed with PATB were recruited. Symptoms were determined to include medial knee pain when going downstairs or upstairs, rigidity for more than 1 h, sensitivity to compression on the tendon insertion area, and occasional local edema. All participants were randomly assigned into two groups—the US-guided injection group and the blind injection group. The randomization and allocation sequences were generated by using Microsoft Excel. Seven patients were dropped out to follow-up, and a total of 47 patients were finally analyzed (**Figure 1**). Patients who had knee OA (grade I–III Kellgren-Lawrence), pain in the medial aspect of the knee, and symptoms lasting for at least 3 months were included. These patients presented maximal tenderness over the PAB, not on the joint line or around the patella bone. The exclusion criteria were history of traumatic injury or mechanical derangement, surgical intervention, systemic inflammatory disorders, concomitant severe rheumatic disease, microcrystalline arthropathy, or fibromyalgia.

The study was carried out with permission from the institutional review board of our hospital. Informed consent was obtained from each subject for study participation, according to the ethical guidelines of the hospital after the subject fully understood the study's purpose and methodology.

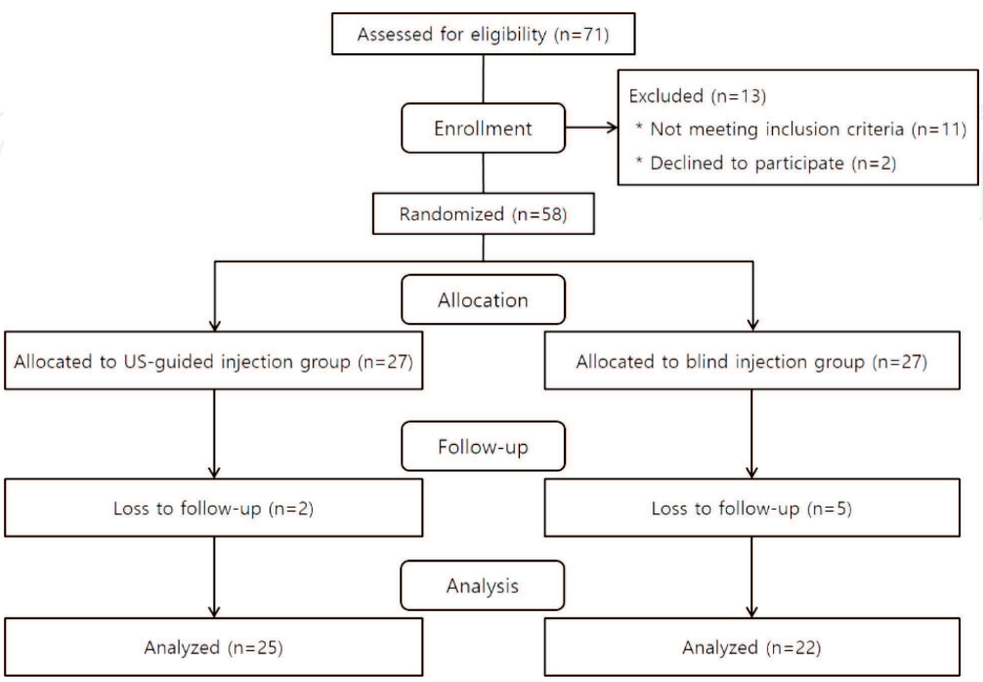

Figure 1.
Study flowchart.

3.2 US-guided injection technique

All sonographic examinations and injections were performed by one expert physician with over 10 years of experience in the musculoskeletal US and managing knee OA. In the preparation, the subjects were placed in the supine position with the knee flexed 5-10 degrees. After marking the PAB area, the skin was prepped with the usual products. US assessment was performed on the medial part of the knee using a linear array probe with a 6–12-MHz frequency and penetration depths of 2.5–4 cm. The needle was inserted at the point where the PA crossed over the anterior fibers of the MCL. The transducer was positioned in a longitudinal orientation relative to the anterior fibers of the MCL, with an oblique transverse orientation relative to the PA. Under US guidance, a 25-gauge 38-mm needle was inserted through the skin proximal to the transducer in a longitudinal plane. Continuously advanced in the distal direction and introduced the needle tip into the tissue space between the PA and the MCL. When the needle tip was visualized between the middle of the PA and the MCL, the materials were injected under direct sonographic visualization (**Figures 2** and **3**).

3.3 Blind injection technique

The same physician who carried out US-guided injections provided the blind injections. The blind injection was performed in a similar technique to the method described previously [16]. The subjects were placed in the supine position, with the slightly flexed knee as like for the US-guided methods; palpated the point of maximal tenderness and marked it; prepped the skin using a usual product; inserted the 25-gauge 38-mm needle to the skin perpendicularly into the maximal tender point until touching the bone gently. After that, the needle of 2–3 mm is withdrawn to avoid injecting into the conjoined tendon directly; the materials are injected into the syringe, which should easily flow.

3.4 Injection material

The injection material was a mixture of 20 mg of triamcinolone acetonide and 1 mL of 1% lidocaine. It was injected at the maximal tender point in the PAB area

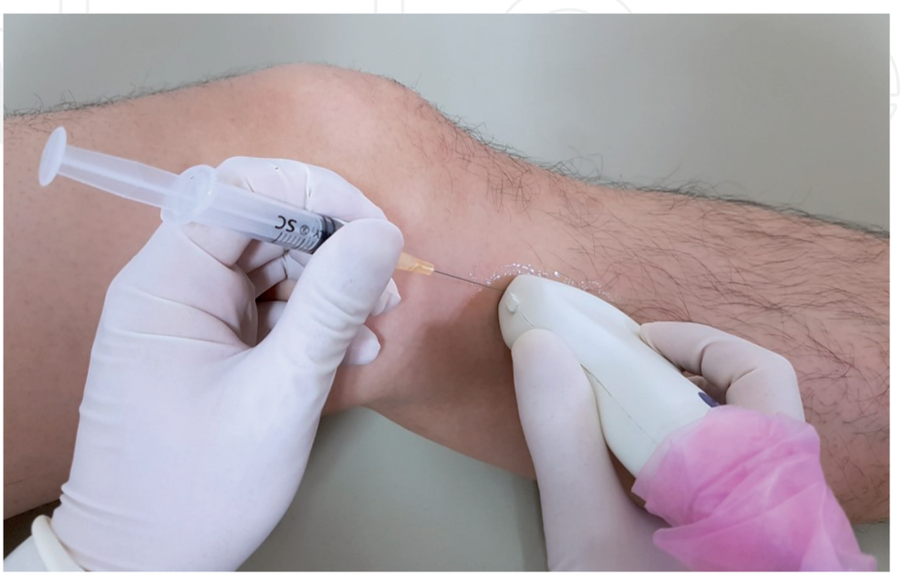

Figure 2.
US-guided injection, the transducer was positioned in a longitudinal orientation relative to the anterior fibers of the medial collateral ligament, with an oblique transverse orientation relative to the pes anserinus.

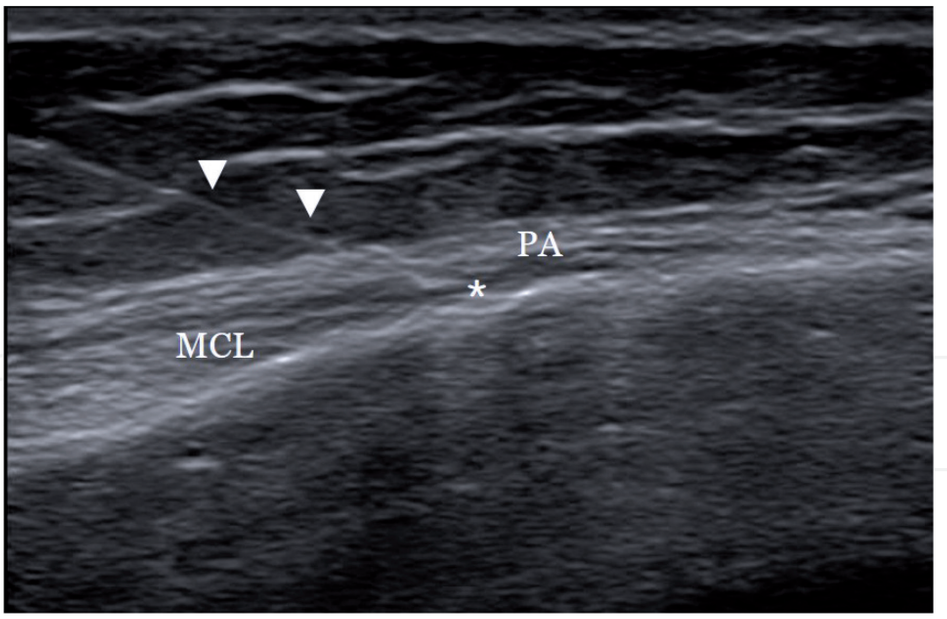

Figure 3.
US-guided injection, longitudinal ultrasound image of a needle (arrowhead) in the pes anserinus bursa (asterisk) between the medial collateral ligament (MCL) and the pes anserinus (PA) tendon.

under US guidance and blind method each. After the PA injections, to identify the location of the material, sonographic scanning was performed in both groups.

3.5 Assessment

After the management, the accuracy of the injections was assessed by identifying the injectate location using the US. The injectate location was evaluated by a second operator who was unaware of the previous procedure with more than 8 years of musculoskeletal US experience in diagnosis and management.

Treatment efficacy to the injection was assessed with a pain visual analog scale (VAS) of knee tenderness. The patients were asked to check the degree of pain intensity ranging from 0 (the absence of pain) to 10 (the worst pain ever). Because all the participants in this study had degenerative arthritis of the knees, it was important to distinguish between articular pain and bursal pain. If the patients described it as simply knee pain, the distinction could be confusing. Therefore, the VAS scores were measured while the constant force was applied to the tender point of PA by an examiner with a pressure algometer (FPK-5®Wagner Instruments, USA). This measurement was performed before 1 week and 4 weeks after the injection.

We did not provide any drugs which had the analgesic effect, including non-steroidal anti-inflammatory drugs that could mask the pain symptoms of the participants. All patients were informed about discomforts after injection. To avoid possible tendon tear or rupture, the patients were advised to rest for at least 2–3 days with the application of ice 3 times every day. Also, they were taught not to do jumping, squatting, kneeling, and bending of the knee for 3 weeks. About 4 weeks after the procedures, complications that had occurred were assessed by individual interviews.

The data were analyzed by using Windows SPSS 18.0 software. To evaluate the outcome measurements before and after treatment in each group, the Wilcoxon signed-rank test was used. Statistical processing was conducted with the Mann-Whitney *U* test for comparison between the two groups. A statistical significance level was set at $p < 0.05$.

4. Results

Forty-seven patients diagnosed with PATB and knee OA were finally recruited. The US-guided injection group included 25 patients with a mean age of 65.36 ± 7.12 years (two men and 23 women). The blind injection group included 22 patients with a mean age of 63.40 ± 6.20 years (two men and 20 women). There were no significant differences in general characteristics including knee OA K-L grade, and baseline VAS scores between the two groups (**Table 1**).

In the US-guided injection group, changes of the VAS for PA tenderness showed that pain reduced significantly from 6.82 ± 1.45 at baseline to 2.28 ± 1.08 1 week after the injection and 3.27 ± 0.94 4 weeks after the injection ($p < 0.05$) (**Table 2**). In the blind injection group, changes of the VAS also revealed that pain reduced statistically from 6.45 ± 1.12 at baseline to 3.95 ± 1.23 1 week after the injection and 4.60 ± 0.95 4 weeks after the injection ($p < 0.05$) (**Table 2**).

Table 3 shows the comparison between the two groups in changes of the VAS score for PA tenderness. The US-guided injection group showed that pain reduced significantly greater than the blind group with regard to ΔVAS scores at 1 week after injection (4.54 ± 0.98 vs. 2.50 ± 1.03) and 4 weeks after injection (3.55 ± 1.14 vs. 1.85 ± 0.84).

After the PAB injections, the injectates were found to be accurate in the PAB, between the PA tendon and the tibia or the MCL, in all 25 subjects in the US-guided injection group (**Figure 4**). On the other hand, in the blind injection group the materials were found to be located in the PAB in only four of 22 subjects, deep to the MCL in two, and superficial to the PA tendon in 16 patients (**Figure 5**). Most injectates were administered outside the PA bursa.

	US-guided group	Blind group	p value
Age (year)	65.36 ± 7.12	63.40 ± 6.20	0.412
Sex (male/female)	2/23	2/20	
Right/left	11/14	12/10	
Knee OA duration (year)	7.21 ± 6.33	6.35 ± 6.24	0.137
Knee OA K-L grade	2.20 ± 0.56	2.15 ± 0.57	0.652
Baseline pain score			
VAS (knee pain)	5.24 ± 1.20	4.80 ± 1.45	0.255
VAS (PA tenderness)	6.82 ± 1.45	6.45 ± 1.12	0.320

Values are presented as mean ± standard deviation.
US = ultrasound; OA = osteoarthritis; K-L grade = Kellgren-Lawrence grade; VAS = visual analog scale; PA = pes anserinus.

Table 1.
Baseline characteristics of both groups.

VAS	US-guided group	Blind group
Baseline	6.82 ± 1.45	6.45 ± 1.12
1 week after injection	2.28 ± 1.08*	3.95 ± 1.23*
4 weeks after injection	3.27 ± 0.94*	4.60 ± 0.95*

Values are presented as mean ± standard deviation.
VAS = visual analog scale; PA = pes anserinus; US = ultrasound.
**p < 0.05 by Wilcoxon signed-rank test.*

Table 2.
Changes of VAS of PA tenderness comparing baseline.

Intra-tendon injection was not performed on any of the participants in either group. Complications were not reported after the intervention in both groups.

	US-guided group	Blind group	p value
ΔVAS			
1 week after injection	4.54 ± 0.98	2.50 ± 1.03	0.000*
4 weeks after injection	3.55 ± 1.14	1.85 ± 0.84	0.003*

Values are presented as mean ± standard deviation.
VAS = visual analog scale; US = ultrasound.
**p < 0.05 by Mann-Whitney U test.*

Table 3.
Changes of VAS of PA tenderness between two groups.

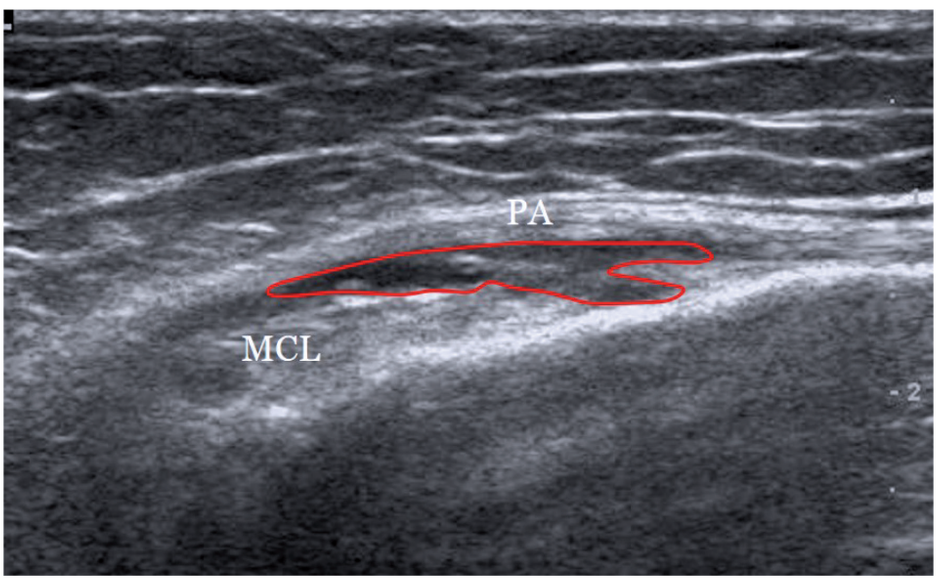

Figure 4.
Ultrasound image of the injectate location after injection; intra-pes anserinus bursa area.

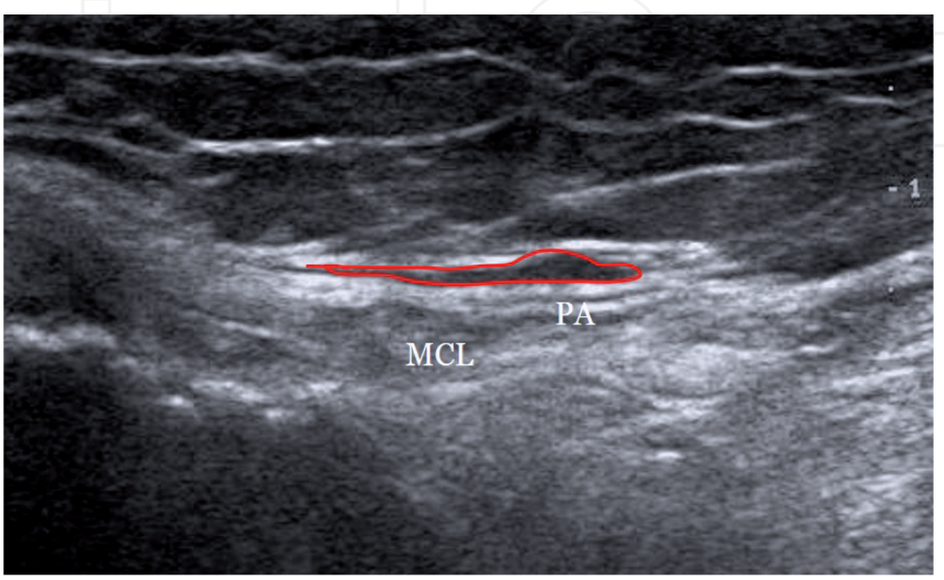

Figure 5.
Ultrasound image of the injectate location after injection; extra-pes anserinus bursa area, the injection was superficial to the tendon.

5. Discussion

The US is widely used for diagnosis and treatment in musculoskeletal fields. There have been several studies representing US features of PA tendon or PAB in patients with PATB. Some studies reported that the US is limited in detecting PATB, while others concluded that it can be helpful. Uson et al. [17] assessed the US findings of the PA and the subcutaneous fat of medial knee in clinically diagnosed PATB patients. The diagnostic findings were the thickness of the insertion of the tendons, the presence of fluid collection greater than 2 mm in the bursa, and changes in the subcutaneous fat of the medial aspect of the knee. For a total of 37 participants, PA tendinitis was diagnosed in just one knee and PA bursitis in three knees (two symptomatic and one asymptomatic). From the results, they concluded that it was difficult to detect US findings of PA tendinitis or bursitis in patients diagnosed with PATB syndrome. Unlu et al. [18] examined US evidence of PA tendinitis or bursitis in patients with type 2 diabetes mellitus. Only 8.3% of 48 patients were found to have PA tendinitis findings in the US. Although PA tendinitis or bursitis syndrome is not uncommon in patients with diabetes mellitus, there might be less frequent morphologic US changes of the PA tendons. Yoon et al. [2] prospectively studied the correlation between US findings and response to steroid injection in 26 patients with clinically diagnosed PATB syndrome. Only two patients (8.7%) showed sonographic evidence of PATB. One patient with PA tendinitis showed thickening and loss of normal fibrillar echotexture. The other who had bursitis revealed circumscribed anechoic fluid collection of 2 mm or greater.

Uysal et al. [12] evaluated the prevalence of PA bursitis in OA patients. A total of 170 knees from 85 patients with knee OA were assessed, and 20% (34/170) of the knees showed PA bursitis in US examinations. They suggested that PA bursitis was easily found in the US, and there was a positive correlation between OA grade and PAB size and area. Toktas et al. [19] studied the US findings of PA tendon and bursa in 183 clinically diagnosed PATB among the 314 knees with OA. The results showed that the mean thickness of PA in knees with OA with/without PATB was significantly greater than the controls. US could be a useful diagnostic tool for detecting PATB syndrome in knee OA patients.

The term PATB is generally used to describe the inflammatory condition of PAB; however, the structure associated with symptoms is still not identified. After the intervention in our study, all injectates (25 of 25 subjects) were located accurately in the PAB in the US-guided injection group, whereas just 18% (4 of 22 subjects) were properly located in the blind injection group. The US-guided group revealed greater pain reduction significantly than the blind group. This suggests that the pain might be arisen from the bursa, so a diagnosis of tendinobursitis is more suitable for this condition.

As previous studies have shown, US-guided injections are more accurate than blind injections. Various reviews have recently been reported on the clinical utility of US-guided injections in locations such as shoulder girdles, hip joints, and knee joints. A systematic review of US-guided shoulder girdle injections reviewed four cadaveric studies and nine human studies, and concluded that US-guided injections had greater accuracy for all types of shoulder injections than landmark-guided injections, except subacromial injection. The efficacy for the subacromial and biceps tendon sheath injections was improved [20]. Another systematic review of US-guided hip joint injections showed the improvement of accuracy. They reviewed four US-guided and five landmark-guided studies, and suggested that US-guided hip injections were significantly more accurate than landmark-guided techniques [21].

A review of US-guided intra-articular knee injections revealed that US-guided injections notably improved accuracy in the intra-articular joint injections than conventional palpation-guided injections by analyzing a total of 13 previous studies. US guidance also directly improved patient-reported clinical outcomes and cost-effectiveness [15].

PAB injection is usually performed by blind technique in actual clinical settings because PA is located closer to the superficial layer compared to other deep joints. Acromioclavicular joint (AC) is also located superficially, and blind injection is often performed through palpation. Nevertheless, a previous study has shown that the use of US in the AC joint injection is more accurate and effective [22]. They concluded that US-guided AC joint articular injection resulted in better pain and functional status improvement than palpation-guided injection at the 6-month follow-up. Therefore, even in the superficial structures, US-guided injection is recommended for accurate treatment.

For this reason, although the effectiveness of US examination in the PATB diagnosis is controversial, the value of US-guided injection treatment is sufficiently recognized for its accuracy. Overall, the accuracy of blind injections is 40–80%, while that of US-guided injections is approximately 90–100%. In most of these injections, the improved accuracy achieved by US guidance directly enhances clinical outcomes.

Consistent with previous studies, this research observed that US-guided injection was more accurate than the blind injection, and intra-bursal injection had a better clinical result in the treatment of PATB. Although the standardized US-guided injection technique has not yet been established, longitudinal access to the tibia would be appropriate to administer materials. Anatomically, the transducer is positioned in a longitudinal orientation relative to the MCL, oblique transverse access relative to the PA. While monitoring the image, insert the needle through the skin proximal to the transducer and advance in a proximal to the distal direction in a longitudinal plane. According to the physician's preference, a needle can approach the distal to the transducer and advance in the proximal direction in a longitudinal plane. The target of the injection is the space beneath the PA tendon. When the needle tip is visualized in the target space, inject the materials slowly and carefully, since the space is relatively narrow.

The PAB corticosteroid injections are contraindicated in patients with systemic infection states (sepsis, bacteremia, etc.), joint infection (septic arthritis, cellulitis, osteomyelitis, etc.), fracture, osteoporosis, coagulopathy, skin defect, hypersensitivity to the steroid, uncontrolled hyperglycemia; also, some complications such as bleeding, bruising, swelling, infection, post-injection pain (steroid flare), face flushing, skin depigmentation, cutaneous atrophy can occur [23].

There were several limitations of our study. Because of the short-term follow-up period, the long-term clinical effects could not be determined. The morphologic US features of the anserine bursa or tendon were not examined that might help to identify the source of pain in PATB. In addition, potential differences caused by activity levels were not considered even if they had a potential impact on the results of the study.

6. Conclusion

Both US-guided and blind injections significantly reduced pain levels in patients with PATB. In the US-guided injection group, the accuracy was higher than in the blind injection group. Clinical results were more affected in the US group.

All injectates were located in the PAB after the US-guided injections, while only in some cases of the blind approaches, injectates were located in the PAB. This suggests that the optimal source of pain might be associated with the bursa.

Conflict of interest

The authors declare no conflict of interest.

Author details

Jong Hwa Lee*, Jae Uk Lee and Seung Wan Yoo
Department of Physical Medicine and Rehabilitation, Dong-A University College of Medicine, Busan, Republic of Korea

*Address all correspondence to: jhlee08@dau.ac.kr

References

[1] Helfenstein M Jr, Kuromoto J. Anserine syndrome. Revista Brasileira de Reumatologia. 2010;**50**:313-327

[2] Yoon HS, Kim SE, Suh YR, Seo YI, Kim HA. Correlation between ultrasonographic findings and the response to corticosteroid injection in pes anserinus tendinobursitis syndrome in knee osteoarthritis patients. Journal of Korean Medical Science. 2005;**20**:109-112. DOI: 10.3346/jkms.2005.20.1.109

[3] Marra MD, Crema MD, Chung M, Roemer FW, Hunter DJ, Zaim S, et al. MRI features of cystic lesions around the knee. The Knee. 2008;**15**:423-438. DOI: 10.1016/j.knee.2008.04.009

[4] Handy JR. Anserine bursitis: A brief review. Southern Medical Journal. 1997;**90**:376-377. DOI: 097/00007611-199704000-00002

[5] Moschcowitz E. Bursitis of sartorius bursa, an undescribed malady simulating chronic arthritis. Journal of the American Medical Association. 1937;**109**:1362-1366. DOI: 10.1001/jama.1937.92780430001009

[6] Kang I, Han SW. Anserine bursitis in patients with osteoarthritis of the knee. Southern Medical Journal. 2000;**93**: 207-209

[7] Brookler MI, Mongan ES. Anserine bursitis, a treatable cause of knee pain in patients with degenerative arthritis. California Medicine. 1973;**119**:8-10

[8] Cohen SE, Mahul O, Meir R, et al. Anserine bursitis and noninsulin dependent diabetes mellitus. The Journal of Rheumatology. 1997;**24**: 2162-2165

[9] Klippel JH. Primer on the Rheumatic Diseases. Musculoskeletal Signs and Symptoms—Regional Rheumatic Pain Syndromes— Disorders of the Knee Region. 12th ed. Arthritis Foundation, New York: Springer; 2001. p. 182. DOI: 10.1007/978-0-387-68566-3

[10] Finnoff JT, Nutz DJ, Henning PT, Hollman JH, Smith j. Accuracy of ultrasound-guided versus unguided pes anserinus bursa injections. PM & R: The Journal of Injury, Function, and Rehabilitation. 2010;**2**:732-739. DOI: 10.1016/j.pmrj.2010.03.014

[11] Rennie WJ, Saifuddin A. Pes anserine bursitis: Incidence in symptomatic knees and clinical presentation. Skeletal Radiology. 2005;**34**:395-398. DOI: 10.1007/s00256-005-0918-7

[12] Uysal F, Akbal A, Gökmen F, Adam G, Reşorlu M. Prevalence of pes anserine bursitis in symptomatic osteoarthritis patients: An ultrasonographic prospective study. Clinical Rheumatology. 2015;**34**:529-533. DOI: 10.1007/s10067-014-2653-8

[13] Koh WL, Kwek JW, Quek ST, Peh WCG. Clinics in diagnostic imaging. Singapore Medical Journal. 2002;**43**: 485-491

[14] Gilliland CA, Salazar LD, Borchers JR. Ultrasound versus anatomic guidance for intra-articular and periarticular injection: A systematic review. The Physician and Sportsmedicine. 2011;**39**:121-131. DOI: 10.3810/psm.2011.09.1928

[15] Berkoff DJ, Miller LE, Block JE. Clinical utility of ultrasound guidance for intra-articular knee injections: A review. Clinical Interventions in Aging. 2012;**7**:89-95. DOI: 10.2147/CIA.S29265

[16] Brock G, Gurekas V. The occasional pes anserinus bursitis injection. Canadian Journal of Rural Medicine. 2014;**19**:71-73

[17] Uson J, Aguado P, Bernad M, Mayordomo L, Naredo E, Balsa A, et al. Pes anserinus tendino-bursitis: What are we talking about? Scandinavian Journal of Rheumatology. 2000;**29**:184-186. DOI: 10.1080/030097400750002076

[18] Unlu Z, Ozmen B, Tarhan S, Boyvoda S, Goktan C. Ultrasonographic evaluation of pes anserinus tendino-bursitis in patients with type 2 diabetes mellitus. The Journal of Rheumatology. 2003;**30**:352-354

[19] Toktas H, Dundar U, Adar S, Solak O, Ulasil AM. Ultrasonographic assessment of pes anserinus tendon and pes anserinus tendinitis bursitis syndrome in patients with knee osteoarthritis. Modern Rheumatology. 2015;**25**:128-133. DOI: 10.3109/14397595.2014.931909

[20] Aly AR, Rajasekaran S, Ashworth N. Ultrasound-guided shoulder girdle injections are more accurate and more effective than landmark-guided injections: A systematic review and meta-analysis. British Journal of Sports Medicine. 2015;**49**:1042-1049. DOI: 10.1136/bjsports-2014-093573

[21] Hoeber S, Aly AR, Ashworth N, Rajasekaran S. Ultrasound-guided hip joint injections are more accurate than landmark-guided injections: A systematic review and meta-analysis. British Journal of Sports Medicine. 2016;**50**:392-396. DOI: 10.1136/bjsports-2014-094570

[22] Park KD, Kim TK, Lee J, Lee WY, Ahn JK, Park Y. Palpation versus ultrasound-guided acromioclavicular joint intra-articular corticosteroid injections: A retrospective comparative clinical study. Pain Physician. 2015;**18**:333-341

[23] Simurina T, Mraovic B, Zupcic M, Zupcic SG, Vulin M. Local anesthetics and steroids: Contraindications and complications-clinical update. Acta Clinica Croatica. 2019;**58**:53-61