

We are IntechOpen, the world's leading publisher of Open Access books Built by scientists, for scientists

6,900

Open access books available

186,000

International authors and editors

200M

Downloads

Our authors are among the

154

Countries delivered to

TOP 1%

most cited scientists

12.2%

Contributors from top 500 universities



WEB OF SCIENCE™

Selection of our books indexed in the Book Citation Index
in Web of Science™ Core Collection (BKCI)

Interested in publishing with us?
Contact book.department@intechopen.com

Numbers displayed above are based on latest data collected.
For more information visit www.intechopen.com



Surgical Digitally Guided Planning for the Mini-Screw Assisted Rapid Palatal Expansion (MARPE) and Suture Perforation: MARPE Guide

*Cristiane Barros André, Bruno de Paula Machado Pasqua,
José Rino Neto and Fábio Dupart Nascimento*

Abstract

The surgical planning digitally guided for the mini-screw assisted rapid palatal expansion (MARPE) technique consists of a three-dimensional positioning of MARPE and its mini-implants by a nasomaxillary anatomic evaluation. This technique also includes the simulation of the perforation areas on the midpalatal and transpalatal sutures. This type of planning is performed by superimposing the patients' files (STL and DICOM). Correct positioning without colliding with the lateral tissues of the palate and the bicortical positioning of each mini-implant are important components of the case study. The MARPE device permits individualization of the height of the mini-implant rings in each region. To avoid incorrect insertion of the drill, the location of the midpalatal and transpalatal sutures was determined using digital planning. A positioning that avoids contact with important structures, such as the nasopalatine canal, while permitting bicortical drilling of the sutures is recommended. Then, a guide that reproduces MARPE positioning and another guide that reproduces the perforations are fabricated, providing exact reproducibility as performed virtually.

Keywords: orthodontic anchorage procedures, palatal expansion technique, skeletal anchorage, cone-beam computed tomography

1. Introduction

The mini-screw assisted rapid palatal expansion (MARPE) technique comprises rapid maxillary expansion (RME) in adult patients using a mini-implant-supported device, permitting orthopedic expansion with few side effects [1–3]. This procedure is well accepted by patients owing to its low cost and less invasiveness compared to surgically assisted RME [4].

To perform the MARPE technique, cone-beam computed tomography (CBCT) is essential as it allows a complete anatomical evaluation of the nasomaxillary complex

region where the expander screw and mini-implants are placed [5]. Moreover, by assessing bone thickness from CBCT images, the amount of bicortical mini-implant thread insertion can be measured [6]. This is critical as the bicortical positioning of mini-implants permits wider distribution of expansion forces, avoiding the concentration of stress areas around the mini-implants, providing better skeletal effects [7, 8].

Therefore, an evaluation protocol using CBCT [9] was introduced to select the ideal region for the mini-implants. However, this technique does not consider all anatomical variations in each patient, and the lack of a guide that reproduces this planning in the patient's oral cavity is a matter of concern. Thus, André [6] described a technique that performs a careful evaluation of important anatomical structures, such as nasal septum deviation, maxillary sinus extension, the sinuosity of the sutures evaluated, and location of the incisive foramen and transpalatal suture. Although the planning is more comprehensive, there is still a lack of guidance for reproducibility in the oral cavity.

With the advent of digital flow technology, a new technique was introduced, not only for planning, but also to reproduce the virtual placement of the entire appliance, providing accuracy, reproducibility, and safety to the MARPE technique. This technique, called MARPE Guide, consists of a three-dimensional digital placement, which comprises the positioning of the mini-implants specific for MARPE, as well as the expander screw itself. To overcome the shortcomings of the previously described planning techniques, a guide is generated that reproduces this digital placement [5, 10–15].

By superimposing the intraoral digital scanning file (STL) and CBCT (DICOM), it is possible to choose the correct location accurately and safely for the placement of the mini-implants and expander screws. Additionally, the structures of the nasomaxillary complex in a three-dimensional form are individually evaluated (**Figure 1**). Thus, the

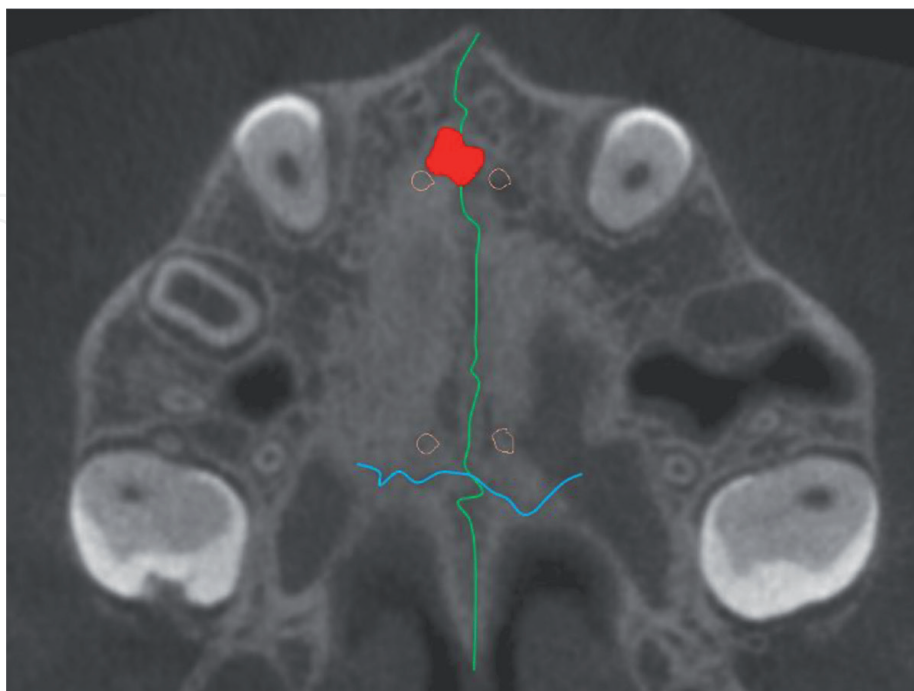


Figure 1.

The image of this case shows a MARPE complex positioning between the incisive foramen and transpalatal suture, not extending to the soft palate area. The midpalatal suture is observed in green, transpalatal suture is represented in blue, nasopalatine duct is visualized in red, and mini-implants are presented in orange.

chances of failure are reduced using the MARPE guide, as it is possible to select the size and amount of mini-implant thread insertion of each mini-implant. Moreover, it permits accurate prediction of the mini-implant trajectory. Even in the most complex cases of anatomical variations, injury to important anatomical structures is avoided. This increases the safety of the technique, as well as the chances of success. For patients with severe transverse maxillary deficiency, increased palatal depth, or severe asymmetry, the MARPE Guide is associated with a MAEPE model called MARPE EX, developed in 2017 by Peclab (Peclab®, Belo Horizonte, Brazil). This device has an individualized mini-implant ring height, which permits positioning of the MARPE complex without colliding with the lateral palatal soft tissues. Height adjustment is performed according to the anatomy of each patient's palate, even in severe cases of transverse deficiency and maxillary asymmetry [16]. Among the physical characteristics of MARPE EX, the increased distance between the anterior and posterior mini-implant rings is observed, in search of a larger support area for the mini-implants. Regarding the tension exerted by this device on the skull, less tension on the supporting teeth was observed, as well as a wider tension distribution over the entire lateral lamina of the pterygoid process [16].

However, in complex cases of varying thickness of the maxilla and cases of advanced maturation of the midpalatal suture, even with virtual planning, these cases are limited. The increased interdigitation of the midpalatal suture is a strong resistance during RME. Therefore, Suzuki et al. [17] proposed the performance of corticoperforations in the region of the midpalatal suture during RME, to reduce the resistance by weakening the midpalatal suture, relying on the phenomenon of regional acceleration (corticoperforations). Although it appears to be an effective method, it is not a precise procedure as drilling is performed based on the palatal raphe (soft tissue), which does not always coincide with the midpalatal suture itself. Therefore, the Corticoperforation Guide (Cortex guide) provides the most effective weakening of this suture, enabling guided drilling, performed precisely following its path, that may be sinuous, rectilinear, or curved. Another important and unmentioned factor is perforation along the transpalatal suture. Perforation in the more posterior region is of utmost importance, as the maxillary posterior region demonstrates greater resistance during RME [16, 18].

By adding this new technique of digital planning with the advantages of MARPE EX, treatments are anticipated to become safer, more accurate; thus, expanding the possibility of treatment for patients with severe transverse deficiency, maxillary asymmetry, and variations in the maxillary thickness. Thus, this book chapter proposes the presentation of the virtual MARPE placement as well as the guided corticoperforation technique (Cortex Guide).

2. Materials and methods

2.1 Anatomical evaluation and virtual placement

The analysis of the maturation of facial sutures is performed through the file in DICOM format. For the midpalatal suture, the analysis follows the method proposed by Angelieri et al. [19], where the operator must be calibrated to perform this technique with reproducibility [20]. This technique is critical as an auxiliary diagnostic method, as it provides information regarding the challenge and resistance during the separation of the midpalatal suture according to its maturation stage. Next, another

suture, the zygomaticomaxillary suture, involved in RME is classified (established by Angelieri et al. [21]). This evaluation is performed by accessing the sagittal and coronal sections of the CT scan, and the suture is evaluated in a stage from A to E, where A is the earliest stage of maturation and E is the most advanced stage. The pterygopalatine suture was also evaluated, although there is no consolidated classification in the literature. When it is in an advanced stage of maturation, this suture is quite homogeneous compared to neighboring bone tissues, which is alarming to orthodontists as it suggests greater resistance to RME. Next, the location and shape of the transpalatal suture are analyzed. It is ideal to perform virtual placement of the mini-implants anteriorly to this suture (**Figure 1**); however, in many cases, owing to the positioning of the incisive foramen and reduced anteroposterior dimension of the maxilla, the most anterior virtual placement is not always feasible [5] (**Figure 2**).

In addition to the maturation stage, it is critical to verify the shape and aspect of these sutures as they can be straight, sinuous, or curvilinear. This can occur both horizontally and vertically (observed in coronal and axial sections). This verification is of total importance to perform the virtual placement without touching the sutures (**Figure 3**).

After suture analysis, the three-dimensional files (STL and DICOM, **Figure 4**) were superimposed [10–15]. As described in the literature [5], both files should be of good quality because they provide essential information, such as hard and soft tissue thickness, anatomical variations, and location and trajectory of the mini-implants. Failure to take this information into account may lead to complications and failure of the MARPE technique.

This procedure can be performed in any software that accepts the superimposition of the STL and CBCT files and also permits the importation of mini-implants and the MARPE expander screw-in STL format. This combination allows a three-dimensional

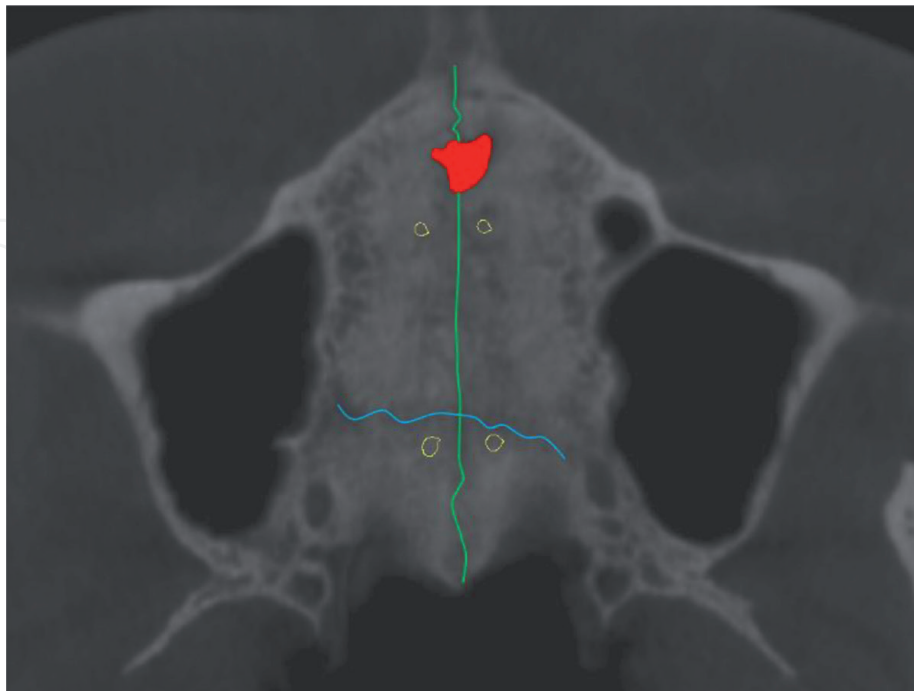


Figure 2.

In this case, the posterior mini-implants could not be placed anterior to the transpalatal suture due to the reduced sagittal size of the maxilla, and the variation in shape and size of the incisive foramen. The midpalatal suture is observed in green, the transpalatal suture is observed in blue, the nasopalatine duct is visualized in red, and mini-implants are presented in red.

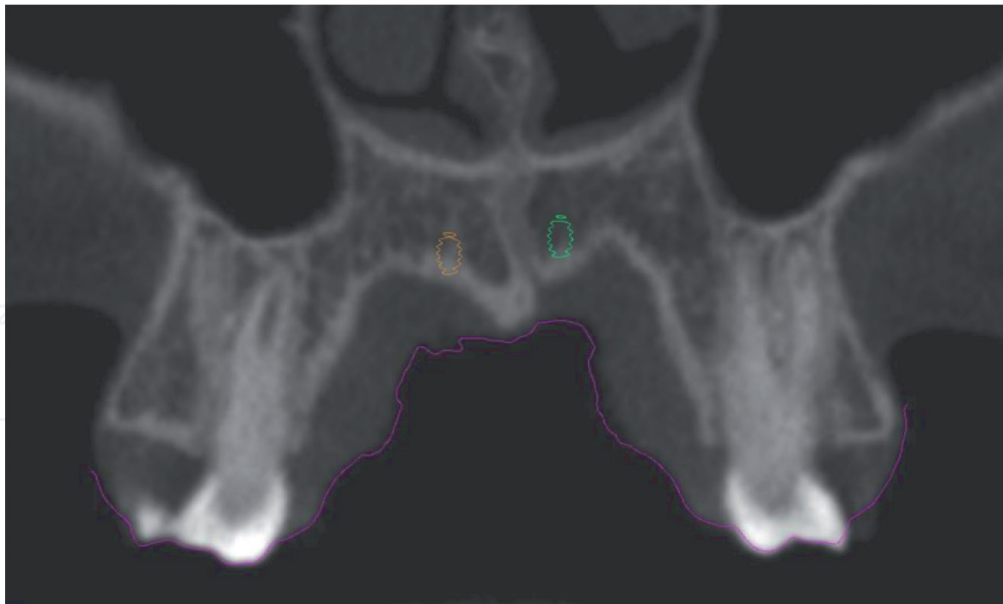


Figure 3.
Anterior mini-implants bordering a sinuous suture, without touching it.

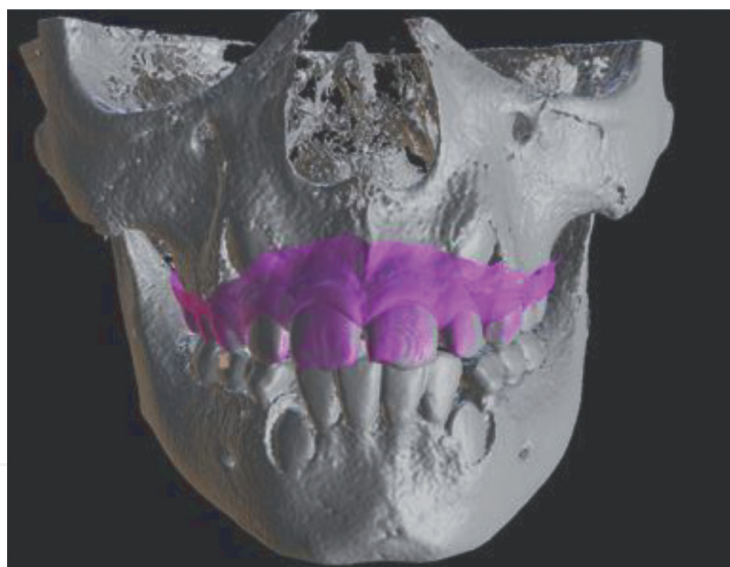


Figure 4.
Superimposition of the CBCT file (DICOM) and the digital file reproducing the teeth and the soft tissue of the upper dental arch (STL).

evaluation of the maxilla; therefore, the orthodontist can evaluate important aspects for the digital positioning of the MARPE device, as it permits simulation of the positioning in different regions.

The ideal region for the mini-implant insertion should contain sufficient bone to perform the expansion, advocating a bicortical positioning [7], as observed in **Figure 5A**. In cases of reduced bone thickness along the maxilla, it is currently feasible to add two more mini-implants to the device [22], as depicted in **Figure 5B**.

After the initial evaluation of the region with the most appropriate bone thickness, a complete anatomical evaluation is initiated, where the location of the midpalatal suture, transpalatal suture, and incisive foramen are first considered.

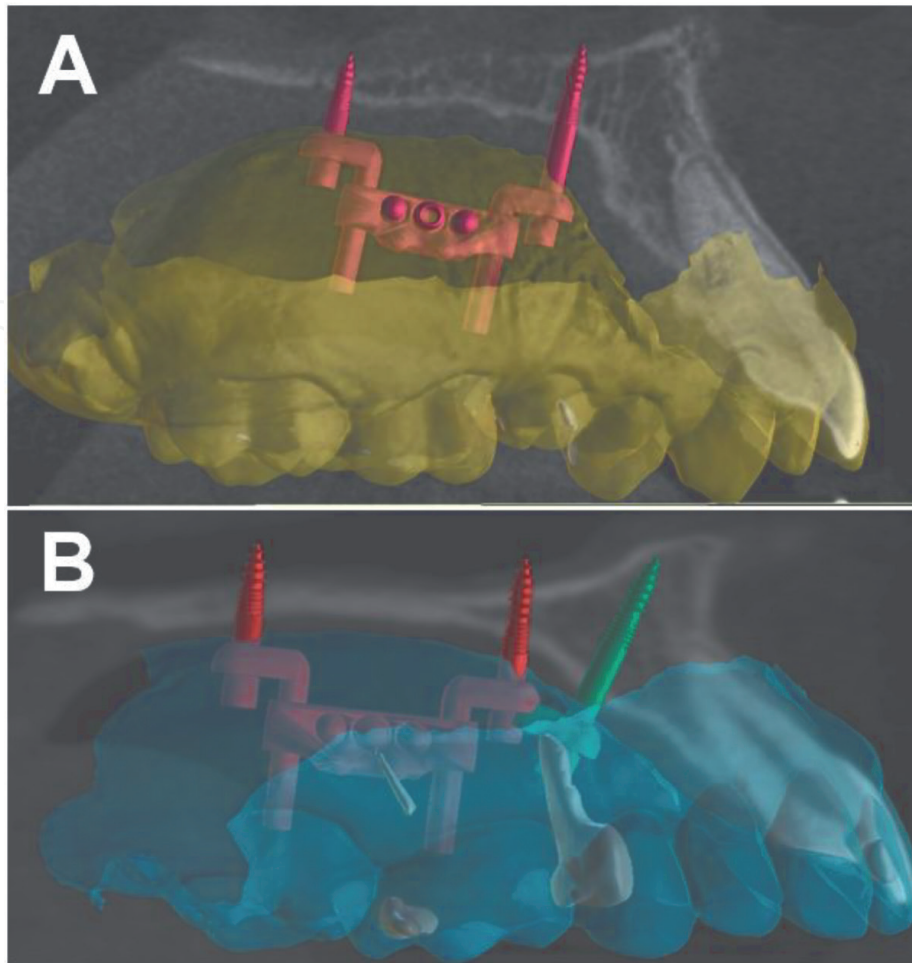


Figure 5. (A) Bicortical insertion of mini-implants in a patient with good bone thickness. (B) Reduced bone thickness along the entire maxilla, requiring the placement of two additional mini-implants.

These three anatomical components plus adequate bone thickness are the key factors for positioning the EX expander screw and the four or six mini-implants. However, it is critical to observe the distance of this complex from the lateral mucosa to maintain soft tissue integrity during RME.

Anatomical variations are common and must be thoroughly observed when planning the MARPE digital placement such as deviated septum (**Figure 6**), maxillary sinus extension (**Figure 7**), impacted teeth (**Figure 8**), maxillary torus (**Figure 9**), palate depth, and maxillary reduced shape and size (**Figure 7**). For patients with V-shaped palate in the anterior region the digital planning requires a posterior displacement of the appliance for the mini-implant support rings to be well adapted, bicortical, and have an adequate amount of excess mini-implant thread.

Digital placement with MARPE EX permits not only to individualize the height of the mini-implant rings in each region (respecting the anatomy of each individual and a safe distance from the mucosa) but also to measure and place different mini-implant lengths, always preconizing a bicortical positioning [2, 14]. This positioning is verified in each section of the tomography (**Figure 10**) and in the three-dimensional reconstruction.

For more complex cases, such as bone volume variation, advanced age and advanced skeletal maturation, guided corticoperforation is performed. This is done following the anatomy of the midpalatal suture and the transpalatal suture. In some

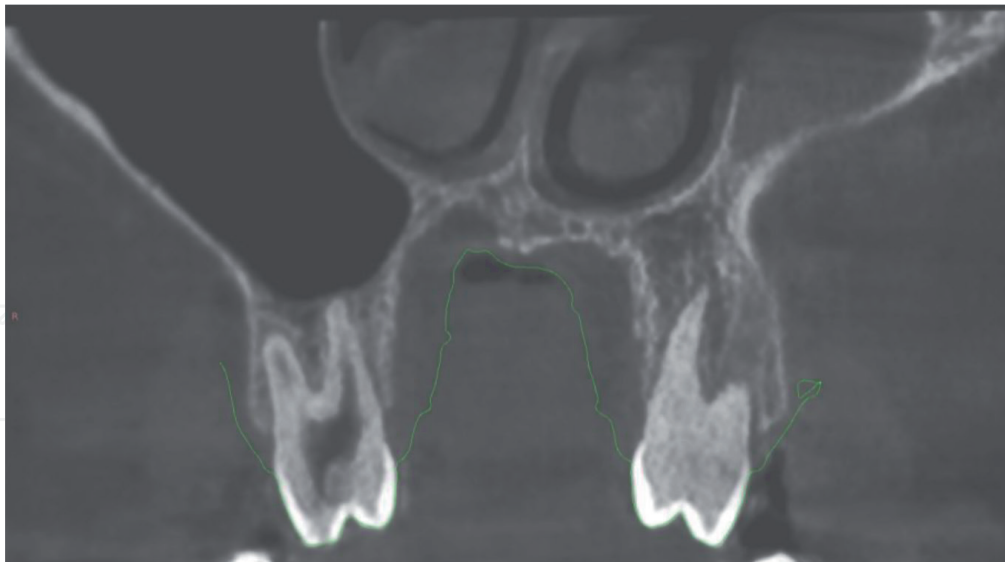


Figure 6.
Nasal septum deviation to the left side of the patient.

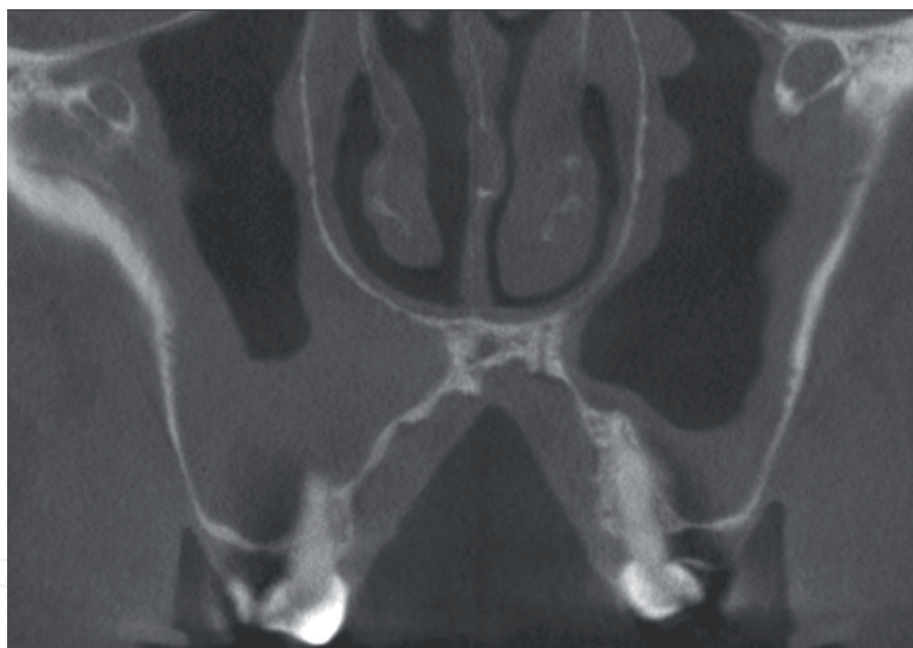


Figure 7.
Alveolar extension of the maxillary sinus and severe transverse deficiency of the maxilla.

patients, the midpalatal suture is inclined and/or sinuous in the coronal direction. We do not use the soft tissue (palatine raphe) as a reference to locate the midpalatal suture, because sometimes they are not coincident (**Figure 11**).

For the simulation of the drilling, we used digital files with a cylindrical format that reproduces the thickness of the widest portion of the drill used. These cylinders are positioned in such a way that they reach bicortical positioning and maintain a uniform distance between them when possible. Each perforation is analyzed in the three-dimensional simulation and checked in each tomography section to ensure that the perforations are bicortical and if there is no collision with important structures such as the nasopalatine duct.

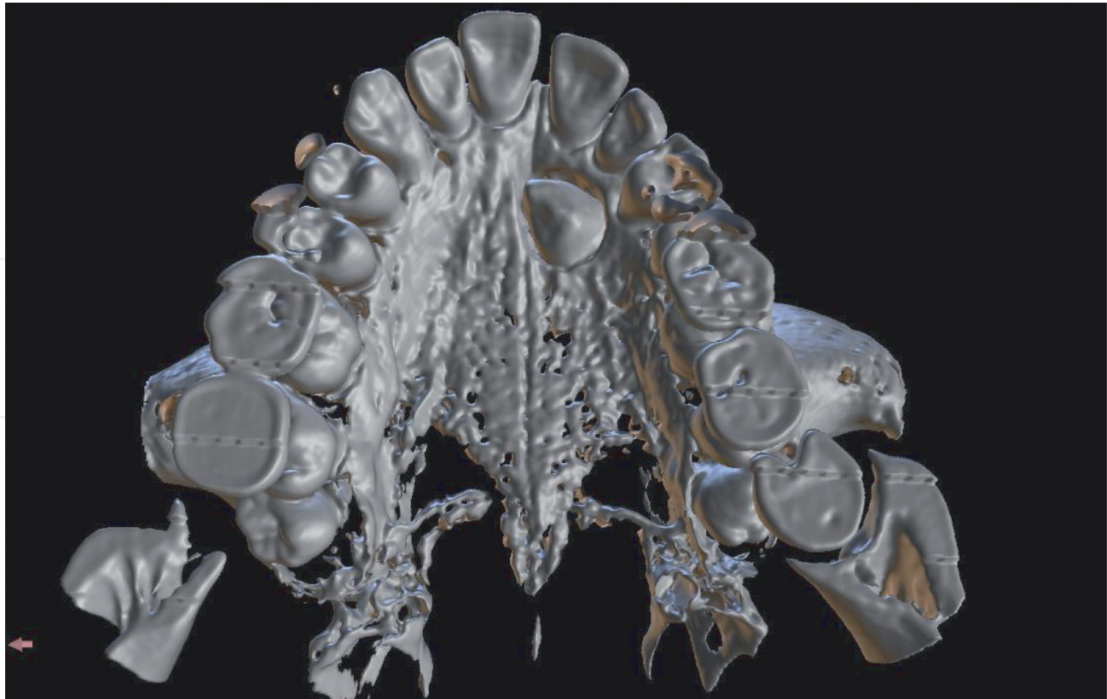


Figure 8.
Impacted tooth in the region near the anterior mini-implant installation placement site.

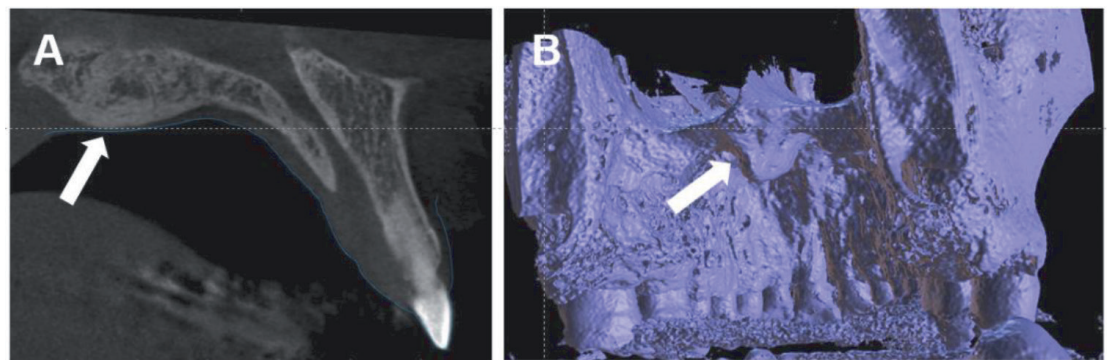


Figure 9.
(A) Sagittal section demonstrating the presence of the palatal torus. (B) Three-dimensional reconstruction of the maxilla illustrating the palatine torus.

When installing drills, we always recommend an inclination that can be performed in the mouth. In this way, we inclined the drills between 10° and 30° with respect to the occlusal plane. The drills are performed precisely following the direction of the suture, either rectilinear or sinuous (**Figure 12**).

It is advisable to maintain a safe distance between the corticoperforation and the region of the MARPE mini-implants as when trying to weaken the suture, we should not weaken the region surrounding the mini-implants, as the tension exerted in this region is high [16] and close perforations can weaken this region, which requires a large bone supply (**Figure 12C**). For this reason, MARPE Guide and Cortex Guide planning should be performed together (**Figure 13**).

After this careful process, it is time to create the guides, which will reproduce both the digital positioning in the prototyped model (MARPE Guide), providing reproducibility to the appliance manufacturing, exactly as done virtually, and the

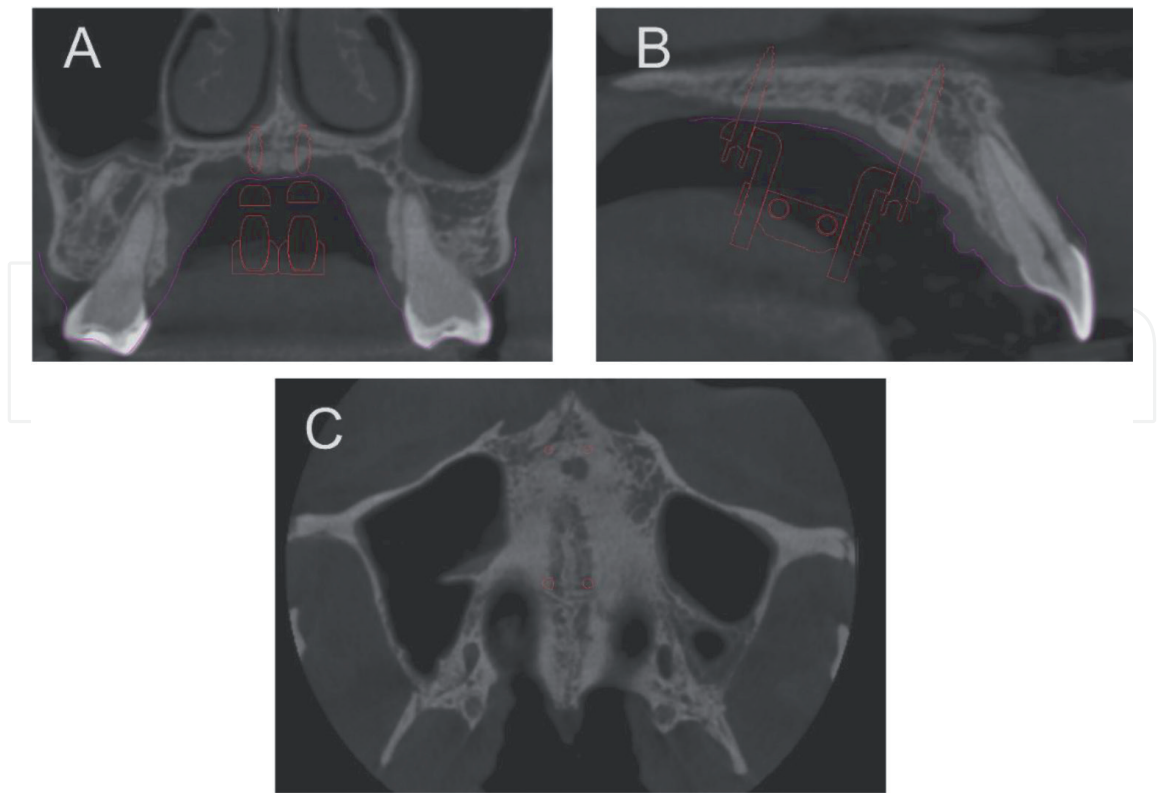


Figure 10.
(A) Coronal section, illustrating the digital placement of MARPE, even in cases of severe atresia and asymmetry. (B) Sagittal section, showing the bicortical position of the mini-implants, respecting a discrete distance from the mucosa to avoid collision during expansion. (C) Placement of the mini-implants, respecting the midpalatal suture, as well as the transpalatal suture and the incisive foramen.

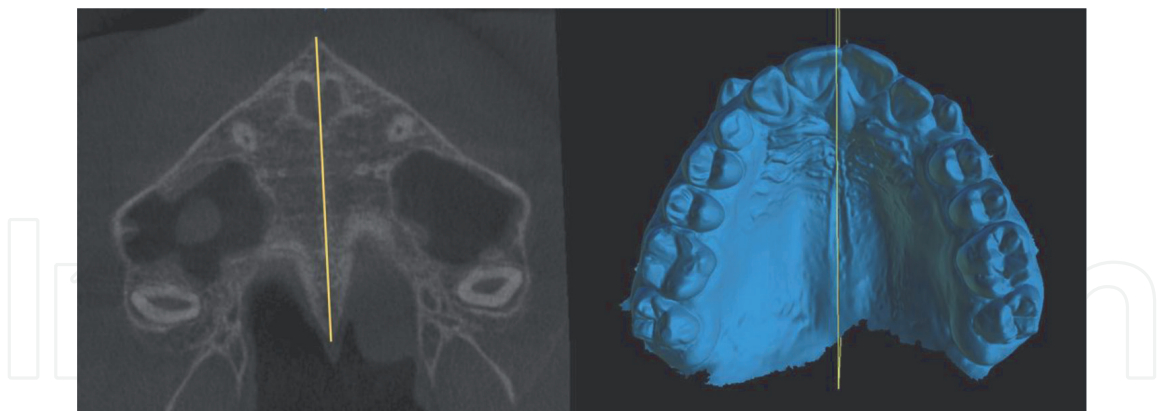


Figure 11.
Palatal raphe and midpalatal suture are not coincident. If the corticoperforation is not performed in a guided way. It can lead to an error during the procedure.

corticoperforation guide (Cortex Guide), which reproduces the digital perforation of each point created, with angulation and insertion limits.

2.2 Presentation of a complete planning

Below, we present a complete MARPE Guide and Cortex Guide planning, following all the parameters discussed above (**Figures 14–19**).

Subsequently, the MARPE guide and cortex guide are made as detailed above.

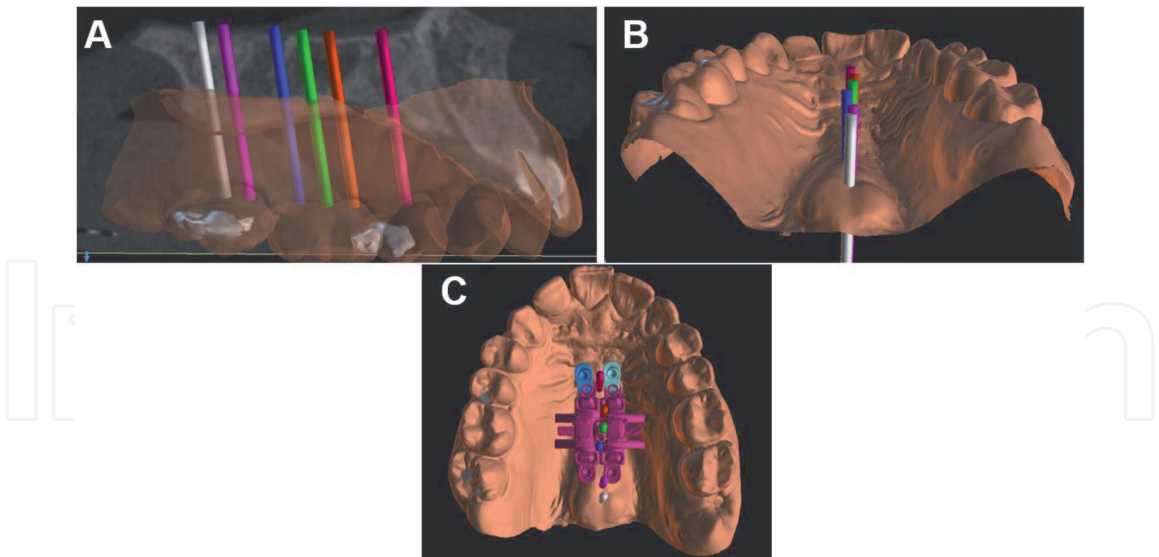


Figure 12.
(A) Perforations performed with bicortical positioning. (B) Note that the positioning respects the suture inclination in both coronal and axial directions. (C) The perforations are performed preserving bone tissue around the MARPE mini-implants.

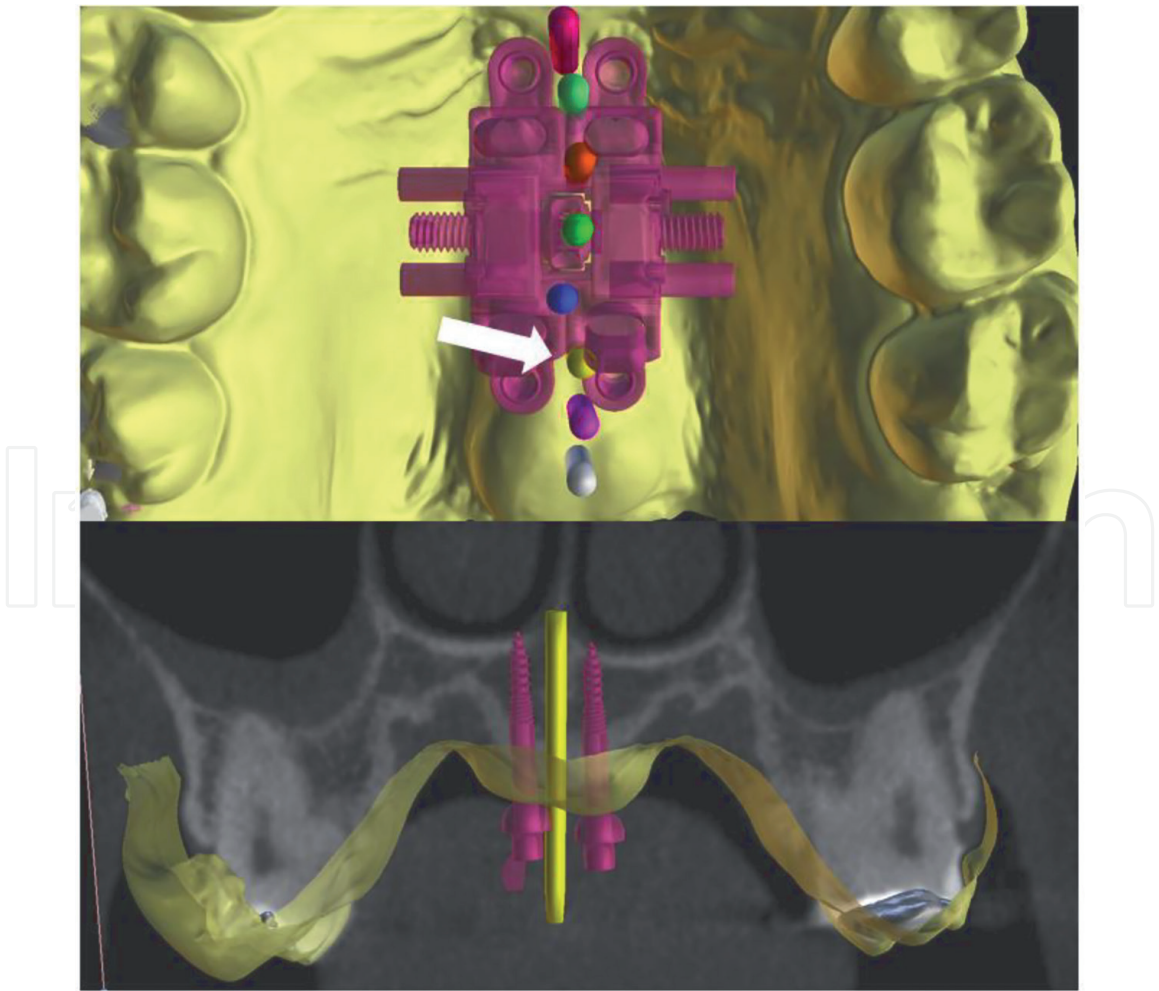


Figure 13.
In the top image we see the simulations of the corticoperforations that would be ideal for this case. However, in the bottom image we note that the perforation in yellow is very close to the posterior mini-implants, which could compromise the technique.

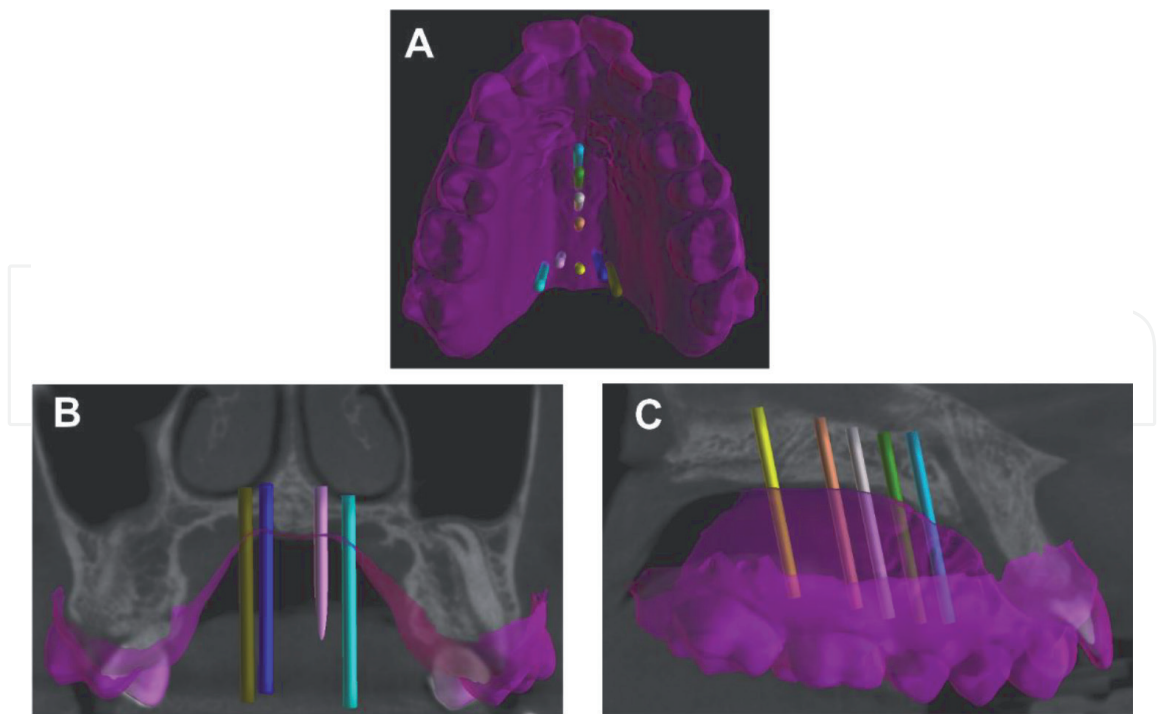


Figure 14.
(A) Virtual corticoperforation drills installed in the midpalatal suture and transpalatal suture. (B) Coronal view (transpalatal suture). (C) Lateral view in sagittal section (midpalatal suture).

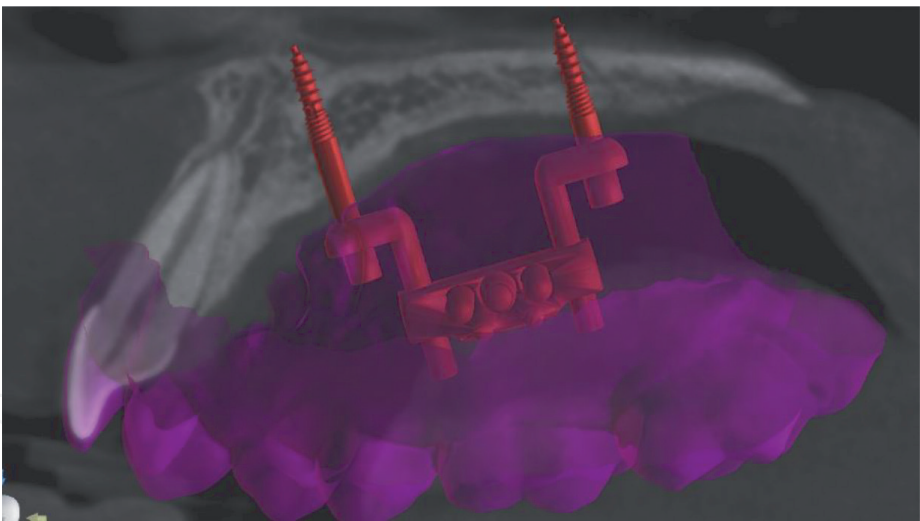


Figure 15.
Sagittal section of the tomography – left side. MARPE installed respecting the bicortical positioning and with the distance of the mini-implant rings from the mucosa.

2.3 MARPE guide

For the virtual placement of MARPE, a concern about injuries caused to the soft tissue due to the contact of the mini-implant rings is resolved with the digital placement (with the MARPE EX and MARPE guide). It has an internal stop that accommodates each mini-implant support ring (**Figure 20**), and its height is established according to the individual's anatomy. It is important to keep the expander screw body as horizontal as possible (**Figure 21**) in the coronal section of the tomography without touching the lateral mucosa.

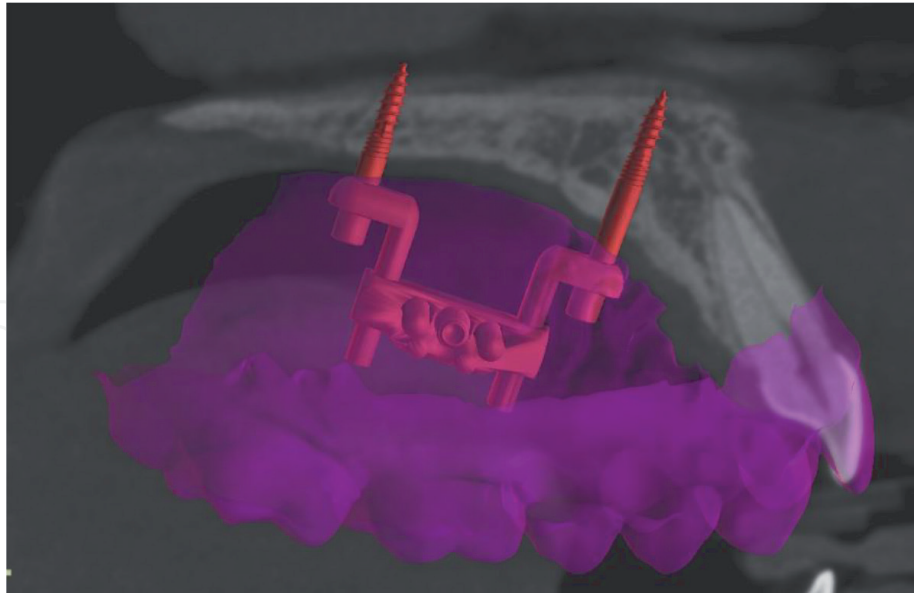


Figure 16.
Sagittal section of the CT scan – left side.

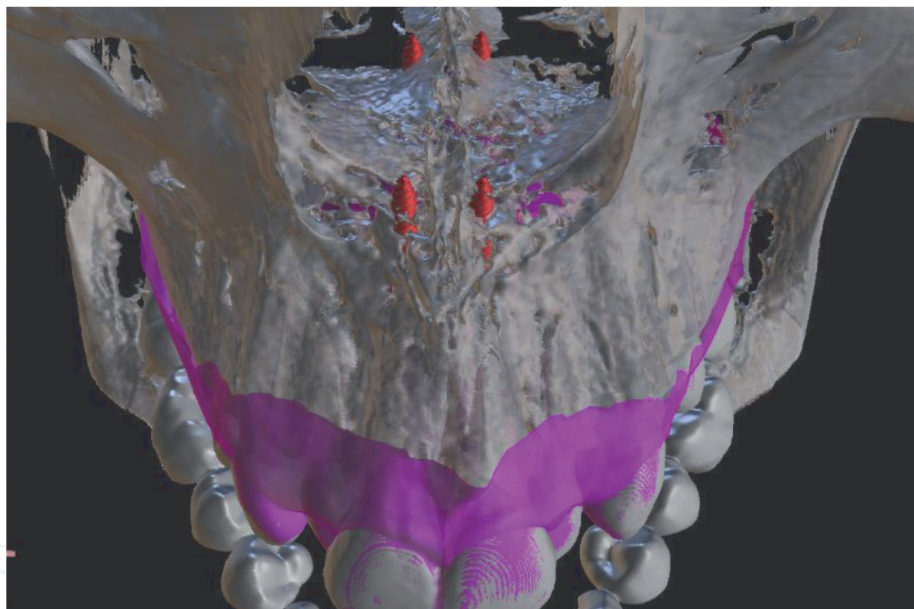


Figure 17.
3D reconstruction of the CT scan illustrating a safe distance of the mini-implants from the transpalatal suture. Note the bicortical positioning of the four mini-implants.

We should be aware of the occlusal plane and nasal floor inclination, which, when altered, can cause asymmetry in the patient. Thus, a stop that holds the expander screw body in position is necessary (**Figure 21**). This guide design is inserted into the patient's STL file, so they are printed at once, which reduces the chances of error by overlapping the guide to the patient's model, in addition to saving printed material.

2.4 Corticoperforation guide

The corticoperforation guide, requires a retentive design (that embraces the posterior teeth), as it will be adapted in the mouth, as a positioner and vertical limiter of each perforation (**Figure 22**) and must remain stable during the process.

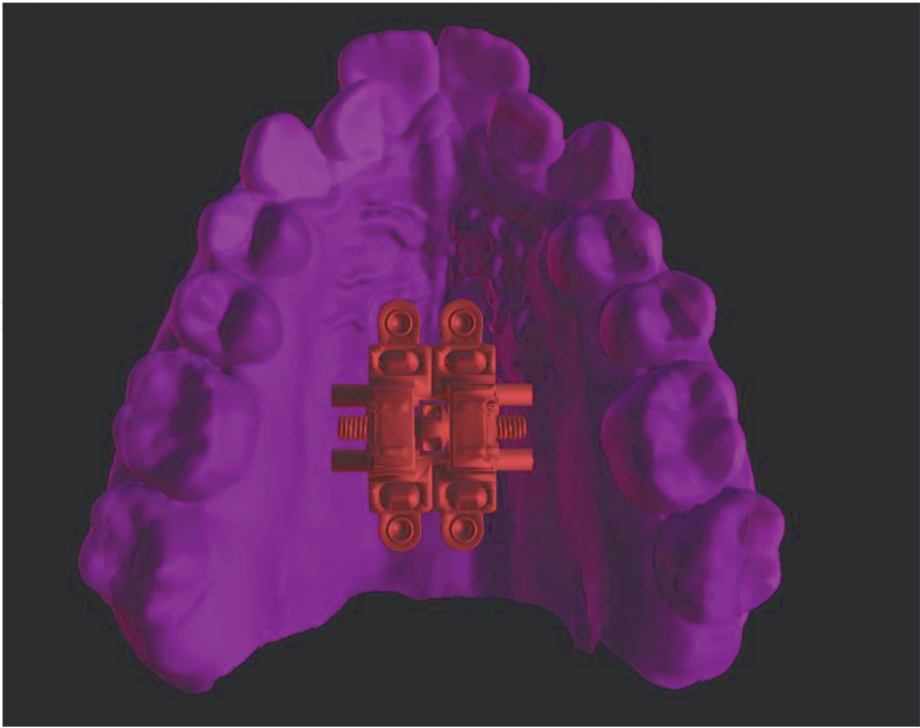


Figure 18.
Occlusal view of the virtually installed MARPE, preserving the lateral tissue and soft palate.

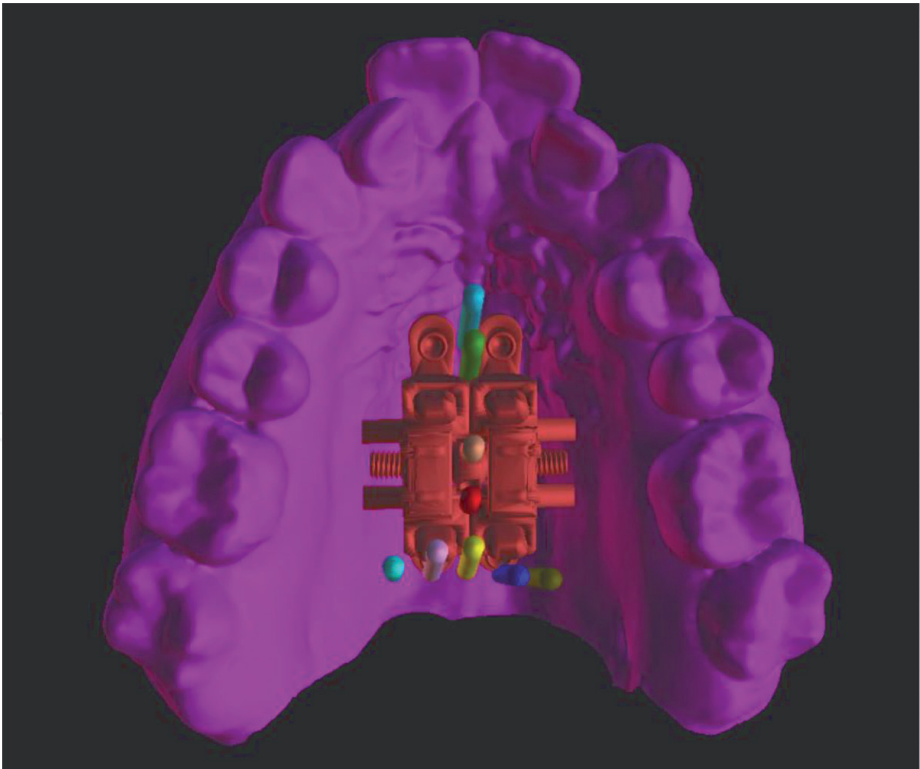


Figure 19.
MARPE guide and cortex guide in the same image to check if there is any collision between the digital plans, such as drilling too close to a mini-implant.

2.5 Laboratory phase – printing the MARPE guide and cortex guide

Finally, it is possible to fabricate MARPE with the reproducibility of each of the precautions taken during the virtual placement. The MARPE EX is made on the guide

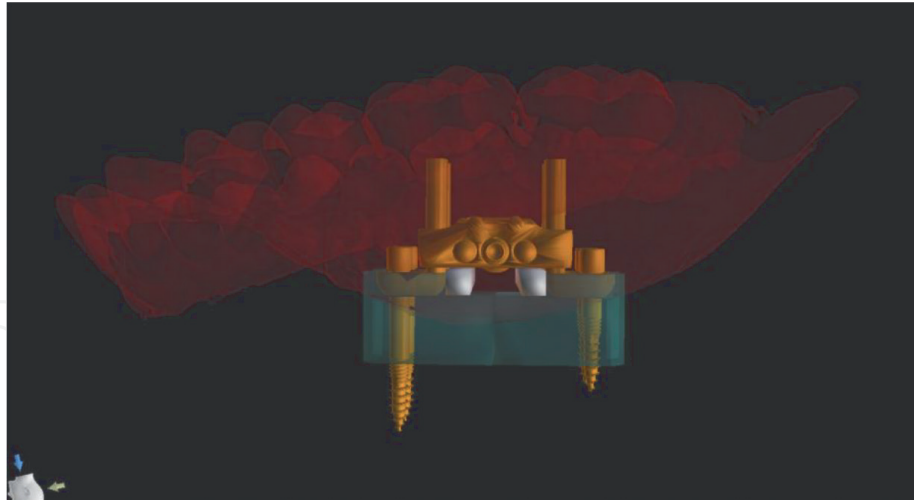


Figure 20.

In green we see the MARPE guide, which accommodates the adjustable mini-implant rings of the MARPE EX, to reproduce the positioning performed during the virtual placement.

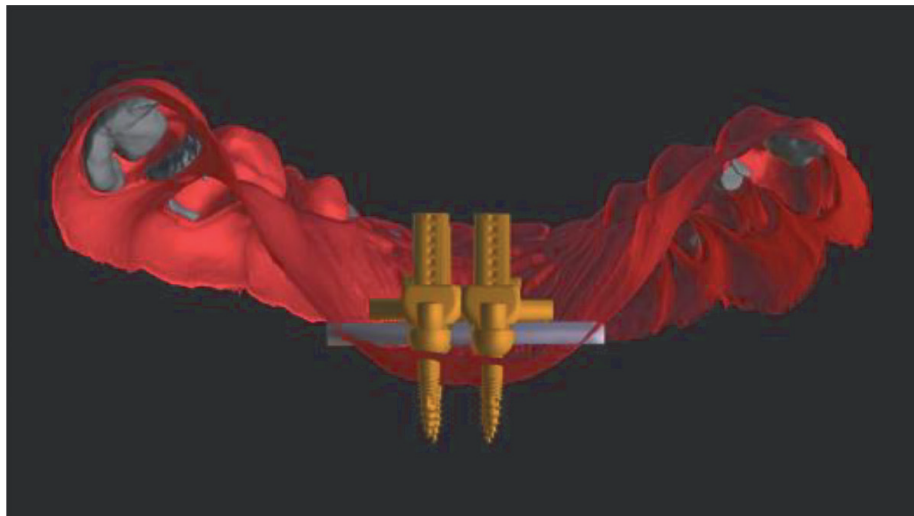


Figure 21.

Digital horizontal support (gray) that are responsible for keeping the MARPE appliance at the planned height during the virtual placement, so that the expander screw does not touch the soft tissue and mainly, remains as horizontal as possible, preventing it from causing any asymmetry in the patient.

template (**Figure 23**), where its mini-implant rings fit exactly inside each small guide, which eliminates transfer errors. It also determines the height and inclination of the expander screw, preventing asymmetries during expansion. Using laser welding, it is possible to weld the MARPE EX to the bands without damaging the prototype model or causing any swelling of the metal of the MARPE EX, owing to the heat of the formerly used silver-based welds.

After this phase, the appliance is polished, and it is ready to reproduce with accuracy the digital planning in the oral cavity. Note that the guide is not used in the oral cavity; it serves as a guide for fabricating the appliance. In the oral cavity the guide for cementation is the bands on the first permanent molars.

To reproduce the corticoperforations in the oral cavity, after designing the guide, it is critical to make an impression of the guide in biocompatible resin (**Figure 24**), and this protocol must be followed even if the guide remains in the oral cavity for some time.

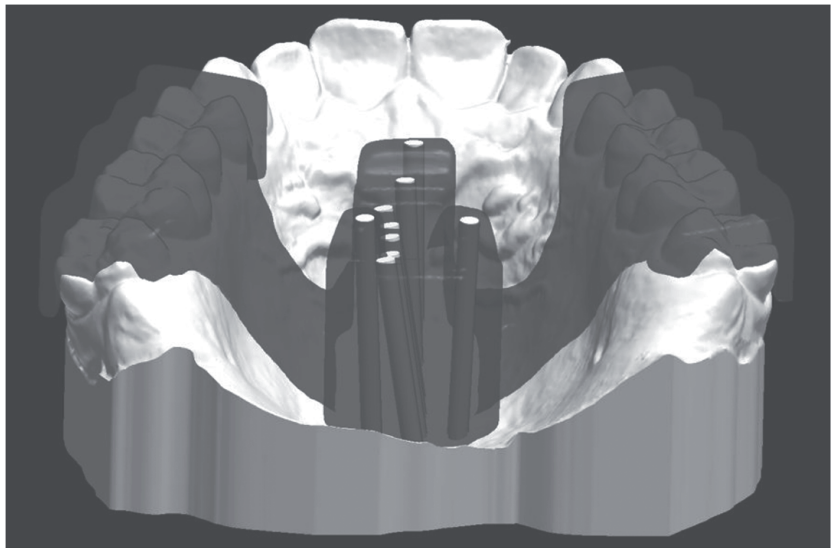

Figure 22.
3D planning of the corticoperforation guide, which reproduces the angulation of each perforation, following the midpalatal suture and transpalatal suture. This guide will also be the limiter for the drill cutter, as soon as it touches the guide, the clinician will know that it has reached the nasal floor cortical.

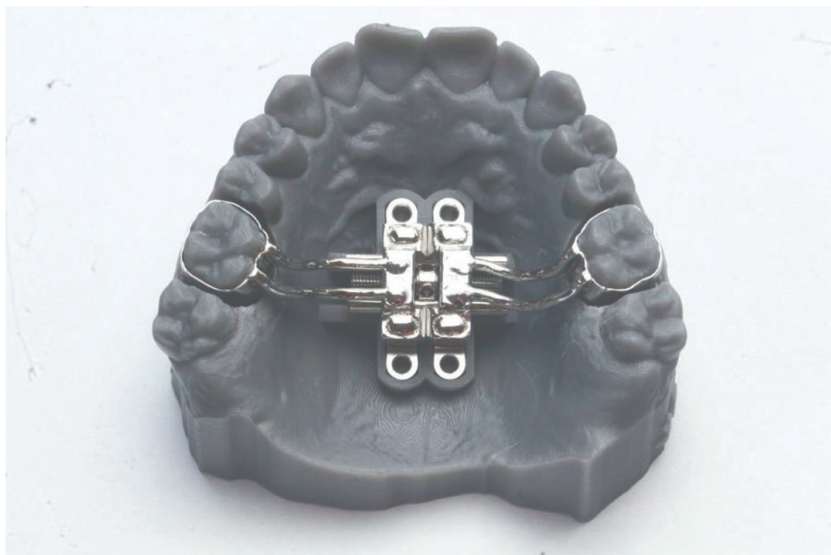

Figure 23.
MARPE device built over the printed MARPE guide template.

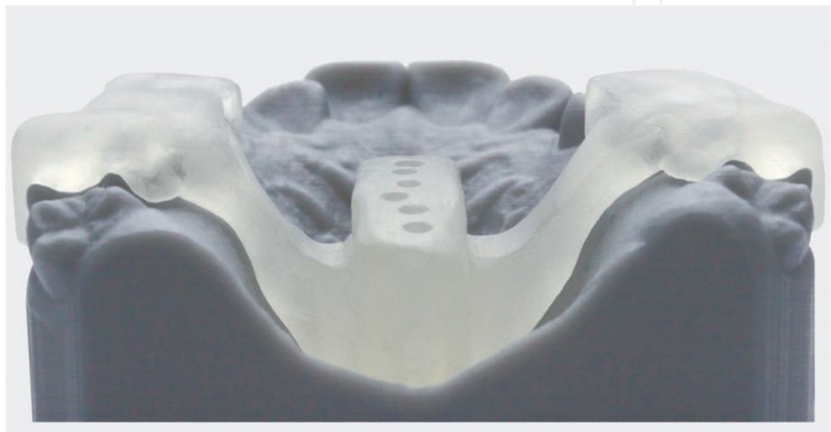


Figure 24.
Cortex guide printed in biocompatible resin.

3. Discussion

For a very short time, the MARPE technique was performed without CT scanning. This type of treatment required three-dimensional (3D) planning since the maxilla contains important structures that must be preserved, both for the patient's safety and success of the technique. The first safety protocols were based on bone and mucosa thickness measurements in the region of first premolars, second premolars, first molars, and second molars [6, 9]. Despite providing important information, these protocols did not show the exact trajectory of MARPE mini-implants. Moreover, the standardization of the patient's head position and evaluation of the tomography sections could not be faithfully reproduced in the oral cavity. This necessitated the creation of digital positioning guides [10–13]. In cases of severe transverse deficiency of the maxilla or asymmetry [23], devices such as the MARPE maxillary skeletal expansion (MARPE MSE) or MARPE SL cannot be indicated because the expander screw does not fit in the palate (**Figure 25**).

Thus, the present study proposes the development of a guide for planning the MARPE technique using MARPE EX [5, 16], to evaluate the capacity of this guide in performing an ideal positioning of the MARPE, prioritizing the adaptation of the mini-implant rings, and respecting the individual anatomy of the patient's palate. The distance between the mini-implants is higher in MARPE EX than that of the other models of MARPE, which, according to a previous study [16], was favorable for better results. Another advantage is that MARPE EX accepts this guide model, where we can place the mini-implant rings away from the palate at customized heights according to the patient's anatomy. This distance from the palate in its closest region is approximately 0.2 mm, both towards the palate (vertical) and towards the lateral mucosa (horizontal) [5]. Therefore, no ring juxtaposed should be left juxtaposed to the tissues.

The EX model was also chosen because it demonstrated less tension in the teeth and mini-implants during RME [16], and it presented more tension, with wide distribution, in the lateral lamina of the pterygoid process [16]. According to Brunetto et al. [18], the lateral lamina of the pterygoid process offers the greatest resistance during

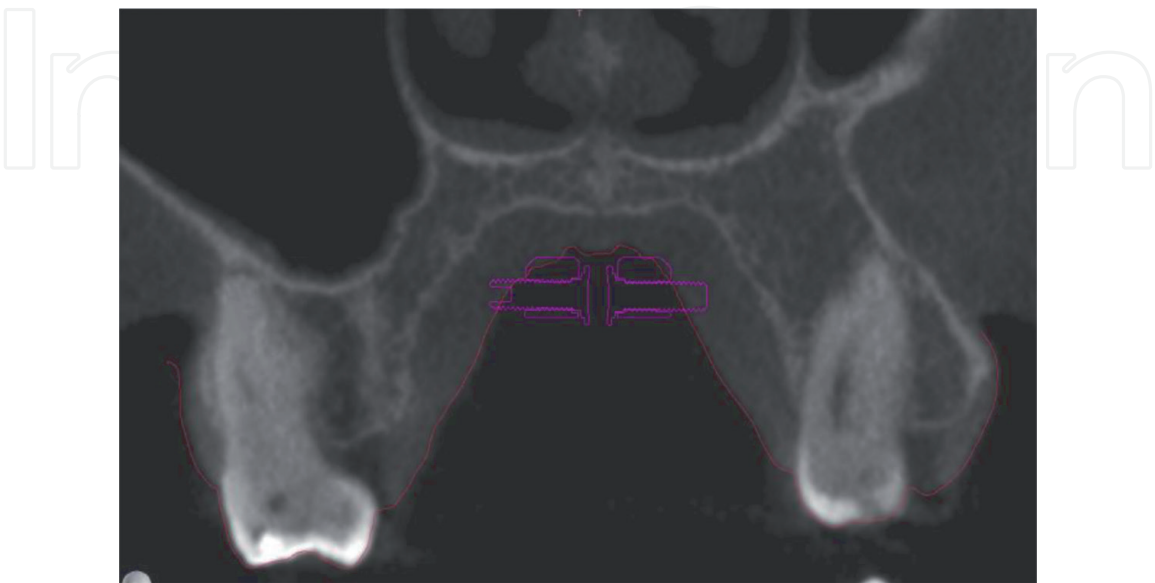


Figure 25.
Model of MARPE without adjustable mini-implant rings. This figure shows that without adjustable mini-implant rings the MARPE does not fit patients with severe transverse disability.

RME. Recent clinical studies have shown that bicortical directly influence treatment with MARPE [8, 24], particularly in patients with advanced maturation stage sutures as the bicortical positioning of mini-implants permits the separation of even the most posterior sutures, such as the lateral lamina from the medial lamina of the pterygoid process [8]. Thus, this demonstrates the importance of a guide that correctly reproduces this bicorticality in the patient, such as the MARPE Guide. It is also important to recognize the importance of the bands, which, in addition to distributing stress, are responsible for transferring the guide model to the oral cavity.

The three initial parameters for placing an MARPE must be discussed. First, it should not touch the midpalatal and transpalatal sutures; second, it should be distant from the incisive foramen; and third, preferably anterior to the transpalatal suture, avoiding collision/perforation of the mini-implants with sutures. We should not touch the incisive foramen to avoid contact with the nerve of the incisive canal, which can result in anterior maxillary paresthesia.

The location of the transpalatal suture does not always coincide with the soft palate; however, if it does, we avoid placing it posteriorly to the transpalatal suture, so that the mini-implants are not inserted in a region of free mucosa, with more chances of inflammation, great difficulty in cleaning, and loss of the mini-implants. However, in some cases of the reduced anteroposterior distance of the maxilla, this becomes unavoidable. The patient's anatomical variation should be considered as it influences the results, such as mini-implants placed in the nasal septum in a patient with palate asymmetry [25] and resulting in a unilateral opening [25]. This highlights the importance of using 3D planning, where insertion in the septum can be easily avoided and bilateral opening can be achieved, eliminating side effects.

While dealing with anatomical variations, it is common to find patients with variations in maxillary sinus extension (**Figure 7**). If the mini-implants are inserted into the sinus cavity, in addition to creating an oral-sinus communication that can generate pain, inflammation, and discomfort, this is a region without trabecular bone, that is, a region that lacks bone volume. Therefore, mini-implants cannot withstand the tension exerted during maxillary expansion [16].

Corticoperforation can be indicated when a torus palatine (**Figure 9**) is detected as it has the potential to decrease the chances of success. Guided corticoperforation, besides allowing perforation of the transpalatal suture, provides accuracy due to the angulation of the guide, which was determined in the virtual simulation, leaving the patient free of perforations outside the suture. Corticoperforations oriented by the palatine raphe may cause asymmetric fractures or even case failure because if performed too close to the mini-implant placement site, they reduce the bone volume required for the tension exerted in the mini-implant region [16]. Another risk of not virtually simulating the corticoperforations and creating a stop guide is to over drill the nasal cavity floor, causing pain to the patient and a bucco-nasal communication, which may lead to sinusitis; in case of inflammation, possibly worsening to bone necrosis or osteomyelitis.

4. Conclusions

The two-dimensional plans do not predict the mini-implant trajectory, and the choice of the mini-implant can be highly subjective and susceptible to errors. The use of the MARPE Guide has already presented interesting results in the literature. By combining the benefits of the MARPE Guide with the MARPE EX and the use of the

Cortex Guide, virtual placement may be performed in a patient with palate asymmetry, bone volume variation, and advanced stage of midpalatal suture classification. This results in tension in the lateral lamina considering the patient's anatomy. Clinical studies are needed to evaluate the results of this new technique in a considerable number of patients.

Conflict of interest

The authors declare no conflict of interest.

Author details


Cristiane Barros André^{1*}, Bruno de Paula Machado Pasqua², José Rino Neto² and Fábio Dupart Nascimento¹

1 Technology Research Center, University of Mogi das Cruzes, Mogi das Cruzes, Brazil

2 School of Orthodontics, University of São Paulo, São Paulo, Brazil

*Address all correspondence to: kika@kikaortodontia.com.br

IntechOpen

© 2021 The Author(s). Licensee IntechOpen. This chapter is distributed under the terms of the Creative Commons Attribution License (<http://creativecommons.org/licenses/by/3.0>), which permits unrestricted use, distribution, and reproduction in any medium, provided the original work is properly cited. 

References

- [1] Lee KJ, Park YC, Park JY, Hwang WS. Mini-implants-assisted nonsurgical palatal expansion before orthognathic surgery for a patient with severe mandibular prognathism. *Am J Orthod Dentofacial Orthop* 2010;(138): 830-839.
- [2] Cantarella D, Dominguez-Mompell R, Moschik C, et al. Midfacial changes in the coronal plane induced by micro-implant-supported skeletal expander, studied with cone-beam computed tomography images. *Am J Orthod Dentofac Orthop* 2018;154(3):337-345.
- [3] Celenk-Koca T, Erdinc AE, Hazar S, Harris L, English JD, Akyalcin S. Evaluation of mini-implants-supported rapid maxillary expansion in adolescents: A prospective randomized clinical trial. *Angle Orthod* 2018;(88):702-709.
- [4] Stuart DA, Wiltshire WA. Rapid palatal expansion in the young adult: Time for a paradigm shift? *J Can Dent Assoc* 2003;(69):374-377.
- [5] André CB. MARPE guide: from consolidation to technique evolution. *Clin Orthod* 2020;19(5):00-00.
- [6] André CB. Análise tomográfica para técnica Marpe. *Rev Clin Ortod Dental Press* 2018;17(4):50-53.
- [7] Lee RJ, Moon W, Hong C. Effects of monocortical and bicortical micro-implant anchorage on bone-borne palatal expansion using finite element analysis. *Am J Orthod Dentofac Orthop* 2017;151(5):887-897.
- [8] Li N, Sun W, Li Q, Dong W, Martin D, Guo J. Skeletal effects of monocortical and bicortical mini-implant anchorage on maxillary expansion using cone-beam computed tomography in young adults. *Am J Orthod Dentofacial Orthop* 2020;157(5):651-661.
- [9] Nojima LI, Nojima M, Cunha ACD, Guss NO, Sant'Anna EF. Mini-implant selection protocol applied to MARPE. *Dental Press J Orthod* 2018;23(5):93-101.
- [10] Maino BG, Paoletto E, Lombardo L, Siciliani G. A three-dimensional digital insertion guide for palatal micro-implant placement. *J Clin Orthod* 2016;50(1): 12-22.
- [11] De Gabriele O, Dallatana G, Riva R, Vasudavan S, Wilmes B. The easy driver for placement of palatal micro-implants and a maxillary expander in a single appointment. *J Clin Orthod* 2017;51(11): 728-737.
- [12] André CB. Instalação virtual dos aparelhos: para que serve? *Rev Clin Ortod Dental Press* 2019;18(5):52-58.
- [13] Lombardo L, Occhiuto G, Paoletto E, Maino BG, Siciliani G. Class II treatment by palatal mini-implants-system appliance: A case report. *Angle Orthod* 2019;90(2):305-313.
- [14] Antonino Lo Giudice, Vincenzo Quinzi, Vincenzo Ronsivale, Stefano Martina, Orazio Bennici, and Gaetano Isola. Description of a digital work-flow for CBCT-guided construction of micro-implant supported maxillary skeletal expander. *Materials* 2020(13):1815.
- [15] Cantarella D, Savio G, Grigolato L, Zanata P, Bervegliieri C, Lo Giudice A, Isola G, Del Fabbro M, Moon W. A new methodology for the digital planning of micro-implant-supported maxillary skeletal expansion. *Med. Devices Evid. Res.* 2020;13:93-106.

- [16] André CB, Rino-Neto J, Iared W, et al. Stress distribution and displacement of three different types of micro-implant assisted rapid maxillary expansion (MARME): A three-dimensional finite element study. *Prog Orthod* 2021; 22:20.
- [17] Suzuki SS, Garcez AS, Reese PO, Suzuki H, Ribeiro MS, Moon W. Effects of corticopuncture (CP) and low-level laser therapy (LLLT) on the rate of tooth movement and root resorption in rats using micro-CT evaluation. *Laser Med Sci* 2018;33(4):811-821.
- [18] Brunetto DP, Sant'Anna EF, Machado AW, Moon W. Non-surgical treatment of transverse deficiency in adults using microimplant-assisted rapid palatal expansion (MARPE). *Dental Press J Orthod* 2017;22(1):110-125.
- [19] Angelieri F, Franchi L, Cevidanes LHS, Toyama-Hino C, Nguyen T, McNamara JA Jr. Zygomaticomaxillary suture maturation: A predictor of maxillary protraction? Part I: Classification method. *Orthod Craniofac Res* 2017;(20):85-94.
- [20] Barbosa NMV, Castro AN, Conti F, Capelozza-Filho L, Almeida-Pedrin RR, Cardoso MA. Reliability and reproducibility of the method of assessment of midpalatal suture maturation: A tomographic study. *Angle Orthod* 2019;89(1):71-77.
- [21] Angelieri F, Franchi L, Cevidanes LHS, Hino CT, Nguyen T, McNamara Jr JA. Zygomaticomaxillary suture maturation: A predictor of maxillary protraction? Part I – A classification method. *Orthod Craniofac Res* 2017;20(2):85-94.
- [22] Cury SEN, Mondelli AL, André CB, Iared W, Guerra JGP, Rovira J, Berni L. Protocolo diferencial para a técnica MARPE em pacientes com variação no volume ósseo do palato. *Rev Clín Ortod Dental Press* 2019;18(4): 116-129.
- [23] Andrade T. MARPE: uma alternativa não cirúrgica para o manejo ortopédico da maxila – parte 2. *Rev Clín Ortod Dental Press* 2019;17(6):24-41.
- [24] Moon HW, Kim, MJ, Ahn, HW, Kim, SJ, Kim, SH, Chung, KR, Nelson, G. Molar inclination and surrounding alveolar bone change relative to the design of bone-borne maxillary expanders: A CBCT study. *Angle Orthod* 2020;90(1):13-22.
- [25] Santos AM, Miranda F, Rocha AD, Cruz AP, Naveda R, Garib D. Mini-implants-assisted rapid palatal expansion in adult patient with severe maxillary constriction: Case report. *Clin Orthod* 2021;19(6):101-112.