

# We are IntechOpen, the world's leading publisher of Open Access books Built by scientists, for scientists

6,900

Open access books available

186,000

International authors and editors

200M

Downloads

Our authors are among the

154

Countries delivered to

TOP 1%

most cited scientists

12.2%

Contributors from top 500 universities



WEB OF SCIENCE™

Selection of our books indexed in the Book Citation Index  
in Web of Science™ Core Collection (BKCI)

Interested in publishing with us?  
Contact [book.department@intechopen.com](mailto:book.department@intechopen.com)

Numbers displayed above are based on latest data collected.  
For more information visit [www.intechopen.com](http://www.intechopen.com)



# Sphincter Preserving Techniques in Anal Fistula Treatment

*Dorian Kršul, Damir Karlović, Đordano Bačić  
and Marko Zelić*

## Abstract

Complex anal fistulas present a challenge to even a seasoned colorectal surgeon due to high rate of recurrence and a real possibility of fecal incontinence if treated with conventional methods (e.g., fistulotomy, fistulectomy, seton placement). Although the illness is benign in nature, it can significantly decrease patient's quality of life because of symptoms like pain and soiling. Given those facts, minimally invasive or sphincter preserving methods of treatment were introduced. Some of these include: Video-assisted anal fistula treatment (VAAFT), ligation of intersphincteric fistula tract (LIFT), Fistula-tract laser closure (FILAC), rectal advancement flap (RAF), treatment with platelet cells and combinations of techniques. This chapter would be an overview of these novel techniques with reference to latest clinical trials and meta-analyses.

**Keywords:** VAAFT, LIFT, RAF, FiLaC, anal fistula, sphincter preserving, proctology

## 1. Introduction

Anal fistula is a chronic abnormal connection between the anal canal and the perianal skin. It is a tract lined with granulation tissue which supports chronic inflammation. Incidence of the disease is about 10 cases per 100 000 individuals with male to female ratio of 2:1. It mostly develops after an abscess of cryptoglandular origin although it can be associated with inflammatory bowel disease (IBD), trauma and carcinomas [1, 2].

Various classifications are proposed, but most widely used is the Parks classification. It relates to the course of fistula in relation to the sphincter mechanism [3]. Nowadays, fistulas can also be classified as simple and complex according to the relation of the proportion of the anal sphincter mechanism they pass through. Simple anal fistulas have one tract that crosses less than 30% of the external anal sphincter. They are treated best by fistulotomy or fistulectomy with very low incidence of continence disturbance. Other fistulas are classified as complex. These tracts cross external anal sphincter at a point that involves more than 30% of the external anal sphincter and can be associated with multiple tracts. Complex fistulas also include those anteriorly positioned in a female, recurrent fistulas and those related to IBD. In case they are treated by lay-open techniques, there is a high risk of postoperative continence disturbance [4].

The average rate of continence disturbance following treatment with a cutting seton is up to 12% which increased when the internal opening of fistula tract was

positioned more proximally [5]. Following lay open techniques, the incidence of flatus incontinence or liquid stool leakage was observed in 20–25% of the patients [6]. This effect on continence has resulted in these techniques being less favorable for complex anal fistulas and the appetite for the use of minimally invasive techniques is increasing.

Various sphincter preserving techniques were introduced in clinical practice in the last 10–15 years with different success rates. This chapter serves as an overview of these techniques. This chapter covers treatment of cryptoglandular anal fistula. Anal fistula associated with Crohn's disease present a somewhat different problem and are not the scope of this chapter.

It is important to note that, given the novelty of some of these techniques, exact indications and contraindications do not exist as such. There are, however, some recommendations made in publications concerning various respective techniques, and these are referred to in the reference section. Authors of this chapter, given our experience in using these novel techniques, will fill in the gaps that may exist, extrapolated from our clinical practice.

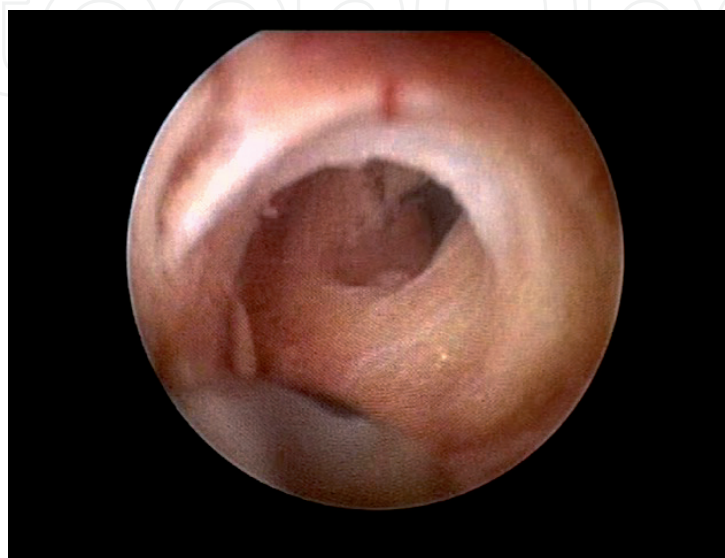
## 2. Sphincter preserving techniques

### 2.1 Video-assisted anal fistula treatment (VAAFT)

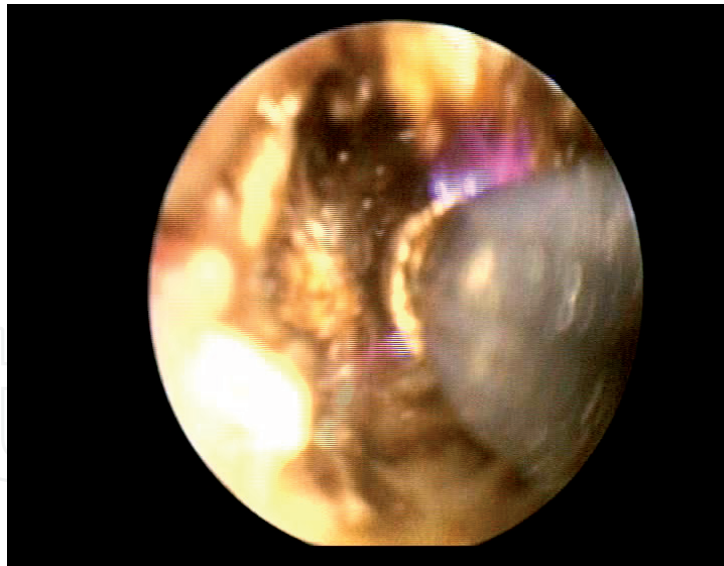
Video-assisted anal fistula treatment is a sphincter preserving procedure that was developed by Italian surgeon Piercarlo Meinero in 2011 where he and others have described long and short-term results.

The operation is performed under spinal or general anesthesia using fistuloscope and specially designed equipment developed by Karl Storz (GmbH, Tuttlingen, Germany).

VAAFT procedure has two phases: diagnostic and therapeutic. The aim of the diagnostic phase is to visualize the entire fistula tract as well as the internal opening and to identify any possible secondary tracts and abscess cavities (**Figure 1**). In the therapeutic phase, complete destruction of the main and any secondary fistula tracts are preformed using monopolar electrode introduced to the fistula tract through working canal of the fistuloscope (**Figure 2**). This is followed by removal of necrotic detritus and closure of internal opening [7].



**Figure 1.**  
*Exploration of anal fistula tract using fistuloscope.*



**Figure 2.**  
*Electrofulguration of anal fistula tract using monopolar electrode.*

The main indication for VAAFT is operative treatment of complex anal fistulas, where there is a high possibility of continence disturbance if the sphincter were to be divided, and complex anal fistulas with multiple tracts [5, 8]. The VAAFT technique is comparable with other sphincter preserving techniques in relation to healing and patient satisfaction [9]. Diminished postoperative pain, earlier recovery after surgery and smaller postoperative perianal wounds allows for earlier return to normal activities. Although simple fistulas were treated with this technique, it is our opinion that VAAFT technique offers no benefit in this setting and should be reserved for complex anal fistulas.

The VAAFT technique allows multiple attempts in case the procedure is not successful in the first instance. The proposed mechanism whereby repeated procedures have an incremental effect is converting a complex fistula with multiple tracts into a more manageable, low, or simple fistula, which can be called conversion of the fistula [10].

To date, the VAAFT has been shown to be safe and associated with good functional outcomes and very low incidence of complications [7, 8, 11], which was shown in a published meta-analysis (Emile et. al). It showed recurrence rate ranging from 7,5 to 33.3% with a weighted mean recurrence rate of 17,7%. Recurrence rates varied significantly depending on the method of internal fistula opening closure (mattress suture, stapler, rectal advancement flap). No affection of anal continence was documented [12].

Compared with other minimally invasive techniques, VAAFT is the only procedure which allows intraoperative visualization of entire fistula tract, possible secondary tracts and the internal fistula opening from within the tract. Limitations of the technique are that it uses rigid instrument to examine curved tracts. Although this is not an issue in most operations due to elasticity of tissue, some fistulas, such as suprasphincteric, may prevent complete examination of the tract due to sharp angle tract makes when it passes above external anal sphincter. This could also lead to creation of false tracts if diathermy is applied unselectively or too much force is used to push fistuloscope when advancing through the tract. When operating on suprasphincteric fistulas, modification of the approach can be used so that the fistuloscope is inserted through internal opening as well as external opening. That way surgeon can explore complete length of the fistula from openings to the curve of suprasphincteric fistula.



## 2.2 Ligation of intersphincteric fistula tract (LIFT)

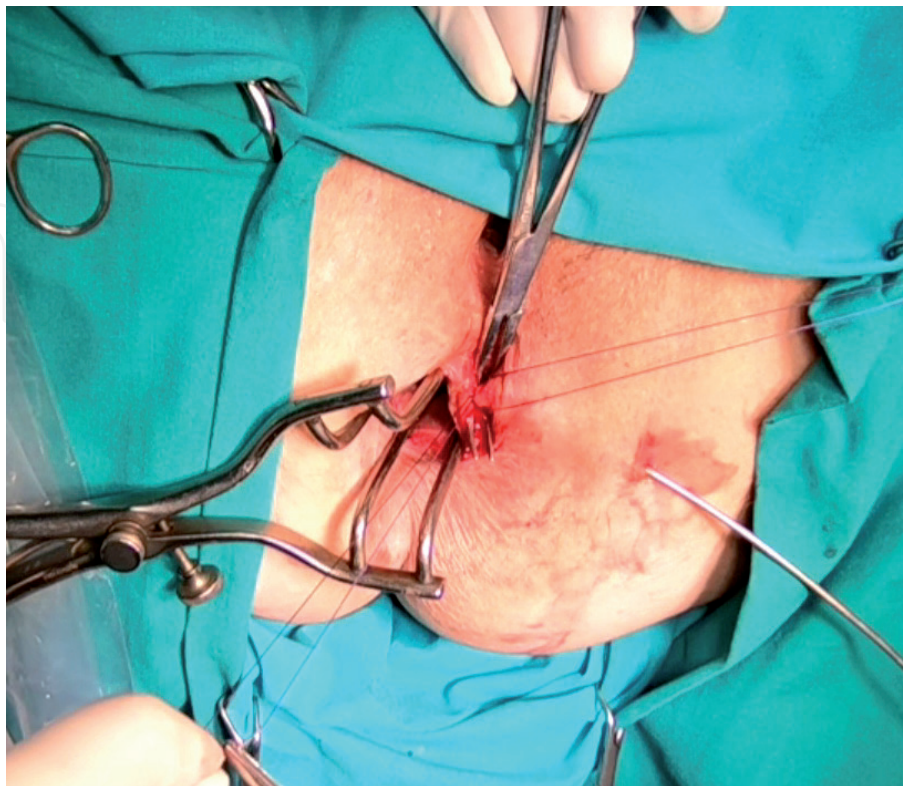
LIFT is a sphincter sparing technique introduced by dr. Arun Rojanasakul in 2007. It is based on the concept of secure closure of the internal opening and concomitant removal of infected cryptoglandular tissue in the intersphincteric plane.

The procedure is performed by identifying fistula tract and internal opening using jet irrigation through external opening or by using metal probe. Next step is making a curvilinear incision on the anocutaneous border and identifying Intersphincteric plane with fistula tract. Intersphincteric portion of fistula tract is then ligated on the side of the internal anal sphincter and cut (**Figure 3**). Rest of the tract is excised along with affected cryptoglandular tissue followed by curettage of the rest of tract through external opening. The defect in the external anal sphincter is sutured and the incision closed [13].

Two available meta-analyses showed that overall rate of success was 76.4 and 78% respectively. The weighted mean complication rate was 5.5–13.9%. The most common complication was wound dehiscence, others being infection, bleeding, anal discharge, anal fissure, and hematoma. Fecal incontinence was recorded in 1.4% of patients, but only of minor grade [14, 15].

LIFT has an advantage over other methods in that it is easily reproducible without investment in potentially costly equipment. Due to specific surgical technique and access in the intersphincteric plane, it is logical to conclude that its role lies mostly in treatment of transsphincteric anal fistula. In case of procedure failure or persistence of fistula, repeated LIFT on the same place might be a problem because of the tissue scarring. Therefore in such cases it would be best to consider some other sphincter preserving technique like VAAFT that has the added value of visualizing branching tracts that might have been the cause of failure in the first place.

While it is always best for transsphincteric fistula to heal primarily, an important observation when dealing with wound dehiscence after LIFT on the anocutaneous border is that loose seton can be inserted through the wound, which converts



**Figure 3.**  
*Anal fistula tract dissected and ligated in the intersphincteric plane.*

transsphincteric into simple intersphincteric fistula that can be dealt with later by lay open technique without fear of continence disturbances.

### **2.3 Anal fistula laser closure (FiLaC™)**

Fistula laser closure was first introduced in 2011 by Wilhelm. The procedure involves destruction of fistula tract using radial emitting laser probe by applying energy while retracting laser probe that was inserted through perianal opening [16]. It was proposed initially to close the site of internal opening with anorectal flap, but procedure was later modified by Giamundo to exclude any form of internal opening closure by using the shrinking effect of laser energy to obliterate the opening, as well as remaining fistula tract [17]. It is postulated that this approach has an advantage over simple diathermy because diathermy cannot elicit shrinking effect on surrounding tissues, and it is more difficult to regulate thermal damage on anal sphincter complex [18].

Since the technique introduction, multiple observational studies were reported and published but only one systematic review and meta-analysis currently exists (Elfeki et al). Overall, mean rate of primary healing among the analyzed studies was 67,3% which was increased to 69.7% with a repeated procedure. Only 5,5% of patients had complications, but those were all minor, scoring I or II on Clavien-Dindo scale. Weighted mean rate of fecal incontinence was 1% but was not statistically significant [19].

Drawback of this procedure is argued to be lack of visualization of fistula tract. Even though energy of the probe can be adjusted to different power settings, and therefore different depth of tissue penetration, there is still an issue of branching tracts that cannot be adequately accessed by blind insertion. On the other hand, increasing power of the laser diode in order to widely affect perianal tissue, could result in inadvertent damage of anal sphincter complex.

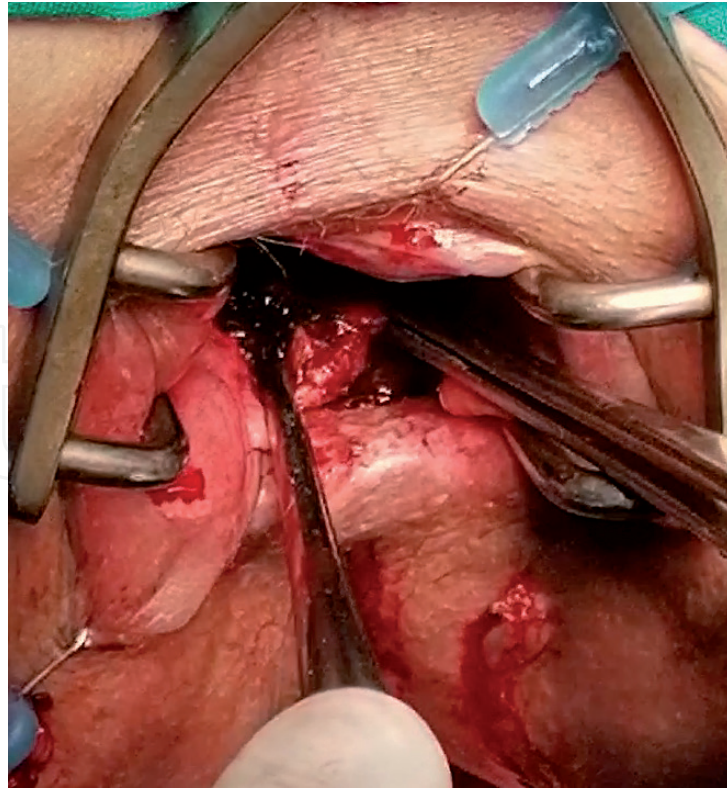
As the probe itself is a flexible instrument, it could potentially reach parts of fistula tract that are otherwise inaccessible behind the sharp angle such is often the case in suprasphincteric fistulas.

### **2.4 Rectal advancement flap (RAF)**

This is the oldest sphincter preserving technique, primarily reserved for treatment of complex anal fistulas. It was first described by Elting in the beginning of the 20th century but was implemented in everyday practice during the last few decades [20]. Many publications about the technique can be found under different names, such as endorectal, endoanal, transanal advancement flap etc.

First step in this procedure is to identify and excise internal fistula opening. Then the U-shaped or rhomboid flap with wider base side should be performed by dissecting anorectal mucosa and adjacent internal anal sphincter muscle. Curettage and irrigation of the whole of fistula tract should be performed followed by suture of defect in sphincter complex left by earlier fistula tract. Site is then covered by previously prepared flap and sutured (**Figure 4**).

Much research has been made about optimal flap thickness, whether be it only mucosal flap or full thickness flap which involves full transection of the rectal wall. Researchers found that there was statistically higher rate of primary healing in group with thicker flaps, but also noticed that there was higher rate of postoperative mild continence disturbance which was more severe the thicker flap was [21–23]. Another frequently discussed issue was necessity to use loose seton prior flap operation to raise the rate of primary healing. Even though there have not been clear statistical findings, many surgeons advocate seton placement as an important step



**Figure 4.**  
*Mobilized full-thickness rectal advancement flap.*

before flap operation [24]. Factors that could affect healing after flap procedure are obesity and smoking, so patients should be advised to quit smoking and to try to reduce their weight prior flap operation [25–27].

There have been many publications and several systematic reviews and meta-analyses on this technique where the effectiveness was shown to be 60–80%, but same cases also reported some degree of postoperative fecal disturbance [23, 28, 29]. That is why we cannot talk about pure sphincter preserving technique, even though this technique was developed primarily for treatment of complex high anal fistulas that would otherwise have high postoperative risk of fecal disturbance if treated by lay open techniques.

It is important to note that although RAF is a treatment technique, it is used by itself as a method of internal fistula opening closure when performing other sphincter preserving procedures. This type of internal opening closure can be made in all cases, but is most appropriate when large openings are present, and when tension on the suture line is presumed to be increased by simple mattress suturing. RAF is also technically most demanding to perform, because it involves dissection and suturing in a confined space, often deeply in anal canal. Flap itself has to be rhomboid in shape or U-shaped with wider base, so that circulation is adequate to avoid dehiscence or flap ischemia. Excessive grasping should also be avoided as well as too big a strain on the suture line.

## 2.5 Autologous platelet rich plasma (APRP)

Although autologous platelet rich plasma (APRP) is used as treatment in other fields of medicine, such as plastic surgery, orthopedics, and dental medicine, treatment of anal fistula using this technique has emerged in the last decade.

Autologous platelet-rich plasma (APRP) is platelet concentration derived from centrifuged full blood after removal of red blood cells. Such plasma is a rich source of growth factors implicated in tissue healing and regeneration [30, 31].

Treatment itself consists of removal of granulation tissue lining the fistula tract followed by irrigation and closure of the internal opening. APRP injection, which



was previously prepared using gravitational platelet separation procedure from autologous blood sample, is then injected into the fistula tract [32]. Specifics of the separation procedure are beyond the scope of this chapter. Majority of publications combined mucosal advancement flap with APRP injection [33–36].

There have been several publications with the reported average healing rate from 60 to 90% [34–36]. All of publications had relatively small number of patients enrolled and still no meta-analyses exist on the subject. No continence disturbances were reported.

This is still somewhat experimental procedure and not widely used. Platelet separation procedures require specialized equipment that is often only available in larger institutions. Cost per patient also exceeds that of the other techniques, which is why this technique needs more solid evidence for patient benefit before it can be considered to become one of the mainstream sphincter preserving treatments.

## **2.6 Hybrid sphincter preserving techniques**

Hybrid sphincter preserving techniques combine two techniques into a single procedure. Some of the reported combinations are as follows.

LIFT-VAAFT is used with intention of combining internal fistula opening closure in the intersphincteric plane with VAAFT to destroy remaining fistula tract and to check for any branching tracts [37]. A new and yet unpublished report combines VAAFT and FiLaC procedures with the same fundamental philosophy [38]. VAAFT was also combined with RAF in order to close especially large internal openings that would not be suitable for closure with mattress suture [10].

BioLIFT combines LIFT with insertion of bioprosthetic graft in the intersphincteric plane. On a study of 31 patients, success rate was reported to be 94% in a one-year follow-up period [39]. Another study combined LIFT and human acellular dermal matrix as a bioprosthetic plug with reported success rate of 95% on 21-patient sample [40].

Advancement flap was combined with injection of porcine dermal collagen implant through external opening in a study of 24 patients with success rate of 82,5% in a 14-month follow-up period [41].

It was to be expected that surgeons, encouraged by initial promising results, started combining sphincter preserving techniques in order to achieve even better healing rates. Some of these procedures were more successful than others, but majority of reports are on a single institution basis or case reports and relatively few patients. Idea of combining two (or more) techniques in order to recruit the individual one's advantage is sound. For example LIFT combined with VAAFT has potential to resolve pathology in intersphincteric plane as well as find additional tract branches. VAAFT in conjunction with FiLaC can visualize branching tracts while managing to reach fistula behind sharp angle etc.

For now, as there is no evidence to the contrary, we can use hybrid techniques in order to take advantage of one's strong suits, overcome the shortages of another and vice versa. Until evidence is found that one technique, or combination of techniques, has significantly better results over the others, they should be tailored individually depending on patient's case.

## **3. Discussion and conclusions**

Complex anal fistulas present a complex problem, although they are often not perceived as such. Operation of anal fistula is usually one of the first operations that a surgical resident will do in the course of their residency as it is thought as simple and straightforward procedure. The actuality is that unless patient requires only



seton placement, no treatment of complex fistulas should be made if surgeon is not acquainted with sphincter preserving procedures or knows how to repair anal sphincter if treatment using traditional techniques results in fecal incontinence. The most difficult cases should be treated in high-volume institutions only, as successfully treated fistula resulting in any degree of fecal incontinence is not a good outcome.

Important point in every operation is to try to identify internal opening even when one is not evident. This is especially important in very complex cases, such as horseshoe fistulas, when multiple internal openings might be present but not all of them immediately visible. Goodsall's rule is a good waypoint as to where the opening might be. Failure of dealing with internal opening is almost certain to result in procedure failure. Surgeon should take care not to use excessive force when identifying the opening to avoid creation of false openings or false tracts. Easy way to find the opening is to inject hydrogen peroxide through external opening and look for the spurt of foam in the anal canal.

Several things can be considered to increase the chance of healing, especially when performing RAF. It might be a good idea to try to reduce intraoperative fecal matter and postoperative stool passage through the anal canal by applying enema. Postoperatively stool regulation by avoiding hard stool and excessive straining should be advised. Although not specific to this pathology, flavonoid use after hemorrhoidectomy has been observed to reduce inflammatory reaction and pain by reducing leukocyte adherence, so the same can be considered after these types of procedures [42].

There is also the issue of direct repair of fistula or seton placement in the first act. It is observed that seton placed and held for several weeks or months helps draining perianal sepsis and promotes fibrosis of the tract, making the subsequent sphincter preserving procedure easier. Therefore, an effort should be made to decrease perianal inflammation before attempting definite procedure, if possible. This opinion is not uniform between surgeons however. Other opinion is that the incidence of false tracts creation with metal probes while placing setons is unacceptably high, so that in this case, the wrong tract ends up being treated and recurrence is certain. This kind of belief is mostly anecdotal and there is no evidence in scientific literature.

Many new methods of sphincter preserving techniques for treating anal fistula emerged in the last 10–15 years. The sheer fact that so many different procedures are proposed, shows that there is no best technique, and those that initially showed exceptional results usually could not be replicated in another institution. This speaks volumes about the complexity of anal fistula problem for the colorectal surgeon and hints that there is much that we still do not understand.

Nevertheless, several techniques gained somewhat wider acceptance, such as LIFT, VAAFT and RAF. Problem in choosing the best procedure lies in heterogeneity of fistulas and still no algorithm exists to rely on, so it is actually no surprise that a wide variety of procedures exist in the first place. We have tried to summarize characteristics of aforementioned techniques along with proposed indications and their pros and cons, but ultimately decision on what technique to choose should still be made on individual basis, surgeon's preference and on equipment availability.

Still, more randomized studies are needed. It is to be expected that success rate of these procedures will increase somewhat as the time passes given that a lot of publications reported initial results that are burdened by surgeon's learning curve. With increasing amount of sphincter preserving procedures being underwent, we will probably have more results to rely on in the future and to extrapolate better conclusions.

## **Conflict of interest**

The authors declare no conflict of interest.

IntechOpen

IntechOpen

### **Author details**

Dorian Kršul\*, Damir Karlović, Đordano Bačić and Marko Zelić  
Clinical Hospital Center Rijeka, Rijeka, Croatia

\*Address all correspondence to: [dorian.krsul@hotmail.com](mailto:dorian.krsul@hotmail.com)

### **IntechOpen**

© 2021 The Author(s). Licensee IntechOpen. This chapter is distributed under the terms of the Creative Commons Attribution License (<http://creativecommons.org/licenses/by/3.0>), which permits unrestricted use, distribution, and reproduction in any medium, provided the original work is properly cited. 

## References

- [1] Mappes HJ, Farthmann EH. Anal abscess and fistula. Munich: Zuckschwardt; 2001.
- [2] Hamalainen KP, Sainio AP. Incidence of fistulas after drainage of acute anorectal abscesses. *Dis Colon Rectum*. 1998; 41:1357-1361.
- [3] Parks AG, Gordon PH, Hardcastle JD. A classification of fistula-in-ano. *Br J Surg*. 1976; 63:1-12.
- [4] Whiteford MH, Kilkenny J III, Hyman N, Buie WD, Cohen J, Orsay C et al. Practice parameters for the treatment of perianal abscess and fistula-in-ano (revised). *Dis Colon Rectum*. 2005; 48:1337-1342.
- [5] Ritchie RD, Sackier JM, Hodde JP. Incontinence rates after cutting seton treatment for anal fistula. *Colorectal Dis*. 2009;11(6):564-571.
- [6] Atkin GK, Martins J, Tozer P, Ranchod P, Phillips RKS. For many high anal fistulas, lay open is still a good option. *Tech Coloproctol*. 2011;15(2):143-150.
- [7] Meinerio P, Mori L. Video-assisted anal fistula treatment (VAAFT): A novel sphincter-saving procedure for treating complex anal fistulas. *Tech Coloproctol*. 2011;15(4):417-422
- [8] Schwandner O. Video-assisted anal fistula treatment (VAAFT) combined with advancement flap repair in Crohn's disease. *Tech Coloproctology*. 2013;17(2):221-225.
- [9] García-Aguilar J, Davey CS, Le CT, Lowry AC, Rothenberger DA. Patient satisfaction after surgical treatment for fistula-in-ano. *Dis Colon Rectum*. 2000;43(9):1206-1212.
- [10] Zelić M, Karlović D, Kršul D, Bačić Đ, Warusavitarne J. Video-assisted anal fistula treatment (VAAFT) for treatment of complex cryptoglandular anal fistulas with 2 years follow up period – our experience. *J Laparoendosc Adv Surg Tech A*. 2020 Dec;30(12):1329-1333.
- [11] Walega P, Romaniszyn M, Nowak W. VAAFT: A new minimally invasive method in the diagnostics and treatment of anal fistulas – initial results. *Pol Przegl Chir*. 2014;86(1):7-10.
- [12] Emile SH, Elfeki H, Shalaby M, Sakr A. A Systematic review and meta-analysis of the efficacy and safety of video-assisted anal fistula treatment (VAAFT). *Surg Endosc*. 2018 Apr;32(4):2084-2093.
- [13] Rojanasakul A. LIFT procedure: a simplified technique for fistula-in-ano. *Tech Coloproctol*. 2009 Sep;13(3):237-240.
- [14] Hong KD, Kang S, Kalaskar S, Wexner SD. Ligation of intersphincteric fistula tract (LIFT) to treat anal fistula: systematic review and meta-analysis. *Tech Coloproctol*. 2014 Aug;18(8):685-691.
- [15] Emile SH, Khan SM, Adejumo A, Koroye O. Ligation of intersphincteric fistula tract (LIFT) in treatment of anal fistula: An updated systematic review, meta-analysis, and meta-regression of the predictors of failure. *Surgery*. 2020 Feb;167(2):484-492.
- [16] Wilhelm A. A new technique for sphincter-preserving anal fistula repair using a novel radial emitting laser probe. *Tech Coloproctol*. 2011 Dec;15(4):445-449.
- [17] Giamundo P, Geraci M, Tibaldi L, Valente M. Closure of fistula-in-ano with laser-FiLaC™: an effective novel sphincter-saving procedure for complex disease. *Colorectal Dis*. 2014 Feb;16(2):110-115

- [18] Limura E, Giordano P. Modern management of anal fistula. *World J Gastroenterol*. 2015 Jan 7; 21(1): 12-20.
- [19] Elfeki H, Shalaby M, Emile SH, Sakr A et al. A systematic review and meta-analysis of the safety and efficacy of fistula laser closure. *Tech Coloproctol*. 2020 Apr;24(4):265-274.
- [20] Elting AW. X. The Treatment of Fistula in Ano: With Especial Reference to the Whitehead Operation. *Ann Surg* 1912; 56:744-752.
- [21] Balciscueta Z, Uribe N, Balciscueta I, Andreu-Ballester JC, Garcia-Granero E. Rectal advancement flap for the treatment of complex cryptoglandular anal fistulas: a systematic review and meta-analysis. *Int J Colorectal Dis* 2017; 32:599-609.
- [22] Dubsky PC, Stift A, Friedl J, Teleky B, Herbst F. Endorectal advancement flaps in the treatment of high anal fistula of cryptoglandular origin: fullthickness vs. mucosal-rectum flaps. *Dis Colon Rectum* 2008; 51:852-857.
- [23] Khafagy W, Omar W, El Nakeeb A, Fouda E, Yousef M, Farid M. Treatment of anal fistulas by partial rectal wall advancement flap or mucosal advancement flap: a prospective randomized study. *Int J Surg* 2010; 8:321- 325
- [24] Mitalas LE, van Wijk JJ, Gosselink MP, Doornebosch P, Zimmerman DD, Schouten WR. Seton drainage prior to transanal advancement flap repair: useful or not? *Int J Colorectal Dis* 2010; 25:1499-1502.
- [25] Zimmerman DD, Delemarre JB, Gosselink MP, Hop WC, Briel JW, Schouten WR. Smoking affects the outcome of transanal mucosal advancement flap repair of trans-sphincteric fistulas. *Br J Surg* 2003; 90:351-354.
- [26] Ellis CN, Clark S. Effect of tobacco smoking on advancement flap repair of complex anal fistulas. *Dis Colon Rectum* 2007; 50:459-463
- [27] Schwandner O. Obesity is a negative predictor of success after surgery for complex anal fistula. *BMC Gastroenterol* 2011; 11:61
- [28] Schouten WR, Zimmerman DD, Briel JW. Transanal advancement flap repair of transsphincteric fistulas. *Dis Colon Rectum* 1999; 42:1419-1422.
- [29] Ozuner G, Hull TL, Cartmill J, Fazio VW. Long-term analysis of the use of transanal rectal advancement flaps for complicated anorectal/vaginal fistulas. *Dis Colon Rectum* 1996; 39:10-14. 7.
- [30] Eppley BL, Woodell GE, Higgins J. Platelet quantification and growth factor analysis from platelet-rich plasma: implications for wound healing. *Plast Reconstr Surg*. 2004; 114:1502-1508
- [31] Bai MY, Wang CW, Wang JY, Lin MF, Chan WP. Threedimensional structure and cytokine distribution of platelet-rich fibrin. *Clinics (Sao Paulo)*. 2017; 72:116-124
- [32] Van der Hagen SJ, Baeten CG, Soeters PB, van Gemert WG. Autologous platelet-derived growth factors (platelet-rich plasma) as an adjunct to mucosal advancement flap in high cryptoglandular perianal fistulae: a pilot study. *Color Dis*. 2011; 13:215-218
- [33] Pérez-Lara FJ, Moreno Serrano A, Ulecia Moreno J, HernándezCarmona J, Ferrer-Márquez M, Romero-Pérez L, del Rey Moreno A, Oliva-Muñoz H (2015) Platelet-rich fibrin sealant as a treatment for complex perianal fistulas: a multicentre study. *J Gastrointest Surg* 19:360-368
- [34] Moreno-Serrano A, García-Díaz JJ, Ferrer-Márquez M, AlarcónRodríguez R,



Álvarez-García A, Reina-Duarte Á (2016) Using autologous platelet-rich plasma for the treatment of complex fistulas. *Rev Esp Enferm Dig* (Madrid) 108:123-128

[35] Göttgens KW, Vening W, van der Hagen SJ, van Gemert WG, Smeets RR, Stassen LP, Baeten CG, Breukink SO (2014) Longterm results of mucosal advancement flap combined with plateletrich plasma for high cryptoglandular perianal fistulas. *Dis Colon Rectum* 57:223-227

[36] Göttgens KWA, Smeets RR, Stassen LPS, Beets GL, Pierik M, Breukink SO (2015) Treatment of Crohn's disease-related high perianal fistulas combining the mucosa advancement flap with platelet-rich plasma: a pilot study. *Tech Coloproctol* 19:455-459

[37] Karlović D, Kršul D, Bačić Đ, Zelić M. Video-assisted anal fistula treatment in combination with ligation of the intersphincteric fistula tract in the treatment of complex transsphincteric fistulas - a video vignette. *Colorectal Dis.* 2020 Sep;22(9):1204-1205. doi: 10.1111/codi.15050.

[38] Yao Y-B, Xiao C-F, Wang Q-T, Zhou H, Dong Q-J, Cao Y-Q, Wang C. AAFT plus FiLaC™: a combined procedure for complex anal fistula. *Tech Coloproctol.* 2021 Jan 21. doi: 10.1007/s10151-021-02411-0. Online ahead of print.

[39] Ellis CN. Outcomes with the use of bioprosthetic grafts to reinforce the ligation of the intersphincteric fistula tract (BioLIFT procedure) for the management of complex anal fistulas. *Dis Colon Rectum* 2010 Oct;53(10):1361e4

[40] Han JG, Yi BQ, Wang ZJ, Zheng Y, Cui JJ, Yu XQ, et al. Ligation of the intersphincteric fistula tract plus a

bioprosthetic anal fistula plug (LIFT-Plug): a new technique for fistula-in-ano. *Colorectal Dis* 2013 May;15(5):582e6.

[41] Sileri P, Boehm G, Franceschilli L, Giorgi F, Perrone F, Stolfi C, et al. Collagen matrix injection combined with flap repair for complex anal fistula. *Colorectal Dis.* 2012 Dec;14(Suppl. 3):24e8.

[42] La Torre F, Nicolai AP. Clinical use of micronized purified flavonoid fraction for treatment of symptoms after hemorrhoidectomy: results of a randomized, controlled, clinical trial. *Dis Colon Rectum.* 2004 May;47(5):704-710.