

# We are IntechOpen, the world's leading publisher of Open Access books Built by scientists, for scientists

6,900

Open access books available

186,000

International authors and editors

200M

Downloads

Our authors are among the

154

Countries delivered to

TOP 1%

most cited scientists

12.2%

Contributors from top 500 universities



WEB OF SCIENCE™

Selection of our books indexed in the Book Citation Index  
in Web of Science™ Core Collection (BKCI)

Interested in publishing with us?  
Contact [book.department@intechopen.com](mailto:book.department@intechopen.com)

Numbers displayed above are based on latest data collected.  
For more information visit [www.intechopen.com](http://www.intechopen.com)



# Fan-Shaped Application of Local Abdominal Wall Analgesia in Abdominoplasty Patients: Does the Technique Lead to Better Recovery?

*Dinko Bagatin, Tomica Bagatin, Judith Deutsch,  
Katarina Sakic, Johann Nemrava, Eduardo Isomura  
and Martina Sarec Ivelj*

## Abstract

Plastic surgery can be considered an art form, molding and shaping areas of the body to provide enhancement and visual improvements. During this process, anesthesia is a key role player, for both local and general aspects. Proper combinations of local and general anesthesia can provide not only great pain relief and the ability to perform the artwork of plastic surgery, but can also lead to better and faster post-operative recovery of patients. Take a moment to imagine doing our skills without anesthesia, not only would it be barbaric, but also unethical. The method of using fan-shaped anesthesia application will be explored as a technique to improve patient recovery. This, instead of the classic straightforward areal injection application, seems to provide improved anesthetic distribution, penetrates layers better, and offers a swifter and more efficient way of blocking pain receptors. Choosing an appropriate anesthetic from the various ones available today is very important for pain control and postoperative recovery, as well as combining it with other drugs to increase its duration of action. This medley of drug combinations provides patient satisfaction and enhanced recovery.

**Keywords:** fan-shaped, anesthetic distribution, pain control, enhanced recovery

## 1. Introduction

The history of local anesthesia starts in 1859 with Niemann's isolation of cocaine. The first drug to be used as a local anesthetic was cocaine by Halstead in 1884. Later, in 1903, Braun used epinephrine as a chemical tourniquet. In 1948, Astra starts to use lidocaine in dentistry. Bupivacaine is discovered in 1957, which is a long-lasting local anesthetic we otherwise prefer. There are many articles detailing local infiltration analgesia used in the abdominal wall. This chapter outlines the use of different long-lasting analgesics in different dosages and compares different analgesics and

applications in the rectus sheath, or wounds and nerve blocks. This is the only study that analyzes using this amount of a specific local long-lasting anesthetics (bupivacaine) in all abdominal wall and abdominoplasty wounds. We use general endotracheal anesthesia in abdominoplasty, tumescent infiltration for liposuction in specific dosages, and pure bupivacaine for infiltration of the abdominal wall and wound areas. The underlying reason for this approach is to facilitate easier and faster recovery in patients, and to mobilize patients after surgery in the shortest time possible. Postoperative conditions concerning the abdominal wall and wounds exhibit less pain, quicker mobilization, and activation of patients on the actual day of surgery and patients resume normal activities within a week after surgery. The tumescent solution with local anesthesia provides an analgesic peak after 8–12 h, losing analgesic quality completely after 48 h. With the inclusion of local infiltration analgesia in the rectus abdominis, external oblique muscles, in the inguinal region, and wound area in a section immediately before the closing procedure, wound pains are reduced in the early postoperative setting, but the effect of infiltrated tumescent fluid is not excluded. Our experience in local infiltration analgesia and analysis as well as talking with our patients after each operation provides the evidence that this analgesic infiltration using bupivacaine is useful in reducing pain during the first postoperative days compared to our other patients who in the past did not receive this type of local infiltration analgesia. This is the reason a larger study and more precise analysis should be undertaken as well as more precisely defining the parameters for obtaining scientific evidence that our method is indeed effective.

## **2. Surgical and analgesic considerations and methods in abdominoplasty**

Abdominoplasty is the third most frequent form of body contouring surgery after breast augmentation and liposuction. In 2019, based on the American Society of Plastic Surgery (ASPS) analysis, there were a total of 123,427 cases in the USA. In all, 34 patients underwent abdominoplasty at the Bagatin Polyclinic in 2019. It is one of the most common and demanding procedures requiring significant recovery where patients are absent from work for 2–3 weeks and sometimes even longer. The age of patients varies from 19 all the way to 75 years of age. The oldest female patient who underwent abdominoplasty at our clinic was 75 years of age for a series of procedures that included breast augmentation and thigh tightening around the groin area. Age is not a limit factor in undergoing these procedures, but patient safety is always an important factor, and caution should be taken.

Among all the procedures covering everyday esthetic surgery, liposuction is statistically the most frequent procedure, which is frequently done in combination with abdominoplasty. It has developed through the years and stems from the eternal search for finding ways of achieving the ideal body dimensions, long-term vitality as well as slowing down and delaying the aging process. This surgical method permanently reduces fatty tissue from a specific part of the body which cannot be done or is very difficult using other methods for removing fat and body contouring. Parts of the body where fat accumulates and is difficult to remove through specific exercises are the abdominal part, the segment above the gluteus, thighs, and sections around the knees and upper arm.

The most often myth relating to this surgical procedure is the opinion that it is a method for treating obesity because the disproportionate deposits of fatty tissue are often visible in persons whose body mass index is within normal limits.

Besides removing fatty tissue, this surgical procedure also offers the following positive results:

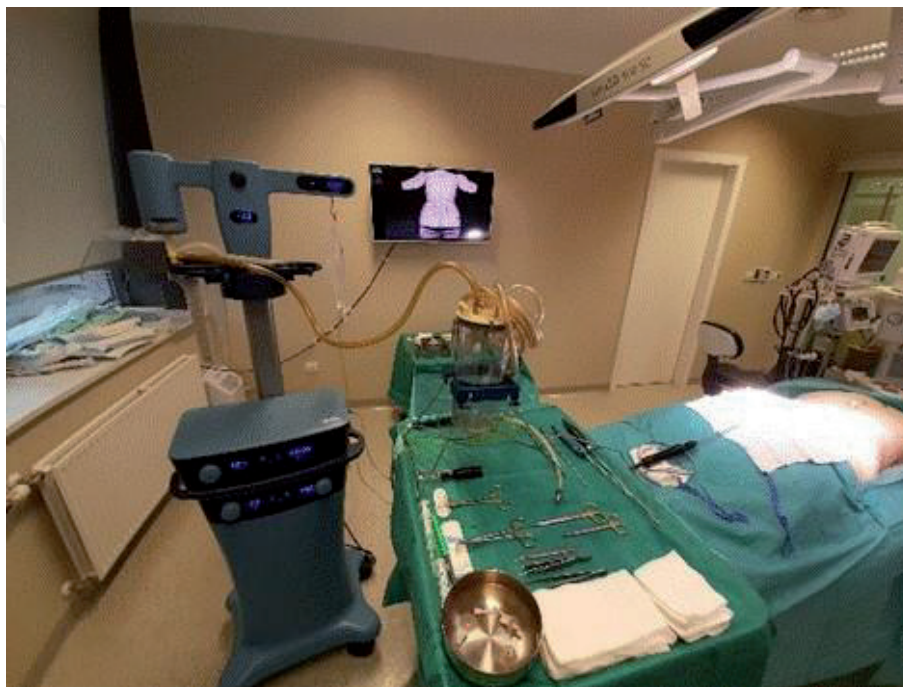
- contouring parts of the body,
- tightening the skin,
- removing cellulite, with emphasis on parts of the body affected by cellulite which can be painful.

Modern liposuction can also be done under local anesthesia, which in turn enables communicating with the patient throughout the entire surgical procedure and an adequate evaluation of pain. The procedure is ordinarily limited to suctioning up to 3 liters of fat, and the patient is able to quickly return home after the procedure. This form of anesthesia enables abdominoplasty to be performed without plication of the abdominal muscles.

Liposuction has undergone a significant evolution from its beginnings to current mass use. The third generation of ultrasound technology based on VASER® (vibration amplification of sound energy at resonance) [1, 2] offers safer liposuction and satisfactory results, especially when wanting to achieve better definition using surface liposuction (**Figure 1**).

The abdominoplasty procedure ordinarily comprises VASER liposuction [1, 2] of the lower or more often lower and middle section of the back and VASER liposuction of the lower chest area, hips, and abdominal wall, most often plication of the abdominal wall longitudinally and the removal of excess skin in a lateral direction in the area of the lower section of the abdominal wall [3, 4]. It is relatively a significant and long operation often accompanied by intense pain and difficult recovery. This can be most evident in the first days following the operation. Hence, attempts are being directed to devising a specific type of analgesic, which will provide patients with the fastest and least painful recovery, as well as a quick return to daily activities and work.

The abdominoplasty procedure begins with infiltration of the abdominal wall with a tumescent fluid: normal saline solution (0.9% NaCl) containing adrenaline (1 mg), bupivacaine (12,5 ml of 5 mg/ml), and sodium bicarbonate (10 mL of



**Figure 1.**  
*VASER device and surgical instrument setup.*



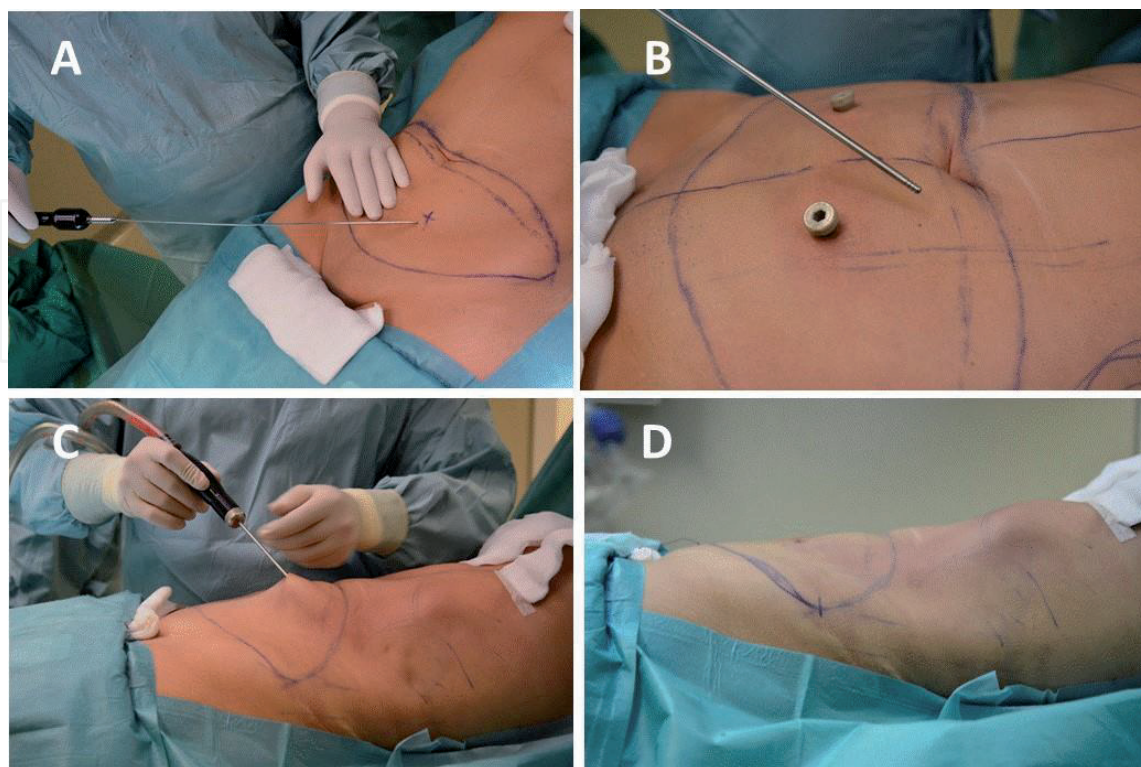
8.4% w/v), for each liter used [5]. It is then necessary to wait 10–15 min for the vasoconstriction and fat breakdown to take effect. The VASER used operates on an ultrasound principle which reduces larger segments of fat into smaller pieces, which in turn facilitates its removal. VASER technology provides a more sparing liposuction method that preserves blood vessels, nerves, and connective tissue, and consequently protects vascularization and sensitivity, while, on the other hand, acts specifically on fat and causes bloating and fragmenting of fatty tissue, facilitating the removal of fatty tissue into a less dense form. This reduces mechanical damage to tissue because the fat is more easily taken out using liposuction (**Figure 2**).

After a thorough liposuction, preserving vascularization and innervation of transitional structures and skin, the strengthening of the abdominal wall can commence, most often in terms of plication of the straight abdominal muscles (**Figure 3**).

In addition to the vertical strengthening of the abdominal wall, a horizontal or central plication is performed. This provides contours to the abdominal wall. Indeed, the BMI is always taken into consideration and should ideally be below 30. This is important, given that the internal abdominal content should be as minimally distended, as possible.

In this phase, a long-acting local anesthetic is administered [6, 7] to the plication area, the horizontal incision, and in the oblique radial direction, across the area of the abdominal wall, toward the hips. This is done to reduce pain in the initial phase, after the operation, and to achieve maximum recovery and mobilization. Optimally, this reduces more serious complications, such as deep vein thrombosis and pulmonary embolism, due to faster postoperative mobilization.

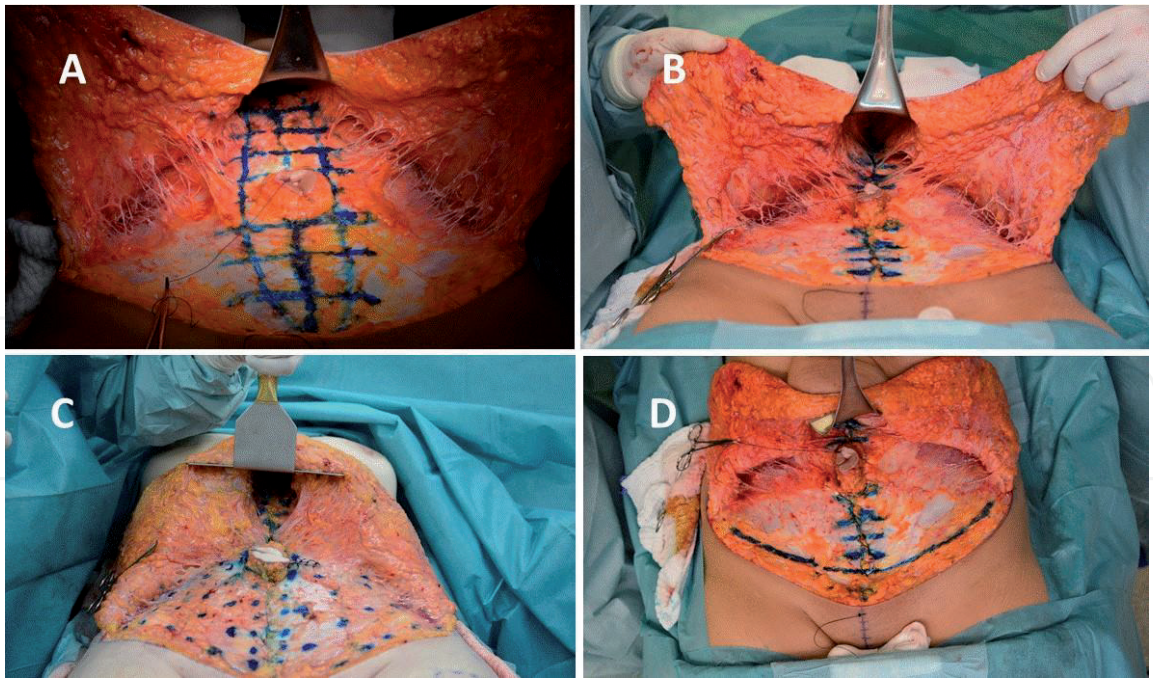
The next step is a fixation of the lower horizontal incision. Freeing the umbilicus and removing excess skin and subcutaneous tissue in the lower area of the abdominal wall are performed. Care is always taken to remove a similar amount of tissue on both sides (**Figure 4**).



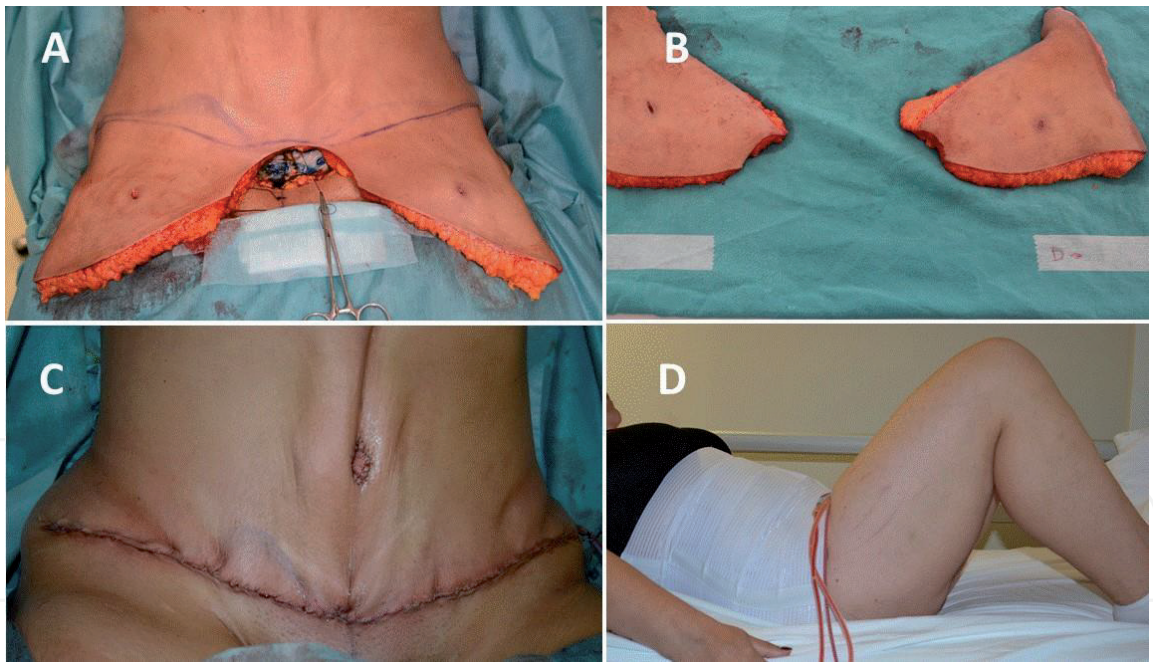
**Figure 2.**

*A: First part of the procedure is the infiltration of the abdominal wall, B: VASER probe with three rings for ultrasound application on the abdominal wall, C: VASER liposuction with VentX cannula, and D: Result immediately after VASER liposuction.*



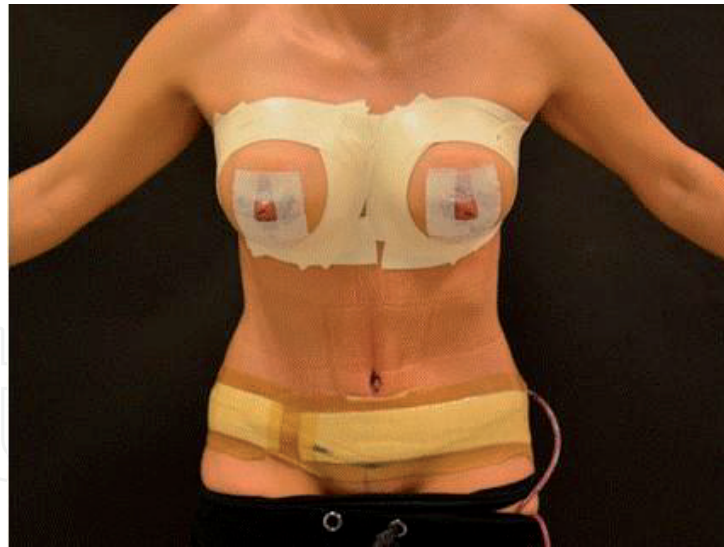


**Figure 3.**  
*A: Markings for plication of straight abdominal wall muscles, B: Result after plication of abdominal wall muscles, C: Markings for application of long-lasting infiltration analgesia, and D: Markings for fixation of lower abdominal wall straight scar.*



**Figure 4.**  
*A. Excess of skin and subcutaneous tissue in abdominoplasty patient. B. Removed tissue in abdominoplasty patient. C. Appearance at the end of abdominal wall surgery (abdominoplasty), and D. position in bed after abdominoplasty.*

Within this phase involves the further mobilization of skin and subcutaneous tissue, as required. The fixation of skin and subcutaneous tissue is performed horizontally and if necessary, vertically to a lesser extent, to achieve the desired results. The final phase involves further freeing of the navel, within the mobilized skin and subcutaneous lobe centrally and this is then fixed into a position just above the hips. Pressurized drains are placed to drain excess fluids. All the wounds are closed off in layers. Sterile surgical bandages and compression garments are applied. The bed should be with an elevated head position, the patient lying comfortably on



**Figure 5.**

*Final presentation and straight position of the patient day after surgery. This shows that patient can straight up without pain immediately after surgery. This is very important for overall recovery.*

their back, legs bent at the knees, to provide support, and careful not to stretch the freshly operated abdominal site (**Figure 5**).

### 3. Innervation of the abdominal wall

The thoracic ventral rami (intercostal nerves) are allocated mostly in the region of the anterolateral walls of the chest area and abdominal wall. There are 12 of them on each side, but only 11 are intercostal. Twelve pairs are situated under the last ribs and end in the subcostal area. The upper six pairs of intercostal nerves are limited to supplying the thoracic parietal region, and in addition, a significant number of fibers from the upper two pairs participate in forming the brachial plexus, innervation of the upper extremities. The lower five pairs of intercostal nerves and subcostal nerves supply the parietal region of the chest and abdomen area and provide fibers to the diaphragm [8].

Typically, the lower 7–12 thoracic and intercostal nerves extend longitudinally toward the thoracic abdominal wall under the respective ribs and intercostal veins. Behind, the nerves extend between the pleura and rear intercostal membrane, and then between the internal and most internal (last, rear) intercostal nerves. Each nerve provides collateral branches and lateral cutaneous branches. The last ones separate from the primary ramus only a few centimeters from the spine, lowering downward into the same intercostal layer as the larger nerves, extending longitudinally along the lower boundary of the intercostal area and ending in the front as small cutaneous nerves or as connected to the main ramus. The lateral cutaneous branch follows the main intercostal nerve to the middle axial line before penetrating the intercostal nerve obliquely and is divided into front and rear branches that have a larger cutaneous distribution. Intercostal nerves supply the intercostal, subcostal, and transversal thoracic muscles. The lower five or six intercostal nerves also supply filaments of the peripheral parts of the diaphragm [8].

The five lower intercostal nerves and subcutaneous nerves stem from the lower rib cartilage and enter the abdominal wall to supply oblique, transversal, and horizontal abdominal muscles and end as the anterior abdominal cutaneous branches. The tenth nerve serves as a dermatome at the umbilicus level. The lateral cutaneous branch of the subcostal nerve (T12) penetrates the internal and external oblique



muscles and then extends lower over the iliac crest so as to assist in supplying the skin on the lower lateral area of the groin [8].

The ventral primary ramus of the lower spinal nerves (five lumbar, five sacral, and one coccygeal) are divided and connect in a plexiform manner to form the lumbar, sacral, and coccygeal plexuses. They are interconnected as described earlier (rami communicantes) with the sympathetic trunks.

The lumbar plexus is formed with the ventral rami from the first three lumbar nerves and mostly the fourth (and also partly from the subcostal twelfth nerve). It is situated in front of the lumbar transverse vertebral body and sits in the rear section of the psoas major muscle which should be dissected for the plexus to be visible. The most common flow and distribution of plexus components and its relationship with bone structures as well as muscle and aponeurotic layers are shown on the next two pages, but consideration should be given to the fact that variations within the system of the lumbar plexus are frequent [8].

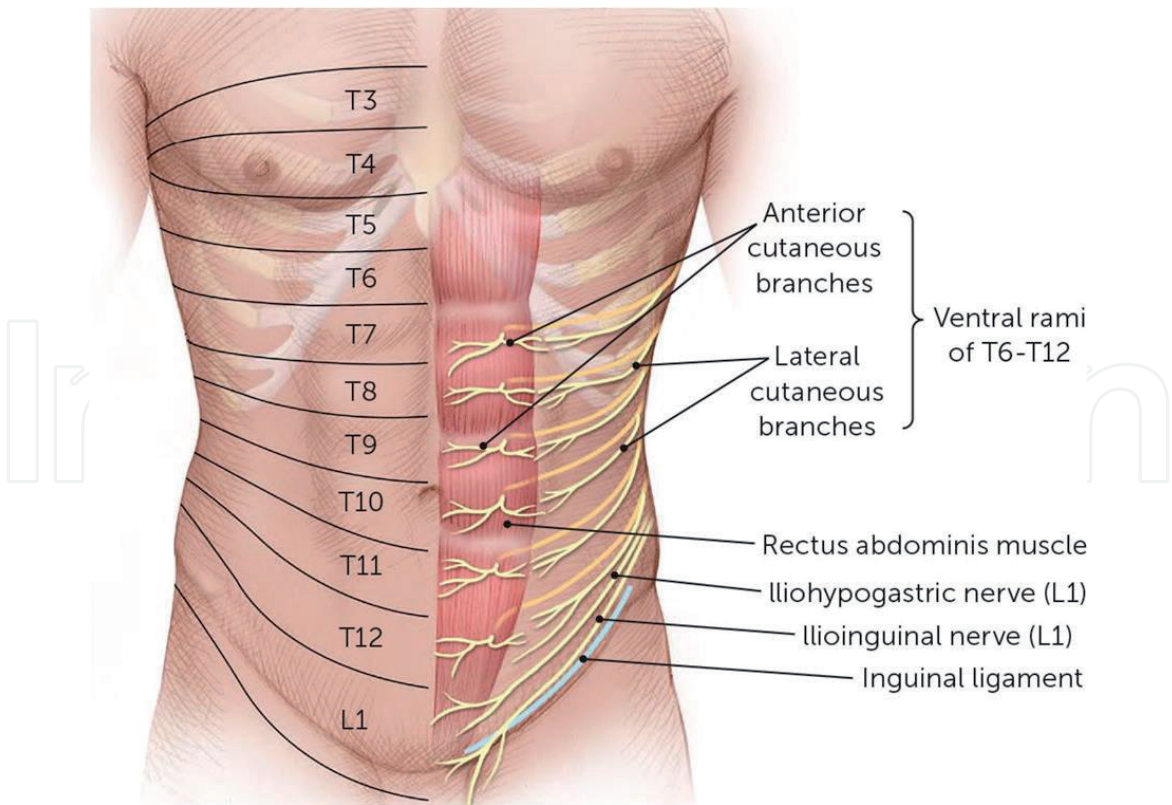
After gaining a branch from the subcostal nerve, the first lumbar nerve is divided into the upper and smaller lower branches. The last section in the iliohypogastric and ilioinguinal nerve is later connected to the branch of the second lumbar nerve to form the genitofemoral nerve. The remainder of the second lumbar nerve, third and fourth nerve that contribute to this plexus are divided into front and rear sections that in turn are connected to form the obturator and femoral nerves. The accessory obturator nerve, when present, forms from branches in the front section of the third and fourth nerves, whereas the lateral femoral cutaneous nerve appears with the fusion of small parts of the rear sections belonging to the second and third lumbar nerves. The muscle branches from the subcostal and upper four lumbar nerves supply the quadratus lumborum muscle and those from the first and second extend to the psoas major and minor muscles. The psoas major muscle is further innervated with branches from the third and sometimes fourth nerve, which also supplies the muscle iliacus [8].

The iliohypogastric and ilioinguinal nerves are similar to thoracic nerves based on their position and distribution and are analogous to the main trunks and collateral branches of the intercostal nerves. The last nerve provides the lateral branch, which passes over the iliac crest a short distance behind the respective branch of the subcostal nerve, where both nerves then extend to the skin in the upper lateral section of the groin. Extending toward the front branch of the iliohypogastric nerve, it sends filaments toward the transversal and oblique abdominal muscles, passing through the external oblique aponeurosis some 3 cm above the surface inguinal ring and ending with innervation of the skin above the pubis [8].

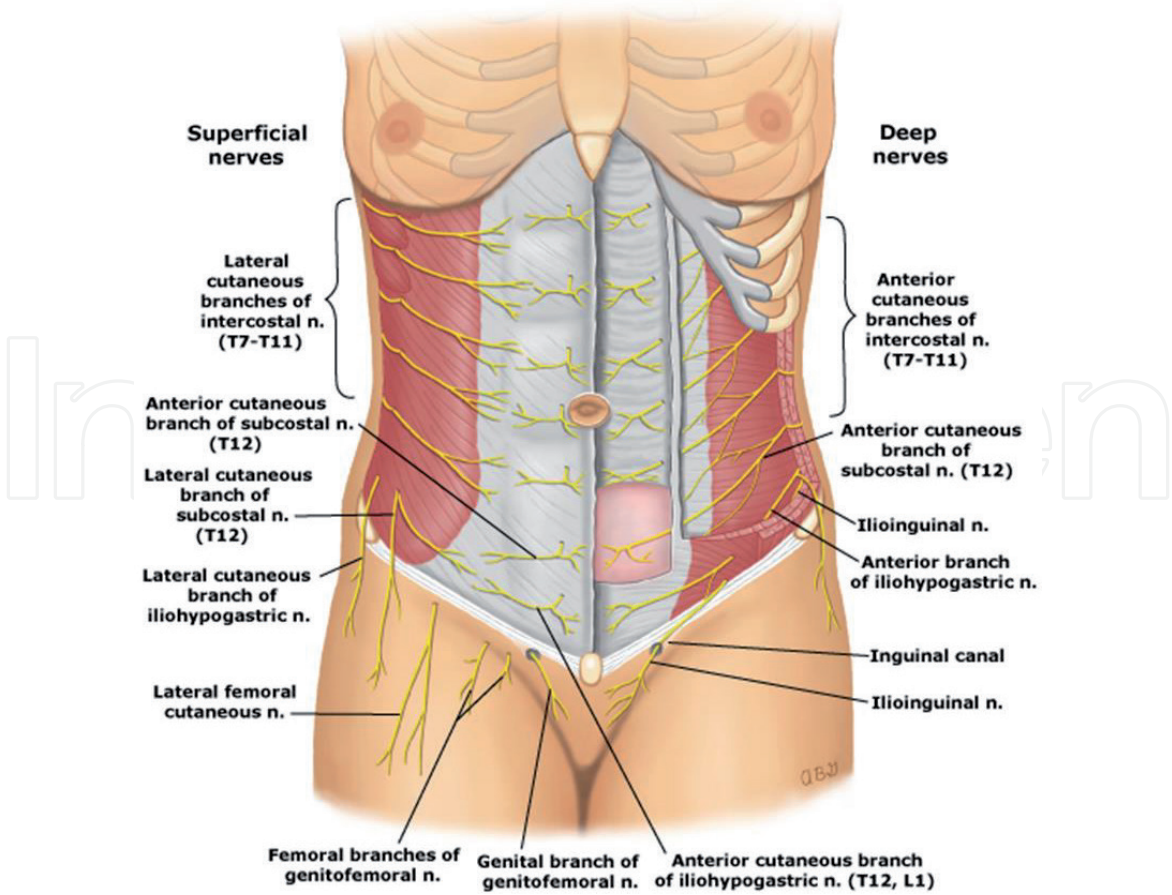
The ilioinguinal nerve supplies the filaments of the adjacent muscles and after passing through the same muscles, as is the case with the iliohypogastric nerve, it passes under the funiculus spermaticus and through the superficial inguinal ring to supply the upper internal side of the groin area, the root of the penis and front section of the scrotum in men as well as the mons pubis and labia majora in women [8].

After leaving the lumbar plexus, the genitofemoral nerve passes through the psoas major muscle and descends to its anterior surface behind the peritoneum, which is then segmented at the fifth lumbar level into the genital and femoral branches. The last branch enters the inguinal canal through the deep inguinal ring, supplying the cremaster muscle, and provides some branches for the scrotum skin and labia major (external spermatic nerve). The femoral (lumboinguinal) branch passes laterally from the external iliac and femoral artery, passing behind the inguinal ligament and after passing through the anterior layer of the femoral sheath and fascia lata branches into the surface skin and skin of the upper section of the femoral (Scarp's) triangle. The genitofemoral nerve and its branches carry many efferent and afferent fiber to and from the common iliac, external iliac, and femoral arteries [8].





**Figure 6.**  
*Innervation of the abdominal wall in the male patients [8].*



**Figure 7.**  
*Innervation of the abdominal wall in the female patients [8].*

The other branches of the lumbar plexus (larger branches, femoral nerve) with the exception of the muscular branches for the quadratus lumborum, psoas major, and muscle iliacus are allocated at the lower extremities and that is why they are not discussed here [8] (**Figures 6 and 7**).

#### **4. Prophylactic (preemptive) analgesia**

This kind of analgesia is a new approach to treating postoperative pain and blocks surgically caused painful sensitivity using regional or systematic anesthesia, prior to its onset. Therapeutic use of the prophylactic analgesia is based on local infiltration anesthesia (LIA) subcutaneous in the area planned for the surgical incision or for instance in the area of the abdominal wall.

LIA implies blocking incoming nerve paths prior to the onset of pain sensitivity due to incision of the skin and subcutaneous tissue, as well as contact with abdominal wall muscles, thereby preventing or reducing the level of pain occurring due to terminating paths of the nervous system between surgically sensitive organs and the brain [9].

The positive effects of a well-planned preemptive analgesia during a surgical procedure can be well utilized for the general well-being, meaning primarily for the patient, and then also for institutions in which the procedures are undertaken, because possible harmful effects can be well supervised and prevented under controlled conditions. Anesthesiologists in collaboration with surgeons determine the most effective preemptive analgesic regime for limiting sensibility of the nervous system throughout the entire perioperative period.

The concept of preemptive analgesia is based on advancements and research in the science of pain, as well as on clinically proven research. It has been shown that a surgical incision is not the only catalyst for central sensitivity of the nervous system, and accordingly, preemptive analgesia is further profiled and developed [10].

Regardless of the results obtained and proven in clinical research on animals, in clinical practice not only in Croatia but throughout the world, controversies do exist in terms of administering preventive analgesia. The reason for this is the general consensus that there is insufficient evidence as to the one-hundred-percent effectiveness of this manner of preventing postoperative pain. The recommendation is, therefore, to expand antinociceptive protection during the postoperative period, which ensures preventing analgesic infiltration, in order to include the most effective possible treatment for the inflammatory phase in the location of the operative area. Some studies on animals have shown that anesthesia techniques that deeply reduce the amount of information on pain reaching the spinal cord and brain may prevent central sensitivity and reduce pain-linked behavior when given prior to the onset of pain [11].

#### **5. Description of analgesia applied to the abdominal wall**

As we have previously described in the anatomy section, it is clear that there is a nerve supply in the area of the abdominal wall from T7–11 intercostal nerves and the T12 subcostal nerve, leading to the anterior and lateral segments, as well as the iliohypogastric and ilioinguinal nerves and their branches. Based on the actual procedure and experience, painful stimuli of the abdominal wall are certainly caused by liposuction, plication of the abdominal wall, lower fixation of the lateral scar,



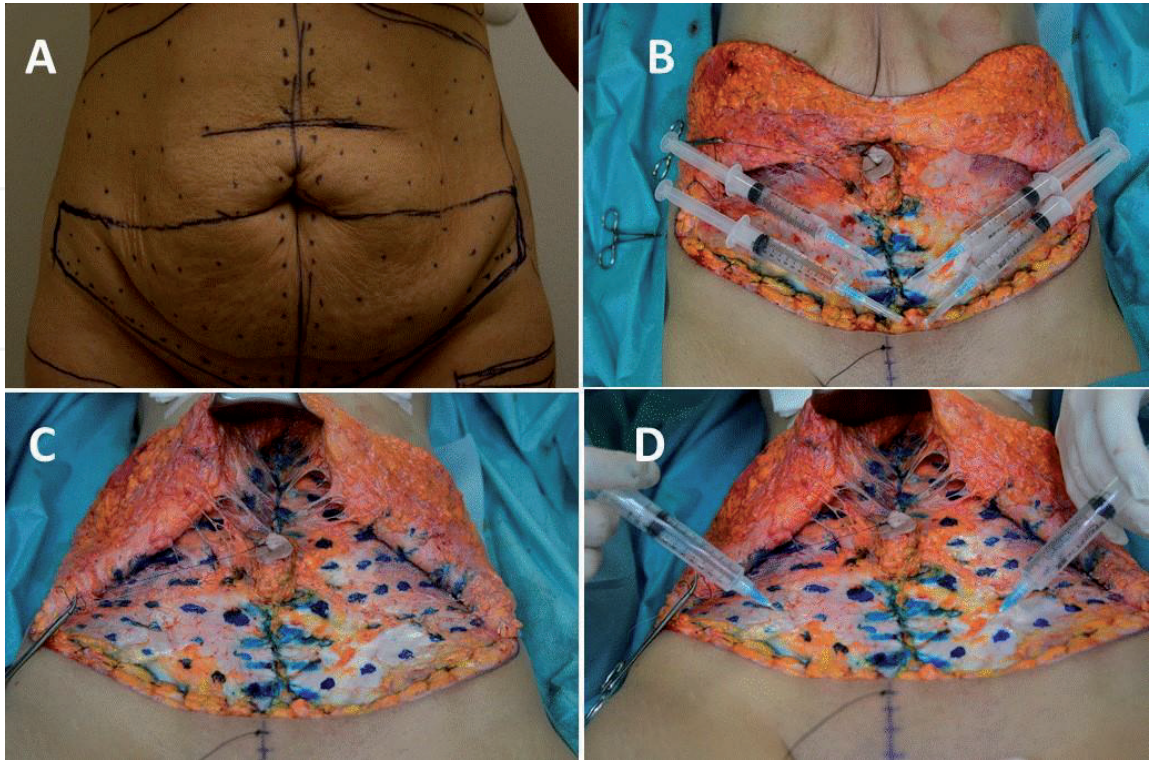
and closing of wounds. This is the main reason why, in the earlier stages of general analgesia and liposuction, the decision to administer additional analgesia into the abdominal wall with 40 mL of levobupivacaine or bupivacaine (0.5%) is used. This step is very important, depending on the availability of local long-lasting anesthetics and analgesics [9].

The pattern of administering the local anesthetic is radial, in the form of a fan-shape. It is applied with a G23 needle, administered centrally, toward the sides, and in the region of the horizontal incision, approximately 40 injections on each side, using 40 ml of the solution. Each jab provides 0.5 ml of local anesthetics.

Levobupivacaine, as opposed to lidocaine, is a long-lasting local anesthetic, providing significantly more than 2–3 h of anesthesia (>9 h) and up to 24 h as analgesia [6, 7]. It acts by blocking transmission in sensory and motor nerves through sodium channels on the cell membrane, but also by blocking potassium and calcium channels. It is far less systemically toxic than lidocaine. It is used as an anesthetic in larger surgical procedures, for instance as an epidural during a cesarean section, as well as an anesthetic in smaller surgical procedures, like those done on the eye. It is used as an analgesic for epidural infusion in treating postoperative pain or as an analgesic during labor. It is contraindicated for patients with known sensitivities against levobupivacaine and bupivacaine, or some of the auxiliary substances, as an intravenous regional anesthesia, and in patients with cardiovascular shock due to serious hypotension.

Due to its known interaction with some drugs, an important factor in the proper and quality administering of levobupivacaine is the experience of the operator.

The most often recorded adverse side effects are mostly related to the side effects based on the group of drugs to which it belongs, which includes hypotension, nausea and vomiting, anemia, dizziness, headache, pyrexia, and fetal distress syndrome. Compared to bupivacaine, levobupivacaine has been shown to have a long-lasting effect, less indirect toxicity, reduced cardiac effect in terms of bradycardia, and a weaker depressive effect on the CNS **Figure 8**.



**Figure 8.** A. Plan of application of local abdominal wall analgesia on the skin. B. Long-lasting local infiltration prepared for application. C. Plan for application of local infiltration analgesia in the abdominal wall, and D. application of long-lasting local anesthetic in the abdominal wall.



## 6. Treating acute postoperative pain

In the literature as well as in clinical practice, pain treatment is often addressed in procedures involving modern analgesia, which, in addition to the continual administering of drugs, implies the continual evaluation of pain, with the aim of titrating the administering of analgesics depending on the changes to pain intensity. All available and applied processes, whether it involves techniques for overcoming pain or administering drugs, must satisfy criteria requiring minimal negative effects on patient mobilization, which in turn means preventing the onset of expected complications and their least possible manifestation. Therefore, the basis for solving postoperative pain is preemptive action, which has the following goals:

- Preventing and halting the transmission of painful stimuli to the central nervous system,
- Preventing the onset of excessive oversensitivity to pain, that is, hyperalgesia, as well as preventing allodynia, which is the onset of pain due to non-painful stimuli,
- Thirdly, reducing the sensitivity of the central nervous system.

In patients who have undergone liposuction and abdominoplasty, the expected period of the presence of pain is relatively long. Therefore, a standardized approach is used in pain management, where an important role is given to the medical nurse as part of the team. It is necessary to do the following:

- Inform the patient of the available methods for preventing postoperative pain,
- Encourage the patient to articulate their sense of pain,
- Educate patients on the importance of taking analgesics over an agreed period of time at intervals,
- Show the exceptional importance of regular medical checkups and regular pain evaluation in order to undertake corrections to analgesic therapy.

Administering analgesics mostly implies the use of opioids. Opioid analgesics have quite a wide range of difficulties and complications, and their use requires educated personnel, in order to achieve the best effect with minimal side effects. Opioid doses used to act on acute postoperative pain are very low; hence, the negative effects are minimal to almost unnoticeable, whereas the interval of administering them is varied depending on the evaluation, which in the first hours is measured in intervals for at most one hour.

Doses are repeated until the desired effect is achieved, and the level of pain is reduced to under level 3 on the VAS scale of 10. The prescribed algorithm for administering drugs given estimates based on the VAS scale is as follows:

- Level 1—pain on the VAS scale amounting to 4—non-opioid and adjuvant drugs,
- Level 2—pain on the VAS scale amounting to between 4 and 7—non-opioid, opioid, and adjuvant drugs,

- Level 3—pain on the VAS scale amounting to between 7 and 10—strong opioids, non-opioids, and adjuvant drugs.

According to this model of levels, the principles in administering drugs are as follows:

- Whenever possible per axis,
- Administer in exactly specified intervals,
- Administer according to a level-based schedule.

Among the non-pharmacological techniques in treating postoperative pain, a psychological approach has been proven to be adequate by reducing anxiety and fear as well as preventing sleep disorders, and also contributing to the well psychological condition of the patient.

The psychological approach is achieved through the following:

- Good quality information provided to the patient,
- Relaxation techniques—proper breathing, muscular relaxation,
- Stress management.

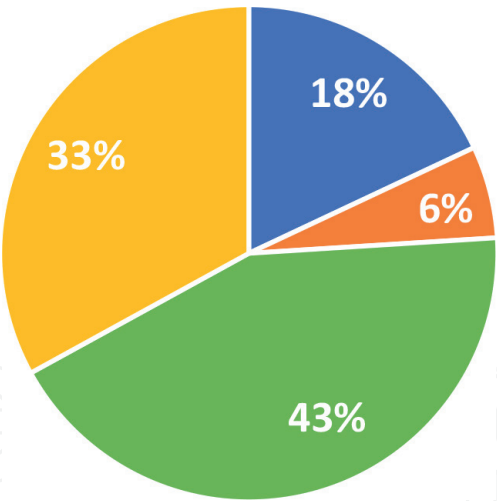
## 7. Our experience with the described technique

We have analyzed a total of the 30 most recent patients ( $N = 30$ ) on whom the VASER liposuction and abdominoplasty procedures were undertaken at the Bagatin Polyclinic in Zagreb. The patients were analyzed in the 2020/2021 period. About 67% of the patients were women, and 33% were men. The surveyed group of women ranged from 19 to 51 years old, and the men varied from 21 to 61 years of age. The bodyweight of the women ranged from 46 to 110 kg and a body height from 155 to 178 cm. The bodyweight of the men ranged from 63 to 108 kg, and a height from 167 to 190 cm. Of the 30 subjects undergoing VASER liposuction and abdominoplasty, 13 were smokers of which 9 were women and 4 men, and 17 were nonsmokers, that is, 12 women and 5 men. In terms of the ASA score, 17 were categorized into Group 1, 12 into Group 2, and 1 into Group 3. All patients were recommended not to smoke 4–6 weeks prior to the operation and also the period after the procedure. The longest operation lasted 8 h and 30 min, and the shortest was 2 h.

Of the total number of subjects who required analgesics in the postoperative period, 69% receive the drug immediately and 29% in less than 10 min, and 2% had no need for analgesics. In all, 64% of the subjects who received some form of an analgesic did not report any of the examined difficulties such as tenderness and soreness, prolonged loss of sensation, difficulty with breathing, headaches, sleepiness, itchiness, or constipation. In the remaining 36% of subjects, vomiting was present.

On a scale of 1–5, as to the question of assessing satisfaction with hospitalization, 100% of the subjects provided a score of 5. Also, all 100% of subjects received directions on pain treatment immediately while being discharged.

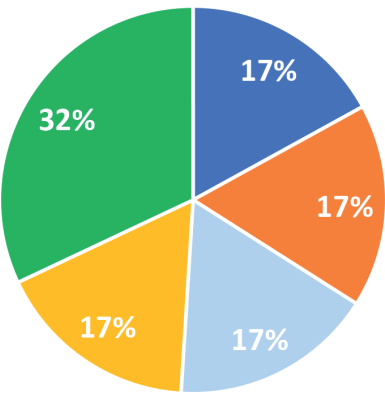
Upon being discharged to home care, 60% of the operated patients continued to take analgesics in the period ranging from 3 to 15 days. **Figure 9** shows the number



**Figure 9.**  
*Percentage of patients taking analgesics at home.*

% of patients and number of days completely stopping analgesia

■ 33 ■ 10 ■ 9 ■ 8 ■ 5



**Figure 10.**  
*Percentage of patients and the number of days completely stopping analgesia.*

of patients who took analgesics at home, and **Figure 10** shows the number of days after completing ceasing to take analgesics.

Of the total number of operated patients, 7% said that the recommended analgesics were sufficient in overcoming pain, and 93% took medication only temporarily when experiencing stronger pain. In the period covering 10 days of home care, 20% completely ceased taking analgesics. A month after the surgical procedure, the level of pain in the subjects had significantly subsided, whereas the level of pain after three months had almost completely ceased in almost all patients.

## 8. Discussion

The fan-shaped, local infiltration anesthesia (LIA), this technique provides a more dispersed area of anesthetic coverage. Although this technique can be more expensive due to the cost of longer-lasting local anesthetic drugs, it allows for an increased certainty that all desired areas will have adequate pain relief, with minimal breakthrough or patchiness. As presented in pain scoring and drug



requirements for pain relief data, the pain scores were significantly reduced, a shorter duration of analgesia was required, and overall patient satisfaction was increased. The advantages seen with this technique are as follows: a faster, more complete analgesic spread in the operative area, less areas being missed out or untouched, reduced postoperative pain, reduced need for long-term analgesic requirements, and increased patient satisfaction. The ripple effect of these advantages leads to faster mobilization, improved and enhanced healing, a faster convalescent stage, and a return to a preoperative functioning state.

## **9. Conclusion**

Fan-shaped LIA is a preventative procedure in managing acute postoperative pain which is based on the systematic, targeted infiltration of local anesthetics plus adrenaline to the operative area which in this case is the abdominal muscular wall. The fan-shaped LIA technique enables quick mobilization of patients and their early discharge.

Pain symptoms are considered an ideal parameter for assessing the quality of the fan-shaped LIA application, in postoperative patient care, not only in hospital environments but also in outpatient surgical practices. Pain management as part of medicine has undergone vast development in the last two decades. However, the treatment of pain still needs to be addressed adequately, which means establishing a specific series of protocols in order to prevent and not only treat pain. The statement, “better to prevent than treat” states a lot about this aspect.

The modern era has placed before us a great challenge, not only before physicians and other health care experts, but also the entire system of management in every country, in order to identify a better way of organizing work, and allocating work tasks on a daily basis, in order to eliminate obstacles that stand in the way to successful practices in pain management. The effectiveness of treating pain is closely linked to an awareness of consequences stemming from suffering caused by pain, including the psychology of pain, the effects of stressors from the immediate environment, cognitive perceptive abilities of persons, and life attitudes.

Administering long-lasting local anesthetics prior to and after a surgical procedure has a significant effect on reducing the intensity of postoperative pain due to surgical procedures involving VASER liposuction and abdominoplasty, which leads to discharging patients from the polyclinic on the same day as undergoing the surgical procedure, or at most within 48 h after the procedure.

Administering fan-shaped LIA intraoperatively into the abdominal wall provides early mobilization and quicker recovery of patients. The fact that patients feel less soreness within the first 48 h after the surgical procedure, their ability to actively mobilize earlier, and their satisfaction gives confirmation to use this method routinely.

IntechOpen

### Author details

Dinko Bagatin<sup>1,2\*</sup>, Tomica Bagatin<sup>1,2</sup>, Judith Deutsch<sup>1,2</sup>, Katarina Sakic<sup>1,2</sup>,  
Johann Nemrava<sup>1,2</sup>, Eduardo Isomura<sup>1,2</sup> and Martina Sarec Ivelj<sup>1,2</sup>

1 Poliklinika Bagatin, Zagreb, Croatia

2 Faculty of Dental Medicine and Health Osijek, University of Josip Juraj,  
Osijek, Polyclinic Bagatin, Zagreb, Croatia

\*Address all correspondence to: [dinkobagatin@gmail.com](mailto:dinkobagatin@gmail.com)

### IntechOpen

© 2021 The Author(s). Licensee IntechOpen. This chapter is distributed under the terms of the Creative Commons Attribution License (<http://creativecommons.org/licenses/by/3.0>), which permits unrestricted use, distribution, and reproduction in any medium, provided the original work is properly cited. 

## References

- [1] Hoyos AE, Millard JA. VASER-assisted high definition lipoplasty. *Aesthetic Surgery Journal*. 2007;27(6):594-604. DOI: 10.1016/j.asj.2007.08.007
- [2] Hoyos A, Perez ME, Guarin DE, Montenegro A. A report of 736 high-definition lipoabdominoplasties performed in conjunction with circumferential VASER liposuction. *Plastic and Reconstructive Surgery*. 2018;142(3):662-675. DOI: 10.1097/PRS.0000000000004705
- [3] Avelar JM. Abdominoplasty combined with lipoplasty without panniculus undermining: Abdominolipoplasty—A safe technique. *Clinics in Plastic Surgery*. 2006;33(1):79-90. DOI: 10.1016/j.cps.2005.08.007
- [4] Shiffman MA, Mirrafati S. *Aesthetic Surgery of the Abdominal Wall*. Berlin Heidelberg: Springer-Verlag; 2005
- [5] Klein JR, Heaton JP, Thompson JP, Cotton BR, Davidson AC, Smith G. Infiltration of the abdominal wall with local anaesthetic after total abdominal hysterectomy has no opioid-sparing effect. *British Journal of Anaesthesia*. 2000;84(2):248-249. DOI: 10.1093/oxfordjournals.bja.a013412
- [6] Burlacu CL, Buggy DJ. Update on local anesthetics: Focus on levobupivacaine. *Therapeutics and Clinical Risk Management*. 2008;4(2):381-392. DOI: 10.2147/tcrm.s1433
- [7] Babst CR, Gilling BN. Bupivacaine: A review. *Anesthesia Progress*. 1978;25(3):87-91
- [8] Netter FH. *Atlas of Human Anatomy*. 7th ed. Elsevier; 2019
- [9] Bagatin D, Bagatin T, Nemrava J, Sarec Ivelj M, Deutsch J, Sakic K. Influence of local infiltration analgesia on postoperative pain in abdominoplasty patients. *Acta Clinica Croatica*. 2019;58(Suppl 1):23-28. DOI: 10.20471/acc.2019.58.s1.03
- [10] Katz J. Pre-emptive analgesia: Evidence, current status and future directions. *European Journal of Anaesthesiology*. 1995;10(Suppl):8-13
- [11] Dickenson AH, Le Bars D. Supraspinal morphine and descending inhibitions acting on the dorsal horn of the rat. *The Journal of Physiology*. 1987;384:81-107. DOI: 10.1113/jphysiol.1987.sp016444