

We are IntechOpen, the world's leading publisher of Open Access books Built by scientists, for scientists

6,900

Open access books available

185,000

International authors and editors

200M

Downloads

Our authors are among the

154

Countries delivered to

TOP 1%

most cited scientists

12.2%

Contributors from top 500 universities



WEB OF SCIENCE™

Selection of our books indexed in the Book Citation Index
in Web of Science™ Core Collection (BKCI)

Interested in publishing with us?
Contact book.department@intechopen.com

Numbers displayed above are based on latest data collected.
For more information visit www.intechopen.com



Pelvic Anatomy for Distal Rectal Cancer Surgery

Sanghyun An and Ik Yong Kim

Abstract

Worldwide, colorectal cancer is the third most common cancer and one of the leading causes of cancer-related deaths. Currently, total mesorectal excision (TME) is considered as the gold standard surgical procedure for rectal cancer. To achieve a good oncologic outcome and functional outcome after TME in distal rectal cancer, exact knowledge regarding the pelvic anatomy including pelvic fascia, pelvic floor, and the autonomic nerve is essential. Accurate TME along the embryologic plane not only reduces local recurrence rate but also preserves urinary and sexual function by minimizing nerve damage. In the past, pelvic floor muscles and autonomic nerves could not be visualized clearly, however, the development of imaging studies and improvements of minimally invasive surgical techniques such as laparoscopic and robotic surgery can clearly show the anatomy of the pelvic region. In this chapter, we will provide accurate anatomy of the rectum and the anal canal, pelvic fascia, and the pelvic autonomic nerve. This anatomical information will be an important indicator for performing an adequate operation for distal rectal cancer.

Keywords: rectal neoplasms, anatomy, colorectal surgery, autonomic nervous system, pelvic floor

1. Introduction

Colorectal cancer is the third most common cancer and the fourth leading cause of cancer-related deaths worldwide [1]. Especially, rectal cancer accounts for 30–40% of colorectal cancer, and the treatment strategy is different and more complicated compared to colon cancer because of its anatomical features. Although the treatment outcome of rectal cancer has greatly improved with the development of multimodality treatment including neoadjuvant radiotherapy, cytotoxic chemotherapy, and target agents, surgery remains the mainstay of therapy. Since the concept of total mesorectal excision (TME) was first described by Richard Heald in 1979, this procedure became the gold standard technique for rectal cancer surgery until now [2]. The fundamental principle of TME is en bloc resection of the rectum with its surrounding fatty tissue complex which contains the blood vessels and lymphatics down to the pelvic floor. To achieve complete TME and sphincter preserving surgery in low-lying rectal cancer, knowledge for regarding the pelvic fascia (mesorectal, parietal) and autonomic nerves, a thorough understanding of the pelvic floor anatomy is essential.

2. Pelvic anatomy

2.1 Basic anatomy of the rectum and mesorectum

The rectum is the most distal part of the large intestine that exists from the sacral promontory level to the anorectal ring. The anterior and lateral portion of the upper one-third of the rectum is covered with peritoneum, and the middle one-third of the rectum is covered with peritoneum on its anterior portion. The lower one-third cannot be observed in the intraperitoneal space because it is located in the extraperitoneal space. The taenia coli disappears in the rectum, forming one longitudinal muscle layer surrounding the rectum. The length of the rectum is approximately 12-15 cm and has three curvatures, which is related to Houston's valves. The upper and lower part are convex to the right, and the middle portion is convex to the left. The middle valve is the most prominent and is located approximately equal to the level of peritoneal reflection [3].

The rectum is surrounded by a fatty tissue complex called the mesorectum, which corresponds to the mesentery of the rectum. Mesorectum contains abundant blood vessels, lymphatics, and lymph nodes, and it is enveloped by thin visceral pelvic fascia [4]. It is developed thickest in the posterolateral side and the anterior part is formed relatively thin. In addition, the volume of the mesorectum decreases as it approaches the pelvic floor, and disappears approximately 2 cm above the levator ani muscle (**Figure 1**). A number of studies have revealed that the mesorectum is an important structure for tumor spreading, and en bloc resection through sharp dissection of mesorectum is very important in improving treatment outcomes [2, 5, 6].

2.2 Fascia structures around the rectum

Dissecting the correct anatomical plane can lead to good oncological outcomes and preserve the autonomic nerves to prevent postoperative urinary, sexual, and defecatory dysfunction. If pelvic dissection is performed along the exact embryologic fascial plane, the operation can be done without bleeding. To perform precise total mesorectal excision, a thorough understanding of the fascia around the rectum and pelvic cavity is essential. **Figure 2** shows the anatomical relationship of the fascia around the rectum.

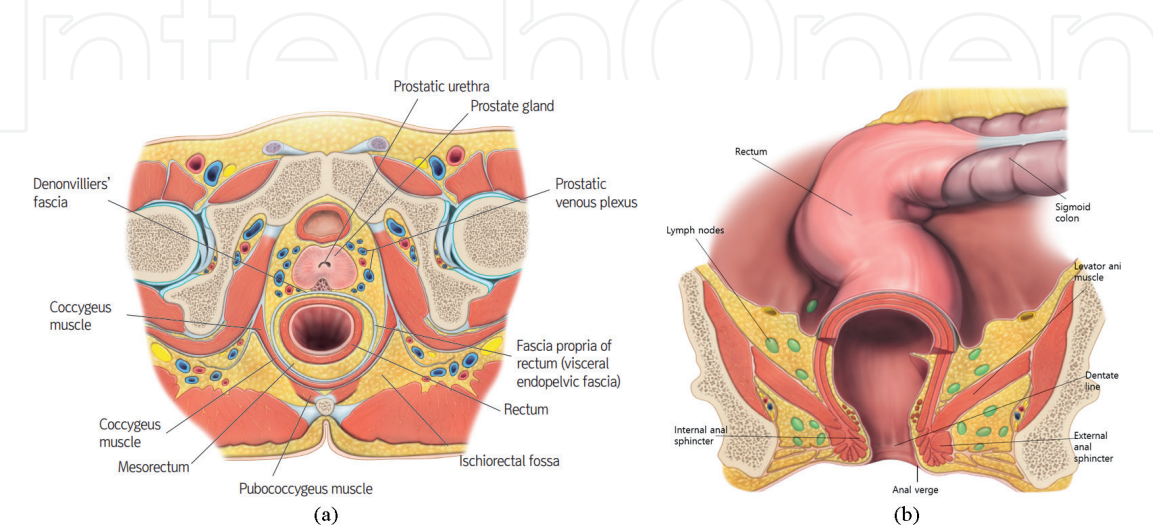


Figure 1. Anatomy of the rectum and mesorectum. (a) Structures around the rectum. The rectum is surrounded by mesorectum, and the rectum and mesorectum are enveloped by the fascia propria of the rectum. (b) Total mesorectal excision (TME). En bloc resection of mesorectum is important.

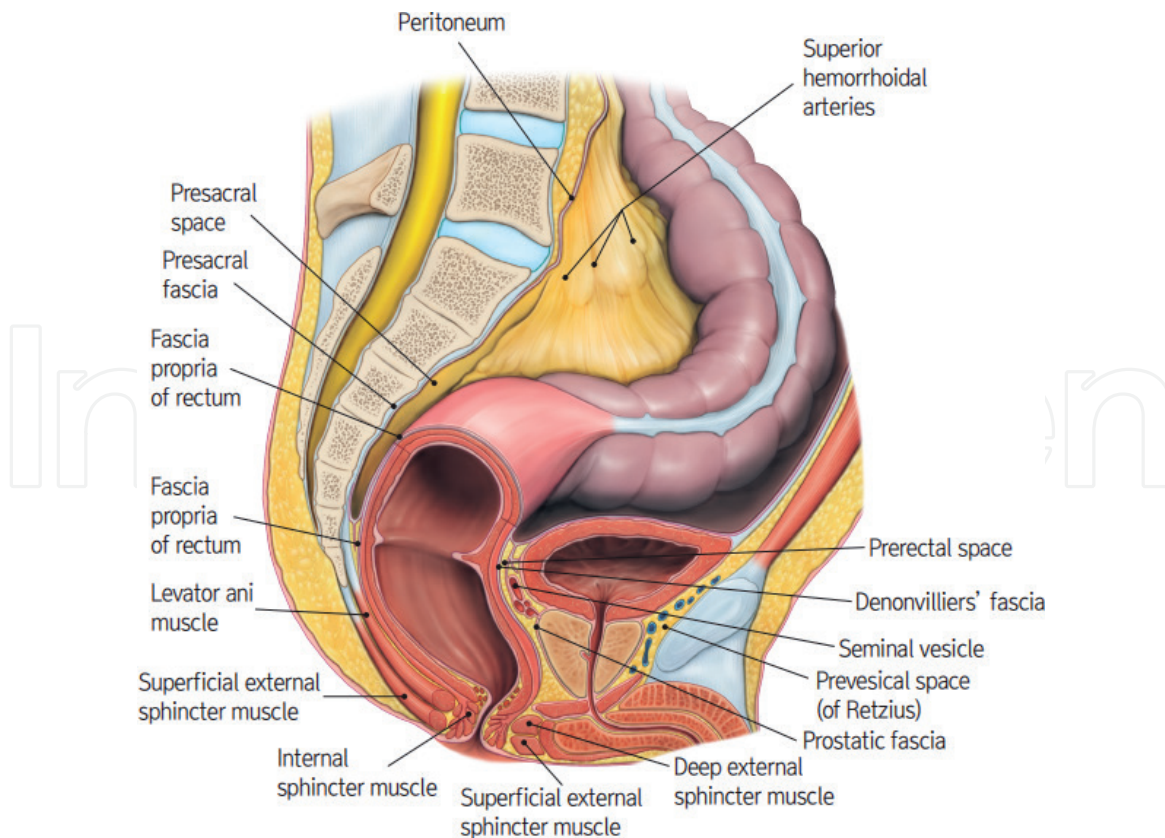


Figure 2.
Anatomy of fascia around the rectum. The fascia propria of the rectum covers the rectum and mesorectum. The presacral fascia covers the anterior surface of the sacrum. It combines with the fascia propria of the rectum at the S4 level (recto-sacral fascia = Waldeyer's fascia). Denonvilliers' fascia is a dense membrane between the rectum and seminal vesicles.

2.2.1 Fascia propria of the rectum and presacral fascia

The rectum and mesorectum are enveloped by the fascia propria of the rectum, also called as mesorectal fascia. The mesorectal fascia corresponds to the visceral fascia of the rectum. Caudally, it ends at the internal sphincter and laterally ends at the internal iliac artery, and is connected to the parietal pelvic fascia [7]. A magnetic resonance image scan (MRI) can clearly show the boundaries of these mesorectum and mesorectal fascia (**Figure 3**). During total mesorectal excision, it is important to completely excise this mesorectal fascia without damage to obtain optimal oncologic outcome [6, 8, 9].

The presacral fascia, also called as parietal pelvic fascia, covers the anterior surface of the sacrum and encloses the sacral vessels and nerves. It combines with the mesorectal fascia at the S4 level and became part of the anococcygeal ligament at the level of anorectal junction. The presacral venous plexus is formed by the two lateral sacral veins, the middle sacral vein, and the communicating veins, and it runs underneath the presacral fascia. If the dissection plane is too deep to damage the presacral fascia during the posterior dissection, life-threatening massive bleeding can occur and it often is difficult to control. Therefore, dissection should be done along with the space between the mesorectal fascia and the presacral fascia until the recto-sacral fascia is encountered [10, 11].

2.2.2 Recto-sacral fascia (Waldeyer's fascia)

Recto-sacral fascia, also known as Waldeyer's fascia, is a dense connective tissue linking the presacral fascia to the mesorectal fascia at the S4 level. As the

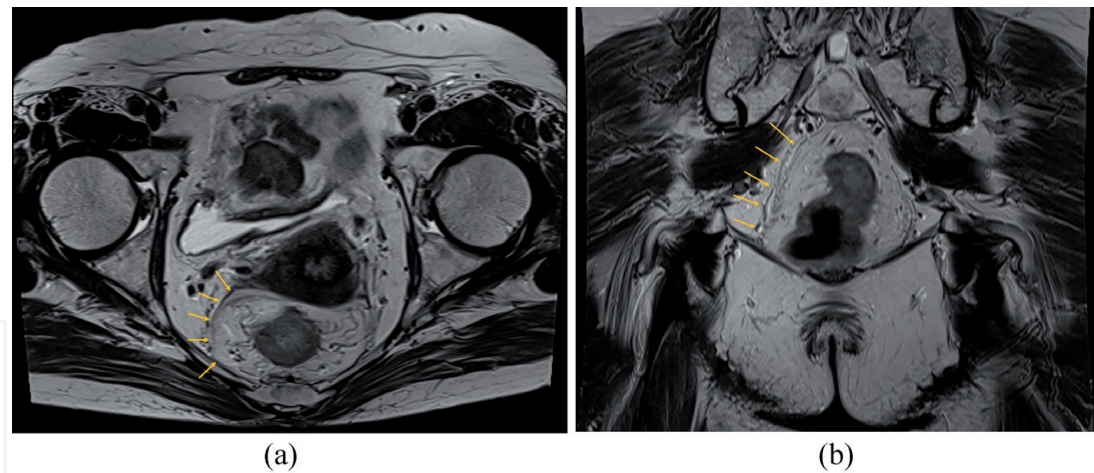


Figure 3. Magnetic resonance image scan. Magnetic resonance image scan (MRI) can clearly show the boundaries of these mesorectum and mesorectal fascia. (a) T2 weighted image on MRI. Axial view. The rectum and mesorectum are enveloped by the fascia propria of the rectum (mesorectal fascia). (b) T2 weighted image on MRI. Coronal view. Mesorectum, mesorectal fascia, and puborectalis muscle.

posterior dissection proceeds down along the plane between the mesorectal fascia and the presacral fascia, a dense, tough recto-sacral fascia is identified. To enter the retro-rectal space and reach the pelvic floor, this fascia must be incised and dissected further caudally. This fascia has a different thickness from individuals, it is not visible when it is too thin. Because the presacral artery and venous plexus and autonomic nerves pass behind this fascia, it is important to perform sharp division to avoid excessive bleeding due to presacral vein injury (**Figure 4**) [8, 12].

2.2.3 Denonvilliers’ fascia

During the anterior dissection of the rectum, a thin, dense connective tissue layer known as the Denonvilliers’ fascia presents between the seminal vesicles and

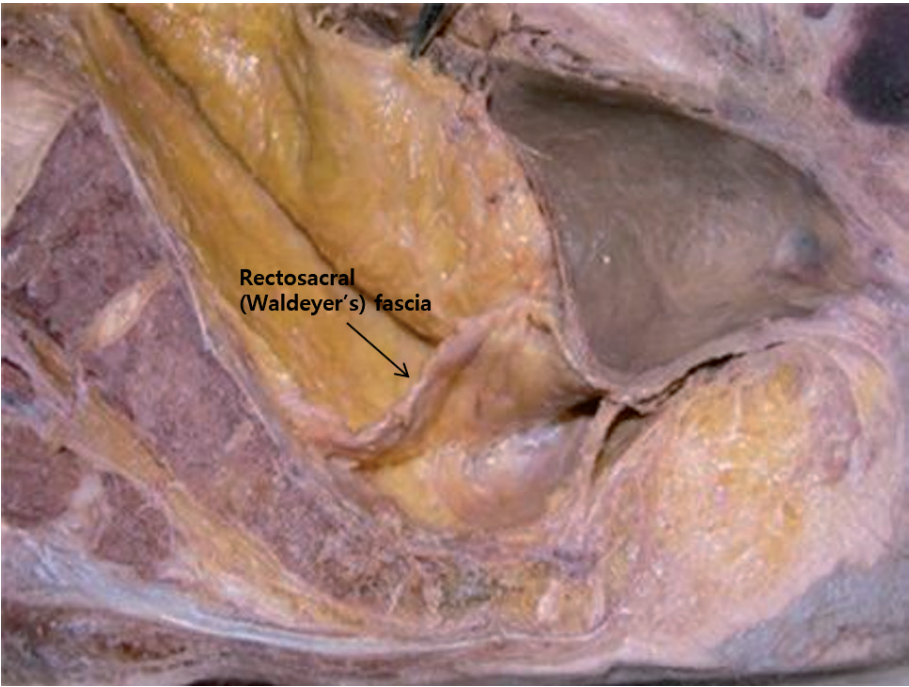

Figure 4. Recto-sacral fascia (Waldeyer’s fascia). Recto-sacral fascia (Waldeyer’s fascia) is a dense connective tissue linking the presacral fascia to the mesorectal fascia at the S4 level. It is important to perform sharp dissection [11].

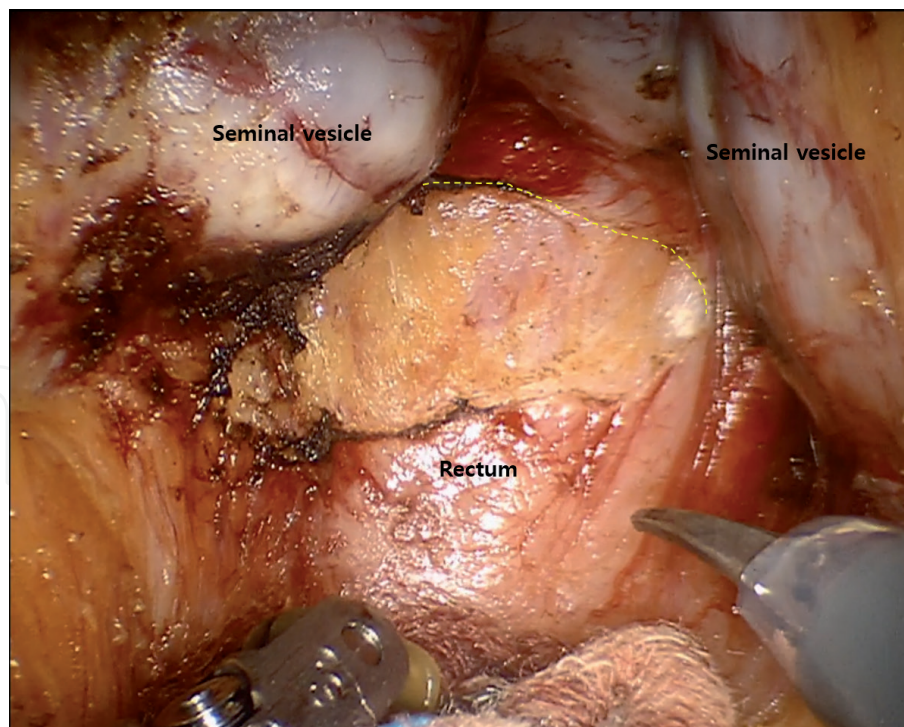


Figure 5.
Denonvilliers' fascia. During anterior dissection of the rectum. The dense connective tissue between rectum and seminal vesicles can be seen. The dissection should be performed below the Denonvilliers' fascia.

rectum [13]. The rectum can be separated from the seminal vesicles and prostate by opening this membrane at the level of anterior peritoneal reflection. After incising the fascia and entering the embryologic plane between the rectum and the seminal vesicles, the dissection should be performed below the Denonvilliers' fascia [14]. It is because there were neurovascular bundles running from the pelvic plexus to the ventral side of the Denonvilliers' fascia, especially in the directions of 10 and 2 o'clock, and these neurovascular bundles were related to urogenital function (**Figure 5**) [15]. However, if the deeply infiltrative tumor is located on the anterior wall of the rectum, the dissection should be performed in front of the Denonvilliers' fascia for curative resection. In females, there is a thin membranous structure that separates the rectum and vagina, which is called the rectovaginal septum. Although Denonvilliers reported that the Denonvilliers' fascia was not present in females, many researchers considered that the rectovaginal septum was consistent with the Denonvilliers' fascia in males (**Figure 6**) [16–19]. During the anterior dissection of the rectum in female, care must be taken not to perforate the vagina since this septum is very thin.

2.3 Anal canal

The rectum enters the pelvic floor and becomes the anus. The anal canal is defined as from the dentate line to the anal verge by anatomists, but most surgeons consider the anal canal from the anorectal ring to the anal verge [20]. The anorectal ring is where the rectum enters the pelvic floor and is angled by the puborectalis muscle. This ring can be palpated by a meticulous digital rectal exam. The dentate line, which divides the upper two-thirds and lower third of the anal canal, is an anatomically important landmark of the anal canal, and there are 6–14 longitudinal folds on the dentate line known as columns of Morgagni (**Figure 7**). The upper and lower part of the anal canal differs in venous and lymphatic drainage, innervation, and the epithelial surface based on the dentate line. Above the dentate line, the blood drains into the portal venous system, and lymphatics drains to the superior

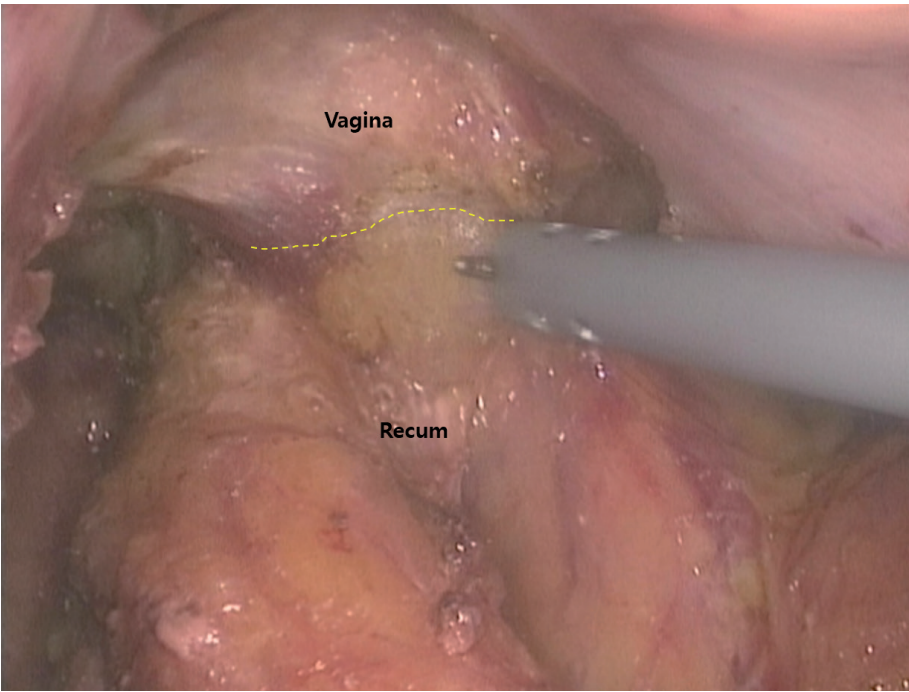


Figure 6.
Rectovaginal septum. In female, the rectovaginal septum was consistent with the denonvilliers' fascia in male.

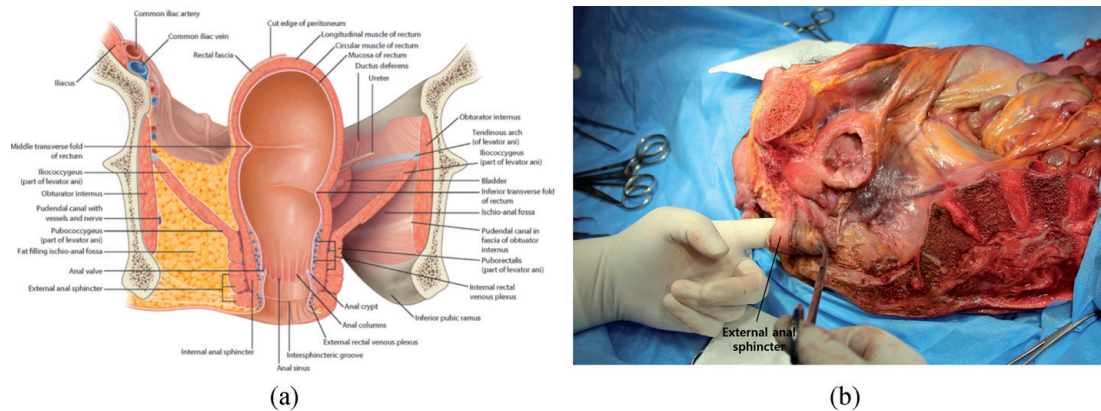


Figure 7.
Anal canal and anal sphincter complex. (a) The dentate line divides the upper two thirds and lower third of the anal canal, and there are longitudinal folds known as columns of Morgagni. The external sphincter consists of three separate parts: Subcutaneous, superficial, and deep part [21]. (b) External anal sphincter. Lt. Hemipelvis.

rectal and iliac lymphatic chains. Below the dentate line, the blood drains into the caval system, and lymphatics drain into the inguinal lymph nodes.

There are two sphincter muscles surrounding the anus, the internal sphincter and the external sphincter. The internal sphincter is connected from the inner circular smooth muscle of the rectum and descends to 1–1.5 cm below the dentate line. Its length is about 2.5–4 cm and the mean thickness is about 0.5 cm. It is an involuntary smooth muscle and plays an important role in the maintenance of fecal incontinence because it contributes a majority of the resting pressure of the anal canal. The outer longitudinal muscle of the rectum conjoins the fibers from the puborectalis muscle and is located between the external and internal sphincter. The external sphincter muscle is a striated muscle surrounding the internal sphincter in the shape of a cylinder, and it extends slightly below the internal sphincter. The external sphincter consists of three separate parts: subcutaneous, superficial, and deep part. The subcutaneous external sphincter attaches to the perianal skin encircling the anus. The external anal sphincter is innervated by the rectal branch

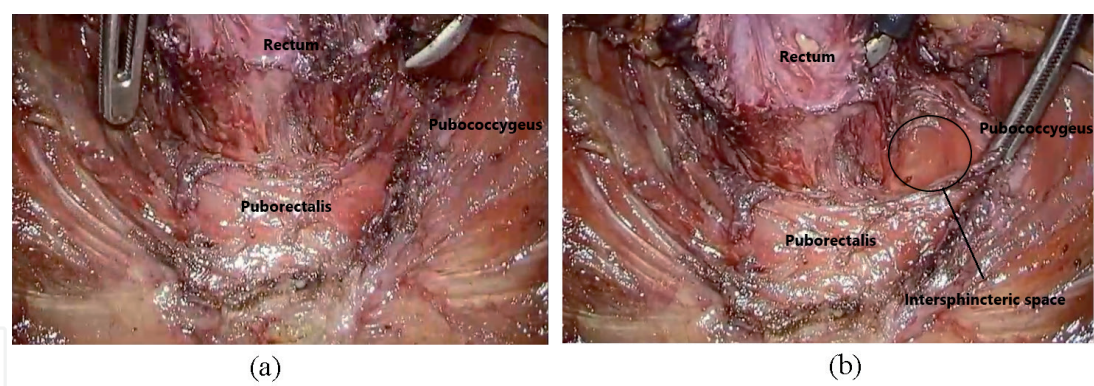


Figure 9.
Levator ani muscles and intersphincteric space. (a) Puborectalis and pubococcygeus muscle. (b) Intersphincteric space between rectum and puborectalis muscle.

ligament was divided into two layers. The ventral layer of the ligament was loose and rich in small and fragile vessels and extended from the presacral fascia to the conjoint longitudinal muscle layer of the anal canal. The dorsal layer of the ligament was thin and dense and extended between the coccyx and external anal sphincter (**Figure 10**) [28]. To fully mobilize the rectum from the pelvic floor at the final stage of total mesorectal excision, the anococcygeal ligament must be divided. If the anococcygeal ligament cannot be seen in the final step, it can be visualized after the mesorectum is completely mobilized from the pelvic floor.

2.5 Surgical plane for very low-lying rectal cancer

In case of very low-lying rectal cancer, several surgical options can be considered (**Figure 11**). If the tumor did not invade the anal sphincter complex, the ultra-low anterior resection with coloanal anastomosis could be considered. If the tumors are located close to the dentate line, the intersphincteric resection (ISR) could be considered. The ISR is the partial or complete resection of the internal anal sphincter along the intersphincteric plane. However, if the tumor invades the external sphincter complex, the abdominoperineal resection (APR) should be performed. For invasive low rectal cancer which invades the levator ani muscle, extralevator APR (ELAPE) should be considered to achieve adequate resection margin. The ELAPE is the cylindrical anorectal excision and removes more tissue around the tumor including levator ani muscle (**Figure 12**). This procedure has the advantage of reducing the risk of tumor perforation during operation and acquiring sufficient

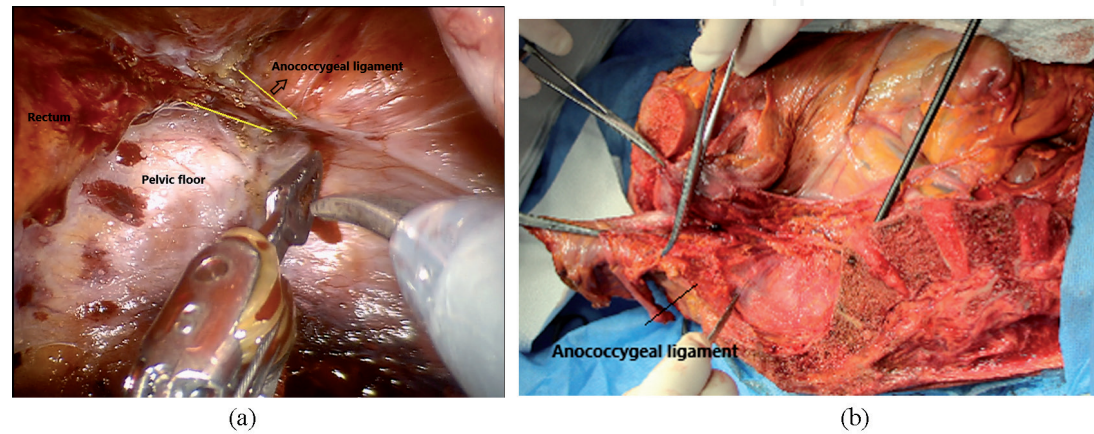


Figure 10.
Anococcygeal ligament. (a) Anococcygeal ligament and pelvic floor. During posterior dissection of the rectum. (b) Anococcygeal ligament during cadaveric dissection. Lt. hemipelvis.

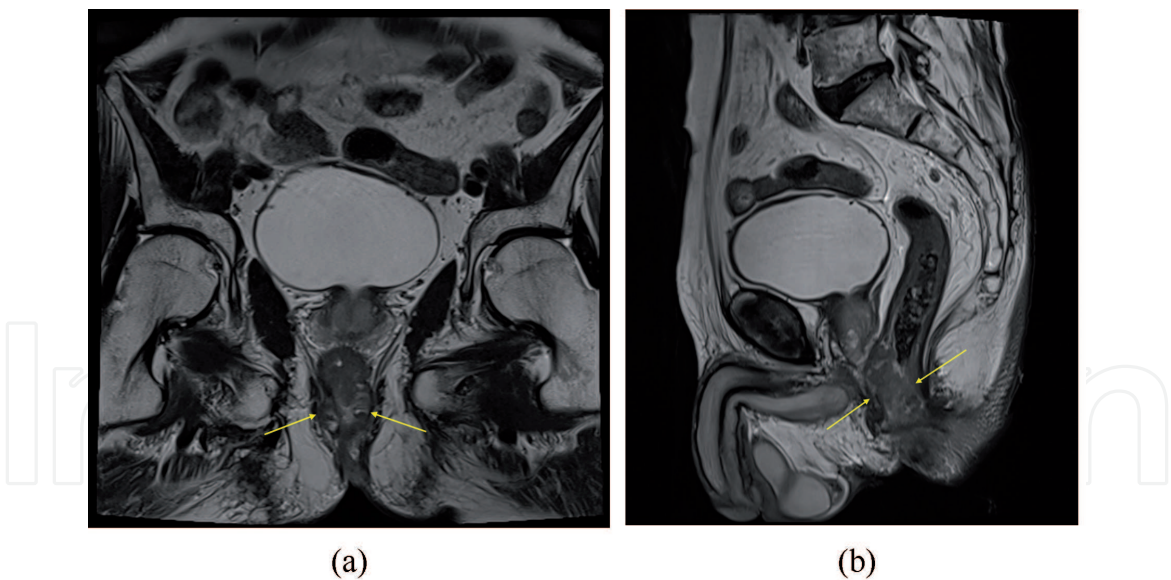


Figure 11.
Low-lying rectal cancer. (a) T2 weighted image on MRI. Coronal view. The low-lying rectal cancer invades internal anal sphincter. (b) T2 weighted image on MRI. Sagittal view.

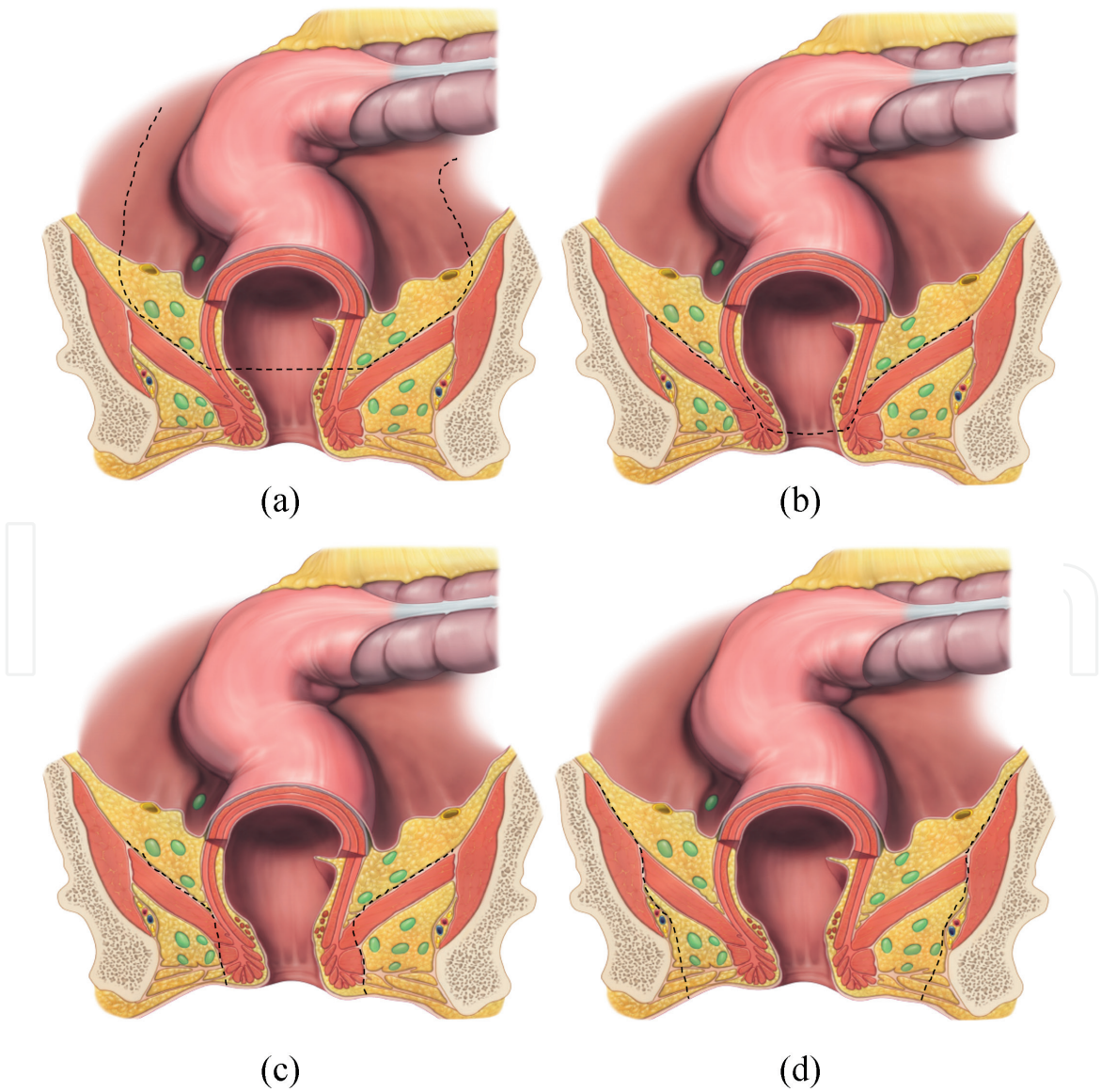


Figure 12.
Surgical plane for low-lying rectal cancer. (a) Low anterior resection (LAR). (b) Intersphincteric resection (ISR). (c) Abdominoperineal resection (APR). (d) Extralevator APR.

safety resection margin, but there is still controversy about the long-term oncologic outcome [29]. In addition, the postoperative complications can be increased due to the wide resection range.

2.6 Pelvic autonomic nerve system

In terms of quality of life, the importance of not only oncological outcomes but also functional outcomes such as urinary function, sexual function, and defecatory function after rectal cancer surgery have been emphasized. Urinary dysfunction after rectal surgery occurs in approximately 27%, and it includes difficulty emptying the bladder and incontinence [30, 31]. Sexual dysfunction for males consists of erectile dysfunction, absence of ejaculation, or retrograde ejaculation. For females, it causes sexual dysfunction such as impaired ability to achieve orgasm, decreased vaginal secretion, or dyspareunia [15]. The major cause of postoperative urogenital dysfunction is autonomic nerve damage that occurs during surgery. As minimally invasive surgery such as laparoscopy and robotic approach develops, meticulous nerve preserving surgery became possible with good visualization of the pelvic autonomic nerves [32–34]. To preserve the postoperative urogenital function, a thorough understanding of the anatomy of the pelvic autonomic nerve is crucial.

2.6.1 Superior hypogastric plexus and hypogastric nerves

The superior hypogastric plexus, which is a collection of sympathetic nerve bundles arising from T10–L3, forms a dense nerve plexus at the anterior area to the body of L5 and bifurcates into hypogastric nerves at the level of the sacral promontory (**Figure 13**). The superior hypogastric plexus runs around the inferior mesenteric artery. Therefore, this nerve can be damaged during dissection around the origin of the inferior mesenteric artery, and it results in retrograde ejaculation, urinary incontinence [35]. The hypogastric nerve crosses the left common iliac artery at the level of the first sacrum and descends to the pelvic cavity along the lateral pelvic wall.

2.6.2 Pelvic splanchnic nerves

The pelvic splanchnic nerves are considered to be parasympathetic nerves that arise from the second to fourth sacral spinal nerves. These nerves enter the pelvis through the sacral foramen, posterior to the parietal fascia that covers the piriformis

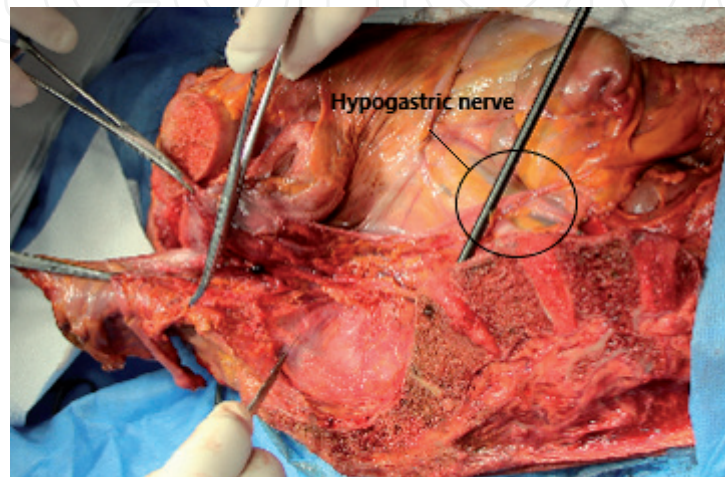


Figure 13. Hypogastric nerves. The hypogastric nerves run from the superior hypogastric plexus and descend to the pelvic cavity and meet the pelvic splanchnic nerves.

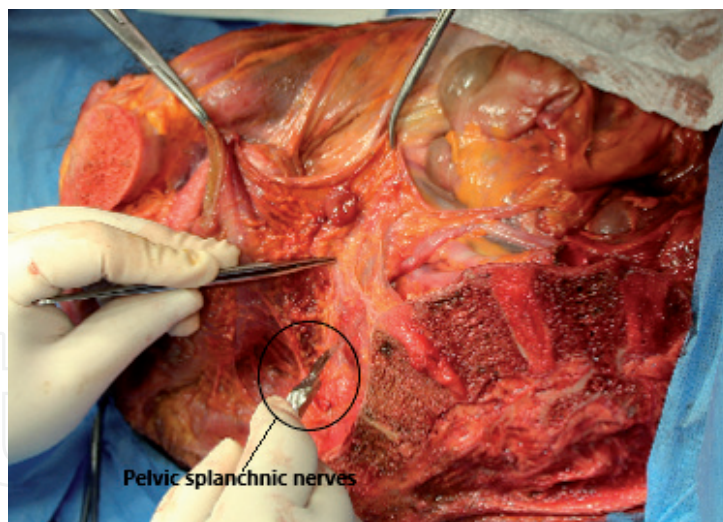


Figure 14.

Pelvic splanchnic nerves. The pelvic splanchnic nerves arise from the S2 to S4 spinal nerves. Small branches of the pelvic splanchnic nerves run medially and enter the mesorectum.

muscle and crosses the retrorectal space, to enter the visceral compartment through the visceral fascia about 4 cm from the midline. Small branches of the pelvic splanchnic nerves run medially and enter the mesorectum (**Figure 14**). These nerves regulate the emptying of the urinary bladder and influence erectile functions and motility of the rectum. Therefore, damage to these nerves causes erectile dysfunction and decreased blood flow to the vagina and vulva, which can reduce vaginal lubrication.

2.6.3 Inferior hypogastric (pelvic) plexus

The pelvic splanchnic nerves meet the hypogastric nerves and form the inferior hypogastric plexus at the lateral pelvic wall. It lies outside the fascia propria in the superficial layer of the parietal fascia. The inferior hypogastric plexus can be observed as a mesh-like structure at the posterolateral pelvic wall close to the prostate and seminal vesicles. Because the inferior hypogastric plexus consists of both sympathetic and parasympathetic efferent fibers, any damage to this plexus may cause severe disturbances in urogenital and sexual function including erection and ejaculation. It extends forward to form neurovascular bundles running down the seminal vesicle at 2 o'clock and 10 o'clock direction (**Figure 15**).

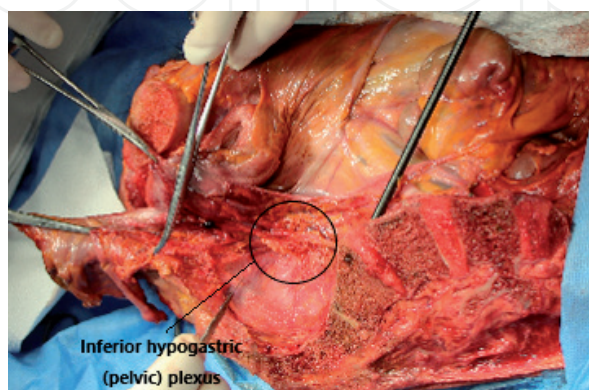


Figure 15.

Inferior hypogastric (pelvic) plexus. The inferior hypogastric (pelvic) plexus is a network of sympathetic and parasympathetic fibers arising from the hypogastric nerves and the pelvic splanchnic nerves. It can be observed as a mesh-like structure at the posterolateral pelvic wall. It extends forward to form neurovascular bundles running down the seminal vesicle on both sides.

These neurovascular bundles run through the posterolateral border of the prostate and continue to the periprostatic plexus, which supplies to the prostate, seminal vesicles, corpora cavernosa, and the vas deferens [15, 36]. Injury to the neurovascular bundles during anterior dissection may cause urinary and sexual dysfunction. Meticulous dissection is required because nerve damage may occur when surgery is performed along the wrong plane or excessive traction is performed.

3. Conclusion

The rectum is surrounded by a fatty tissue complex called the mesorectum, which contains abundant blood vessels, lymphatics, and lymph nodes. The rectum and mesorectum are enveloped by the mesorectal fascia. During total mesorectal excision, it is important to completely excise this mesorectal fascia without damage. The mesorectal fascia conjoins with the recto-sacral fascia, which extends forward from the presacral fascia at the level of S4, and descends to the pelvic floor. To enter the retro-rectal space and reach the pelvic floor, this fascia must be incised and sharp dissection should be performed to prevent severe bleeding due to injury to the presacral plexus. During the anterior dissection of the rectum, it is important to recognize Denonvilliers' fascia located between the rectum and seminal vesicles, and dissection should be performed below the Denonvilliers' fascia. The pelvic floor is a structure that forms the bottom of the pelvis and is mainly composed of the levator ani muscle complex: pubococcygeus, iliococcygeus, and puborectalis muscle. The levator ani muscle received direct innervation from sacral nerve roots (S3-S5) and play an important role in cooperative action during defecation. To reach the deep part of the anal canal, the dissection should be performed between the puborectalis muscle and the rectal wall. During the whole process of TME, surgeons should take care to identify and preserve the autonomic nerve in order to avoid postoperative urogenital dysfunction. Care should be taken not to damage the superior hypogastric nerve during IMA ligation, and not to damage the pelvic plexus during posterolateral pelvic dissection. In addition, during anterior dissection of the rectum, it is important to perform meticulous dissection so as not to injure small numerous neurovascular bundles running in the 2 o'clock and 10 o'clock directions of the seminal vesicle. Based on a sufficient understanding of pelvic anatomy, precise surgical techniques using advanced surgical tools will give favorable oncologic and functional outcomes for rectal cancer patients.

Conflict of interest

The authors declare no conflict of interest.

Notes/thanks/other declarations

None.

IntechOpen

IntechOpen

Author details

Sanghyun An and Ik Yong Kim*
Department of Surgery, Yonsei University Wonju College of Medicine,
Wonju, Korea

*Address all correspondence to: iykim@yonsei.ac.kr

IntechOpen

© 2021 The Author(s). Licensee IntechOpen. This chapter is distributed under the terms of the Creative Commons Attribution License (<http://creativecommons.org/licenses/by/3.0>), which permits unrestricted use, distribution, and reproduction in any medium, provided the original work is properly cited. 

References

- [1] Ferlay J, Colombet M, Soerjomataram I, Parkin DM, Pineros M, Znaor A, et al. Cancer statistics for the year 2020: An overview. *International Journal of Cancer*. 2021. DOI:10.1002/ijc.33588
- [2] Heald RJ, Husband EM, Ryall RDH. The mesorectum in rectal cancer surgery—the clue to pelvic recurrence? *British Journal of Surgery*. 1982;69:613-616. DOI:10.1002/bjs.1800691019
- [3] Engin O. Colon polyps and the prevention of colorectal cancer: Springer; 2015. 249 p. DOI:10.1007/978-3-319-17993-3
- [4] Culligan K, Walsh S, Dunne C, Walsh M, Ryan S, Quondamatteo F, et al. The mesocolon: a histological and electron microscopic characterization of the mesenteric attachment of the colon prior to and after surgical mobilization. *Annals of Surgery*. 2014;260:1048-1056. DOI:10.1097/SLA.0000000000000323
- [5] Bokey EL, Öjerskog B, Chapuis PH, Dent OF, Newland RC, Sinclair G. Local recurrence after curative excision of the rectum for cancer without adjuvant therapy: role of total anatomical dissection. *British Journal of Surgery*. 1999;86:1164-1170. DOI:10.1046/j.1365-2168.1999.01216.x
- [6] Silva-Velazco J, Stocchi L, Valente MA, Church JM, Liska D, Gorgun E, et al. The relationship between mesorectal grading and oncological outcome in rectal adenocarcinoma. *Colorectal Disease*. 2019;21:315-325. DOI:10.1111/codi.14535
- [7] Stelzner S, Heinze T, Nikolouzakakis TK, Torge Mees S, Witzigmann H, Wedel T. Perirectal fascial anatomy: New insights into an old problem. *Diseases of the Colon and Rectum*. 2021;64:91-102. DOI:10.1097/DCR.0000000000001778
- [8] Kim NK, Kim HS, Alessa M, Torky R. Optimal complete rectum mobilization focused on the anatomy of the pelvic fascia and autonomic nerves: 30 years of experience at Severance Hospital. *Yonsei Medical Journal*. 2021;62:187-199. DOI:10.3349/ymj.2021.62.3.187
- [9] Heald RJ, Santiago I, Pares O, Carvalho C, Figueiredo N. The perfect total mesorectal excision obviates the need for anything else in the management of most rectal cancers. *Clinics in Colon and Rectal Surgery*. 2017;30:324-332. DOI:10.1055/s-0037-1606109
- [10] Lou Z, Zhang W, Meng RG, Fu CG. Massive presacral bleeding during rectal surgery: from anatomy to clinical practice. *World Journal of Gastroenterology : WJG*. 2013;19:4039-4044. DOI:10.3748/wjg.v19.i25.4039
- [11] Kim NK. Anatomic basis of sharp pelvic dissection for curative resection of rectal cancer. *Yonsei Medical Journal*. 2005;46:737-749. DOI:10.3349/ymj.2005.46.6.737
- [12] Açar Hİ, Kuzu MA. Anatomical planes in rectal cancer surgery. *Turkish Journal of Colorectal Disease*. 2019;29:165-170. DOI:10.4274/tjcd.galenos.2019.2019-10-2
- [13] Lindsey I, Guy RJ, Warren BF, Mortensen NJ. Anatomy of Denonvilliers' fascia and pelvic nerves, impotence, and implications for the colorectal surgeon. *British Journal of Surgery*. 2000;87:1288-1299. DOI:10.1046/j.1365-2168.2000.01542.x
- [14] Zhu XM, Yu GY, Zheng NX, Liu HM, Gong HF, Lou Z, et al. Review of Denonvilliers' fascia: the controversies and consensuses. *Gastroenterology Report*. 2020;8:343-348. DOI:10.1093/gastro/goaa053

- [15] Nagpal K, Bennett N. Colorectal surgery and its impact on male sexual function. *Current Urology Reports*. 2013;14:279-284. DOI:10.1007/s11934-013-0341-x
- [16] Kim JH, Kinugasa Y, Hwang SE, Murakami G, Rodriguez-Vazquez JF, Cho BH. Denonvilliers' fascia revisited. *Surgical and Radiologic Anatomy : SRA*. 2015;37:187-197. DOI:10.1007/s00276-014-1336-0
- [17] Kraima AC, West NP, Treanor D, Magee DR, Rutten HJ, Quirke P, et al. Whole mount microscopic sections reveal that Denonvilliers' fascia is one entity and adherent to the mesorectal fascia; implications for the anterior plane in total mesorectal excision? *European Journal of Surgical Oncology*. 2015;41:738-745. DOI:10.1016/j.ejso.2015.03.224
- [18] Ludwikowski B, Hayward IO, Fritsch H. Rectovaginal fascia: An important structure in pelvic visceral surgery? About its development, structure, and function. *Journal of Pediatric Surgery*. 2002;37:634-638. DOI:10.1053/jpsu.2002.31624
- [19] Aigner F, Zbar AP, Ludwikowski B, Kreczy A, Kovacs P, Fritsch H. The rectogenital septum: morphology, function, and clinical relevance. *Diseases of the Colon and Rectum*. 2004;47:131-140. DOI:10.1007/s10350-003-0031-8
- [20] Lee JM, Kim NK. Essential anatomy of the anorectum for colorectal surgeons focused on the gross anatomy and histologic findings. *Annals of Coloproctology*. 2018;34:59-71. DOI:10.3393/ac.2017.12.15
- [21] Richard L. Drake, A. Wayne Vogl and Adam W.M. Mitchell. *Gray's Atlas of Anatomy*, 5, 213-292
- [22] Kim NK, Sugihara K, Liang J-T. Surgical treatment of colorectal cancer: Asian perspectives on optimization and standardization; : Springer Singapore 2018. 414 p. DOI:10.1007/978-981-10-5143-2
- [23] Fritsch H, Brenner E, Lienemann A, Ludwikowski B. Anal sphincter complex: reinterpreted morphology and its clinical relevance. *Diseases of the Colon and Rectum*. 2002;45:188-194. DOI:10.1007/s10350-004-6144-x
- [24] Rullier E, Zerbib F, Laurent C, Bonnel C, Caudry M, Saric J, et al. Intersphincteric resection with excision of internal anal sphincter for conservative treatment of very low rectal cancer. *Diseases of the Colon and Rectum*. 1999;42:1168-1175. DOI:10.1007/Bf02238569
- [25] Eickmeyer SM. Anatomy and physiology of the pelvic floor. *Physical Medicine and Rehabilitation Clinics of North America*. 2017;28:455-460. DOI:10.1016/j.pmr.2017.03.003
- [26] Siccardi MA, Bordoni B. Anatomy, Abdomen and Pelvis, Perineal Body [Internet]. 2021. Available from: <https://www.ncbi.nlm.nih.gov/books/NBK537345/> [Accessed: 2021-04-01]
- [27] Stelzner S, Holm T, Moran BJ, Heald RJ, Witzigmann H, Zorenkov D, et al. Deep pelvic anatomy revisited for a description of crucial steps in extralevator abdominoperineal excision for rectal cancer. *Diseases of the Colon and Rectum*. 2011;54:947-957. DOI:10.1097/DCR.0b013e31821c4bac
- [28] Kinugasa Y, Arakawa T, Abe S, Ohtsuka A, Suzuki D, Murakami G, et al. Anatomical reevaluation of the anococcygeal ligament and its surgical relevance. *Diseases of the Colon and Rectum*. 2011;54:232-237. DOI:10.1007/DCR.0b013e318202388f
- [29] Tao Y, Han JG, Wang ZJ. Extralevator abdominoperineal excision for advanced low rectal cancer: Where to go. *World*

Journal of Gastroenterology : WJG. 2020;26:3012-3023. DOI:10.3748/wjg.v26.i22.3012

[30] Kim NK, Kim YW, Cho MS. Total mesorectal excision for rectal cancer with emphasis on pelvic autonomic nerve preservation: Expert technical tips for robotic surgery. *Surgical Oncology*. 2015;24:172-180. DOI:10.1016/j.suronc.2015.06.012

[31] Chew MH, Yeh YT, Lim E, Seow-Choen F. Pelvic autonomic nerve preservation in radical rectal cancer surgery: changes in the past 3 decades. *Gastroenterology Report*. 2016;4:173-185. DOI:10.1093/gastro/gow023

[32] Luca F, Valvo M, Ghezzi TL, Zuccaro M, Cenciarelli S, Trovato C, et al. Impact of robotic surgery on sexual and urinary functions after fully robotic nerve-sparing total mesorectal excision for rectal cancer. *Annals of Surgery*. 2013;257:672-678. DOI:10.1097/SLA.0b013e318269d03b

[33] Garbarino GM, Canali G, Tarantino G, Costa G, Ferri M, Balducci G, et al. Laparoscopic versus open rectal resection: a 1:2 propensity score-matched analysis of oncological adequateness, short- and long-term outcomes. *International Journal of Colorectal Disease*. 2021;36:801-810. DOI:10.1007/s00384-021-03841-w

[34] Hur H, Bae SU, Kim NK, Min BS, Baik SH, Lee KY, et al. Comparative study of voiding and male sexual function following open and laparoscopic total mesorectal excision in patients with rectal cancer. *Journal of Surgical Oncology*. 2013;108:572-578. DOI:10.1002/jso.23435

[35] Mari GM, Crippa J, Cocozza E, Berselli M, Livraghi L, Carzaniga P, et al. Low ligation of inferior mesenteric artery in laparoscopic anterior resection for rectal cancer reduces genitourinary dysfunction: Results from a randomized

controlled Trial (HIGHLOW Trial). *Annals of Surgery*. 2019;269:1018-1024. DOI:10.1097/SLA.0000000000002947

[36] Hollabaugh Jr RS, Steiner MS, Sellers KD, Samm BJ, Dmochowski RR. Neuroanatomy of the pelvis: Implications for colonic and rectal resection. *Diseases of the Colon and Rectum*. 2000;43:1390-1397. DOI:10.1007/BF02236635