

We are IntechOpen, the world's leading publisher of Open Access books Built by scientists, for scientists

6,900

Open access books available

185,000

International authors and editors

200M

Downloads

Our authors are among the

154

Countries delivered to

TOP 1%

most cited scientists

12.2%

Contributors from top 500 universities



WEB OF SCIENCE™

Selection of our books indexed in the Book Citation Index
in Web of Science™ Core Collection (BKCI)

Interested in publishing with us?
Contact book.department@intechopen.com

Numbers displayed above are based on latest data collected.
For more information visit www.intechopen.com



Maxillary Sinus in Dental Implantology

Nikolay Uzunov and Elena Bozhikova

Abstract

Dental implants have significantly increased prosthetic options for the edentulous patient. Implant placement in the posterior maxilla may often be hampered due to anatomical limitations, inadequate height and width, and poor bone quality. After tooth extraction, three-dimensional physiological resorption and sinus expansion take place and reduce the volume of the alveolar ridge. The concomitant actions of alveolar atrophy and sinus pneumatization reconstruct the subantral alveolar segment into a low, shallow, and sloped ridge which is incapable to accommodate dental implants and bear the functional strains. Advanced maxillary resorption can be managed by several surgical options, the most popular of which is maxillary sinus floor elevation. The chapter discusses recent advancements in bone biology and biomechanics in the light of alveolar atrophy and the impact of anatomy on maxillary sinus floor elevation as a treatment modality for the partially or totally edentulous patient.

Keywords: maxillary sinus floor elevation, dental implants, maxillary atrophy, maxillary pneumatization, maxillary edentulism

1. Introduction

Dental implants (DI) have significantly increased prosthetic options for the edentulous patient. However, implant placement in the posterior maxilla is often hampered by anatomical limitations such as inadequate vertical and buccopalatal dimensions, poor bone quality, thin or missing cortex, and undercuts. Following tooth extraction, three-dimensional resorption of the alveolar ridge takes place and reduces its' dimensions; in addition, the periosteum of the maxillary sinus (MS) can exhibit an increase in osteoclastic activity. The latter can aggravate the physiological process of maxillary sinus pneumatization (MSP) or aeration. The concomitant actions of postextraction alveolar atrophy (AA) and MSP worsen the subantral alveolar dimensions in short terms and makes doubtful the prosthetic rehabilitation with DIs, as adequate bone height and width are mandatory to implant treatment [1–4]. The principal solution for alveolar insufficiency is to augment the distal maxilla. Several surgical approaches have the potential to improve the subantral osseous environment to prepare the edentulous segment for the accommodation of DI, and the most popular is maxillary sinus floor elevation (MSFE).

2. Alveolar atrophy after tooth extraction

Alveolar atrophy is defined as loss or diminution of supportive alveolar bone due to loss of teeth or to function, trauma, reduced blood supply, or unknown cause [5]. The most common reason for AA is the alveolar resorption after tooth loss [6]. Removal of a tooth is followed by remodeling and reduction of the buccolingual and apicocoronal dimensions of the edentulous segment and results in a shorter and narrower alveolar ridge [6–10]. Unaddressed, postextraction AA develops through the whole lifespan of the person (**Figure 1**). Jaws with progressive bone loss are subjected to continuing anatomical make-over that alters normal orofacial tissue configuration which may affect the social integration and realization of the affected individuals. In advanced AA cases, adequate anatomical, functional, and esthetic rehabilitation is highly complicated.

2.1 Physiology and biomechanics of bone atrophy

In 1881 Wilhelm Roux suggested that the natural forces acting on the alveolar ridge are reduced after tooth loss. As result, less bone is needed to maintain function, and, consequently, the body gets rid of the non-functioning structures. It was concluded that loss of alveolar bone after tooth removal is an example of disuse atrophy. Eleven years later Wolff’s law stated that bone tissue adapts its mass and architecture to the mechanical demands [10].

It was understood that loads play a key role in bone biology. The principles of biomechanics were applied to present bone mass maintenance and resorption as a reaction to continuously repeated loading impetus. The daily stress stimulus theory of bone adaptation was formulated to describe the loading conditions necessary to support bone mass and recognized the stress/strain magnitude and loading cycle number as sufficient to define an appropriate maintenance loading signal [11]. Frost [12] published a hypothesis on a provisional general model of the skeleton’s mechanostat. According to this hypothesis, the mechanostat spans the biological distance

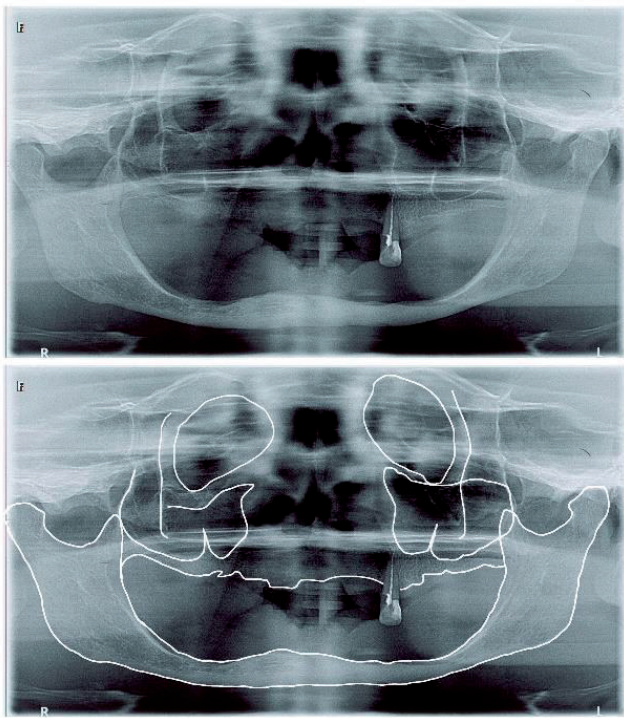


Figure 1.
Advanced maxillary and mandibular alveolar atrophy in a 64-year-old male.

between organs and macromolecules and can be applied to “all organs and tissues, including bone, made wholly or in part from the basic tissues”. It was proposed that “interlocking negative feedback loops” provide mechanical-usage-dedicated message traffic routes on which nonmechanical agents could act to optimize postnatal skeletal adaptations to varied mechanical and nonmechanical challenges, and treatments of disease [12]. The understanding that mechanical stimuli can be transferred to the bone by a signaling network was further developed by Burger and Klein-Nulend in the mechanotransduction concept. They pointed that the osteocytes function as mechanosensory cells of osseous tissues and explained the capacity of bone to change its mass and structure in response to mechanical demands within specific cellular mechanisms [13].

For a long time, the contribution of osteocytes to bone biology was undervalued as they were accepted as terminal stage cells of the osteoblastic lineage. Recent investigations addressed the osteocytes and their role in bone orchestration and revealed that they may have mechanosensory, endocrine, and homeostatic activity.

Osteocytes are the most abundant bone cells and the only cells embedded in the bone mineral matrix. After being entrapped in bone, the osteocytes are housed within lacunae and connect to each other by cytoplasmic processes hosted in channels called canaliculi. The lacunae and the canaliculi form a three-dimensional (3D) network named the lacuno-canalicular network (LCN). In the light of mechanotransduction, the strains in bone accumulated under loads may induce a strain-derived flow of interstitial fluid through the LCN which mechanically activates the osteocytes to respond to the loading stimuli and ensure the transport of cell signaling molecules, nutrients, and waste products. This explains local bone gain, loss, and remodeling, in response to fatigue damage, as cellular and intercellular activity supervised by the mechanosensitive osteocytes [13]. The LCN is a negative imprint of the cellular network in the bone and its morphology is considered to play a central role in bone mechanosensation and mechanotransduction [14]. Within the LCN, the osteocytes can transport nutrients, biochemical signals, and hormonal stimuli, enabling the integration of the information between and interaction with other bone cells [15].

The general existence and micro-anatomy of the LCN have been known for a long time. The connections of the osteocyte network with other regions of the body [16] and its importance for phosphate metabolism [13, 15] were debated in recent research [17, 18]. As endocrine cells, osteocytes have an impact on many organs [16]. They communicate with the kidney through the factor FGF23 [19], and with the brain, through the expression of leptin [20]. The osteocytes could be regulators of bone resorption by secreting the Receptor activator of NF- κ B ligand (RANKL) [21] and control bone formation by producing WNT1 glycoprotein [22, 23]. They contribute to fat metabolism by secreting sclerostin, which promotes the increase of beige adipogenesis [22], and influence hematopoiesis by the adjustment of the endosteal microenvironment through the release of soluble factors [24].

The connectivity between osteocytes themselves is of crucial importance to understand bone health [17]. Within the complex communication between cells, the osteocyte network acts as a mechano-sensory organ [25]. Through sensing the fluid flow in LCN and sclerostin expression, the osteocytes regulate bone's mechanobiological adaptation and remodeling [26]. The hypothesis of the LCN connectome, paralleling the neurosensory connectome, is emerging from the complex LCN organization and wealth of connections within the bone and with other organs [17].

It is important to distinguish between the LCN and the osteocyte network as a connected cell network. However, most of the functions of the osteocyte network can only be understood in the interplay between the “biological” cell network and the “material” porosity in the mineralized matrix [25]. In human osteons, canaliculi

that are not oriented towards the Haversian canal were found to be co-aligned with the preferred matrix orientation. The pericanalicular matrix in the immediate vicinity of the cell processes was shown to be disordered and more mineralized with increased thickness of the mineral particles incorporated in the collagen matrix. This higher mineral content around the canaliculi is remarkable in the context of the osteocytes' contribution to calcium and phosphate metabolism. Recent evidence revived the almost forgotten idea of osteocytic osteolysis. Due to the high surface area of the LCN and the small distance from the LCN to any point in the bone matrix, osteocytes have easy access to the bone mineral and can demineralize bone. The role of osteocytes as mechanosensors and orchestrators of bone remodeling depends crucially on the interaction between cell network and porous network.

The fluid flow hypothesis assumes that mechanical loads squeeze interstitial bone fluid through the pericellular space between the cell processes and bodies in the canaliculi and lacunae. The osteocytes and their processes sense the shear forces caused by the fluid flow, and it seems that the cell processes are more mechanosensitive than the cell body. The details of the fluid flow and the resulting shear forces do not only depend on the connectivity and the irregular shape of the canaliculi, but also on how the cells deform due to the flow and how the cell processes are anchored on the canaliculi walls [17]. More recently, a newly discovered cell type, osteomorphs, was proved to participate in bone resorption and remodeling. It was shown that osteoclasts recycle via osteomorphs and that the latter may be targeted for the treatment of resorptive skeletal diseases [27].

2.2 Biomechanics of alveolar bone

It was confirmed that the grounds of understanding bone physiology are the osteocyte reactions to stress stimuli, inducing bone resorption, remodeling, and adaptation, on one hand, and biomechanics, on the other. Several investigations addressed the biomechanics of bone adaptation. Qin et al. examined a turkey ulna model of disuse osteopenia to determine whether the daily stress theory of bone adaptation can be applied to conditions of very high numbers of loading cycles at very low strain magnitudes [28]. They found that the strain stimulus needed per day to maintain bone mass could be expressed by the formula

$$y = 10^{2.28} (5.6 - \log_{10} x)^{1.5} \quad (1)$$

where x is the number of loading cycles per day and y is the strain magnitude. The results proved the strong antiresorptive influence of mechanical loading identifying a threshold for a daily loading cycle regimen near 70 microstrain of approximately 100,000 strain cycles, and suggest that the strain frequency or strain rate associated with the loading stimulus must also play a critical role in the mechanism by which bone, as a tissue, responds to mechanical loads.

In 2012 Hansson and Halldin tested such experiments and investigated, in the light of mechanics of materials, the correlation between established principles of bone physiology and the changes in the dimensions of the alveolar ridge after tooth extraction [10]. Their considerations were based on the mathematical presentation of principal stresses and strains acting on the mandible as a beam subjected to loads and, also, the differences in the response of cancellous and cortical bone to strains. Data analysis from clinical and experimental investigations on the effects of strains on lamellar organization and orientation of cancellous bone [29–31], the alignment of the Haversian systems in cortical bones [32], and bone mass dependence on the magnitude

of strains, was integrated with experimental findings on the healing of postextraction sockets and resorption of the empty alveolar ridge. One month after tooth extraction the empty socket is filled with woven bone. Three months later the woven bone is substituted by a cortical ridge-like structure consisting of lamellar and woven bone which, in turn, is substituted in the sixth month by an alveolar ridge constructed of lamellar bone and bone marrow [33]. It was also pointed that the resorption of the buccal and lingual alveolar walls occurs in two overlapping phases; in the first phase, the bundle bone is resorbed and replaced with woven bone, while the second phase includes resorption from the outer surface of both bone walls, and that the resorption is larger at the buccal aspect of the ridge than at the lingual aspect [34–37].

Considering the mandible as a beam subjected to strains, i.e., bending moments, the authors speculated that the extraction socket will gradually be filled with lamellar and cancellous bone, which will make the healed extraction site stiffer both to horizontal and vertical bending. The bending moments remain unchanged and, consecutively, the bone strains will be reduced [10]. Reduced bone strains result in bone loss [28, 38]. Speculation on bone physiology and biomechanics brings the conclusion that alveolar and jaw resorption is a natural result of the fundamental physiological principle of adaptation of bone mass and bone structure to the levels and frequencies of strain [10].

3. Practical aspects of alveolar atrophy of the distal maxilla

3.1 Alveolar atrophy and dental implants

Masticatory forces are distributed to the skull through the fronto-maxillary (frontonasal), the zygomatico-maxillary, and the pterygomaxillary pillars, and the palatine arch [38, 39]. DI placement requires bony structures with adequate volume, and [1] therefore, the volume of the alveolar crest is a principal consideration for DI treatment. In the distal maxilla, the subantral height, i.e., the height of the inferior MS wall, and width of the alveolar span are of crucial importance in treatment planning.

After tooth loss, the alveolar bone undergoes fast remodeling that leads to horizontal and vertical decrease of crestal dimensions [6, 40]. When, after tooth extraction, the alveolus is occupied by bone, or by DI and bone, the stiffness of the edentulous span will be increased. With unchanged loads, increased stiffness implies reduced strains, and the strain stimulus needed to maintain bone mass is no longer reached. The biological response to this is to remove bone and reduce the bony volume. Therefore, placing a DI in the empty alveolus will increase alveolar stiffness, and, theoretically, immediate DI placement into fresh extraction sockets should not be expected to prevent the dimensional reduction of the alveolar ridge [10].

Clinical trials and systematic reviews demonstrated that horizontal and vertical resorption is more pronounced at the buccal aspect of the ridge than at the lingual aspect [34, 35, 37, 41–43] and that the horizontal reduction is greater than the loss in height [34]. The consequence of a greater vertical bone loss buccally than lingually is a ridge that is sloped in the lingual to the buccal direction (**Figure 2**). A new “tug-of-war” hypothesis explains the more pronounced buccal resorption with the forces acting at the empty socket after tooth loss and the activity of the myofibroblasts as their pull is directed from the buccal and palatal edges towards the center of the alveolus. Since the balance depends on the relative mass of the two edges, the thin buccal wall would be the one to cede under the tension of the granulation tissue [44].

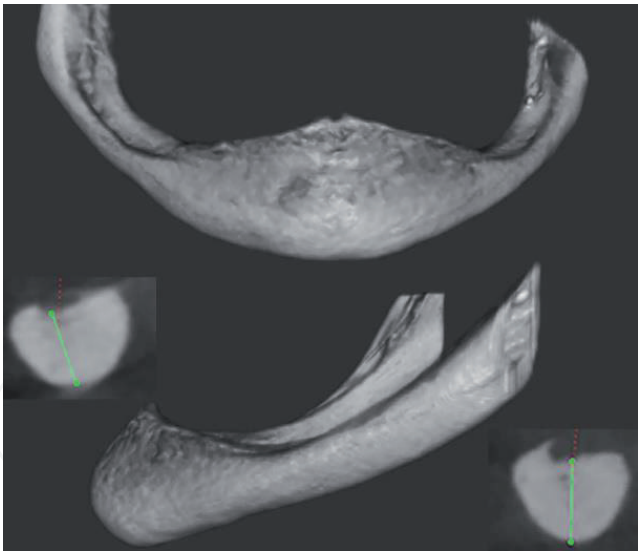


Figure 2.
Advanced alveolar atrophy of the mandible resulting in a sloped alveolar ridge.

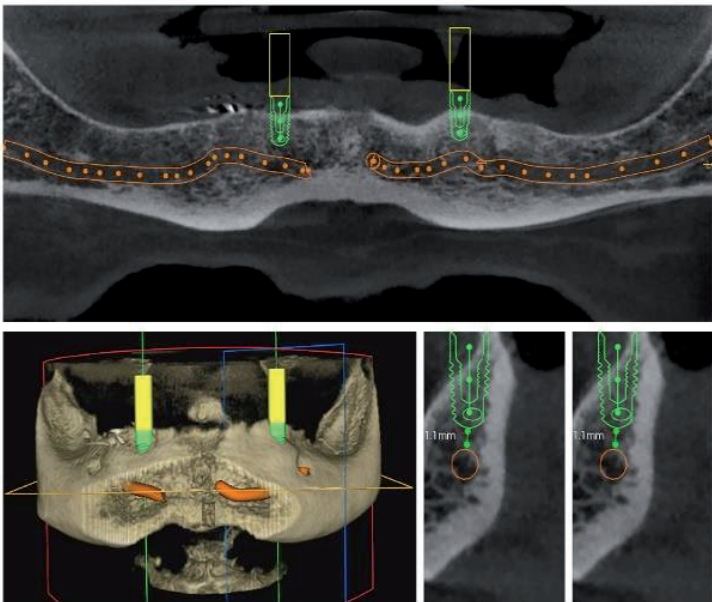


Figure 3.
The sloped alveolar ridge does not allow for placement of DI without ridge augmentation.

In cases with a sloped alveolar ridge, the insertion of standard DI might not be optimal (**Figure 3**). Implant placement in level with the lingual bone margin may result in compromised esthetics. If DI instead is placed at a level with the buccal margin, the lingual marginal bone is at risk to be resorbed due to insufficient strain stimulus. In a clinical study, DI with a sloped marginal contour was used in cases with an alveolar crest sloped in lingual to buccal direction. Both the mean buccal marginal bone level change and the mean lingual marginal bone level change after 16 weeks amounted to -0.2 mm. Thus, the installation of a DI with a sloped marginal contour may be a treatment option in cases where the alveolar ridge is sloped in lingual to the buccal direction [10, 45].

3.2 Atrophy of the distal maxilla

The above line of arguments can be applied to the maxilla with its complicated anatomy, lesser bone density, and aeration. Disuse atrophy creates a sloped and

reduced in height alveolar profile, constructed mostly from soft trabecular bone. Moreover, the edentulous maxillary posterior sextants were shown to have the least amount of residual bone height compared with other edentulous regions of the maxilla and, therefore, represent one of the most critical areas to be rehabilitated by an implant-supported prosthesis [46]. In addition, the postextraction bone resorption in the distal maxilla may be associated with MSP, which may contribute to a further decrease of the available bone volume for DI placement [47].

3.3 Residual alveolar height of the distal maxilla and maxillary sinus pneumatization

The aeration of the paranasal cavities is a physiological process the effect of which is an increase in sinus volume and decrease in the volume of the surrounding bone during growth. MSP adds additional three-dimensional reduction to the postextraction alveolar resorption in the distal maxilla (**Figure 4**) [2, 40].

The MS begins its development in the 10th week. At the time of birth, the sinus is already pneumatized and increases in size through continuous MSP during the whole life of the individual [48, 49]. With the eruption of the permanent dentition, MSP is paused, and the sinus reaches 4–5 mm below the nasal cavity as an alveolar recess [50]. The variations in MS volume and dimensions among individuals and tooth position are significant. The alveolar recess can project between adjacent teeth or between the roots of the same tooth [51]. This is often observed between the roots of the first and the second molar which have a very close relationship to the sinus floor [52–55]. Tooth loss unlocks sinus aeration again and its effect is added to the effect of the postextraction alveolar resorption.

Several studies reported significant MSP after tooth extraction and accepted that alveolar bone height in the edentulous distal maxilla is a result of the concomitant actions of crestal atrophy and apical sinus enlargement. The anatomical and pathological peculiarities of the distal maxilla contribute to the MS expansion after removal of the first and the second upper molars. The ultimate anatomical

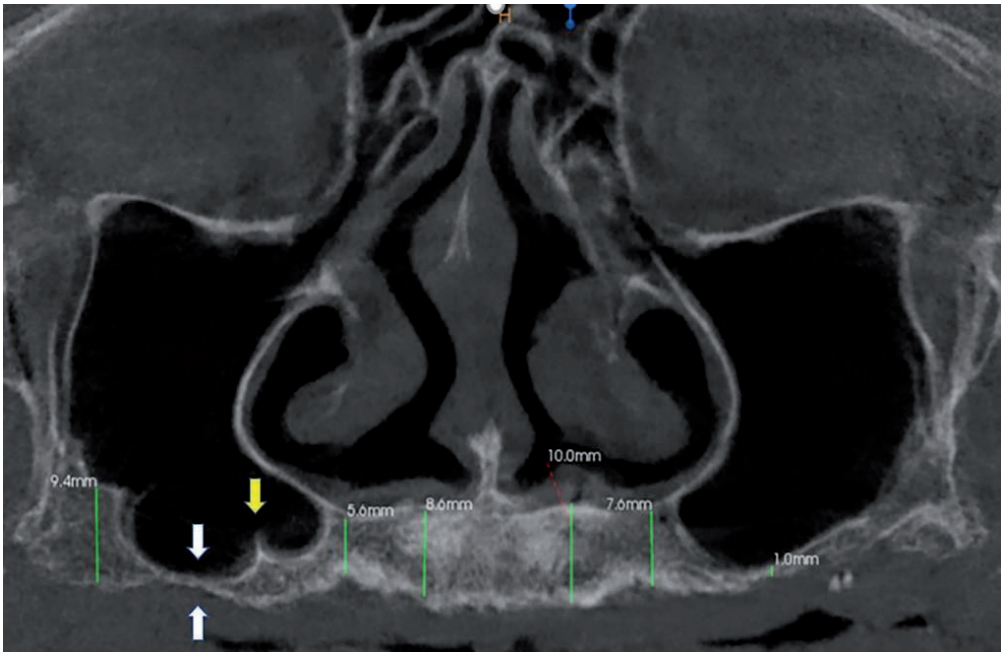


Figure 4. Advanced alveolar atrophy and pneumatization of the distal maxilla. Note that the subantral height is 1 mm on the left and even less on the right (white arrows). The sinus pneumatization extends into the premolar region and lies beneath the nasal floor bilaterally approximating the canines. A well-defined sinus floor septum is found in the right (yellow arrow). The sinus drainage is doubtful on both sides, due to thickened mucosa.

consideration is the proximity between the root apices of these teeth and the sinus floor [2, 40, 55–57]. This means that the height of the bony roofs of the alveoli of the upper molars, i.e., the thickness of the inferior sinus wall, is anatomically small, and, in turn, can be more readily reduced by AA and MSP even in cases without preceding pathology in or trauma to this region. The same is the cause for asymptomatic cortical bone fractures of the alveolar roof during upper molar extraction. Extensive ridge atrophy and MSP can be provoked by the removal of teeth which roots elevate the sinus floor or are enveloped by a superiorly curving floor. Multiple extractions within the same segment initiate more aggressive AA and MSP and reduce considerably ridge volume and resistance to the loading stimuli. Considering that the causes for tooth loss are mainly periapical and/or periodontal pathology, and trauma, it becomes clearer why postextraction alveolar resorption is often accelerated at the distal maxilla and why the loss of maxillary molars is considered to provoke excessive MSP [2, 40, 57–60]. It is not still completely understood how much atrophy and MSP contribute actually to the total loss of bony height [2, 61, 62].

Other studies could not confirm MS expansion after tooth loss [63, 64]. The role of residual ridge resorption and MSP was recently addressed in the overall maxillary bony atrophy using principal components analysis [65]. They found that most of the bone loss occurring in the alveolar process is caused by disuse atrophy due to edentulism and concluded that while the alveolar crest is changed by tooth loss, the MS is not, which refers sinus depth to anatomical variation independent of dentition. Prolonged edentulism in the maxillary molar region leads to centripetal and, to minor degrees, to centrifugal ridge resorption. Minor MSP occurs in the walls thinning the buccal and palatal aspects, which may be attributed to the absence of roots or variation in force transmission to the zygomatic or the nasopalatal buttresses [65].

The reasons for MSP after tooth extraction are still debated. With tooth loss, the functional forces which are normally transferred to the bone are weakened which can cause a shift in the physiologic bone remodeling to a resorptive pattern [58]. Previous studies demonstrated a downward expansion of the MS after tooth loss and showed that it was larger if the extracted tooth was surrounded by a superiorly curved sinus floor [2, 66–68].

In conclusion, advanced alveolar resorption constitutes a sloped alveolar ridge with inadequate bone volume and quality that limits conventional DI treatment. The bone density in the distal maxilla is the lowest in comparison to other jaw regions. The edentulous upper molar alveolar ridge presents with a thin cortex and a loose trabecular subcortical bone. This means that the biomechanical properties and the healing potential of this segment may be insufficient to secure primary DI stability and graft consolidation.

4. Maxillary sinus floor elevation

Treatment limitations present functional and esthetic impairments to the affected individuals. In such cases, the rehabilitation of the altered jaw segments necessitates the reconstruction of the missing dentoalveolar tissues. An increasing number of patients with edentulous posterior maxilla needs bone and soft tissue augmentation procedures to allow proper DI placement and achieve satisfactory results [46].

Maxillary sinus floor elevation (MSFE) is a treatment concept the purpose of which is volume augmentation of the distal maxilla to enhance the prosthetic rehabilitation of partial or total maxillary edentulism with DI. The goal is achieved with two basic surgical techniques and their variations that share a common key point which is to intrude the subantral alveolar ridge, or part of it, into the sinus,

thus establishing a new sinus bottom at a higher level and creating an empty space between it and the alveolar crest. Various grafting techniques are applied at the empty space to induce new bone formation and convert it into a newly constructed ridge allowing placement of DI. The two main surgical approaches of MSFE are the lateral window (external) approach and the transalveolar (internal) approach [69].

The lateral window technique (external approach) was first presented by Tatum at the Birmingham, Alabama, implant meeting of 1976 [70]. The first publication on the technique was made by Boyne and James in 1980 [71]. The classical operation consists of the preparation of a top hinge door in the lateral sinus wall, which is luxated inward and upward together with the Schneiderian membrane to a horizontal position forming the new sinus bottom. The space below the new sinus bottom is filled with graft material. In cases with sufficient alveolar height (± 4 mm) for primary stability, the DI can be inserted simultaneously with the MSFE (**Figure 5**). In cases with doubtful primary stability (bone height < 4 mm), the DI is inserted in a second procedure (**Figure 6**) when bone remodeling of the graft has taken place [1, 72].

Although safe and predictable, complications and morbidity can be associated with the lateral MSFE. Several surgical techniques have been proposed to minimize these problems with the use of specialized trephine burrs, piezosurgical devices, balloons, and hydrostatic pressure.

The transcrestal approach (internal approach) was also presented by Tatum. A “socket former” for the selected DI size was used to prepare the implant site. A green-stick fracture of the sinus floor was then created by hand-tapping the socket former towards the sinus cavity [70]. The internal approach is considered less invasive than the external lateral window approach.

The osteotome technique is a development of the transcrestal approach used for MSFE and site development by compressing the soft maxillary bone to improve the mineral density intraalveolarly by osseous deformation and trabecular microfracture [73, 74]. Summers used specialized osteotomes with increasing diameters to intrude the sinus bottom and compress the adjacent bone optimizing its density. The green-stick fractured bottom together with the sinus membrane is displaced step-by-step into the MS cavity to form a “tent” above the original sinus floor level.

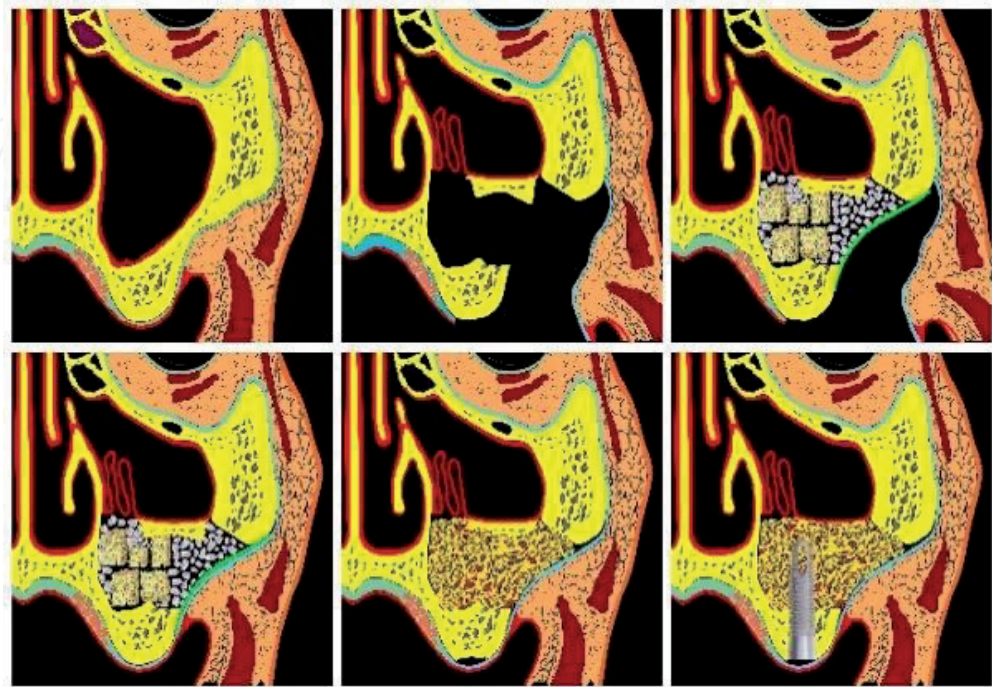


Figure 5.
MSFE with lateral approach, one-stage procedure.

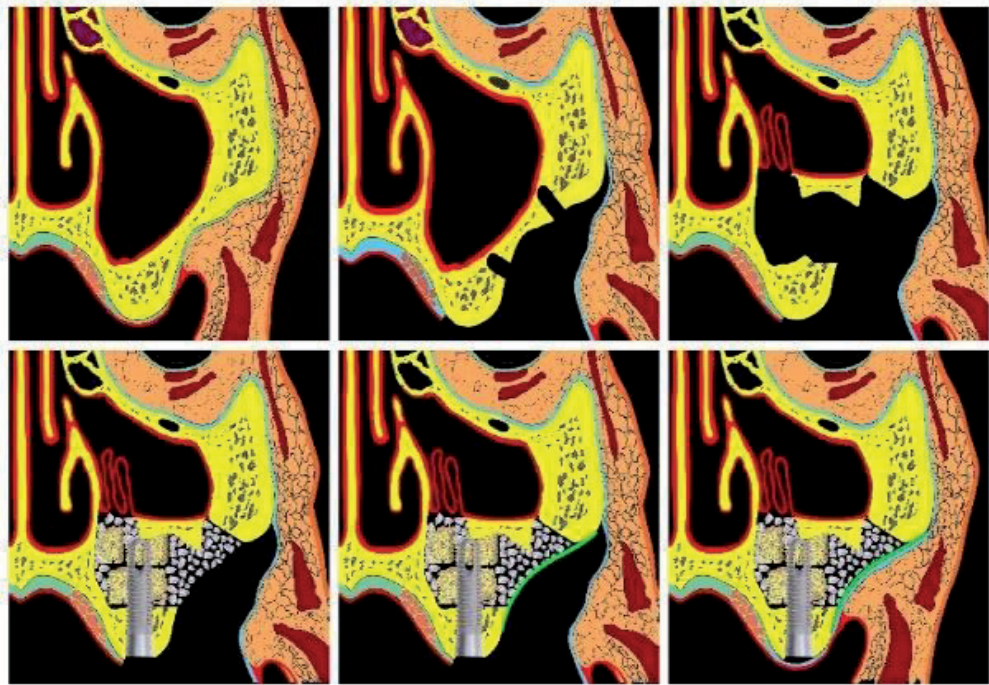


Figure 6.
MSFE with lateral approach, two-stage procedure.

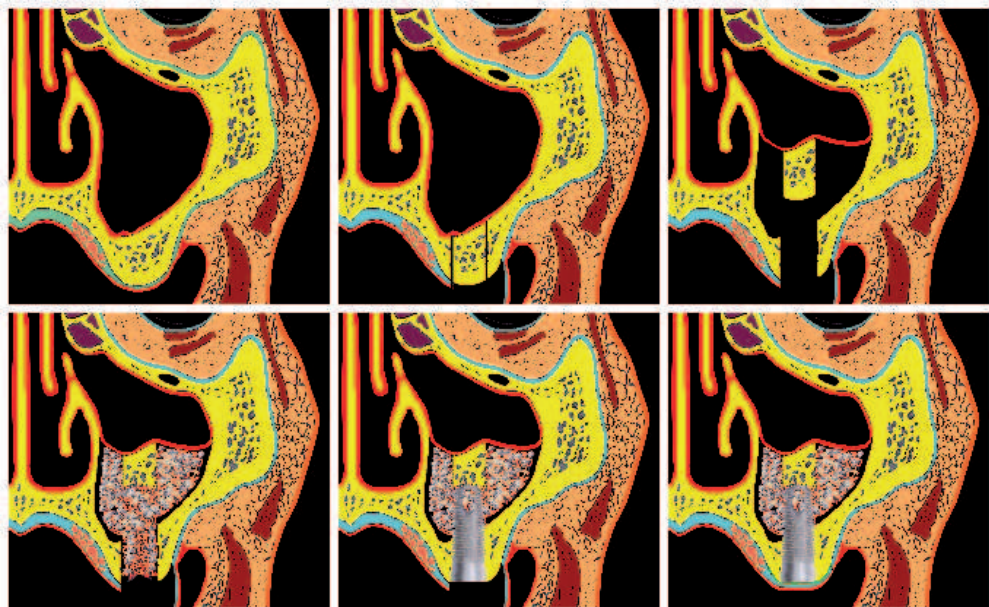


Figure 7.
MSFE with transcrestal approach, one-stage procedure.

The space within the “tent” is filled with grafting material and blood clot and the DI may be inserted into the tented space through the osteotomy opening (**Figure 7**). In cases when initial stability is doubtful the placement of the DI is postponed until the end of the healing period.

Several surgical techniques have been proposed to minimize the complications and postoperative morbidity of MSFE procedures.

Interradicular bone intrusion with MSFE is advocated in cases when sufficient in quantity (4–5 mm) interradicular septum is present after tooth removal. The central portion of the septum is freed with a standard osteotome, then a round osteotome is used to upfracture and intrude the alveolar fragment into the MS. This way, the socket is extended into the MS creating a new sinus floor at a higher level. Implant

placement is carried out if adequate bone height and primary implant stability can be achieved, otherwise, the DI is inserted after a healing period of 4 months [75].

The trans-alveolar sinus elevation with ridge expansion is applicable at sites with prominent MS with horizontal alveolar resorption. The procedure combines in a single surgery MSFE with buccal ridge expansion and implant placement. The crestal distraction develops an expanded intrabony space within the cancellous bone with intact periosteal blood supply followed by immediate gentle upfracture and displacement of the floor segment into the MS [76, 77].

Other options for augmentation of the distal maxilla include:

On-lay bone grafts and MSFE. In patients with insufficient subantral bone height and unfavorable interarch relations due to advanced horizontal and vertical resorption, the MSFE procedure may be conducted simultaneously with on-lay block grafts for vertical and/or horizontal ridge augmentation. The grafting material can be harvested from extra- and intraoral donor sites or allogeneous, xenogeneous, and alloplastic blocks can be used [78–80].

Le Fort I downgraft with MSFE. Cases with nearly total alveolar atrophy and unfavorable maxillo-mandibular interrelations can be treated with the Le Fort I downgraft osteotomy and interpositional bone graft from the iliac crest [81–84].

Le Fort I and alveolar distraction osteogenesis with bone grafting. A moderately atrophic, retro displaced edentulous maxilla can be distracted to Class I jaw relation when combined with sinus bone grafting. When a sinus bone grafted maxilla is anteriorized via distraction osteogenesis, the repositioned sinus floor bone mass allows for axial implant development throughout the arch, especially in the canine, premolar, and first molar areas [85].

Alternative procedures were proposed to avoid the more complex MSFE surgery.

Alveolar ridge preservation is a surgical technique developed to resist postextraction ridge resorption to simplify the treatment plan for DI insertion and to decrease the need for advanced surgical procedures. Recent systematic reviews with meta-analysis confirmed the effectiveness of this approach in reducing postextraction horizontal and vertical alveolar ridge resorption when compared to spontaneous socket healing. Alveolar ridge preservation after the extraction of a maxillary molar could be regarded as a preventive treatment, in cases where a DI-supported restoration is planned, allowing a standard DI placement without additional regenerative procedures. Today alveolar ridge preservation is the most common, easy to perform, and cheap procedure aiming to control crestal bone resorption after tooth loss [47].

Other alternatives that may avoid MSFE procedures are tilted, short, zygomatic, and pterygomaxillary implants.

5. The impact of maxillary sinus anatomy on maxillary sinus elevation procedures

All MSFE techniques share common features:

- DI is inserted into the MS through an osteotomy in the sinus floor, which is presented by the subantral alveolar ridge.
- A different amount of bone from the inferior and/or the lateral sinus wall is osteotomized, drilled, or removed.
- The Schneiderian membrane alone or kept attached to an osteotomized bone segment from the MS floor and/or the lateral wall is intruded into the sinus cavity, creating the new transpositioned sinus floor.

- Under the intruded with or without osteotomized bone Schneiderian membrane an empty space (“tent effect”) is created.
- The empty space is filled with bone grafts, osteoconductive or osteoinductive bone substitutes, blood clot, different compositions with the mentioned materials or it can be left empty, to be occupied with histologically mature host bone after a corresponding healing period.
- The MSFE techniques may be applied alone or in combination with other techniques for bone regeneration and augmentation, including alveolar augmentation, grafting, and transposition, distraction osteogenesis, and free revascularized flaps.

As seen from above, the MSFE operations use the inferior and lateral MS walls to enter the sinus cavity and to reconstruct its bottom into an alveolar ridge competent enough to accept, integrate, and keep DI capable to bear masticatory loads, and to oppose alveolar atrophy.

5.1 The maxillary sinus floor

All MSFE procedures insert DI through the inferior sinus wall. The transcrestal approach with its variations uses the sinus floor to approach and elevate the Schneiderian membrane. Thus, the inferior MS wall is assigned a key role in MSFE.

The floor of the antrum in dentate adults is approximately 1 cm below the nasal floor. Anteriorly the sinus extends in general to the canine and the premolar region. There is, however, a large variety in size and shape of the sinuses even within the same person. The convex sinus floor usually reaches its deepest point at the first molar region. Roots of the maxillary teeth frequently cause convolutions in the floor of the sinus [1].

Primary alveolar bone height and width. It is believed that the concomitant actions of AA and MSP determine the bone quality and quantity of the subantral ridge. The subantral alveolar dimensions should be examined before MSFE to assure that the conditions are suitable for DI accommodation and primary stability. The prerequisites are enough height, width, bone thickness, and intermaxillary relations that permit adequate functional loading and biomechanics. These features are of crucial importance to decide whether DI can be inserted in one or a two-stage procedure. The ridge dimensions necessary for conventional DI placement are 1.5 mm of intact bone on the buccal and the palatal side to resist the horizontal AA and tension, and 2 mm above the apical tip of the implant to withstand functional loads and spare neighboring anatomical structures, if any. When planning a one-stage MSFE for an implant with a 4 mm diameter the recommended ridge dimensions must be at least 4 mm bone height and 5 mm width. The bone density must also be considered. Soft bone cannot guarantee primary stability. Otherwise, when bone quality and quantity cannot meet the needed osseous environment for a one-stage procedure, the DI should be placed in a second stage 4 to 6 months after sinus floor grafting [1]. In conclusion, when sufficient alveolar height (± 4 mm) for primary stability is present, the DI can be inserted simultaneously with the MSFE. In cases with doubtful primary stability (bone height < 4 mm), the DI is inserted in a second procedure when bone-remodeling of the graft has taken place [1, 72].

Subantral dimensions as indications for MSFE procedures. The decision concerning DI size and number should rest not only on the available bone volume but should also take into consideration the prosthetic and biomechanical aspects. The classification of the International Team of Implantology categorizes the atrophic maxilla

into groups, and each group requires a different surgical approach to achieve ideal bone volume and three-dimensional interarch relations. These groups are [86]:

Group 1: Insufficient subantral bone height, adequate alveolar width, acceptable vertical and horizontal interarch relations. *Surgical approach:* MSFE with bone substitute and/or autogenous bone from intraoral bone sight.

Group 2: Insufficient subantral bone height, inadequate alveolar width, acceptable vertical and horizontal interarch relations. *Surgical approach:* MSFE with horizontal ridge augmentation. Autogenous horizontal block graft (from intra- or extraoral site according to the extent of AA) may be combined with a bone substitute and barrier membrane.

Group 3: Insufficient subantral bone height, adequate alveolar width, acceptable horizontal but unfavorable vertical interarch relations due to advanced crestal resorption. *Surgical approach:* MSFE and vertical ridge augmentation. Autogenous vertical block graft (from intra- or extraoral site according to the extent of AA) may be combined with a bone substitute and barrier membrane.

Group 4: Insufficient subantral bone height, unfavorable interarch relations due to advanced horizontal and vertical crestal resorption. *Surgical approach:* MSFE with vertical and horizontal ridge augmentation. Autogenous vertical block graft (from intra- or extraoral site according to the extent of AA) may be combined with a bone substitute and barrier membrane.

More detailed classifications have been proposed by Misch [87] and Chiapasco et al. [88].

5.2 The lateral (buccal) wall and trap-door preparation

The external MSFE enters the MS by preparing a hinge trapdoor osteotomy in it which is intruded into the sinus (**Figure 8**).

The lateral sinus wall is covered by muscle-periosteal tissue, containing the facial artery and vein, the lymphatic system, and the infraorbital nerves [69, 89]. The wall usually is thin, semi-transparent and the grayish blue Schneiderian membrane can be seen through it. The thin wall facilitates door preparation and intrusion; if this is not the case, it should be thinned out to ease the mobilization of the membrane from the inner aspect of the MS. A trapdoor that follows the inner

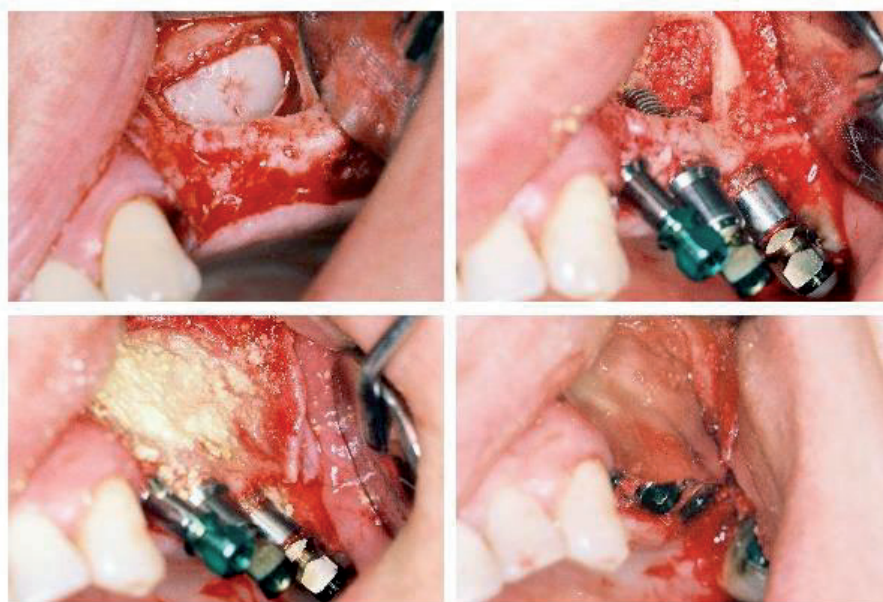


Figure 8.
 Lateral MSFE, trapdoor preparation and intrusion.

shape of the MS with a wide cranial hinge base and rounded corners is advocated. Three-dimensional cone-beam computed tomography and clinical inspection will provide information on the form, the curvature, the extent, and the circumference of the sinus. The rounded corners help door mobilization and intrusion and reduce the incidence of Schneiderian membrane perforations. After the preparation of the door is finished the Schneiderian will be visualized. Normal MS anatomy will allow the trapdoor to be intruded and lifted to a horizontal position. This is possible if only the Schneiderian membrane is sufficiently mobilized from the sinus floor. The too convex outer aspect of the lateral wall (the zygomatic process of the maxilla) restricts the door base to function as a hinge because the hinge line would cause a membrane tear during door luxation. This can be avoided by the transformation of the hinged door into a hatch door; after that, the whole bone fragment can be dislocated cranially [1].

5.3 The Schneiderian membrane

Normal antral mucosa is thin (1 mm thick) and less vascular than the nasal mucosa. The ciliated respiratory epithelium transports fluids like mucus and pus towards the internal ostium. The healthy membrane is grayish blue, with traces of blood vessels. In smokers, it may be atrophic, extremely thin, and fragile even to the slightest touch. During MSFE the membrane should be kept intact to secure hermetic graft seal. Only when the whole caudal membrane is prepared free from the sinus bottom the door can be lifted to the new horizontal position; the graft material must be placed until this level. Overfilling and tension may cause necrosis of the Schneiderian membrane, loss of graft, and sinusitis [1].

The most common complication during MSFE is the Schneiderian membrane perforation (**Figure 9**). Mobilization difficulties are met in detaching it from septa, longitudinal floor rims, convolutions, and root tip expressions. Certain anatomical features such as narrow sinuses and sharp sinus opening angles have also been recognized to increase the risk of membrane perforation. Adhesions between the oral and sinus mucosa in places with totally missing alveolar bone, as well, as scars from previous MS surgery may be a contraindication for MSFE because the membrane cannot be kept intact. Small perforations located in areas where the elevated mucosa forms multiple folds usually do not necessitate treatment because the folded membrane tends to close the perforation which heals spontaneously. Larger and/or unfolded perforations need closure and must be covered with resorbable membranes and biologic glues. In cases with very large perforations, further sinus elevation should be abandoned. Re-entry might be considered 6–8 weeks after the first surgical attempt [1].

5.4 Maxillary sinus septa

Maxillary sinus septa, or Underwood's septa, complete and incomplete, arise mainly from the floor but can spur from other walls. Incomplete septa divide the floor into compartments known as recesses (**Figure 9**), while complete septa may intercept the sinus into smaller sinuses (**Figure 10**). It is assumed that floor septa function as struts bearing the masticatory forces during the dentate phase of life and slowly disappear after tooth loss.

The presence of sinus floor septa determines the shape of the osteotomy. Short floor septa have no serious impact on the lateral MSFE as they cannot block the trapdoor intrusion, but the mobilization of the Schneiderian membrane is usually difficult. With high septa the door design must either follow the floor contour, outlining it in a W-shaped or any suitable form (**Figure 14**), or two trapdoors must

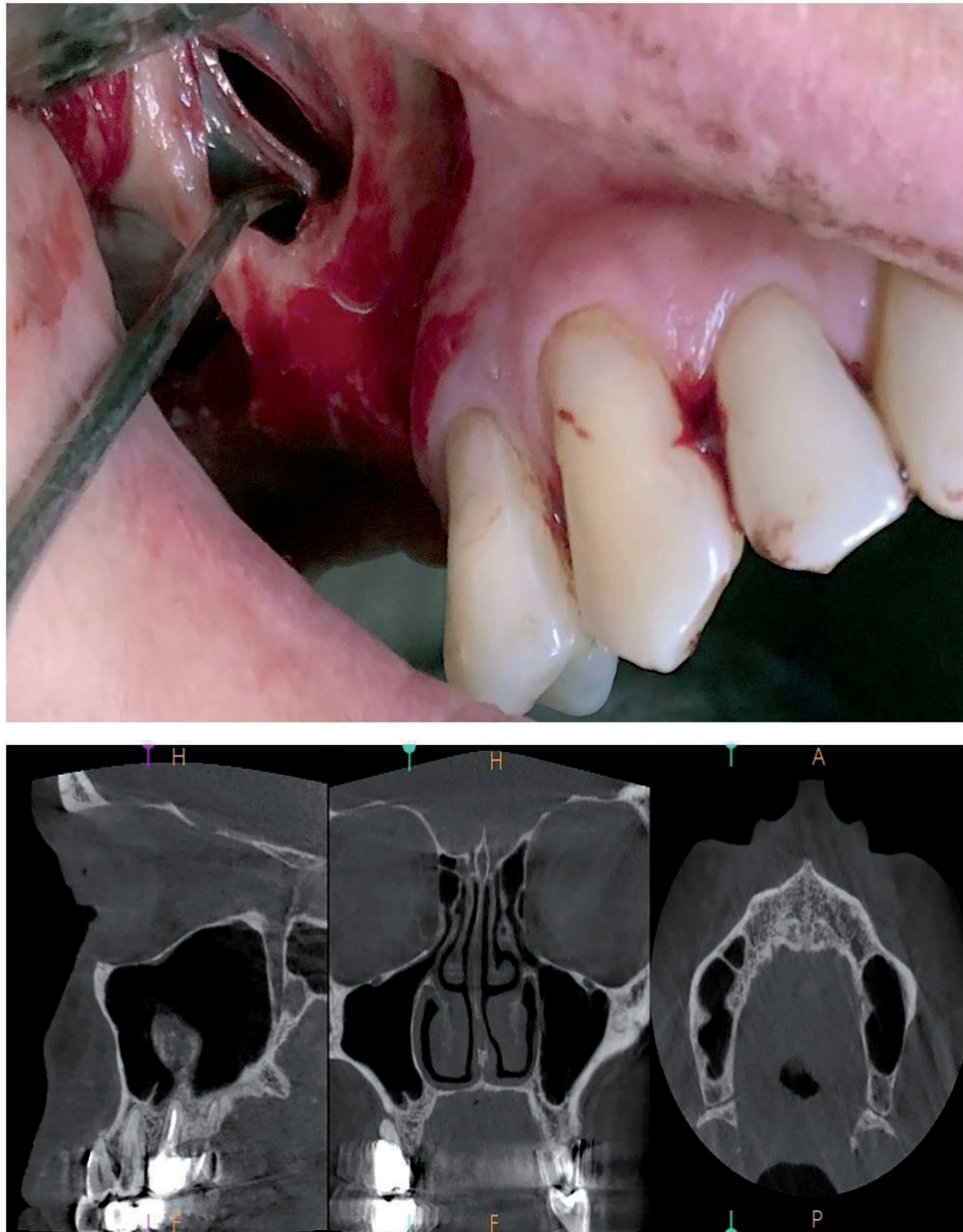


Figure 9.
A one-stage procedure consisting of extraction of the periodontally compromised right first and second maxillary molars, and lateral MSFE with simultaneous DI placement. The cause for the sinus membrane perforation is the inflammatory adhesion to the well-defined sinus floor septa and the lateral wall due to the long-lasting chronic periodontal lesions.

be performed, or the entry must be located at that side of the septum that corresponds to a recess (medial usually) in which the DI will be placed. Another option is to remove the septum through an antrostomy after the sinus mucosa has been prepared [1].

5.5 The narrow sinus

Narrow MS can only be recognized on a CT scan [90–92]. The narrow sinus, similarly, to high antral septa, will not allow for the upward intrusion of the trap-door to the appropriate level (**Figure 11**), because the sharp MS opening angle is a predisposition to a Schneiderian membrane perforation.

The solutions to this situation are either to make an antrostomy, removing the osteotomized segment of the lateral sinus wall, or convert the trapdoor into a hatch door, mobilized all around and kept attached to the sinus membrane peduncle only.

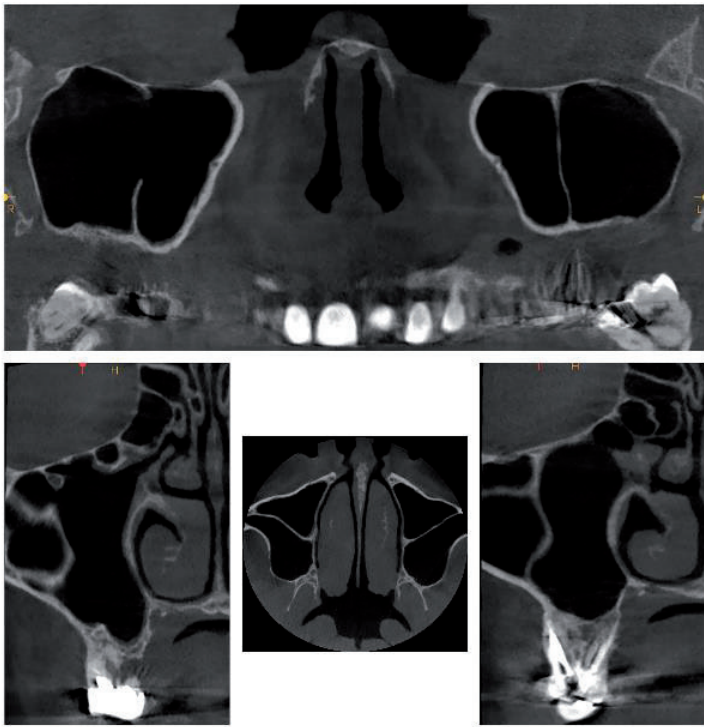

Figure 10.
Complete septa may divide the sinus into smaller sinuses.




Figure 11.
The narrow sinus will not allow for the upward intrusion of the trapdoor.

5.6 Anterior (buccal) wall and the infraorbital foramen

The anterior wall is made of thin compact bone, containing the neurovascular canals to the anterior teeth if present. The structure that must be avoided cranially is the infraorbital foramen. Not only might the preparation of the door be a threat

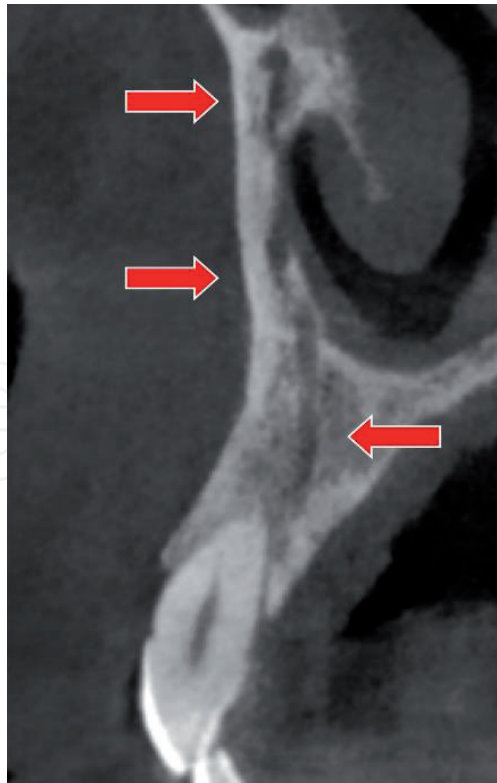


Figure 12.
Canalis sinuosus, ending in the canine area.

to the neuro-vascular bundle but also the possibility of mechanical damage by the wound retractor should be regarded. Normally however there is no reason for such high preparations because there is no need for such a high “door”. It might even cause the door to be too large for the width of the sinus, making it impossible to raise it to a horizontal level. This problem may also be encountered with the combination of “normal” sized doors and very narrow sinuses [1].

Canalis sinuosus is a small canal running through the anterior wall of the maxilla and then along the lateral wall of the nasal cavity, residing in the alveolar process of the maxilla (**Figure 12**). Its nerves and vessels supply anterior teeth and adjacent soft tissues. In rare cases, the small canal could be damaged if the anterior edge projection of the trapdoor goes too far anteriorly above the first maxillary premolar [93].

5.7 The internal or nasal wall and maxillary ostium

The internal wall has a rectangular shape and forms the bony septum between the nasal cavity and MS. The inferior part of the wall corresponds with the inferior meatus of the nasal cavity, marked by the tuberosity of the inferior concha at the top. At the cranial side of this wall a fragile bony structure, the so-called sinus hiatus or ostium, can be recognized, which drains the sinus into the middle nasal meatus. The architecture of the MS drainage is complex and consists of three passages. The first one is the ostium, which leads into the second passage, the ethmoid infundibulum, that conducts mucus from the maxillary sinus into the middle meatus via the third passage, the hiatus semilunaris. The obstruction of any of the three interconnected passages may lead to retention of the sinus secretions [94]. The competence of the ostium must be evaluated before and after MSFE and kept intact because arrests on drainage during the healing period may compromise the postoperative result (**Figure 13**).

An accessory ostium may sometimes be found on the medial wall. When this occurs, it should be identified before any maxillary sinus elevation procedure is performed to avoid detaching the mucosa up to this point.

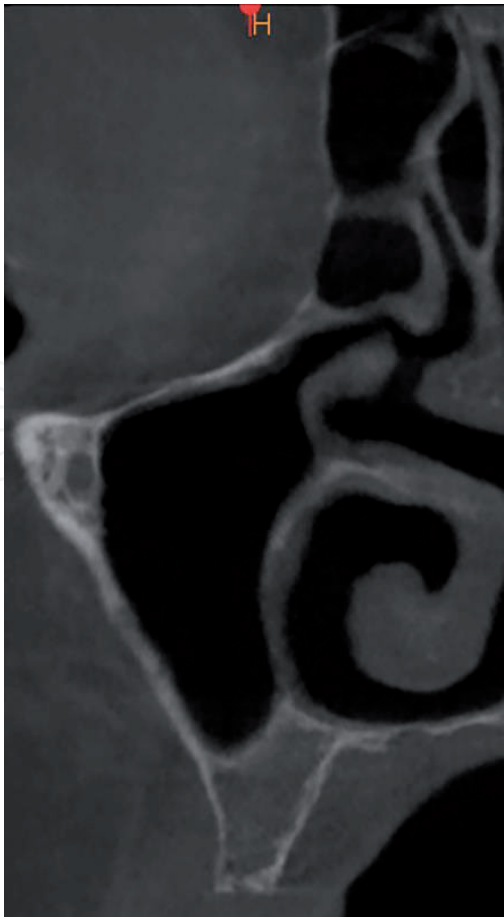

Figure 13.
Competent MS drainage.

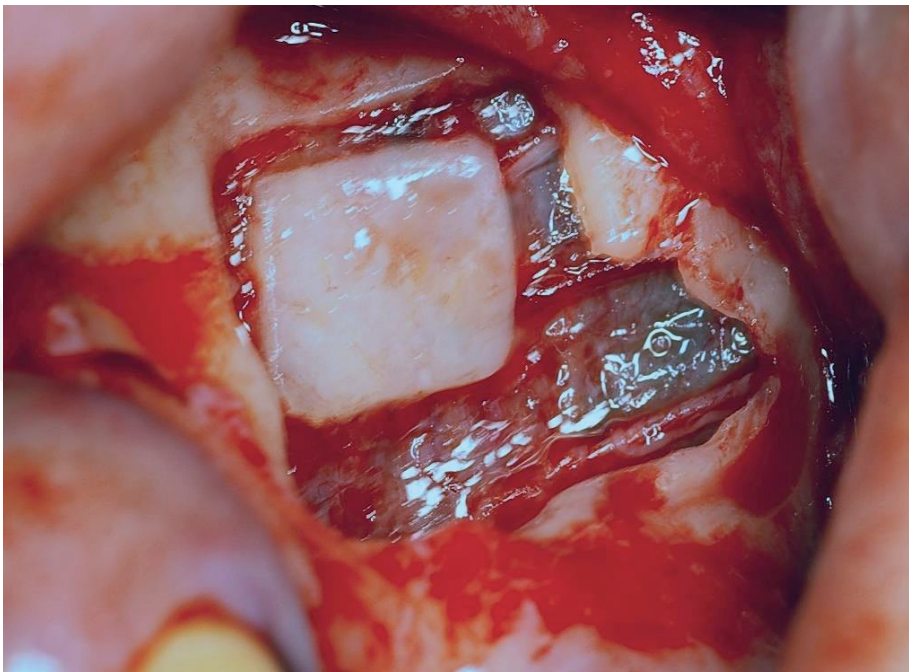


Figure 14.
Lateral MSFE with hatch door design and additionally enlarged window to follow the floor topography due to the presence of a floor septum. Note the neurovascular structures attached to the Schneiderian membrane. At the top, the membrane is traversed by the medial alveolar nerve, the bottom is crossed by the alveolar antral artery and its accompanying vein is seen in the middle.

Normal sinus physiology could be threatened if the function of the ciliated epithelium of the ostium is impaired after MSFE, but there is no clinical evidence for changed antral mucosal function after surgery [1].

5.8 Blood supply

The blood supply of the MS derives from the infraorbital artery, the greater palatine artery, and the posterior superior alveolar artery. Several anastomoses between the posterior superior alveolar artery and the infraorbital artery can be found inside the bony lateral antral wall, which also supplies the Schneiderian membrane as well as in the epiperiosteal vestibular tissues. The major intraosseous anastomosis, called the alveolar antral artery (**Figure 14**), passes through the area of the bony window [95]. In its course, the artery can lie strictly within the sinus wall, or it may occupy the inner surface of the bony window, or even may be attached to the outer

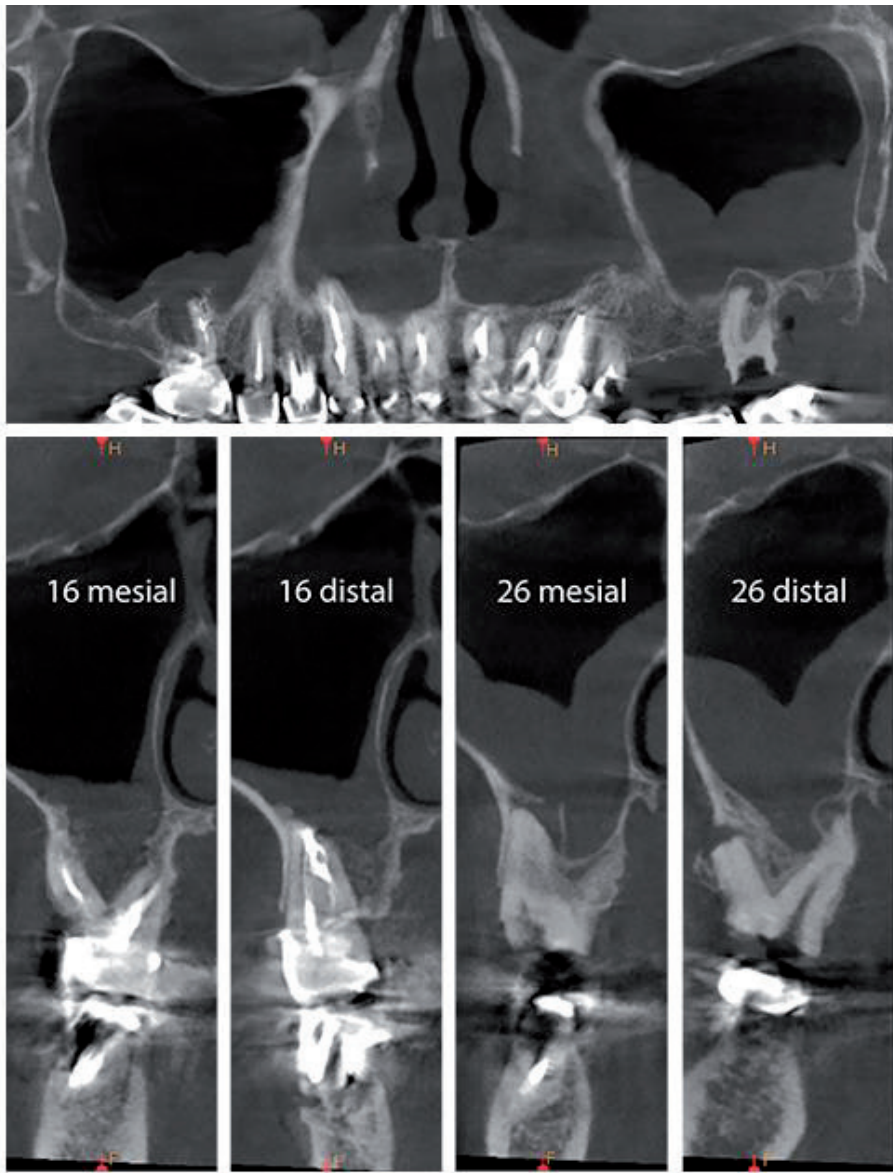


Figure 15.
Heavy chronic odontogenic sinusitis on both sides due to extensive endodontic and periodontal lesions. The interradicular septum of 16 is fully destroyed. The apical lesion around the mesio-vesibular root of 26 perforates the sinus floor and drains directly into the sinus.

aspect of the Schneiderian membrane. The mean distance between the intraosseous anastomoses and the alveolar ridge is 19 mm. The epiperiosteal vestibular anastomosis is situated at a more cranial level [1]. Hemorrhages during sinus grafting are rare since the main arteries are not within the surgical area. However, small vessels might be damaged. If they are located in the exposed Schneiderian membrane, they should best be left to stop spontaneously or stopped by slight gauze pressure. Electro-surgery will cause necrosis of the membrane and therefore can threaten the coverage of the graft.

The posterior teeth are supplied by neurovascular branches coming from the maxillary tuberosity. This must be kept in mind because a surgical approach too close to the apexes of vital neighboring teeth might devitalize them.

6. Maxillary sinus elevation and odontogenic sinus infections

Odontogenic infection of the MS, odontogenic sinusitis, accounts for about 10–25% of all cases suffering MS sinusitis. The primary cause usually is periapical or periodontal infection from maxillary molars and premolars, as the inflammatory exudate can easily erode through the thin floor to drain into the sinus (**Figure 15**). The etiology is predominantly bacterial, but, fungal infections must also be suspected because filamentous fungi from endodontically and periodontally compromised teeth can invade the sinus. Such teeth can serve as reservoirs for most common fungal infections as candidiasis, aspergillosis, and mucormycosis (zygomycosis). Allergic conditions may also lead to chronic reactive mucosal changes and can block normal sinus drainage. Obstruction of the osteomeatal unit is thought to be pivotal in the development and persistence of sinusitis (**Figure 15**) [96, 97].

In many patients, the disease is asymptomatic or causes minor inconveniences which explains why its role in MSFE is underestimated [97]. It must be emphasized that retention of secretions may compromise the short-term and long-term treatment success. The careful clinical and roentgenological examination is mandatory before MSFE, with no regard to the chosen approach. Chronic sinusitis is recognized as a thickening of the Schneiderian membrane and presents a contra-indication for sinus elevation. Even asymptomatic forms of infection cause serious complications. The operation should be postponed until the condition is placed under control.

Author details


Nikolay Uzunov^{1*} and Elena Bozhikova²

¹ Private Practice, Plovdiv, Bulgaria

² Medical University Plovdiv, Plovdiv, Bulgaria

*Address all correspondence to: nouzoun.nu@gmail.com

IntechOpen

© 2021 The Author(s). Licensee IntechOpen. This chapter is distributed under the terms of the Creative Commons Attribution License (<http://creativecommons.org/licenses/by/3.0>), which permits unrestricted use, distribution, and reproduction in any medium, provided the original work is properly cited. 

References

- [1] Bergh JPA, Bruggenkate ten CM, Disch F, Tuinzing D. Anatomical aspects of sinus floor elevations. *Clin Oral Impl Res.* 2000;11(3):256-265. doi:10.1034/j.1600-0501.2000.011003256.x 17
- [2] Sharan A, Madjar D. Maxillary sinus pneumatization following extractions: a radiographic study. *Int J Oral Maxillofac Implants.* 2008;23(1):48-56.
- [3] Esposito M, Felice P, Worthington H. (2014). Interventions for replacing missing teeth: augmentation procedures of the maxillary sinus. *Cochrane Database Syst Rev.* 2014;13(5), CD008397. doi:10.1002/14651858.CD008397.pub2.
- [4] Tarun Tumar A, Anand U. Maxillary sinus augmentation. *J Int Clin Dent Res Organ.* 2015;7:81-93.
- [5] Alveolar atrophy. (n.d). In Farlex partner medical dictionary. (2012). Retrieved 5 27, 2021, from <https://medical-dictionary.thefreedictionary.com/alveolar+atrophy>
- [6] Schropp L, Wenzel A, Kostopoulos L, Karring T. Bone healing and soft tissue contour changes following single-tooth extraction: a clinical and radiographic 12-month prospective study. *Int J Periodontics Restorative Dent.* 2003;23(4):313-323.
- [7] Lekovic V, Camargo PM, Klokkevold PR, Weinlaender M, Kenney EB, Dimitrijevic B, Nedic M. Preservation of alveolar bone in extraction sockets using bioabsorbable membranes. *J Periodontol.* 1998;69:1044-9.
- [8] Tallgren A. The continuing reduction of the residual alveolar ridges in complete denture wearers: a mixed-longitudinal study covering 25 years. 1972. *J Prosthet Dent* 2003;89(5): 427-435.
- [9] Pinho M, Roriz V, Novaes A, Taba MJ, Grisi M, de Souza S., Palioto D. Titanium membranes in prevention of alveolar collapse after tooth extraction. *Implant Dent.* 2006;15(1):53-62.
- [10] Hansson S, Halldin A. Alveolar ridge resorption after tooth extraction: A consequence of a fundamental principle of bone physiology. *J Dent Biomech.* 2012;31. doi:10.1177/1758736012456543 20
- [11] Beaupre G, Orr T, Carter D. An approach for time dependent bone modeling and remodeling - theoretical development. *J Orthop Res.* 1990;8(5):651-661. doi: 10.1002/jor.1100080506.
- [12] Frost HM. Perspectives: a proposed general model of the "mechanostat" (suggestions from a new skeletal-biologic paradigm). *Anat Rec.* 1996;244(2):139-47.
- [13] Burger E, Klein-Nulend J. Mechanotransduction in bone – role of the lacuno-canalicular network. *FASEB J.* 1999;13 (Supl.), S101-S112.
- [14] Schneider P, Meier M, Wepf R, Müller R. Towards quantitative 3D imaging of the osteocyte lacuno-canalicular network. *Bone.* 2010;47; 848-858
- [15] Bonewald L. The amazing osteocyte. *J Bone Miner Res.* 2011;26(2):229-238. doi:10.1007/s11914-019-00515-z
- [16] Dallas S, Prideaux M, Bonewald L, et al. The osteocyte: An endocrine cell ... and more. *Endocr. Rev.* 2013;34(5), 658-690.
- [17] Weinkamer, R, Kollmannsberger P, Fratzl P. (2019). Towards a connectomic description of the osteocyte lacunocanalicular network in bone. *Curr Osteoporos Rep.* 2019;1:186-194.

- [18] Yu B, Pacureanu A, Olivier C, Cloetens C, Peyrin F. Assessment of the human bone lacuno-canalicular network at the nanoscale and impact of spatial resolution. *Sci Rep.* 2020;10:4567. doi:10.1038/s41598-020-61269-8
- [19] Bonewald L. Osteocytes as dynamic multifunctional cells. *Ann N Y Acad Sci.* 2007;1116:281-290. doi:10.1196/annals.1402.018
- [20] Hamrick, M. Leptin, bone mass, and the thrifty phenotype. *J Bone Miner Res.* 2004;19(10):1607-1611. doi:10.1196/annals.1402.018.
- [21] Nakashima T, Hayashi, M, Fukunaga T, Kurata K, Oh-Hora M, Feng JQ, et. al. Evidence for osteocyte regulation of bone homeostasis through RANKL expression. *Nat. Med.* 2011;17(10):1231-1234.
- [22] Fulzele K, Lai F, Dedic F, Saini V, Uda Y, Shi C, et al. Osteocyte-secreted Wnt signaling inhibitor sclerostin contributes to beige adipogenesis in peripheral fat depots. *J. Bone Miner. Res.* 2017;32:373-384.
- [23] Rauch F. The brains of the bones: how osteocytes use WNT1 to control bone formation. *J. Clin. Invest.* 2017;127(7):2539-2540.
- [24] Asada N, Sato M, Katayama Y. Communication of bone cells with hematopoiesis, immunity, and energy metabolism. *BoneKEy Rep.* 2015;4:748. doi:10.1038/bonekey.2015.117.
- [25] Jacobs C, Temiyasathit S, Castillo A. Osteocyte mechanobiology and pericellular mechanics. *Annu Rev Biomed Eng.* 2010;12(1);369-400. doi:10.1146/annurev-bioeng-070909-105302
- [26] Moester M, Papapoulos S, Löwik C, Van Bezooijen R. Sclerostin: current knowledge and future perspectives. *Calcif Tissue Int.* 2010;87(2):99-107
- [27] McDonald M, Khoo W, Ng P, Xiao Y, Zamerli J, Thatcher P. et al. Osteoclasts recycle via osteomorphs during RANKL during RANKL-stimulated bone resorption. *Cell.* 2021. doi:10.1016/j.cell.2021.02.0022021
- [28] Qin Y-X, Rubin C, McLeod K. Nonlinear dependence of loading intensity and cycle number in the maintenance of bone mass and morphology. *J Orthop Res.* 1998;16: 482-489.
- [29] Lanyon L. Experimental support for the trajectorial theory of bone structure. *J Bone Joint Surg Br.* 1974;156-B(1);160-166.
- [30] Skedros J, Baucom S. Mathematical analysis of trabecular ‘trajectories’ in apparent trajectorial structures: the unfortunate historical emphasis on the human proximal femur. *J Theor Biol.* 2007;244(1):15-45.
- [31] Pontzer H, Lieberman D, Momin E, Devlin M, Polk J, Hallgrímsson B, Cooper, D. Trabecular bone in the bird knee responds with high sensitivity to changes in load orientation. *J Exp Biol* 2006;209(1):57-75.
- [32] Petrtyl M, Hert J, Fiala P. Spatial organization of the Haversian bone in man. *J Biomech.* 1996;29(2):161-169.
- [33] Cardaropoli G, Araujo M, Lindhe J. Dynamics of bone tissue formation in tooth extraction sites. An experimental study in dogs. *J Clin Periodontol.* 2003;30(9):809-818. doi:10.1034/j.1600-051x.2003.00366.x.
- [34] Pietrokovski J. Massler M. Alveolar ridge resorption following tooth extraction. *J Prosthet Dent.* 1967;17 (1):21-27.
- [35] Botticelli D, Berglundh T, Lindhe J. Hard-tissue alterations following immediate implant placement in extraction sites. *J Clin Periodontol,* 2004;31:820-828.

- [36] Araujo M, Sukekava F, Wennstrom JL, Lindhe J. Ridge alterations following implant placement in fresh extraction sockets: an experimental study in the dog. *J Clin Periodontol*. 2005;32(6):645-652.
- [37] Sanz M, Cecchinato D, Ferrus J, Pjetursson EB, Lang NP, Lindhe J. A prospective, randomized-controlled clinical trial to evaluate bone preservation using implants with different geometry placed into extraction sockets in the maxilla. *Clin Oral Implants Res*. 2010;21(1):13-21.
- [38] Rubin C, Sommerfeldt D, Judex S, Qin, Y. Inhibition of osteopenia by low magnitude, high-frequency mechanical stimuli. *Drug Discov Today*. 2001;6(16):848-858.
- [39] Toro-Ibacache V, Zapata Muñoz V, O'Higgins P. The relationship between skull morphology, masticatory muscle force and cranial skeletal deformation during biting. *Ann Anat*. 2016;203:59-68.
- [40] Van der Weijden F, Dell'Acqua F, Slot DE. Alveolar bone dimensional changes of post-extraction sockets in humans: a systematic review. *J Clin Periodontol*. 2009;36(12):1048-1058.
- [41] Covani U, Ricci M, Bozzolo G, Mangano F, Zini A, Barone A. Analysis of the pattern of the alveolar ridge remodeling following single tooth extraction. *Clin Oral Implants Res*. 2011;22(8):820-825.
- [42] Chappuis V, Engel O, Reyes M, Shahim KN-P, Buser D. Ridge alterations post-extraction in the esthetic zone: a 3D analysis with CBCT. *J Dent Res*. 2013;92(12):195s-201s. doi:10.1177/0022034513506713.
- [43] Misawa M, Lindhe J, Araújo MG. The alveolar process following single-tooth extraction: a study of maxillary incisor and premolar sites in man. *Clin Oral Implants Res*. 2016 Jul;27(7):884-9.
- [44] Covani U, Giammarinaro E, Marconcini S. Alveolar socket remodeling: The tug-of-war model. *Med Hypotheses*. 2020;142(109746).
- [45] Noelken R, Oberhansl F, Kunkel M, Wagner W. Immediately provisionalized OsseoSpeed[™] Profile implants inserted into extraction sockets: 3-year results. *Clin Oral Implants Res*. 2016;27(6):744-9.
- [46] Pramstraller M, Farina R, Franceschetti G, Pramstraller C, Trombelli L. Ridge dimensions of the edentulous posterior maxilla: a retrospective analysis of a cohort of 127 patients using computerized tomography data. *Clin Oral Implants Res*. 2011 Jan;22(1):54-61. Erratum in: *Clin Oral Implants Res*. 2011 Feb;22(2):235.
- [47] Lombardi T, Bernardello F, Berton F, Porrelli D, Rapani A, Piloni A-C, et al. Efficacy of alveolar ridge preservation after maxillary molar extraction in reducing crestal bone resorption and sinus pneumatization: A multi-center prospective case-control study. *BioMed Res Int*. 2018;9352130.
- [48] Adibelli ZH, Songu M, Adibelli H. Paranasal sinus development in children: A magnetic resonance imaging analysis. *Am J Rhinol Allergy*. 2011;25(1):30-5.
- [49] Nuñez-Castruita A, López-Serna N, Guzmán-López S. Prenatal development of the maxillary sinus: a perspective for paranasal sinus surgery. *Otolaryngol Head Neck Surg*. 2012;146(6):997-1003.
- [50] Scuderi AJ, Harnsberger HR, Boyer RS. Pneumatization of the paranasal sinuses: normal features of importance to the accurate interpretation of CT scans and MR images. *AJR Am J Roentgenol*. 1993;160(5):1101-1104.

- [51] Hauman C, Chandler N, Tong D. Endodontic implications of the maxillary sinus: a review. *Int Endod J*. 2002;35:127-141.
- [52] Eberhardt JA, Torabinejad M, Christiansen EL. A computed tomographic study of the distances between the maxillary sinus floor and the apices of the maxillary posterior teeth. *Oral Surg Oral Med Oral Pathol*. 1992;73(3):345-6.
- [53] Ariji Y, Kuroki T, Moriguchi S, Ariji E, Kanda S. Age changes in the volume of the human maxillary sinus: a study using computed tomography. *Dentomaxillofac Radiol*. 1994;23(3):163-8.
- [54] Ariji Y, Obayashi N, Goto M, Izumi M, Naitoh M, Kurita K, Shimozato K, Ariji E. Roots of the maxillary first and second molars in horizontal relation to alveolar cortical plates and maxillary sinus: computed tomography assessment for infection spread. *Clin Oral Investig*. 2006;10(1):35-41.
- [55] Gu Y, Sun C, Wu D, Zhu Q, Leng D, Zhou Y. Evaluation of the relationship between maxillary posterior teeth and the maxillary sinus floor using cone-beam computed tomography. *BMC Oral Health*. 2018 3;18(1):164.
- [56] Cavalcanti MC, Guirado TE, Sapata VM, Costa C, Pannuti CM, Jung RE, César Neto JB. Maxillary sinus floor pneumatization and alveolar ridge resorption after tooth loss: a cross-sectional study. *Braz Oral Res*. 2018;32:e64.
- [57] Kwak HH, Park HD, Yoon HR, Kang MK, Koh KS, Kim HJ. Topographic anatomy of the inferior wall of the maxillary sinus in Koreans. *Int J Oral Maxillofac Surg*. 2004;33(4):382-8.
- [58] Wehrbein H, Diedrich P. Die fortschreitende Pneumatisation der basalen Kieferhöhle nach Extraktion und Lückenschluss [Progressive pneumatization of the basal maxillary sinus after extraction and space closure]. *Fortschr Kieferorthop*. 1992 Apr;53(2):77-83. German.
- [59] Nimigeon VR, Nimigeon V, Maru N, Andressakis D, Balatsouras DG, Danielidis V. The maxillary sinus and its endodontic implications: clinical study and review. *B-ENT*. 2006;2(4):167-75.
- [60] Kasikcioglu A, Gulsahi A. Relationship between maxillary sinus pathologies and maxillary posterior tooth periapical pathologies. *Oral Radiol*. 2016;32:180-186. doi:10.1007/s11282-015-0231-7.
- [61] Chaiyasate S, Baron I, Clement P. Analysis of paranasal sinus development and anatomical variations: a CT genetic study in twins. *Clin Otolaryngol*. 2007;32(2):93-97.
- [62] Butaric LN, Maddux SD. Morphological Covariation between the Maxillary Sinus and Midfacial Skeleton among Sub-Saharan and Circumpolar Modern Humans. *Am J Phys Anthropol*. 2016;160(3):483-97. doi: 10.1002/ajpa.22986. Epub 2016 Mar 24. PMID: 27009746.
- [63] Ariji Y, Ariji E, Yoshiura K, Kanda S. Computed tomographic indices for maxillary sinus size in comparison with the sinus volume. *Dentomaxillofac Radiol*. 1996 Jan;25(1):19-24.
- [64] Ohba T, Langlais RYM, Tanaka T, Hashimoto K. Maxillary sinus floor in edentulous and dentate patients. *Indian J Dent Res*. 2001;12(3):121-125.
- [65] Wagner F, Dvorak G, Nemec S, Pietschmann P, Figl M, Seemann R. A principal components analysis: how pneumatization and edentulism contribute to maxillary atrophy. *Oral Dis*. 2017;23(1):55-61.

- [66] Nimigean V, Nimigean VR, Măru N, Sălăvăstru DI, Bădiță D, Tuculină MJ. The maxillary sinus floor in the oral implantology. *Rom J Morphol Embryol*. 2008;49(4):485-9.
- [67] Shahbazian M, Xue D, Hu Y, van Cleynebreugel J, Jacobs R. Spiral computed tomography based maxillary sinus imaging in relation to tooth loss, implant placement and potential grafting procedure. *J Oral Maxillofac Res*. 2010;1(1):e7.
- [68] Levi I, Halperin-Sternfeld M, Horwitz J, Zigdon-Giladi H, Machtei EE. Dimensional changes of the maxillary sinus following tooth extraction in the posterior maxilla with and without socket preservation. *Clin Implant Dent Relat Res*. 2017;19(5): 952-958.
- [69] Kao D. Clinical Maxillary Sinus Elevation Surgery. (D. Kao, Ed.) 2014. Willey-Blackwell. doi:10.1002/9781118871331.
- [70] Tatum H Jr. Maxillary and sinus implant reconstructions. *Dent Clin North Am*. 1986;30(2):207-209.
- [71] Boyne P, James R. Grafting of the maxillary sinus floor with autogenous marrow and bone. *J Oral Surg* 1980;38: 613-616.
- [72] Woo I, Le BT. Maxillary sinus floor elevation: review of anatomy and two techniques. *Implant Dent*. 2004;13(1): 28-32.
- [73] Summers RB. A new concept in maxillary implant surgery: the osteotome technique. *Compendium*. 1994;15(2):152, 154-6, 158 passim; quiz 162.
- [74] Summers, R. Osteotome technique for site development and sinus floor augmentation. In: Jensen O, editor. *The sinus bone graft*. 2nd ed. Chicago: Quintessence Publishing Co, Inc.;2006: 263-272.
- [75] Fugazzotto P, Jensen O. Sinus floor augmentation at the time of tooth removal. In: Jensen O, editor. *The sinus bone graft*. 2nd ed. Chicago: Quintessence Publishing Co, Inc.;2006; 67-74.
- [76] Bruschi GB, Scipioni A, Calesini G, Bruschi E. Localized management of sinus floor with simultaneous implant placement: a clinical report. *Int J Oral Maxillofac Implants*. 1998;13(2):219-26.
- [77] Cullum D, Jensen O. Trans-alveolar sinus elevation with ridge expansion. In: Jensen O, editor. *The sinus bone graft*. 2nd ed. Chicago: Quintessence Publishing Co, Inc.;2006;251-262).
- [78] Isaksson S, Alberius P. Maxillary alveolar ridge augmentation with onlay bone-grafts and immediate endosseous implants. *J Craniomaxillofac Surg*. 1992;20(1):2-7.
- [79] Schwartz-Arad D, Levin L. Intraoral autogenous block onlay bone grafting for extensive reconstruction of atrophic maxillary alveolar ridges. *J Periodontol*. 2005;76(4):636-641.
- [80] Schwartz-Arad D, Ofec R, Eliyahu G, Sterer N, Ruban A. Onlay bone graft augmentation for the treatment of maxillary atrophy: Long-term (up to 131 months) follow-up on 272 implants. *Journal of Cosmetic Dentistry*. 2015;31(3):78-93.
- [81] Farrell CD, Kent JN, Guerra LR. One-stage interpositional bone grafting and vestibuloplasty of the atrophic maxilla. *J Oral Surg*. 1976 Oct;34(10):901-6. PMID: 787482.
- [82] Kahnberg K, Nystrom E, Bartholdsson L. Combined use of bone grafts and Branemark fixtures in the treatment of severely resorbed maxillae. *Int J Oral Maxillofac Implants*. 1989;4:297-304.
- [83] Isaksson S. Evaluation of three bone grafting techniques for severely

resorbed maxillae in conjunction with immediate endosseous implants. *Int J Oral Maxillofac Implants*. 1994;9: 679-688.

[84] Jensen O, Branca R. Le Fort I downgraft with sinus elevation. In: Jensen O, editor. *The sinus bone graft*. 2nd ed. Chicago: Quintessence Publishing Co, Inc.;2006;241-250.

[85] Jensen O, Laster Z. Le Fort I and alveolar distraction osteogenesis with bone grafting. In: Jensen O, editor. *The sinus bone graft*. 2nd ed. Chicago: Quintessence Publishing Co, Inc.;2006;281-288.

[86] Katsuyama, H., & Jensen, S. *ITI treatment guide. Sinus floor elevation procedures*. 1st ed. Vol. 5. (S. Chen, D. Buser, & D. Wismejer, Eds.) Berlin: Quintessence Publishing Co, Inc.; 2011.

[87] Misch, C. Treatment planning for the edentulous posterior maxilla. In: Misch, C, editor. *Contemporary Implant Dentistry*. St. Louis: Mosby-Elsevier; 2008: 389-405.

[88] Chiapasco M, Zaniboni M, Rimondini L. Dental implants placed in grafted maxillary sinuses: a retrospective analysis of clinical outcome according to the initial clinical situation and a proposal of defect classification. *Clin Oral Implants Res*. 2008;19(4):416-28.

[89] Chanavaz M. Maxillary sinus: anatomy, physiology, surgery, and bone grafting related to implantology--eleven years of surgical experience (1979-1990). *J Oral Implantol*. 1990;16(3): 199-209.

[90] Velloso GR, Vidigal GM Jr, de Freitas MM, Garcia de Brito OF, Manso MC, Groisman M. Tridimensional analysis of maxillary sinus anatomy related to sinus lift procedure. *Implant Dent*. 2006;15(2): 192-6.

[91] Cho SC, Wallace SS, Froum SJ, Tarnow DP. Influence of anatomy on Schneiderian membrane perforations during sinus elevation surgery: three-dimensional analysis. *Pract Proced Aesthet Dent*. 2001;13:160-3.

[92] Wagner F, Dvorak G, Nemec S, Pietschmann P, Traxler H, Schicho K, Seemann R. Morphometric analysis of sinus depth in the posterior maxilla and proposal of a novel classification. *Sci Rep*, 2017;7:45397.

[93] Neves FS, Crusoé-Souza M, Franco LC, Caria PH, Bonfim-Almeida P, Crusoé-Rebello I. Canalis sinuosus: a rare anatomical variation. *Surg Radiol Anat*. 2012;34(6):563-6.

[94] Prasanna L, Mamatha H. The location of maxillary sinus ostium and its clinical application. *Indian J Otolaryngol Head Neck Surg*.2010; 62(4): 335-337. doi:10.1007/s12070-010-0047-z.

[95] Valente NA. Anatomical Considerations on the Alveolar Antral Artery as Related to the Sinus Augmentation Surgical Procedure. *Clin Implant Dent Relat Res*. 2016;18(5):1042-1050.

[96] Ferguson M. Rhinosinusitis in oral medicine and dentistry. *Aust Dent J*. 2014;59(3):289-95.

[97] Selvamani M, Donoghue M, Bharani S, Madhushankari GS. Mucormycosis causing maxillary osteomyelitis. *J Natural Sci Biol Med*. 2015;6(2):456-459.