

# We are IntechOpen, the world's leading publisher of Open Access books Built by scientists, for scientists

6,900

Open access books available

185,000

International authors and editors

200M

Downloads

Our authors are among the

154

Countries delivered to

TOP 1%

most cited scientists

12.2%

Contributors from top 500 universities



WEB OF SCIENCE™

Selection of our books indexed in the Book Citation Index  
in Web of Science™ Core Collection (BKCI)

Interested in publishing with us?  
Contact [book.department@intechopen.com](mailto:book.department@intechopen.com)

Numbers displayed above are based on latest data collected.  
For more information visit [www.intechopen.com](http://www.intechopen.com)



# Arthroscopic Bankart Repair Using a Lasso-Loop Stitch

*Christian Konrads and Stefan Döbele*

## Abstract

Anterior inferior shoulder dislocation is a common injury. After primary traumatic shoulder dislocation and conservative treatment, the risk of re-dislocation is very high in patients younger than 35 years. With age, the risk of re-dislocation after traumatic shoulder dislocation and conservative treatment decreases. Surgical treatment via either open or arthroscopic stabilization minimizes the risk of re-dislocation. Today, anterior shoulder stabilization by arthroscopic refixation of the labroligamentous complex with suture anchors is a standard procedure, if there is no severe chronic bony defect at the glenoid site. Lafosse et al. described the so-called „Lasso-loop stitch“. This technique allows for positioning of the knot away from the joint and at the same time it establishes a labral bump that stabilizes the humeral head against (sub)luxation. The surgical principle and aim consist of refixation of the anterior labrum-capsule-ligament complex to the glenoid with positioning of the knot at distance to the joint as well as bulging up the labrum. This stabilizes the shoulder joint and therefore avoids further dislocations and associated pathologies. The aim of this work is to give an illustrated instruction of the surgical technique of arthroscopic Bankart repair using the lasso-loop stitch.

**Keywords:** Shoulder instability, Dislocation, ALPSA, Perthes lesion, Hill Sachs

## 1. Introduction

After traumatic first-time shoulder dislocation followed by conservative treatment, the re-dislocation rate is >70% in patients <30 years. With age, the risk of re-dislocation after traumatic shoulder dislocation and conservative treatment decreases. Surgical treatment via either open or arthroscopic stabilization minimizes the risk of re-dislocation [1–4].

In cases without severe chronic bone loss at the glenoid site, anterior shoulder stabilization by arthroscopic refixation of the labroligamentous complex with suture anchors is the standard therapeutic procedure [1, 5]. The so-called „Lasso-loop stitch“ was described by Lafosse et al [6–9]. This technique allows positioning of the knot away from the joint and at the same time it establishes the sought labral bump. With the “Oblique mattress lasso-loop stitch” Parnes et al. published a resembling arthroscopic technique, but without giving clinical results [10].

The goal of the surgery is refixation of the anterior labrum-capsule-ligament complex to the glenoid with positioning of the knot at distance to the joint as well as bulking up the labrum. This stabilizes the gleno-humeral joint and therefore

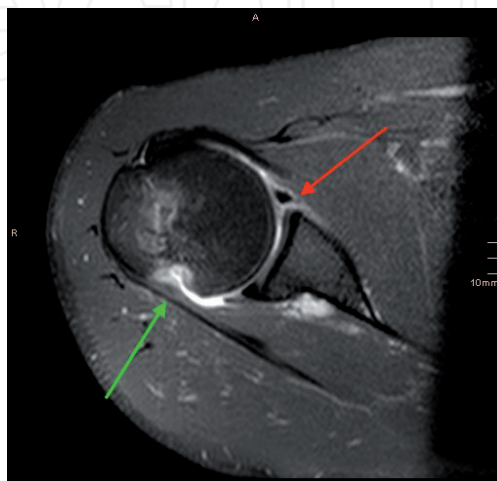
avoids further dislocations and associated pathologies. Using lasso-loop stitches probably leads to more bulging up of the labrum than other stitching techniques as for example the single interrupted stitch or the mattress stitch. The lasso-loop stitch accentuates the physiological bumper effect of the glenoid labrum and can therefore avoid re-dislocation.

Indications for this operation are shoulder instabilities with repairable damage to the labrum: Bankart lesion, bony Bankart lesion, ALPSA, Perthes lesion, and reversed (posterior) Bankart lesions as well as injuries to the long head biceps tendon anchor (SLAP). Contraindications for this operation are arbitrary shoulder dislocations during growth period without damage to the labrum and chronic bony glenoid defects >15% of the glenoid surface [11–13]. HAGL lesions require soft-tissue refixation at the humeral site [14].

Patient consent should contain the following issues apart from the standard operation risks: cartilage damage, lesion to the axillary nerve, suture rupture, switching to open surgical procedure in case of larger bony defects, standardized postoperative treatment, restriction of motion (especially external rotation), re-dislocation, anchor dislocation, osteolysis in case of resorbable anchors, post-traumatic arthritis, pain, hospitalization for 1–2 days, day surgery possible, work leave dependent on job and arm dominance 2 days to 16 weeks.

While recording the patient history, it is critical to differentiate between traumatic and habitual cause and evaluate the main symptom, either pain or instability. It is followed by a standardized clinical examination including apprehension sign and determination of the instability direction as well as evaluating an existing hyperlaxity. X-rays of the shoulder in three planes (true a.p., y-view, axial) and MRI (**Figure 1**) are performed [15, 16]. The surgical site should be shaved, if strongly covered by hair. An examination under anesthesia is performed to record the passive glenohumeral range of motion following the neutral-zero method as well as evaluation of glenohumeral stability and translation according to the modified Hawkins classification [6] and exclusion of multidirectional instability. In case of larger glenoid defects, a CT scan is necessary [17].

With this technical modification to the classic arthroscopic Bankart repair, we reliably experienced very good clinical results and high patient satisfaction. It is the aim of this work to give an illustrated instruction of the surgical technique of arthroscopic Bankart repair using the lasso-loop stitch.



**Figure 1.** MRI of the right shoulder of a 20-year-old male after primary traumatic anterior-inferior shoulder dislocation. The red arrow marks a classic Bankart lesion. The green arrow marks a concomitant hill-Sachs lesion.

## 2. Surgery

### 2.1 Setup

Surgery is performed under general anesthesia. Preoperatively, a prophylactic antibiotic single shot dose of 2 g Ampicillin and 1 g Sulbactam i. v. is administered. Dependent on preference, the operation can be done in beach chair position or lateral decubitus position with lateral tension. The latter increases the intraarticular space by putting traction on the arm. Alternatively, a special arm holder with free positioning of the arm in slight abduction and external rotation can be used. We routinely used the latter option.

After diagnostic arthroscopy, fixation of the anterior capsulo-labral complex with suture anchors in lasso-loop technique is performed. The following arthroscopy equipment and instruments are used during surgery:

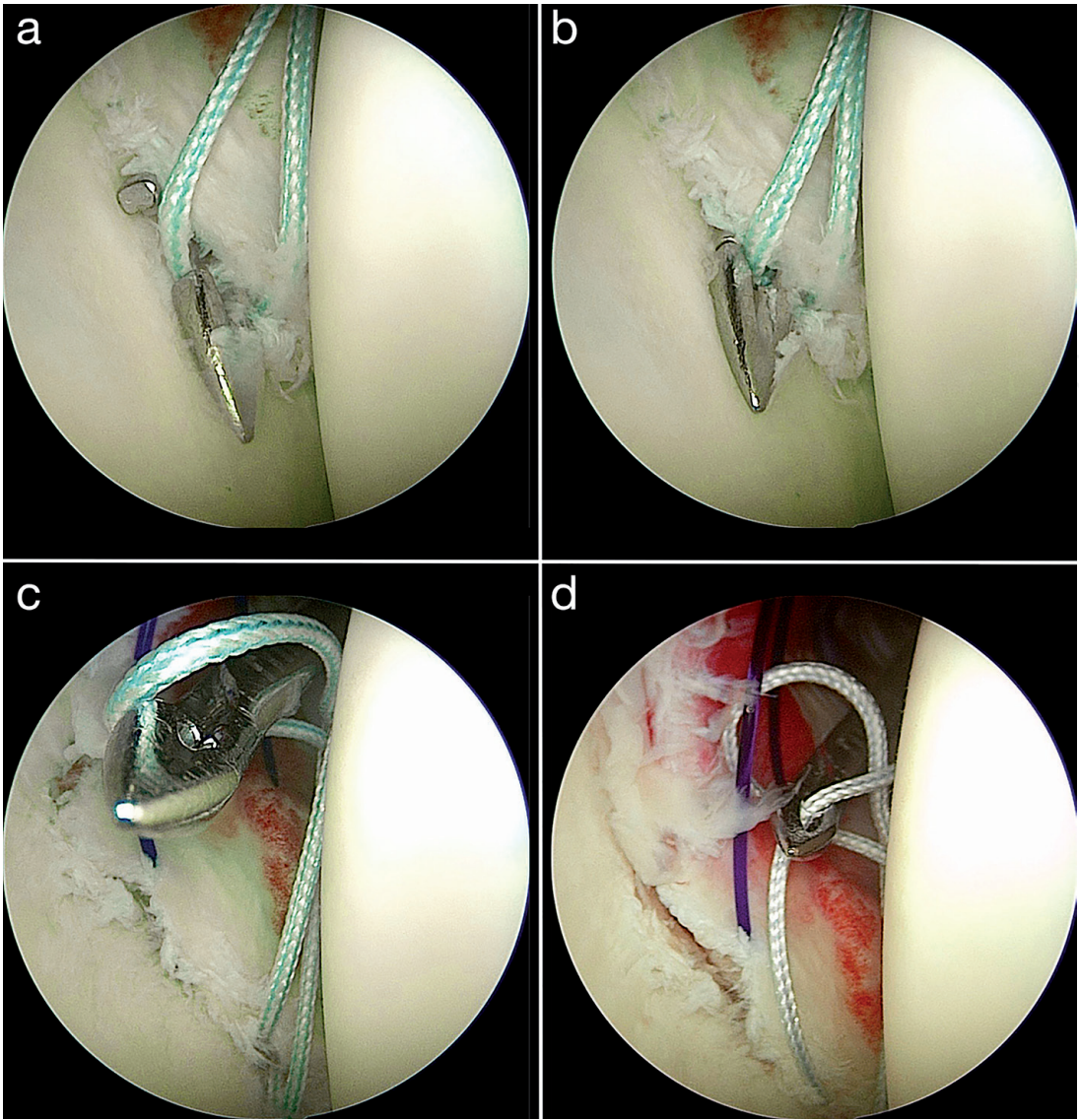
- Arthroscopy tower with arthroscope (4 mm, 30°), monitor, camera, and documentation unit, cold light source, light cable, shaver, hook probe
- Working cannula 8.25 mm x 70 mm (transparent)
- Working cannula 5.5 mm x 72 mm (transparent)
- Bankart raspatory 30°
- Bankart rasp 30°
- PDS no. 0 as hold-suture
- Birdpeak
- Optional: Suture-lasso
- Drill
- Gliding all-suture anchor (Alternatively: singular armed resorbable suture anchor)

### 2.2 Surgical technique

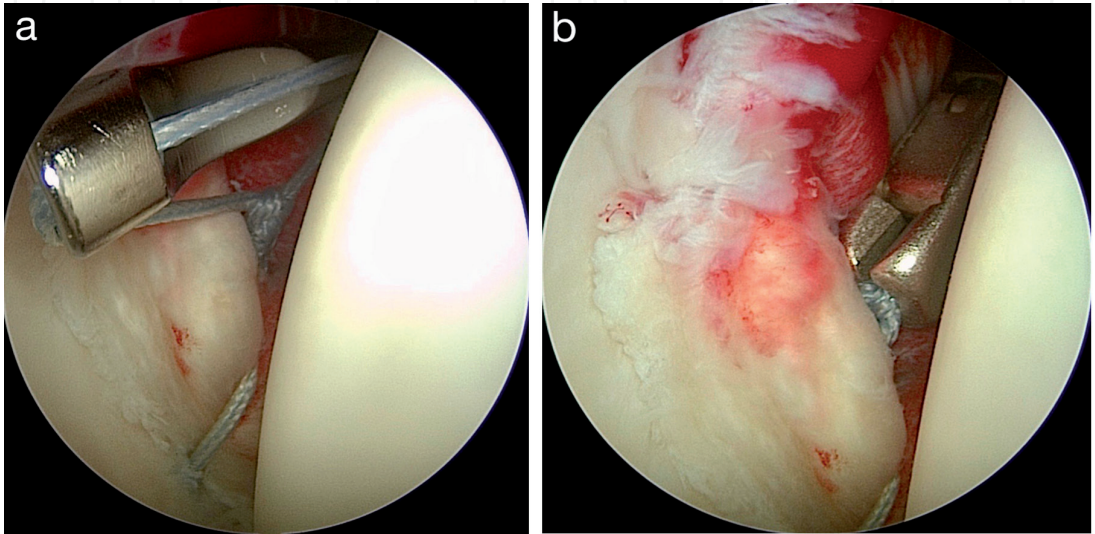
For developing a posterior arthroscopy portal, a stab incision of the skin is made 2 cm caudal and 2 cm medial of the posterolateral corner of the acromion. After entering the glenohumeral joint with a switching stick, the arthroscopy sheath is introduced, the joint is filled up with water, and the arthroscope is inserted. At first, a diagnostic arthroscopic evaluation and incision for the anterior inferior working portal in outside-in technique just above the subscapular tendon is performed. In this antero-inferior working portal, a working cannula (8.25 mm) is inserted. Alternatively, a 5:30 o'clock portal can be used about 8 cm distal to the coracoid through the inferior (muscular) part of the subscapularis tendon. This facilitates placement of the first suture anchor as low as recommended.

An additional antero-superior portal is developed directly anterior to the acromio-clavicular joint (ACJ) in outside-in technique and a working cannula (5.5 mm) is introduced here. The **Figures 2–4** illustrate the surgical technique:

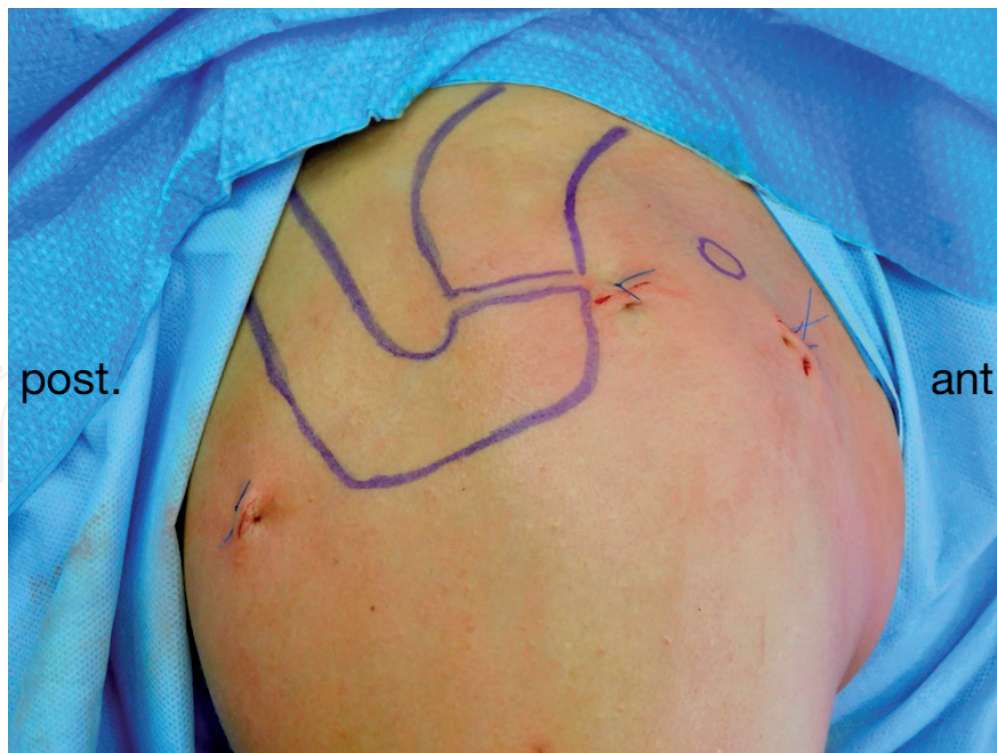



**Figure 2.**  
*The lasso-loop stitch (a-d). A Birdpeak is pushed through the capsulolabral complex from anterior (a). Then, one suture end of the anchor is grasped (b), pulled through the capsulolabral complex anteriorly, and formed into an intraarticular loop (c). The Birdpeak is pushed through the loop and the same suture end is grasped again (d). Now, the Birdpeak is kept closed and the suture end is pulled out of the shoulder joint through the working cannula. During this procedure, the other suture end outside of the shoulder joint is secured by a clamp.*



**Figure 3.**  
*Tying of the knot (a) and shortening of both FibreWire ends with arthroscopic scissors (b).*



**Figure 4.**  
*Right shoulder after arthroscopic anterior stabilization.*

Examination with a hook probe, mobilization of the labrum with the Bankart raspator and debridement of the glenoid neck with the Bankart rasp.

Trial cranialisation of the capsulo-labral complex is performed via a grasper through the anterior superior portal followed by insertion of a hold-suture (PDS no. 0).

The first single-armed resorbable suture anchor is positioned through the anterior inferior portal onto the anterior glenoid rim as caudal as possible at the anterior cartilage border. The anchor is inserted ca.  $135^\circ$  to the glenoid plane. Not too steep and not too flat. The anchor should not be inserted too deep either; under no circumstances should the end of the anchor stick out. Because this could lead to cartilage damage and it could potentially cause anchor dislocation.

Cranialisation of the labrum is accomplished using the hold-suture. Then, refixation of the capsulo-labral complex in lasso-loop technique is performed. Also the second suture end is stitched through and behind the labrum, so the knot comes to lie away from the joint. This suture end represents the drawstring. Seven singular knots are made.

Then, the clamp is switched and with the birdpeak (or a suture lasso) the second suture end is pulled anteriorly through the labrum and outside of the joint through the antero-inferior working cannula.

Now, the hold-suture can be removed as it is no longer needed after tying of the first antero-inferior suture anchor.

Slightly further cranial, labral refixation is undertaken in the same way with the second anchor. A further hold-suture is not needed after the first anchor is sutured.

In most cases, an additional third anchor is necessary further cranial for secure labral refixation using the same technique. Enough distance has to be kept from the long head biceps tendon origin not to compromise this tendon mobility.

Final examination of labrum stability with a hook probe and careful clinical verification of joint stability.

Removal of instruments, skin disinfection, closure of the arthroscopic portals via interrupted single Donati backstitches, and sterile wound dressing as well as immobilization with a sling.



### 2.2.1 Tips and tricks

For improved arthroscopic evaluation of potential glenoid bone loss and subluxation of the humeral head, we recommend arthroscopic view via the anterior superior portal.

Only if the second suture end is also positioned behind the labrum, the knot will come to lie away from the joint surface.

Pulling on the one suture end without the loop reattaches the capsulo-labral ligament complex to the glenoid. Strain to the other suture end – the one creating the loop – would pull the tissue away from the glenoid. Therefore, the singular stitched suture end has to be the drawstring while tying the knot.

When using the lasso-loop technique, only one of the anchor dependent suture ends can slide through the tissue. Therefore, no arthroscopic slip knots can be made. Seven half hitches come into use. Alternating half hitches lead to a secure blocking of the knot.

### 2.3 Postoperative treatment

Postoperatively, physical therapy out of a sling or Gilchrist bandage for four to six weeks with external rotation limited to 20° is applicated. Clinical follow up with the surgeon at six weeks postoperatively is recommended for clinical control. Then, careful unlimited motion is allowed. No forced external rotation should be performed for further six weeks. Training of the active and dynamic stabilizers of the shoulder girdle is important. Throwing and contact sports can be taken up again at the earliest six months postoperatively, if power and coordination are fully restored [18–22].

## 3. Results

For one year, we followed up our operatively treated patients using the described technique after antero-inferior shoulder dislocation with damage to the glenoid labrum. We identified all 30 consecutive patients (3 females, 27 males), who had been treated for shoulder dislocation with anterior-inferior damage to the glenoid labrum by arthroscopic refixation of the anterior capsulolabral complex with suture anchors in lasso-loop technique. Patients with relevant anterior-inferior bone loss or Bankart fracture >15% of the glenoid joint surface received either bony augmentation or osteosynthesis and were not part of the patient cohort used for this analysis.

Five patients were either not available or not prepared to take part in the follow-up examination. 25 of 30 patients could be followed up. One patient had to be excluded for a recent ipsilateral elbow fracture dislocation. In this case, no shoulder re-dislocation occurred. In total, we followed up three female and 21 male patients completely. The mean age was 27.8 years (17–49 years). The average follow-up took place 30.4 months (25–36 months) postoperatively.

In 96% of all cases, there was an excellent subjective and objective outcome. The average Rowe Score was 96.3 points (80–100 points; SD = 3.9). The mean QuickDash was 2.8 points (0–14 points, SD = 3.9). The Constant Score had an average of 93.7 points (65–100 points, SD = 8.8). The average pain level on the numeric analogue pain scale (NAS 0–10) was very low with reported 0.4 points (0–3 points, SD = 1.0). The average passive and active range of motion of the operated glenohumeral joint was Ext/Flex 30/0/170°, Abd/Add 70/0/20°, and Ero/Iro 60/0/95°. There was no restriction of movement greater than 10° compared to the other side. No significant difference in passive or active range of motion in comparison to the healthy side could be seen. The rotator cuff tests were negative. The anterior

apprehension sign was negative in all cases; in one case accompanied by slight pain. Apart from one traumatic re-dislocation during handball there were no further complications.

#### **4. Discussion**

An anatomic reconstruction of the capsulo-labral complex is one of the advantages of the described surgical technique. It is possible to address SLAP lesions (Superior labrum anterior to posterior) and rotator cuff tears at the same time. The subscapular muscle or its insertion are not compromised as in an open surgical procedure. Compared to other arthroscopic techniques, the procedure presented here leads to an accentuated labral bump and enables secure knot-tying with positioning of the knot away from the articular cartilage while avoiding the suture cutting through the tissue.

As shown, the arthroscopic Bankart repair using the lasso-loop stitch leads to very good results, which are comparable to other studies of arthroscopic shoulder stabilization with good clinical outcomes [16–18]. Possible disadvantages of the lasso-loop stitch compared to arthroscopic single interrupted or mattress sutures are a relatively demanding and slightly more time-consuming technique, and not being able to use slip knots. Iatrogenic cartilage damage, misplacement of anchors, or lesions to the axillary nerve can occur intraoperatively; the latter when too much tissue is taken while performing a capsular shift in the anterior inferior recessus.

Malcompliance by the patient with risk to the healing process of the anterior capsulo-labral complex with strong tensile forces during external rotation require extensive patient consent and education. In the event of re-dislocation, a detailed investigation of causes in the patient history and further diagnostics including MRI should be performed before possibly attempting revision surgery [23, 24]. Postoperative infection requires arthroscopic irrigation and systemic antibiotics, beginning with Ampicillin/Sulbactam and possibly changing to the antibiogram.

If a bony Bankart fragment is big enough to allow screw fixation, this should be undertaken either openly or arthroscopically. If the labrum remains partially unstable, a further labrum reconstruction following screw fixation may be necessary [25].

The arthroscopic refixation of the capsulo-labral complex with suture anchors using the lasso-loop stitch is slightly more elaborate due to the suturing technique than single interrupted sutures or mattress sutures. But this technique leads to a stronger bulging of the glenoid labrum and might therefore increase the physiological bumper effect of the labrum. At the same time, the knot can be positioned away from the joint to avoid irritation without cutting through the tissue like it is possible with mattress sutures for glenoid labrum refixation [26]. For further clarification of possible advantages and disadvantages of this technical modification, prospective studies comparing the described procedure with other stitching techniques are recommended.

#### **5. Conclusions**

The lasso-loop stitch in arthroscopic Bankart repair is useful and safe. It leads to an accentuated labral bump and enables secure knot-tying with positioning of the knot away from the articular cartilage while avoiding the suture cutting through the tissue.



Conflict of interest

The authors declare that they have no Conflict of Interest.

Abbreviations and definitions


ACJ	Acromio-clavicular joint
ALPSA	Anterior Labroligamentous Periosteal Sleeve Avulsion
Bankart	A Bankart lesion is a tear of the labrum-capsule-ligament complex from the glenoid
GLAD	Glenoid-Labral Articular Disruption
HAGL	Humeral Avulsion of the Glenohumeral Ligament
MRI	Magnetic Resonance Imaging
PDS	Polydioxanone (Suture)
Perthes	The Perthes lesion is a soft-tissue decollement at the scapular neck (no tissue rupture) leading to a pouch of the joint capsule
SLAP	Superior Labrum Anterior to Posterior

Author details

Christian Konrads\* and Stefan Döbele  
Department of Trauma, Reconstructive Surgery, Sports Medicine and Arthroscopy,  
BG Klinik, University of Tübingen, Tübingen, Germany

\*Address all correspondence to: christian.konrads@gmail.com

IntechOpen

© 2021 The Author(s). Licensee IntechOpen. This chapter is distributed under the terms of the Creative Commons Attribution License (<http://creativecommons.org/licenses/by/3.0>), which permits unrestricted use, distribution, and reproduction in any medium, provided the original work is properly cited. 

## References

- [1] Aboalata M, Plath JE, Seppel G, Juretzko J, Vogt S, Imhoff AB, et al. Results of arthroscopic Bankart repair of anterior-inferior shoulder instability at 13-year follow-up. *Am J Sports Med.* 2017;45:782-787.
- [2] Martetschläger F, Imhoff AB. Shoulder dislocation in athletes: current therapy concepts. *Orthopade.* 2014;43:236-243.
- [3] Minkus M, Böhm E, Moroder P, Scheibel M. Initial management of traumatic ventral shoulder dislocation. *Unfallchirurg.* 2018;121:100-107.
- [4] Martetschläger F, Tauber M, Habermeyer P. Diagnostics and treatment concepts for anteroinferior shoulder instability: current trends. *Orthopade.* 2017;46(October (10)):877-892.
- [5] Balke M, Shafizadeh S, Bouillon B, et al. Management of shoulder instability: the current state of treatment among German orthopaedic surgeons. *Arch Orthop Trauma Surg.* 2016;136:1717-1721.
- [6] Lafosse L, Van Raebroekx A, Brzoska R. A new technique to improve tissue grip: "the lasso-loop stitch". *Arthroscopy.* 2006;22(1246):e1-3.
- [7] Toussaint B, Schnaser E, Lafosse L, Bahurel J, Gobeze R, et al. A new approach to improving the tissue grip of the medial-row repair in the suture-bridge technique: the "modified lasso-loop stitch". *Arthroscopy.* 2009;25:691-695.
- [8] Ponce BA, Hosemann CD, Raghava P, Tate JP, Eberhardt AW, Lafosse L, et al. Biomechanical evaluation of 3 arthroscopic self-cinching stitches for shoulder arthroscopy: the lasso-loop, lasso-mattress, and double-cinch stitches. *Am J Sports Med.* 2011;39:188-194.
- [9] Lafosse L, Meller R. Arthroskopische stabilisierung bei vorderer schulterinstabilität. In: Agneskirchner JD, Lafosse L, Lobenhoffer P, eds. *Arthroskopische schulterchirurgie.* Cologne: deutscher Ärzte-Verlag; 2013; 2013.
- [10] Parnes N, Blevins M, Morman M, Carey P. The oblique mattress lasso-loop stitch for arthroscopic capsulolabral repair. *Arthrosc Tech.* 2016;5:e959-963.
- [11] Mahure SA, Mollon B, Capogna BM, Zuckerman JD, Kwon YQ, Rokito AS. Risk factors for recurrent instability or revision surgery following arthroscopic Bankart repair. *Bone Jt J.* 2018;100-B:324-330.
- [12] Porter DA, Birns M, Hobart SJ, Kowalsky M, Galano GJ. Arthroscopic treatment of osseous instability of the shoulder. *HSS J.* 2017;13:292-301.
- [13] Cartucho A, Moura N, Sarmiento M. Evaluation and management of failed shoulder instability surgery. *Open Orthop J.* 2017;11:897-908.
- [14] Fritz EM, Pogorzelski J, Hussain ZB, Godin JA, Millett PJ. Arthroscopic repair of humeral avulsion of the glenohumeral ligament lesion. *Arthrosc Tech.* 2017;6:e1195-1200.
- [15] Hawkins RJ, Bokor DJ. Clinical evaluation of shoulder problems. In: Rockwood CA, Jr, Matsen FA, III, eds. *The shoulder.* Philadelphia: Saunders; 1998.
- [16] Ng DZ, Kumar VP. Arthroscopic bankart repair using knot-tying versus knotless suture anchors: is there a difference? *Arthroscopy.* 2014;30:422-427.
- [17] Ockert B, Biermann N, Nebelung W, Wiedemann E. Arthroscopic soft tissue stabilization of posttraumatic anterior shoulder instability: techniques,

limitations and long-term results. *Unfallchirurg*. 2018;121:108-116.

[18] Boughebri O, Maqdes A, Moraiti C, Dib C, Leclère FM, Valenti P. Results of 45 arthroscopic bankart procedures: does the ISIS remain a reliable prognostic assessment after 5 years? *Eur J Orthop Surg Traumatol*. 2015;25:709-716.

[19] Ma R, Brimmo OA, Li X, Colbert L. Current concepts in rehabilitation for traumatic anterior shoulder instability. *Curr Rev Musculoskelet Med*. 2017;10:499-506.

[20] DeFroda SF, Mehta N, Owens BD. Physical therapy protocols for arthroscopic Bankart repair. *Sports Health*. 2018;10:250-258.

[21] Kim K, Saper MG. Postoperative management following arthroscopic Bankart repair in adolescents and young adults: a systematic review. *Arthrosc Sports Med Rehabil*. 2020;2:e839-e845.

[22] Wilson KW, Popchak A, Li RT, Kane G, Lin A. Return to sport testing at 6 months after arthroscopic shoulder stabilization reveals residual strength and functional deficits. *J Shoulder Elbow Surg*. 2020;29:S107-S114.

[23] Lacheta L, Siebenlist S, Imhoff AB, Willinger L. Recurrent instability and instability arthropathy. *Unfallchirurg*. 2018;121:142-151.

[24] Waterman BR, Leroux T, Frank RM, Romeo AA. The evaluation and management of the failed primary arthroscopic Bankart repair. *J Am Acad Orthop Surg*. 2020;28:607-616.

[25] Nolte PC, Elrick BP, Bernholt DL, Lacheta L, Millett PJ. The bony Bankart: clinical and technical considerations. *Sports Med Arthrosc Rev*. 2020;28:146-152.

[26] Konrads C, Jovic S, Rueckl K, Fenwick A, Barthel T, Rudert M,

Plumhoff P. Surgical technique and clinical outcome of arthroscopic shoulder stabilization via suture anchors using the lasso-loop stitch. 2018;15:553-557.