

# We are IntechOpen, the world's leading publisher of Open Access books Built by scientists, for scientists

6,900

Open access books available

186,000

International authors and editors

200M

Downloads

Our authors are among the

154

Countries delivered to

TOP 1%

most cited scientists

12.2%

Contributors from top 500 universities



WEB OF SCIENCE™

Selection of our books indexed in the Book Citation Index  
in Web of Science™ Core Collection (BKCI)

Interested in publishing with us?  
Contact [book.department@intechopen.com](mailto:book.department@intechopen.com)

Numbers displayed above are based on latest data collected.  
For more information visit [www.intechopen.com](http://www.intechopen.com)



# Short Root Anomaly in a Hispanic Population: Risk for Orthodontic Root Resorption

*Tara Emerick, Maria Grace Viana and Carla A. Evans*

## Abstract

While the presentation of Short Root Anomaly (SRA) in Hispanic patients has been described previously, it is not known if this population is predisposed to increased orthodontic root resorption. This study evaluates the response of pre-existing short roots in Hispanic SRA patients to orthodontic treatment. Selected maxillary and mandibular teeth of 40 Hispanic SRA patients (19 male, 21 female) and 40 age and gender matched Caucasian patients (19 male, 21 female) with normal root length were evaluated for root resorption following comprehensive orthodontic treatment. The age range of the subjects was between 10 and 19 years. Relative root length was calculated before and after orthodontic treatment from digital panoramic radiographs. Overall, statistically significant root resorption occurred in the control group, but orthodontic root resorption was not significant in the Hispanic group ( $p > 0.05$ ). When genders were separated, Hispanic females did experience a mild degree of root resorption in the upper incisors while resorption in Hispanic males was not significant. Caucasian females experienced greater root resorption than Caucasian males. Hispanic SRA patients may be safely treated with comprehensive orthodontics and could be at no more risk of root resorption than Caucasian patients with normal initial root length.

**Keywords:** orthodontics, short root anomaly, root resorption, Hispanics

## 1. Introduction

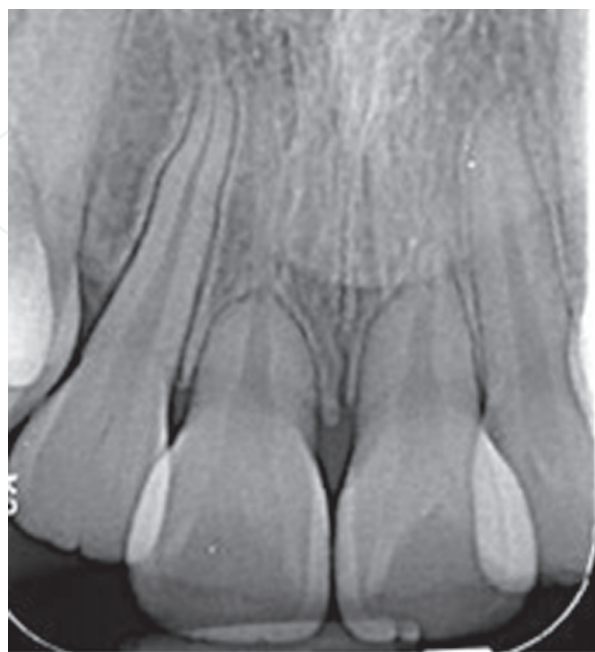There are two main causes of short dental roots: 1) disturbances during root development or 2) resorption of well-developed roots. Developmentally short-rooted permanent teeth can be genetic, known as short root anomaly (SRA) [1, 2], or exogenous, including irradiation of the head and neck and/or chemotherapy in childhood during tooth development [3]. Resorption of dental roots as a result of orthodontic treatment is termed Orthodontically Induced Inflammatory Root Resorption (OIIRR) and is believed to result from a combination of genetics, environmental, and mechanical factors. Puranik et al. [4] identified a population of Hispanic orthodontic patients presenting with SRA. Although the Hispanic population only comprises 17.8% of the U.S. population, it is the largest minority ethnicity with 57.5 million people and continues to grow [5].

In cases of pre-existing short root length (**Figure 1**), orthodontists should be aware if greater root resorption is anticipated as normal orthodontic treatment could sentence these teeth to exfoliation or extraction. Short dental roots may complicate dental treatment planning when considering anchorage or estimating the ability of a tooth to carry masticatory forces. Two recent publications proposed such potential hazards, but did not supply clinical evidence [6, 7]. This is the first study, to the authors' knowledge, that has investigated the response of dental roots to orthodontic treatment in a Hispanic SRA population.

Root resorption is a common side effect of orthodontic treatment and is estimated to occur in 73% of orthodontically treated cases [8]. Luckily, in the majority of cases, resorption is classified as mild to moderate [9] and is clinically insignificant. While some studies have found females to experience more resorption [10], others report that gender is unlikely to have an effect on root resorption [11].

Short-root anomaly (SRA) is a developmental phenomenon in which permanent teeth never reach their normal length and appear very short and blunted [2]. Lind [1] first described SRA in 1972 as "abnormally short roots of a characteristically plump shape affecting maxillary central incisors primarily." It is considered to be familial [1] and prior to Lind, SRA was commonly misdiagnosed as root resorption. Interestingly, multiple studies have suggested a primarily autosomal dominant inheritance pattern. In a recent study by Puranik et al. [4], SRA was found to occur more frequently in Latino individuals with the majority having localized SRA and the minority having generalized SRA, in which every tooth in the mouth is affected [4].

Some studies have found that patients with short or blunted roots prior to treatment, undergo significantly more root shortening during orthodontic treatment than patients with no dental anomaly [12–14], while others have found a minor or non-significant relationship between blunted roots and root resorption with orthodontic treatment [2, 15, 16] and still others report that blunted teeth experience less resorption than normal-shaped teeth [11].



**Figure 1.**  
*Periapical radiograph showing an example of maxillary incisors in a Hispanic female subject with localized SRA before starting orthodontic treatment.*

Some authors believe that this is due to a change in the position of the tooth's center of resistance, moving it more incisally. Studies that looked specifically at "pipette-shaped" roots, rather than blunted, consistently found greater root resorption [11]. Correlations have also been found between initial tooth length and the amount of resorption (i.e., a longer root was more likely to be resorbed with orthodontic treatment) [11, 17]. Mirabella and Artun [17] argued that teeth with longer roots require stronger orthodontic forces to move them; furthermore, the displacement of the root apex is greater during tipping and torquing movements of longer rooted teeth.

The objective of this study was to assess changes in root lengths that occur with orthodontic treatment by comparing: 1. pre- and post-treatment digital panoramic radiographs of Hispanic patients presenting with short dental root lengths; 2. the experience of Hispanic patients and Caucasian patients presenting with normal dental root lengths; and 3. gender differences within each ethnicity group.

## **2. Comparison of treatment outcomes**

### **2.1 Material and methods**

This was a retrospective study that included male and female Hispanic and Caucasian patients in a university orthodontic clinic. Dental records of 40 Hispanic SRA and 40 Caucasian patients were collected. In this clinic, most of the Hispanic patients are of Mexican heritage. The Hispanic group consisted of 19 male and 21 female adolescent patients and the Caucasian group consisted of 19 male and 21 female adolescent patients. The mean age of subjects was  $14.7 \pm 1.91$  years in the Caucasian group and  $13.9 \pm 1.86$  years in the Hispanic group. All pre-existing records were taken at the orthodontic clinic for comprehensive orthodontic treatment. All radiographs were taken in the Radiology Clinic. Panoramic radiographs were taken on a standard combined panoramic/cephalometric machine. All radiographs were consistent with the standard of care for all orthodontic patients in the clinic and included pre- and post-treatment panoramic radiographs. For every extraction case in the Hispanic group, an extraction case in the Caucasian group was included. All subjects were de-identified and assigned a coded number. Only the sex, ethnicity, and age in years and months at the start of treatment were retrieved from the patient chart. All subjects with developmental disorders or complicated medical histories were excluded. Individual teeth were excluded if 1) the apex was not closed, 2) the reference points were not clearly visible, 3) there was a history of dental trauma, root canal therapy, orthodontics, or an incisal or full-coverage restoration, 4) attrition or abrasion of the crown was present. In this study generalized and localized SRA patients were grouped together even though their pathogenesis may differ. IRB exemption was granted prior to data collection.

Root lengths were measured on maxillary and mandibular central and lateral incisors, and second premolars, from the apex to the midpoint of the cemento-enamel junction (CEJ) on panoramic radiographs. The aforementioned teeth were selected because they are single-rooted teeth (with the exception of the variation in upper second premolar) and the root outline of these teeth can be more clearly visible on radiographs than multi-rooted teeth. Furthermore, SRA in a Mexican cohort most commonly occurred in maxillary central incisors and mandibular second premolars [4]. It is assumed that during orthodontic treatment, the crown length does not change. Therefore, the ratio between the root and crown length should reflect any

changes in root length. Crown and root lengths were measured on panoramic radiographs using the Dolphin™ digital caliper (Dolphin Imaging 11.8, Chatsworth, CA).

The Lind method of relative root length calculation was used [1] in which the midpoint of the mesial and distal CEJ (median CEJ) is used to demarcate the transition from crown to root. Root length was measured from the median CEJ (point M) to the tip of the root (point R). Crown length was measured from point M to the incisal edge or tip (point I). Relative root length was calculated by dividing point M to point R length by point I to point M length [1]. Root length guidelines set by Holtta et al. [3] were used in the measurements of all panoramic radiographs.

Statistical analysis was done using IBM SPSS Statistics for Windows (version 22.0, IBM Corp., Armonk NY). Analyses were performed by the Explore function in SPSS to check the raw data distribution by Shapiro–Wilk Tests of Normality. Parametric tests were done based on the results that the majority of the variables showed normal distribution of the data. Student Paired Sample *t*-tests were used to assess the mean differences between pre and post measurements of all the variables in each of the Hispanic and Caucasian groups with the sample gender in consideration. Independent *t*-tests were done for the mean comparisons to all study variables between groups. All values were considered statistically significant for a value of  $p < 0.05$ .

2.2 Results

The Caucasian group had a statistically significant differences between pre-orthodontic treatment and post-orthodontic treatment relative root lengths (**Table 1**). The post-orthodontic treatment relative root lengths ( $1.87 \pm 0.30$ ) were significantly less than the initial relative root lengths ( $2.10 \pm 0.29$ ), indicating root resorption

Group	Caucasian pre-orthodontic treatment Group		Caucasian post-orthodontic treatment Group		p-value
	(N = 40)		(N = 40)		
	Mean	S.D.	Mean	S.D.	
Tooth					
UR5	1.89	0.27	1.69	0.33	.005*
UR2	2.24	0.27	1.90	0.40	.000*
UR1	2.01	0.29	1.68	0.31	.000*
UL1	2.06	0.27	1.64	0.29	.000*
UL2	2.19	0.30	1.82	0.32	.000*
UL5	1.96	0.30	1.71	0.26	.000*
LL5	2.29	0.28	2.11	0.25	.000*
LL2	2.10	0.42	2.03	0.28	.387
LL1	2.09	0.28	2.06	0.24	.613
LR1	2.12	0.31	1.99	0.29	.048*
LR2	2.06	0.32	1.93	0.27	.038*
LR5	2.13	0.24	1.95	0.47	.026*

*\*Statistically significant at  $p < 0.05$ .*

**Table 1.**  
Mean comparison of pre-orthodontic relative root lengths and post-orthodontic treatment relative root lengths in the Caucasian group.



from the orthodontic treatment in the Caucasian group. The only measurements that did not show statistical significance were the lower left lateral and lower left central incisors.

Overall, there was only a mild difference between Hispanic initial relative root lengths ( $1.57 \pm 0.27$ ) and Hispanic post-orthodontic treatment relative root lengths ( $1.55 \pm 0.29$ ) (**Table 2**). Significant root resorption was seen in five teeth: UR2, UR1, UL1, LR1 and LR2. Differences were also seen in the mandibular left second premolars which increased in relative root length after orthodontic treatment. Furthermore, the percentage decrease in relative root length was consistently higher in the Caucasian group (**Tables 1 and 2**).

Genders were separated and post-treatment relative root lengths were compared against pre-treatment relative root lengths in order to further evaluate any significant root resorption that occurred with orthodontic treatment. There was no difference in post-orthodontic treatment relative root length when sexes were compared within the Hispanic group. However, there was a difference between males and females in post-orthodontic treatment relative root length with Caucasian females ( $1.80 \pm 0.28$ ) experiencing a smaller post-orthodontic treatment relative root lengths than Caucasian males ( $1.95 \pm 0.31$ ). Statistically significant differences in post-orthodontic treatment relative root length were found in four teeth when Caucasian male and Caucasian female groups were compared (**Tables 3 and 4**). Specifically, the relative root lengths of UR1, UL1, LL2, and LL1 were found to be significantly less in the Caucasian female group than the Caucasian male group. Because there was no statistically significant gender difference in pre-orthodontic treatment root lengths in the Caucasian group, this finding suggests that Caucasian females experienced more root resorption from the orthodontic treatment than Caucasian males.

Group	Hispanic pre-orthodontic treatment Group		Hispanic post-orthodontic treatment Group		p-value
	(N = 40)		(N = 40)		
Tooth	Mean	S.D.	Mean	S.D.	
UR5	1.31	0.25	1.43	0.29	.009*
UR2	1.83	0.25	1.65	0.22	.002*
UR1	1.34	0.34	1.22	0.33	.009*
UL1	1.32	0.30	1.13	0.30	.000*
UL2	1.74	0.29	1.66	0.27	.070
UL5	1.31	0.20	1.50	0.35	.001*
LL5	1.56	0.34	1.68	0.38	.008*
LL2	1.83	0.20	1.82	0.20	.712
LL1	1.70	0.35	1.68	0.30	.581
LR1	1.72	0.23	1.64	0.24	.048*
LR2	1.78	0.27	1.68	0.18	.031*
LR5	1.52	0.25	1.54	0.41	.830

*\*Statistically significant at  $p < 0.05$ .*

**Table 2.**  
Mean comparison of the pre-orthodontic relative root lengths and post-orthodontic treatment relative root lengths in the Hispanic group.

Group	CM pre-orthodontic treatment Group		CM post-orthodontic treatment Group		p-value
	(N = 40)		(N = 40)		
Tooth	Mean	S.D.	Mean	S.D.	
UR5	1.79	0.21	1.67	0.35	.252
UR2	2.31	0.30	1.99	0.41	.000*
UR1	2.01	0.29	1.79	0.36	.000*
UL1	2.07	0.31	1.75	0.33	.000*
UL2	2.24	0.30	1.91	0.37	.006*
UL5	1.89	0.33	1.78	0.26	.192
LL5	2.27	0.25	2.13	0.23	.036*
LL2	2.02	0.46	2.12	0.32	.432
LL1	2.01	0.24	2.13	0.24	.119
LR1	2.11	0.28	2.04	0.35	.387
LR2	1.99	0.31	2.01	0.30	.889
LR5	2.01	0.19	2.01	0.31	.937

*\*Statistically significant at  $p < 0.05$ .*

**Table 3.**  
Mean comparison of pre-orthodontic relative root lengths and post-orthodontic treatment relative root lengths in the Caucasian male (CM) group.

Group	CF pre-orthodontic treatment Group		CF post-orthodontic treatment Group		p-value
	(N = 40)		(N = 40)		
Tooth	Mean	S.D.	Mean	S.D.	
UR5	2.00	0.28	1.71	0.32	.005*
UR2	2.17	0.24	1.82	0.39	.001*
UR1	2.01	0.29	1.58	0.23	.000*
UL1	2.04	0.24	1.55	0.21	.000*
UL2	2.15	0.30	1.74	0.26	.000*
UL5	2.02	0.27	1.64	0.24	.000*
LL5	2.31	0.31	2.09	0.28	.004*
LL2	2.18	0.36	1.93	0.21	.016*
LL1	2.16	0.29	1.99	0.22	.102
LR1	2.13	0.33	1.94	0.22	.077
LR2	2.11	0.32	1.86	0.24	.005*
LR5	2.24	0.23	1.91	0.57	.013*

\*Statistically significant at  $p < 0.05$ .

**Table 4.**  
Mean comparison of pre-orthodontic relative root lengths and post-orthodontic treatment relative root lengths in the Caucasian female (CF) group.

In the Caucasian male group, significance was found in five teeth: UR2, UR1, UL1, UL2, LL5 (**Table 3**). In all five teeth, the final was smaller than the initial, indicating that these teeth did in fact experience statistically significant orthodontic root resorption.

Significance between pre and post-treatment relative root length was found for nearly every tooth in the Caucasian female group: UR5, UR2, UR1, UL1, UL2, UL5, LL5, LL2, LR2, LR5 (**Table 4**). All teeth showed decreased relative root lengths post-treatment, suggesting significant root resorption from the orthodontic treatment. The only teeth that did not show a significant difference between pre and post were the two lower central incisors: the post-treatment mean relative lengths for these teeth were still smaller than the pre-treatment.

When post-treatment relative root lengths were compared to pre-treatment root lengths in Hispanic males, three teeth showed a significant difference: UR5, UL5, and LL5 (**Table 5**). However, the mean relative root lengths showed that these root lengths increased in apparent length after treatment.

Significance was found for five teeth in the Hispanic Female group: UR2, UR1, UL1, UL5, LR2 (**Table 6**). While there does appear to be mild root resorption from orthodontic treatment in UR2, UR1, UL1, and LR2; the mean relative root length for UL5 is increased in the post group, suggesting an increase in relative root length with orthodontic treatment.

### 2.3 Discussion

There have been many claims that SRA predisposes patients to increased orthodontic root resorption, for example the study of Wang and Feng [6]. However, it is not

Group	HM pre-orthodontic treatment		HM post-orthodontic treatment		p-value
	Group		Group		
	(N = 40)		(N = 40)		
Tooth	Mean	S.D.	Mean	S.D	
UR5	1.31	0.27	1.49	0.24	.007*
UR2	1.87	0.21	1.72	0.18	.064
UR1	1.35	0.36	1.29	0.27	.444
UL1	1.36	0.33	1.24	0.26	.067
UL2	1.73	0.25	1.68	0.30	.445
UL5	1.36	0.18	1.54	0.28	.013*
LL5	1.52	0.34	1.73	0.44	.009*
LL2	1.78	0.22	1.78	0.19	1.000
LL1	1.68	0.38	1.65	0.32	.697
LR1	1.71	0.21	1.65	0.29	.276
LR2	1.69	0.20	1.66	0.20	.656
LR5	1.49	0.27	1.52	0.33	.728

*\*Statistically significant at  $p < 0.05$ .*

**Table 5.**  
Mean comparison of pre-orthodontic relative root lengths and post-orthodontic treatment relative root lengths in the Hispanic male (HM) group.



Group	HF pre-orthodontic treatment		HF post-orthodontic treatment		p-value
	Group		Group		
	(N = 40)		(N = 40)		
Tooth	Mean	S.D.	Mean	S.D	
UR5	1.31	0.24	1.38	0.33	.305
UR2	1.78	0.29	1.58	0.24	.018*
UR1	1.34	0.34	1.18	0.36	.002*
UL1	1.28	0.28	1.05	0.30	.000*
UL2	1.74	0.33	1.64	0.24	.069
UL5	1.28	0.22	1.47	0.41	.018*
LL5	1.59	0.34	1.63	0.31	.392
LL2	1.89	0.16	1.86	0.21	.673
LL1	1.73	0.32	1.70	0.29	.709
LR1	1.72	0.26	1.64	0.19	.092
LR2	1.88	0.29	1.71	0.15	.013*
LR5	1.55	0.24	1.55	0.49	.962

*\*Statistically significant at  $p < 0.05$ .*

**Table 6.**  
Mean comparison of pre-orthodontic relative root lengths and post-orthodontic treatment relative root lengths in the Hispanic female (HF) group.

known if this cohort indeed experiences a higher degree of orthodontic root resorption, or if they experience a similar degree of resorption to unaffected patients, but the appearance is more suggestive due to their pre-existing short roots. If a greater degree of relative root loss does occur, the orthodontic professional should be aware so that treatment complications can be anticipated when treating Hispanic SRA patients.

Post-orthodontic treatment relative root lengths were significantly smaller than the initial relative root lengths for the Caucasian group, indicating root resorption from the orthodontic treatment. Hispanic initial relative root lengths and Hispanic post-orthodontic treatment relative root lengths were similar. Furthermore, the percentage decrease in relative root length was consistently higher in the Caucasian group, further supporting the finding that the Caucasian subjects experienced OIIRR while the Hispanic subjects had minimal, if any. Because the treating orthodontists in this study were aware of the pre-existing short roots in the Hispanic SRA group, it is likely that these patients were treated more conservatively, with lower forces, and with greater care. Studies have also speculated that shorter roots may experience less root resorption due to 1) shorter teeth requiring less force to move and 2) the root tip being displaced a shorter distance through the bone in second and third-order tipping motions [18, 19].

In the Caucasian male group, the maxillary incisors experienced statistically significant orthodontic root resorption. This finding agrees with the literature as the upper incisors are commonly the most affected teeth in orthodontic root resorption. However, in the Caucasian female group, root resorption was found in nearly every tooth measured and to a greater extent. There was no statistically significant root

resorption found in the Hispanic male group. Conversely, statistically significant root resorption was found for four teeth in the Hispanic female group: UR2, UR1, UL1, and LR2 but the percentage decrease in relative root length was still mild in comparison to the degree of root resorption that both Caucasian groups (male and female) experienced. These findings that females experience greater OIIRR than males agree with other findings in the literature [10, 20].

Most teeth were bilaterally affected; however, resorption of the mandibular second premolar was the tooth that most commonly presented unilaterally. One of the limitations of this study was the assessment of closed apices in the SRA group. SRA roots are characterized by wide pulp chambers and truncated roots which is very similar in appearance to roots that are still undergoing development. Some of the second premolar measurements displayed slightly longer final root lengths than initial. Explanations for this finding are 1) some form of error in measurement, or 2) the second premolar root lengths were measured in the Hispanic group prior to cessation of root development.

Future studies are needed to complete a more detailed analysis regarding the nature of the genetic inheritance and prevalence of the SRA condition in the Hispanic population. In this study, Hispanic SRA patients were found to comprise approximately 2% of the total patient population treated in the university orthodontic clinic. A point of interest would include the geographic origins within Mexico and inheritance patterns of SRA Hispanic patients. Also, while there is much speculation regarding the etiology of SRA, the developmental process resulting in the SRA condition has yet to be determined. It is also not known whether the mechanism is the same across all subgroups of SRA.

### 3. Conclusions

The following conclusions were obtained from this study:

1. While OIIRR occurred in the Caucasian group, the Hispanic SRA group did not experience statistically significant root resorption from the orthodontic treatment when all teeth were combined. However, when individual teeth were evaluated, the Hispanic SRA group did experience OIIRR, but to a lesser degree than the Caucasian group.
2. Females were found to experience greater root resorption than males in both ethnicities. While Hispanic females experienced slightly greater root resorption in the upper incisors than Hispanic males, Caucasian females were found to experience much greater OIIRR than Caucasian males.

The observations of this study suggest that Hispanic SRA patients may be safely treated with comprehensive orthodontics and could be at no more risk of root resorption than Caucasian patients with normal pre-treatment root length. Clinicians are still advised to treat Hispanic SRA patients conservatively. Although more studies are needed, these findings can be considered when making educated treatment decisions for this specialized population of orthodontic patients. To the authors' knowledge, this is the first study to evaluate the response of Hispanic patients with SRA to orthodontic treatment.

## **Acknowledgements**

The authors gratefully acknowledge substantive discussions with Drs. Chester Handelman and Ahmed Masoud.

## **Conflict of interest**

The authors declare no conflict of interest.

## **Author details**

Tara Emerick<sup>1</sup>, Maria Grace Viana<sup>2</sup> and Carla A. Evans<sup>3\*</sup>

1 Private Practice, Carmel, Indiana, USA


2 Department of Orthodontics, College of Dentistry, University of Illinois at Chicago, Chicago, IL, USA

3 Department of Orthodontics, Boston University, Boston, MA, USA

\*Address all correspondence to: caevans@bu.edu

## **IntechOpen**

---

© 2021 The Author(s). Licensee IntechOpen. This chapter is distributed under the terms of the Creative Commons Attribution License (<http://creativecommons.org/licenses/by/3.0>), which permits unrestricted use, distribution, and reproduction in any medium, provided the original work is properly cited. 

## References

- [1] Lind V. Short root anomaly. *Scand J Dent Res* 1972;80:85-93.
- [2] Apajalahti S, Arte S, Pirinen S. Short root anomaly in families and its association with other dental anomalies. *Eur J Oral Sci* 1999;107:97-101.
- [3] Holtta P, Nystrom M, Evalahti M, Alaluusua S. Root-crown ratios of permanent teeth in a healthy finnish population assessed from panoramic radiographs. *Eur J Orthod* 2004;26: 491-497.
- [4] Puranik C, Hill A, Henderson Jeffries K, Harrell S, Taylor R, Frazier-Bowers S: Characterization of short root anomaly in a Mexican cohort – Heredity idiopathic root malformation. *Orthod Craniofac Res* 2015;18:62-70.
- [5] US Census Bureau: [census.gov/quickfacts/fact/table/US/PST045216](http://census.gov/quickfacts/fact/table/US/PST045216). Accessed 18 Aug. 2017.
- [6] Wang J, Feng JQ. Signaling pathways critical for tooth root formation. *J Dent Res* 2017;96:1221-1228.
- [7] Dutra EH, Janakiraman N, Nanda R, Uribe FA. Targeted mechanics for treatment of patients with severe short-root anomaly. *J Clin Orthod* 2017; 51:279-289.
- [8] Lupi J, Handelman C, Sadowsky C. Prevalence and severity of apical root resorption and alveolar bone loss in orthodontically treated adults. *Am J Orthod Dentofacial Orthop* 1996;109: 28-37.
- [9] Levander E, Malmgren O, Stenback K. Apical root resorption during orthodontic treatment of patients with multiple aplasia: A study of maxillary incisors. *Eur Orthod Soc* 1998;20:427-434.
- [10] Kjaer I. Morphological characteristics of dentitions developing excessive root resorption during orthodontic treatment. *Eur J Orthod* 1995;17:25-34.
- [11] Sameshima G, Sinclair P. Predicting and preventing root resorption: Part I. diagnostic factors. *Am J Orthod Dentofacial Orthop* 2001;119:505-510.
- [12] Thongudomporn U, Freer T. Anomalous dental morphology and root resorption during orthodontic treatment: A pilot study. *Aust Orthod J* 1998; 15:162-167.
- [13] Newman W. Possible etiologic factors in external root resorption. *Am J Orthod* 1975;67:522-539.
- [14] Valladares N, Rino N, de Paiva J. Orthodontic movement of teeth with short root anomaly: Should it be avoided, faced or ignored? *Dent Press J Orthod* 2013;18:72-85.
- [15] Weltman B, Vig K, Fields H, Shanker S, Kaizar E. Root resorption associated with orthodontic tooth movement: A systematic review. *Am J Orthod Dentofacial Orthop* 2010;137: 462-476.
- [16] Lee R, Artun J, Alonzo T. Are dental anomalies risk factors for apical root resorption in orthodontic patients? *Am J Orthod Dentofacial Orthop* 1999;116: 187-195.
- [17] Mirabella A, Artun J. Risk factors for apical root resorption of maxillary anterior teeth in adult orthodontic patients. *Am J Orthod Dentofacial Orthop* 1995;108:48-55.
- [18] Levander E, Malmgren O. Evaluation of the risk of root resorption during

orthodontic treatment. Eur J Orthod 1988; 10:30-38.

[19] Goldin B. Labial root torque: Effect on the maxilla and incisor root apex. Am J Orthod Dentofacial Orthop 1989;95:209-219.

[20] Newman WG. Possible etiologic factors in external root resorption. Am J Orthod 1975;67:522-539.