

We are IntechOpen, the world's leading publisher of Open Access books Built by scientists, for scientists

6,900

Open access books available

186,000

International authors and editors

200M

Downloads

Our authors are among the

154

Countries delivered to

TOP 1%

most cited scientists

12.2%

Contributors from top 500 universities



WEB OF SCIENCE™

Selection of our books indexed in the Book Citation Index
in Web of Science™ Core Collection (BKCI)

Interested in publishing with us?
Contact book.department@intechopen.com

Numbers displayed above are based on latest data collected.
For more information visit www.intechopen.com



Ovarian Cancer Tumour Biology: Genesis

Ján Varga

Abstract

Ovarian cancer (OC) is the fifth leading cause of cancer deaths among women, thus early diagnosis is of paramount importance to survival. A clear OC etiopathogenesis is not yet fully understood. Large histopathological variability predicts more initial tissue for carcinogenesis. Many connections of biologically different tissue as *locus minoris resistentiae* for carcinogenesis have been confirmed. Expansion of knowledge about OC etiopathogenesis may help to construct an algorithm for early diagnosis. Ovarian surface epithelium, ectopic Müllerian epithelium, and fallopian tubes, along with endometriosis, are significant in the process of OC development. An oxidative microenvironment caused by recurrent ovulation or arising due to a degradative process in ectopic endometrium, mainly endometriomas, play a prominent role in the development of OC.

Keywords: ovarian cancer, etiopathogenesis, ovarian surface epithelium, cortical inclusion cyst, fallopian tube, endometriosis, endosalpingiosis, ovulation, tubo-ovarian junction, ovarian carcinogenesis

1. Introduction

Although ovarian cancer (OC) is not the most common cancer, it is the fifth leading cause of cancer deaths among women [1] and accounts for 3–4% of all female cancers. Improvement of therapeutic options in OC patients has improved disease-free survival but has had no significant effect on overall survival. There is still the need for genetic profiling to identify patients who will benefit from anti-angiogenic treatment [2, 3]. Due to the typical disease characteristics, such as initially asymptomatic growth and delayed symptoms, most OC patients are diagnosed at an advanced stage. Early diagnosis at the asymptomatic stage is of paramount importance for survival. Understanding OC development pathways can help with early diagnosis and thus increase the potential of curability as well as screening programs.

2. Ovarian cancer - background

2.1 Classification

Histo-anatomy and tumour biology are main determining factors in OC classification.

Up to 90% of all OC is derived from the epithelium. The remaining 10% represents non-epithelial cancers with sex-cord stromal tumours and germ cell tumours. Epithelial OC is either mucinous (3%) or non-mucinous (97%). The most represented group, non-mucinous, includes serous OC, endometrioid ovarian cancer (EOC), clear cell ovarian cancer (CCOC), transitional cell carcinoma, and others.

The model of two different tumour types in epithelial OC is widely supported and was officially accepted by the World Health Organisation (WHO) in 2004 [4]. Type 1 OC is defined from precursor through borderline variants. These cancers usually have an indolent course and good prognosis. Type 2 OC, such as high-grade serous ovarian cancer (HGSOC), reports fast progression, aggressiveness, and poor prognosis (**Figure 1**). Ninety percent of all deaths from OC are caused by this type [5].

The most common secondary cancers are metastatic lesions in the gastrointestinal tract or breasts [6].

2.2 Carcinogenesis: basic orientation

The cells of origin for OC are well studied, although some OC may not originate in the ovaries. OC in extra-ovarian tissue can also occur. For example, mucinous OC can resemble other endocervical glands and gastro-intestinal epithelium.

EOC and CCOC often show the presence of endometriosis in their histology. Histopathological criteria can clearly define a couple of types of endometriosis with different biological potential. While benign endometriosis faces the onset of the endometriosis overthrow, atypical endometriosis is already an ongoing process. The range as well as the time interval of oxidative load significantly affect which deposit of benign endometriosis progresses. The degradation processes typically seen in ectopic endometrium are the source of oxidative stress, and close contact with the

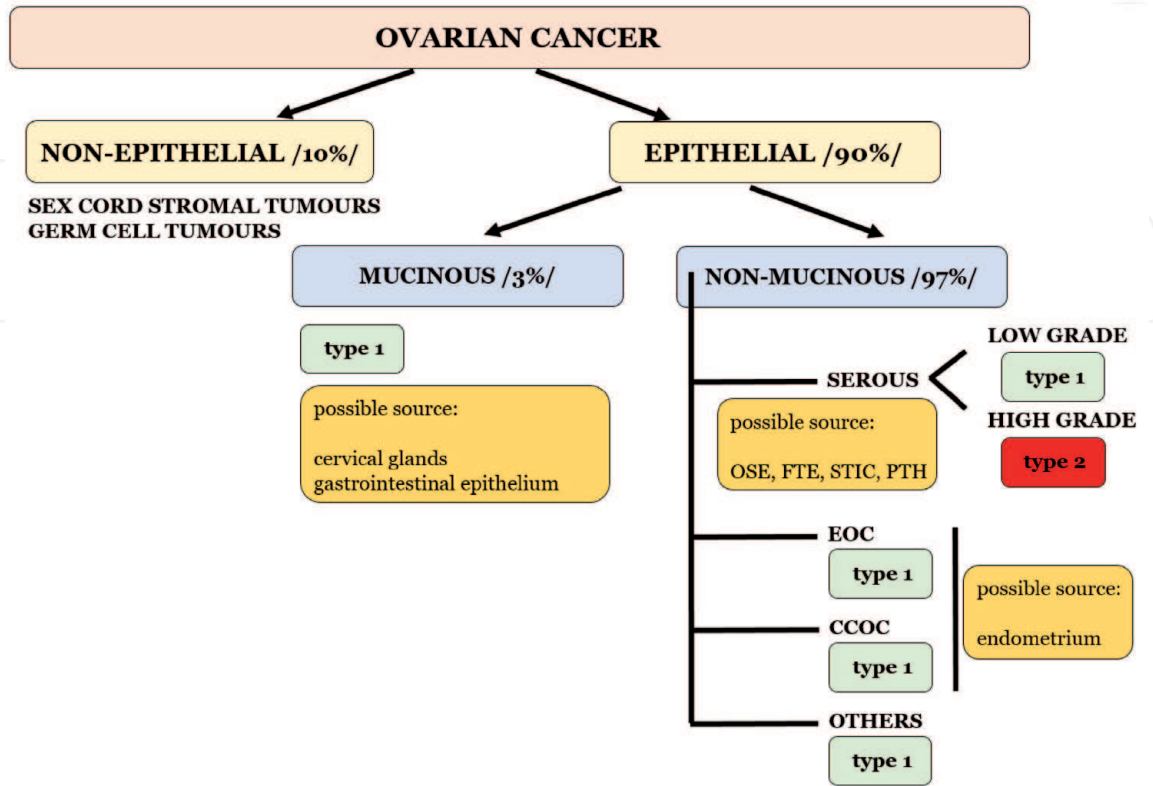


Figure 1.
Ovarian cancer classification due to histo-anatomy and tumour biology with possible initial source.

ovary potentiates this process. This explains why ovarian endometriomas have the greatest potential for progression and why there is less risk of progression in deep infiltrating endometriosis.

Serous OC can originate in the ovary as well as extra-ovarian tissue. The close relationship was observed with fallopian tube, mainly its fimbriated end. Fallopian tube epithelium (FTE) plays an important role in the development of ovarian malignancy. The precursor originating from the FTE can locally progress or, more often, adhere to the more favourable environment of the ovary. Local progression of the precursor derived from the FTE is rare. The reason for this is the inhibitory effect of the fallopian tube microenvironment on carcinogenesis when compared to the ovarian microenvironment. Oxidative stress resulting from incessant ovulation leads to accumulation of DNA changes in the FTE with subsequent exfoliation of precursors to the ovarian surface epithelium. Even more tissues for ovarian carcinogenesis with different biological potential have been recognised in the FTE. Type 1 OC, although containing oncogene alterations of RAS-PMK or PI3K-AKT, is genomically stable, for example, as in wild-type p53. Type 2 OC reports p53 mutations and pronounced genomic instability [5].

Generally, the initial tissue for OC development can be located in the ovary, ectopic Müllerian epithelium, fallopian tube, or endometrium (**Figure 1**).

Age older than 64 years is a risk factor for OC mortality and risk of disease increases significantly with advancing age. Within a genetic predisposition only limited clinically relevant mutations are currently known. Knowledge about tumour suppressor genes, *BRCA* mutations, and Lynch syndrome help to construct a preventive surgery programme for patients. An oxidative microenvironment due to incessant ovulation in the tubo-ovarian junction or degradative processes in endometriomas are considerable risk factors for DNA alterations. Thus, decreased ovulation may act as a protective factor against OC, although not every situation

Group of factors	Factor	+	—	+/-
Age	Age		•	
Genetic	Family history		•	
	BRCA mutation		•	
	Lynch syndrome		•	
Reproduction	Incessant ovulation		•	
	Menarche			•
	Menopause			•
	Parity	•		
	Lactation	•		
Hormonal	Hormonal contraceptives	•		
	Hormone replacement therapy			•
Gynaecological	Endometriosis		•	
	Pelvic inflammatory disease			•
	Fallopian tube occlusion	•		
Others	Obesity			•
	Alcohol/cigarettes/caffeine			•

Table 1.
The share of individual factors in protection (+), predisposition (—) or controversial position (+/—) in relation to the OC development.

confirms this fact (**Table 1**). The main factors influencing risk-reduction strategies are genetic predispositions, ageing, and parity.

3. Ovarian cancer: etiopathogenesis

3.1 Ovary

The infiltration of the ovaries by cancer cells even in the early stages of OC has been confirmed. Due to this fact, the initial concept was that the origin of OC is in the ovary. The ovarian surface epithelium (OSE) covers the ovary and during ovulation invagination of the OSE may occur, leading to the formation of small cystic lesions located in the ovarian cortex called cortical inclusion cysts (CICs).

The engagement of ovulation in carcinogenesis has been known for about 50 years. The oxidative stress accompanying ovulation alters the cells of the OSE. The accumulation of DNA damages arising due to the pro-inflammatory and pro-oxidative microenvironment and subsequent inability to repair them leads to the formation of pathological clone cells (**Figure 2**). In addition, women with a *BRCA* mutation and decreased ability of DNA repair are more prone to this process [7].

Incorporated CICs containing DNA-altered cells, as well as ambient pluripotent stem cells, are exposed to cyclic inflammatory activity. It has already been described that stem cell activity is silenced in cancerous OSE [8]. Thus, dysregulated pluripotency of stem cells may contribute to growth promotion and differentiation, finally leading to cancer formation [7]. Inadequate host tissue stem cell activity as the factor potentiating growth and malignant transformation in other cancers such as colorectal carcinoma has also been described [9].

The histology of certain HGSOE shows similarity to tissue developmentally derived from Müllerian ducts (**Figure 3**). One possible reason for this is that the relatively unstable, undifferentiated nature of OSE may mould the tissue of a Müllerian phenotype through the process of metaplasia [10]. Metaplastic OSE with different phenotype create after its incorporation into CIC Müllerian type of cortical inclusion cyst (mCIC), finally progressing into OC. This represents a theory of OC development from Müllerian epithelium but initially arising from metaplastic OSE. Another theory is the transport of Müllerian epithelium into the OSE from extra-ovarian localisation (e.g., ectopic Müllerian epithelium, endosalpingiosis, or fallopian tubes).

3.2 Ectopic Müllerian epithelium

As early as 1999, the theory that all epithelial OC originated initially from the ovary was challenged. As a primary source was indicated extra-ovarian müllerian epithelium (**Figure 3**). It was observed that Müllerian epithelium has more similar patterns to HGSOE than to OSE. The theory was supported by proof of the absence of ovarian tissues in primary peritoneal cancers without ovarian invasion but that were clinically and histopathologically consistent with HGSOE. Secondary Müllerian tissue as the residue of ectopic Müllerian epithelium (outside of the cervix, endometrium, or fallopian tubes) as the source of cells for carcinogenesis has been confirmed [11].

3.2.1 Endosalpingiosis

Endosalpingiosis (ES) represents an ectopic presence of FTE. When compared to endometriosis, ES shows ciliary epithelium and absence of inflammatory

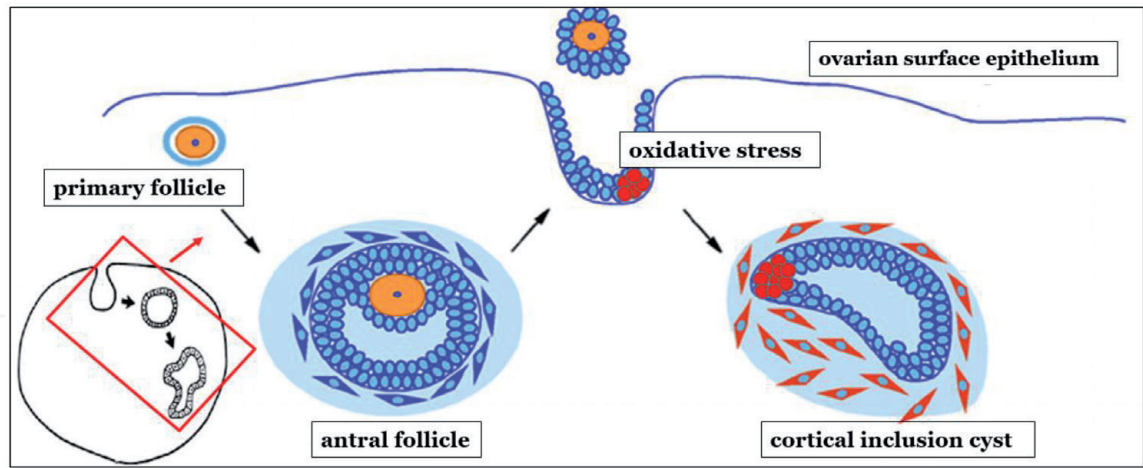


Figure 2.
Cortical inclusion cyst formation from ovarian surface epithelium under the effect of oxidative stress resulting from ovulation.

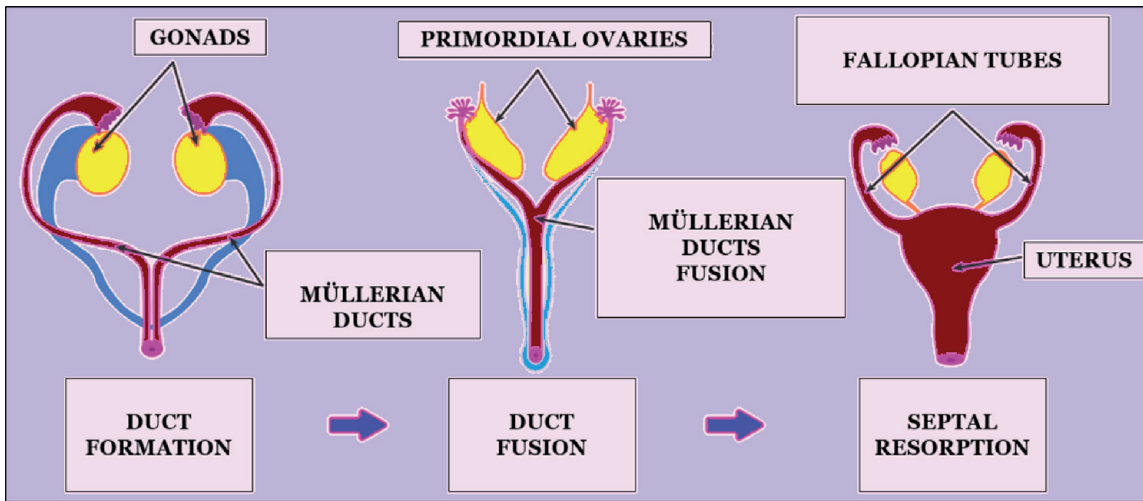


Figure 3.
The development of female genitals and role of Müllerian ducts.

reaction. In addition, there is a difference in incidence related to age among these two conditions. The discovery of fallopian tube importance in the process of ovarian carcinogenesis and subsequent implementation of sectioning and extensively examining the fimbriated end protocol (SEE-FIM) led to increased ES rates. In women aged 31–50 years, ES incidence is 37%. In menopausal women, incidence increases to 66% [12]. Endometriosis incidence rapidly decreases after menopause, whereas an opposite effect is seen in ES. This is caused by the different biology of the diseases, although both entities probably arise from dissemination of physiologically localised tissue. While endometriosis represents a hormone-dependent disease, ES probably arises from tissue detachment of FTE. Due to the hormonal attenuation after menopause, endometriosis regresses; however, increasing age increases the probability of exfoliation of FTE from fallopian tubes. Different biological potential can also be present. In ES tissues degradative processes are missing, which means less oxidative load. Thus also malignant potential of ES should be present when compare to endometriosis.

The theories of ES development discuss two possibilities. One envisages a metaplasia of pluripotent coelomic peritoneal epithelium to FTE tissue. More likely it is a process of primary dissemination of FTE. This second theory explains the presence of ES in women only and that the most common localization of ES is in the ovaries.

Relevant clinical data about ES are scarce, although recent studies show its association with gynaecological malignancies [13]. A significant relationship between ES and borderline ovarian carcinoma (BOC) has been observed. One third of serous BOC patients present with ES in their histology and incidence of ES increases to 70% in recurrent serous BOC [14]. The connection with slowly progressing cancers is likely due to low biological activity of ES.

3.3 Fallopian tube

In 2001, small dysplastic lesions similar to HGSOC containing *BRCA* mutations were discovered in a patient's fallopian tubes [15]. Serous tubal intraepithelial carcinoma (STIC) is characterised by enlarged epithelial cells with atypia of nucleoli. The distal part of the fallopian tube is the main region where STIC is seen. This is most probably due to the close connection with the ovary where ovulation with chronic inflammatory and oxidative microenvironment takes place. Immunohistochemical study of STIC showed positivity of p53 as well as γ H2AX, which is a marker of double-stranded DNA breaks [16].

The presence of STIC and HGSOC at the same time was confirmed in 11–61%. The incidence of STIC in asymptomatic risky patients after prophylactic adnexectomy was reported to be 0.4%–8.5%. The incidence in risk-free patients was 0.8%–3.1% [17]. Relatively wide incidence of STIC in HGSOC patients is due to non-identical diagnostic criteria of STIC. The criteria for STIC diagnosis are:

- morphological abnormalities including change of nucleus/cytoplasm ratio, enlarged nucleus with prominent nucleoli, ciliary cells reduction, and absence of basement membrane penetration
- p53 overexpression (> 60%) or absence of expression
- increased proliferative index Ki67 (> 10% positive cells in lesion)

The knowledge of early tubal precursors increased a request for precise fallopian tubes assessment. On the other hand implementation of detailed investigation protocol uncovered more microscopic lesions with not known tasks. Apart from STIC, three other lesions need to be taken into consideration: p53 signature, secretory cell outgrowth (SCOUT), and serous intraepithelial lesion (STIL).

p53 signature represents a cluster of FTE reporting p53 positivity with Ki67 < 10%. Morphological changes are not present and therefore a diagnostic process is focused on immunohistochemical examination. It can be a bilateral and multifocal lesion; the role is not fully clarified. It can be an initial step with subsequent progression or the lesion can persist.

SCOUT is defined as a proliferation of at least 30 secretory fallopian tube cells with Bcl2 positivity as well as P53 negativity. Another feature is loss of *PAX2*, which is seen in STIC as well as in HGSOC. This predicts *PAX2* inactivity as part of carcinogenesis and SCOUT can be a step of this process. The amount of SCOUT increases with age and most likely represents a precursor of p53 lesions [18]. However, they are not reported in clinical findings due to their unclear clinical importance.

STIL contains atypia but does not reach STIC. It represents a morphological intermediate stage between p53 and STIC [18].

The process of ovarian carcinogenesis starting in the FTE under the effect of ovulation takes more than 30 years. Development of p53 signature from secretory epithelial cells of the fallopian tubes lasts approximately 10 years, and it takes

another 15 years for the development of STIC, and then 5 more years for the development of HGSOC from STIC (**Figure 4**) [19].

The knowledge of FTE hypothesis as the source of OC potentiates an idea of reduction of preventive surgery range in high-risk patients. Due to the lack of information about the role of fallopian tubes on general OC incidence, the risk reduction of OC occurrence after prophylactic salpingectomy cannot be established. The omission of oophorectomy in premenopausal women prevents menopausal side effects but certain risk of OC remains.

3.3.1 STIC transport to ovaries

Although the STIC as a precursor of HGSOC is clearly defined, infiltration of the fallopian tubes was not observed in a large proportion of patients with HGSOC [20]. The reason for this is the theory of transportation of early genomically altered secretory epithelial cells from the distal part of fallopian tubes into the OSE. Implantation of tissue in the CIC of OSE leads to formation of mCIC (**Figure 5**) where the ovarian microenvironment creates better conditions for cancer progression [21].

The question of whether OC originates in the ovary or the fallopian tube is not fully answered. The microenvironment plays a crucial role. Whereas the ovary accelerates the process of cancer initiation, progression, and growth, the fallopian tubes more likely have an inhibitory effect [21]. This may explain why the precursor in case of cancer originating from the ovary cannot be detected. The process in these cancers is so rapid that precancerous lesions are often not detected. Inversely, in the fallopian tubes there is a longer time window for detecting early lesions, and after their transportation into the ovary the acceleration of the cancer is seen.

Although the conditions for progression are apparently better in the ovaries, local progression of STIC in the fallopian tubes and formation of primary fallopian tube carcinoma can occur.

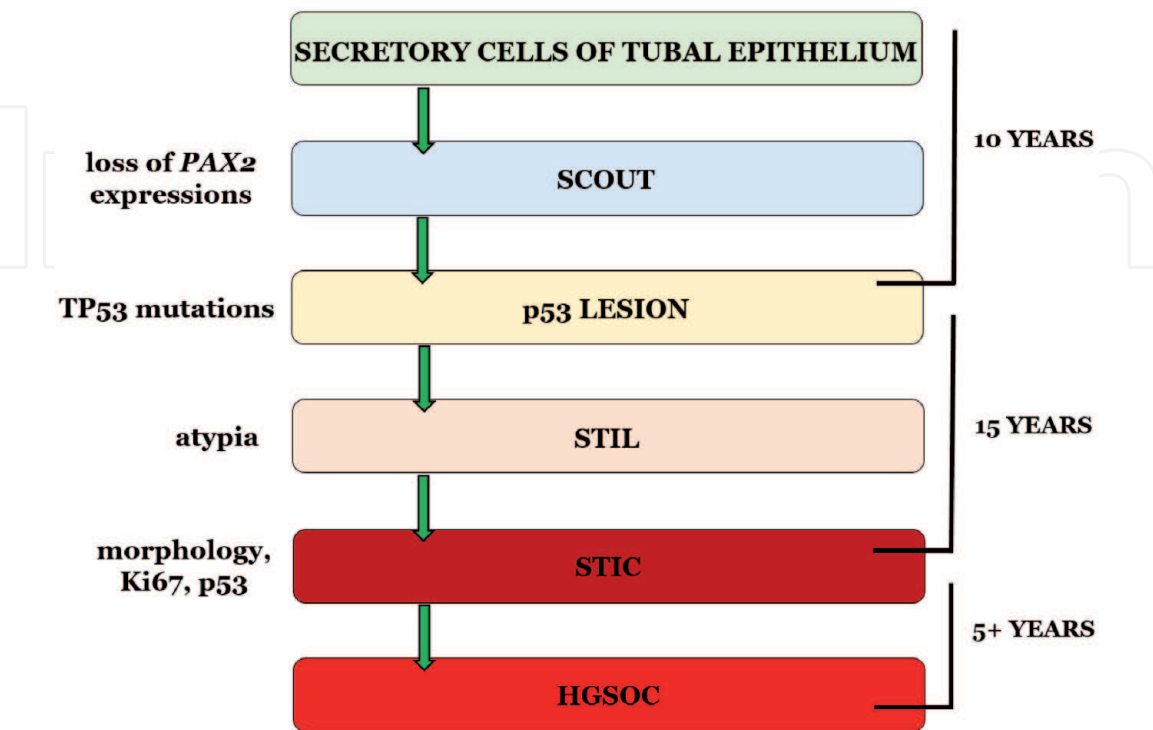


Figure 4.
The biological course of ovarian carcinogenesis starting in fallopian tube epithelium.

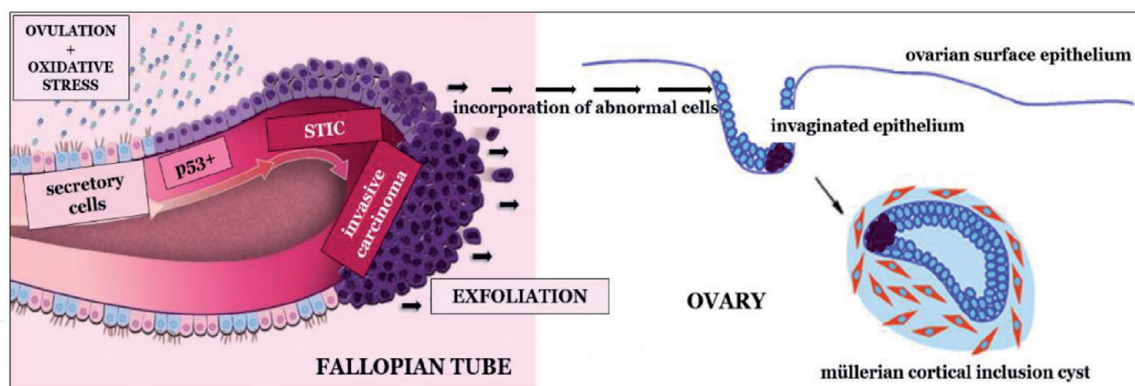


Figure 5.
The process of incorporation of fallopian tube cells into ovarian surface epithelium.

3.3.2 Papillary tubal hyperplasia

The fallopian tubes play a role in some type 1 cancers. Papillary tubal hyperplasia (PTH) represents a cluster of epithelial cells and small papillae with or without psammomatous bodies in the lumen of the fallopian tube (**Figure 6**). They float freely in tubal lumen or protrude from the epithelium into the lumen. This is a crucial difference from tubal hyperplasia. It was suggested that PTH represents the most advanced stage of tubal hyperplasia and has a significant association with some ovarian and extra-ovarian low-grade tumours. Earlier stages of tubal hyperplasia do not show such a prominent association [22].

PTH arises as the consequence of chronic inflammatory processes and can be diffuse or focal. Anatomically the most common place of appearance is the tubal ampoule. After its transport into the ovary, PTH can progress and form serous BOC and subsequently low-grade serous ovarian cancer (LGSOC). Many morphological similarities of PTH and LGSOC have been confirmed. Both contain ciliary and secretory cells as well as intraepithelial lymphocytes. Psammomatous bodies commonly present in PTH as well as LGSOC. After its transportation on peritoneal surfaces, PTH represents a precursor of ES or non-invasive implants.

Chronic inflammatory changes (i.e., chronic salpingitis or other forms of pelvic inflammatory disease) leading to architectural reconstruction of the fallopian tube induce FTE proliferation resulting in PTH. Mutation of *KRAS* or *BRAF* genes represent the main trigger of carcinogenesis. After its transportation into the ovary, the final structure is usually mCIC. Not all studies have confirmed this algorithm and significant association of PTH with LGSOC or serous BOC was not seen [23, 24]. More studies in this area are still needed.

3.3.3 Primary fallopian tube carcinoma

Primary fallopian tube carcinoma (PFTC) represents a rare entity accounting for 0.14%–1.8% of all female genital tract cancers. Nevertheless, the incidence in the last several years has increased due to the change in fallopian tube assessment. Wide implementation of the SEE-FIM protocol into clinical practice increased detection of different precursors from FTE as well as the incidence of PFTC. Unfortunately, they represent mainly asymptomatic lesions or, like in some PFTC cases, are indicated for surgery due to adnexal mass. At present, PFTC is considered to be the presence of STIC or invasion of the carcinoma into the fallopian tube mucosa or if the fallopian tube is incorporated into the tumour mass [25].

The precursor in HGSOC or high-grade serous extra-ovarian cancer is STIC with a typical p53 mutation. In case of HGSOC or extra-ovarian cancer, STIC is

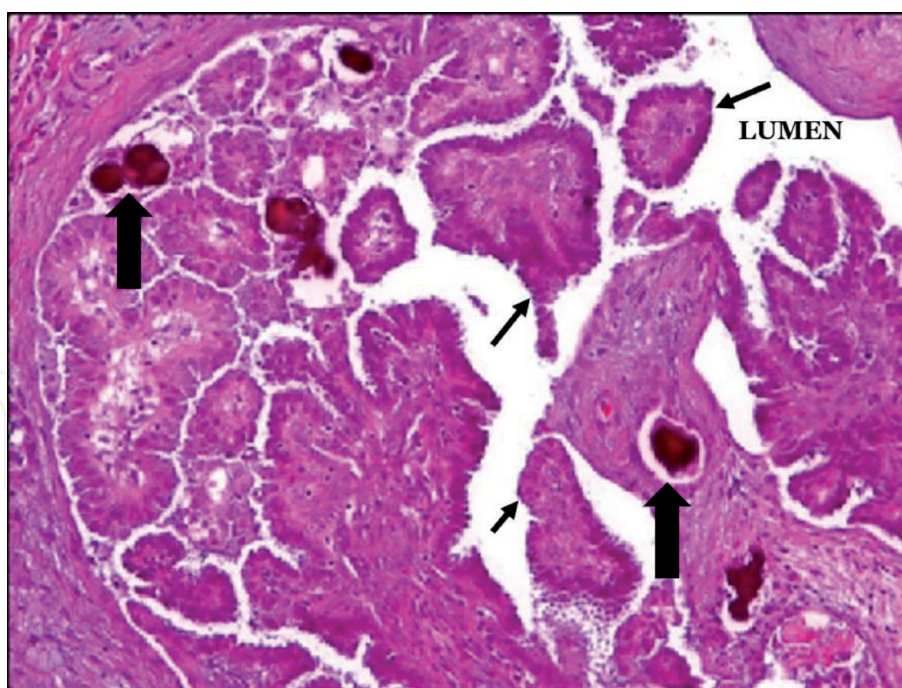


Figure 6.
Papillary tubal hyperplasia. Numerous small papillae/thin arrows/psamomatous bodies/gross arrows/.

detached from the FTE and implanted on surfaces without invasion of tissue under the basement membrane of the FTE. However, in case of PFTC a local progression of STIC with invasion into deeper structures is seen. Localisation of PFTC in the tubal lumen leads to its distension with earlier clinical symptoms. Therefore, PFTC diagnosis is done earlier than that for HGSOc. In addition, the partially closed space of tubal lumen can delay spread of disease in the abdominal cavity.

3.4 Endometriosis

Endometriosis is a clinically complex syndrome with chronic hormone-dependent inflammation and notable proliferative potential. Although endometriosis incidence is around 10%, it accounts for less than 1% of malignancies [26].

The common features of endometriosis and cancer cells have been clearly described. These include angiogenic potential of stem cells as well as their ability to evade apoptosis. Haemolysis, the process typical for endometriosis, is highly associated with oxidation. An oxidative microenvironment results in accumulation of DNA mutations and leads to, under the supervision of the immune system, either cell death or formation of pathogenic clone cells.

The similar effect like in FTE, which is for better conditions of malignization transported into ovary is also in endometriosis seen. Inflamed stroma with mutated epithelium can progress to cancer when located on the ovary. This explains why malignant overthrow is uncommon in the case of deep infiltrating endometriosis even when containing similar DNA mutations [26]. The microenvironment plays an important role in these situations as well.

Endometriosis-associated ovarian cancer (EAOC) includes mainly endometrioid ovarian cancer (EOC), clear cell ovarian cancer (CCOC), and sero-mucinous borderline ovarian cancer. Nevertheless, not every case of EAOC presents with endometriosis. EAOCs are characterised as well-differentiated tumours occurring at a younger age and initially diagnosed at an earlier stage when compared to endometriosis-free EAOC. The question which endometriotic lesion tend to progress into carcinoma remains still not completely answered.

Benign and atypical (premalignant) endometriosis can be defined using histopathological criteria. There is a significant association of atypical endometriosis (AE) with EAO. While benign endometriosis (BE) does not contain atypia and has greater incidence, AE is less frequently seen and the atypia can be defined in two grades [27]. Cellular atypia, also called cytological atypia, defines epithelial layer changes such as hyperchromasia and pleomorphism. However, structural atypia, also called hyperplasia, deputises hyperplastic changes similar to ectopic endometrium, which includes simple or complex hyperplasia with or without cellular atypia [28]. Although plenty of studies refer to AE as tissue with cytological and structural atypia, cytological atypia are seen in cancer-free patients, whereas structural atypia are typically present in OC patients (**Figure 7**) [27].

The different potential of both types of atypia have been confirmed by studies of COX-2, Ki-67, and BAF250a. In the case of BE, immunohistochemical COX-2 positivity is significantly higher compared to that in AE. In both types of atypia in AE, rapidly higher COX-2 positivity in cytological atypia has been observed. This predicts BE as well as cytological atypia of AE into reactive changes. In Ki-67 examinations lower values in BE and cytological atypia of AE were detected. Thus, the structural atypia of AE can be concluded as the tissue with greater proliferative potential. The decrease in BAF250a was confirmed in both OC and AE patients. Comparing both types of atypia in AE, we can see lower BAF250a expressions in structural atypia patients [27].

EAO tissue can be present with or without endometriosis. If endometriosis is confirmed, both types can be seen (BE as well as AE). In some cases even gradual transition from BE to AE and BOC can be detected. Approximately one of 10 women suffers from endometriosis and only less than 1% (0.3%–0.8%) of endometriosis patients will progress to cancer. When checked for AE incidence in endometriosis patients, 8% show atypia in their histology. The incidence of AE increases in patients with OC, whereas one-third of EAO patients present with AE [27]. Detailed analysis of AE patients showed those with long-term history of disease, advanced stage, and older age when compared to BE patients. Current accepted criteria for AE include eosinophilic cytoplasm, large hyperchromatin or pale nuclei with moderate-to-marked pleomorphism, increased nucleus-to-cytoplasm ratio, and cell aggregation.

The endometriosis was solidly confirmed as the precursor of some OC, preferentially of certain portion of EAO. Due to the low incidence of endometriosis

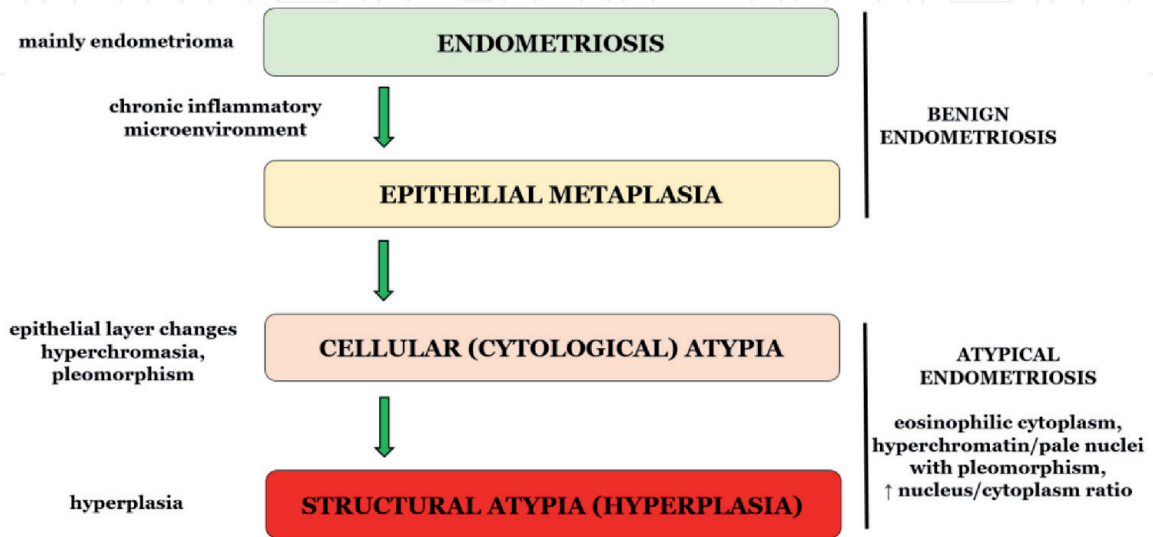


Figure 7.
The development of changes in ectopic endometrium.

Initial structure	Biological process	Final structure
OSE	Mutation + incorporation into small cyst	CIC
OSE	Metaplasia + incorporation into small cyst	mCIC
Ectopic Müllerian epithelium	Local progression transport to the ovary	Primary peritoneal cancer mCIC
ES	Transport to the ovary	Serous BOC
FTE	Transport to the ovary	mCIC
STIC	Local progression	PFTC
STIC	Transport to the ovary	HGSOC
PTH	Transport to the ovary	BOC/LGSOC
Endometriosis	Retrograde reflux/transport to tubo-ovarian junction	EOC, CCOC

Table 2.
Simplified process of ovarian carcinogenesis.

overthrow, predictive factors are not fully clarified. There is significantly greater association of endometriomas with malignancy when compared to deep infiltrating endometriosis. In those cases, the ovarian microenvironment plays a crucial role. Thus, even in endometriosis overthrow a tubo-ovarian junction is inevitably needed to ensure endometrial reflux to the ovary and then cellular progression in the endometrioma. From the clinical characteristics of OC, patients with long-term history of disease as well as large endometriomas (> 9 cm) may be defined as high-risk patients for progression and thus require more precise observation (**Table 2**) [29].

4. Conclusion

Incidence of OC is relatively low when compared to other onco-gynaecological diseases. Nevertheless, OC is the fifth leading cause of cancer deaths among women with 95% of deaths occurring in women older than 45 years.

Disease localisation in the abdominal cavity allows asymptomatic growth at the early stages. The diagnostic timing of symptomatic disease does not affect the parameters of survival. To increase survival rate, it is important to detect the disease at the early asymptomatic stage. Knowledge of disease etiopathogenesis increases the probability of detecting precancerous lesions or early-stage cancers.

The source of OC can be OSE through CIC or mCIC. Local progression is seen less frequently, whereas transport of the precursor to the ovarian surface is more common. Retrograde menstruation may be a cause of some EAOs, mainly EOC and CCOC.

IntechOpen

IntechOpen

Author details

Ján Varga

Department of Gynaecology and Obstetrics, Faculty of Medicine, P.J. Šafárik
University, L. Pasteur University Hospital, Košice, Slovakia

*Address all correspondence to: janko.varga@gmail.com

IntechOpen

© 2021 The Author(s). Licensee IntechOpen. This chapter is distributed under the terms of the Creative Commons Attribution License (<http://creativecommons.org/licenses/by/3.0>), which permits unrestricted use, distribution, and reproduction in any medium, provided the original work is properly cited. 

References

- [1] Bray F, Ferlay J, Soerjomataram I, et al. Global cancer statistics 2018: GLOBOCAN estimates of incidence and mortality worldwide for 36 cancers in 185 countries. *CA: A Cancer Journal for Clinicians*. 2018;**68**:394-424. DOI: 10.3322/caac.21492
- [2] Schmid BC, Oehler MK. Improvements in progression-free and overall survival due to the use of anti-angiogenic agents in gynecologic cancers. *Current Treatment Options in Oncology*. 2015;**16**:318. DOI: 10.1007/s11864-014-0318-0
- [3] Tewari KS, Burger RA, Enserro D, et al. Final overall survival of a randomized trial of bevacizumab for primary treatment of ovarian cancer. *Journal of Clinical Oncology*. 2019;**37**: 2317-2328. DOI: 10.1200/JCO.19.01009
- [4] Shih LEM, Kurman RJ. Ovarian tumorigenesis: A proposed model based on morphological and molecular genetic analysis. *The American Journal of Pathology*. 2004;**164**:1511-1518. DOI: 10.1016/s0002-9440(10)63708-x
- [5] Kurman RJ, IeM S. The dualistic model of ovarian carcinogenesis: Revisited, revised and expanded. *The American Journal of Pathology*. 2016;**186**:733-747. DOI: 10.1016/j.ajpath.2015.11.011
- [6] Peres LC, Cushing-Haugen KL, Anglesio M, et al. Histotype classification of ovarian carcinoma: A comparison of approaches. *Gynecologic Oncology*. 2018;**151**:53-60. DOI: 10.1016/j.jygyno.2018.08.016
- [7] Klotz DM, Wimberger P. Cells of origin of ovarian cancer: Ovarian surface epithelium or fallopian tube? *Archives of Gynecology and Obstetrics*. 2017;**296**:1055-1062. DOI: 10.1007/s00404-017-4529-z
- [8] Bowen NJ, LDe W, Matyunina LV, et al. Gene expression profiling supports the hypothesis that human ovarian surface epithelia are multipotent and capable of serving as ovarian cancer initiating cells. *BMC Medical Genomics*. 2009;**2**:71. DOI: 10.1186/1755-8794-2-71
- [9] Barker N, Ridgway RA, Es JH, et al. Crypt stem cells as the cells-of-origin of intestinal cancer. *Nature*. 2009;**457**:608-611. DOI: 10.1038/nature07602
- [10] Kuhn E, Kurman RJ, IeM S. Ovarian cancer is an imported disease: Fact or fiction? *Current Obstetrics and Gynecology Reports*. 2012;**1**:1-9. DOI: 10.1007/s13669-011-0004-1
- [11] Dubeau L. The cell of origin of ovarian epithelial tumors and the ovarian surface epithelium dogma: Does the emperor have no clothes? *Gynecologic Oncology*. 1999;**72**:437-442. DOI: 10.1006/gyno.1998.5275
- [12] Sunde J, Wasickanin M, Katz TA, et al. Prevalence of endosalpingiosis and other benign gynecologic lesions. *PLoS One*. 2020;**15**:e0232487. DOI: 10.1371/journal.pone.0232487
- [13] Hermens M, Altena AM, Bulten J, et al. Increased association of ovarian cancer in women with histological proven endosalpingiosis. *Cancer Epidemiology*. 2020;**65**:101700. DOI: 10.1016/j.canep.2020.101700
- [14] Chui MH, Xing D, Zeppernick F, et al. Clinicopathologic and molecular features of paired cases of metachronous ovarian serous borderline tumor and subsequent serous carcinoma. *The American Journal of Surgical Pathology*. 2019;**43**:1462-1472. DOI: 10.1097/PAS.0000000000001325
- [15] Piek JM, van Diest PJ, Zweemer RP, et al. Dysplastic changes in prophylactically removed fallopian

tubes of women predisposed to developing ovarian cancer. *The Journal of Pathology*. 2001;**195**:451-456. DOI: 10.1002/path.1000

[16] Kobayashi H, Iwai K, Niino E, et al. The conceptual advances of carcinogenic sequence model in high-grade serous ovarian cancer. *Biomedical Reports*. 2017;**7**:209-213. DOI: 10.3892/br.2017.955

[17] Chen F, Gaitskell K, Garcia MJ, et al. Serous tubal intraepithelial carcinomas associated with high-grade serous ovarian carcinomas: A systematic review. *BJOG*. 2017;**124**:872-878. DOI: 10.1111/1471-0528.14543

[18] Nakamura M, Obata T, Daikoku T, et al. The association and significance of p53 in gynecologic cancers: The potential of targeted therapy. *International Journal of Molecular Sciences*. 2019;**20**:5482. DOI: 10.3390/ijms20215482

[19] Wu NYY, Fang C, Huang HS, et al. Natural history of ovarian high-grade serous carcinoma from time effects of ovulation inhibition and progesterone clearance of p53-defective lesions. *Modern Pathology*. 2020;**33**:29-37. DOI: 10.1038/s41379-019-0370-1

[20] Bowtell DD, Böhm S, Ahmed AA, et al. Rethinking ovarian cancer II: Reducing mortality from high-grade serous ovarian cancer. *Nature Reviews. Cancer*. 2015;**15**:668-679. DOI: 10.1038/nrc4019

[21] Karnezis AN, Cho KR, Gilks CB, et al. The disparate origins of ovarian cancers: Pathogenesis and prevention strategies. *Nature Reviews. Cancer*. 2017;**17**:65-74. DOI: 10.1038/nrc.2016.113

[22] Kurman RJ, Russell V, Junge J, et al. Papillary tubal hyperplasia: The putative precursor of ovarian atypical proliferative (borderline) serous

tumors, noninvasive implants, and endosalpingiosis. *The American Journal of Surgical Pathology*. 2011;**35**:1605-1614. DOI: 10.1097/PAS.0b013e318229449f

[23] Wolsky RJ, Price MA, Zaloudek CJ, et al. Mucosal proliferations in completely examined fallopian tubes accompanying ovarian low-grade serous tumors: Neoplastic precursor lesions or normal variants of benign mucosa? *International Journal of Gynecological Pathology*. 2018;**37**:262-274. DOI: 10.1097/PGP.0000000000000410

[24] Horn LC, Angermann K, Hentschel B, et al. Frequency of papillary tubal hyperplasia (PTH), salpingoliths and transition from adenoma to borderline ovarian tumors (BOT): A systematic analysis of 74 BOT with different histologic types. *Pathology, Research and Practice*. 2017;**213**:305-309. DOI: 10.1016/j.prp.2017.02.001

[25] Singh N, Gilks CB, Hirschowitz L, et al. Primary site assignment in tuboovarian highgrade serous carcinoma: Consensus statement on unifying practice worldwide. *Gynecologic Oncology*. 2016;**141**:195-198. DOI: 10.1016/j.ygyno.2015.10.022

[26] Anglesio MS, Papadopoulos N, Ayhan A, et al. Cancer associated mutations in endometriosis without cancer. *The New England Journal of Medicine*. 2017;**376**:1835-1848. DOI: 10.1056/NEJMoa1614814

[27] Niguez Sevilla I, Machado Linde F, Marín Sánchez MDP, et al. Prognostic importance of atypical endometriosis with architectural hyperplasia versus cytologic atypia in endometriosis associated ovarian cancer. *Journal of Gynecologic Oncology*. 2019. DOI: 10.3802/jgo.2019.30.e63

[28] Tanase Y, Kawaguchi R, Uchiyama T, et al. Long-term follow up

after surgical management for atypical endometriosis: A series of nine cases. *Case Reports in Oncology*. 2019;**12**: 76-83. DOI: 10.1159/000496178

[29] Tanase Y, Furukawa N, Kobayashi H, et al. Malignant transformation from endometriosis to atypical endometriosis and finally to endometrioid adenocarcinoma within 10 years. *Case Reports in Oncology*. 2013;**6**:480-484. DOI: 10.1159/000355282