

We are IntechOpen, the world's leading publisher of Open Access books Built by scientists, for scientists

6,900

Open access books available

186,000

International authors and editors

200M

Downloads

Our authors are among the

154

Countries delivered to

TOP 1%

most cited scientists

12.2%

Contributors from top 500 universities



WEB OF SCIENCE™

Selection of our books indexed in the Book Citation Index
in Web of Science™ Core Collection (BKCI)

Interested in publishing with us?
Contact book.department@intechopen.com

Numbers displayed above are based on latest data collected.
For more information visit www.intechopen.com



Acute Postoperative Infectious Endophthalmitis: Advances in Diagnosis and Treatment

*Sergio E. Hernandez-Da Mota,
Jose Luis Guerrero-Naranjo, Jose Dalma-Weiszhausz,
Raul Velez-Montoya and Jesus H. Gonzalez-Cortes*

Abstract

Acute postoperative infectious endophthalmitis remains one of the most dreaded complications of ophthalmic surgery. One of the keys to success in treating this complication is to make an early clinical diagnosis and, if possible, an etiologic diagnosis that can guide treatment with antibiotic therapy. Different antibiotic therapy modalities have emerged over the years that have made it possible to treat even resistant strains of various microorganisms that cause endophthalmitis. Another relevant advance made in the etiologic diagnosis of endophthalmitis is the advent of molecular biology techniques, such as the real-time polymerase chain reaction, which can detect minimal amounts of the genetic material of the causative microorganism present in the vitreous in a short period of time, thus improving treatment outcomes with better-guided therapy with intravitreal antibiotics. Aside from advances in postoperative diagnosis methods, the surgical treatment of endophthalmitis has had significant improvements in vitrectomy techniques, and in many cases, it has been proposed as the first-line treatment concomitantly with intravitreal antibiotic therapy. Moreover, there is increasing evidence that prophylaxis with intracameral antibiotic therapy further decreases postoperative endophthalmitis incidence.

Keywords: Acute postoperative endophthalmitis, vitrectomy, intravitreal antibiotics, polymerase chain reaction

1. Introduction

Acute postoperative infectious endophthalmitis (APIE) is an uncommon complication of eye surgery. It generally causes severe inflammation, which could significantly damage the ocular tissues and often has a poor prognosis, especially if it is not diagnosed and treated promptly [1–4].

APIE etiology is varied, being bacterial, the most frequent cause [3, 4]. Different ways to corroborate the microbiological diagnosis, such as a Gram staining on a smear and culture, have been described [2, 4]. Nonetheless, the use of molecular biology methods like the polymerase chain reaction (PCR) and other novel diagnostic tests has increased the speed and accuracy of etiologic diagnosis [2].

For several decades, intravitreal antibiotics injection (IAI) has been one of APIE treatment's mainstays [3, 4]. In recent years, the application of new antibiotic classes has been described, especially to treat APIE caused by resistant strains of the most prevalent causative pathogens [5]. Moreover, vitrectomy has become a crucial adjunctive therapeutic modality for infectious endophthalmitis [3–7]. Thanks to development in instrumentation and vitrectomy systems, visual results in APIE patients have consistently improved in recent years [6, 7].

2. Epidemiology

The incidence of APIE after cataract surgery has decreased considerably in the era of small incision surgery. In some reports, the incidence of APIE ranges from 0.12% to 1–3% [6, 7]. In patients undergoing trabeculectomy, the risk of developing endophthalmitis at five years is 1.1%, and the cumulative risk at 20 years can be as high as 20% [2–6, 8, 9]. The rate of endophthalmitis after endothelial keratoplasty and penetrating keratoplasty has been reported in up to 0.2% and 0.7%, respectively [10]. Regarding vitrectomy, the incidence of endophthalmitis tends to be relatively low. Some publications indicate an incidence of 0.05 to 0.06% [6]. Incidence of APIE following intravitreal injection of anti-VEGF agents is also infrequent. In one series of 10,164 injections only 3 cases of endophthalmitis were reported (0.030%) [1].

3. Risk factors

Multiple factors increase the likelihood of APIE in patients undergoing intraocular surgery. Some intraoperative complications such as posterior capsular rupture with or without vitreous loss, hypotony with aqueous humor filtration, especially in cases of clear corneal wounds and increased manipulation of intraocular tissues, are some factors that may raise the possibility of developing infectious endophthalmitis [3, 4, 11, 12].

The presence of inflammatory-infectious processes on the ocular surface or adnexa, such as conjunctivitis, keratitis, blepharitis, and dacryocystitis also, increases the incidence of endophthalmitis [4]. Additional systemic factors include advanced age [12] and chronic systemic debilitating diseases, such as diabetes mellitus (DM), malignancies, congenital or acquired immunodeficiencies and immunosuppression [3, 4, 12]. Patients with DM represent significant changes in the conjunctival flora, representing an important subgroup of patients who might develop endophthalmitis [3, 4].

APIE risk factors after anti-VEGF intravitreal injections, include not wearing a face mask, not using povidone prior to the injection and speaking while performing the injection [12].

A systematic review and meta-analysis [11] of the risk factors for APIE following cataract surgery, reported that there is a significant association between male gender and APIE. The overall OR for male gender was 1.43 (95% CI 1.29, 1.58). There was a significant association between extra- or intracapsular cataract extraction and APIE (OR 2.19, 95% CI 1.40, 3.42) compared with phacoemulsification. Furthermore, intracameral cefuroxime had a protective effect against APIE compared with topical antibiotics alone (OR 5.48, 95% CI 3.79, 7.92).

Analysis of the included retrospective studies in the meta-analysis showed that posterior capsular rupture was also a significant risk factor of APIE (OR 6.33, 95%

CI 4.22, 9.49), and a significant increase in risk of APIE with other intraoperative complications (OR 4.95, 95% CI 2.31, 10.63) was observed, as well.

4. Etiology

Multiple microorganisms may cause APIE [3, 4]. Bacterial pathogens are the most common [4]. Gram-positive cocci are responsible for 65–80% of APIE cases, mainly *Staphylococcus spp.* [12, 13].

Staphylococci belong to the *Micrococcaceae* family and have a diameter of between 0.2 and 12 microns [3, 14, 15]. The most common staphylococci species that cause endophthalmitis are coagulase-negative Staphylococci and *Staphylococcus aureus*.

Among all Staphylococci, *Staphylococcus epidermidis*, a coagulase-negative staphylococci, has emerged as the main cause of APIE [4, 13]. These bacteria have the property of producing an exopolysaccharide, which can be a factor that hampers phagocytosis and induces antibiotic resistance, including methicillin and beta-lactam antibiotics. However, these microorganisms are almost always susceptible to vancomycin [3].

Staphylococcus aureus is a non-spore-forming facultative aerobic microorganism that colonizes human skin. It produces different enzymes such as catalase, coagulase, beta-lactamase, many of which, are related to its pathogenicity [14, 15]. *Staphylococcus aureus* is the second most common bacteria isolated in cases of APIE [3, 13].

Other causes of APIE include Streptococci, Gram-positive bacilli, Gram-negative cocci, and Gram-negative bacilli [4].

Streptococci are facultative Gram-positive, aerobic microorganisms or obligate anaerobes and produce various toxins that increase their virulence. They are also sensitive to vancomycin [3].

Gram-positive bacilli causative agents of endophthalmitis include bacteria from the *Bacillus* genus. The most common intraocular Gram-positive bacilli pathogen is *Bacillus cereus* [3, 4]. *Bacillus* is a spore-forming rod that is Gram-positive or Gram-variable. It produces extracellular products, including toxins that induce severe inflammation when injected into the eye. *Bacillus* infection risk factors include foreign bodies, immunosuppression from malignant tumors, corticosteroid use, penetrating and perforating trauma, as well as acquired immunodeficiency syndrome. The infection is quite virulent and may significantly damage the eye in less than 24 hours. Systemically, it may induce fever and leukocytosis [3]. Vancomycin is the first-line drug used against *Bacillus spp.*

The genus *Pseudomonas* are Gram-negative, strictly aerobic organisms found in soil and water. They are part of the normal human flora but are predominantly isolated in cases of nosocomial infection [3]. *Pseudomonas aeruginosa* is the most common Gram-negative bacteria causing APIE, but other species have also been isolated [3, 16]. The pathogenesis of the infectious disease caused by *Pseudomonas* includes the production of extracellular enzymes and other toxic proteins and hemolysin, endotoxin, and exotoxin A, which explain the fulminant and severe nature of its clinical presentation [3]. *Pseudomonas spp.* are usually sensitive to aminoglycosides and ceftazidime [3].

Other bacteria members of the *Enterobacteriaceae* family may cause APIE. *Enterobacteriaceae* is a group of Gram-negative, facultative aerobes. They are distributed in the soil and plants, and colonize the human and animals' gastrointestinal tract [3].

Type of surgery	Most frequently isolated microorganisms
Cataract	Gram-positive bacteria (95% of culture-positive isolates). 70% of gram-positive bacteria are coagulase-negative Staphylococci
Trabeculectomy	Early-onset bleb related endophthalmitis: coagulase-negative staphylococcus. Late-onset: Streptococcus species
Glaucoma drainage implants	Streptococcus species, Staphylococcus and <i>Haemophilus influenzae</i>
Vitrectomy	Gram-positive cocci account for more than 90% positive cultures
Penetrating keratoplasty	Coagulase-negative Staphylococci and Methicillin-resistant <i>Staphylococcus aureus</i>

Table 1.
Most frequently isolated microorganisms in different types of eye surgery [10, 12].

Fungal endophthalmitis is an infrequent cause of APIE; however, it should be considered as a possible pathogen [4]. *Candida*, *Aspergillus spp*, *Histoplasma*, and *Blastomyces dermatitidis* are some of the fungal microorganisms that may cause APIE.

Candida albicans is frequently found as part of the normal flora on the mucosal surfaces, and is the most common cause of fungal APIE, followed by *Aspergillus spp*. Patients that become immunocompromised by debilitating conditions such as AIDS, and other malignancies may also carry a higher risk for developing *Candida* APIE **Table 1** [4]. Summarizes the most frequently isolated microorganisms in different types of eye surgery.

5. Diagnosis

5.1 Signs and symptoms

The diagnosis of APIE is eminently clinical at onset. Intraocular surgery, mainly cataract surgery, is usually a painless procedure in the vast majority of cases [4, 12]. The sudden appearance of red eye, pain, and blurred vision as symptoms in the early postoperative period of patients that have undergone any intraocular surgery should always alert the surgeon to the possibility of APIE, although it is considered a rare but feared and devastating postoperative complication [3].

Common signs that may occur at onset are palpebral erythema and edema, ciliary injection, and conjunctival chemosis, corneal edema, hypopyon, anterior chamber cells, and vitreous haze due to vitritis (**Figures 1** and **2**). It is essential to mention that most endophthalmitis cases present between the third and tenth postoperative day, and 88% of the cases occur within six weeks after surgery (**Table 2**) [3, 4].

Fundus evaluation should be performed to determine the vitreous clarity, and to establish the status of the retina and the optic nerve. If fundus visualization is not feasible, linear B-ultrasound examination is mandatory to evaluate the posterior segment and rule out vitreous hemorrhage, retained lens material, retinal detachment, choroidal thickening, or the presence of membranes [4, 17].

5.2 Microbiology diagnosis

Samples obtained from anterior-chamber aspiration and vitreous needle biopsy or pars plana vitrectomy (PPV) should be process for smear and cultured

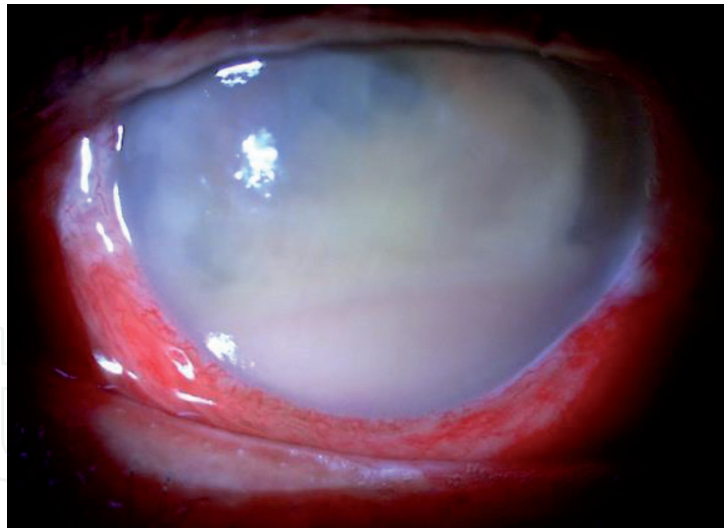


Figure 1.
*Clinical image of a case of an acute postoperative infectious endophthalmitis caused by *Pseudomonas aeruginosa*, showing prominent ciliary injection and conjunctival chemosis, a 3 mm hypopyon, and marked anterior chamber inflammatory infiltrate that obstructs visualizing the anterior segment details.*

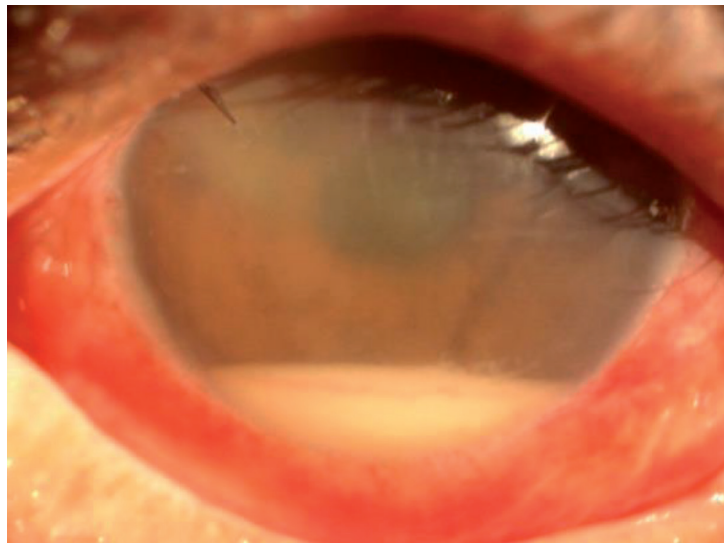


Figure 2.
*Clinical image of a case of an infectious endophthalmitis 3 days after phacoemulsification surgery caused by *Staphylococcus epidermidis*. The presence of hypopyon, corneal folds and edema, ciliary injection and cloudy media are observed.*

separately. The sample obtained from the vitreous should be undiluted and taken directly from the vitrectomy line. This has the potential advantage of having an adequate amount of bacterial load to grow in the culture plates, thus increasing the sensitivity of the culture to identify the possible APIE causative microorganism.

Alternatively, cassette washings from PPV should be concentrated by a centrifuge before culture and staining [3, 4]. Samples are placed on glass slides and stained using Gram and Giemsa stains. Obtained samples are plated on blood, thioglycolate, chocolate, and Sabouraud agars and cultured under both, anaerobic and aerobic conditions. Whenever possible, it is advisable to place the obtained samples directly on agar plates in the operating room for better yield. They should be at room temperature by the time they are used, avoiding using them at refrigeration temperature because microbial growth might be reduced. Care should be taken to avoid contamination while placing the samples on the plates or transport media.

Symptoms	Percentage present in endophthalmitis patients
Blurred vision	94%
Red eye	82%
Pain	74%
Lid edema	36%
Signs	
Hypopyon	86%
Red eye	82%
Loss of fundus visualization	79%
Corneal infiltrate	5%

Table 2.
Percentage of presentation of common symptoms and signs in acute postoperative infectious endophthalmitis [4].

The endophthalmitis vitrectomy study (EVS) study reported positive cultures from 69.3% of biopsied cases using traditional agar plates and broth culture methods [13].

These conventional microbiology methods are commonly used for laboratory identification and antibiotic sensitivity tests of pathogens in APIE cases. Disadvantages of culture, include a low sensitivity and specificity for bacterial detection in the aqueous and vitreous humor, and are time-consuming [3, 4]. Nonetheless, whenever a minimal suspicion of infectious endophthalmitis exists, smear and culture are mandatory. Vitreous sample for culture gets a better yield than aqueous humour.

Disadvantages of lack of a microbiological confirmation in cases of APIE include non-response to IAI, increased morbidity from prolonged infection, repeated biopsies and IAI, and the potential to require performing more surgeries [4].

6. Polymerase chain reaction techniques and other novel methodologies for the diagnosis of acute postoperative endophthalmitis

Since the advent of PCR, molecular laboratory techniques have increased rapidly. Its use is part of many routine processing of clinical samples in microbiology laboratories, establishing a new era for diagnosing infectious diseases [17]. The use of PCR for APIE diagnosis increases significantly bacterial detection sensitivity and speed for etiologic diagnosis in vitreous and aqueous humors. The bacteria detection rate in aqueous and vitreous samples increased from approximately 48% to up to 95% using PCR techniques [17–21].

PCR and nested PCR protocols followed by post-PCR techniques such as RFLP (restriction fragment length polymorphism), DNA sequencing, and DNA-probe hybridization have all been utilized to improve the etiologic diagnosis of APIE [22, 23].

Reported sensitivities for bacterial identification in vitreous samples for several PCR techniques like nested PCR and real-time multiplex PCR are 84%, and 90–95%, respectively, although reported sensitivities vary among different publications [17].

Real-time PCR technology (RT-PCR) is a modification and enhancement of the PCR technique. It is a homogeneous technique in which DNA amplification and detection of the target sequence co-occur, decreasing PCR products’ handling and

risks of carryover contamination. Simultaneous DNA amplification and detection allow higher reliability as compared to other traditional multi-step techniques. One of the main advantages of real-time PCR technology is the rapid access to results, with microbial detection times of 30 to 50 minutes, compared to 1–14 days for previous PCR methods [18–21].

Green 16S rDNA–Based Universal PCR (SGRU-PCR) and a Multiplex Gram-Specific TaqMan–Based PCR (MGST-PCR) are useful for microorganism detection in many culture-negative samples. In one study, 90% were PCR positive among ten microbiologically negative samples, and five gave interpretable sequence data [17]. The pathogens identified included one coagulase-negative *Staphylococcus*, one *Moraxella spp.*, and two *Streptococcus mitis* group, all APIE causative bacteria. Sequencing of PCR-positive/culture-negative samples also included the identification of a *Proteus spp.* causing APIE, which is a rare causative microorganism in postoperative endophthalmitis [17].

Albeit being useful in APIE diagnosis, molecular identification of pathogen microorganisms remains an expensive technique. It is not available in many small cities, underdeveloped countries, laboratory settings, and in many instances, it requires a high workload that makes it inadequate for routine use. Furthermore, clinical definitions of some species do not match those used for 16S rRNA identification [17, 18].

Among another novel microbial detection methods that could eventually be used in the expedite diagnosis of APIE cases are Matrix-Assisted Laser Desorption Ionization–Time of Flight Mass Spectrometry (MALDI-TOF MS) [24, 25] and the utilization of magneto-DNA nanoparticle Dovepress system [26]. The latter method was reported to simultaneously identify up to thirteen species of bacteria in under two hours [26].

Bacterial recognition directly from samples and colonies using MALDI-TOF MS has been described as a revolutionary method that better adapts to the clinical microbiology laboratory. MALDI-TOF MS is used to identify bacterial species and to detect microorganisms previously misidentified [24]. Moreover, detection of antimicrobial resistance using MALDI-TOF MS has been reported for many bacteria, including *Escherichia coli* and *Staphylococcus aureus*. Another advantage of MALDI-TOF MS is that the time required for pathogen identification declines by 55-fold and 169-fold and the cost by 5-fold and 96-fold compared with culture and molecular gene sequencing, respectively [24, 25].

The Magneto-DNA nanoparticle Dovepress system is an assay that utilizes magnetic nanoparticles and oligonucleotide probes to detect target nucleic acids from the pathogen. Rather than sequencing the whole RNA strand, a series of primers and probes were established to amplify and detect specific regions of interest within common bacterial types. They used a miniaturized micro-nuclear magnetic resonance system that requires only small volumes of sample for processing for signal readout [26].

It is hypothesized that ribosomal RNA sequence information from microorganisms such as bacteria could be used in a robust magneto-DNA assay. Because this magnetic detection strategy allows near background-free sensing, the assay steps are greatly simplified, and detection is much faster [26].

7. Treatment of acute postoperative infectious endophthalmitis

7.1 Intravitreal antibiotics and other pharmacologic therapies

Initial and one of the mainstays of treatment for APIE include intravitreal antibiotic therapy [3–5, 12]. Treatment with IAI should be started empirically before

having any culture results. For many years, the EVS conclusions and recommended IAI had been a paradigm in APIE patients' care [4, 12]. Nonetheless, it is currently critical in most cases that clinical judgment should be used to determine treatment on a case-by-case basis. Moreover, first-line IAI recommendations have changed after EVS was published and, some authors have proposed vitrectomy as a concomitant treatment of IAI, for the treatment of APIE [27–29].

The EVS was a prospective, multicenter, randomized clinical trial evaluating the efficacy of immediate PPV and intravenous antibiotics to treat APIE. The EVS included endophthalmitis cases after cataract surgery. Patients were randomized to either vitrectomy or vitreous needle biopsy and intravenous antibiotics or no intravenous antibiotics [4, 13, 30]. The study endpoints were media clarity and best-corrected visual acuity. Patients received vancomycin and amikacin IAI. Furthermore, subconjunctival ceftazidime, vancomycin, dexamethasone, topical vancomycin, amikacin, cycloplegic, 1% topical prednisolone acetate and 30 mg bid of oral prednisone, for 5–10 days were prescribed as well [13, 30].

The EVS conclusions included no difference in final vision or media clarity whether or not intravenous antibiotics were used. In addition, patients with light perception visual acuity who received PPV had a three-fold increment in the probability of achieving 20/40, and a 50% reduction in the probability of severe visual loss than patients receiving only vitreous needle biopsy [13].

Patients with hand-motions or better vision showed no significant difference in final best-corrected visual acuity or media clarity whether or not an early vitrectomy was performed.

IAI recommendations have changed over the years. Initial treatment includes mainly intravitreal, as well as oral and topical antibiotics. Currently, two antibiotics are recommended by most retina specialists as first-line IAI treatment for APIE:

- Vancomycin (1 mg in 0.1 ml), and
- Ceftazidime (2.5 mg in 0.1 ml) [4, 11].

Vancomycin and/or amikacin are considered as intravitreal antibiotics alternatives in cases of cephalosporin allergy and/or the presence of ceftazidime resistant Gram-negative strains. Vancomycin has an excellent Gram-positive coverage despite isolated reports of resistance (**Table 3**) [4].

For fungal APE cases, voriconazole, 50–100 µg/0.1 ml, and amphotericine B, 5–10 µg/0.1 ml are described as first-line treatments.

Ceftazidime has emerged as first-line treatment for Gram-negative organisms due to its safer profile than amikacin. Another advantage of ceftazidime is that it may show synergy with vancomycin against gram-positive organisms [4, 12]. Oral, subconjunctival, and systemic antibiotics are used as adjuvant therapy in some hospital settings, although there is little or no evidence of their clinical effectiveness [3, 12]. Among all systemic antibiotics, ciprofloxacin is a first-generation fluoroquinolone that has been routinely used in APIE due to adequate ocular penetration and low side effect profile [4].

Third- and fourth-generation fluoroquinolones have shown a better Gram-positive coverage than ciprofloxacin while maintaining an adequate level of Gram-negative activity. Moxifloxacin has the most potent in vitro activity against Gram-negative and Gram-positive endophthalmitis pathogens [3–5]. It has been used as an intracameral antibiotic for cataract surgery prophylaxis, and there has been a three-fold decline in endophthalmitis rates with its use in phacoemulsification surgery. It is increasingly being used as an alternative intravitreal antibiotic for APIE cases [31]. Furthermore, moxifloxacin has also exhibited adequate ocular

Antimicrobial	Name	Class of drugs	Intravitreal dose
Antibiotics	Vancomycin*	Glycopeptide	1 mg/0.1 ml
	Ceftazidime*	Cephalosporin	2.25mgs/0.1 ml
	Amikacin	Aminoglycoside	0.4 mgs/0.1 ml
Antifungals	Voriconazole	Azol	50–100 µg/0.1 ml
	Amphotericine B	Polyene	5–10 µg/0.1 ml

*Vancomycin and ceftazidime are used as first-line treatment of acute postoperative endophthalmitis.

Table 3.
*Intravitreal antibiotics used for the management of acute postoperative infectious endophthalmitis [5].
Intravitreal injections of vancomycin and ceftazidime are currently recommended as first-line treatment in acute postoperative endophthalmitis.*

penetration after systemic administration, with vitreous levels above minimum inhibitory concentration (MIC₉₀) for most bacteria [32].

Vitreous moxifloxacin pharmacokinetics have shown in several studies comparable bioavailability characteristics to ciprofloxacin, with reasonable safety [4, 5, 32]. Moreover, cases of vancomycin-resistant bacteria have been reported to respond adequately to intravitreal injection of moxifloxacin [4, 5, 32].

Linezolid is an oxazolidinone-class antibiotic that the FDA approved in 2000 [5, 33, 34]. It has excellent bioavailability when administered orally, and intra-ocular levels can reach therapeutic levels within one hour of being administered. Linezolid provides mainly gram-positive coverage [5, 33]. If Gram-positive organisms have shown resistance to vancomycin, it might be reasonable to supplement with oral linezolid, and likewise, oral ciprofloxacin or moxifloxacin may increase the antimicrobial properties of intravitreal ceftazidime [5, 33]. Other IAI used in animal models or humans for endophthalmitis include quinupristin-dalfopristin [5, 34–37], daptomycin [5, 38–40], tygeciline [5, 41], imipenem [5], among others [42, 43]. New antifungals for APIE, include miconazole, caspofungin, and micafungin [5]. In **Table 4**, some of the antibiotics that have been used in endophthalmitis are summarized.

Another debated topic in APIE treatment is the use of steroid therapy. Experimental endophthalmitis animal models have shown that the degree of retinal tissue damage is partly secondary to the elicited severe inflammatory response in the eye [4]. Hence, it is appropriate to address this issue besides the use of antimicrobial therapy, and aggressive steroid therapy should be prescribed in APIE patients, which include topical 1% prednisolone acetate as frequently as every hour as well as oral steroids [3, 4, 44]. Cycloplegic topical medication such as 1% atropine, BID should be prescribed as well, to help decrease pain.

Controversy, however, still prevails regarding the use of intravitreal steroids in APIE. Some authors reported an improvement in inflammation and final visual results with intravitreal injection of steroids and antibiotics, whereas other studies have described worse inflammation and worse visual outcomes [44]. Histopathology reports have also shown contradictory outcomes for intravitreal steroids. In addition, intravitreal triamcinolone has been shown a favorable effect for APIE when combined with IAI in some reports [44].

Dexamethasone implants have been approved for use in several forms of uveitis, which has led to evaluate their possible use in endophthalmitis patients. Moisseiev et al. [45] reported APIE patients treated with immediate intravitreal dexamethasone at the time of vitreous tap. Compared to a group without steroid use, a trend towards the reduced need for antibiotic re-injection was observed in the steroid group. Currently, intravitreal dexamethasone recommended dose is 400 µg in 0.1 ml.

Microorganism	Name of drug	Class of drug	Intravitreal dose
Gram positive	Linezolid	Oxazolidinone	300 µg/0.1 ml
	Quinupristine-dalfopristine	Streptogramin	0.4 mg/0.1 ml
	Daptomycin	Cyclic lipoglycopeptide	200 µg/0.1 ml
	Tigecycline	Glycylcycline	0.5–0.1 mg/0.1 ml
	Piperacillin/tazobactam	Ureidopenicillin/β-lactamase inhibitor	250 µg/0.1 ml
Gram negative	Imipenem	Carbapenem	50 µg/0.1 ml
	Ciprofloxacin	Fluoroquinolone	0.1 mg/0.1 ml
	Levofloxacin	Fluoroquinolone	0.1 ml 0.5% solution
	Moxifloxacin*	Fluoroquinolone	0.2 mg/0.1 ml
Fungi	Miconazole	Azole	25 µg/0.1 ml
	Caspofungin	Echinocandin	50 µg/0.1 ml
	Micafungin	Echinocandin	0.025 mg/0.1 ml

* Moxifloxacin is increasingly being used as part of APIE prophylaxis and as alternative intravitreal antibiotic in acute postoperative endophthalmitis cases [5, 30].

Table 4.
Main alternative antibiotics for potential use in the management of endophthalmitis caused by resistant microorganisms to standard IAI. Evidence of their use comes from case reports and case series in humans and animal models.

7.2 Vitrectomy for postoperative endophthalmitis

The EVS concluded that early vitrectomy in endophthalmitis was only beneficial in patients with visual acuity of light perception or worse [13]. Hence, delaying vitrectomy in APIE patients with a better presenting vision has been a common practice among retina specialists. Nonetheless, there is still debate on the adequate timing to perform vitrectomy in APIE patients.

The methods and results of EVS may not reflect modern surgery practice patterns. Furthermore, with the advent of more refined surgical techniques in recent years like minimally-invasive vitrectomy surgery (MIVS), which entail a lower complication rate compared to conventional vitrectomy, the EVS study’s conclusions are possibly obsolete. Currently, performing both vitrectomy and IAI as first-line treatments might be more beneficial for many APIE cases [6, 7, 27–29, 46].

In many hospital settings, vitrectomy is usually performed in those APIE patients that do not respond to an initial dose of IAI. In these patients, repeating IAIs instead of performing PPV is likely to be of little benefit. Persisting levels of vitreous antibiotic above MIC₉₀ for three days or more after IAI and repeating the same agents after 2–3 days may be deleterious to the eye due to an increased risk of retina toxicity. In addition, some authors [47] have hypothesized that bacterial sequestering or biofilm production might reduce the bacteria’s sensitivity to IAI; furthermore, vitrectomy might help remove the bacterial load and increase antibiotic bioavailability in the vitreous cavity.

Peyman et al. were the first to report the use of early vitrectomy in endophthalmitis patients [48]. Cases underwent vitrectomy 24 hours after diagnosis, 65% achieving a final visual acuity of 20/400 or better.

The EVS evaluated the early vitrectomy role and contrasted immediate vitrectomy within six hours of diagnosis against inject-only as subgroups. Only core vitrectomy was performed on the included patients. While no advantage for

performing PPV was found unless vision was light perception or worse, no disadvantage in the final visual outcome was found in performing vitrectomy [13].

Moreover, the induction of a posterior hyaloid separation and a complete vitrectomy were usually avoided in the EVS. Contrary to the EVS methods, some reports suggest that removing the posterior hyaloid and using silicone oil as a tamponade in APIE patients could improve anatomic and visual outcomes [13].

Kuhn et al. [46] described a series of patients who underwent early vitrectomy for endophthalmitis with a more thorough surgical vitrectomy and found no rhegmatogenous detachment cases. Ninety one percent of the cases had a final vision of 20/40 or better, contrary to 53% in the EVS study group. They postulated that removing the posterior vitreous cortex may remove the toxic load from proximity to the macula. Other case series have reached similar conclusions [6, 7, 27–29].

Current vitrectomy techniques include 23 Ga, 25 Ga, or 27 Ga MIVS rather than conventional 20 Ga techniques. In addition, some key points should be considered while performing vitrectomy in APIE patients:

First, because the media is frequently hazy for the surgeon to visualize a pars plana port, an infusion cannula sometimes cannot be used for the initial stages of the operation. It is advisable to place an inferotemporal port, reserving its use later in the procedure, once the tip's location in the vitreous cavity can be verified. Alternatively, an anterior chamber maintainer could be placed.

Second, opacities such as hypopyon and pupillary membranes should be aspirated from the anterior segment. Often, because of poor dilation of the pupil and visualization of the internal structures, the lens in phakic eyes must be removed. If the cornea remains too cloudy due to bacterial infiltration and inflammation, and it does not allow adequate visualization of the vitreous cavity, the use of keratoprosthesis should sometimes be considered.

Third, separation of the posterior hyaloid besides core vitrectomy should be attempted in some APIE cases. Some authors [46] have described performing complete vitrectomy to help decrease inflammatory cells and bacterial loads. It can be achieved with current vitrectomy systems, using high-cutting rates and low-flow to lessen the retina traction while removing vitreous strands, thus minimizing the risk of iatrogenic retinal breaks, as well. Nonetheless, caution should still prevail in performing peripheral vitrectomy, and posterior hyaloid separation in cases where the retina appears too necrotic since the risk of formation of retinal tears may increase in this scenario.

Video 1 (<https://youtu.be/Q0ILB4Ozkoc>) shows an APIE case where hypopyon aspiration, core and peripheral 23 Ga PPV, as well as posterior hyaloid separation were performed.

Fifth, the use of silicone oil as a tamponade has been shown to have a bactericidal effect in vitro and may be worth considering in the context of performing PPV in APIE patients, especially if retinal tamponade is also required in cases of retinal detachment. However, silicone oil's bactericidal effect has been challenging to prove in vivo [4, 6, 7, 27–29].

Another recently described surgical technique for endophthalmitis is endoscopic vitrectomy that uses an endoscopic probe inserted via pars plana to improve visualization in the vitreous cavity, identify intraocular structures, and avoid iatrogenic damage performing a PPV [49]. It has the advantage that it does not require clear anterior media, which is frequently compromised in endophthalmitis patients. It does not require waiting for media clearing, which carries an additional risk of tissue damage due to the infection and severe inflammation processes. Disadvantages of endoscopic vitrectomy include the steep curve for re-learning vitrectomy via an endoscope probe.

If an early vitrectomy is performed because of initial non-response to IAI or removing inflammatory debris, it is common to inject antibiotics concomitantly into the vitreous cavity. Antibiotics can be injected at the end of the vitrectomy or via the diluted solution infused into the vitreous cavity throughout the vitrectomy procedure.

The patient may be left with saline solution, air, gas, or silicone oil as tamponade. It is of the utmost relevance to consider that the volume of water-based fluid in the eye dictates the antibiotic's amount and concentration [4, 6, 7, 27–29, 46]. This is because high antibiotic levels present in the remaining meniscus of aqueous fluid may increase toxicity risk to the retinal tissue that may eventually induce further vision loss. Therefore, it is essential to consider injecting a third or fourth of the recommended intravitreal antibiotic dose in patients with gas or silicone oil-filled eyes to obtain an antibiotic's adequate concentration, as the concentration of the antibiotic changes in the small meniscus of aqueous fluid that will remain in the vitreous cavity.

Alternatively, antibiotic could be diluted at the proper concentration in the irrigation solution that enters the vitreous cavity, thus the remaining fluid will also have adequate antibiotic concentration. The antibiotic can be injected into the vitreous cavity before the tamponade [27–29, 46]. It may be necessary to position the patient face-down a few days after surgery to minimize macular exposure to antibiotics.

Some authors have described the successful use of infused vancomycin throughout vitrectomy at different concentrations. This approach might expose the retinal tissue to a more constant antibiotic level than an intravitreal injection. Nevertheless, it also may have the risk of using sub-therapeutic concentrations of the antibiotic [27].

7.3 Endophthalmitis prophylaxis

The single most effective prophylaxis of endophthalmitis includes preoperative application of 5% povidone-iodine (PI) conjunctival surface and cul-de-sac [50–53]. Bacteria have not developed resistance to PI, and PI is also effective against many microorganisms such as fungi and viruses. Several studies have proven the effectiveness of the aseptic technique and the use of PI in ophthalmological surgery. One report assessed the incidence of APIE over many years in the same hospital with the incorporation of PI, with no use of intraocular antibiotics. Over this time, the rate of APIE went from 0.38% to <0.03%. This rate is almost the same as the current studies looking into risk reduction using intracameral antibiotics [51].

Checking for lid infections like blepharitis, nasolacrimal duct obstruction, leaking wounds, and intracameral antibiotics like cefuroxime 1000 µg/0.1 ml or moxifloxacin at the end of the surgery, and the use topical postoperative antibiotics are some other measures that might decrease endophthalmitis incidence [3, 4].

A large study of eyes that underwent cataract surgery [54] showed that intracameral moxifloxacin declined postcataract surgery endophthalmitis incidence. Nonetheless, the routinary application of intracameral antibiotics has some risks, such as the development of resistant strains of pathogens, and retinal toxicity. For instance, hemorrhagic occlusive retinal vasculitis has been described after using intracameral vancomycin [53].

The most common causative bacteria in post intravitreal injections endophthalmitis are streptococci, common oral flora members. The use of masks and adhering to a strict no-talking policy has decreased post-injection endophthalmitis incidence.

Prompt surgical repair of open globe injuries and prophylactic IAI with or without systemic antibiotics have also been associated with reduced post-traumatic endophthalmitis incidence.

7.4 Other novel treatments and developments

Nakashizuka et al. [52] reported the safety and efficacy of 1.25% povidone-iodine (PI) intravitreal injection followed by vitrectomy using 0.025% irrigation to treat endophthalmitis. Most of the cases included in the study resolved rapidly, and good visual results were observed. No adverse events were reported. Moreover, the electrorretinogram (ERG) results showed increases in the oscillatory potentials amplitudes, flicker ERG and the a-wave's implicit time, suggesting the functional improvement in the retinal inner and outer layers after surgery. They concluded that intravitreal injection of PI followed by PPV was thought to be an effective and safe therapy for APIE. Other authors have reported similar findings [52, 53].

Other novel therapies under investigation for APIE include the development of microdevices such as biomimetic nanosponge to treat endophthalmitis caused by virulent pathogens such as *Enterococcus faecalis* isolates. *Enterococcus faecalis* produces the pore-forming bicomponent cytolysin that adds to retinal tissue damage in endophthalmitis. LaGrow et al. [55] hypothesized that a biomimetic nanosponge, which imitates erythrocytes, could adsorb subunits of the cytolysin and decrease damage to the retina, preserving vision in endophthalmitis patients.

They reported that biomimetic nanosponges nullified cytolysin activity and protected the retinal tissue from damage. These outcomes indicate that this therapeutic option could guard eyes against the deleterious effects of pore-forming toxins of various aggressive ocular bacteria [55].

8. Prognosis of acute postoperative endophthalmitis

One of the most important predictors of final visual outcome is presenting visual acuity. Patients with presenting vision of light perception or worse may have worse outcomes [3, 4]. Therefore, prompt treatment of endophthalmitis cases is associated with improved visual acuity outcomes. Prompt initiation of therapy is more important than any other factor, including PPV versus vitreous tap or the use of adjunctive systemic antibiotics.

Other predictors of worse visual outcomes include DM, older age, corneal infiltrate, high or low intraocular pressure, rubeosis iridis, an absent red reflex, and an open posterior capsule. Dense vitreous opacities, and vitreous membranes, retinal detachment, are also associated with a more unsatisfactory visual outcome [4].

9. Conclusions

Although many breathtaking advances have been described and applied for APIE treatment, further measures and prophylactic strategies are needed to decrease the incidence and improve the prognosis of this devastating complication of intraocular surgery.

Novel molecular biology techniques like RT-PCR have been developed to aid in the etiologic diagnosis of endophthalmitis, which has improved and expedited APIE patients' antibiotic treatment.

Advances in vitreoretinal surgery techniques such as the advent of MIVS and other improvements in vitrectomy systems have changed our way of thinking about early vitrectomy in the treatment of these patients.

However, controversy still prevails on many issues, such as the role of steroid use, vitrectomy timing, and the incorporation of other innovative diagnostic and therapeutic modalities for APIE.

Conflict of interest

The authors have no conflicts of interest to declare.

Nomenclature

Anti-VEGF	Anti-Vascular Endothelial Growth Factor
APIE	Acute Postoperative Infectious Endophthalmitis
DM	Diabetes Mellitus
EVS	Endophthalmitis Vitrectomy Study
ERG	Electroretinogram
IAI	Intravitreal Antibiotic Injection
MIVS	Minimally-invasive Vitrectomy Surgery
MGST-PCR	Multiplex Gram-Specific TaqMan–Based PCR
PCR	Polymerase Chain Reaction
RT-PCR	Real-Time Polymerase Chain Reaction
SGRU-PCR	Green 16S rDNA–Based Universal PCR
PPV	Pars Plana Vitrectomy
PI	Povidone-Iodine

Author details

Sergio E. Hernandez-Da Mota^{1*}, Jose Luis Guerrero-Naranjo²,
Jose Dalma-Weiszhausz², Raul Velez-Montoya² and Jesus H. Gonzalez-Cortes³

1 Retina Department, David Clinic and Michoacan University School of Medicine
“Dr. Ignacio Chavez”, Morelia, Mexico

2 “Dr. Luis Sanchez Bulnes” Hospital, APEC, National Autonomous University of
Mexico (UNAM), Mexico City, Mexico

3 Ophthalmology Department, Dr. Jose Eleuterio Gonzalez University Hospital,
Autonomous University of Nuevo Leon, Monterrey, Mexico

*Address all correspondence to: tolodamota@yahoo.com.mx

IntechOpen

© 2021 The Author(s). Licensee IntechOpen. This chapter is distributed under the terms of the Creative Commons Attribution License (<http://creativecommons.org/licenses/by/3.0>), which permits unrestricted use, distribution, and reproduction in any medium, provided the original work is properly cited. 

References

- [1] Schwartz SG, Flynn HW Jr, Das T, Mieler WF. Ocular Infection: Endophthalmitis. *Dev Ophthalmol*. 2016;55:176-88. DOI: 10.1159/000431195
- [2] Packer M, Chang DF, Dewey SH, Little BC, Mamalis N, Oetting TA, Talley-Rostov A, Yoo SH; ASCRS Cataract Clinical Committee. Prevention, diagnosis, and management of acute postoperative bacterial endophthalmitis. *J Cataract Refract Surg*. 2011;37:1699-714. DOI: 10.1016/j.jcrs.2011.06.018
- [3] Meredith TA, Ulrich JN. Infectious endophthalmitis. In: Wilkinson CP, Hinton DR, Sadda SR, Wiedemann P, editors. *Ryan's Retina*. 6th ed. Amsterdam:Elsevier; 2018. p. 2266-2281.
- [4] Eichenbaum DA, Park RI, Topping TM. Postoperative endophthalmitis. In: Steinert RF, editor. *Cataract surgery*. 3rd ed. Saunders-Elsevier; 2010. p. 671-680.
- [5] Relhan N, Pathengay A, Schwartz SG, Flynn HW. Emerging Worldwide Antimicrobial Resistance, Antibiotic Stewardship and Alternative Intravitreal Agents for the Treatment of Endophthalmitis. *Retina*. . 2017;37:811-818. DOI: 10.1097/IAE.00000000000001603
- [6] Relhan N, Forster RK, Flynn HW Jr. Endophthalmitis: Then and Now. *Am J Ophthalmol*. 2018;187:20-27. DOI: 10.1016/j.ajo.2017.11.021
- [7] Clarke B, Williamson TH, Gini G, Gupta B. Management of bacterial postoperative endophthalmitis and the role of vitrectomy. *Surv Ophthalmol*. 2018;63:677-693. DOI: 10.1016/j.survophthal.2018.02.003
- [8] Gedde SJ, Herndon LW, Brandt JD, Budenz DL, Feuer WJ, Schiffman JC, Tube Versus Trabeculectomy Study Group. Postoperative complications in the tube versus trabeculectomy (TVT) study during five years of follow up. *Am J Ophthalmol*. 2012;153:804-814. DOI:10.1016/j.ajo.2011.10.024
- [9] Olayanju JA, Hassan MB, Hodge DO, Khanna CL. Trabeculectomy related complications in Olmsted County, Minnesota, 1985-2010. *JAMA Ophthalmol*. 2015;133 (5):574-580. DOI:10.1001/jamaophthalmol.2015.57
- [10] Borkar DS, Wibbelsman TD, Buch PM, Rapuano SB, Obeid A, Ho AC, et al. Endophthalmitis Rates and Clinical Outcomes Following Penetrating and Endothelial Keratoplasty. *Am J Ophthalmol*. 2019;205:82-90. DOI: 10.1016/j.ajo.2019.05.004.
- [11] Cao H, Zhang L, Li L, Lo S. Risk factors for acute endophthalmitis following cataract surgery: A systematic review and meta-analysis. *PLoS One*. 2013;8(8):e71731. DOI:10.1371/journal.pone.0071731
- [12] Rahmani S, Elliott D. Postoperative Endophthalmitis: A Review of Risk Factors, Prophylaxis, Incidence, Microbiology, Treatment, and Outcomes. *Review Semin Ophthalmol*. 2018;33:95-101. DOI: 10.1080/08820538.2017.1353826
- [13] Han DP, Wisniewski SR, Wilson, Barza M, Vine AK, Doft BH, Kelsey SF. Spectrum and susceptibilities of microbiologic isolates in the Endophthalmitis Vitrectomy Study, *Am J Ophthalmol*. 1996; 122:1-17. DOI: 10.1016/s0002-9394(14)71959-2
- [14] O'Callaghan RJ. The Pathogenesis of *Staphylococcus aureus* Eye Infections. *Pathogens*. 2018;7:9. DOI: 10.3390/pathogens7010009

- [15] Astley R, Miller FC, Mursalin MH, Coburn PS, Callegan MC. An Eye on Staphylococcus aureus Toxins: Roles in Ocular Damage and Inflammation. *Toxins (Basel)*. 2019;11:356. DOI: 10.3390/toxins11060356
- [16] Choi JA, Chung SK. Postoperative Endophthalmitis following Cataract Surgery in Asia. *ISRN Ophthalmol*. 2011;2011:917265. DOI: 10.5402/2011/917265
- [17] Cornut PL, Boisset S, Romanet JP, Maurin M, Carricajo A, Benito Y, Vandenesch F, Chiquet C. Principles and applications of molecular biology techniques for the microbiological diagnosis of acute postoperative endophthalmitis. *Surv Ophthalmol*. 2014;59:286-303. DOI: 10.1016/j.survophthal.2013.08.002
- [18] Ogawa M, Sugita S, Shimizu N, Watanabe K, Nakagawa I, Mochizuki M. Broad-range real-time PCR assay for detection of bacterial DNA in ocular samples from infectious endophthalmitis. *Jpn J Ophthalmol*. 2012; 56:529-535. DOI: 10.1007/s10384-012-0174-z
- [19] Bispo PJM, de Melo GB, Hoing-Lima AL, Pignatari ACC. Detection and gram discrimination of bacterial pathogens from aqueous and vitreous humor using real-time PCR assays. *Invest Ophthalmol Vis Sci*. 2011;52:873-881. DOI: 10.1167/iovs.10-5712
- [20] Ogawa M, Sugita S, Watanabe K, Shimizu N, Mochizuki M. Novel diagnosis of fungal endophthalmitis by broad-range real-time PCR detection of fungal 28S ribosomal DNA. *Graefes Arch Clin Exp Ophthalmol*. 2012;250:1877-1883. DOI: 10.1007/s00417-012-2015-7
- [21] Sugita S, Kamoi K, Ogawa M, Watanabe K, Shimizu N, Mochizuki M. Detection of Candida and Aspergillus species DNA using broad-range real-time PCR for fungal endophthalmitis. *Graefes Arch Clin Exp Ophthalmol*. 2012;250:391-398. DOI: 10.1007/s00417-011-1819-1
- [22] Nandi K, Ranjan P, Therese L, Biswas J. Polymerase chain reaction in intraocular inflammation. *Open Ophthalmol J*. 2008;2:141-5. DOI: 10.2174/1874364100802010141
- [23] Biwas J, Bagyalakshmi R, Therese LK. Diagnosis of Aspergillus fumigatus endophthalmitis from formalin fixed paraffin-embedded tissue by polymerase chain reaction-based restriction fragment length polymorphism. *Indian J Ophthalmol*. 2008;56:65-6. DOI: 10.4103/0301-4738.37600
- [24] Lacroix C, Gicquel A, Sendid B, Meyer J, Accoceberry I, François N, Morio F, Desoubeaux G, Chandenier J, Kauffmann-Lacroix C, Hennequin C, Guitard J, Nassif X, Bougnoux ME. Evaluation of two matrix-assisted laser desorption ionization-time of flight mass spectrometry (MALDI-TOF MS) systems for the identification of Candida species. *Clin Microbiol Infect*. 2014;20:153-158. DOI: 10.1111/1469-0691.12210
- [25] Seng P, Abat C, Rolain JM, Colson P, Lagier JC, Gouriet F, Fournier PE, Drancourt M, La Scola B, Raoult D. Identification of rare pathogenic bacteria in a clinical microbiology laboratory: impact of MALDI-TOF mass spectrometry. *J Clin Microbiol*. 2013;51:2182-2194. DOI: 10.1128/JCM.00492-13. DOI: 10.1128/JCM.00492-13
- [26] Chung HJ, Castro CM, Im H, Lee H, Weissleder R. A magneto-DNA nanoparticle system for rapid detection and phenotyping of bacteria. *Nat Nanotechnol*. 2013;8:369-375. DOI: 10.1038/nnano.2013.70

- [27] Clarke B, Williamson TH, Gini G, Gupta B. Management of bacterial postoperative endophthalmitis and the role of vitrectomy. *Surv Ophthalmol*. 2018;63:677-693. DOI: 10.1016/j.survophthal.2018.02.003
- [28] Park JC, Ramasamy B, Shaw S, Ling RH, Prasad S. A prospective and nationwide study investigating endophthalmitis following pars plana vitrectomy: Clinical presentation, microbiology, management and outcome. *Br J Ophthalmol*. 2014;98:1080-1086. DOI:10.1136/bjophthalmol-2013-304486
- [29] Grzybowski A, Turczynowska M, Kuhn F. The treatment of postoperative endophthalmitis: should we still follow the endophthalmitis vitrectomy study more than two decades after its publication? *Acta Ophthalmol*. 2018;96:e651-e654. DOI: 10.1111/aos.13623
- [30] Doft BH, Barza M. Optimal management of postoperative endophthalmitis and results of the Endophthalmitis Vitrectomy Study. *Curr Opin Ophthalmol*. 1996;7:84-94. DOI: 10.1097/00055735-199606000-00015
- [31] Haripriya A, Baam ZR, Chang DF. Endophthalmitis Prophylaxis for Cataract Surgery. *Asia Pac J Ophthalmol (Phila)*. 2017;6:324-329. DOI: 10.22608/APO.2017200
- [32] Sharma T, Kamath MM, Kamath MG, Nayak RR, Bairy KL, Musmade PB. Aqueous penetration of orally and topically administered moxifloxacin. *Br J Ophthalmol*. 2015;99:1182-5. DOI: 10.1136/bjophthalmol-2014-306502
- [33] Duke SL, Kump LI, Yuan Y, et al. The safety of intraocular linezolid in rabbits. *Invest Ophthalmol Vis Sci*. 2010;51:3115-3119. DOI: 10.1167/iovs.09-4244
- [34] Babalola OE. Intravitreal linezolid in the management of vancomycin-resistant enterococcal endophthalmitis. *Am J Ophthalmol Case Rep*. 2020;20:100974. DOI: 10.1016/j.ajoc.2020.100974
- [35] Hernandez-Da Mota SE. Quinupristin/dalfopristin in *Staphylococcus aureus* endophthalmitis: a case report. *J Med Case Rep*. 2011;5:130. DOI: 10.1186/1752-1947-5-130
- [36] Stroh EM. Quinupristin/dalfopristin in vancomycin-resistant *Staphylococcus aureus* endophthalmitis. *Arch Ophthalmol* 2012;130:1323-1324. DOI: 10.1001/archophthalmol.2012.1504
- [37] Giordano VE, Hernandez-Da Mota SE, Adabache-Guel TN, Castillejos-Chevez A, Corredor-Casas S, Salinas-Longoria SM, Romero-Vera R, Jimenez-Sierra JM, Guerrero-Naranjo JL, Morales-Canton V. Safety of intravitreal quinupristin/dalfopristin in an animal model. *Int J Ophthalmol* 2016;9:373-378. DOI: 10.18240/ijo.2016.03.08
- [38] Buzzacco DM, Carroll CP. Intravitreal daptomycin in a case of bilateral endogenous endophthalmitis. *Arch Ophthalmol* 2012;130:940-941. DOI: 10.1001/archophthalmol.2011.2527
- [39] Sim JM, Kapoor KG, Wagner AL. Intravitreal daptomycin for recalcitrant postoperative endophthalmitis. *Case Rep Ophthalmol* 2016;7:103-107. DOI: 10.1159/000444046
- [40] Comer GM, Miller JB, Schneider EW, Khan NW, Reed DM, Elner VM, Zacks DN. Intravitreal daptomycin: a safety and efficacy study. *Retina* 2011;31:1199-1206. DOI: 10.1097/IAE.0b013e318207d1b9
- [41] Horozoglu F, Metan G, Sever O, Percin D, Topal CS, Gonen T,

- Keskinbora KH, Topcu B, Yanyali A. Intravitreal tigecycline treatment in experimental *Acinetobacter baumannii* endophthalmitis. *J Chemother* 2012;24:101-106. DOI: 10.1179/1120009X12Z.000000000018
- [42] Aziza Y, Kodrat E, Saharman YR, Setiabudy R, Susiyanti M, Sjamsoe S. Efficacy of intravitreal Levofloxacin 0.5% ophthalmic solution in treating *Pseudomonas aeruginosa* endophthalmitis on a rabbit model. *Asia Pac J Ophthalmol (Phila)* 2013;2:199-205. DOI: 10.1097/APO.0b013e3182970cc9
- [43] Ozkiriş A, Evereklioglu C, Eşel D, Akgün H, Erkiliç K. The efficacy of intravitreal piperacillin/tazobactam in rabbits with experimental *Staphylococcus epidermidis* endophthalmitis: a comparison with vancomycin. *Ophthalmic Res.* 2005;37:168-74. DOI: 10.1159/000086074.
- [44] Ching Wen Ho D, Agarwal A, Lee CS, Chhablani J, Gupta V, Khatri M, Nirmal J, Pavesio C, Agrawal R. A Review of the Role of Intravitreal Corticosteroids as an Adjuvant to Antibiotics in Infectious Endophthalmitis. *Ocul Immunol Inflamm.* 2018;26:461-468. DOI: 10.1080/09273948.2016.1245758
- [45] Moisseiev E, Abbassi S, Park SS. Intravitreal dexamethasone in the management of acute endophthalmitis: a comparative retrospective study. *Eur J Ophthalmol.* 2017;27:67-73. DOI: 10.5301/ejo.5000866.
- [46] Kuhn F, Gini G. Vitrectomy for endophthalmitis. *Ophthalmology.* 2006;113:714. DOI: 10.1016/j.opthta.2006.01.009
- [47] Leung EH, Gibbons A. Environmental, Local, and Systemic Endophthalmitis Prophylaxis for Cataract Surgery. *Int Ophthalmol Clin.* 2020;60:113-126. DOI: 10.1097/IIO.0000000000000327
- [48] Peyman GA, Rose M, Sanders D. Intravitreal antibiotic injection and vitrectomy in acute bacterial endophthalmitis. *Can J Ophthalmol.* 1976;11:188-90.
- [49] Dave VP, Pappuru RR, Tyagi M, Pathengay A, Das T. Endoscopic vitrectomy in endophthalmitis: initial experience of 33 cases at a tertiary eye care center. *Clin Ophthalmol.* 2019;13:243-251. DOI: 10.2147/OPTH.S185716
- [50] Otani K, Shimada H, Nakashizuka H, Okubo H Capsular bag irrigation using 0.025% povidone-iodine in balanced salt solution PLUS for the treatment of postoperative endophthalmitis. *Int Ophthalmol.* 2018;38:1787-1790. DOI: 10.1007/s10792-017-0645-9
- [51] Shimada H, Hattori T, Mori R, Nakashizuka H, Fujita K, Yuzawa M. Minimizing the endophthalmitis rate following intravitreal injections using 0.25% povidone-iodine irrigation and surgical mask. *Graefes Arch Clin Exp Ophthalmol.* 2013;251:1885-90. DOI: 10.1007/s00417-013-2274
- [52] Nakashizuka H, Shimada H, Hattori T, Noguchi T, Kokubo N, Yuzawa M. Vitrectomy using 0.025% povidone-iodine in balanced salt solution plus for the treatment of postoperative endophthalmitis. *Retina.* 2015;35:1087-94. DOI: 10.1097/IAE.0000000000000634
- [53] Grzybowski A, Schwartz SG, Matsuura K, Ong Tone S, Arshinoff S, Ng JQ, et al. Endophthalmitis Prophylaxis in Cataract Surgery: Overview of Current Practice Patterns Around the World. *Curr Pharm Des.* 2017;23:565-573. DOI: 10.2174/1381612822666161216122230
- [54] Melega MV, Alves M, Cavalcanti Lira RP, Cardoso da Silva I, Ferreira BG, Assis Filho HL, et al. Safety and efficacy

of intracameral moxifloxacin for
prevention of post-cataract
endophthalmitis: Randomized
controlled clinical trial. J Cataract
Refract Surg. 2019;45:343-350. DOI:
10.1016/j.jcrs.2018.10.044

[55] LaGrow AL, Coburn PS, Miller FC,
Land C, Parkunan SM, Luk BT, Gao W,
Zhang L, Callegan MC. A Novel
Biomimetic Nanosponge Protects the
Retina from the *Enterococcus faecalis*
cytolysin. mSphere. 2017;2:e00335-17.
DOI: 10.1128/mSphere.00335-17