

We are IntechOpen, the world's leading publisher of Open Access books Built by scientists, for scientists

6,900

Open access books available

186,000

International authors and editors

200M

Downloads

Our authors are among the

154

Countries delivered to

TOP 1%

most cited scientists

12.2%

Contributors from top 500 universities



WEB OF SCIENCE™

Selection of our books indexed in the Book Citation Index
in Web of Science™ Core Collection (BKCI)

Interested in publishing with us?
Contact book.department@intechopen.com

Numbers displayed above are based on latest data collected.
For more information visit www.intechopen.com



Fundamentals of the Currently Available Single Port Abdominal Laparoscopic Gynecologic Systems and Utility in Minor Gynecologic Surgery

M. Luann Racher and Ann Marie Mercier

Abstract

Single incision laparoscopic surgery encompasses a plethora of techniques and styles. Single incision laparoscopy has demonstrated outcomes comparable to traditional multiport laparoscopy with the added benefit of improved cosmesis. This book chapter will review single incision surgery for minor gynecologic surgery, including adnexal surgical procedures and myomectomy. The chapter reviews available data in regard to outcomes in single incision laparoscopy. It also discusses the commercially available single incision surgical access systems, laparoscopes, and accessory instruments. Surgical techniques beneficial in single incision laparoscopy, including uterine manipulation, are also reviewed.

Keywords: single port, laparoscopy, SILS, LESS, single incision, minimally invasive, gynecology

1. Introduction

Single incision laparoscopic surgery encompasses a plethora of techniques and styles. Multiple names have been used to describe similar surgical techniques, including single incision laparoscopy (SILS), single port access surgery (SPA), laparoscopic endoscopic single site surgery (LESS), single laparoscopic incision transabdominal (SLIT), one-port umbilical surgery (OPUS), and natural orifice transluminal endoscopic surgery (NOTES). The purpose of this chapter is to review single incision surgery in minor gynecologic surgery and discuss currently available single incision surgical access systems, accessory instruments and surgical techniques in single incision gynecologic surgery.

2. Use of single port abdominal laparoscopy in minor gynecologic surgery

Female sterilization by tubal ligation was the first procedure performed by way of single incision laparoscopy in the late 1960s. Though gynecologists were the first

surgeons to perform SILS, the technique was more readily adopted by urologists in the 1990s [1]. Now, more than 40 years since its development, single incision laparoscopy has become widespread in gynecologic surgery. Minor gynecologic procedures that have been performed by single incision include, but are not limited to: diagnostic laparoscopy, tubal sterilization (by both occlusion and partial or complete salpingectomy), management of ectopic pregnancy, ovarian cystectomy, oophorectomy, ovarian detorsion, oophoropexy and myomectomy. Adnexal surgeries, especially oophorectomy and ovarian cystectomy, are the most commonly performed minor gynecologic SILS procedures [2–4].

Single incision laparoscopy has a greater degree of difficulty than multiport laparoscopy, mainly due to reduction of triangulation (**Figure 1a, b**). In multi-port laparoscopy, ports may be placed in a triangular formation in Ref. to the target organ. Generally, the central optical trocar is placed 10–15 cm away from the target organ and accessory ports are placed laterally along an arc maintaining a similar distance from the target organ. Instruments are then commonly introduced at a 60 degree angle. A wide angle of manipulation, ideally between 45 and 75 degrees, results in the most efficient movements from the surgeon. Triangulation also allows for the appropriate traction and countertraction necessary to retract, dissect, ligate, and suture during a multiport laparoscopic procedure [5, 6].

With a narrow angle of triangulation, as in single incision laparoscopy, ergonomics become more limited. Surgical techniques, advanced uterine manipulation, articulating or prebent instruments, and angled or flexible laparoscopes can improve surgical constraints, but the degree of technical difficulty remains higher in single incision laparoscopy. Cross-triangulation, or the crossing of surgical instruments, may improve triangulation constraints [5, 6].

Most authors agree that between 5 and 30 cases are required to establish proficiency in single incision laparoscopy. A multicenter analysis revealed a linear improvement in both entry and operating times for SILS cases, with the most substantial decrease (9.2 min to 4.8 min for abdominal entry and 79.4 min to 56.8 min for total operating time) after increasing procedure volume from 10 to 20 cases [6].

Based on available data, outcomes of single incision laparoscopy for minor gynecologic procedures are similar to multiport laparoscopy [1, 2, 4–30].

Abdominal access is often obtained more quickly with single incision laparoscopy, with one study demonstrating a near 50% shorter entry time for SILS. Operating times for adnexal surgery by way of SILS may be increased when compared to multi-port procedures. A meta-analysis of 3 randomized control trials

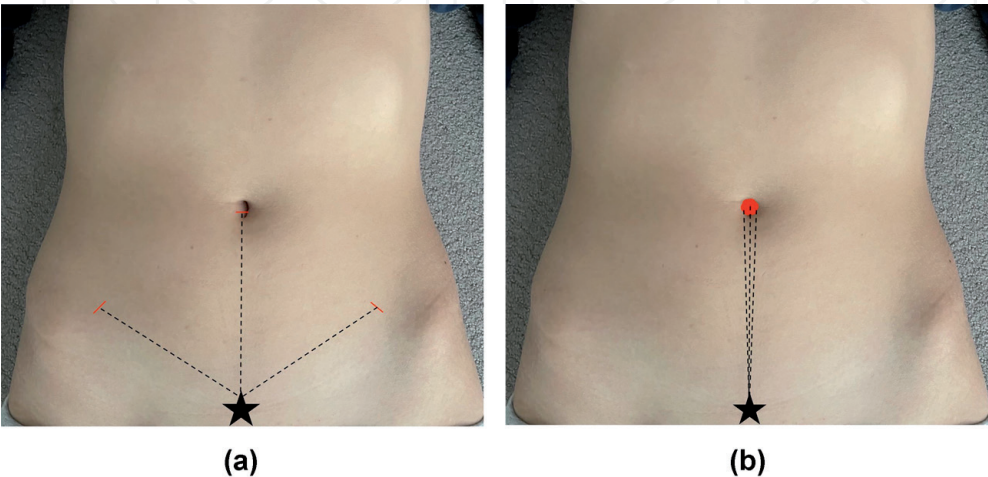


Figure 1.
(a) Triangulation in multiport laparoscopy. (b) Loss of triangulation with single incision laparoscopy.

(RCT) published in 2013 demonstrated an increase in operating time of 6.9 minutes for adnexal surgery performed via SILS [8]. A 2017 meta-analysis of 5 RCT found similar increases in operating time [2]. However, subsequent studies not included in these meta-analyses have shown operating time for SILS is not significantly different when compared to multiport laparoscopy [9]. Surgeon proficiency greatly impacts operating time, and has been demonstrated to improve in a linear fashion [6].

Intraoperative complications, such as bowel or vascular injury, blood loss, or conversion to laparotomy are similar. In the 2013 meta-analysis, 2.78% of SILS were converted to multi-port laparoscopy and 0.11% were converted to laparotomy. Of the multi-port laparoscopies, 0.5% were converted to laparotomy. The authors did not distinguish between hysterectomy and adnexal procedures [8]. In the 2017 meta-analysis, no adnexal SILS cases were converted to laparotomy [2]. Decline in hemoglobin on postoperative day 1 was similar in nearly all studies and was found to be statistically similar in the 2016 meta-analysis [4].

Postoperative pain has been found to be comparable in most studies [8–30]. Some have demonstrated less immediate postoperative pain (in recovery and at 6 and 12 hours postoperatively) when a single incision surgical approach is used. Others have also noted less use of postoperative analgesia after SILS. Meta-analyses have demonstrated no significant difference in postoperative pain between the two procedures [2, 4, 9]; however, minor gynecologic surgery, especially adnexal procedures, is generally not associated with a high amount of postoperative pain.

Length of hospital stay is comparable for both types of laparoscopy. Given that the length of the average hospital stay for minor gynecologic surgery is already short, significant improvement is difficult to demonstrate. Resumption of normal postoperative activity is also similar [2, 4, 8].

Patient reported satisfaction with cosmetic results is most often higher with single incision laparoscopy, although some studies have reported no significant difference [8–30]. One analysis conducted by Bush et al. in 2011 revealed that when presented with three illustrations of the placement of port sites - traditional multi-port placement, umbilical SILS, and robotic port placement - over 56% of the 241 female respondents preferred the traditional multiport trocar placement over the SILS ($p = .007$). Importantly, the illustration of single incision laparoscopy denoted a 2.5 cm umbilical incision that extended past the borders of the model's navel [31] (**Figure 2a**). Many SILS surgeons strive to keep umbilical incisions hidden within the borders of the umbilicus (**Figure 2b**). A similar study conducted in the 1990s - prior to the rise in popularity of laparoscopic gynecology - showed 68% of women

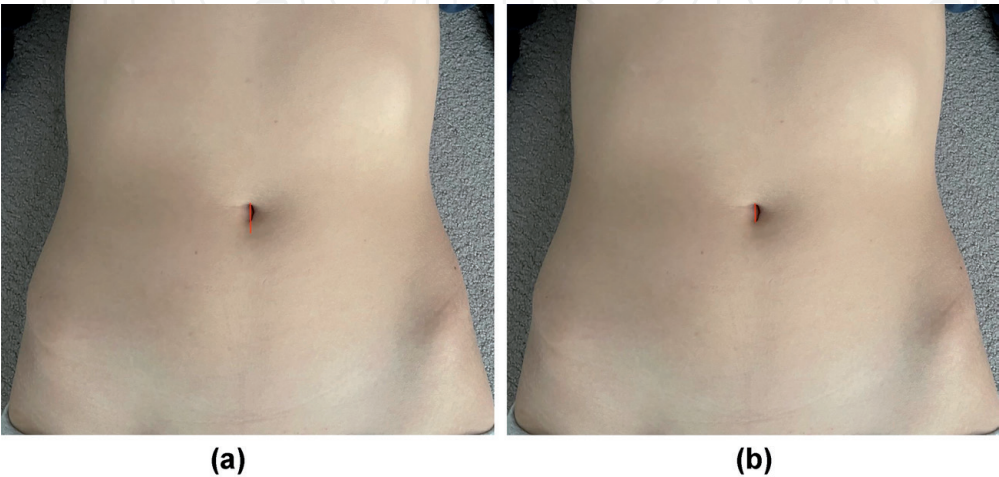


Figure 2.
(a) Replication of incision used during Bush study – umbilical incision extends past the umbilicus. (b) Most single incision laparoscopic surgeons will confine the umbilical incision in the borders of the natural orifice.

would choose a Pfannenstiel incision while only 31% would choose multiport laparoscopic incisions, indicating that patient familiarity with the incision type may have played a role in Bush's findings [32].

Data regarding outcomes for single incision non-adnexal surgery is less abundant than that for adnexal procedures. A single RCT with 66 participants undergoing laparoscopic myomectomy by either SILS or multi-port laparoscopy demonstrated no significant differences in surgical outcomes with the exception of more favorable cosmesis and better patient satisfaction in the SILS group [29].

3. Commercially available single incision access systems

A variety of access systems are available for single incision laparoscopic surgery [33, 34] (**Figure 3a-d**). Surgeon preference and comfort level is key when choosing laparoscopic entry. SILS ports were designed to allow the passage of many instruments through one access point with a single, larger skin incision.

3.1 GelPOINT advanced access platform by applied Medical

The GelPOINT system is a gel topped port combined with Alexis wound retractor technology. The Alexis wound retractor provides 360 degree

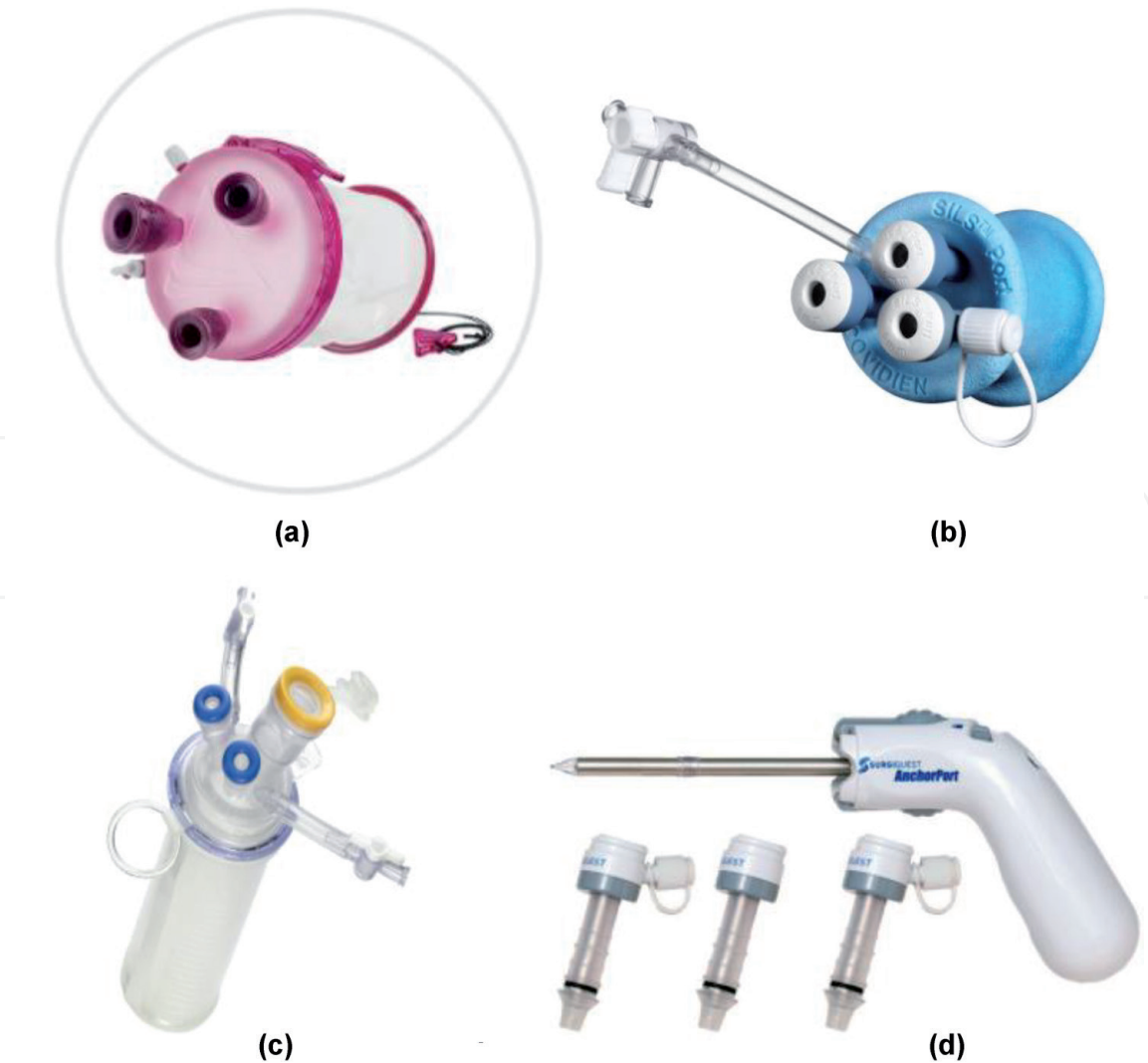


Figure 3.
(a) GelPOINT system, (b) SILS port, (c) TriPort15, (d) AnchorPort.

retraction of the port site; the rounded retraction allows for better instrument triangulation. Trocars supplied with the device are introduced through the GelSeal cap and may be arranged in any formation. The trocars accommodate instrument diameters from 5 to 12 mm. The device can be used in incisions ranging from 1.5 cm to 7 cm in length. The GelSeal cap has a diameter of 10 cm. The cap can be removed from the Alexis retractor for specimen retrieval [33–35].

The GelPOINT Mini uses the same GelSeal and Alexis retractor technology but with a smaller footprint. This system accommodates incisions up to 4 cm. Triangulation is reduced further with the GelPOINT Mini system, limiting its utility in more complex single incision laparoscopy [35].

3.2 SILS port by Medtronic

The SILS port by Medtronic consists of a blue colored foam, soft, flexible port that maintains pneumoperitoneum by conforming to the body wall. The outer diameter is 49 mm and the inner diameter is 29 mm. The port has an insufflation valve and three instrument placement channels. Three variations of the SILS port are available and can accommodate a range of instrument diameter from 5 mm to 15 mm [33, 34, 36].

3.3 TriPort and QuadPort by advanced surgical concepts

Advanced Surgical Concepts offers three single incision laparoscopy platforms. All three variations are composed of an outer ring connected to an inner ring by a clear retracting sleeve. The distal ring is placed into the abdominal cavity with an introducer which punctures the abdominal wall. After the introducer is removed, the outer ring is passed over the retracting sleeve until it creates a seal. Because of its self adjusting retraction sleeve, this port can be used in abdominal walls up to 10 cm in thickness. The fixed ports are angled in order to minimize instrument crowding. The 10 mm and 15 mm ports are equipped with lip seal valves that allow for the introduction and removal of smaller diameter instruments without losing pneumoperitoneum [33, 34, 37].

One model, the Triport+, contains four instrument ports (three 5 mm and one 10 mm) and two insufflation valves, while Triport15 contains three instrument ports (two 5 mm and one 15 mm) and two insufflation valves. Optimal incision length is between 12 mm and 25 mm. QuadPort contains five instrument ports (two 5 mm, one 10 mm, one 12 mm and one 15 mm) and two insufflation valves. It can be used with incisions 20 mm to 60 mm [37].

3.4 AnchorPort by Conmed

The Anchorport system uses a set of unique self-adjusting, self-anchoring trocars [38]. The 5 mm trocar is available in three lengths: 75 mm, 100 mm, 135 mm. It has a clear bladeless optical tip for direct entry and a pistol-like grip handle. The distal portion of the cannula system adjusts to the patient's abdominal wall thickness with its accordion-like design, which anchors to the body wall for security. The AnchorPort design allows a minimum amount of the cannula tip inside the abdomen; this assists with laparoscopic instrument range of motion and widening instrument angles inside the abdomen. AnchorPort is uniquely designed for single incision laparoscopy; a single skin incision is made and then the trocars are introduced directly into the fascia, maintaining a bridge of tissue between each trocar [33, 34].

4. Accessory products

4.1 Laparoscopes

Traditional lens-based laparoscopes have a rigid shaft and utilize two dimensional views. Laparoscope diameters vary from <1 mm to 15 mm, with the most commonly used diameters being 5 and 10 mm. Classically, laparoscopes utilize charge coupled device (CCD) sensors, in which higher resolution is obtained with larger diameters. In SILS, a smaller diameter, such as 5 mm or less, is often preferred at the expense of resolution in order to maintain maneuverability of surgical instruments [39].

Though flexible tip endoscopy was developed as early as the 1950s, it wasn't until the 2000s that flexible tip laparoscopes with adequate imaging capabilities were developed. The EndoEye Flex video laparoscope with "chip on the tip" design was developed in 2005 by Olympus. It has a deflectable tip that can rotate up to 100 degrees. The latest model allows for high definition video in a 5 mm diameter scope by utilizing complementary metal-oxide semiconductor (CMOS) technology as opposed to CCD. It is also the first autoclavable articulating videoscope, as other designs require chemical sterilization. Stryker has also developed articulating 5 and 10 mm videoscopes, however at the time of this manuscript, the Ideal Eyes HD Articulating Laparoscope does not appear to be available in the current Stryker product catalog. Flexible tip laparoscopes have demonstrated shorter operating times for single incision cholecystectomy, but have not yet been evaluated for gynecologic SILS [39].

Lens angles of rigid laparoscopes can vary. Zero degree scopes are most commonly utilized by gynecologic surgeons in multiport laparoscopy. Angled scopes, however, can be very useful in SILS gynecology by moving the imaging plane out of the line of the operating plane in order to reduce instrument collision. Thirty degree laparoscopes are most commonly used, although 45 degree and 70 degree options are available as well. Variable view laparoscopes developed by Karl Storz allow the surgeon to adjust the lens angle between 0 and 90 degrees without removing the scope from the trocar.

An in-line light cord adapter and low profile camera head are two updates that reduce tangling of cords and instrument collision. Use of a longer laparoscope, as those used in bariatric surgery, may also improve mobility. Future laparoscopes may be cordless and wireless [40].

4.2 Instruments

Traditional laparoscopic instruments are rigid with an average length of 33 cm. Some instruments allow for rotation of the tip while others are fixed. Prebent instruments have been utilized by other specialties in the past but have not been widely utilized in gynecologic SILS [33, 34].

Articulating instruments have been pivotal in improving triangulation constraints of SILS while also increasing the surgeon's range of motion (**Figure 4a** and **b**). Companies including Medtronic, BD and others manufacture articulating grasping instruments. There are currently 2 articulating 5 mm bipolar instruments on the market. Ethicon's Enseal G2 provides bipolar sealing of vessels up to 7 mm in diameter with 110 degrees of articulation and 360 degree rotation. The Caiman 5 Vessel Sealer by Aesculap offers 80 degrees of articulation, a 26.5 mm sealing length and 23.5 mm cutting length [41, 42].

The ArtiSential line of wristed instruments with 360 degree of freedom was registered with the FDA in 2019. They have yet to be described in single incision gynecology but offer similar range of motion as robotic instruments and may have utility in SILS procedures.

In instances where wider triangulation is necessary, mini laparoscopic instruments can be introduced away from the single incision port site. Many companies promote miniature laparoscopic instruments with diameters 3 mm and under. Some of the smallest diameter instruments are manufactured by Teleflex, which produces instruments with only a 2.4 mm shaft. The instrument is introduced directly through the skin using an integrated needle tip, which eliminates the need for a skin incision or trocar. The product line offers 2 handpieces, 4 types of graspers and 4 monopolar electro-surgical tools.

The magnetically anchored and guidance system (MAGS) was first described in 2007. This device utilizes magnetic coupling of an external handpiece and an internal instrument or camera. The internal components are inserted through a single incision and paired to their external components via magnetic attraction across the

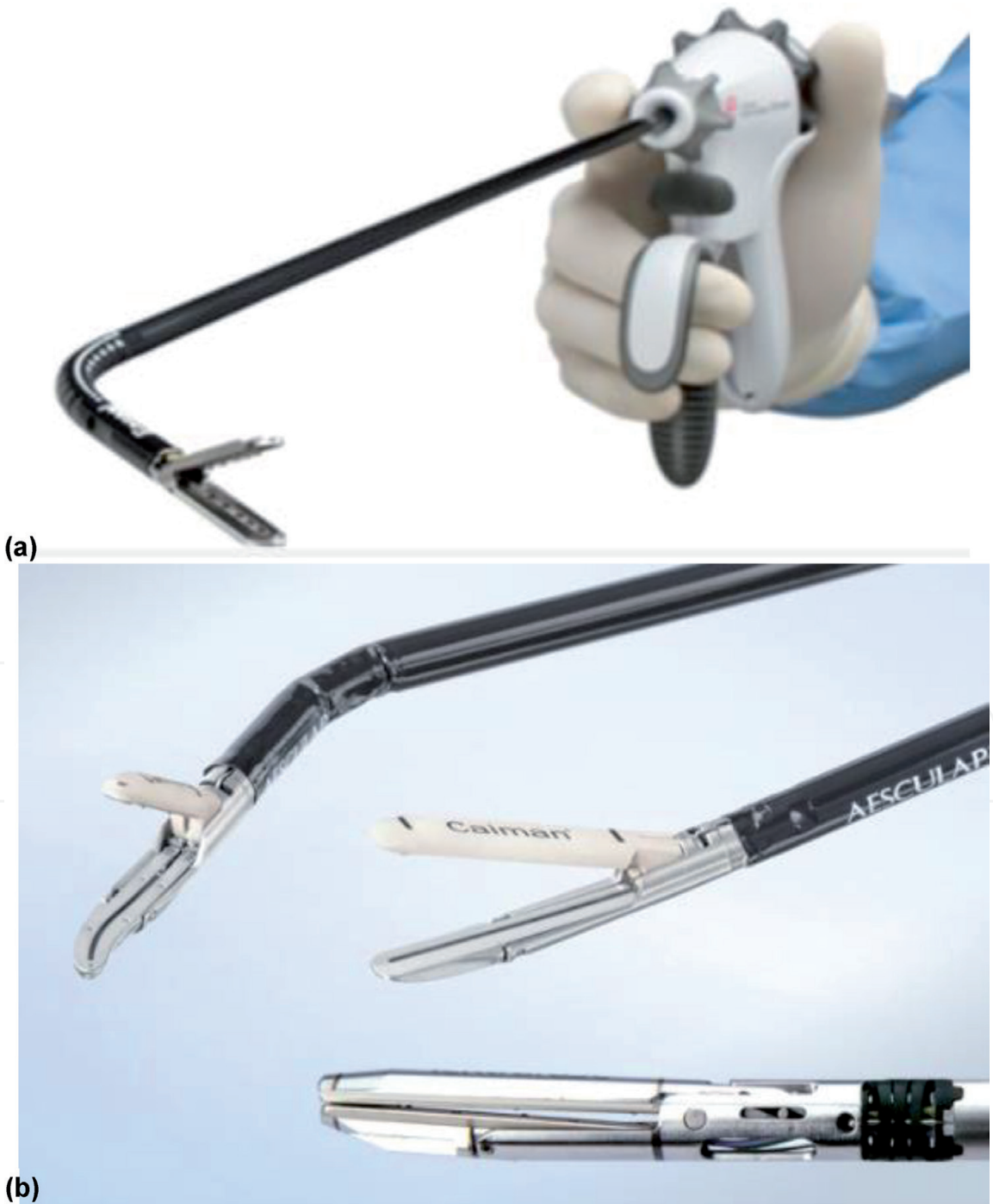


Figure 4.
Articulating Bipolar Vessel Sealers. (a) Enseal G2, (b) Calman 5.

abdominal wall, up to a maximal thickness of 10 cm. The internal components can then be arranged in an ergonomic configuration by moving the external components along the abdominal wall. MAGS has been utilized in urology and thoracic surgery, but has not yet been seen in gynecologic surgery [43].

4.3 Smoke evacuation systems

The dangers of surgical smoke to the surgical team are well documented. Electrocauterization instruments, lasers, and ultrasonic scalpels all release particulate matter (PM) into the ambient air during both open and laparoscopic surgery. Particles 10 microns or smaller can be inhaled. Studies evaluating the long term effects specific to surgical smoke are insufficient; however the PM found in surgical smoke is associated with coronary artery disease, congestive heart failure, asthma, and chronic obstructive pulmonary disease. Deposits of PM have been found in remote organs, including the brain, and may be associated with increased oxidative stress and systemic inflammation. Long term exposure may be associated with decreased life expectancy [44].

During laparoscopy, surgical smoke also impairs visualization. As simply venting the plume into the ambient air is ill advised, smoke evacuation systems are crucial in providing adequate visualization of structures. Dozens of smoke evacuation systems have been marketed for laparoscopic procedures. ConMed's Airseal, released in 2007, is uniquely beneficial to gynecologic SILS. The Airseal system maintains the pneumoperitoneum, provides constant smoke evacuation and allows valve free port access. The high pressure nozzles of the port's cannula direct recirculated CO₂ gas down into the trocar in order to maintain pressure which creates a horizontal gas barrier across the cannula. Thus, introduction of a smaller caliber instrument or even 2 instruments through a single trocar does not result in loss of pneumoperitoneum. AirSeal has 3 operational modes: AirSeal Mode, Smoke Evacuation Mode, and Standard Insufflation Mode. The system filters particles as small as 0.01 microns [33, 34, 44].

5. Surgical techniques

Although traditionally, the least experienced member of the surgical team is often tasked with uterine manipulation, expert uterine manipulation is often key in gynecologic SILS. Introduction of multiple instruments through a single port site reduces mobility, and manipulation of the uterus can enhance or replace retraction usually done through the abdominal wall. Retroversion of the uterus allows access to the vesicouterine space. Anteversion of the uterus exposes the rectouterine space. Rotational uterine manipulation, rather than straight lateral displacement of the uterus, provides better access to the adnexa of surgical interest. The uterus can also be pushed cephalad to displace the ureters laterally or pulled caudad to access the fundus of a larger uterus.

Creation of a posterior colpotomy during a non-hysterectomy SILS procedure can provide a second point of access for instrumentation, passing suture or removing specimens. Vaginal natural orifice transluminal endoscopic surgery (vNOTES), which utilizes the vaginal as the sole entry point for endoscopic surgery, is discussed in a separate chapter. The techniques described for vNOTES may be employed in complex SILS cases as well.

Temporary sutures can be used to provide retraction during SILS procedures. This technique is often called "puppeteering" [1]. Straight needles are useful in that they can be passed through a trocar or inserted directly through the abdominal wall. Curved needles may be introduced through larger caliber trocars or partially

straightened to pass through smaller trocars. Choice of suture is based upon surgeon preference as the suture is removed after the procedure is completed. As long as care is taken to avoid vascular structures, the uterus and adnexa can be retracted with puppet sutures. Large bowel should only be retracted by suturing through the epiploica. Small bowel should not be retracted in this manner due to risk of injury.

IntechOpen

IntechOpen

Author details

M. Luann Racher* and Ann Marie Mercier
Department of Obstetrics and Gynecology, University of Arkansas for Medical
Sciences, Little Rock, AR, USA

*Address all correspondence to: mlracher@uams.edu

IntechOpen

© 2021 The Author(s). Licensee IntechOpen. This chapter is distributed under the terms of the Creative Commons Attribution License (<http://creativecommons.org/licenses/by/3.0>), which permits unrestricted use, distribution, and reproduction in any medium, provided the original work is properly cited. 

References

- [1] Rao PP, Rao PP, Bhagwat S. Single-incision laparoscopic surgery - current status and controversies. *J Minim Access Surg.* 2011;7(1):6-16. doi:10.4103/0972-9941.72360
- [2] Schmitt A, Crochet P, Knight S, Tourette C, Loundou A, Agostini A. Single-Port Laparoscopy vs Conventional Laparoscopy in Benign Adnexal Diseases: A Systematic Review and Meta-Analysis. *J Minim Invasive Gynecol.* 2017 Nov-Dec;24(7):1083-1095. doi: 10.1016/j.jmig.2017.07.001. Epub 2017 Jul 10. PMID: 28705751.
- [3] Supe AN, Kulkarni GV, Supe PA. Ergonomics in laparoscopic surgery. *J Minim Access Surg.* 2010;6(2):31-36. doi:10.4103/0972-9941.65161
- [4] Far SS, Miraj S. Single-incision laparoscopy surgery: a systematic review. *Electron Physician.* 2016;8(10):3088-3095. Published 2016 Oct 25. doi:10.19082/3088
- [5] Bradford LS, Boruta DM. Laparoendoscopic single-site surgery in gynecology: a review of the literature, tools, and techniques. *Obstet Gynecol Surv.* 2013 Apr;68(4):295-304. doi: 10.1097/OGX.0b013e318286f673. PMID: 23943039.
- [6] Amanda Nickles Fader, Luis Rojas-Espaillet, Okechukwu Ibeanu, Francis C. Grumbine, Pedro F. Escobar, Laparoendoscopic single-site surgery (LESS) in gynecology: a multi-institutional evaluation, *American Journal of Obstetrics and Gynecology*, Volume 203, Issue 5, 2010, Pages 501.e1-501.e6
- [7] Zhao M, Zhao J, Hua K, Zhu Z, Hu C. Single-incision multiport laparoscopy versus multichannel-tipped single port laparoscopy in gynecologic surgery: outcomes and benefits. *Int J Clin Exp Med.* 2015 Sep 15;8(9):14992-14998. PMID: 26628982; PMCID: PMC4658871.
- [8] Murji A, Patel VI, Leyland N, Choi M. Single-incision laparoscopy in gynecologic surgery: a systematic review and meta-analysis. *Obstet Gynecol.* 2013 Apr;121(4):819-828. doi: 10.1097/AOG.0b013e318288828c. PMID: 23635683.
- [9] Karasu Y, Akselim B, Kavak Cömert D, Ergün Y, Ülker K. Comparison of single-incision and conventional laparoscopic surgery for benign adnexal masses. *Minim Invasive Ther Allied Technol.* 2017 Oct;26(5):278-283. doi: 10.1080/13645706.2017.1299763. Epub 2017 Mar 14. PMID: 28290726.
- [10] Cho YJ, Kim ML, Lee SY, Lee HS, Kim JM, Joo KY. Laparoendoscopic single-site surgery (LESS) versus conventional laparoscopic surgery for adnexal preservation: a randomized controlled study. *Int J Womens Health.* 2012;4:85-91. doi: 10.2147/ijwh.s29761. Epub 2012 Mar 13. PMID: 22448110; PMCID: PMC3310352.
- [11] Hoyer-Sørensen C., Vistad I., and Ballard K.: Is single-port laparoscopy for benign adnexal disease less painful than conventional laparoscopy? A single-center randomized controlled trial. *Fertil Steril* 2012; 98: pp. 973-979
- [12] Fagotti A., Bottoni C., Vizzielli G., et al: Postoperative pain after conventional laparoscopy and laparoendoscopic single site surgery (LESS) for benign adnexal disease: a randomized trial. *Fertil Steril* 2011; 96: pp. 255-259
- [13] Im K.S., Koo Y.J., Kim J.B., and Kwon Y.S.: Laparoendoscopic single-site surgery versus conventional laparoscopic surgery for adnexal tumors: a comparison of surgical

outcomes and postoperative pain outcomes. *Kaohsiung J Med Sci* 2011; 27: pp. 91-95

[14] Yoo E.H., and Shim E.: Single-port access compared with three-port laparoscopic adnexal surgery in a randomized controlled trial. *J Int Med Res* 2013; 41: pp. 673-680

[15] Yoon B.S., Kim Y.S., Seong S.J., et al: Impact on ovarian reserve after laparoscopic ovarian cystectomy with reduced port number: a randomized controlled trial. *Eur J Obstet Gynecol Reprod Biol* 2014; 176: pp. 34-38

[16] Kim T.J., Lee Y.Y., An J.J., et al: Does single-port access (SPA) laparoscopy mean reduced pain? A retrospective cohort analysis between SPA and conventional laparoscopy. *Eur J Obstet Gynecol Reprod Biol* 2012; 162: pp. 71-74

[17] Lee Y.Y., Kim T.J., Kim C.J., et al: Single port access laparoscopic adnexal surgery versus conventional laparoscopic adnexal surgery: a comparison of peri-operative outcomes. *Eur J Obstet Gynecol Reprod Biol* 2010; 151: pp. 181-184

[18] Buda A., Cuzzocrea M., Montanelli L., et al: Evaluation of patient satisfaction using the EORTC IN-PATSAT32 questionnaire and surgical outcome in single-port surgery for benign adnexal disease: observational comparison with traditional laparoscopy. *Diagn Ther Endosc* 2013; 2013: pp. 578392

[19] Park J.Y., Kim D.Y., Kim S.H., Suh D.S., Kim J.H., and Nam J.H.: Laparoendoscopic single-site compared with conventional laparoscopic ovarian cystectomy for ovarian endometrioma. *J Minim Invasive Gynecol* 2015; 22: pp. 813-819

[20] Lee I.O., Yoon J.W., Chung D., et al: A comparison of clinical and surgical

outcomes between laparo-endoscopic single-site surgery and traditional multiport laparoscopic surgery for adnexal tumors. *Obstet Gynecol Sci* 2014; 57: pp. 386-392

[21] Kim M.L., Song T., Seong S.J., et al: Comparison of single-port, two-port and four-port laparoscopic surgery for cyst enucleation in benign ovarian cysts. *Gynecol Obstet Invest* 2013; 76: pp. 57-63

[22] Bedaiwy M.A., Starks D., Hurd W., and Escobar P.F.: Laparoendoscopic single-site surgery in patients with benign adnexal disease: a comparative study. *Gynecol Obstet Invest* 2012; 73: pp. 294-298

[23] Bedaiwy M.A., Sheyn D., Eghdami L., et al: Laparoendoscopic single-site surgery for benign ovarian cystectomies. *Gynecol Obstet Invest* 2015; 79: pp. 179-183

[24] Yim G.W., Lee M., Nam E.J., Kim S., Kim Y.T., and Kim S.W.: Is single-port access laparoscopy less painful than conventional laparoscopy for adnexal surgery? A comparison of postoperative pain and surgical outcomes. *Surg Innov* 2013; 20: pp. 46-54

[25] Huang B.S., Wang P.H., Tsai H.W., Hsu T.F., Yen M.S., and Chen Y.J.: Single-port compared with conventional laparoscopic cystectomy for ovarian dermoid cysts. *Taiwan J Obstet Gynecol* 2014; 53: pp. 523-529

[26] Liliana M, Alessandro P, Giada C, Luca M. Single-port access laparoscopic hysterectomy: a new dimension of minimally invasive surgery. *J Gynecol Endosc Surg.* 2011;2(1):11-17.
 doi:10.4103/0974-1216.85273

[27] Kim SK, Lee JH, Lee JR, Suh CS, Kim SH. Laparoendoscopic single-site myomectomy versus conventional laparoscopic myomectomy: a comparison of surgical outcomes.

- J Minim Invasive Gynecol. 2014 Sep-Oct;21(5):775-781. doi: 10.1016/j.jmig.2014.03.002. Epub 2014 Mar 12. PMID: 24632396.
- [28] Choi CH, Kim TH, Kim SH, Choi JK, Park JY, Yoon A, Lee YY, Kim TJ, Lee JW, Kim BG, Bae DS. Surgical outcomes of a new approach to laparoscopic myomectomy: single-port and modified suture technique. J Minim Invasive Gynecol. 2014 Jul-Aug;21(4):580-585. doi: 10.1016/j.jmig.2013.12.096. Epub 2013 Dec 31. PMID: 24384072.
- [29] Lee D, Kim SK, Kim K, Lee JR, Suh CS, Kim SH. Advantages of Single-Port Laparoscopic Myomectomy Compared with Conventional Laparoscopic Myomectomy: A Randomized Controlled Study. J Minim Invasive Gynecol. 2018 Jan;25(1):124-132. doi: 10.1016/j.jmig.2017.08.651. Epub 2017 Aug 18. PMID: 28826957.
- [30] Ramesh B, Vidyashankar M, Bharathi B. Single incision laparoscopic myomectomy. J Gynecol Endosc Surg. 2011;2(1):61-63. doi:10.4103/0974-1216.85288
- [31] Bush AJ, Morris SN, Millham FH, et al. Women's preference for minimally invasive incisions. J Minim Invasive Gynecol. 2011; 18: 640-643
- [32] Currie I, Onwude J.L., Jarvis G.J.: A comparative study of the cosmetic appeal of abdominal incisions used for hysterectomy. Br J Obstet Gynaecol 1996; 103: pp. 252-254.
- [33] Romanelli, J.R., Earle, D.B. Single-port laparoscopic surgery: an overview. Surg Endosc 23, 1419-1427 (2009).
- [34] Kumar, Chigurupathi Venkata Pavan. "Different types of single incision laparoscopy surgery (SILS) ports." *World J Laparosc Surg* 4.1 (2011): 47-51.
- [35] Applied Medical. GelPOINT Advanced Access Platforms. 2019
- [36] Medtronic. Laparoscopic Access Catalogue. June 2020
- [37] Advanced Surgical Concepts. Laparoendoscopic Single Site Surgery Access Devices. 2020.
- [38] ConMed. Advanced Surgical Product Catalog. 2019.
- [39] Matsui Y, Ryota H, Sakaguchi T, Nakatani K, Matsushima H, Yamaki S, Hirooka S, Yamamoto T, Kwon AH. Comparison of a flexible-tip laparoscope with a rigid straight laparoscope for single-incision laparoscopic cholecystectomy. Am Surg. 2014 Dec;80(12):1245-1249. PMID: 25513924.
- [40] Chatzipapas, Ioannis PhD; Kathopoulis, Nikolaos MD; Siemou, Panagiota PhD; Protopapas, Athanasios PhD Wireless Laparoscopy in the 2020s, Obstetrics & Gynecology: November 2020 - Volume 136 - Issue 5 - p 908-911
- [41] Ethicon. Enseal G2 Articulating Tissue Sealer Brochure. 2020.
- [42] Aesculap. Caiman Vessel Sealers. March 2019.
- [43] Best SL, Cadeddu JA. Development of magnetic anchoring and guidance systems for minimally invasive surgery. Indian J Urol. 2010;26(3):418-422. doi:10.4103/0970-1591.70585
- [44] Limchantra IV, Fong Y, Melstrom KA. Surgical Smoke Exposure in Operating Room Personnel: A Review. JAMA Surg. 2019;154(10):960-967. doi:10.1001/jamasurg.2019.2515