

# We are IntechOpen, the world's leading publisher of Open Access books Built by scientists, for scientists

6,900

Open access books available

186,000

International authors and editors

200M

Downloads

Our authors are among the

154

Countries delivered to

TOP 1%

most cited scientists

12.2%

Contributors from top 500 universities



WEB OF SCIENCE™

Selection of our books indexed in the Book Citation Index  
in Web of Science™ Core Collection (BKCI)

Interested in publishing with us?  
Contact [book.department@intechopen.com](mailto:book.department@intechopen.com)

Numbers displayed above are based on latest data collected.  
For more information visit [www.intechopen.com](http://www.intechopen.com)



# Appendicitis in Children: Fundamentals and Particularities

*Alin Villalobos Castillejos, Carlos Baeza Herrera,  
Miguel Alejandro Sánchez Durán, Jhonatan Mata Aranda,  
Miguel Ángel Minero Hibert, Ricardo Cortés García  
and Jorge Escorcía Dominguez*

## Abstract

Acute appendicitis in children under 5 years of age is a diagnostic challenge, its delay is usually dramatic and leaves serious sequelae. It is one of the main causes of surgical intervention, it is common for other diseases to be associated with it and to simulate it. Acute appendicitis is of obstructive etiology and its pathophysiology, the bacteriology involved and the evolution of the disease progresses through its phases, from the simple to the complex, is addressed in each case. The typical abdominal pain of appendicitis, in addition to vomiting and fever at a young age, is most often accompanied by an atypical clinical picture such as diarrhea. Integrating the clinical signs at this age requires the full capacity and good sense of the pediatric surgeon. For a correct and timely diagnosis, unfortunately many pediatric patients present in complicated stages of the disease, which implies decision-making regarding the type of surgical intervention and subsequent treatments.

**Keywords:** acute appendicitis, children, classification, treatment, special conditions

## 1. Introduction

Acute appendicitis is the main cause for abdominal surgery, and it is also one of the main diseases in pediatrics that requires surgical treatment. It is among the primary reasons for hospital care in developing countries [1]. The most frequent age of presentation is in the second decade of life; however, we must pay special attention to children under 5 years of age, as they have an atypical clinical presentation that can delay diagnosis and treatment [1]. According to our experience, based on the management of up to 1,200 appendicitis cases a year at the Surgery Unit of the Moctezuma Pediatric Hospital of the Mexico City Secretary of Health, a regional referral center in a densely populated area, we observed a predominance of males, and children under 10 years of age accounted for almost 85% of the cases. We combined a series of more than 300 children three years of age or less. Pediatric appendicitis is a common sporadic event; however, it is often associated with specific regional diseases such as Hirschsprung's disease [2]. The appendix serves as a reservoir for normal intestinal flora and has a high concentration of gut-associated lymphoid tissue [3]. A family history of appendicitis imparts a risk. Although a specific gene has not been identified, the

likelihood of appendicitis is approximately three times greater in family members with a positive history than in those with a negative history [3, 4].

## **2. Etiology**

The most frequent, almost exclusive, cause is the luminal obstruction of the proximal segment, the appendico-caecal junction, which makes practical sense as this structure is like the finger of a glove. Everything that prevents the natural drainage of mucus that normally accumulates inside, be it an appendicolith, foreign body, a vegetable seed, intestinal parasites (*Ascaris lumbricoides*), even hyperplasia and hypertrophy of lymphoid tissue, primary tumors (carcinoid, adenocarcinoma, Kaposi's sarcoma and lymphoma) or metastatic tumors will cause structural and physiological changes and depending on the time it remains occluded, the clinical and histopathological stages of the disease can be obtained [5].

### **2.1 Fecaliths/appendicular stones**

The formation of a fecalith and a stone occurs when feces, trapped within the appendicular lumen, are continuously bathed with minerals and thickened. Like gallstones, fecaliths and appendix stones can enlarge to a critical diameter, resulting in complete lumen obstruction. The consequence is an increase in intraluminal pressure in the obstructed part of the appendix, which interferes with the circulation in the intestinal mucosa and alters venous drainage, causing a thrombosis of the terminal appendicular artery, which results in a transmural infarction and perforation [6]. The presence of fecaliths or appendicular stones is associated with a higher number of complicated acute appendicitis, with perforation in 18% of cases and appendicular abscess in 42%. Therefore, fecaliths and appendicular stones play an important role in the pathogenesis of appendicitis [6].

### **2.2 Bacterial infection**

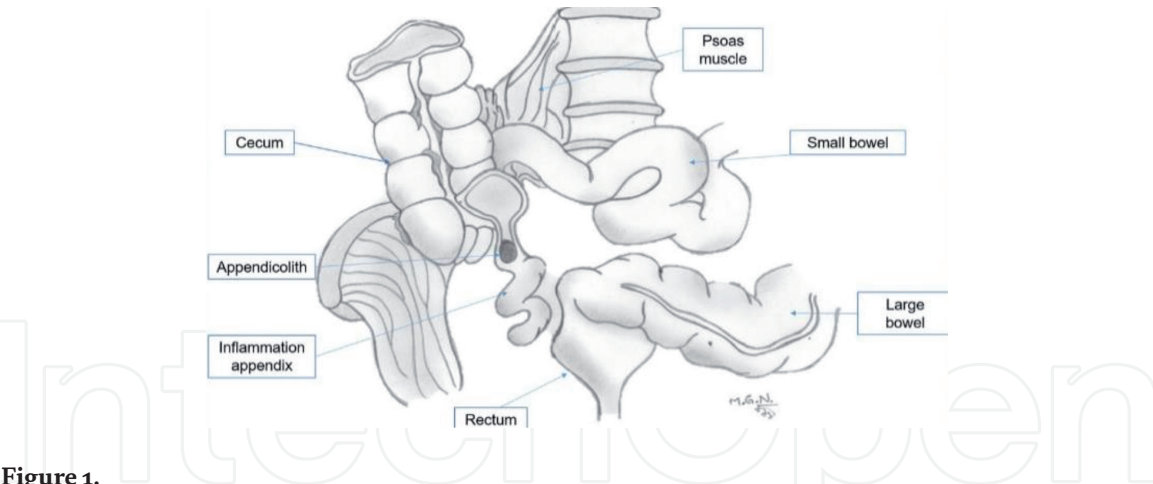
Most opponents of the obstruction theory advocate an infectious pathogenesis for acute appendicitis. The lack of increased bacterial counts in acute inflammation suggests that the environment for bacterial growth is unfavorable and that the number of organisms invading the wall is low compared to those in the lumen or associated with the mucosa [6].

### **2.3 Hiperplasia linfoide**

Since the cecal appendix is rich in lymphatic follicles, lymphoid hyperplasia can lead to obstruction of the lumen of the appendix. In a pathology analysis of 405 appendages, Babekir and Devi found significant lymphoid hyperplasia in 25% of acutely inflamed appendixes. Although this could be partly a secondary phenomenon during the inflammatory process, a typical viral illness with symptoms of gastroenteritis could probably trigger an acute appendicitis after a few days [6].

## **3. Pathophysiology**

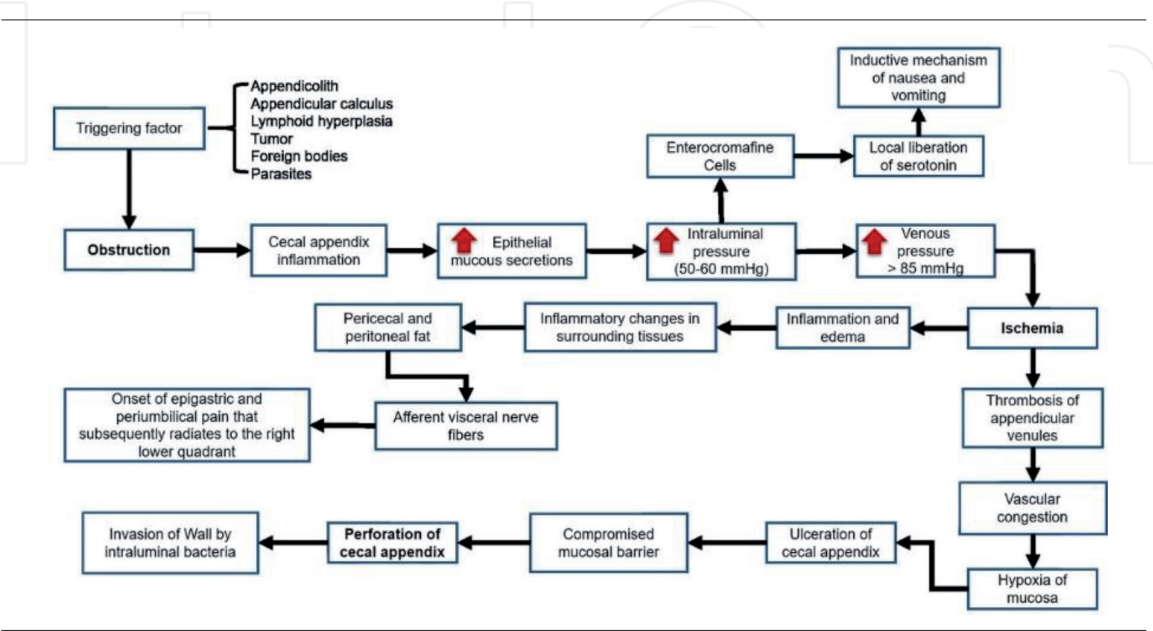
The obstruction of the appendicular lumen causes inflammation, increased intraluminal pressure and ultimately ischemia. Subsequently, the appendix enlarges and incites inflammatory changes in the surrounding tissues, such as the pericecal fat



**Figure 1.**  
Showing the anatomy of the cecal appendix and the fecalith obstructing the lumen.

and the peritoneum. Rapid distention of the appendix occurs due to its small luminal capacity, and intraluminal pressures can reach 50 to 65 mm Hg (**Figure 1**) [7]. This appendicular condition leads to an enlargement of the cecum, the cecal content is stored and does not advance towards the right colon. The presence of fecal load within a large cecum can be identified on plain abdominal radiography as a specific sign of acute appendicitis [7]. Once the luminal pressure exceeds 85 mm Hg, thrombosis of the venules draining the appendix occurs, and in the setting of continuous arteriolar flow, vascular congestion and congestion of the appendix develop [5, 7]. Lymphatic and venous drainage is impaired and ischemia develops. The mucosa becomes hypoxic and begins to ulcerate, resulting in compromise of the mucosal barrier and leading to invasion of the appendicular wall by intraluminal bacteria. Most bacteria are gram-negative, mainly *Escherichia coli* (76%), followed by *Enterococcus* (30%), *Bacteroides* (24%), and *Pseudomonas* (20%) [8].

The inflammation spreads to the serosa, parietal peritoneum, and adjacent organs and as a result, visceral afferent nerve fibers entering the spinal cord at T8-T10 are stimulated, causing epigastric and periumbilical pain referred by the corresponding dermatomes. At this stage, somatic pain replaces early referred pain, and patients generally experience a shift at the site of maximum pain towards the right lower



**Table 1.**  
Pathophysiology of appendicitis.

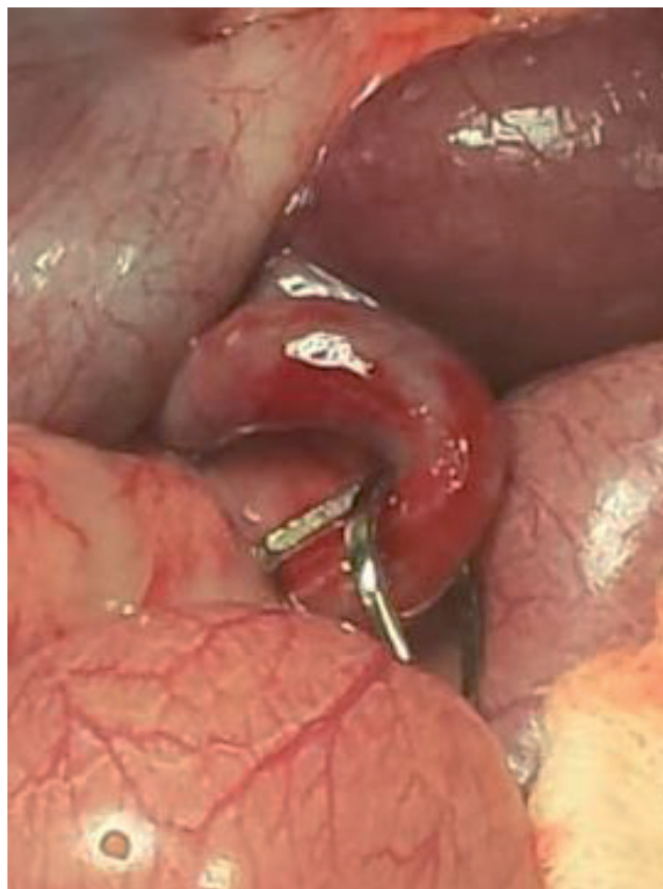


quadrant. If this continues, arterial blood flow is eventually compromised and a heart attack occurs, resulting in gangrene and perforation (**Table 1**) [9].

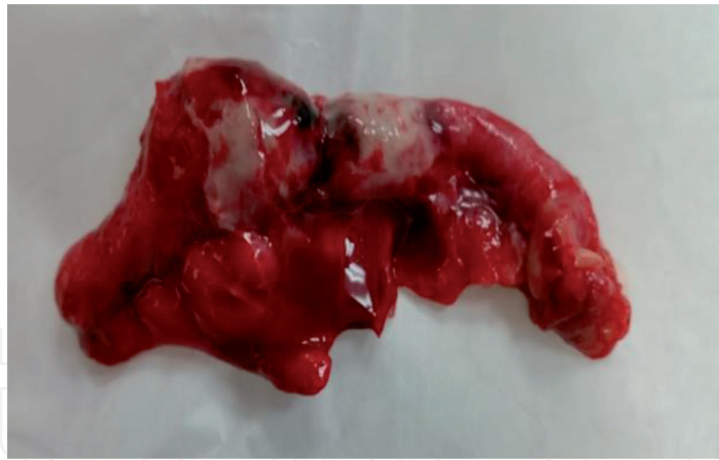#### **4. Classification of appendicitis**

After a few hours, sometimes less than 24 hours or a little longer, the appendix is observed, (describing it from the inside out) with a large accumulation of mucus in which a significant variety of bacteria, especially anaerobes, are immersed. Being usual inhabitants in normal conditions, they find the ideal means to proliferate. The mucous lining, following the natural history of the disease, responds with the migration of specific inflammatory cells in response to the situation. Therefore, arterial and venous circulation also alter their dynamics and the flow slows down, causing what that observed when the disease is in the initial phase, simple acute appendicitis. There may or may not be a generally small amount of peri-appendicular fluid, rich in bacteria, but transparent in appearance. As time passes, from 24 to 36 hours after symptoms begin and in an average of 3.2 days, that process worsens and the name of the following stages basically obeys the appearance of the structure. Thus, if the appendix is seen intact, with or without a large fecalith inside, but with a blackish coloration of its wall and dark purulent fluid in its environment, it is gangrenous (**Figure 2**) [10].

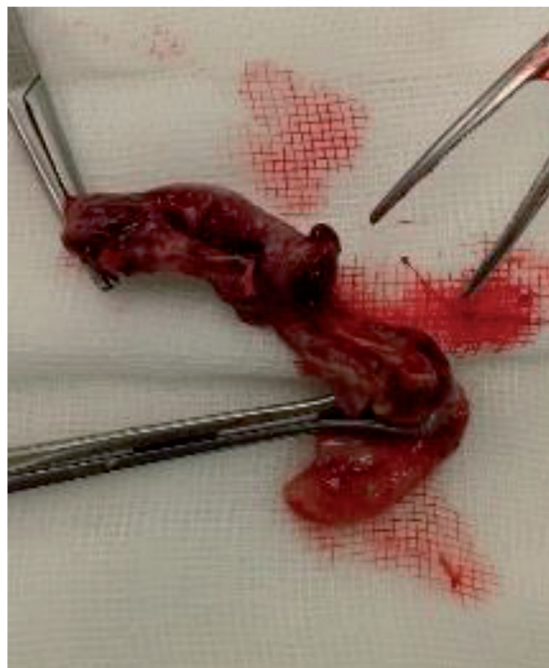
The most advanced phase is labeled as abscess appendicitis when the evolution time has been days or sometimes weeks, with a tendency for pus to spread to the entire peritoneal cavity. The appendix is usually ruptured or destroyed, and there is a great liquefaction of periappendicular tissue with a quantity of liquid greater than 10 ml, sometimes reaching more than two liters, depending on the age of the child (**Figure 3**) [10].



**Figure 2.**  
*Appendix in gangrenous phase with dilated bowel loops.*



**Figure 3.**  
*Appendix with fecalith.*



**Figure 4.**  
*Appendix with perforation in the middle third.*

In all cases clinical behavior is unpredictable, although it can be stated with certainty that the patient's condition will worsen as the hours go by. Although this category obeys somewhat arbitrary rules, in accord with our experience, we believe there is a strong relationship with the response of each phase to the antimicrobial management schemes that are established, and in the same sense, it coincides with the prognosis. A concern of some academics is when the cecal appendix is perforated. According to a study published by the National Institute of Pediatrics of Mexico, micro-perforations can be observed even in the earliest stage of the disease, so that for each stage we add the perforated phase at the margin if it is minimally or grotesquely broken or destroyed (**Figures 3 and 4**) [11].

According to the findings found during surgery, appendicitis is initially staged as simple or uncomplicated and complicated; this staging sets the course for postoperative treatment. Simple and gangrenous appendicitises are considered uncomplicated and have a good prognosis; perforated and abscessed appendicitises are classified as complicated (**Table 2**) [11].

<b>Simple appendicitis</b>
<ul style="list-style-type: none"><li>• Inflammation, erythema</li><li>• Inflammatory fluid</li><li>• No inflammation</li><li>• Gangrenated (change of gray or black color in the wall of the appendix, without evidence of complicated appendicitis)</li></ul>
<b>Complicated appendicitis</b>
<ul style="list-style-type: none"><li>• Extraluminal appendicolith</li><li>• Visible perforation in the cecal appendix</li><li>• Well-formed abscesses</li><li>• Diffuse pus</li></ul>

**Table 2.**  
*Classification of appendicitis.*

5. Clinical picture

The symptoms and signs that accompany the disease are typically three, which almost always appear in this order: pain of sudden onset, progressive intensity and periumbilical location, as the appendix is innervated by the splanchnic nerves that emerge of the lower thoracic ganglia, ganglion 10, one of the structures that conducts the painful stimulus to the dorsal nerve root along the dorsal spinothalamic tract. With the appearance of pain and the vagal stimulus, vomiting, anorexia and occasionally diarrhea are added. At the end of the process fever appears, which almost never exceeds 38.5° C, and when it does, the disease has been treated with antibiotics and is in advanced stage, or is not appendicitis. These symptoms can occur in less than 50% of patients and be nonspecific in children under 5 years of age. Children under 3 years of age have perforated appendicitis in more than 80% of cases compared to 20% of children between 10 and 17 years of age [12].

The complementary support resources to prepare the diagnosis in a timely manner, hematic cytology and the radiological study, are almost always useful, but above all is the skill of the surgeon, with the subtlety that a good physical exam requires, who collects the most important data: right quadrant muscle stiffness in the location of the appendix and exquisite pain located around no more than three square centimeters on the same anatomical site. This rule is not carved in stone. If the order is different, it has the same usefulness and validity. Palpation of the lower left quadrant and referred pain in the lower right quadrant, the obturator sign (internal rotation of the right lower limb) and the psoas sign may be nonspecific for appendicitis and only rebound has a greater clinical correlation with appendicitis [12]. With regard to digital rectal examination, we are convinced that it does not provide data to substitute for a good physical study of McBurney’s point, so we do not recommend performing it. For a child, the maneuver, in addition to being unnecessary and annoying, requires the informed consent of the parents. The abdominal maneuvers and signs referred to in the literature are useful and should be sought [12].

The support provided by cytology is important, since the increase in the leukocyte count has been mentioned as having a significant relationship of 60–90% with perforated appendicitis. It is advisable to carry out the band count, since in our experience, they are almost always very high, even without leukocytosis. If more than 15,000 are found, it may not be appendicitis or it is complicated. Finally, the total leukocyte count, absolute neutrophils and C-reactive protein have been shown to have a greater sensitivity and specificity for appendicitis when the three are used in addition to the clinical history and evaluation of the patient [12].

6. Diagnosis

There are difficulties in the diagnosis of acute appendicitis, mainly in young children, which has led to the development of tools that have been useful in the clinical evaluation of these patients. The most frequently used instruments have been the Alvarado Scale (**Table 3**), the Pediatric Appendicitis Scale (PAS) (**Table 4**) and the Inflammatory Response Scale for Appendicitis (AIR). The last scale differs from the first two in that it incorporates C-reactive protein as a predictive value [13]. These three scales evaluate variables such as: vomiting, nausea, anorexia, pain in the lower right quadrant, pain migration, muscle stiffness, temperature, polymorphonuclear leukocytes, leukocytes, and the concentration of C-reactive protein. Macco et al. compared the three scales mentioned above and determined that the Inflammatory Response Scale for Appendicitis has greater discriminatory power and surpasses the other two in predicting acute appendicitis in children [13].

Regarding the radiological study, it should be emphasized that the projection is in a vertical position, since what is intended is that a small air-fluid level appears in the right iliac fossa and eventually a concretion (**Figure 5A, B**). Several findings are mentioned that, alone or together, can help and are: effacement of the preperitoneal line, the shadow of the psoas muscle and of the sacroiliac joint, scoliosis, bird's nest sign and ground glass. When in doubt, the next resource is pelvic us, with high sensitivity and specificity. We believe that criteria such as Alvarado's do not replace the above [14].

Migration of pain	1
Anorexia	1
Nausea / Vomiting	1
Rebound pain	1
Increase in temperature(>37.3°C)	1
Leukocytosis (>10,000/mL)	2
Polymorphonuclear neutrophilia (>75%)	1
Righy lower quadrant tenderness	2
Total	10

From Alvarado A. A practical score for the early diagnosis of acute appendicitis. *Ann Emerg Med* 1986; 15(5):558.

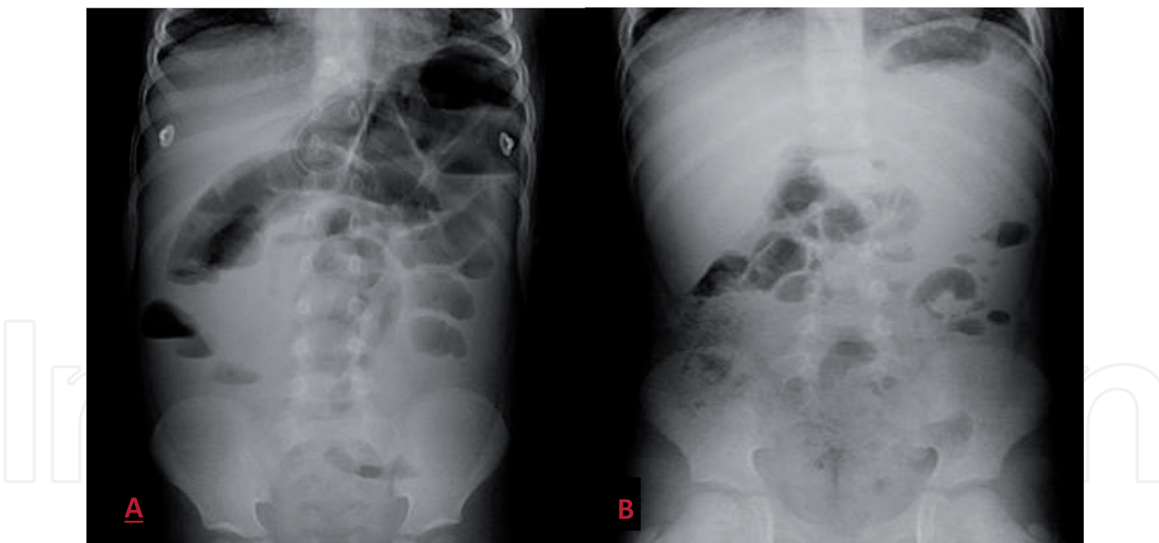
**Table 3.**  
Alvarado score.

Migration of pain	1
Anorexia	1
Nausea / Vomiting	1
Right lower quadrant tenderness	2
Cough/hopping/percussion tenderness in right lower quadrant	2
Increase in temperature	1
Leukocytes >10,000/mL	1
Polymorphonuclear neutrophilia >75%	1
Total	10

From Samuel M. Pediatric appendicitis score. *J Pediatr Surg* 2002;37(6):878.

**Table 4.**  
Pediatric appendicitis score.





**Figure 5.**

*A. a 4-year-old boy with abdominal pain and decreased consistency of bowel movements. Standing abdominal X-ray, air levels in the right iliac fossa and large dilatation of the proximal bowel loops. B. 8-year-old female with pain in the right iliac fossa and fever. Standing abdominal X-ray shows water level in the right iliac fossa.*

Despite the enormous frequency with which it occurs, it is still one of the entities that presents the greatest difficulties for its identification, especially in the early phase, when recognition is essential. Symptomatic progression in children over 12 years of age is practically the same as it appears at later ages. However, there are three circumstances that the clinician frequently encounters: the young child, the child who was inappropriately given antibiotics, and the child with profound psychomotor retardation [14].

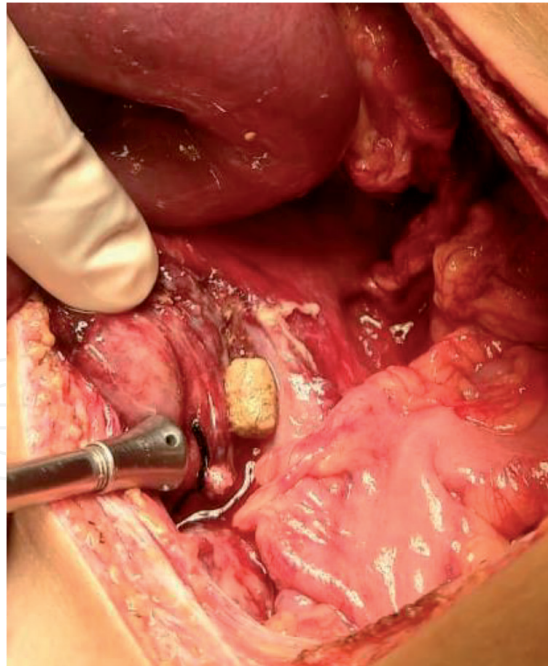
## **7. Treatment**

### **7.1 Surgical treatment**

There is controversy regarding the ideal time to perform an appendectomy; if it should be done immediately upon admission to the emergency service or the next morning, if the admission was during the night. Several studies report no difference between the time of surgery, since it does not change between finding an appendix in a gangrenous or perforated phase, the days of hospital stay or the development of postoperative complications [15]. Our group performs most of the procedures the next morning; upon arrival we begin intravenous hydration and antibiotic therapy as well as analgesic and antipyretic therapies [14].

Secondly, we perform an open or laparoscopic surgical procedure. Regarding the open approach, we always recommend a McBurney incision, unlike adult surgeons, at least in our country, who access through a paramedian or median right infraumbilical incision. We are convinced that the oblique incision on the problem offers the opportunity to resolve the situation in 100% of cases. We learned after a few setbacks, that other injuries such as the right transrectal paramedian in most cases, does not help to resolve the situation no matter how serious it is, as McBurney's does. The golden rules we have established for that purpose are all related to neat and orderly technique. Never do we allow even a finger to enter the peritoneal cavity without justification. Everything is within the reach of some instrument. The stump is preserved with a knot and hidden as with a tobacco bag [14, 15].

Patience is the other ingredient, which consists in carrying out a cleaning of such magnitude in the inflamed space, that only the inaccessible residual material



**Figure 6.**  
*Free appendicolith in a child with complicated appendicitis*

or material that cannot be removed remains. If the previous step is satisfactorily completed, the possibility of not placing drains is considered; we suggest its use almost exclusively if we leave unremoved liquid or solid material to be liquefied. Therefore, it is very feasible that complying with these premises in the first three phases of the disease, the simple, the gangrenous and the suppurative, will not contribute to measures such as drains in most cases. It is almost always required to leave the cavity drained in case there is a missing appendicolith (**Figure 6**) or if it has been destroyed during the maneuvers. Based on what we have learned, we are convinced that almost always, in the first two phases of the disease, the time we dedicate to solving the problem does not require an investment of more than 30–40 minutes [14–16].

## 7.2 Medical treatment

Both complicated appendicitis and secondary peritonitis have sequelae outside the peritoneal cavity and can result in systemic disease. When diagnosis, and therefore treatment, is delayed, morbidity and mortality increase considerably. Some series report that between 30% and 40% of patients present with complicated appendicitis, although the course of the disease and the prognosis vary widely depending on various factors [16–18].

Both cell injury and some bacterial proteins activate a cellular and humoral response, with recruitment of phagocytic cells and the release of inflammatory substances. These substances induce a local cascade through the activation of receptors in inflammatory and endothelial cells that produce chemo-attractant substances (IL-8 and MPC-1), cytokines (TNF- $\alpha$ , IL-1 $\beta$ , and IL-6) and factors growth (TFG $\beta$ , IGF-1, and PDGF) [19].

If the body's regulatory mechanisms fail to control the infection or primary injury, the release of pro-inflammatory mediators predominates and a systemic inflammatory response syndrome (SIRS) develops. If this pro-inflammatory response is excessive and persists, it can progress to organ dysfunction, multisystem compromise, cardiovascular failure, and even death [20].

Respirations rate $\geq 22$ resp/min
Altered mental state
Systolic pressure $\leq 100$ mmHg.
(qSOFA) adapted by Singer et al. [21].

**Table 5.**  
*qSOFA criteria.*

Age group	Beats/min Tachycardia / Bradycardia		Respirations/ min	Leukocyte count $10^3/\text{mm}^3$	Systolic pressure mmHg
Newborn	>180	<100	>50	>34	<59
Neonate	>180	<100	>40	>19.5 o < 5	<79
Infant	>180	<90	>34	>17.5 o < 5	<75
Preschool	>140	NA	>22	>15.5 o < 6	<74
School age	>130	NA	>18	>13.5 o < 4.5	<83
Adolescent and young adult	>110	NA	>14	>11.5 o < 4.5	<90

**Table 6.**  
*Vital signs and laboratory variables by age.*

In 2016, the last update of the definition of sepsis was carried out, emphasizing that there is no validated diagnostic test criterion and no process to operationalize the definitions of sepsis and septic shock. The qSOFA scale (**Table 5**) has been used to identify adult patients with suspected infection who may have prolonged stays in the ICU or die in hospital [21]. An acute change in the qSOFA scale score of 2 points or more has a high predictive value for in-hospital mortality [21].

The definition of sepsis in the pediatric patient is made more difficult by age-specific vital signs and their enormous physiological reserve, so the severity of their condition is often masked [22].

In children, we continue using the criteria of the 2005 Pediatric Sepsis Consensus Congress (CCSP), in which the Systemic Inflammatory Response Syndrome (SIRS) data are categorized by age group (**Table 6**) [22].

SIRS is a generalized inflammatory response that may or may not be associated with an infection. It is characterized by the presence of two or more of the following criteria, one of which must be an abnormal temperature or an alteration in the leukocyte count (**Table 6**) [22].

Sepsis is defined as an organic dysfunction caused by an unbalanced response of the host to a life-threatening infection, and can be significantly amplified by endogenous factors [21]. Septic shock refers to sepsis with cardiovascular dysfunction that persists despite the administration of crystalloids within one hour ( $> 40$  mL/kg) (**Table 7**) [21].

Septic shock is defined as the subset with cardiovascular dysfunction that includes at least one of the following data:

- Hypotension
- Dependence on the administration of vasoactive drugs to maintain normal blood pressure.

Severe sepsis
<ul style="list-style-type: none"><li>• <math>\geq 2</math> SIRS criteria for age.</li></ul>
<ul style="list-style-type: none"><li>• Suspected or proven invasive infection.</li></ul>
<ul style="list-style-type: none"><li>• Cardiovascular dysfunction, acute respiratory distress syndrome (ARDS), or <math>\geq 2</math> non-cardiovascular organ system dysfunctions.</li></ul>

**Table 7.**  
*Criteria for severe sepsis.*

- Two or more of the following signs of inadequate tissue perfusion:
  - Prolonged capillary filling.
  - Oliguria.
  - Metabolic acidosis.
  - Elevated blood lactate. The American College of Critical Care Medicine recommends the use of the following parameters to identify septic shock: • Hypothermia or hyperthermia. • Altered mental state. • Abnormal capillary filling (either in “flash” or  $> 2$  seconds).

The American College of Critical Care Medicine recommends the use of the following parameters to identify septic shock:

- Hypothermia or hyperthermia.
- Altered mental state.
- Abnormal capillary filling (either in “flash” or  $> 2$  seconds).

The International Consensus on Pediatric Sepsis developed criteria for organ dysfunction based on various scoring systems, considering a balance of specificity, sensitivity, and wide availability of laboratory tests [22].

Organ dysfunction criteria include the following:

- Cardiovascular: Hypotension or dependence on vasoactive drugs to maintain blood pressure, or two of the following: metabolic acidosis, elevated arterial lactate, oliguria, or prolonged capillary filling.
- Respiratory: arterial oxygen pressure/inspired oxygen fraction ( $\text{PaO}_2/\text{FiO}_2$ )  $< 300$ , arterial carbon dioxide pressure ( $\text{PaCO}_2$ )  $> 65$  Torr or 20 mmHg above the initial  $\text{PaCO}_2$ , need  $> 50\%$   $\text{FiO}_2$  to maintain the oxygen saturation  $\geq 92\%$ , or need for non-selective mechanical ventilation.
- Neurological: Glasgow Coma score  $\leq 11$  points or acute changes in alertness.
- Hematologic: Platelet count  $< 80,000/\text{microL}$  or a 50% decrease from the highest value recorded in the past 3 days, or disseminated intravascular coagulation (DIC), a consumptive coagulopathy diagnosed by



clinical findings of hemorrhage and microthrombi and abnormalities including thrombocytopenia, prolonged clotting times (PT and aPTT), and evidence of fibrinolysis (low fibrinogen with high fibrin breakdown products).

- Renal: serum creatinine  $\geq 2$  times the upper limit of normal for age or double baseline creatinine increase.
- Hepatic: total bilirubin  $\geq 4$  mg/dL (not applicable in newborns) or ALT  $> 2$  times the upper limit of normal for age.

Studies carried out to date support the use of a standardized scoring system for organ dysfunction on the SIRS criteria in children; Efforts are currently underway to update the definition and clinical criteria for sepsis in pediatrics [22].

### 7.3 Antibiotic therapy

The selection of an antimicrobial therapy must take into consideration three fundamental aspects: the adequate use of antimicrobial prophylaxis, the clinical conditions of the patient to choose an empirical initial regimen, and to adjust the antimicrobial therapy based on the findings during the surgical event [23]. Highlighting this last consideration, the selection of antimicrobial treatment is based on the usual microbiota, however, in the context of a complicated picture of appendicitis with perforation, the germs involved may present some modification [23].

The use of antimicrobials for pre-surgical prophylaxis should be focused on maintaining coverage primarily on the bacteria that are part of the skin microbiota (*S. epidermidis*, *S. aureus*), and in the specific context of appendicitis, coverage on microorganisms typical of the integral intestinal microbiota must be maintained (without evidence of perforation), such as Gram-negative bacilli (*E. coli* and *K. pneumoniae*), as well as for anaerobic agents (*B. fragilis*) [24].

Multiple bacteria are involved in the microbiology of surgical site infection. The isolates isolated in about 50% of cases are gram positive cocci, *Staphylococcus aureus*, and coagulase-negative *Staphylococcus*. One third of the isolates correspond to gram negative bacilli such as *Escherichia coli*, *Pseudomonas aeruginosa*, and *Enterobacter* spp [24].

The greatest change in the microbiology of surgical site infection is due to the emergence of methicillin-resistant *Staphylococcus aureus*, especially of community acquisition, with a dramatic increase, occupying up to 40% of all strains in developing countries. Gram negative bacilli have also shown increased resistance with the indiscriminate use of broad-spectrum antibiotics [25].

The establishment of a pre-surgical antibiotic prophylaxis guide is important, since this procedure is usually not regulated in most institutions, creating confusion among physicians, an increase in hospital bacterial resistance as well as a waste of supplies [26].

The route of administration is intravenous, as it produces a rapid, reliable and predictable effect in serum and tissues [27]. Successful prophylaxis requires that the antimicrobial be delivered to the surgical site before contamination occurs and that it reaches its minimum inhibitory concentrations (MIC) from the moment of incision and throughout the surgical procedure. In general, the administration of the antimicrobial is recommended 60 minutes before the surgical incision (except in fluoroquinolones and vancomycin, which must be 120 minutes before the surgical event) [28].

To ensure that serum and tissue antimicrobial concentrations are achieved, both pharmacokinetics and pharmacodynamics must be considered. In the case of

the pediatric population, the dose is standardized according to the weight of the patient, which is ideal, since in certain conditions the concentrations may not be adequate. For example, obese patients have alterations in pharmacokinetics because lipophilic drugs (e.g., vancomycin) reach lower concentrations and hydrophilic drugs can be excessive (e.g., amikacin) [29].

Administration of a second intraoperative dose of the antimicrobial is required to ensure optimal serum and tissue concentration, if the duration of the procedure exceeds two half-lives of the antimicrobial or there is excessive loss of blood. The interval is defined by the preoperative dose and not by the start of the procedure [30].

Appendicitis is divided into uncomplicated and complicated, the latter including perforated appendicitis, peritonitis or abscess formation. Approximately 80% of appendicitises are uncomplicated. All patients with clinical suspicion of appendicitis, even when not complicated, should receive preoperative intravenous antimicrobials to prevent surgical site infection [31].

The most frequently involved microorganisms are aerobic and anaerobic enteric gram negatives. The most common aerobic is *Escherichia coli* and the anaerobic is *Bacteroides fragilis*. *Streptococci*, *Staphylococcus spp.*, *Enterococcus spp.* Much less frequently *P. aeruginosa* has been reported. The mean surgical site infections reported by the NHSN ranged from 1.15% to 3.47% according to risk. The rate of superficial and deep incisional infections was lower in laparoscopic versus open appendectomy; however, the organ-space infection rate was higher for laparoscopic appendectomy [32].

Recommendations:

- Uncomplicated appendicitis:
  - A single dose of cephalothin + metronidazole.
  - In patients allergic to beta-lactams, clindamycin + gentamicin or a fluoroquinolone is recommended.
  - The duration of prophylaxis should be less than 24 hours.
- Complicated appendicitis:
  - ceftriaxone or cefotaxime + metronidazole with a duration of less than 5 days and complete outpatient treatment for 7 days with amoxicillin/clavulanate.

Current recommendations stipulate that children receive intravenous antibiotics after appendectomy until they tolerate a regular diet and are afebrile. Children who persist with fever or a WBC count greater than 12,000 cell/mm<sup>3</sup> and/or cannot tolerate a regular diet five to seven days after surgery require imaging studies to look for an abdominal or pelvic abscess [33]. In the immediate postoperative period, based on a meta-analysis of 45 studies, initial treatment with intravenous antibiotics significantly reduces wound infection and intra-abdominal abscess formation [34].

Piperacillin may be used with tazobactam as recommended by the American Association for Pediatric Surgery for perforated appendicitis [35]. However, it is important to note that in perforated appendicitis, the microorganisms involved remain covered with the use of third-generation cephalosporins such as ceftriaxone or cefotaxime, adding metronidazole and ampicillin to the coverage of *Enterococcus spp.* antimicrobial pressure on *Pseudomonas spp.*, with the use of Piperacillin with Tazobactam [36].

In retrospective series, single antibiotic therapy (piperacillin/tazobactam, cefoxitin, or ceftriaxone) appears to be as effective as multiple antibiotic therapy (ampicillin, gentamicin, and metronidazole) in preventing complications of

perforated appendicitis, measured by duration of hospital stay, readmission rates and profitability [36].

In a prospective randomized controlled trial of 98 children with perforated appendicitis, metronidazole (30 mg/kg as a single daily dose) and ceftriaxone (50 mg/kg as a single daily dose) were as effective as standard multiple daily doses of ampicillin, gentamicin and clindamycin, to prevent abscesses or wound infections and is a reasonable alternative to piperacillin/tazobactam [36], observed that metronidazole and ceftriaxone once daily was equivalent to ertapenem alone or in combination with cefoxitin in terms of abscesses or other postoperative complications. The length of hospitalization was similar between the groups, however, patients who received the simplified regimen incurred significantly lower antibiotic charges [37]. Studied more than 7,000 children with complicated appendicitis, defined as treatment failure upon readmission of a child within 30 days of the appendectomy, and observed complications in about 6% of patients with complicated appendicitis and in patients receiving extended-spectrum antibiotics [38]. Therefore, the benefits of extended-spectrum antibiotics are unclear. More clinical trials are needed to determine the optimal antibiotic regimen [37].

## **8. Complications**

Some authors have pointed out that the frequency of perforated appendicitis is similar in children as in adults [1]. Samiksha et al., mention that perforated appendicitis occurs more frequently in the pediatric age group and up to 60% in those under 5 years of age, reaching up to 86% in children under one year of age, and therefore, the risk of perforation is directly related to age [1]. The poor ability of young children to communicate clearly can result in a misinterpretation of their symptoms and thus delay the diagnosis, as well as the suspicion of other causes of abdominal pain such as respiratory or gastrointestinal infection as the main diagnosis and not suspecting appendicitis [1].

Perforated appendicitis increases morbidity and intra-abdominal abscesses are the most significant complication. The presence of postoperative abscesses is found between 0% and 4% of cases of uncomplicated appendicitis and their incidence increases from 12–20% in the cases of perforated appendicitis [1].

Another complication is undoubtedly residual cavitary abscesses. The proposal of many textbooks, including Sabiston and Schwartz, who stated that all abscesses should be approached surgically, was a proposal that we rejected. In meticulous clinical observations we found that a laparotomy on an already intervened abdomen is more harmful than beneficial, and after many cases, we find that all of them are susceptible to disappear with antibiotic treatment [14]. Something that still interests us is to know the relationship between this complication and the subsequent presence of another even more serious complication: intestinal obstruction due to fibrous bands with severe ischemia or perforation of a section of the small intestine, were those with the highest mortality due to appendicitis, apart from pneumonia, which was frequently fatal when associated with appendicitis [16].

## **9. Special conditions**

Another area of this topic is related to the management of three different entities: appendicitis in young children, appendicitis modified by inappropriate use of antibiotics and appendicitis in children with psychomotor retardation and suffering severe neurological damage.

The first item is, according to our experience, the most frequent cause of abusive laparotomies in children who undergo emergency surgery. These patients have a totally different course from that seen in older children. It is usual that they begin with generalized severe symptoms, diarrhea, fever and vomiting. Data that change with the passing of the hours, and what were diarrheal evacuations, become a presumed picture of intestinal obstruction, not only from the clinical point of view but especially from the perspective of a vertical X-ray. That progression has led, in our experience, to abusive surgical intervention. To dispel doubts, the correct measure is the pelvic sonogram. Another rarely mentioned complication is the appearance of liver hollow fibers, which are a consequence of the migration via portal of bacterial boluses that lodge in the liver and that require long hospitalizations. Finally, the most serious of all and that has been a consequence of our having had patients who lost their lives, is the postoperative presence of associated pneumonia [14–16].

The second refers to those patients who have previously received antimicrobial treatment. Children with appendicitis without having received at least one antimicrobial were almost never admitted to our hospital unit. We learned that when we carried out the clinical study, we frequently found them asymptomatic. If these children come from the outpatient clinic, we study them more thoroughly, and if they have been hospitalized and were given antibiotics, we almost always take them to the operating room [14–16].

The third item is related to the child who suffers from psychomotor retardation and neurological deterioration. In this section, we are talking particularly about those children who suffer from infantile cerebral palsy and myelomeningocele and less frequently children with trisomy 21. Primarily these children are almost always over 6 years of age and the problem is that the parents do not capture disease manifestations beyond local infections and the urinary tract, and secondly because constipation is almost a rule in them. In these cases, we never operated in the initial stages of the disease and they always harbored a considerable amount of pus, due to the delay in diagnosis [14–16].

In recent months, with the COVID-19 pandemic secondary to the SARS CoV-2 virus, there is a delay in the diagnosis of acute appendicitis in children. Therefore, a perforated appendix was found in almost 39% of these cases in surgery, which significantly increases morbidity, produces complications such as pelvic abscesses, intestinal obstruction and sepsis, and prolongs hospitalization [38].

## **10. Recommendations**

Based on the experience of the group, we recommend starting clear liquid diet for children operated on for uncomplicated appendicitis in the mediate postoperative period, early ambulation and considering discharge to home from 12 to 24 hours later. Under certain conditions, such as careful selection of patients and application of state-of-the-art anesthetic-operative procedures, the operation can be performed with a short-stay surgery program within the safety margins that the quality of the procedures require.

## **Conflict of interest**

The authors declare no conflict of interest.



IntechOpen

## Author details

Alin Villalobos Castillejos<sup>1,2</sup>, Carlos Baeza Herrera<sup>3,4</sup>,  
Miguel Alejandro Sánchez Durán<sup>5</sup>, Jhonatan Mata Aranda<sup>5</sup>,  
Miguel Ángel Minero Hibert<sup>5</sup>, Ricardo Cortés García<sup>6,7\*</sup>  
and Jorge Escorcia Dominguez<sup>8</sup>

1 Department of Pediatric Surgery, Regional Specialty Hospital of Ixtapaluca (HRAEI), UNAM, México

2 Department of Pediatrics, Central North Hospital, PEMEX, México

3 Universidad Nacional Autónoma de México (UNAM), Mexico

4 Nacional Academy of Medicine of Mexico and Mexican Academy of Surgery, Mexico

5 Department of Pediatrics, Regional Specialty Hospital of Ixtapaluca (HRAEI) México

6 Moctezuma Pediatric Hospital, México

7 Hospital of Gynecology and Obstetrics #4 “Luis Castelazo Ayala” Mexican Social Security Institute, México

8 Pediatrician. Private Practice, México

\*Address all correspondence to: dr.ricardocortes@hotmail.com

## IntechOpen

© 2021 The Author(s). Licensee IntechOpen. This chapter is distributed under the terms of the Creative Commons Attribution License (<http://creativecommons.org/licenses/by/3.0>), which permits unrestricted use, distribution, and reproduction in any medium, provided the original work is properly cited. 

## References

- [1] Bansal, S., Banever, G. T., Karrer, F. M., & Partrick, D. A. Appendicitis in children less than 5 years old: Influence of age on presentation and outcome. *American Journal of Surgery*, 2012, 204(6), 1031-1035. <https://doi.org/10.1016/j.amjsurg.2012.10.003>
- [2] Baeza-Herrera C., López-Medina P., Vidal-Medina JM., Cruz-Viruel N., Velasco-S. Enfermedad de Hirschsprung y apendicitis. Una asociación rara. *Acta Pediatr Mex*. 2016 May; 37(3):159-164.
- [3] Rentea RM, St. Peter SD. Pediatric Appendicitis. *Surg Clin North Am* [Internet]. 2017;97(1):93-112. Disponible en: <http://dx.doi.org/10.1016/j.suc.2016.08.009>
- [4] Bhangu A, Søreide K, Di Saverio S, Assarsson JH, Drake FT. Acute appendicitis: Modern understanding of pathogenesis, diagnosis, and management. *Lancet*. 2015;386(10000):1278-87
- [5] Petroianu A, Villar Barroso TV. Pathophysiology of Acute Appendicitis. *JSM Gastroenterol Hepatol*. 2016;4(3):4-7.
- [6] Singh JP, Mariadason JG. Role of the faecolith in modern-day appendicitis. *Ann R Coll Surg Engl*. 2013;95(1):48-51.
- [7] Petroianu A. Diagnosis of acute appendicitis. *Int J Surg* [Internet]. 2012;10(3):115-9. <http://dx.doi.org/10.1016/j.ijsu.2012.02.006>
- [8] D'Souza N, Nugent K. Appendicitis. *Am Fam Physician*. 2016;93(2):142-3.
- [9] Abbas PI, Zamora IJ, Elder SC, Brandt ML, Lopez ME, Orth RC, et al. How Long Does it Take to Diagnose Appendicitis? Time Point Process Mapping in the Emergency Department. *Pediatr Emerg Care*. 2018;34(6):381-4.
- [10] Baeza-Herrera, C., Vidrio-Patrón, F., Barrera-Muñoz, CE., Nájera-Garduño, HM., Velasco-Soria, L. Apendicectomía abierta en programa de corta estancia hospitalaria. *Acta Pediatr Mex* 2011;32(3):147-151
- [11] Nordin, A. B., Diefenbach, K., Sales, S. P., Christensen, J., Besner, G. E., & Kenney, B. D. Gangrenous appendicitis: No longer complicated. *Journal of Pediatric Surgery*, 2019, 54(4), 718-722. <https://doi.org/10.1016/j.jpedsurg.2018.10.064>
- [12] Rentea, R. M., & St. Peter, S. D. Pediatric Appendicitis. *Surgical Clinics of North America*. W.B. Saunders 97 (2017), pp. 93-112. <https://doi.org/10.1016/j.suc.2016.08.009>
- [13] Macco, S., Vrouenraets, B. C., & de Castro, S. M. M. Evaluation of scoring systems in predicting acute appendicitis in children. *Surgery (United States)*, 2016, 160(6), 1599-1604. <https://doi.org/10.1016/j.surg.2016.06.023>
- [14] López, T.R., Escobar I,A,M., León C, A. Baeza-Herrera, C. Apendicitis aguda. In Baeza-Herrera, C. Coloproctología en la infancia y adolescencia. Ed. Alfil. 1era Edición. 2004. Pp 251-268. ISBN 968-7620-11-0
- [15] Baeza-Herrera, C., Vidrio-Patrón, F., Barrera-Muñoz, C.E., Nájera-Garduño, HM., Velasco-Soria, L. Apendicectomía abierta en programa de corta estancia hospitalaria. *Acta Pediatr Mex* 2011;32(3):147-151. DOI: <http://dx.doi.org/10.18233/APM32No3pp147-151>
- [16] Baeza-Herrera, C., García-Cabello, LM., Villalobos-Ayala, D., Domínguez-Pérez, ST., Mora-Hernández F. Isquemia intestinal por laparotomía previa. *Gac Med Mex*. 2003;139(5):465-469.
- [17] Wijkerslooth, EML Et Al. Postoperative Outcomes of Patients

- With Nonperforated Gangrenous Appendicitis: A National Multicenter Prospective Cohort Analysis. *Dis Colon rectum*. 2019 Nov;62(11):1363-1370. doi: 10.1097/DCR.0000000000001466. PMID: 31596762.
- [18] Martijn W.J. Stommel, Chema Strik, Harry van Goor, M. Response to pathological processes in the peritoneal cavity—Sepsis, tumours, adhesions, and ascites. *Seminars in Pediatric Surgery*. 2014. 23(6), 331-335. <https://doi.org/10.1053/j.sempedsurg.2014.06.003>.
- [19] Cinel I, Opal SM. Molecular biology of inflammation and sepsis: a primer. *Crit Care Med*. 2009 Jan;37(1):291-304. doi: 10.1097/CCM.0b013e31819267fb. PMID: 19050640.
- [20] Singer, M., Deuytsman, C., Warreb Seymour, C., Shankar-Hari, M., Annane, D., Bauer, M., et al. The Third International Consensus Definitions for Sepsis and Septic Shock (Sepsis-3). *JAMA*. 2016 Feb 23;315(8):801-10. doi: 10.1001/jama.2016.0287. PMID: 26903338; PMCID: PMC4968574.
- [21] Goldstein B, Giroir B, Randolph A; International Consensus Conference on Pediatric Sepsis. International pediatric sepsis consensus conference: definitions for sepsis and organ dysfunction in pediatrics. *Pediatr Crit Care Med*. 2005 Jan;6(1):2-8. doi: 10.1097/01.PCC.0000149131.72248.E6. PMID: 15636651. Epub 2017 Dec 19. PMID: 29256116; PMCID: PMC5816088.
- [22] Schlapbach LJ, Straney L, Bellomo R, MacLaren G, Pilcher D. Prognostic accuracy of age-adapted SOFA, SIRS, PELOD-2, and qSOFA for in-hospital mortality among children with suspected infection admitted to the intensive care unit. *Intensive Care Med*. 2018 Feb;44(2):179-188. doi: 10.1007/s00134-017-5021-8.
- [23] Holcomb GW, St Peter SD. Current management of complicated appendicitis in children. *Eur J Pediatr Surg*. 2012; 22:207-212.
- [24] Le D, Rusin W, Hill B, Langer J. Port-operative antibiotic use in non-perforated appendicitis. *Am J Surg*. 2009; 198 (6): 748-452.
- [25] Bratzler DW, Patchen DE, Olsen KM, Perl TM, Auwaerter PG, Bolon MK. Clinical practice guidelines for antimicrobial prophylaxis in surgery. *Am J Health Syst Pharm* 2013; 70 (1): 195-283.
- [26] Mangram AJ, Horas TC, Pearson ML, Silver LC, Jarvis WR. Guideline for prevention of surgical site infection 1999. *Infect Control Hosp Epidemiol* 1999; 20 (4) 249-264
- [27] Anderson DJ, Kaye KS, Classen D, Arias KM, Podgorny K, Burstin H, et al. Strategies to prevent surgical site infections in acute care hospitals. . *Infect Control Hosp Epidemiol* 2008; 9 (S1): 51-58.
- [28] Grenc MG, Derganc M, Trsinar B, Cizman M. Antibiotic prophylaxis for surgical procedures on children. *J Chem* 2006; 18 (1): 38-42
- [29] Hamdan-Oartida A, Sainz-Espuñes T, Bustos-Martínez J. Characterization of persistence of *Staphylococcus aureus* strains isolated from the anterior nares and throats of healthy carriers in Mexican Community. *J Clin Microbiol* 2010; 48 (5): 1701-1705.
- [30] Bhangu A, Søreide K, Di Saverio S, Assarsson JH, Drake FT. Acute appendicitis: Modern understanding of pathogenesis, diagnosis, and management. *Lancet*. 2015;386 (10000):1278-87
- [31] Bansal, S., Banever, G. T., Karrer, F. M., & Partrick, D. A. Appendicitis in children less than 5 years old: Influence of age on presentation and outcome. *American Journal of Surgery*, 2012,

204(6), 1031-1035. <https://doi.org/10.1016/j.amjsurg.2012.10.003>

[32] Petroianu A, Villar Barroso TV. Pathophysiology of Acute Appendicitis. *JSM Gastroenterol Hepatol*. 2016;4(3):4-7.

[33] Nordin, A. B., Diefenbach, K., Sales, S. P., Christensen, J., Besner, G. E., & Kenney, B. D. Gangrenous appendicitis: No longer complicated. *Journal of Pediatric Surgery*, 2019, 54(4), 718-722. <https://doi.org/10.1016/j.jpedsurg.2018.10.064>

[34] D'Souza N, Nugent K. Appendicitis. *Am Fam Physician*. 2016;93(2):142-3.

[35] Anderson DJ. Surgical Site Infections. *Infect Dis Clin N Am* 2011; 25: 135-153.

[36] Andersen BR, Kellenhave FL, Andersen HK. Antibiotics versus placebo for prevention of postoperative infection after appendicectomy. *Cochrane Database Syst Rev*. 2005; 3.

[37] Kirby JP, Mazuski JE. Prevention of surgical site infection. *Surg Clin N Am* 2009; 89: 365-389.

[38] Rick Place, MHA., Jonathan Lee., John Howell. Rate of Pediatric Appendiceal Perforation at a Children's Hospital During the COVID-19 Pandemic Compared With the Previous Year. *JAMA Network Open*. 2020;3(12):e2027948. doi:10.1001/jamanetworkopen.2020.27948