

# We are IntechOpen, the world's leading publisher of Open Access books Built by scientists, for scientists

6,900

Open access books available

186,000

International authors and editors

200M

Downloads

Our authors are among the

154

Countries delivered to

TOP 1%

most cited scientists

12.2%

Contributors from top 500 universities



WEB OF SCIENCE™

Selection of our books indexed in the Book Citation Index  
in Web of Science™ Core Collection (BKCI)

Interested in publishing with us?  
Contact [book.department@intechopen.com](mailto:book.department@intechopen.com)

Numbers displayed above are based on latest data collected.  
For more information visit [www.intechopen.com](http://www.intechopen.com)



# Common Congenital Neural Tube Anomalies: Epidemiology, Classification, Management and Outcome

*Mohammad Hossein Khosravi and Bita Najafian*

## Abstract

The prevalence of Congenital central nervous system (CNS) anomalies, including those of the brain and spinal cord, is 3 to 6% in stillbirth and 0.14 to 0.16% in live births. Holoprosencephaly, spina bifida, anencephaly, and encephalocele are major neural tube defects (NTD) encountered in clinical practice. Proper management and diagnosis of these conditions mandate a good understanding of their etiology and classification. Research is being conducted to investigate the etio-pathogenesis and treatment of these anomalies. In this chapter, we have reviewed the clinical and pathological aspects of the major NTDs and the latest principles of their management.

**Keywords:** the central nervous system, congenital anomalies, Fetal CNS anomalies, Neural Tube Defects

## 1. Introduction

Until recently, central nervous system (CNS) malformations were the second most common congenital abnormalities after congenital cardiac defects [1, 2]. Recent reports have documented CNS malformations to be the most common anomalies among all systems, with a prevalence of 3 to 6% in stillbirth and 0.14 to 0.16% in live births [3]. There is limited information about the precise etiology of congenital CNS anomalies, and most of the cases are idiopathic. It is speculated that a combination of genetic and environmental factors plays a major role in the pathogenesis of these defects [4]. Management and diagnosis of these conditions are challenging and require a proper understanding of their etiology and categories.

CNS anomalies (CNSA) include those of the spinal cord (such as meningocele, myelomeningocele, and encephalocele) and brain (including growth disorders of the cerebrum, cerebellum, and brain stem) [5]. CNSA may be associated with other anomalies pertaining to other systems as well, such as those of the heart [6]. These malformations need complex surgeries along with long-term intensive care and impose a significant financial impact on the families and healthcare system. In this chapter, we review the classification, epidemiology, and the newest modalities of treatment of congenital CNS anomalies with respect to NTDs.

## 2. Incidence

Despite remarkable developments in diagnostic technologies and therapeutic modalities, the epidemiology of congenital CNS anomalies has not changed significantly. The prevalence of CNSA varies widely according to geographic regions and socioeconomic situations and is reported to be between 1 and 10 in every 1000 live births [7, 8]. The incidences of anencephaly and spina bifida per 10000 births range from 0.7 in central France to 0.9 in Canada, 7.7 in the United Arab Emirates, and 11.7 in South America [9]. A recently published systematic review and meta-analysis, which included 6558 infants, has reported a prevalence of occult spinal dysraphism (OSD) with cutaneous stigmata to be 2.8% [10].

## 3. Classification

In general, NTDs are classified into open and closed defects [11].

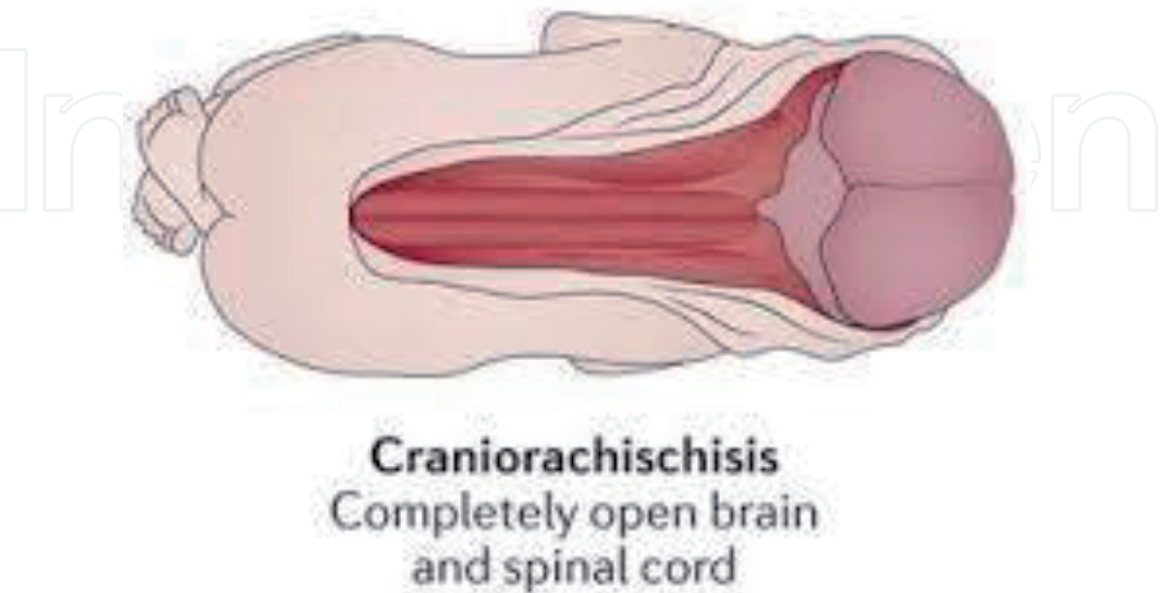### 3.1 Open NTDs

#### 3.1.1 Craniorachischisis

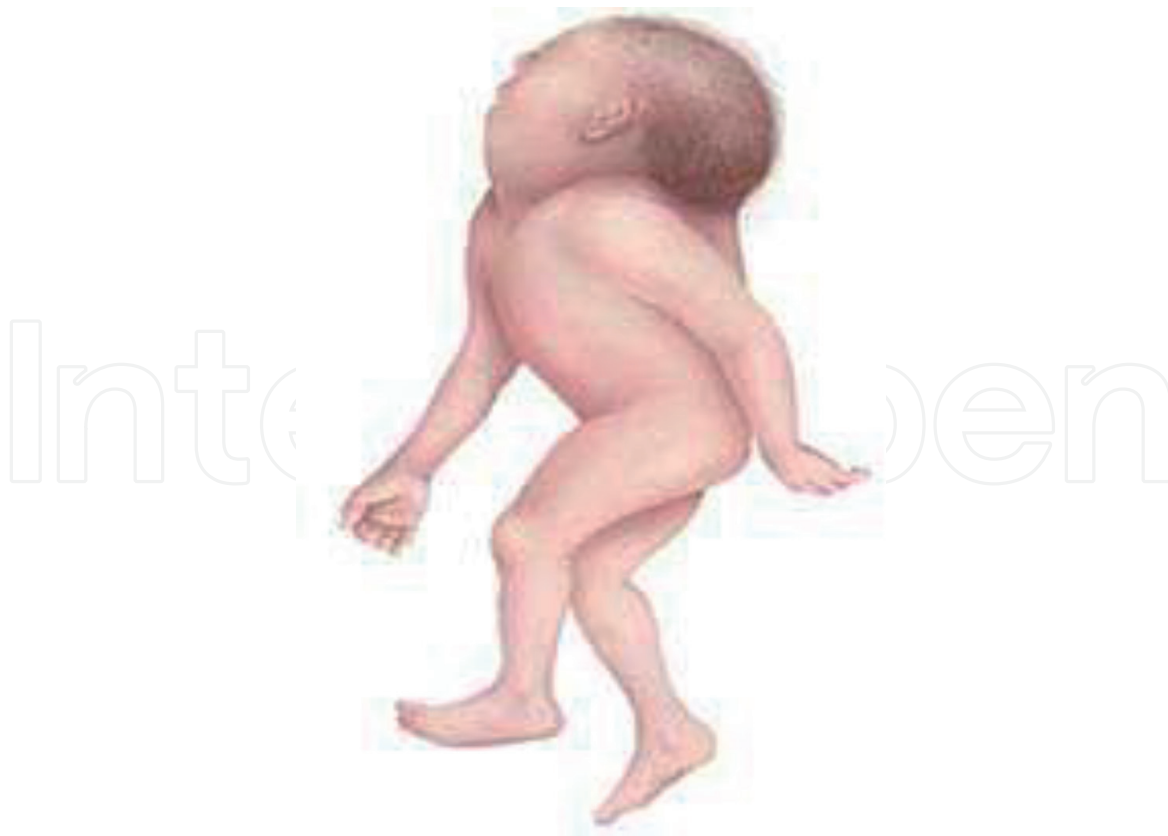This is the most severe presentation of NTDs and involves both the spinal and cranial parts of the neural tube (**Figure 1**) [12]. Craniorachischisis is a combination of anencephaly with a contiguous bony defect of the spine, both without the neural tissue's meningeal cover.

#### 3.1.2 Iniencephaly

It is a rare severe defect of the occipital bone, with cervical spina bifida and retroflexion of the head on the cervical spine. An occipital encephalocele may be present. Like anencephaly, there is a strong female preponderance (**Figure 2**).



**Figure 1.**  
*Diagram of Craniorachischisis.*



**Figure 2.**  
*Diagram of iniencephaly.*

### 3.1.3 Anencephaly

In this defect, the cranial portion of the neural tube fails to close, resulting in exencephaly. This ends up in the neural tissue getting a destructive exposure to an intra-amniotic environment which turns the exencephaly into anencephaly (**Figure 3**) [12].

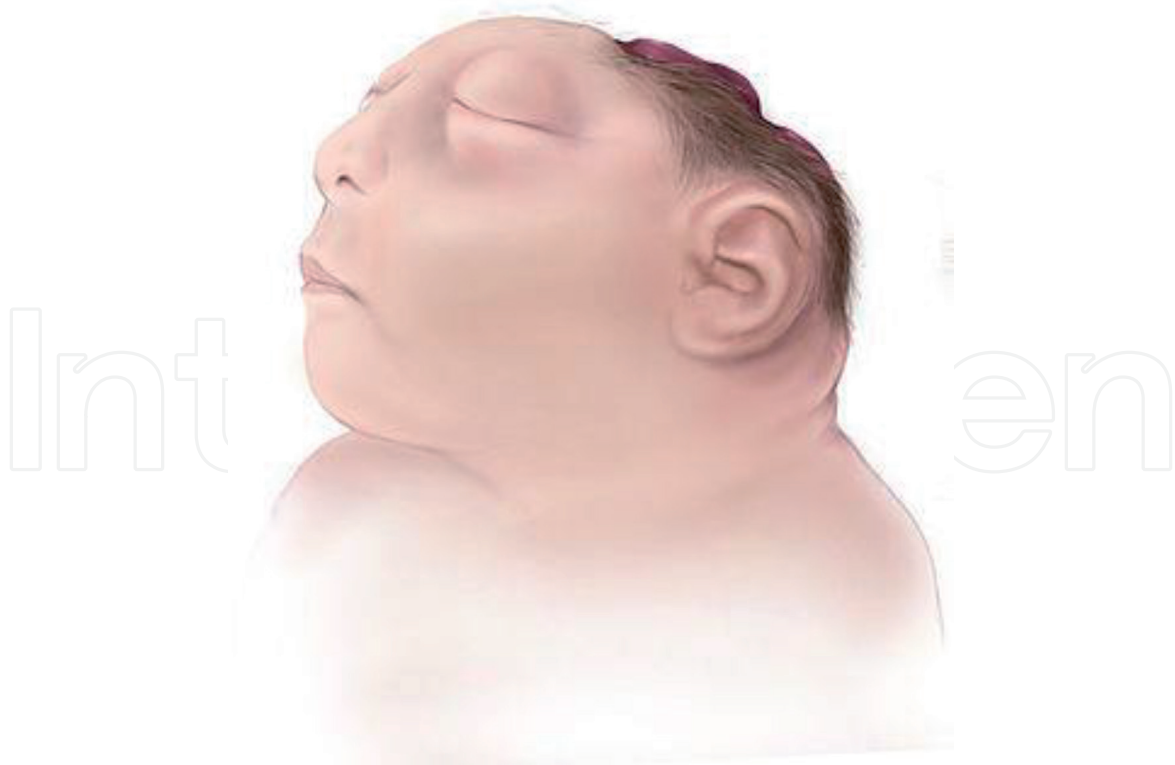### 3.1.4 Myelomeningocele

In this defect, the posterior part of the spinal portion of the neural tube fails to close; This defect occurs most commonly in the lumbar region. A bony defect in the vertebral arch provides the condition for the meningeal sac to herniate (**Figure 4**). Myelocoele is a similar condition that involves the spinal cord without protrusion of the meningeal sac.

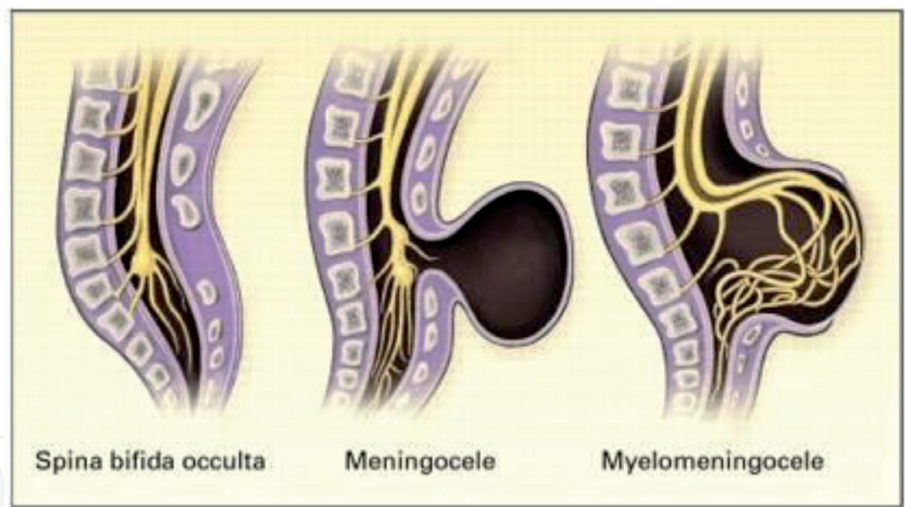
## 3.2 Closed NTDs

### 3.2.1 Encephalocele

It is defined as a sac-like protrusion of the brain accompanied with or without meninges through an opening in the skull (**Figure 5**). According to the type of involved tissues, encephaloceles are classified as meningocele (herniation of meninges), encephalomeningocele (herniation of both meninges and brain), and encephalomeningocystocele (herniation of meninges, brain, and ventricle).



**Figure 3.**  
*Diagram showing anencephaly.*



**Figure 4.**  
*Diagram showing spina bifida occulta, meningocoele and myelomeningocoele.*

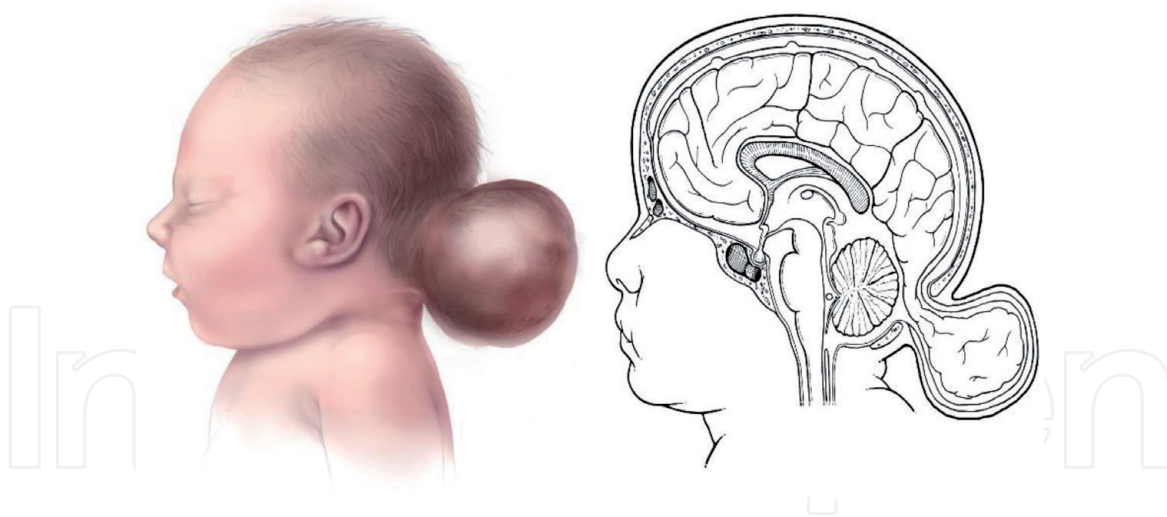
### 3.2.2 Meningocele

Meningocele is the protrusion of meninges through the vertebral arch defect without the spinal cord (**Figure 4**) [13]. This defect is macroscopically similar to myelomeningocele with differences in the contents of the herniated sac.

### 3.2.3 Spina bifida Occulta

Abnormal development of the embryonic tail bud results in a wide range of spinal cord abnormalities grouped as spina bifida occulta (**Figure 2**). It is generally accompanied by other skeletal defects such as sacral agenesis. The anomaly mostly involves sacral and lower lumbar vertebrae.





**Figure 5.**  
*Diagrams of encephalocele.*

#### 4. Etiology and embryology

Despite recent progress in epidemiologic and clinical research, the exact etiology of NTDs has remained undetermined. It is in common agreement that the interactions between genetic and environmental factors are the possible etiopathogenic factors [14, 15]. More than 70% of cases of NTDs are found to have a genetic etiology [16].

Some of the potential non-genetic environmental risk factors for NTD-affected pregnancy are poor socioeconomic status, maternal hyperthermia; maternal exposure to high doses of irradiation, certain chemicals, and drugs; cigarette smoking; maternal metabolic diseases, and advanced parental age, including those of both mother and father. Pregnancies associated with a fetus with NTD have higher chances of going into preterm labor and being delivered prematurely [5, 17, 18]. In 2008, a large study in California reported that mothers who do not graduate from high school or live in neighborhoods under poor socioeconomic conditions have a greater risk of delivering an NTD-affected child [19]. Brough et al. elaborated in their study that the mothers with higher socioeconomic and educational levels are more likely to consume folic acid during preconception and early gestational age when the neural tube is developing [20], and this might have contributed to the findings of the California study. A meta-analysis regarding the effect of maternal age on the risk of NTD reported that mothers older than 40 and younger than 19 years of age had increased risks of NTD-affected pregnancies [21], the chances being higher for spinal Bifida but not for anencephaly. Studies have assessed the role of parental occupational exposures in the development of NTDs. Brender et al. found self-reported multiple pesticide exposure to be a risk factor for fetal NTD [22]. The role of paternal exposures to hazardous materials in increasing the risk of NTDs in offsprings was emphasized when studies showed that fathers who work as a cook, gardener, janitor, and cleaner have higher chances of getting a child with spina bifida, as these professions have a higher likelihood of exposure to hazardous chemicals [23]. The occupational exposure of fathers to metal-working oil mists and hydrocarbons do not show any association with NTD risk [24]. Caffeine has been investigated as another risk factor for NTDs. Past studies have shown that higher Caffeine consumption during the year before pregnancy increases the risk of spina bifida [25]. The use of antimicrobial medications during the preconception period and first trimester of pregnancy are found to be associated with a higher risk of anencephaly [26].

## 4.1 Genetics of congenital CNS anomalies

In addition to the potential environmental risk factors as outlined above, congenital CNSA may be a consequence of genetic disorders. NTD, including encephalocele, spina bifida, and exencephaly, have become less prevalent since the widespread consumption of folic acid by pregnant women. So the etiology has shifted toward mutations in folate-responsive or folate-dependent pathways [27]. Knowing the underlying genetic disorders for congenital CNS anomalies helps in counseling about the existing pregnancy, as well as the risk of recurrence in future ones. Sophisticated genetic investigations are available to detect chromosomal anomalies in the cases of NTD.

While a low rate of karyotype abnormality has been reported in isolated ventriculomegaly (0 to 3.8%) [28], Dandy-Walker malformation has been associated with 50% of aneuploidies if associated with other anomalies [29]. In a nearly similar pattern, isolated holoprosencephaly is not accompanied by any significant genetic anomaly; however, 25 to 50% of cases have been reported to have aneuploidies if associated with other organ anomalies. Holoprosencephaly is detected in 70% of Trisomy 13 cases. In the cases with NTDs, Trisomy 13 and 18 are the most commonly reported aneuploidies [30]. Studies have reported notable connections between deletions on the long arm of the 13th chromosome and CNS anomalies [31].

Genes participating in folate metabolism have been studied for the pathogenesis of NTDs. The C677T and A1298C polymorphisms of methylenetetrahydrofolate reductase (MTHFR), encode a key enzyme of folate metabolism responsible for homocysteine remethylation [16]. These polymorphisms are associated with a 1.8fold increase in the risk of NTDs. More than 200 genetic models of NTD have been described in mice that can affect the open NTD phenotypes, such as anencephaly, open spina bifida and craniorachischisis. Their roles in human NTDs are understudy. Some inbred strain variation in the penetrance and expressivity of NTD phenotypes in mice have suggested the roles of modifier gene function. The *Cecr2* mutation that causes exencephaly in mice is strongly affected in its expression by one or more modifier genes on Chromosome 19. Strain differences have also been described for non-genetic causes of NTD, including hypoglycemia, hyperthermia, valproic acid, and cytochalasins.

## 4.2 Embryologic formation of neural tube

Formation of the brain and spinal cord begins with the development of the neural tube through the embryonic process of neurulation. The neural tube is the origin of the brain and spinal cord. The process of neurulation, has two separate phases in mammalian embryos, termed primary and secondary neurulation [32].

Primary neurulation occurs in the third and fourth weeks of development, during which the flat layer of ectodermal cells is transformed into a hollow tube. On the 18th day of fertilization, the neural plate is formed by a thickening of the embryonal midline dorsal ectoderm. The neural plate develops from the cranial end of the embryo moving toward the caudal end. *This sentence is deleted* ---Then, the edges of the neural plate move upward to form the neural fold---. On 19th day, the border of the neural plate becomes elevated and folds longitudinally from the head to the tail, which results in the formation of a neural groove. By the 23rd day, the folds get merged and make the neural tube which is open at both ends. "Closure," a process in which both open ends of the neural tube (neuropores) are closed, occurs on the 26th and 28th day of gestational age in rostral and caudal ends, respectively. This neural tube closure is initiated at the hindbrain/cervical boundary (Closure 1).

Fusion extends into the hindbrain and along the spinal region, leading to several closure sites appearing at the midbrain/forebrain boundary (Closure 2) and at the rostral extremity of the forebrain (Closure 3). The progression of fusion ('zippering') continues along the spine, ending in the last closure at the posterior neuropore at the level of the second sacral segment. This process of neural folding is called 'primary' neurulation.

Stem cell proliferation is the main mechanism involved in secondary neurulation, which is limited to the tailbud. During this process, a rod-like condensation is formed, which subsequently becomes cavitated. Cavitation transforms the rod into a tube which remains in continuation with the tube constructed as the result of primary neurulation. Tail bud develops in tailed mammals, and as the anatomy of humans is tailless, secondary neurulation does not seem to be involved in the formation of neural tube defects [8]. Instead, the lateral sclerotome cells derived from the multipotential tail bud cell population organize themselves around the secondary neural tube to form the sacral and coccygeal vertebrae. Subsequently, the caudal-most neural tube degenerates via apoptosis.

Primary neurulation is essential for the formation of the brain and spinal cord. Failure of Closure 1 leads to the most severe NTD, called craniorachischisis, which comprises an open neural tube encompassing the midbrain, hindbrain, and spinal region. In the presence of normal completion of closure one incomplete closure of the cranial neural tube leads to anencephaly with may have the defect confined to the midbrain (meroanencephaly) or extending into the hindbrain (holoanencephaly). Failure of Closure 3 is uncommon and presents with abnormal face with anencephaly. In the spinal region, failure of final closure at the posterior neuropore yields an open spina bifida (myelomeningocele). In this anomaly, the upper limit of SB depends upon the timing of the arrest of the progression of zippering and, as such, may end up at varying axial levels.

A hypothesis forwarded by Morgagni believes that the increased intraventricular pressure caused by over-production of cerebrospinal fluid (CSF), leads to the reopening of an already closed neural tube [33–35].

## **5. Diagnosis**

### **5.1 Laboratory-based diagnosis of NTDs**

Maternal serum alpha-fetoprotein blood levels are used for the screening of CNS anomalies in the fetus, in addition to magnetic resonance imaging or ultrasonography [36, 37].

### **5.2 Imaging-based diagnosis of NTDs**

Fetal magnetic resonance imaging (MRI) was first reported in 1983 [38]. In the late 1990s, fast-sequence MRI was introduced (which eliminated the need for maternal sedation), and fetal MRI was preferred by clinicians [39]. Many studies have reported MRI to be a more accurate technique for diagnosing fetal CNS anomalies compared to ultrasound [40, 41].

In 2014, a systematic review was conducted by Rossi et al., which included 13 original articles and 710 fetuses. This report documented that in addition to confirming the US findings in 65.4% of cases, MRI provides additional information (especially about midline anomalies) in 22.1% of cases [37]. Overall, MRI was able to identify CNS anomalies in 18.4% of cases. Ultrasound was more accurate than MRI in 2% of cases. In 30% of cases, the MRI findings of fetal visualization were



different from US findings enough to change the management. They reported a false-positive rate of 2.5% in diagnosing conditions like midline anomalies, hemorrhage, and cell-proliferation disorders by MRI. It is suggested that clinicians should combine fetal MRI with 2- or 3-D-US in order to reduce false-positive diagnosis and increase the sensitivity [42].

It is known that the placenta plays a key role in the fetal development and in protecting the fetus against the maternal immune system and pathogens. There are correlations between placental dysfunction and neurodevelopmental injury [43, 44], and placental ischemia and inflammation can damage the developing fetal CNS. Fetal MRI provides the opportunity to accurately assess *in vivo* fetal placental and brain function [45]. In intrauterine growth restricted conditions, placentas have decreased volume as well as lower apparent diffusion coefficient (ADC) values [46–48]. Shapira-Zaltsberg et al., in an interesting study in 2017, evaluated the MRI characteristics of the placenta in fetuses with and without CNS anomalies. They concluded that in diffusion-weighted imaging (DWI) of fetal MRI, restricted diffusion in placenta as well as reduced ADC values are accompanied with fetal CNS abnormalities [43].

## **6. Clinical presentation, management, and outcomes**

Clinical presentations are highly dependent on the type, size, and location of abnormalities, varying from no evident symptoms to lifelong disabilities and even death [10].

### **6.1 Craniorachischisis**

This anomaly is lethal and has no cure or surgical management.

### **6.2 Anencephaly**

Being a condition incompatible with survival, anencephaly diagnosed during early pregnancy may result in a legal interruption of pregnancy. The majority of anencephalic newborns die within the first day of birth. Surgical treatment is not indicated [49].

### **6.3 Myelomeningocele**

If the infant is not affected by other serious anomalies or malformations, most cases with myelomeningocele or myelocele survive with a wide range of neurological impairments. The level of the defect is a determining factor of the clinical characteristics. In levels below the spinal lesion, patients may face a variety of motor and sensory deficits, including bladder incontinence or sexual dysfunction [50]. Most of these lesions are managed by surgical intervention, followed by rehabilitation.

### **6.4 Encephalocele**

Content and location of the herniated mass is a predictive marker of prognosis and clinical manifestations. “The more rostral the site, the better the prognosis” [50]. Epilepsy, sensorial or motor neuron dysfunction, or various degrees of developmental deficiencies may occur in cases due to mechanical effects of traction and distortion on the brain stem [51]. Some patients may take benefits from surgical intervention.

## 6.5 Meningocele

Patients usually have a normal neurological examination with no evident sphincter dysfunction or deformity of the lower extremities. A simple surgical correction is the main treatment method.

## 6.6 Spina Bifida Occulta

Children with spina bifida have a higher first-year mortality rate in comparison with the general population [14]. Researchers have shown that children with Spina Bifida have increased sedentary behaviors and lower physical activity levels than their healthy counterparts [52]. This increases the risk of various comorbidities such as diabetes, obesity, thrombosis, etc. Most commonly, this malformation is diagnosed later in life as it has no evident neurological manifestations and disabilities. The neurological symptoms may occur when the spinal cord faces damage or traction. In symptomatic patients, neurosurgical intervention is the main therapeutic method.

## 7. Future direction

An extensive review of the literature shows a dearth of epidemiologic and etiological studies. More original studies and meta-analyses are needed to understand the genetic and environmental risk factors of NTDs. Although most of the established surgical interventions have positive effects, prevention remains the best strategy in the management of NTDs.

## Author details

Mohammad Hossein Khosravi<sup>1,2</sup> and Bita Najafian<sup>3\*</sup>

1 Functional Neurosurgery Research Center, Shohada Tajrish Comprehensive Neurosurgical Center of Excellence, Shahid Beheshti University of Medical Sciences, Tehran, Iran

2 Department of Research, Arka Education and Clinical Research Consultants, Tehran, Iran

3 Department of Pediatrics, Faculty of Medicine, Baqiyatallah University of Medical Sciences, Tehran, Iran

\*Address all correspondence to: [dr.najafian@yahoo.com](mailto:dr.najafian@yahoo.com)

## IntechOpen

© 2021 The Author(s). Licensee IntechOpen. This chapter is distributed under the terms of the Creative Commons Attribution License (<http://creativecommons.org/licenses/by/3.0>), which permits unrestricted use, distribution, and reproduction in any medium, provided the original work is properly cited. 

## References

- [1] Icenogle DA, Kaplan AM. A review of congenital neurologic malformations. *Clinical pediatrics*. 1981;20(9):565-76.
- [2] Aydın E, Tanacan A, Büyükeren M, Uçkan H, Yurdakök M, Beksac MS. Congenital central nervous system anomalies: Ten-year single center experience on a challenging issue in perinatal medicine. *Journal of the Turkish German Gynecological Association*. 2019;20(3):170.
- [3] Ekmekci E, Demirel E, Gencdal S. Conventional Chromosome Analysis of Fetuses with Central Nervous System Anomalies and Associated Anomalies: Is Anything Changed? *Medical Sciences*. 2018;6(1):10.
- [4] Mashuda F, Zuechner A, Chalya PL, Kidenya BR, Manyama M. Pattern and factors associated with congenital anomalies among young infants admitted at Bugando medical centre, Mwanza, Tanzania. *BMC research notes*. 2014;7(1):1-7.
- [5] Kinsman SL, Johnston MV, Kliegman RM, Stanton FB, Jenson HB, Behrman RE. *Nelson Text book of pediatrics*. 19th ed. Philadelphia: Saunders; 2011. Congenital anomalies of the central nervous system; pp. 1998-2013.
- [6] Hadžagić-Ćatibušić F, Maksić H, Užičanin S, Heljić S, Zubčević S, Merhemić Z, et al. Congenital malformations of the central nervous system: clinical approach. *Bosnian Journal of Basic Medical Sciences*. 2008;8(4):356.
- [7] De LN, Medeiros F, Martins V, Sampaio G, Serapiao M, Kastin G, et al. Malformations of the central nervous system: analysis of 157 pediatric autopsies. *Arquivos de neuro-psiquiatria*. 2000;58(3B):890-6.
- [8] Detrait ER, George TM, Etchevers HC, Gilbert JR, Vekemans M, Speer MC. Human neural tube defects: developmental biology, epidemiology, and genetics. *Neurotoxicology and teratology*. 2005;27(3):515-24.
- [9] Rimoin DL, Connor JM, Pyeritz RE, Korf BR. *Emery and Rimoin's principles and practice of medical genetics*: Churchill Livingstone Elsevier; 2007.
- [10] Choi SJ, Yoon HM, Hwang JS, Suh CH, Jung AY, Cho YA, et al. Incidence of occult spinal dysraphism among infants with cutaneous stigmata and proportion managed with neurosurgery: a systematic review and meta-analysis. *JAMA network open*. 2020;3(7):e207221-e.
- [11] Avagliano L, Massa V, George TM, Qureshy S, Bulfamante GP, Finnell RH. Overview on neural tube defects: From development to physical characteristics. *Birth defects research*. 2019;111(19):1455-67.
- [12] Stewart W. *Pathology and genetics: developmental neuropathology*. Wiley Online Library; 2005.
- [13] McComb JG. A practical clinical classification of spinal neural tube defects. *Child's Nervous System*. 2015;31(10):1641-57.
- [14] Frey L, Hauser WA. Epidemiology of neural tube defects. *Epilepsia*. 2003;44:4-13.
- [15] Padmanabhan R. Etiology, pathogenesis and prevention of neural tube defects. *Congenital anomalies*. 2006;46(2):55-67.
- [16] Copp AJ, Greene ND. Neural tube defects--disorders of neurulation and related embryonic processes. *Wiley Interdiscip Rev Dev Biol*. 2013 Mar-Apr;2(2):213-27. DOI: 10.1002/wdev.71.

Epub 2012 May 29. PMID: 24009034;  
 PMCID: PMC4023228.

[17] Taksande A, Vilhekar K, Chaturvedi P, Jain M. Congenital malformations at birth in Central India: A rural medical college hospital based data. *Indian journal of human genetics*. 2010;16(3):159.

[18] Little J, Cardy A, Arslan M, Gilmour M, Mossey P, includes IMc. Smoking and orofacial clefts: a United Kingdom-based case-control study. *The Cleft palate-craniofacial journal*. 2004;41(4):381-6.

[19] Grewal J, Carmichael SL, Song J, Shaw GM. Neural tube defects: an analysis of neighbourhood-and individual-level socio-economic characteristics. *Paediatric and perinatal epidemiology*. 2009;23(2):116-24.

[20] Brough L, Rees G, Crawford M, Dorman E. Social and ethnic differences in folic acid use preconception and during early pregnancy in the UK: effect on maternal folate status. *Journal of human nutrition and dietetics*. 2009;22(2):100-7.

[21] Vieira AR. Maternal age and neural tube defects: evidence for a greater effect in spina bifida than in anencephaly. *Revista medica de Chile*. 2005;133(1):62-70.

[22] Brender JD, Felkner M, Suarez L, Canfield MA, Henry JP. Maternal pesticide exposure and neural tube defects in Mexican Americans. *Annals of epidemiology*. 2010;20(1):16-22.

[23] Shaw GM, Nelson V, Olshan AF. Paternal occupational group and risk of offspring with neural tube defects. *Paediatric and perinatal epidemiology*. 2002;16(4):328-33.

[24] Fear NT, Hey K, Vincent T, Murphy M. Paternal occupation and neural tube defects: a case-control study

based on the Oxford Record Linkage Study register. *Paediatric and perinatal epidemiology*. 2007;21(2):163-8.

[25] Schmidt RJ, Romitti PA, Burns TL, Browne ML, Druschel CM, Olney RS. Maternal caffeine consumption and risk of neural tube defects. *Birth Defects Research Part A: Clinical and Molecular Teratology*. 2009;85(11):879-89.

[26] Crider KS, Cleves MA, Reefhuis J, Berry RJ, Hobbs CA, Hu DJ. Antibacterial medication use during pregnancy and risk of birth defects: National Birth Defects Prevention Study. *Archives of pediatrics & adolescent medicine*. 2009;163(11):978-85.

[27] Goetzinger KR, Stamilio DM, Dicke JM, Macones GA, Odibo AO. Evaluating the incidence and likelihood ratios for chromosomal abnormalities in fetuses with common central nervous system malformations. *American journal of obstetrics and gynecology*. 2008;199(3):285. e1-. e6.

[28] Pilu G, Falco P, Gabrielli S, Perolo A, Sandri F, Bovicelli L. The clinical significance of fetal isolated cerebral borderline ventriculomegaly: report of 31 cases and review of the literature. *Ultrasound in Obstetrics and Gynecology: The Official Journal of the International Society of Ultrasound in Obstetrics and Gynecology*. 1999;14(5):320-6.

[29] Forzano F, Mansour S, Ierullo A, Homfray T, Thilaganathan B. Posterior fossa malformation in fetuses: a report of 56 further cases and a review of the literature. *Prenatal Diagnosis: Published in Affiliation With the International Society for Prenatal Diagnosis*. 2007;27(6):495-501.

[30] Ekin A, Gezer C, Taner C, Ozeren M, Ozer O, Koç A, et al. Chromosomal and structural anomalies in fetuses with open neural tube defects.



Journal of Obstetrics and Gynaecology. 2014;34(2):156-9.

[31] Ballarati L, Rossi E, Bonati MT, Gimelli S, Maraschio P, Finelli P, et al. 13q Deletion and central nervous system anomalies: further insights from karyotype–phenotype analyses of 14 patients. *Journal of Medical Genetics*. 2007;44(1):e60-e.

[32] Purves D. *Principles of neural development*: Sinauer Associates, Incorporated; 1985.

[33] Recklinghausen Fv. *Untersuchungen über die Spina bifida*: Walter de Gruyter GmbH & Co KG; 2018.

[34] Padmanabhan R. Experimental induction of cranioschisis aperta and exencephaly after neural tube closure: a rat model. *Journal of the neurological sciences*. 1984;66(2-3):235-43.

[35] Morgagni G. *The Seats and Causes of Diseases, Investigated by Anatomy*, 3 vols., trans. Benjamin Alexander (London: A Millar et al, 1769).1(652):48-9.

[36] Kehl S, Schelkle A, Thomas A, Puhl A, Meqdad K, Tuschy B, et al. Single deepest vertical pocket or amniotic fluid index as evaluation test for predicting adverse pregnancy outcome (SAFE trial): a multicenter, open-label, randomized controlled trial. *Ultrasound in Obstetrics & Gynecology*. 2016;47(6):674-9.

[37] Rossi A, Prefumo F. Additional value of fetal magnetic resonance imaging in the prenatal diagnosis of central nervous system anomalies: a systematic review of the literature. *Ultrasound in Obstetrics & Gynecology*. 2014;44(4):388-93.

[38] Smith FW, Adam AH, Phillips WP. NMR imaging in pregnancy. *The Lancet*. 1983;321(8314):61-2.

[39] Kandula T, Fahey M, Chalmers R, Edwards A, Shekleton P, Teoh M, et al. Isolated ventriculomegaly on prenatal ultrasound: what does fetal MRI add? *Journal of medical imaging and radiation oncology*. 2015;59(2):154-62.

[40] Griffiths P, Porteous M, Mason G, Russell S, Morris J, Fanou E, et al. The use of in utero MRI to supplement ultrasound in the foetus at high risk of developmental brain or spine abnormality. *The British Journal of Radiology*. 2012;85(1019):e1038-e45.

[41] Garcia-Flores J, Recio M, Uriel M, Canameres M, Cruceyra M, Tamarit I, et al. Fetal magnetic resonance imaging and neurosonography in congenital neurological anomalies: supplementary diagnostic and postnatal prognostic value. *The Journal of Maternal-Fetal & Neonatal Medicine*. 2013;26(15):1517-23.

[42] Gonçalves L, Lee W, Mody S, Shetty A, Sangi-Haghpeykar H, Romero R. Diagnostic accuracy of ultrasonography and magnetic resonance imaging for the detection of fetal anomalies: a blinded case–control study. *Ultrasound in Obstetrics & Gynecology*. 2016;48(2):185-92.

[43] Shapira-Zaltsberg G, Grynspan D, Quintana M, Dominguez P, Reddy D, Davila J, et al. MRI features of the placenta in fetuses with and without CNS abnormalities. *Clinical radiology*. 2018;73(9):836. e9-. e15.

[44] Hsiao EY, Patterson PH. Placental regulation of maternal-fetal interactions and brain development. *Developmental neurobiology*. 2012;72(10):1317-26.

[45] Siauve N, Chalouhi GE, Deloison B, Alison M, Clement O, Ville Y, et al. Functional imaging of the human placenta with magnetic resonance. *American journal of obstetrics and gynecology*. 2015;213(4):S103-S14.

[46] Bonel HM, Stolz B, Diedrichsen L, Frei K, Saar B, Tutschek B, et al. Diffusion-weighted MR imaging of the placenta in fetuses with placental insufficiency. *Radiology*. 2010;257(3):810-9.

[47] Vedmedovska N, Rezeberga D, Teibe U, Melderis I, Donders GG. Placental pathology in fetal growth restriction. *European Journal of Obstetrics & Gynecology and Reproductive Biology*. 2011;155(1):36-40.

[48] Pomorski M, Zimmer M, Florjanski J, Michniewicz J, Wiatrowski A, Fuchs T, et al. Comparative analysis of placental vasculature and placental volume in normal and IUGR pregnancies with the use of three-dimensional Power Doppler. *Archives of gynecology and obstetrics*. 2012;285(2):331-7.

[49] Anencephaly\* MTFo. The infant with anencephaly. *New England Journal of Medicine*. 1990;322(10):669-74.

[50] Thompson DN. Postnatal management and outcome for neural tube defects including spina bifida and encephalocoeles. *Prenatal Diagnosis: Published in Affiliation With the International Society for Prenatal Diagnosis*. 2009;29(4):412-9.

[51] Caldarelli M, Rea G, Cincu R, Di Rocco C. Chiari type III malformation. *Child's Nervous System*. 2002;18(5):207-10.

[52] Claridge EA, Bloemen MA, Rook RA, Obeid J, Timmons BW, Takken T, et al. Physical activity and sedentary behaviour in children with spina bifida. *Developmental Medicine & Child Neurology*. 2019;61(12):1400-7.