

# We are IntechOpen, the world's leading publisher of Open Access books Built by scientists, for scientists

6,900

Open access books available

185,000

International authors and editors

200M

Downloads

Our authors are among the

154

Countries delivered to

TOP 1%

most cited scientists

12.2%

Contributors from top 500 universities



WEB OF SCIENCE™

Selection of our books indexed in the Book Citation Index  
in Web of Science™ Core Collection (BKCI)

Interested in publishing with us?  
Contact [book.department@intechopen.com](mailto:book.department@intechopen.com)

Numbers displayed above are based on latest data collected.  
For more information visit [www.intechopen.com](http://www.intechopen.com)



# Utility of Robotic Assisted and Single Site Laparoscopy to Gynecologic Oncology

*Conor J. Corcoran and Stephen H. Bush II*

## Abstract

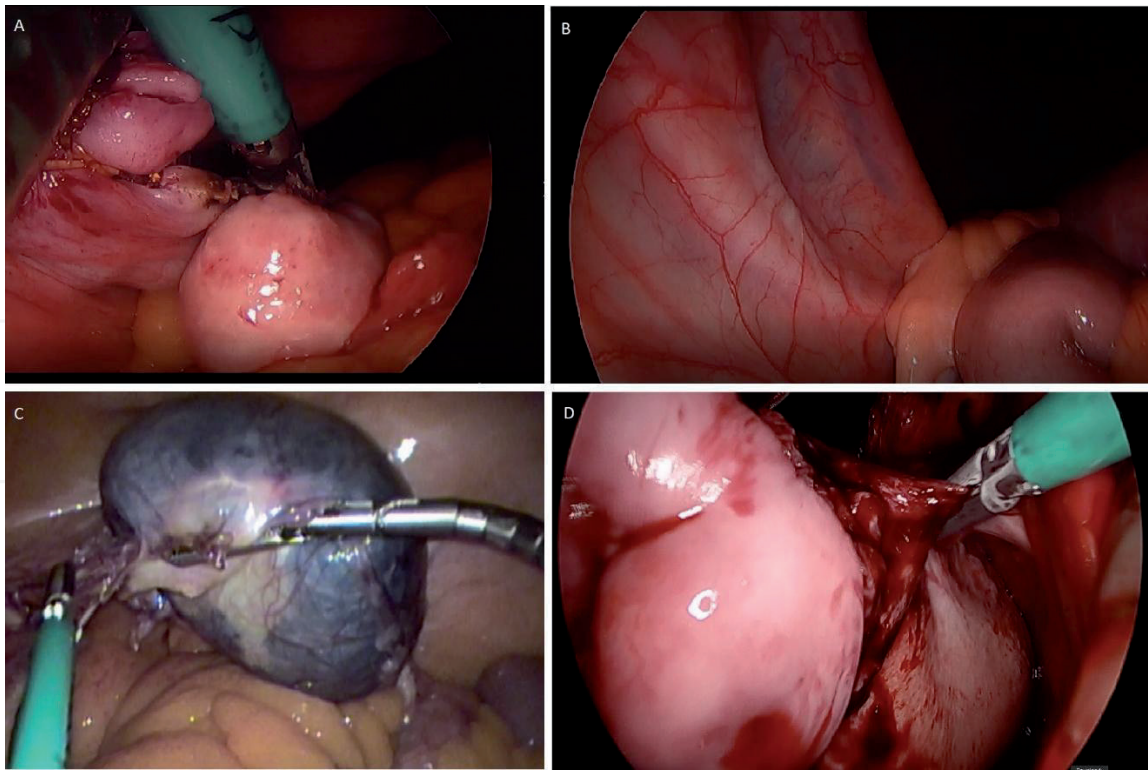
Single site laparoscopy, while in its infancy, is being explored for potential areas of application within the realm of gynecology. Gynecologic Oncology is a field with high potential benefit from the single site technique. It boasts many practical and theoretical surgical improvements, such as facilitated specimen removal, which are elaborated further in this chapter. While much more research is needed, there are exciting and uniquely useful utilities of Laparo-endoscopic Single-site Surgery (LESS) in gynecology oncology.

**Keywords:** Gynecology Oncology, minimally invasive surgery, cancer, mini-laparotomy, surgical staging

## 1. Introduction

Historically, gynecologic oncology has been dominated by laparotomy for peritoneal access, and this has carried partially even into the era of minimally invasive surgery [1]. There were good reasons for initial concern regarding laparoscopy, including port site metastasis, intact specimen removal, and technical complications of staging. Many would credit the hallmark LAP2 trial [2] with forever changing the face of gynecologic oncology, as it was the first high powered study to demonstrate laparoscopy to be comparable to laparotomy in gynecologic oncology procedures. This, combined with the already known advantages of minimally invasive surgery over classic laparotomy, launched the advent of laparoscopy in gynecologic oncology, in the opinion of many. The advantages were seen initially in the treatment of uterine cancer [3]. Many feel the extrapolation of this data was the impetus that eventually led to the saturation of minimally invasive surgery in the treatment of all other gynecologic malignant processes. With decreased length of stay, lower hernia rates, improved cosmesis, and lower infection rate, laparoscopy quickly became the preferred surgical methodology across gynecologic oncology. Gynecologic oncology has since contributed countless minimally invasive techniques since the LAP2 trial. Most notably, gynecologic oncologists were among the first to utilize and publish on single site laparoscopy [4–7].

Single site laparoscopic surgery provides many of the same potential improvements in cosmesis as benign gynecology, but also may hold the critical benefit of facilitated intact specimen extraction [8]. Removal of the intact specimen is generally a critical aspect of oncologic surgery, as attempting to avoid tumor spillage into body cavities is a critical concept in the treatment of malignancy [9]. This fulfills



**Figure 1.**  
(A) Completion of Salpingectomy vNTOES single site (B) Single site vNOTES visualization of the ureter.  
(C) Large adnexal mass liberated during laparoscopic single site surgery. (D) Uterine artery ligation and cauterization during vNOTES.

what many authors refer to as the so-called “Goldilocks” concept of specimen removal [10], allowing the surgical oncologist to laparoscopically remove larger organ systems, a feat which which would have required laparotomy previously. Multiple methods of large specimen extraction in standard laparoscopy have been described, ranging from mini-laparotomy [11, 12] and nonstandard incisions [13], to incisional extension. While useful techniques, these are less studied in malignant processes and their long term sequelae are less elucidated. Therein, many would consider that Laparoendoscopic Single-site Surgery (LESS) techniques have great merit and promise in Gynecologic Oncology (**Figure 1**).

## 2. Applications for gynecologic oncology

The majority of studies done to date in gynecology oncologic are case series or longitudinal studies done at major facilities in the United States, United Kingdom, and China. The first reports of use and feasibility highlighted the expected benefits of standard laparoscopy with the improvement of single incision cosmesis, decreased blood loss, and decreased pain. Decreased pain was the most consistent finding among early publications, which was noted in a Cochrane review of LESS in benign and oncologic gynecology [14]. Here we will outline specific advantages of the single-site technique and other considerations for specific gynecologic malignant processes.

### 2.1 Uterine cancers

The majority of LESS procedures have been performed for hysterectomy in uterine cancers, (mirroring the LAP2 trial [2]) and for risk-reducing salpingectomies. These have included, in some studies, lymphadenectomy for cancer staging purposes [15]. Given the literature available, there are many potential benefits



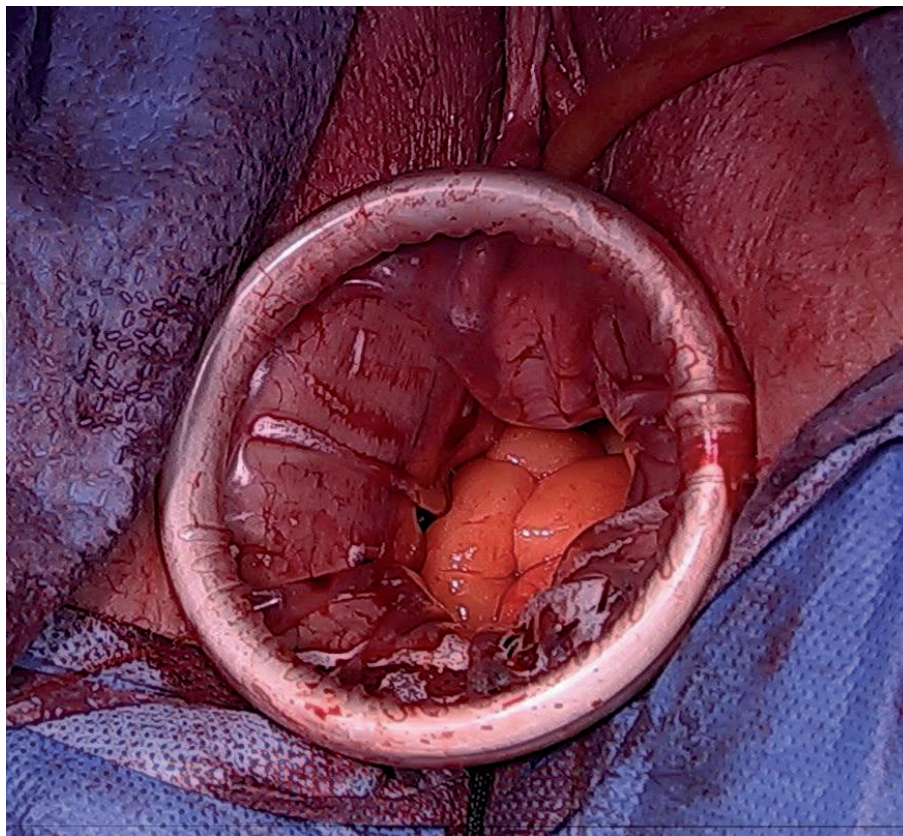
offered by LESS techniques, including: preventing peritoneal tumor spillage, tissue preservation for pathologic analysis, and facilitation of extraction.

LESS requires more time to master for advanced retroperitoneal dissection and lymphadenectomies, but a surgeon adept at traditional laparoscopic surgery can overcome these challenges and master these techniques relatively quickly. Patient selection is also of the utmost importance, as obesity is a well known major risk factor for endometrial cancer, and this excess adiposity can increase the difficulty of the already complex LESS procedure.

In 2012 a publication from Memorial Sloan Kettering Cancer Center on sentinel node biopsy in endometrial cancer, it was suggested to change the standard practice in the United States to a sentinel node algorithm rather than comprehensive lymphadenectomy in most patients with endometrial adenocarcinoma [16]. Their algorithm suggested: (1) peritoneal evaluation thorough inspection and washing, (2) retroperitoneal evaluation with excision of all mapped or suspicious nodes, (3) side specific lymph node dissection in case of no mapping into a hemi-pelvis, (4) para-aortic node dissection performed at the discretion of the attending surgeon [12].

Sentinel node biopsy and mapping was gained acceptance as the standard of care for endometrial cancer. This comes after multiple publications such as the FIRES trial which paved the way for the NCCN guidelines suggesting LESS techniques may be adopted more easily, given the need for less extensive dissection and ease at transition to a multiport procedure when needed [17].

A new subfield of LESS, vaginal natural orifice transluminal endoscopic surgery (vNOTES) is emerging in the field of gynecologic surgery. While the vast majority of investigation of vNOTES has been in benign gynecology, there are recent documented applications for oncologic purposes, specifically for early stage endometrial cancer (**Figure 2**).



**Figure 2.**  
*Single site wound retractor applied to the vagina status post vaginal hysterectomy, accessing the peritoneum for vNOTES procedure.*

## 2.2 Cervical cancers

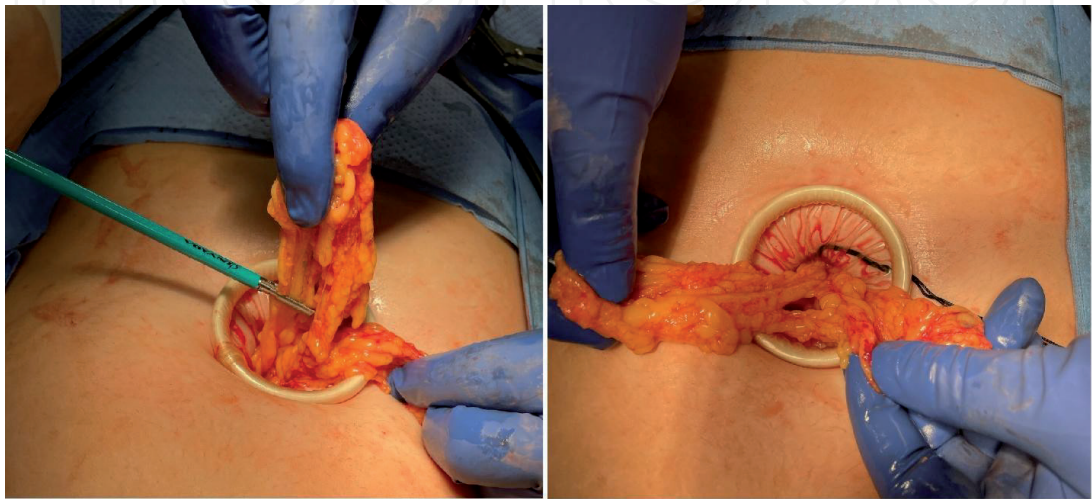
Interestingly, there were successful publications on using single-site for radical hysterectomy for early stage cervical cancers. The theoretical benefits of LESS were similar to the general benefits mentioned previously. Unfortunately, a landmark 2018 study performed by Ramirez et al., (the LACC trial,) [18] demonstrated a decrease in overall and disease-free survival with laparoscopic radical hysterectomies for early cervical cancers. As a result, laparoscopic radical hysterectomies have become rare in practice [19]. Therefore, until confounding literature published, many gynecologic oncologists feel the utility of LESS for radical hysterectomy is limited and maybe more of an interesting historical footnote than a viable procedure.

## 2.3 Ovarian cancer

While it is widely considered that advanced ovarian cancers may still be best managed via laparotomy, laparoscopy and robot assisted laparoscopy is still routinely utilized in early stage ovarian cancers. Complete staging is imperative for all ovarian malignancies. The protocol for assessing these early ovarian cancers includes: lymph node dissection, peritoneal biopsies, and omentectomy. These measures allow for peritoneal sampling which allows for improved detection of micro-metastatic disease, which, in turn, optimizes adjuvant chemotherapeutic selection and prognosis for patients.

Perhaps the greatest area of potential use in Gynecologic Oncology for LESS techniques would be adnexal masses. When the uterus is left in situ in traditional laparoscopic surgery retrieval of a large adnexal mass can be very frustrating. A 10 or 12 mm incision is often not large enough for removal of a large specimen. As a result, this scenario requires an incision to be extended, (including fascial extension) and creates a risk of injury to the bowel or other structures, as well as a risk of spillage from the isolating bag. LESS techniques in general will require a 2-3 cm umbilical incision but this can be made larger for certain clinical scenarios. Making the incision in a natural defect such as the umbilicus can yield excellent cosmetic results when a larger incision for extraction is required [20].

For a suspicious mass large extraction bags are available in sizes up to 17 cm. These vary in size and shape and are available from various manufacturers. They can be deployed intraperitoneally and the mass can be brought out through the umbilical incision, or if necessary, drained while contained. If a frozen section



**Figure 3.**  
*Omentectomy at the time of minimally invasive removal of suspicious ovarian cyst.*



is obtained and this reveals a borderline or ovarian malignancy, the surgeon may feel an infracolic omentectomy is indicated. Generally, the LESS port provides an incision large enough to deliver omentum intact and large enough to perform a relatively easy and quick infracolic omentectomy using whatever laparoscopic energy device has already been used. This technique is similar to previous described techniques of omentectomy performed through a miniature laparotomy (**Figure 3**).

For the very large benign appearing mass with normal tumor markers in a young patient, a LESS approach through the umbilicus can facilitate contained drainage. After placing the LESS port of choice the mass can be visualized before insufflation. One technique is to place two purse string sutures of 3-0 monofilament suture into the mass concentric to each other. A small hole is then made and the suction aspirator inserted with the inner stitch tied to contain leakage. Once the mass is decompressed the suction aspirator is removed, and the outer stitch can be tied to prevent any further spillage. The decompressed mass is then removed laparoscopically. The slightly large incision in the umbilicus usually allows for easy removal.

It is important to note that the above techniques for adnexal mass removal are not appropriate for all patients. For any patients in which a malignancy is suspected, great care must be taken to avoid any technique that introduces the risk of spilling malignant cells in the abdominal cavity, effectively working to spread the lesion. For patients with a low suspicion of malignancy, however, we feel that the technique is a welcome addition to the armamentarium of the gynecologic surgeon. We welcome further research, including case studies and described techniques. This will serve to further develop the minimally invasive literature as well as to stimulate ideas for new clinical trial protocols.

## 2.4 Robotic applications

A number of studies have been performed in the realm of benign gynecology with robotic LESS with varied success. Few, however, have been published specifically on oncologic robotic surgery. The most notable of these demonstrated the feasibility of robotic single-site [21]. The benefits and pitfalls of robotic single-site surgery are similar to benign gynecology as previously discussed in this text [22].

## 3. Limitations and considerations

Despite the various sources listed in this chapter and the multitude of studies on LESS for gynecologic oncology, there is an overall lack of data on the topic given its relatively new emergence. With only a decade passing since first recorded data in this topic, more research will need done before long-term conclusions can be drawn. To date, the longest single study follow up our authors could find was 3 years [23, 24].

Perhaps more than any other adverse outcome, there is evidence that LESS techniques may hold a higher hernia rate than previously expected [1, 13–16]. One study by Multon *et al.* demonstrated that hernia rates within 1 year are similar to standard laparoscopy (5.5%), 3 year follow up seemed to indicate a significant increase in hernia rates as high as 23% [1]. As a result, several authors have stated that it would appear the increased incision size for LESS may have a greater effect on incisional hernia than previously thought [25, 26].

The technical difficulties of LESS techniques are identical to the benign gynecologic applications of the surgical method, including loss of triangulation, arm clashing, and surgeon comfort [27]. With training, time, and improving surgical instruments, these limitations may be overcome.

4. Conclusion

LESS appears to be a viable, safe alternative to standard laparoscopy for most gynecologic oncology procedures. While more research is needed and is ongoing, it is the hope of the authors that more will endeavor and utilize single-site techniques for oncologic cases.

Author details


Conor J. Corcoran<sup>1</sup> and Stephen H. Bush II<sup>1,2\*</sup>

1 Charleston Area Medical Center, USA

2 West Virginia University School of Medicine Charleston Division, USA

\*Address all correspondence to: sbush1@gmail.com

IntechOpen

© 2021 The Author(s). Licensee IntechOpen. This chapter is distributed under the terms of the Creative Commons Attribution License (<http://creativecommons.org/licenses/by/3.0>), which permits unrestricted use, distribution, and reproduction in any medium, provided the original work is properly cited. 

## References

- [1] Moulton, L et al. Single-port laparoscopy in gynecologic oncology: seven years of experience at a single institution. *Am J Obstet Gynecol*. 2017;217(5):610.e1-610.e.8.
- [2] Walker, JL et al. Laparoscopy compared with laparotomy for comprehensive surgical staging of uterine cancer: Gynecologic Oncology Group study LAP2. *J Clin Oncol*. 2009;27:5331-5336.
- [3] Cho YH, Kim DY, Kim JH, Kim YM, Kim YT, Nam JH. Laparoscopic management of early uterine cancer: 10-year experience in Asan Medical Center. *Gynecologic oncology*. 2007 Sep 1;106(3):585-90.
- [4] Pontis, A et al. Review and meta-analysis of prospective randomized controlled trials (RCTs) comparing laparo-endoscopic single site and multiport laparoscopy in gynecologic operative procedures. *Arch Gynecol Obstet*. 2016;294:567-577.
- [5] Escobar, PF et al. Single-port laparoscopic pelvic and para-aortic lymph node sampling or lymphadenectomy: development of a technique and instrumentation. *Int J Gynecol Cancer*. 2010;20:1268-1273.
- [6] Escobar, PF et al. Single-port risk-reducing salpingo-oophorectomy with and without hysterectomy: surgical outcomes and learning curve analysis. *Gynecol Oncol*. 2010;119:43-47.
- [7] Single-port vs multiport laparoscopic hysterectomy: a meta-analysis of randomized controlled trials. *J Minim Invasive Gynecol*. 2016;23:1049-1056.
- [8] Fader, AN & Escobar, PF. Laparoscopic single-site surgery (LESS) in gynecologic oncology: Technique and initial report.
- [9] Richardson H. Goldilocks Mastectomy 24. *Oncoplastic Breast Surgery Techniques for the General Surgeon*. 2020 May 22:413.
- [10] Matanes E, Lauterbach R, Boulus S, Amit A, Lowenstein L. Robotic laparoendoscopic single-site surgery in gynecology: a systematic review. *European Journal of Obstetrics & Gynecology and Reproductive Biology*. 2018 Dec 1;231:1-7.
- [11] Kato, K. *et al*. 2017. "Extraction of a specimen through an umbilical zigzag incision during laparoscopic surgery for endometrial cancer". Kato et al. *World Journal of Surgical Oncology* (2017) 15:110. DOI 10.1186/s12957-017-1180-x.
- [12] P. B. Panici, M. A. Zullo, R. Angioli, and L. Muzii, "Minilaparotomy hysterectomy. A valid option for the treatment of benign uterine pathologies," *European Journal of Obstetrics Gynecology and Reproductive Biology*, vol. 119, no. 2, pp. 228-231, 2005.
- [13] Buckley III, FP et al. Influencing factors for port-site hernias after single-incision laparoscopy. *Hernia*. 2016;20:729-733.
- [14] Sasada T, Murakami S, Kataoka T, Ohara M, Ozaki S, Okada M, Ohdan H. Memorial Sloan-Kettering Cancer Center Nomogram to predict the risk of non-sentinel lymph node metastasis in Japanese breast cancer patients. *Surgery today*. 2012 Mar;42(3):245-9.
- [15] Fagotti, A. et al. First 100 early endometrial cancer cases treated with Laparoendoscopic single-site surgery: a multicentric retrospective study. *Am J Obstet Gynecol*. 2012;206:353.e.1-353.e.6.
- [16] Jennings, AJ et al. The feasibility and safety of adopting single-incision



laparoscopic surgery into gynecologic oncology practice. *J Minim Invasive Gynecol.* 2016; 23:358-363.

[17] Tergas AI & Fader, AN. Laparoendoscopic single-site surgery (LESS) radical hysterectomy for the treatment of early stage cervical cancer. *Gynecol Oncol* 2013; 129:241-243.

[18] Ramirez PT, Frumovitz M, Pareja R, Lopez A, Vieira MA, Ribeiro R. Phase III randomized trial of laparoscopic or robotic versus abdominal radical hysterectomy in patients with early-stage cervical cancer: LACC Trial. *Gynecologic Oncology.* 2018 Jun 1;149:245.

[19] Boruta, DM et al. Laparoendoscopic single-site radical hysterectomy with pelvic lymphadenectomy: Initial multi-institutional experience for treatment of invasive cervical cancer. *J Minim Invasive Gynecol.* 2014;21:394-398.

[20] Gunderson, CC et al. The risk of umbilical hernia and other complications with laparoendoscopic single-site surgery. *J Minim Invasive Gynecol.* 2012;19:40-45.

[21] Agaba, EA et al. Incidence of port-site incisional hernia after single-incision laparoscopic surgery. *JSLs.* 2014;18:204-210.

[22] Antoniou, SA et al. Single-incision laparoscopic surgery through the umbilicus is associated with a higher incidence of trocar-site hernia than conventional laparoscopy: a meta-analysis of randomized controlled trials. *Hernia.* 2016;20:1-10.

[23] P. Royo, J. L. Alcázar, M. García-Manero, B. Olartecoechea, and G. López-García, "The value of minilaparotomy for total hysterectomy for benign uterine disease: a comparative study with conventional Pfannenstiel and laparoscopic

approaches," *International Archives of Medicine*, vol. 2, article 11, 2009.

[24] Ramirez, P. et al. "Minimally invasive versus abdominal radical hysterectomy for Cervical Cancer". *New England Journal of Medicine*, 2018; 379:1895-1904.

[25] Nam, E. et al. "Robotic Single-port transumbilical total hysterectomy: a pilot study". *J Gynecol Oncol.* 2011 Jun;22(2):120-126.

[26] Barlin JN, Khoury-Collado F, Kim CH, et al. The importance of applying a sentinel lymph node mapping algorithm in endometrial cancer staging: beyond removal of blue nodes. *Gynecol Oncol.* 2012;125(3):531-535.

[27] Rossi, E.C. et al. A comparison of sentinel lymph node biopsy to lymphadenectomy for endometrial cancer staging (FIRES trial): a multicentre, prospective, cohort study. *The Lancet Oncology* 2017. 18(3);384-392.