

We are IntechOpen, the world's leading publisher of Open Access books Built by scientists, for scientists

6,900

Open access books available

186,000

International authors and editors

200M

Downloads

Our authors are among the

154

Countries delivered to

TOP 1%

most cited scientists

12.2%

Contributors from top 500 universities



WEB OF SCIENCE™

Selection of our books indexed in the Book Citation Index
in Web of Science™ Core Collection (BKCI)

Interested in publishing with us?
Contact book.department@intechopen.com

Numbers displayed above are based on latest data collected.
For more information visit www.intechopen.com



Brief Review of Portal Hypertension Related Complications

Achyut Bikram Hamal

Abstract

The pathologic increase in the pressure gradient between portal vein and inferior venacava is called portal hypertension. Increased portal blood flow and increased resistance in the portal venous system cause portal hypertension. The structural components and the functional components contribute to the resistance. Hepatic venous pressure gradient (HVPG) reflects the degree of portal pressure in liver disease. HVPG is calculated as the difference between the wedged hepatic venous pressure (WHVP) and the free hepatic venous pressure (FHVP). Clinically significant portal hypertension (CSPH) is defined as HVPG ≥ 10 . Different values of HVPG have been defined as threshold for different consequences of portal hypertension. Variceal hemorrhage, portal hypertensive gastropathy, ascites, colopathy, biliopathy and hepatopulmonary syndrome are main complications of portal hypertension. Besides nonselective beta blockers, other drugs like statins, antioxidants, antidiabetic, anti-inflammatory and antiapoptotic drugs have also been seen to be effective in reducing portal pressure.

Keywords: portal hypertension, Hepatic venous pressure gradient (HVPG), variceal hemorrhage, hepatopulmonary syndrome, cirrhotic cardiomyopathy

1. Introduction

Vesalius [1] was the person who drew an anatomical picture of the portal venous system in 1543 and described a case of bleeding hemorrhoids and suggested that this was due to a dilatation of the portal branches. Glisson [2] at a dissection in London, in 1650 established that blood was collected from the gastrointestinal tract by portal vein and finally to the systemic circulation.

Morgagni described a patient who had died from gastrointestinal hemorrhage: at the autopsy, dilatation of the splenic vein and of the short gastric veins were found.

The name cirrhosis was introduced in 1819, in Paris, by Renè Laennec, deriving from two words of the antique Greek: Skirros (hard, fibrotic) and Kirrhos (yellowish). He used the word “cirrhosis” in the textbook published by him [3].

Dusaussey [4], wrote an important thesis ‘Studies on esophageal varices in liver cirrhosis’, in 1872. He believed that the obstruction to portal flow was a consequence of liver cirrhosis.

Gilbert [5] introduced the term portal hypertension in 1902. A ‘pressure close to that in the portal vein’ without opening the abdomen, was obtained by puncturing one of the dilated abdominal wall veins (the caput medusae) by Davidson [6].

Thompson (1937) [7] directly measured portal pressure for the first time, with the open abdomen, the pressure in the portal vein and in the inferior vena cava. In 1953 Lebon et al. [8] diagnosed portal hypertension by percutaneous measurement of the intrasplenic pressure.

2. Definition

Patients with portal hypertension are identified when they present to hospitals or clinic after they have complications such as ascites, gastrointestinal bleeding, hepatic encephalopathy or hypersplenism. The pressure gradient between the portal vein and the inferior vena cava (the so-called portal perfusion pressure of the liver or portal pressure gradient) increases to greater than the normal range of values (1–5 mm Hg) when there is pathologic increase in portal pressure, which is called portal hypertension [9].

3. Portal pressure measurement and its importance

While evaluating them the need for the evaluating the underlying cirrhosis, the degree of portal hypertension, the site of obstruction and the presence of collateral circulation makes the diagnosis of portal hypertension complete [10]. As the disease progresses, the amount of fibrosis increases and in parallel the portal pressure rises corresponding to worsening in the prognosis. Direct or indirect measurement of portal pressure can be done with various methods.

Measurement of the hepatic venous pressure gradient (HVPG) is the gold standard technique used to quantify the degree portal hypertension in liver disease. Diagnosis, classification, and monitoring of portal hypertension, risk stratification, identification of candidates for liver resection, and monitoring efficacy of β -adrenergic blockers are the main clinical applications of HVPG measurements.

HVPG is calculated as the difference between the wedged hepatic venous pressure (WHVP) and the free hepatic venous pressure (FHVP) [11]. The WHVP is measured by occluding a main hepatic vein which causes the static column of blood to transmit the pressure that is present in the preceding vascular territory i. e. the hepatic sinusoids. This measurement, in the absence of presinusoidal obstruction, reflects portal pressure [12]. The FHVP is a measure of the pressure of unoccluded hepatic vein. HVPG calculated with right atrial pressure shows a worse correlation with clinical outcomes, therefore FHVP should be used [13]. There are several methods to measure portal pressure as enumerated in **Table 1**.

The changes in HVPG are due to the alterations in the intrahepatic resistance, collateral resistance, portal blood inflow or their combination [14]. Dynamic factors such as hepatic vascular tone and mechanical factors such as fibrosis, thrombosis and formation of regenerative nodules cause the alterations in HVPG.

The complications of portal hypertension increase as HVPG increases. Clinical manifestations and complications occur at a threshold of HVPG of 10 mm Hg, which is called clinically significant portal hypertension (CSPH). Different thresholds of HVPG correlate with different prognostic significance (**Table 2**).

3.1 Technique of measurement of HVPG

Under sedation a balloon-tipped catheter is introduced through the central line inserted into the right internal jugular vein, usually under ultrasound guidance [28].

SN	Methods	Procedures
1.	Indirect estimation of Portal hypertension	Ascitic fluid analysis Serum Ascitic Albumin Gradient (SAAG) ≥ 1.1
2.	Hepatic Vein Pressure Gradient (HVPG)	Open-ended catheter placed in one of the hepatic veins via a supraclavicular or internal jugular approach. Double-lumen balloon catheter placed in the hepatic vein via a femoral approach
3.	Direct measurement of the portal pressure gradient	The portal vein can be catheterized directly, either by a trans hepatic approach or by a catheter placed via the umbilical vein. The added advantage is that collaterals can be embolized while this procedure. Angiography can be performed at the same time to minimize the number of procedures performed. Portal pressure measurements should be obtained prior to the injection of contrast, which in itself can alter pressures.
4.	Intrahepatic portal vein pressure	Percutaneous catheterization of an intrahepatic branch of the portal vein with a thin Chiba needle; a catheter is passed via the intrahepatic branch into the main portal vein.
5.	Intrasplenic pressure	Placement of a needle percutaneously in the substance of the spleen.
6.	Umbilical vein catheter	Requires dissection to expose the umbilical vein; may require dilation of the umbilical vein to facilitate advancement of the catheter.

Table 1.
Different methods of measuring portal pressure.

HVPG	Clinical characteristics
< 5 mm Hg	Normal
5–10 mm Hg	Mild portal hypertension
>6 mm Hg	Progression of chronic viral hepatitis [15] High risk of recurrence after liver transplantation [16]
>10 mm Hg	Clinically significant Portal hypertension (CSPH)
>10 mm Hg	Esophageal variceal development [17, 18] Decompensation with ascites [19] Hepatocellular carcinoma (HCC) [20] Decompensation after Hepatic resection [21]
>12 mm Hg	Variceal bleeding [22, 23]
>16 mm Hg	High mortality [24]
>20 mm Hg	Failure to control bleeding in acute variceal bleed [25] Low 1-year survival
>22 mm Hg	High mortality in severe alcoholic hepatitis [26]
>30 mm Hg	Spontaneous bacterial peritonitis (SBP) [27]

Table 2.
Different thresholds of hepatic venous pressure gradient (HVPG) correlated with prognostic significance.

The catheter is advanced through the right atrium into the inferior venacava (IVC) under fluoroscopic guidance and then pushed into the right hepatic vein. Alternatively, the femoral approach can be used.

FHVP is obtained after the catheter is maintained in the hepatic vein 2 to 4 cm from its takeoff from the IVC. Typically, the difference in pressure between the IVC (measured at the hepatic vein ostium) and hepatic vein is ≤ 1 mmHg. If the difference is >1 mmHg it means the catheter is placed too deep into the hepatic vein. After this, WHVP is measured after the hepatic vein is occluded by inflating the balloon at the tip of the catheter. A small amount of contrast dye (5 mL) or carbon dioxide (if allergic to the contrast) is injected to confirm that the hepatic vein is occluded so that no reflux of the dye above the balloon or should washout via communications with other hepatic veins. Around 3 each measurements of wedged and free hepatic venous pressure are made each time with the stability of the value for at least 45–60 seconds [29]. Finally, the HVPG is calculated by subtracting the FHVP from the WHVP.

The findings of hemodynamic measurements in patients with intrahepatic portal hypertension are enumerated [28] in **Table 3**.

At the same time along with HVPG measurement include transjugular liver biopsy, measurement of hepatic blood flow and indocyanine green clearance, and wedged hepatic retrograde portography using carbon dioxide can be done. Complications during the procedure can be arrhythmia or injury to the local site.

3.2 Noninvasive tests

Though these noninvasive tests cannot replace HVPG measurement for confirming the diagnosis of portal hypertension, ultrasonogram and transient elastography may be helpful.

3.2.1 Ultrasonography

Portal hypertension findings in transabdominal ultrasound are [28]:

- Ascites
- Splenomegaly (> 13 cm or Splenic index >20 cm²)
- Coarse echotexture of liver with irregular margin and dull edge
- Portal flow mean velocity < 12 cm/second
- Reversal of flow in the portal vein and left gastric vein
- Portosystemic collaterals (patent-paraumbilical vein, splenorenal collaterals, dilated left and short gastric veins)
- Portal vein diameter > 13 mm
- Decreased or no respiratory variation in splenic and superior mesenteric vein diameter
- Portal/splenic/superior mesenteric vein thrombosis

Hemodynamic measurement	Presinusoidal	Sinusoidal	Post-sinusoidal
FHVP (a)	Normal	Sinusoidal	Increased
WHVP (b)	Normal or mild increased	Increased	Increased
HVPG (b-a)	Normal or mild increased	Increased	Normal

Table 3.
Hemodynamic measurements in portal hypertension.

3.2.2 Transient elastography

Transient elastography using ultrasound is a noninvasive method for detecting hepatic fibrosis. Studies are also looking at it as an option for noninvasively diagnosing portal hypertension.

A value <13.6 kPa can be used to rule out portal hypertension, whereas a value ≥ 21.1 kPa is likely to have portal hypertension [28].

4. Pathophysiology of portal hypertension

With the concept of physics, it is important to note that portal hypertension is related to both flow and resistance.

Pressure (P) equals flow (Q) times resistance (R), demonstrated by the formula.

$$P = Q \times R$$

Resistance is a function of the length and radius as shown by the formula $R = 8nL/\pi r^4$, where n is the coefficient of viscosity, L is the length of the vessel, and r is the radius. The pathophysiology of portal hypertension is explained in **Figure 1**.

4.1 Etiology of portal hypertension

Various etiologies of portal hypertension can be enumerated as:

Prehepatic

- Splenic vein thrombosis
- Portal vein thrombosis
- Congenital portal vein stenosis
- Cavernomatosis of the portal vein
- Arteriovenous fistula
- Tropical splenomegaly

Intrahepatic

- Presinusoidal: Schistosomiasis
- Sarcoidosis
- Primary Biliary Cirrhosis (Early)
- Chronic active hepatitis
- Congenital hepatic fibrosis
- Hepatic artery portal vein fistula
- Porto-sclerosis
- Drugs
 - Arsenic, copper sulfate and Vinyl chloride poisoning.
- Amyloidosis
- Tuberculosis
- Wilson's disease
- Hemochromatosis
- Mastocytosis
- Sinusoidal: Acute alcoholic Hepatitis
- Liver cirrhosis independent of etiology
- Amyloidosis
- Partial nodular transformation
- Nodular regenerative hyperplasia
- Hypervitaminosis A

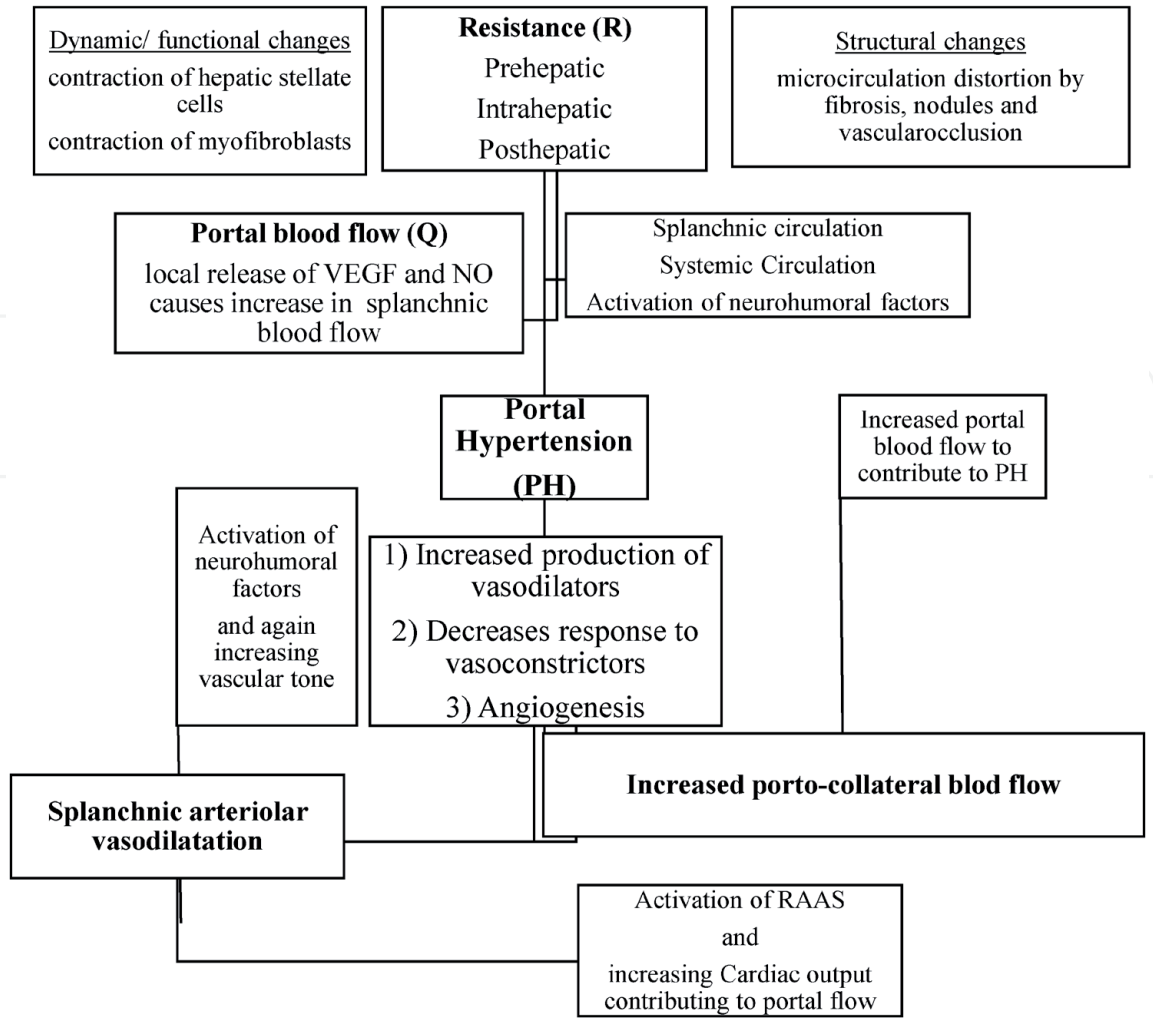


Figure 1.
Pathophysiology of portal hypertension.

- Cytotoxic drugs
 - Acute fatty liver of pregnancy
 - Peliosis hepatitis
 - Polycystic liver disease
 - Idiopathic portal hypertension
 - Metastatic malignant disease
 - Post-sinusoidal: Veno-occlusive disease
 - Alcoholic central hyaline sclerosis
 - Post-hepatic**
 - Budd-Chiari syndrome
 - Congenital malformations and thrombosis of the inferior vena cava
 - Constrictive pericarditis
 - Congenital heart diseases
 - Cardiomyopathy
 - Tricuspid valve diseases
 - Miscellaneous**
 - Arteriovenous fistulas (splenic, aorto-mesenteric, aorto-portal, and hepatic artery-portal vein)
- Formation of collateral circulation connects the portal blood vessels to systemic circulation, bypassing the liver and leading to portal hypertension [30]. Sometimes, when a pathological process causes occlusion of the splenic vein and the resultant

elevated splenic bed venous pressure causes formation of gastric varices which can lead to hematemesis it is called sinistral portal hypertension. Sinistral portal hypertension is a rare, less than 1%, but life-threatening cause of upper gastric bleeding. In fact, the name sinistral portal hypertension is a misnomer since portal pressure is usually within the normal range in these cases. Other names for sinistral portal hypertension are left sided portal hypertension, segmental, regional, localized, compartmental, lineal, or spleno-portal hypertension [31–33]. It accounts for less than 5% of all patients with portal hypertension [33].

Chronic pancreatitis, pancreatic cancer, pancreatic cysts and neuroendocrine tumor are common causes of sinistral portal hypertension. Most involved vessel in pancreatitis-related splanchnic vein thrombosis is splenic vein followed by portal vein and mesenteric vein. It is mainly related to pancreatic inflammation and compression by pancreatic pseudocyst [34]. Around 8% of patients of chronic pancreatitis experience splenic vein thrombosis, the majority do not experience any form of symptomatic GI bleeding [35]. They present with hypersplenism, abdominal pain and gastrointestinal bleeding. They should undergo gastroscopy evaluation in search of varices. Suspicion of this portal hypertension should be done when patient has gastric varices only in fundus with or without any aberrant liver functions or features of liver cirrhosis with the presence of splenomegaly.

Iatrogenic splenic vein injury, ectopic spleen, colonic tumor infiltration, peri-renal abscess, post liver transplantation, Hodgkin's disease, retro-peritoneal fibrosis, pancreatic transplantation, and spontaneous thrombus formation are among the less common causes of splenic vein thrombosis that can lead to left sided hypertension [31, 32].

5. Complications of portal hypertension

Patients with portal hypertension are usually asymptomatic until they develop complications. Complications of portal hypertension include:

1. Variceal hemorrhage
2. Portal hypertensive gastropathy (PHG)
3. Ascites
4. Spontaneous bacterial peritonitis
5. Hepatorenal syndrome (HRS)
6. Hepatic hydrothorax
7. Hepatopulmonary syndrome (HPS)
8. Porto-pulmonary hypertension (POPH)
9. Portal hypertensive colopathy
10. Cirrhotic cardiomyopathy
11. Portal Biliopathy

5.1 Variceal hemorrhage

Bleeding occurs in 30%–40% of patients with cirrhosis and varices [36]. The incidence of first variceal bleeding is about 12–15% per year in patients with cirrhosis and esophageal varices and mortality ranges from 17% - 57% in patients at first episode of variceal bleeding [37]. Carbonell et al. has also estimated mortality during the first episode of bleeding to be 15–20% but with Child Pugh C, it is around 30% [38].

The preventive measures advocated are beta blockers and endoscopic variceal ligation (EVL). Beta blockers provide protection against rebleeding after index hemorrhage while local obliteration of varices is done by EVL.

Nonselective beta blockers have been used daily in patients with cirrhosis and portal hypertension with varices either for primary or secondary prophylaxis. Recommended agents for primary prophylaxis of variceal hemorrhage are propranolol and nadolol [39, 40].

Secondary prophylaxis with nonspecific beta blocker (NSBB) has been shown to be effective in decreasing both the risk of recurrent bleeding and mortality [41, 42]. Without secondary prophylaxis, rebleeding occurs in approximately 60% to 70% of patients, usually within one to two years of the index hemorrhagic event [43]. Most used NSBB for secondary prophylaxis is propranolol but carvedilol can also be used. The decrease in HR at 6 weeks was significantly higher in carvedilol than propranolol group ($p = 0.036$). The rebleeding at least once within 6 months was also higher in propranolol group than carvedilol group (32 vs. 22.7%) [44].

5.2 Portal hypertensive Gastropathy

It is the characteristic appearance which is a mosaic-like pattern or a diffuse, erythematous and reticular cobblestone pattern of gastric mucosa consisting of small polygonal areas, with or without superimposed red punctate lesions, >2 mm in diameter and a depressed white border [45–47]. PHG is classified as mild or severe.

Mild PHG has features like fine pink speckling (scarlatina-type rash), and mosaic pattern (snakeskin appearance) and Severe one has discrete red spots or diffuse hemorrhagic lesion [48].

The prevalence of PHG in Nepalese population with Chronic Liver Diseases (CLD) was 67 percent [49] though it varies significantly from 16 to 100 percentage [50]. Acute bleeding in PHG is estimated to occur in 2 to 12 percent [51].

5.3 Ascites

Patients with cirrhosis with portal hypertension may present with ascites leading to distension of abdomen and dyspnea. They will have flank fullness with dullness on examination. The grading of ascites as graded by International Club for Ascites are [52]:

- Grade 1 – Mild ascites detectable only by ultrasound examination
- Grade 2 – Moderate ascites manifested by moderate symmetrical distension of the abdomen
- Grade 3 – Large or gross ascites with marked abdominal distension

Ascites may range from mild to refractory. Mild to moderate ascites should be managed by modest salt restriction and combination of loop diuretics and potassium sparing diuretics.

Ultrasonographic detection of mild ascites is either pelvic or perihepatic or peri splenic ascites, while moderate ascites is presence of pelvic and perihepatic and perisplenic ascites, and marked ascites is diffuse ascites in the peritoneal cavity [52].

Diuretics should be added in a stepwise fashion along with sodium restriction. Gross ascites should be treated with therapeutic paracentesis followed by colloid volume expansion, and diuretic therapy. Sometimes refractory ascites is managed by repeated large volume paracentesis or insertion of a transjugular intrahepatic portosystemic stent shunt (TIPS) [53].

5.4 Spontaneous bacterial peritonitis (SBP)

Spontaneous bacterial peritonitis occurs with a prevalence of 10–25% in cirrhotic patients with ascites [54]. It can be community acquired, health care associated or nosocomial.

Major pathogenic organisms are *E. coli* (24.3%), followed by *Klebsiella pneumoniae* (12.0%) and *Enterococcus faecium* (10.5%). Nosocomial SBP has significantly higher proportion of Enterococcus (27.7% vs. 6.1%, $P < 0.001$) than community acquired SBP. Nosocomial SBP has a poorer outcome than community acquired pneumonia (24.6% vs. 36.8%; $P = 0.016$). The independent predictors for 30-day mortality are nosocomial infection, Child-Pugh classification, hepatocellular carcinoma, renal failure and hepatic encephalopathy [54].

Suspicion of nosocomial SBP should be done in a patient with SBP with a history of ICU stay during the previous 3 months or on prophylactic antibiotics for infection or had antibiotic treatment during previous 3 months or had a recent intervention in the hospital setting. Resistance to 3rd generation cephalosporins and quinolones has been documented in 40–50% of such cases [55].

Recently, Elsadek et al. found that Patients with SBP ($n = 60$) have significantly higher serum PEC index than those with sterile ascites ($n = 118$) (41.0/31.2–93.0 vs. 9.9/5.9–15.0, $P < 0.001$) and it distinguished culture positive cases significantly ($P < 0.001$) [56].

Diagnostic paracentesis should be performed in all patients who present with [57] (1) compatible signs or symptoms (abdominal pain and/or tenderness on palpation, fever, and chills); (2) impairment of the hepatic or renal function; (3) unexplained hepatic encephalopathy; (4) gastrointestinal bleeding.

SBP is diagnosed by polymorphonuclear cells ≥ 250 cells/mm³ in ascitic fluid in the absence of an intra-abdominal and surgically treatable source of infection. Other potential diagnostic methods are leukocyte esterase reagent strips (LERS), measurement of leukocyte-derived proteins such as granulocyte elastase and lactoferrin, detection of bacterial DNA using polymerase chain reaction (PCR) and detecting bacterial DNA in SBP ascites using in situ hybridization [57].

5.5 Hepatorenal syndrome (HRS)

HRS occurs in the setting of advanced cirrhosis and portal hypertension [58] with prevalence of 13–45 percentage [59]. It is characterized by peripheral arterial vasodilatation and intrarenal vasoconstriction with decrease in renal blood flow and renal dysfunction. The most recent proposed diagnostic criteria for HRS-AKI are as-

Diagnostic Criteria for HRS-AKI [60].

- Cirrhosis with ascites; acute liver failure; acute-on-chronic liver failure

- Increase in serum creatinine ≥ 0.3 mg/dl within 48 h or $\geq 50\%$ from baseline value according to International Club of Ascites (ICA) consensus document and/or urinary output ≤ 0.5 ml/kg B.W. ≥ 6 h*
- No full or partial response, according to the ICA consensus, after at least 2 days of diuretic withdrawal and volume expansion with albumin. The recommended dose of albumin is 1 gm/kg of body weight per day to a maximum of 100 gm/day
- Absence of shock
- No current or recent treatment with nephrotoxic drugs
- Absence of parenchymal disease as indicated by proteinuria >500 mg/day, micro-hematuria (>50 red blood cells per high power field), urinary injury biomarkers (if available) and/or abnormal renal ultrasonography**.
- Suggestion of renal vasoconstriction with FENa of $<0.2\%$ (with levels $<0.1\%$ being highly predictive)

*The evaluation of this parameter requires a urinary catheter.

**This criterion would not be included in cases of known pre-existing structural chronic kidney disease (e. g. diabetic or hypertensive nephropathy). AKI, acute kidney injury; FENa, fractional excretion of sodium; HRS, hepatorenal syndrome.

Nowadays, HRS has been classified as HRS-AKI and HRS-NAKI. The diagnosis of HRS-NAKI has been proposed to be made in the context of CKD, or AKD that does not meet the criteria for AKI and lasts for <90 days.

HRS-AKD is defined as a percent increase in sCr $<50\%$ or as an eGFR <60 ml/min per 1.73 m² for <3 months with the fulfillment of the ICA criteria for HRS.

HRS-CKD defined as an eGFR <60 ml/min per 1.73 m² for ≥ 3 months with the fulfillment of the ICA criteria.

Treatment can be done with terlipressin with albumin as medical treatment or with liver transplantation.

5.6 Hepatic hydrothorax

Hepatic hydrothorax (HH) is defined as the excessive (> 500 mL) accumulation of transudate fluid in the pleural cavity in patients with decompensated liver cirrhosis (LC) with exclusion of cardiopulmonary and pleural diseases [61]. It is present in 5–10% of cirrhotic patients. Right sided HH is common accounting for almost 85% of cases followed by left sided (13%). The mechanism of HH is due to negative intrathoracic pressure and liver acting as piston which results the ascitic fluid to move from the peritoneal cavity into the pleural space through small defects located mainly on the right side of the diaphragmatic tendon [61, 62]. Huang et al. [63] classified diaphragmatic defects into four types: (1) Type 1 - no obvious defects; (2) Type 2 – blebs lying on the diaphragm; (3) Type 3 – broken defects (fenestrations) in the diaphragm; (4) Type 4 – multiple gaps in the diaphragm.

The diagnostic criteria [61] for HH are listed in **Table 4**.

The options for treatment for refractory HH are low sodium diet with therapeutic thoracentesis, pleurodesis, mesh repair of diaphragmatic defects, transjugular

Criteria	Values
Count of white blood cells in pleural fluid	< 250/mm ³
Pleural effusion total protein level	< 25 g/L
Pleural effusion total protein/serum total protein ratio	< 0.5
Pleural effusion Lactate dehydrogenase (LDH)/serum LDH ratio	> 0.6
Pleural effusion albumin/serum albumin ratio	> 1.1
Pleural effusion bilirubin /serum bilirubin ratio	< 0.6
pH	> 7.4
Pleural effusion glucose level is equal to serum glucose level	

Table 4.
The diagnostic criteria for hepatic hydrothorax.

intrahepatic portosystemic shunt (TIPS), pleuro-venous or peritoneo-venous shunting though liver transplantation is the definite therapy.

5.7 Hepato-pulmonary syndrome (HPS)

HPS is defined as a disorder in pulmonary oxygenation, caused by intrapulmonary vasodilatation and, less commonly, by pleural and pulmonary arteriovenous communications occurring in the clinical setting of portal hypertension. HPS has been reported in 10% of patients with chronic viral hepatitis in 15–23% of those with cirrhosis and in 28% of those with Budd-Chiari syndrome [64].

The diagnostic criteria for HPS are [64]:

1. Hypoxia with partial pressure of oxygen <80 mmHg or alveolar–arterial oxygen gradient ≥15 mmHg in ambient air (≥20 mmHg in patients older than 65 years).
2. Pulmonary vascular defect with positive findings on contrast-enhanced echocardiography (i.e., microbubble opacification of the left heart chambers three to six cycles after right atrial passage) or abnormal uptake in the brain (>6%) with radioactive lung-perfusion scanning.

Spontaneous resolution of HPS is less likely and the definite treatment is liver transplantation however long-term oxygen therapy remains the most frequently recommended therapy for symptoms in patients with severe hypoxaemia. No established medical therapy is found however some improvement in Pao2 with garlic has been seen [65].

5.8 Portopulmonary syndrome (POPH)

Vasoconstriction, vascular remodeling, and proliferative and thrombotic events within the pulmonary circulation lead to POPH. The presence of portal hypertension, hemodynamic measurements of mean pulmonary artery pressure > 25 mmHg at rest, mean pulmonary capillary wedge pressure < 15 mmHg, and pulmonary vascular resistance >240 dynes/cm⁻⁵ confirm POPH [66].

POPH is commonly diagnosed during fifth decade of life, 4–7 years after the presence of portal hypertension has been established [67]. Symptoms include dyspnea, fatigue, light headedness, and orthopnea in patients with liver cirrhosis or portal hypertension. Diuretics can be used for symptomatic control with close monitoring. Calcium channel blockers can worsen portal hypertension by causing mesenteric vasodilatation.

5.9 Portal hypertensive colopathy

Severe portal hypertension can cause lower gastrointestinal bleeding and cause anemia. Portal hypertensive colopathy has been defined endoscopically in patients with vascular ectasia, redness, and blue vein. Vascular ectasia is classified into two types: type 1, solitary vascular ectasia; and type 2, diffuse vascular ectasia. Overall portal hypertensive colopathy is found in 2/3rd of the cirrhotic patients including solitary vascular ectasia in 36%, diffuse vascular ectasia in 42%, red ness in 21% and blue vein in 12 percent [68]. Worsening of Child Pugh class and decrease in platelet count increases prevalence of portal hypertensive colopathy in patients with liver cirrhosis warranting colonoscopy to prevent lower gastrointestinal bleeding.

5.10 Cirrhotic cardiomyopathy

The diagnostic criteria of cirrhotic cardiomyopathy [69] are enumerated in **Table 5**. Decreased cardiac responsiveness (chronotropic and inotropic incompetence) through the defect in cardiac β -adrenergic receptor signaling is the main mechanism for systolic dysfunction in cirrhotic cardiomyopathy. The presence of cardiodepressant substances such as nitric oxide (NO) and carbon monoxide (CO) and endogenous cannabinoids also play role [70, 71]. Potential mechanisms for diastolic dysfunction are alteration in collagen configuration, sodium retention and activation of renin angiotensin aldosterone System (RAAS) [72].

Salt and fluid restriction, diuretics and afterload reduction are the aspects of treatment in cirrhotic cardiomyopathy. Compared with non-cirrhotics the benefit of β -blockers in cirrhotic heart failure is not clear. The use of non-selective β -blocker has been shown to reduce prolonged QT interval toward normal values in patients with cirrhosis along with some beneficial effect in improving electromechanical uncoupling [73]. Possible cure for cirrhotic cardiomyopathy is liver transplantation.

5.11 Portal biliopathy

Presence of biliary abnormalities in patients with non-cirrhotic/non-neoplastic extrahepatic portal vein obstruction (EHPVO) and portal cavernoma (PC) is called

Systolic dysfunction	Resting ejection fraction <55%
	Blunted increase in cardiac output with exercise or pharmacological stimuli
Diastolic dysfunction	Early diastolic atrial filling (E/A ratio) < 1.0 (age corrected)
	Deceleration time (DT) > 200 ms
	Prolonged isovolumetric relaxation time > 80 ms
Supportive criteria	Electrophysiological abnormalities (prolongation of QT)
	Abnormal chronotropic response
	Electromechanical uncoupling
	Enlarged left atrium
	Increased myocardial mass
	Increased brain natriuretic peptide or pro-peptide
	Increased troponin I

Table 5.
Diagnostic criteria for cirrhotic cardiomyopathy.

Stage	Portal cavernoma	Biliopathy	Liver function tests	Symptoms	Complications
Preclinic	Yes	No	Normal	No	No
Asymptomatic	Yes	Early changes	Normal or abnormal	No	No
Symptomatic	Yes	Advanced changes	Abnormal	yes	No
Complicated	Yes	Advanced changes	Abnormal	Yes	Yes

Table 6.
Characteristics of four stages in portal biliopathy natural history.

portal biliopathy. Compression of bile ducts by PC and/or to ischemic damage secondary to an altered biliary vascularization in EHPVO and PC leads to contribution of this complication.

Normally, epicholedochal venous plexus of Saint and the paracholedochal plexus of Petren, whose normal diameter does not exceed 1 mm, are responsible for the venous drainage of the biliary tree. Dilation of plexus of Saint causes fine irregularities in biliary walls while dilation of plexus of Petren causes extrinsic compression in chronic portal vein obstruction. Patients present with jaundice, cholangitis, cholecystitis, abdominal pain, and cholelithiasis. Around 5%–38% of patients develop biliary symptoms [74]. Dhiman et al. [75] identified four stages in PB progression (**Table 6**).

On the aspect of treatment, surgical porto-systemic shunt or transjugular intrahepatic porto-systemic shunt can be performed, and treatment on the biliary stenosis includes endoscopic (Endoscopic retrograde cholangiopancreatography with endoscopic sphincterotomy, balloon dilation, stone extraction, stent placement) and surgical (bilioenteric anastomosis, cholecystectomy) approaches are used for decompression of portal cavernoma.

6. Future perspectives

Besides different surgeries with portosystemic shunting, there are newer drugs developed for reduction of portal pressure. Few drugs which have been seen to be beneficial are:

6.1 Farnesoid X receptor (FXR) agonists

Obeticholic acid (OCA), a semisynthetic FXR agonist tested in preclinical models of cirrhosis has shown beneficial effects as transcriptional modulator on PH by reducing the intrahepatic vascular resistance (IHVR) [76].

6.2 Statins

Statins have antioxidative, antiproliferative and anti-inflammatory effects, and can improve endothelial dysfunction [77].

They have shown strong hepatosinusoidal protective effects in preclinical models of chronic liver diseases, ultimately leading to reduction in portal pressure [78, 79]. Simvastatin has shown beneficial effects when administered alone or combined with beta blockers [80, 81].

6.3 Anti-apoptotic drugs

Emricasan has been seen to improve portal pressure and IHVR compared with vehicle-treated rats, in addition to improved liver function and microcirculation, and finally with improved liver sinusoidal endothelial cell (LSEC) and hepatic stellate cells (HSC) phenotype and reduced inflammation [82].

6.4 Anticoagulants

Rivaroxaban, direct inhibitor of factor Xa has been shown to reduce liver microthrombosis, HSC activation and portal pressure in experimental models of cirrhosis [83].

6.5 Antidiabetic drugs

Liraglutide has shown antifibrotic effects in NASH patients, thus with high probabilities of success as a treatment for portal hypertension and chronic liver disease [84]. Metformin has shown to improve liver hemodynamic and fibrosis by a reduction in inflammation and oxidative stress [85].

6.6 Anti-inflammatory agents

Anti-inflammatory drugs such as rapamycin have reduced portal pressure in rats with Portal hypertension due to its intrahepatic and extrahepatic effects [86, 87].

6.7 Taurine

Taurine has pleiotropic effects. A small cohort of patients with clinically significant PH (HVPG >12 mmHg) has reported reduction in portal pressure [88]. Thus, consumption of low carbonated 'energy drinks' rich in taurine may have a positive impact in portal hypertension.

7. Conclusion

Portal Hypertension is responsible for many complications in liver cirrhosis. Reduction of portal pressure decreases the rate of complications in advanced liver diseases. This can improve the quality of life and increase the survival of such patients.

Conflict of interest

None.

IntechOpen

IntechOpen

Author details

Achyut Bikram Hamal
Nepal Police Hospital, Kathmandu, Nepal

*Address all correspondence to: abhamal@gmail.com

IntechOpen

© 2021 The Author(s). Licensee IntechOpen. This chapter is distributed under the terms of the Creative Commons Attribution License (<http://creativecommons.org/licenses/by/3.0>), which permits unrestricted use, distribution, and reproduction in any medium, provided the original work is properly cited. 

References

- [1] Vesalius A. De Humani corporis fabrica. Basileae, 1543
- [2] Glisson F. The portal circulation. In: Child G. N Engl J Med 1955; 252:837
- [3] Genoveffa Balducci, Antonio V Sterpetti and Marco Ventura. A short history of portal hypertension and of its management. Journal of Gastroenterology and Hepatology 31 (2016) 541-545
- [4] Dusaussey M. Etudes sur les varices de l'oesophage dans la cirrhose hepatique. These, Paris, 1877
- [5] Gilbert A, Carnot P. Les fonctions hepatiques. Paris, 1902
- [6] Davidson CS, Gibbons TB, Faloon WW. Systemic and portal venous pressures in cirrhosis of the liver. J Lab Clin Med 1950; 35:181
- [7] Thompson WP, Caughley GL, Whipple AO et al. Splein vein pressure in congestive splenomegaly. J. Clin. Invest. 1937; 16: 571-576.
- [8] Lebon J, Fabregoule M, Eisenbeth H et al. Splenoportographie transperietale. Alg Med 1953; 57: 105-110.
- [9] Abraldes JG, Sarlieve P, Tandon P. Measurement of portal pressure. Clinics in liver disease. 2014 Nov 1;18(4):779-792.
- [10] John C. Hoefs, et al. Diagnosis and hemodynamic assessment of portal hypertension. Surgical Clinics of North America-Vol. 70, No.2, April 1990
- [11] Bosch J, Abraldes JG, Berzigotti A, et al. The clinical use of HVPG measurements in chronic liver disease. Nat Rev Gastroenterol Hepatol 2009;6: 576-582.
- [12] Groszmann RJ, Glickman M, Blei AT, et al. Wedged and free hepatic venous pressure measured with a balloon catheter. Gastroenterology 1979;76(2):253-258.
- [13] La Mura V, Abraldes JG, Berzigotti A, et al. Right atrial pressure is not adequate to calculate portal pressure gradient in cirrhosis: a clinical-hemodynamic correlation study. Hepatology 2010; 51(6):2108-2116.
- [14] Abraldes JG, Araujo IK, Turon F, et al. Diagnosing and monitoring cirrhosis: liver biopsy, hepatic venous pressure gradient and elastography. Gastroenterol Hepatol 2012;35(7):488-495.
- [15] Kumar M, Kumar A, Hissar S et al. Hepatic venous pressure gradient as a predictor of fibrosis in chronic liver disease because of hepatitis B virus. Liver Int 2008; 28: 690-698.
- [16] Blasco A, Forns X, Carrion JA et al. Hepatic venous pressure gradient identifies patients at risk of severe hepatitis C recurrence after liver transplantation. Hepatology 2006; 43: 492-499.
- [17] Garcia-Tsao G, Groszmann RJ, Fisher RL et al. Portal pressure, presence of gastroesophageal varices and variceal bleeding. Hepatology 1985; 5: 419-424.
- [18] Groszmann RJ, Garcia-Tsao G, Bosch J et al. Beta-blockers to prevent gastroesophageal varices in patients with cirrhosis. N Engl J Med 2005; 353:2254-2261.
- [19] Ripoll C, Groszmann R, Garcia-Tsao G et al. Hepatic venous pressure gradient predicts clinical decompensation in patients with compensated cirrhosis. Gastroenterology 2007; 133:481-488.
- [20] Ripoll C, Groszmann RJ, Garcia-Tsao G et al. Hepatic venous pressure gradient predicts development of hepatocellular carcinoma independently

of severity of cirrhosis. *J Hepatol* 2009; 50: 923-928.

[21] Berzigotti A, Reig M, Abraldes JG et al. Portal hypertension and the outcome of surgery for hepatocellular carcinoma in compensated cirrhosis: a systematic review and meta-analysis. *Hepatology* 2015; 61: 526-536

[22] Habib A, Sanyal AJ. Acute variceal hemorrhage. *Gastrointest Endosc Clin N Am* 2007; 17:223-252, v.

[23] De Franchis R, Dell'Era A, Iannuzzi F. Diagnosis and treatment of portal hypertension. *Dig Liver Dis.* 2004; 36:787-798.

[24] Silva-Junior G, Baiges A, Turon F et al. The prognostic value of hepatic venous pressure gradient in patients with cirrhosis is highly dependent on the accuracy of the technique. *Hepatology* 2015; 62:1584-1592.

[25] Abraldes JG, Villanueva C, Banares R ~ et al. Hepatic venous pressure gradient and prognosis in patients with acute variceal bleeding treated with pharmacologic and endoscopic therapy. *J Hepatol* 2008;48: 229-236.

[26] Rincon D, Lo Iacono O, Ripoll C et al. Prognostic value of hepatic venous pressure gradient for in-hospital mortality of patients with severe acute alcoholic hepatitis. *Aliment Pharmacol Ther* 2007; 25:841-848.

[27] Serste T, Bourgeois N, Lebre C, Evrard S, Devière J, Le Moine O. Relationship between the degree of portal hypertension and the onset of spontaneous bacterial peritonitis in patients with cirrhosis. *Acta gastroenterologica Belgica.* 2006;69(4):355.

[28] Berzigotti A, Seijo S, Reverter E, Bosch J, Bosch, Groszmann; Portal Hypertension Collaborative Group, Casado, García-Pagán, Fernández, Roskams. Assessing portal hypertension

in liver diseases. *Expert review of gastroenterology & hepatology.* 2013 Feb 1;7(2):141-155.

[29] Groszmann RJ, Wongcharatrawee S. The hepatic venous pressure gradient: anything worth doing should be done right. *Hepatology.* 2004 Feb;39(2): 280-283.

[30] Bosch J, Navasa M, Garcia-Pagan JC, Delacy AM, Rodes J: Portal hypertension. *Med Clin North Am* 1989; 73:931-953.

[31] Thompson R, Taylor M, McKie L, Diamond T. Sinistral Portal Hypertension. *Ulster Med J.* 2006; 75 (3) 175-177.

[32] Singhal D, Kakodkar R, Soin A, Gupta S, Nundy S. Sinistral Portal Hypertension. A Case Report. *JOP.* 2006; 7(6):670-667.

[33] Koklu S, Coban S, Yuksel O, Arhan M. Left-Sided Portal Hypertension. *Dig Dis Sci.* 2007; 52:1141-1149

[34] Li ZS, Tang CW, Qian JM, Yuan YZ, Wang XP. Practice guidance for diagnosis and treatment of pancreatitis-related splanchnic vein thrombosis (Shenyang, 2020). *Journal of Digestive Diseases.* 2020 Nov 20.

[35] Adams DB, Mauterer DJ, Vujic IJ, Anderson MD. Preoperative control of splenic artery inflow in patients with splenic venous occlusion. *South Med J.* 1990; 83:1021-1024.

[36] Habib A, Sanyal AJ. Acute variceal hemorrhage. *Gastrointest Endosc Clin N Am* 2007; 17:223-252, v.

[37] Zaman A. Current Management of Esophageal Varices. *Curr Treat Options Gastroenterol* 2003; 6:499-507

[38] Carbonell N, Pauwels A, Serfaty L, Fourdan O, Lévy VG, Poupon R. et al. Improved survival after variceal bleeding in patients with cirrhosis over

the past two decades. *Hepatology* 2004; 40:652-659.

[39] Castaneda B, Debernardi-Venon W, Bandi JC, Andreu V, Pérez-del-Pulgar S, Moitinho E, Pizcueta P, Bosch J, et al. The role of portal pressure in the severity of bleeding in portal hypertensive rats. *Hepatology* 2000; 31:581-586

[40] Russo MW. Variceal Bleeding. *Curr Treat Options Gastroenterol.* 2002; 5:471-477.

[41] Bernard B, Lebrec D, Mathurin P, Opolon P, Poynard T. Beta-adrenergic antagonists in the prevention of gastro-intestinal rebleeding in patients with cirrhosis: a meta-analysis. *Hepatology* 1997; 25:63-70.

[42] De Franchis R. Evolving consensus in portal hypertension. Report of the Baveno IV consensus workshop on methodology of diagnosis and therapy in portal hypertension. *J Hepatol* 2005; 43:167-176

[43] Bosch J, Garcia-Pagan JC. Prevention of variceal rebleeding. *Lancet* 2003; 361:952-954.

[44] Hamal AB, KC S, Thapa P, Sharma D, Karki N, et al. Carvedilol Versus Propranolol for Secondary Prophylaxis of Variceal Hemorrhage in Patients with Liver Cirrhosis. *Adv Res Gastroentero Hepatol*, 2020; 15(4): 555920.

[45] Kamath PS, Shah VH: Portal Hypertension and Bleeding Esophageal Varices. *Zakim and Boyer's Hepatology: A Textbook of Liver Disease* (6th ed). In: Boyer TD, Manns MP, Sanyal AJ (ed): Elsevier Saunders, Philadelphia; 2012. 296-326.

[46] Feldman M, Lee EL: Pathophysiology, Diagnosis, Management. *Sleisenger and Fordtran's Gastrointestinal and Liver Disease* (10th ed). In: Feldman M, Friedman LS, Brandt LJ (ed): Elsevier Saunders, Philadelphia; 2010. 868-883

[47] Vigneri S, Termini R, Piraino A, Scialabba A, Pisciotta G, Fontana N: The stomach in liver cirrhosis. Endoscopic, morphological, and clinical correlations. *Gastroenterology.* 1991;101:472-478.

[48] McCormack TT, Sims J, Eyre-Brook I, Kennedy H, Goepel J, Johnson AG, Triger DR: Gastric lesions in portal hypertension: inflammatory gastritis or congestive gastropathy? *Gut.* 1985;26:1226-1232.

[49] Tiwari P S, Kc S, Sharma D, et al. (August 21, 2019) Prevalence of Portal Hypertensive Gastropathy in Chronic Liver Disease and Correlation with the Severity of Liver disease. *Cureus* 11(8): e5454.

[50] Gjeorgjievski M, Cappell MS: Portal hypertensive gastropathy: a systematic review of the pathophysiology, clinical presentation, natural history and therapy. *World J Hepatol.* 2016, 8:231-262.

[51] Primignani M, Carpinelli L, Preatoni P, Battaglia G, Carta A, Prada A, Cestari R, Angeli P, Gatta A, Rossi A, Spinzi G. Natural history of portal hypertensive gastropathy in patients with liver cirrhosis. *Gastroenterology.* 2000 Jul 1; 119(1): 181-187.

[52] Bates JA. *Abdominal Ultrasound.* 2nd ed. Edinburgh: Churchill Livingstone; 2004. p. 97-107.

[53] Moore KP, Wong F, Gines P, Bernardi M, Ochs A, Salerno F, Angeli P, Porayko M, Moreau R, Garcia-Tsao G, Jimenez W. The management of ascites in cirrhosis: report on the consensus conference of the International Ascites Club. *Hepatology.* 2003 Jul 1;38(1):258-266.

[54] Ding X, Yu Y, Chen M, Wang C, Kang Y, Lou J. Causative agents and outcome of spontaneous bacterial peritonitis in cirrhotic patients: community-acquired versus nosocomial

- infections. BMC infectious diseases. 2019 Dec 1; 19(1):463.
- [55] Acharya SK. Difficult to treat spontaneous bacterial peritonitis. Tropical Gastroenterology. 2013 May 18;34(1):7-13.
- [56] Elsaddek HM, Elhawari SA, Mokhtar A. A novel serum index for accurate diagnosis of spontaneous bacterial peritonitis in cirrhotic patients without other infections. Egyptian Liver Journal. 2020 Dec; 10(1):1-8.
- [57] Enomoto H, Inoue SI, Matsuhisa A, Nishiguchi S. Diagnosis of spontaneous bacterial peritonitis and an in situ hybridization approach to detect an “unidentified” pathogen. International journal of hepatology. 2014 Jan 1; 2014.
- [58] Epstein M. Hepatorenal syndrome: emerging perspectives of pathophysiology and therapy. J Am Soc Nephrol JASN. 1994 Apr;4(10):1735-1753
- [59] Low G, Alexander GJM, Lomas DJ. Hepatorenal Syndrome: Aetiology, Diagnosis, and Treatment [Internet]. Gastroenterology Research and Practice. 2015.
- [60] Angeli P et al. News in pathophysiology, definition and classification of hepatorenal syndrome: A step beyond the International Club of Ascites (ICA) consensus document. J Hepatol (2019).
- [61] Garbuzenko DV, Arefyev NO. Hepatic hydrothorax: An update and review of the literature. World J Hepatol 2017; 9(31): 1197-1204
- [62] Lazaridis KN, Frank JW, Krowka MJ, Kamath PS. Hepatic hydrothorax: pathogenesis, diagnosis, and management. Am J Med 1999; 107: 262-267.
- [63] Huang PM, Chang YL, Yang CY, Lee YC. The morphology of diaphragmatic defects in hepatic hydrothorax: thoracoscopic finding.
- J Thorac Cardiovasc Surg 2005; 130: 141-145.
- [64] The European Association for the Study of the Liver. EASL Clinical Practice Guidelines for the management of patients with decompensated cirrhosis. J Hepatol (2018), <https://doi.org/10.1016/j.jhep.2018.03.024>.
- [65] De BK, Dutta D, Pal SK, Gangopadhyay S, Das Bakshi S, Pani A. The role of garlic in hepatopulmonary syndrome: a randomized controlled trial. Can J Gastroenterol 2010; 24:183-188.
- [66] Porres-Aguilar M, Gallegos-Orozco JF, Garcia H, Aguirre J, Macias-Rodriguez RU, Torre-Delgadillo A. Pulmonary vascular complications in portal hypertension and liver disease: a concise review. Rev Gastroenterol Mex. 2013;78(1):35-44. doi: 10.1016/j.rgmex.2012.10.004.
- [67] Hadengue A, Benhayoun MK, Lebrec D, Benhamou JP. Pulmonary hypertension complicating portal hypertension: prevalence and relation to splanchnic hemodynamics. Gastroenterology. 1991 Feb 1; 100(2): 520-528.
- [68] Ito K, Shiraki K, Sakai T, Yoshimura H, Nakano T. Portal hypertensive colopathy in patients with liver cirrhosis. World Journal of Gastroenterology: WJG. 2005 May 28; 11(20):3127.
- [69] Wiese S, Hove JD, Bendtsen F, Møller S. Cirrhotic cardiomyopathy: pathogenesis and clinical relevance. Nature reviews Gastroenterology & hepatology. 2014 Mar;11(3):177.
- [70] Baldassarre M, Giannone FA, Napoli L, Tovoli A, Ricci CS, Tufoni M, et al. The endocannabinoid system in advanced liver cirrhosis: pathophysiological implication and future perspectives. Liver Int. 2013;33: 1298-1308.

- [71] Van Obbergh L, Vallieres Y, Blaise G. Cardiac modifications occurring in the ascitic rat with biliary cirrhosis are nitric oxide related. *J Hepatol*. 1996;24: 747-752.
- [72] Wong F. Cirrhotic cardiomyopathy. *Hepatol Int*. 2009; 3:294-304.
- [73] Henriksen JH, Bendtsen F, Hansen EF, Moller S. Acute non-selective beta-adrenergic blockade reduces prolonged frequency-adjusted Q-T interval (QTc) in patients with cirrhosis. *J Hepatol*. 2004; 40:239-246.
- [74] Franceschet I, Zanetto A, Ferrarese A, Burra P, Senzolo M. Therapeutic approaches for portal biliopathy: A systematic review. *World J Gastroenterol*. 2016 Dec 7; 22(45):9909-9920.
- [75] Dhiman RK, Saraswat VA, Valla DC, Chawla Y, Behera A, Varma V, Agarwal S, Duseja A, Puri P, Kalra N, et al. Portal cavernoma cholangiopathy: consensus statement of a working party of the Indian national association for study of the liver. *J Clin Exp Hepatol*. 2014;4: S2–S14.
- [76] Verbeke L, Farre R, Trebicka J, Komuta M, Roskams T, Klein S, Elst IV, Windmolders P, Vanuytsel T, Nevens F, Laleman W. Obeticholic acid, a farnesoid X receptor agonist, improves portal hypertension by two distinct pathways in cirrhotic rats. *Hepatology*. 2014 Jun; 59(6):2286-2298.
- [77] Pose E, Trebicka J, Mookerjee RP, Angeli P, Ginès P. Statins: old drugs as new therapy for liver diseases? *Journal of hepatology*. 2019 Jan 1;70(1):194-202.
- [78] Trebicka J, Hennenberg M, Laleman W, et al. Atorvastatin lowers portal pressure in cirrhotic rats by inhibition of RhoA/Rho-kinase and activation of endothelial nitric oxide synthase. *Hepatology* 2007; 46: 242-253.
- [79] Abraldes JG, Rodríguez-Vilarrupla A, Graupera M, et al. Simvastatin treatment improves liver sinusoidal endothelial dysfunction in CCl4 cirrhotic rats. *J Hepatol* 2007; 46: 1040-1046.
- [80] Pollo-Flores P, Soldan M, Santos UC, et al. Three months of simvastatin therapy vs. placebo for severe portal hypertension in cirrhosis: a randomized controlled trial. *Dig Liver Dis* 2015; 47: 957-963.
- [81] Abraldes JG, Villanueva C, Aracil C, et al. Addition of simvastatin to standard therapy for the prevention of variceal rebleeding does not reduce rebleeding but increases survival in patients with cirrhosis. *Gastroenterology* 2016; 150: 1160-1170.e3
- [82] Gracia-Sancho J, Contreras PC, Vila S, et al. The pan caspase inhibitor emricasan improves the hepatic microcirculatory dysfunction of CCl4-cirrhotic rats leading to portal hypertension amelioration and cirrhosis regression. *Hepatology* 2016; 64: 811-1050.
- [83] Vilaseca M, García-Calderó H, Lafoz E, et al. The anticoagulant rivaroxaban lowers portal hypertension in cirrhotic rats mainly by deactivating hepatic stellate cells. *Hepatology* 2017; 65: 2031-2044.
- [84] Armstrong MJ, Gaunt P, Aithal GP, et al. Liraglutide safety and efficacy in patients with non-alcoholic steatohepatitis (LEAN): a multicentre, double-blind, randomised, placebo-controlled phase 2 study. *Lancet* 2016; 387: 679-690.
- [85] Tripathi DM, Erice E, Lafoz E, et al. Metformin reduces hepatic resistance and portal pressure in cirrhotic rats. *Am J Physiol Gastrointest Liver Physiol* 2015; 309: G301–G309.
- [86] Wang W, Yan J, Wang H, et al. Rapamycin ameliorates inflammation and fibrosis in the early phase of

cirrhotic portal hypertension in rats through inhibition of mTORC1 but not mTORC2. PLoS One 2014; 9: e83908.

[87] Mejias M, Garcia-Pras E, Gallego J, et al. Relevance of the mTOR signaling pathway in the pathophysiology of splenomegaly in rats with chronic portal hypertension. J Hepatol 2010; 52: 529-539.

[88] Schwarzer R, Kivaranovic D, Mandorfer M, Paternostro R, Wolrab D, Heinisch B, Reiberger T, Ferlitsch M, Gerner C, Trauner M, Peck-Radosavljevic M. Randomised clinical study: the effects of oral taurine 6 g/day vs placebo on portal hypertension. Alimentary pharmacology & therapeutics. 2018 Jan; 47(1):86-94.