

We are IntechOpen, the world's leading publisher of Open Access books Built by scientists, for scientists

6,900

Open access books available

186,000

International authors and editors

200M

Downloads

Our authors are among the

154

Countries delivered to

TOP 1%

most cited scientists

12.2%

Contributors from top 500 universities



WEB OF SCIENCE™

Selection of our books indexed in the Book Citation Index
in Web of Science™ Core Collection (BKCI)

Interested in publishing with us?
Contact book.department@intechopen.com

Numbers displayed above are based on latest data collected.
For more information visit www.intechopen.com



Compartment Syndrome Related to Patient Positioning in the Surgical Treatment of Urolithiasis

*Inés Laso-García, Fernando Arias-Fúnez,
Gemma Duque-Ruiz, David Díaz-Pérez,
Alberto Artiles-Medina and Javier Burgos-Revilla*

Abstract

The incidence of urolithiasis is progressively increasing worldwide, as is the surgical treatment of urinary stones. The most frequent surgery for urolithiasis is ureterorenoscopy, which is performed in the lithotomy position. This position is also used in the endoscopic approach to bladder stones. Lateral decubitus is rarely used in the treatment of urinary stones. In the case of complex kidney stones, the gold standard treatment is percutaneous nephrolithotomy. This surgery has traditionally been performed in the prone position. However, the use of the supine (Valdivia) position is increasing in recent times. Furthermore, the Galdakao-modified supine Valdivia position has been widely used for percutaneous nephrolithotomy since it was described by Ibarluzea et al. in 2007. Treatment of kidney and ureteral stones simultaneously is allowed in both supine positions. In addition, they allow the removal of encrusted stents and the easy placement of double J stents and, in the case of the Galdakao-modified supine Valdivia position, percutaneous nephrostomies. Compartment syndrome is a rare complication in the lithotomy position, but scarcely described in the supine position. This especially applies to the Galdakao-modified supine Valdivia position, in which the lower limbs are in moderate flexion, with the ipsilateral lower limb in a slightly lower position relative to the other. This complication can lead to skin necrosis, myoglobinuric renal failure, amputation, permanent neuromuscular dysfunction, and even death. Risk factors include Body Mass Index, male gender, obesity, increased muscle mass, peripheral vascular disease (advanced age, hypertension, hyperlipidemia and diabetes mellitus), height, lack of operative experience, significant bleeding during surgery, hypothermia, acidemia, combination general-spinal anesthesia, prolonged surgical time, systemic hypotension, ASA (American Society of Anesthesiologists) class or vasoconstrictor drugs. Therefore, compartment syndrome of the leg is a potentially devastating complication that must be suspected and treated through early decompression of the compartment by four compartment fasciotomy. Preventive measures reduce the incidence of this condition.

Keywords: lithiasis, percutaneous nephrolithotomy, Galdakao-modified supine valdivia position, complications, compartment syndrome

1. Introduction

1.1 Urolithiasis

Urinary lithiasis is a disease known since ancient times, characterized by the formation of urinary stones (**Figure 1**). The prevalence of lithiasis in the population in 1913 has been estimated to be 1–2%, and a progressive increase has been found to 2.7% in 1985. [1] An article studying the evolution of the prevalence in a 25-year-period, showed an annual increase in stone formation. The prevalence of lithiasis in population has grown even more in recent years. [2] The incidence of lithiasis in the United States doubled in a 4 year-period. [3]

Furthermore, Scales et al. described a prevalence of almost 9% of the population. [4] Nevertheless, it has been observed a variation according to the country studied: 1–5% in Asia, 5–9% in Europe, 13% in North America and 20% in Saudi Arabia. [5]

In recent years, in the United Kingdom, a 63% increase in hospitalization episodes associated with urolithiasis has been observed. [6] The number of extracorporeal shock wave lithotripsy has increased from 14,491 in 2000 to 822,402 in 2010. There has been an increase of 127% in the number of ureteroscopies. The acts aimed at treating urinary lithiasis have increased compared to other urological activities. In 2010, shock wave lithotripsy was performed with the same frequency as transurethral resection of the prostate or transurethral resection of the bladder. More ureteroscopies were performed than nephrectomies, prostatectomies, and cystectomies combined; and more percutaneous nephrolithectomies than cystectomies. [7] Therefore, the surgical treatment of urolithiasis is of great clinical relevance.

1.2 Surgical positions in urological surgery and urolithiasis

The most frequent surgery for urolithiasis is ureterorenoscopy, which is performed in the lithotomy (Lloyd-Davies) position. This position is also used in the endoscopic approach to bladder stones.

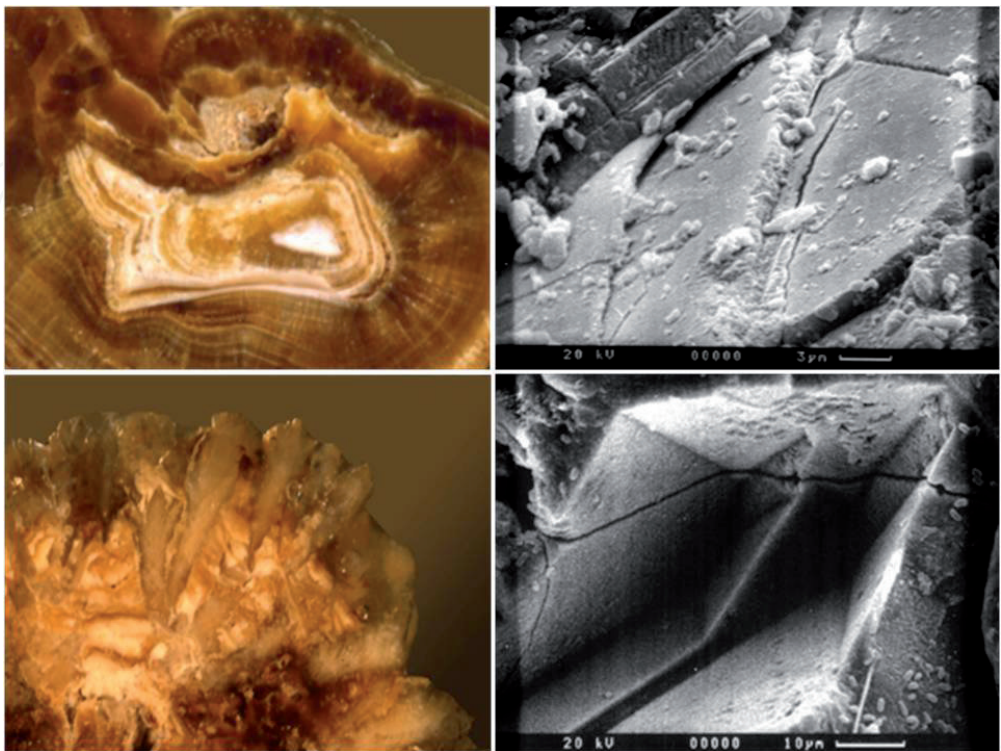


Figure 1.
Calcium oxalate lithiasis: conventional microscope and scanning electron microscope.

Percutaneous nephrolithectomy is currently the treatment of choice for complex renal and renoureteral stones (for example, staghorn lithiasis, **Figure 2**). This surgery has traditionally been performed in the prone position, but in recent years the number of urologists who perform it in the supine position (Valdivia Position) has increased. [8–11]

Ibarluzea et al. described the Galdakao-modified supine Valdivia position in 2007, and it has been widely used for percutaneous nephrolithotomy since then. [11] Treatment of kidney and ureteral stones simultaneously is allowed in both supine positions. In addition, they allow the removal of encrusted stents and the easy placement of double J stents and, in the case of the Galdakao-modified supine Valdivia position, percutaneous nephrostomies. Unlike the prone position, the patient does not need to be relocated during surgery, shortening the operating time. In addition, it allows two surgeons to operate simultaneously.

1.3 The Galdakao-modified supine valdivia position for percutaneous nephrolithotomy

Occasionally, lower extremities are bandaged to prevent venous thrombosis. Once the patient is placed, retrograde pyelography is performed. The upper urinary tract is accessed through an X-ray and ultrasound guided puncture of the lower calyx. After Alken telescopic dilatation, an Amplatz sheath is placed to allow the passage of a nephroscope, reaching the upper urinary tract lumen.

Using the nephroscope and a retrograde flexible ureteroscope, the whole upper urinary tract can be managed, as described by Ibarluzea and Scoffone. [10, 11] This procedure is called Endoscope Combined IntraRenal Surgery (ECIRS).

Sources of lithiasis fragmentation, such as Holmium laser, as well as nitinol baskets, are used to remove the lithiasis. If the stone is too complex, this process can be lengthy, or even ineffective, in treating the entire stone.

1.4 Compartment syndrome related to patient positioning

The position in which a patient is placed, and the duration for which it is maintained, are key factors in the development of well-leg compartment syndrome.

Acute compartment syndrome of the extremities rarely develops in the supine position, commonly used in urologic open surgeries, such as cystolithotomy. Lateral decubitus position is rarely used in the treatment of urolithiasis. Laparoscopic

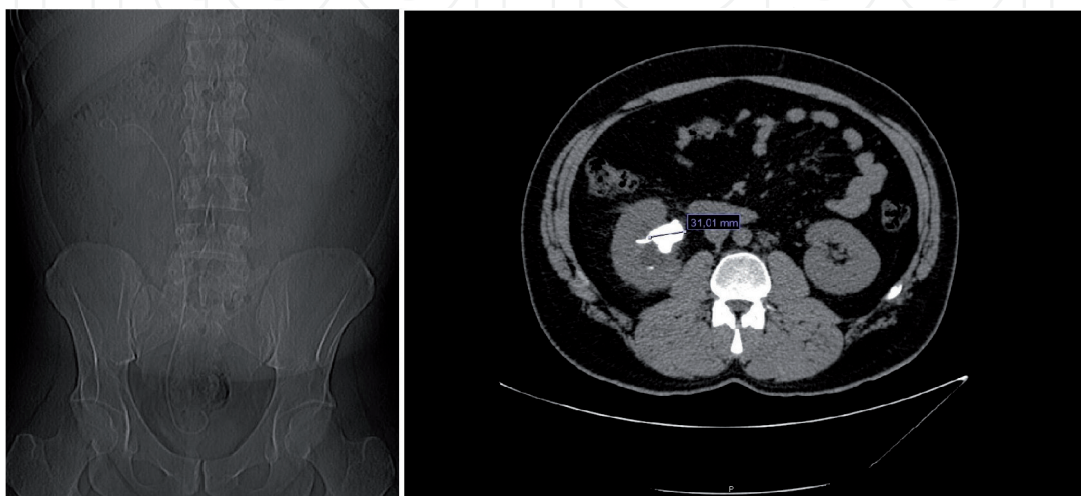


Figure 2.
Right kidney staghorn lithiasis.

pyelolithectomy would be one of the examples. General complications of lateral decubitus positioning are similar to those found with the supine position.

It has been described that lithotomy position, in general surgical, urological and orthopedic patients, is associated with changes in intracompartmental pressure that may eventually develop a compartment syndrome, especially in prolonged surgeries. [12–15]

Well-leg compartment syndrome has also been described in patients placed in the hemilithotomy position. The majority of cases described in the literature have been lengthy procedures with surgical time greater than 5 h. [13]

Prolonged positioning in a steep Trendelenburg position during, for example, a laparoscopic prostatectomy, may cause hypoperfusion of the lower extremities, pressure marks, tissue injury, and even rhabdomyolysis. After long surgical procedures involving extreme positions, rhabdomyolysis from muscle ischemia has been observed. [16]

Acute compartment syndrome of the leg occurs following a rise in the pressure inside the muscle compartment. [16] A significant decrease in deep muscle mixed tissue oxygen saturation of calf muscles is observed, due to the combined effect of perfusion related factors, such as hydrostatic forces, blood and intra-abdominal pressure, which lead to tissue underperfusion. [17, 18]

A delay in the diagnosis and treatment of a compartment syndrome may lead to devastating outcomes for the patient. [19] It may lead to admission to an Intensive Care Unit and necessity of renal replacement therapy, multiple organ dysfunction syndrome, and even death.

Therefore, the suspicion of this syndrome in a patient who presents symptoms compatible with this adverse outcome, is essential to avoid further complications.

2. Epidemiology

Prolonged urological surgeries performed in the lithotomy or extreme Trendelenburg positions for the treatment of urolithiasis may rarely lead to well-leg compartment syndrome. [20] It is thought to be underreported in the literature, especially those with less severe clinical features. Moreover, it is generally misdiagnosed as other possible surgical complications, such as deep vein thrombosis or neuropraxia. [21, 22] In the lithotomy position, the estimated total rate is approximately 1: 3500. [17]

However, studies reporting on the compartment syndrome associated with the lithotomy position in the fields of general and gynecological surgeries are somewhat frequent [23] This complication has also been described in the literature regarding urological surgeries. [21] In some cases, the complication occurs in both extremities simultaneously. [24–26] This circumstance is often described in relation to the performance of a radical prostatectomy, either laparoscopic or robotic, in the extreme Trendelenburg position. [19, 27]

Nonetheless, the appearance of this complication is not frequent during a percutaneous nephrolithotomy. It has hardly been reported in both supine positions, in which the lower limbs present a more moderate flexion than in other endourological procedures. In the Galdakao-Modified Supine Valdivia Position, the patient is placed in a slightly different position from the classic lithotomy, with the lower limbs in moderate flexion, and with the ipsilateral lower limb in a slightly inferior position with respect to the other (**Figure 3**). [28] On the other hand, the appearance of acute abdominal compartment syndrome has already been described during the performance of a percutaneous nephrolithotomy. [29]

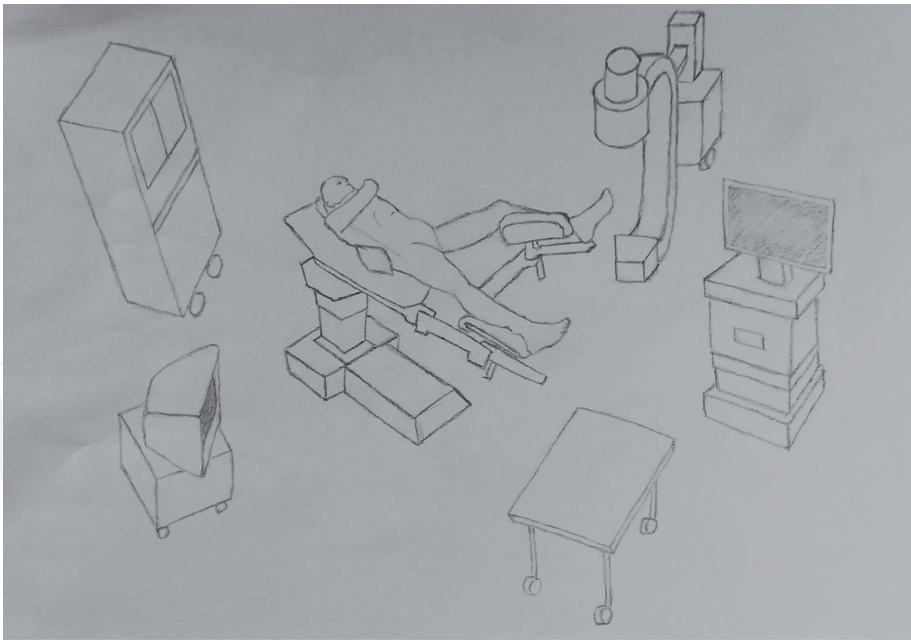


Figure 3.
The Galdakao-modified supine Valdivia position.

3. Etiology

Risk factors (**Table 1**) associated with the development of compartment syndrome reported include Body Mass Index (BMI), male gender, obesity, height, peripheral vascular disease (advanced age, hypertension, hyperlipidemia and

Related to the patient	Obesity
	Advanced age
	Hypertension
	Hyperlipidemia
	Diabetes Mellitus
	Height
	BMI
	Male sex
	ASA (American Society of Anesthesiologists) class
	Increased muscle bulk
Related to the surgery	Prolonged surgery time
	Systemic hypotension
	Acidemia
	Lack of operative experience
	Combined general-spinal anesthesia
	Hypothermia
	The use of vasoconstricting drugs
	Important bleeding during the surgery
	Wrapping elevated legs

Table 1.
Risk factors associated to the development of compartment syndrome.

diabetes mellitus), lack of operative experience, significant bleeding during surgery, hypothermia, acidemia, combination general-spinal anesthesia, prolonged surgical time, systemic hypotension, ASA (American Society of Anesthesiologists) class or vasoconstrictor drugs. Increased muscle bulk is associated with a tighter and less compliant compartment, and also with greater accumulation of toxic metabolites and free radicals. [17, 18, 21–23, 29–31]

The use of compressive leg wraps has been associated with well-leg compartment syndrome in some studies, [12] while in others a reduction in intracompartment pressure of the lower leg was observed with the use of external intermittent compression. [14]

4. Pathophysiology

Compartment syndromes can arise in any area of the body that has little or no capacity for tissue expansion, such as the abdomen, buttocks and hands.

The lower extremity has four main compartments, which are superficial posterior, deep posterior, anterior and lateral. Bone and inelastic fascial layers border the muscles and neurovascular structures. The following nerves traverse these compartments: the tibial and sural nerves, and the superficial and deep branches of the peroneal nerve. The compartment can be accommodated to a limited extent by the sheath. [16] Most commonly involved compartment is the anterior one. [21] As soon as legs are placed in the lithotomy position, the compartmental pressures begin to increase. [17] The height above the level of the heart at which the legs rise is crucial. [17, 18]

An increase in intracompartment pressure in the lithotomy position, with the use of support behind the calf or knee, has been described from 10.7 (SD 5.8) mmHg to 16.5 (SD 3.4) mmHg. [14] Circulation compromise occurs with increased tissue pressure within a closed osteofascial compartment. Compression of the calf produces local ischaemia through two mechanisms: by direct occlusion of the arterial blood flow and by indirect obstruction of the venous drainage. The weight of the limb itself, as well as the use of devices such as braces and cushions, produces greater compression. It should also be noted that operating personnel can cause more compression. [17]

The difference between capillary perfusion pressure and the interstitial fluid pressure determines tissue perfusion. When interstitial fluid pressure exceeds capillary perfusion pressure, capillary collapse and consequent ischemia of the muscles and nerves occurs. [32] It has two main implications: a decrease in the rates of both delivery of oxygenated arterial blood and drainage of deoxygenated venous blood. [17]

The integrity of the vascular endothelium is impaired by initial ischemia. Its capacity as a barrier to the movement of solute and serum disappears. Thus, a self-perpetuating cycle of ischaemia and tissue oedema begins. When the patient returns to the initial position, the compartment pressure may increase even further, producing a reperfusion injury. [16, 17] After 1 h of ischaemia, on restoring blood flow, through the release of prostaglandins and thromboxane, platelets are activated. This may predispose to deep vein thrombosis, which may increase venous pressure and therefore, compromise local blood flow. [18]

In addition, once reperfusion occurs, large amounts of toxic intracellular content are released into the bloodstream. They are the markers of rhabdomyolysis. [18] After surgery, serum creatine phosphokinase increases significantly, peaking at 18 hours. [19] The main pathophysiologic mechanisms involved in renal insufficiency from rhabdomyolysis are renal vasoconstriction, intraluminal cast formation, and direct myoglobin toxicity. [16]

5. Clinical features

5.1 Clinical findings

Once the patient is in the recovery room, in the immediate postoperative period, despite analgesic infusion, significant pain is reported in the lower extremity (a pain out of proportion). The limb appears oedematous and cyanotic, although the pedis pulses may be preserved. General inflammation of the leg and dorsal ankle flexion and toe mobility deficit is observed. In a more advanced stage, we may observe the absence of peripheral pulses. [24]

5.2 Intraoperative findings

Once the compartment fasciotomy has been performed, we can observe that only the deep compartments may be affected by ischemia. In this case, the muscle mass of the anterolateral compartment and the deep posteromedial compartment shows evidence of necrosis. Muscles show pale pink edema. Stimulation with an electric scapel shows absence of contractility. Correct tonality and contractility can be seen in the muscle mass of both superficial compartments if this occurs. When diagnosis and treatment are delayed, both deep and superficial masses are affected by ischemia.

6. Diagnosis

After lengthy surgeries, we must be aware of the possibility of the development of a compartment syndrome. Prompt diagnosis and treatment should be performed using a four-compartment fasciotomy to avoid serious and irreversible complications. [23]

The appearance of the following signs and symptoms must warn us: pink skin, presence of pulse, paresis of muscles, paraesthesia and a disproportionate pain, generally described by the patient as burning and deep. It is reproduced by passive stretching of the muscles of the compartment. The diagnosis is more difficult in unconscious and sedated patients.

On analysis, serum creatinine kinase activity is increased. We must bear in mind that the first signs are subtle and more often neurological. This is due to the fact that nonmyelinated type C sensory fibers are the tissues most sensitive to hypoxia. [21, 32] Therefore, a delay in the diagnosis should be considered with the use of epidural anesthesia, due to a masking effect. [21]

However, the definitive diagnosis is made by direct measurement of the compartmental pressure. Compartment pressure can be measured with different pressure catheters. These catheters have fine bore and their use is associated with minimal morbidity. [24] It can be measured by using a simple needle manometer, continuous infusion, wick catheter, slit catheter, or solid-state transducer method. [30] The indication for a fasciotomy is a value greater than 20–30 mmHg, although it may vary depending on the perfusion pressure and the clinical setting. [32]

We can use various non-invasive imaging techniques to determine intracompartiment pressure, including laser Doppler flowmetry, ultrasonic devices, or near infrared spectroscopy. [16] These techniques might be particularly useful in pediatric patients, in whom invasive monitoring is not ideal. Near-infrared spectroscopy has proven useful in one-month-old infants. Nevertheless, both laser Doppler flowmetry and near-infrared spectroscopy may be more useful in chronic compartment syndrome, as they measure variations in muscle oxygenation. In acute compartment syndrome, changes may have already occurred at the time of

measurement. Magnetic resonance imaging has limited utility in the diagnosis of acute compartment syndrome, as it can detect oedema and swelling, but only when the syndrome is well established, delaying the diagnosis.

In rhabdomyolysis, we can observe the presence of myoglobinuria in the absence of urinary erythrocytes. An increase in serum creatine phosphokinase activity is observed. Increased levels of other markers, such as phosphate, potassium, lactate dehydrogenase, aspartate, and alanine aminotransferase, may be seen in rhabdomyolysis. [17]

Venous thrombosis should be ruled out through Doppler ultrasound. Differential diagnoses include venous thrombosis and peripheral nerve or arterial injury.

It has to be taken into account that the limb may be capable of being saved up to 10–12 hours after the complication sets in.

7. Treatment

7.1 Surgical treatment

Regarding treatment (**Table 2**), early decompression of the compartment must be performed by an orthopedic surgeon, to avoid the self-perpetuating cycle of ischaemia and oedema.

Long incisions (20–25 cm) are made along the length of the leg. After that adequate and extensile incision, complete released of all involved compartment and preservation of vital structures is performed. All necrotic tissue is removed. Care should be taken to avoid the superficial peroneal nerve damage. The relief of pressure minimizes functional impairment, structural damage, and breaks the cycle of ischemia and edema, preventing additional devitalization of tissue and infection risk. [12]

If necessary, the four compartments are open, and if the muscles are under tension, the skin is left open, and approximated with vessel-loop temporarily. Only around 15% can be primarily closed without high compartment pressure.

Surgical treatment	If necessary, four compartments opening Long incisions (20–25 cm) along the length of the leg Complete release of all involved compartments Preservation of vital structures Necrotic tissue removal Avoidance of superficial peroneal nerve damage In muscles under tension: skin left open Use of moist dressings Skin incisions closing after a few days (for repeat irrigation and debridement)
Medical treatment	Adequate analgesia Early and aggressive fluid replacement Central venous monitoring Transferring to high dependency unit/intensive care therapy unit Adequately hydration (target urinary output of at least 0.5 ml/kg.) Use of mannitol (renal vasodilator effect, expands intravascular volume and decreases oxygen radicals) Urinary pH maintained as neutral as possible (avoidance urate and myoglobin precipitation): sodium bicarbonate or acetazolamide

Table 2.
Surgical and medical treatment of well-leg compartment syndrome.

Moist dressings are used the following days, and the skin incisions are usually closed after a few days or weeks with a non-absorbable (polypropylene) suture. There may be need for repeat irrigation and debridement before final wound closure. [17, 32]

Other options for the closure of fasciotomy wounds include split-thickness skin graft. It has been recommended the use of meshed split-thickness skin graft secured with foam vacuum suction dressing after excising all devitalized tissues. [24]

Pain is a major feature of compartment syndrome and adequate analgesia should be prescribed. [16]

7.2 Medical treatment

Creatine phosphokinase may reach values over 80,000 IU / L. In rhabdomyolysis, myoglobinuric renal failure develops, followed by multisystemic organ failure and possible death. Renal failure should be treated with early and aggressive fluid replacement, central venous monitoring and transfer to high dependency unit/intensive care therapy unit.

Mean Arterial Pressure should be maintained over 65 mmHg. Patients should be adequately hydrated to achieve a target urinary output of at least 0.5 mL/Kg. [16] Mannitol may be used as it has a renal vasodilator effect. It also expands intravascular volume and decreases oxygen radicals. Urinary pH should be maintained as neutral as possible to avoid urate and myoglobin precipitation by alkalizing urine with sodium bicarbonate or acetazolamide. [21]

Wound infection is a potential complication, which has to be considered and controlled.

Through intensive therapy with serum and diuretics, a progressive and complete recovery of kidney function is usually achieved. Rhabdomyolysis is also controlled, observing a decrease in its markers during admission to the Intensive Care Unit.

Before the patient is discharged from hospital, it is advisable to request the Rehabilitation Service to improve leg recovery and normal mobility.

8. Prognosis

The damage is thought to be reversible if the ischemic time is less than 2 hours. When cell death occurs it results in permanent disability (in this order: sensitive nerves, motor nerves, muscle and bone). [17]

Prognosis depends on various factors: injury severity, duration of ischaemia, pre-injury status and comorbidities and, most importantly, time to fasciotomy. [32]

A delay in decompression may lead to 20% of the patients requiring amputation. Muscle necrosis and nerve ischemia lead to permanent neuromuscular dysfunction after the first 12 hours. [16] Other possible sequela is a Volkmann contracture. Exposure of the necrotic muscle after a delayed surgery is associated with loss of the extremity. [17]

In case the diagnosis has been missed or delayed, definitive reconstructive surgery should be postponed. Meanwhile, the patient should be treated through supportive renal therapy until the morbidity has been removed. [32]

From the four compartments of the legs, the loss of one or two can be tolerated. If the patient attends aggressive physical therapy, and also uses ankle-foot braces or splints, he or she can return to normal ambulation eventually. However, if more than two compartments are affected, amputation is sometimes required. The following sequelae are the consequence of nerve injuries: claw or hammer toes, cavus foot, quinovarus, ankle equines, foot drop. All this causes difficulties in the use of footwear, pressure zones as a result of the deformity and impairment of gait. [21]

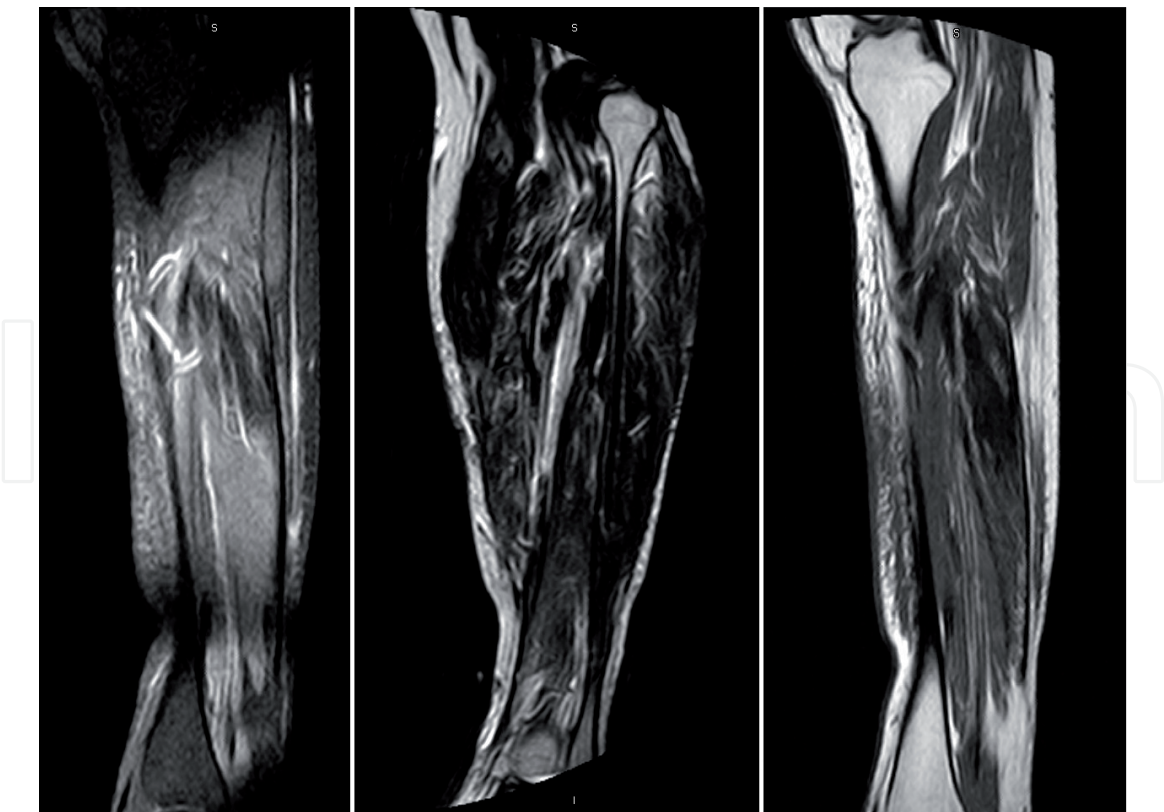


Figure 4. Magnetic resonance imaging showing sequelae of the compartment syndrome after 6 months: the presence of a certain degree of discrete muscular oedema in a trajectory of approximately 18 cm is observed, affecting the soleus muscles, with a chronic appearance. There is a certain degree of fat infiltration mainly in the proximal third of the muscle mass. Likewise, an apparent degree of scarring and / or fibrosis is also detected in the muscle. The fascia signal is preserved.

Complication	Percentage
Dry scaly skin	40%
Discolored wounds	30%
Tethered scars	26%
Muscle herniation	13%
Pruritus	33%
Swollen limbs	25%
Recurrent ulceration	13%
Tethered tendons	7%
Appearance of scars causing discomfort	23%
Chronic venous insufficiency	—

Table 3. Fasciotomy complications.

Although the majority of positioning injuries resolve in one month, they may persist beyond 6 months, and the patient may still be needing rehabilitation care. [31] Patient’s MRI (Magnetic Resonance Imaging) still shows signs of damage 6 months after the surgery, even in the case of being attending rehabilitation care (**Figure 4**).

In the long-term, reported complication rates of early and late fasciotomies are 4.5% and 54%, respectively (**Table 3**). Pain and altered sensation around the fasciotomy wound occur in 10% and 77%, respectively. [18]

Fasciotomy wounds can cause dry scaly skin in 40% of cases, discolored wounds in 30%, tethered scars in 26%, muscle herniation in 13%, pruritus in 33%, swollen limbs in 25%, recurrent ulceration in 13% and tethered tendons in 7%. Chronic venous insufficiency due to impaired calf muscle pumps may also occur. [21, 32] Appearance of the scars affects 23% of the patients. [17]

Well-leg compartment syndrome may lead to permanent disability and, therefore, has considerable medico-legal implications. This may apply to other rare and life-threatening syndromes during percutaneous nephrolithotomy, such as acute abdominal syndrome. [33]

9. Prevention

Strategies have been developed to prevent the occurrence of this complication, including limitation of the patients' position, optimal medical management of comorbidities before surgery, or even the use of checklists. [18]

In terms of positional preventive measures, the most important thing is to reserve the positioning in extreme Trendelenburg, lithotomy, Trendelenburg or supine Valdivia modified by Galdakao only for when it is necessary. [34] Wrapping of raised legs should be avoided. Intermittent compression is still controversial. It increases the risk of compartment syndrome of the leg, but significantly reduces the occurrence of deep vein thrombosis. Complete passive plantar flexion should be avoided. [17] The use of stirrups has theoretical disadvantages over the use of a split leg table. [18] Positioning the patient's calves just below the level of the right atrium may be beneficial, as it minimizes the degree of elevation of the ankle. [21, 30] It has been advised to remove leg from support every 2 hours for short periods if operating for more than 4 hours. [21]

Overweight patients should be advised to lose weight before the procedure. Other diseases, such as peripheral vascular disease or diabetes, must be optimized. [35] Use of checklists has been shown to help avoid complications by directing attention to risk factors associated with the operation. [18]

Regarding anesthetic issues, we must perform an epidural block with intensity appropriate to the potential pain of the patient. During surgery, the patient must be adequately hydrated, and we must maintain blood pressure in the standard range. [17]

Intraoperative measurement of serum creatine phosphokinase in patients with risk factors who undergo prolonged surgery during ventilation and sedation may be helpful in anticipating an early diagnosis of compartment syndrome of the leg. [21]

In addition, in these types of patients, intraoperative monitoring of compartment pressure could be an option. This monitoring can detect signs of compartment syndrome before the onset of clinical ones. Thus, it could reduce the treatment time for compartment syndrome (fasciotomy) and, therefore, the risk of subsequent complications. [32] If the patient exhibits small elevations, mannitol can be used to induce osmotic diuresis. Additionally, mannitol is as a free radical scavenger. In high risk patients or in prolonged surgeries, urinary pH monitoring allows us to avoid the precipitation of myoglobin and urates, through the infusion of acetazolamide or sodium bicarbonate. [17]

10. Conclusions

Well-leg compartment syndrome is a rare, but potentially devastating complication that may occur during urological surgeries performed in the lithotomy

position. It is also possible the development of a compartment syndrome during a percutaneous nephrolithotomy in the Galdakao-modified Supine Valdivia Position.

The factors associated with the development of this complication include: obesity, advanced age, hypertension, hyperlipidemia, diabetes mellitus, combined general-spinal anesthesia, prolonged surgery time and systemic hypotension.

In prolonged surgeries and in patients with risk factors, high levels of awareness of the possibility of this condition are advisable, leading possibly to early treatment. Definitive diagnosis is assessed by directly measuring compartmental pressure.

Early diagnosis and treatment by four compartment fasciotomy is the only way to prevent irreversible damage. Preventive measures reduce the incidence of this condition, which may lead to skin necrosis, permanent neuromuscular dysfunction, myoglobinuric renal failure, amputation and even death.

Conflict of interest

The authors declare no conflict of interest.

Author details

Inés Laso-García*, Fernando Arias-Fúnez, Gemma Duque-Ruiz, David Díaz-Pérez, Alberto Artiles-Medina and Javier Burgos-Revilla
Ramón y Cajal University Hospital, Alcalá University, IRYCIS, Madrid, Spain

*Address all correspondence to: ines.laso.garcia@gmail.com

IntechOpen

© 2021 The Author(s). Licensee IntechOpen. This chapter is distributed under the terms of the Creative Commons Attribution License (<http://creativecommons.org/licenses/by/3.0>), which permits unrestricted use, distribution, and reproduction in any medium, provided the original work is properly cited. 

References

- [1] Ljunghall S. Incidence of upper urinary tract stones. *Miner Electrolyte Metab* [Internet]. 1987 Jan [cited 2015 Jun 1];13(4):220-7. Available from: <http://www.ncbi.nlm.nih.gov/pubmed/3306313>
- [2] Johnson CM, Wilson DM, O'Fallon WM, Malek RS, Kurland LT. Renal stone epidemiology: a 25-year study in Rochester, Minnesota. *Kidney Int* [Internet]. 1979 Nov [cited 2016 Oct 25];16(5):624-31. Available from: <http://www.ncbi.nlm.nih.gov/pubmed/548606>
- [3] Boyce WH, Garvey FK, Strawcutter HE. Incidence of urinary calculi among patients in general hospitals, 1948 to 1952. *J Am Med Assoc* [Internet]. 1956 Aug 11 [cited 2016 Oct 25];161(15):1437-42. Available from: <http://www.ncbi.nlm.nih.gov/pubmed/13345602>
- [4] Scales CD, Smith AC, Hanley JM, Saigal CS, Urologic Diseases in America Project. Prevalence of Kidney Stones in the United States. *Eur Urol* [Internet]. 2012 Jul [cited 2017 Feb 25];62(1):160-5. Available from: <http://www.ncbi.nlm.nih.gov/pubmed/22498635>
- [5] Ramello A, Vitale C, Marangella M. Epidemiology of nephrolithiasis. *J Nephrol* [Internet]. 2000 [cited 2017 Mar 27];13 Suppl 3:S45-50. Available from: <http://www.ncbi.nlm.nih.gov/pubmed/11132032>
- [6] Decoster M, Bigot JC, Carre JL, Morin JF, Mahé JL, Tanquerel T, et al. [Epidemiologic study of urinary calculi in Western France]. *Presse Med* [Internet]. 2002 Jan 26 [cited 2016 Oct 25];31(3):113-8. Available from: <http://www.ncbi.nlm.nih.gov/pubmed/11859735>
- [7] Turney BW, Reynard JM, Noble JG, Keoghane SR. Trends in urological stone disease. *BJU Int* [Internet]. 2012 Apr [cited 2017 Feb 13];109(7):1082-7. Available from: <http://www.ncbi.nlm.nih.gov/pubmed/21883851>
- [8] Zhao F, Li J, Tang L, Li C. A comparative study of endoscopic combined intrarenal surgery (ECIRS) in the Galdakao-modified supine valdivia (GMSV) position and minimally invasive percutaneous nephrolithotomy for complex nephrolithiasis: a retrospective single-center study. *Urolithiasis* [Internet]. Springer; 2020 [cited 2021 Feb 1];Aug 10. Available from: <https://pubmed.ncbi.nlm.nih.gov/32776245/>
- [9] Melo PA de S, Vicentini FC, Perrella R, Murta CB, Claro JF de A. Comparative study of percutaneous nephrolithotomy performed in the traditional prone position and in three different supine positions. *Int Braz J Urol* [Internet]. Brazilian Society of Urology; 2019 Jan 1 [cited 2021 Feb 1];45(1):108-17. Available from: <https://pubmed.ncbi.nlm.nih.gov/30521168/>
- [10] Scoffone CM, Cracco CM. Invited review: the tale of ECIRS (Endoscopic Combined IntraRenal Surgery) in the Galdakao-modified supine Valdivia position [Internet]. *Urolithiasis*. Springer Verlag; 2018 [cited 2021 Jan 31]. p. 115-23. Available from: <https://pubmed.ncbi.nlm.nih.gov/29189885/>
- [11] Ibarluzea G, Scoffone CM, Cracco CM, Poggio M, Porpiglia F, Terrone C, et al. Supine Valdivia and modified lithotomy position for simultaneous anterograde and retrograde endourological access. *BJU Int* [Internet]. 2007 Jul [cited 2019 Oct 15];100(1):233-6. Available from: <http://doi.wiley.com/10.1111/j.1464-410X.2007.06960.x>
- [12] Cohen SA, Hurt WG. Compartment syndrome associated with lithotomy

position and intermittent compression stockings. *Obstet Gynecol.* 2001;97(5):832-3.

[13] Clarke D, Mullings S, Franklin S, Jones K. Well leg compartment syndrome. *Trauma Case Reports.* Elsevier Ltd; 2017 Oct 1;11:5-7.

[14] Pfeffer SD, Halliwill JR, Warner MA. Effects of lithotomy position and external compression on lower leg muscle compartment pressure. *Anesthesiology* [Internet]. 2001 Sep [cited 2019 Oct 15];95(3):632-6. Available from: <https://insights.ovid.com/crossref?an=00000542-200109000-00014>

[15] Gill M, Fligelstone L, Keating J, Jayne DG, Renton S, Shearman CP, et al. Avoiding, diagnosing and treating well leg compartment syndrome after pelvic surgery. *Br J Surg.* John Wiley and Sons Ltd; 2019 Aug 1;106(9):1156-66.

[16] Mattei A, Di Pierro GB, Rafeld V, Konrad C, Beutler J, Danuser H. Positioning Injury, Rhabdomyolysis, and Serum Creatine Kinase-Concentration Course in Patients Undergoing Robot-Assisted Radical Prostatectomy and Extended Pelvic Lymph Node Dissection. *J Endourol* [Internet]. 2013 Jan [cited 2019 Oct 15];27(1):45-51. Available from: <http://www.liebertpub.com/doi/10.1089/end.2012.0169>

[17] Mabvuure NT, Malahias M, Hindocha S, Khan W, Juma A. Acute Compartment Syndrome of the Limbs: Current Concepts and Management. *Open Orthop J* [Internet]. 2012 Nov 30 [cited 2019 Oct 15];6(1):535-43. Available from: <https://openorthopaedicsjournal.com/VOLUME/6/PAGE/535/>

[18] Mumtaz FH, Chew H, Gelister JS. Lower limb compartment syndrome associated with the lithotomy position: Concepts and perspectives for the urologist. *BJU Int.* 2002;90(8):792-9.

[19] Sukhu T, Krupski TL. Patient positioning and prevention of injuries in patients undergoing laparoscopic and robot-assisted urologic procedures. *Curr Urol Rep* [Internet]. 2014 Apr 27 [cited 2019 Oct 15];15(4):398. Available from: <http://link.springer.com/10.1007/s11934-014-0398-1>

[20] Chung JH, Ahn KR, Park JH, Kim CS, Kang KS, Yoo SH, et al. Lower leg compartment syndrome following prolonged orthopedic surgery in the lithotomy position -A case report-. *Korean J Anesthesiol* [Internet]. 2010 Dec [cited 2020 Apr 21];59 Suppl(SUPPL.):S49-52. Available from: <http://www.ncbi.nlm.nih.gov/pubmed/21286459>

[21] RAZA A, BYRNE D, TOWNELL N. Lower Limb (Well Leg) Compartment Syndrome After Urological Pelvic Surgery. *J Urol* [Internet]. 2004 Jan [cited 2019 Oct 15];171(1):5-11. Available from: <http://www.ncbi.nlm.nih.gov/pubmed/14665832>

[22] Simms MS, Terry TR. Well leg compartment syndrome after pelvic and perineal surgery in the lithotomy position. *Postgraduate Medical Journal.* 2005. p. 534-6.

[23] Wassenaar EB, van den Brand JGH, van der Werken C. Compartment syndrome of the lower leg after surgery in the modified lithotomy position: report of seven cases. *Dis Colon rectum* [Internet]. 2006 Sep [cited 2019 Oct 15];49(9):1449-53. Available from: <https://insights.ovid.com/crossref?an=00003453-200649090-00025>

[24] Chin KY, Hemington-Gorse SJ, Darcy CM. Bilateral well leg compartment syndrome associated with lithotomy (Lloyd Davies) position during gastrointestinal surgery: a case report and review of literature. *Eplasty* [Internet]. 2009 Oct 14 [cited 2020 Apr 21];9:e48. Available from: <http://www.ncbi.nlm.nih.gov/pubmed/19915657>

- [25] Yamamoto T, Fujie A, Tanikawa H, Funayama A, Fukuda K. Bilateral Well Leg Compartment Syndrome Localized in the Anterior and Lateral Compartments following Urologic Surgery in Lithotomy Position. *Case Rep Orthop* [Internet]. 2018 Nov 14 [cited 2019 Oct 15];2018:1-4. Available from: <http://www.ncbi.nlm.nih.gov/pubmed/30538877>
- [26] Tison C, Périgaud C, Vrignaud S, Capelli M, Lehur PA. Syndrome bilatéral des loges de jambe après chirurgie colorectale en position à double équipe. *Ann Chir*. 2002 Sep;127(7):535-8.
- [27] Rosevear HM, Lightfoot AJ, Zahs M, Waxman SW, Winfield HN. Lessons learned from a case of calf compartment syndrome after robot-assisted laparoscopic prostatectomy. *J Endourol* [Internet]. 2010 Oct [cited 2019 Oct 15];24(10):1597-601. Available from: <http://www.liebertpub.com/doi/10.1089/end.2009.0666>
- [28] Wollin DA, Preminger GM. Percutaneous nephrolithotomy: complications and how to deal with them. *Urolithiasis*. Springer Verlag; 2018. p. 87-97.
- [29] Tao J, Sheng L, Zhang H jie, Chen R, Sun Z quan, Qian W qing. Acute Abdominal Compartment Syndrome as a Complication of Percutaneous Nephrolithotomy: Two Cases Reports and Literature Review. *Urol Case Reports*. Elsevier Inc; 2016 Sep 1;8:12-4.
- [30] Mizuno J, Takahashi T. Male sex, height, weight, and body mass index can increase external pressure to calf region using knee-crutch-type leg holder system in lithotomy position. *Ther Clin Risk Manag* [Internet]. 2016 Feb [cited 2019 Oct 15];12:305. Available from: <http://www.ncbi.nlm.nih.gov/pubmed/26955278>
- [31] Romero FR, Pilati R, Kulysz D, Canali FA V, Baggio P V, Brenny Filho T. [Combined risk factors leading to well-leg compartment syndrome after laparoscopic radical prostatectomy]. *Actas Urol Esp* [Internet]. 2009 Sep [cited 2019 Oct 15];33(8):920-4. Available from: <http://www.ncbi.nlm.nih.gov/pubmed/19900389>
- [32] Mills JT, Burris MB, Warburton DJ, Conaway MR, Schenkman NS, Krupski TL. Positioning injuries associated with robotic assisted urological surgery. *J Urol*. 2013 Aug;190(2):580-4.
- [33] Donaldson J, Haddad B, Khan WS. The Pathophysiology, Diagnosis and Current Management of Acute Compartment Syndrome. *Open Orthop J*. Bentham Science Publishers Ltd.; 2014 Jul 17;8(1):185-93.
- [34] Googe B, Lackey AE, Arnold PA, Vick LR. The Modified Lithotomy: A Surgical Position for Lower Extremity Wound Care Procedures in Super Morbidly Obese Patients. A Case Study. *Wound Manag Prev* [Internet]. 2019 Jul [cited 2020 Apr 21];65(7):30-4. Available from: <http://www.ncbi.nlm.nih.gov/pubmed/31373561>
- [35] Takechi K, Kitamura S, Shimizu I, Yorozya T. Lower limb perfusion during robotic-assisted laparoscopic radical prostatectomy evaluated by near-infrared spectroscopy: an observational prospective study. *BMC Anesthesiol* [Internet]. BioMed Central Ltd.; 2018 Aug 18 [cited 2020 Apr 21];18(1):114. Available from: <http://www.ncbi.nlm.nih.gov/pubmed/30121089>