

# We are IntechOpen, the world's leading publisher of Open Access books Built by scientists, for scientists

6,900

Open access books available

185,000

International authors and editors

200M

Downloads

Our authors are among the

154

Countries delivered to

TOP 1%

most cited scientists

12.2%

Contributors from top 500 universities



WEB OF SCIENCE™

Selection of our books indexed in the Book Citation Index  
in Web of Science™ Core Collection (BKCI)

Interested in publishing with us?  
Contact [book.department@intechopen.com](mailto:book.department@intechopen.com)

Numbers displayed above are based on latest data collected.  
For more information visit [www.intechopen.com](http://www.intechopen.com)



# Ocular Toxoplasmosis: An Update on Diagnosis, Multimodal Imaging and Therapy

*Terese Kamal Gerges*

## Abstract

Ocular toxoplasmosis remains to be the most common cause of infectious uveitis in immunocompetent individuals with highly variable prognosis. The transmission mode can be either congenital or acquired. A precise diagnosis of the disease is necessary to opt effective and rapid treatment. While ocular toxoplasmosis usually presents in the classic form, it may as well present in variable clinical spectrum. The diagnosis can be suspected by the ocular inflammatory clinical presentation as well as multimodal imaging. However, serologic tests including intraocular fluid testing may be needed. Treatment includes combination of systemic antiparasitic and anti-inflammatory drugs with variable effectivity. More recently, intravitreally antimicrobials may be used. The chapter aims to layout the different clinical presentations and complications of ocular toxoplasmosis. Diagnostic techniques and different antimicrobial combinations for treatment will also be discussed.

**Keywords:** ocular toxoplasmosis, clinical presentation, diagnosis, treatment

## 1. Introduction

Approximately 25 to 30% of the world's human population is infected by toxoplasma [1]. Ocular toxoplasmosis is one of the most common cause of posterior uveitis caused by an intracellular parasite, toxoplasma gondii [2, 3].

1952, Helenor Campbell Wilder (later Helenor Campbell Wilder Foerster) confirmed the growing suspicion that toxoplasma gondii was a cause of uveitis in otherwise healthy adults by identifying the presence of both trophozoites and bradyzoites in enucleated eyes, that suffered severe intraocular inflammation [4].

Retinitis is the most common manifestation of ocular toxoplasmosis with vitritis. Factors that may influence visual prognosis include severity of the inflammation, size of the lesion and site of the inflammation. Also, progression to complications such as a neovascularization, vitreomacular traction, retinal detachment, glaucoma and cataract renders worse visual prognosis. Multimodal imaging can assist in meticulously evaluating and studying the extent of intraocular damage imposed by toxoplasma inflammation. Laboratory testing of intraocular fluid has been widely studied and employed, including PCR testing and detection of intraocular antibodies using Goldmann-Witmer coefficient (GWC), to enable more precise diagnosis. Ocular toxoplasmosis has a self-limiting nature, treatment can help rapid control of inflammation specially if the retinitis involves the posterior pole. Treatment includes different combinations of antimicrobials; none have can prevent

recurrences, but some combinations have shown more effective reduction in the size of the retinal lesion in comparison to other combinations or no treatment [5].

## **2. Life cycle and mode of transmission**

Toxoplasma exists in 3 infectious forms including sporozoites, which are contained within oocysts, tachyzoites and bradyzoites, which reside in tissue cysts. Oocysts are produced only in cat intestines and become infectious when defecated by cats. Tachyzoites are the fastest replicating form and responsible for systemic dissemination and active tissue infection in intermediate hosts. Tachyzoites can enter almost any type of host cell and multiply until the host cell is filled with parasites. Lysis of the host cell results in tachyzoite release followed by reentry into a new host cell. As a result of this cycle, multifocal tissue necrosis may occur. The host usually limits this phase of infection, then the parasite enters the dormant form, named bradyzoites, and gets isolated in tissue cysts. Cysts may contain hundreds of bradyzoites. These cysts usually cause no host reaction and may remain dormant throughout the life of the host [6].

The infection may be acquired or congenital by vertical transmission to the fetus. However, reports have supported the view that acquired infections might be a more important cause of ocular diseases than congenital [7–9].

Acquired infection occurs by consumption of raw meat containing cysts or ingestion of water or food contaminated by oocytes [9, 10]. Once the active parasite has invaded the body, it will spread via the blood stream, and due to a high affinity for cerebro- and retinovascular endothelial cells, can become established within the retina [10]. Following invasion of the parasite into the eye, the tachyzoite remains latent in the cyst under the control of the immune response of host [11–13]. In event of trigger of cyst rupture, the tachyzoite is converted to bradyzoite, and the inflammatory response is activated [5, 14].

## **3. Clinical presentation and phenotypes**

Congenital- transplacental transmission occurs in 40–70%, while acquired ocular involvement was reported in 1–21% [15]. However, each entity has significantly different clinical manifestation. A study conducted in southern Brazil reported lower prevalence of ocular toxoplasmosis in children below the age of 13 and 21.3% above the age of 13, concluding that ocular toxoplasmosis is a sequela of postnatal rather than congenital infection [7].

### **3.1 Congenital ocular toxoplasmosis**

Ocular lesions are the most frequent manifestations of congenital toxoplasmosis [16, 17]. Vertical transmission of toxoplasmosis occurs during primary infection in pregnant women, and generally the maternal disease goes unnoticed. When pregnant women become infected in the first trimester, the frequency of fetal infection goes up to 15–20%, in the second up to 25%, and in the third up to 65–70%. The most compromised fetuses are those who are infected earlier [1, 18, 19].

Besides retinochoroiditis, other ocular manifestations of congenital toxoplasmosis are described, such as microphthalmia, optic nerve atrophy, and abnormalities of the iris, cataract, and strabismus [17, 20–24].

However, typical presentation in the retina is an atrophic hyperpigmented scarred macular lesion that is described as ‘wagon-wheel’ lesion caused by

congenital toxoplasmosis. It shows a central area composed of glial and pigmented material connected by pigmented strands to a peripheral ring of pigment at the edge of the lesion **Figure 1**. A study designed to detect ocular involvement in infants with congenital toxoplasma reported that ocular involvement occurred in 70.4% of the cases, with mean age of active lesion at 1.4 months. Bilateral involvement occurred in 15.7% of the patients, mainly involving the papillomacular bundle in 76.3%. The retinochoroiditis lesions were active in 15.7% of the eyes and had healed in 84.3% [25].

It is worth mentioning that new lesions continue to appear well after the age of 5 years, likely with severe visual impairments. Therefore, screening of women for toxoplasmosis before pregnancy is advisable [26].

A significant reduction in prevalence and severity of the disease has been attributed to prenatal and neonatal treatment maintained throughout the first year of life [27–29].

### 3.2 Acquired toxoplasma

Acquired ocular toxoplasmosis commonly manifests in the second through fourth decades [10, 30]. Approximately 10% of otherwise healthy individuals who contract the infection report nonspecific symptoms, such as fatigue, fever and myalgias. Cervical lymphadenopathy [31].

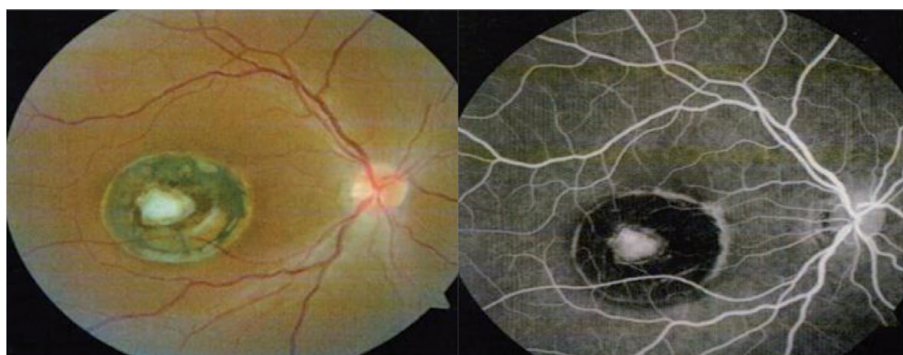Though floaters with altered vision may be the most common symptom of toxoplasma retinitis, however, clinical presentation ranges a wide spectrum.

Anterior uveitis is a common finding, with mutton-fat keratic precipitates, fibrin, cells and flare, iris nodules and posterior synechiae [32]. Raised intraocular pressure has been reported in (30%–38%) of the cases [33, 34].

#### 3.2.1 Typical *toxoplasma* retinitis

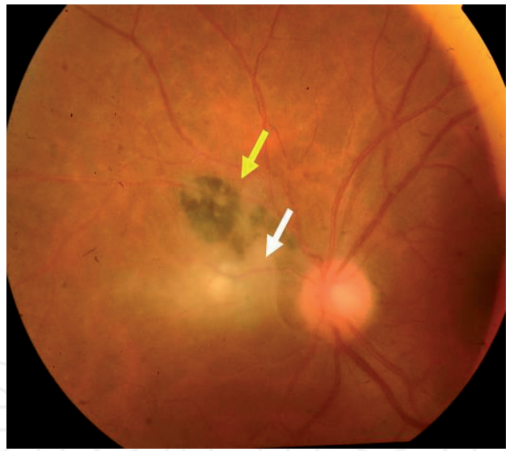
This usually manifests as active focal necrotizing retinitis, at the edge of an old, pigmented scar with overlying vitritis **Figure 2**. Bosch-Driessen et al. reported 72% of the patients had pre-existing retinochoroidal scars, indicating prior subclinical disease. The pigmented scar has been described to harbor the cysts that remain dormant until the cyst ruptures with release of organisms into the surrounding retina inducing adjacent retinitis [10].

Toxoplasma retinitis may occasionally manifest without an adjacent scar **Figure 3**. It is known that tissue cysts can exist in normal-appearing retina. The retina may be infected at the time of an initial systemic infection, but without clinically apparent lesions at the time [32].

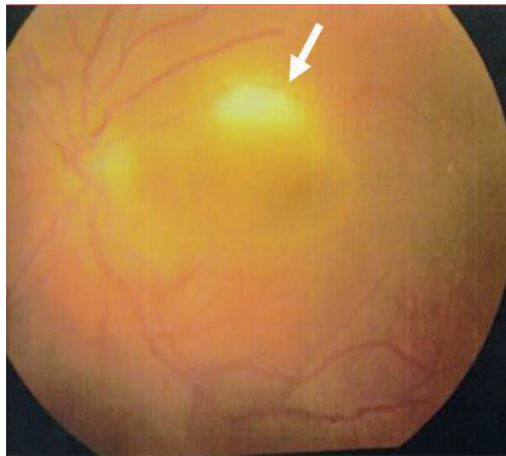


**Figure 1.**  
Colored image (left) and fundus fluorescein angiography (right) of atrophic pigmented congenital toxoplasma 'wagon wheel' macular scar.





**Figure 2.**  
*Colored image of a supranasal peripapillary pigmented scar (yellow arrow) with adjacent area of active retinitis (white arrow)*

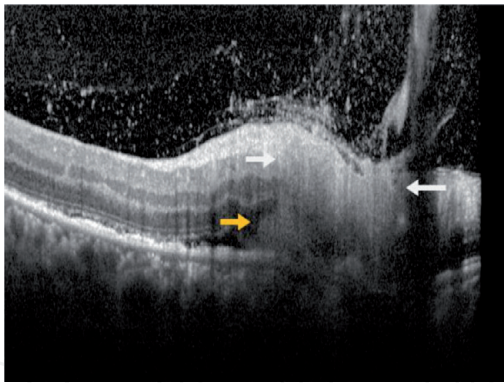


**Figure 3.**  
*Colored image of superior macular toxoplasma retinitis lesion (white arrow) without adjacent scar.*

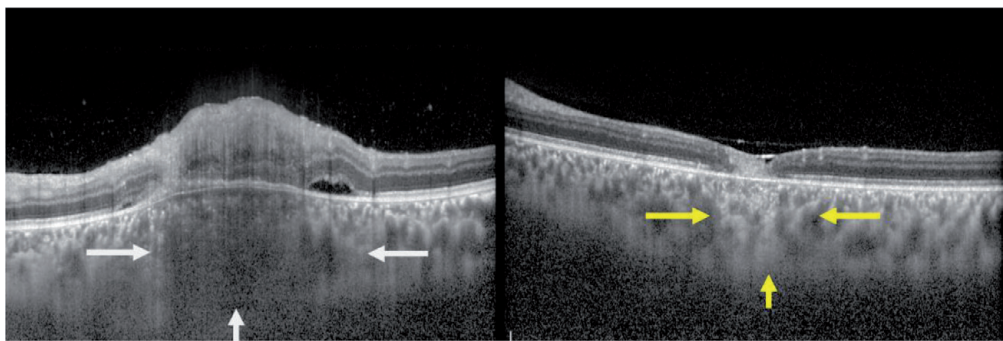
The focus of retinitis is of necrotizing nature and usually involves the full thickness of the retina, although occasional limited involvement of either inner or outer retina occurs, as described by Friedmann and Knox. Depending upon the thickness of involved retina, the overlying vitreous and underlying choroid are variably involved [30].

Large, full-thickness lesions tend to incite more severe vitritis, producing the classic ‘headlight in the fog’ sign. Optical coherence tomography (OCT) of active lesions can detect the level of retinal involvement, severity of choroiditis, as well as monitoring the regression of the lesion with treatment **Figures 4 and 5**. On regression of the retinitis, a pigmented scar that is smaller than the actual size of the retinitis forms.

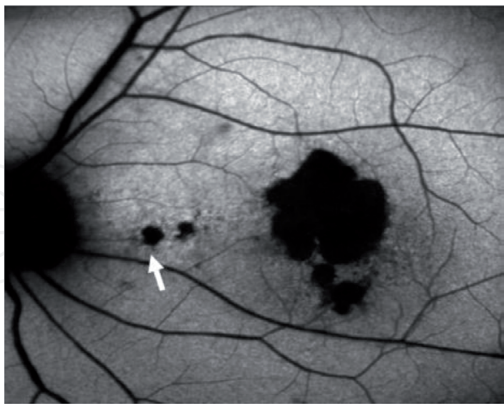
Punctate outer retinal toxoplasma (PORT) was first described in 1985 by Doft and Gass [35]. They elucidated the outer variation of punctate toxoplasmosis that primarily affects the outer retinal layers of the macular area. This entity usually presents in younger, immunocompetent patients [35, 36]. These can be either a single or several deep retinal infiltrates that may extend as far as the inner plexiform layer (IPL). The underlying retinal pigment epithelium is interrupted with variable involvements of the Bruch’s membrane and choroid. These lesions have been detected in the same eye with typical retinal toxoplasma lesions as in **Figures 6 and 7** or in eyes with no previous toxoplasma lesions [37]. PORT lesions resolve slowly, leaving an atrophic chorioretinal scar and frequently recur in adjacent areas of the macula [38].



**Figure 4.**  
*OCT line scan through full thickness retinitis seen between the two white arrows with complete loss of architecture of inner retinal layers, with a small deep retinal infiltrate (orange arrow) and adjacent mild subretinal fluid. Dense localized overlying vitreous infiltration overlying the area of retinitis.*



**Figure 5.**  
*OCT line scan through active toxoplasma retinitis seen between the white arrows in the photo on the left with underlying choroidal involvement exhibiting a hyporeflective elevated appearance. Healed lesion in the photo on the right between yellow arrows shows resolved retinitis with thinned retina, decreased thickness of the choroid with increased choroidal transmission.*

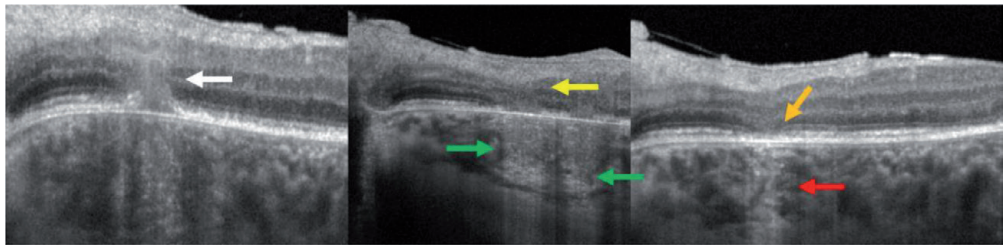


**Figure 6.**  
*Autofluorescence showing foveal hypofluorescent toxoplasma lesion with an active edge, and two nasal PORT lesions (white arrow).*

### 3.2.2 Retinal vascular involvement of ocular toxoplasmosis

Inflammatory vascular involvement in acute toxoplasma retinochoroiditis constitutes an invariable clinical sign of the disease and was reported in (100%) of cases in a previous study [39].

During the acute phase of toxoplasmic retinochoroiditis, perivasculitis with arterial involvement in the form of multiple small periarterial plaques, previously



**Figure 7.**  
**Left image:** OCT of one of the PORT lesions in the active stage (white arrow) showing inflammatory nodular infiltrate breaking through the RPE and extending to the inner plexiform layer corresponding to the nasal PORT lesions in the autofluorescent image in **Figure 6**, both pointed on by white arrows. The underlying choroid shows thickening and loss of normal architecture. **Middle image:** As the lesion heals the infiltrate decreases in size (yellow arrow) and the choroid appears less thickened with incomplete recovery of the normal choroidal vasculature (green arrow). **Right image:** Complete recovery of the lesion with complete disappearance of the nodular infiltrate, leaving thinned depressed inner retinal layers (orange arrow) with partial recovery of the RPE and increased choroidal transmission with recovered choroidal vasculature (red arrow).

described as Kyreilles plaques [40], may occur, whereas that of the vein may show scattered infiltration of the wall, sheathing, or both **Figure 8**. Obstruction of a branch of the central retinal artery and vein as well as choroidal vascular occlusion have also been reported to occur [41–45].

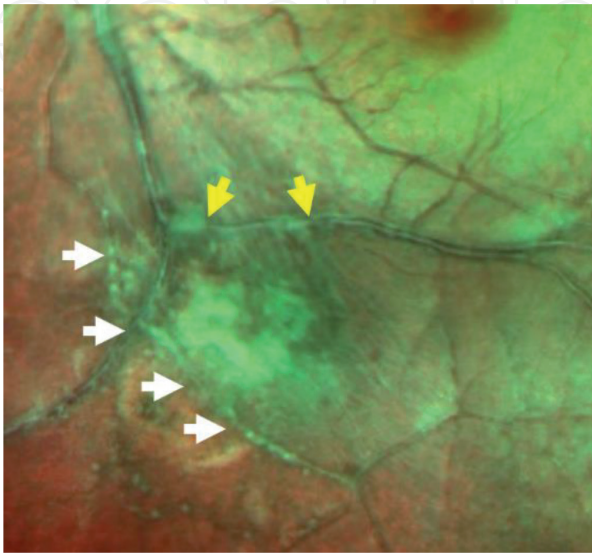
The pathogenesis of vasculitis, was previously explained to be, is secondary to a reaction between local antigens and circulating antibody, and the beads seen along the vessels represent cuffs of mononuclear cells [46, 47].

Inflammation of the retinal vessels can occur in close proximity to the area of retinitis. The intensity of the vascular involvement was reported to be more prominent where the vessel traverses the active lesion. Vasculitis may also present away from the actual focus of inflammation **Figure 9** and involve vessels in all four quadrants [39].

Occasionally, vascular occlusion may occur when thick focal retinitis engulfs the course of retinal vessels, leaving a permanent area of retinal ischemia [43] **Figure 10**. Retinal vascular occlusion has been reported to be 5% [39].

### 3.2.3 Optic nerve involvement in ocular toxoplasma

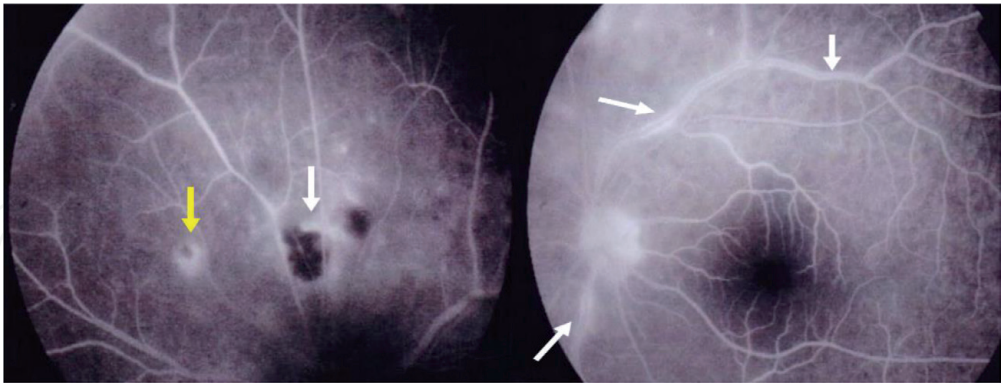
Optic nerve involvement may be due to parasitic invasion or reactive inflammation [48–51]. Eckert et al., reported optic nerve changes in 5% of the cases.



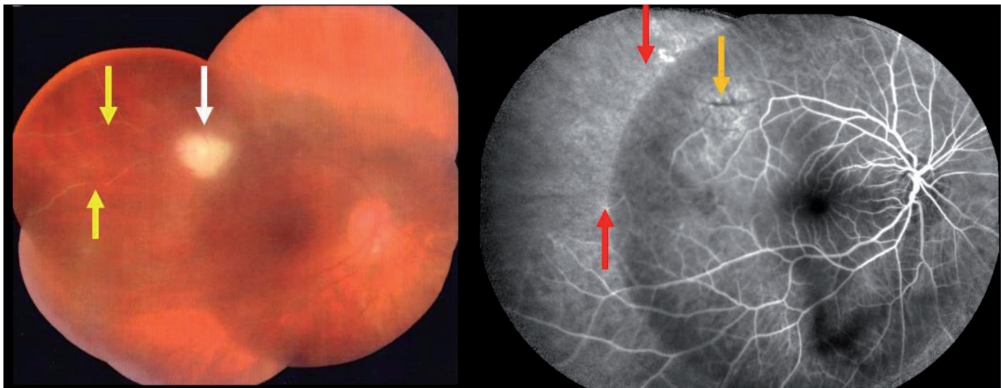
**Figure 8.**  
Small Kyreilles plaques along the retinal artery (white arrow) adjacent to patch of toxoplasma retinitis with perivenular infiltrates (yellow arrow).



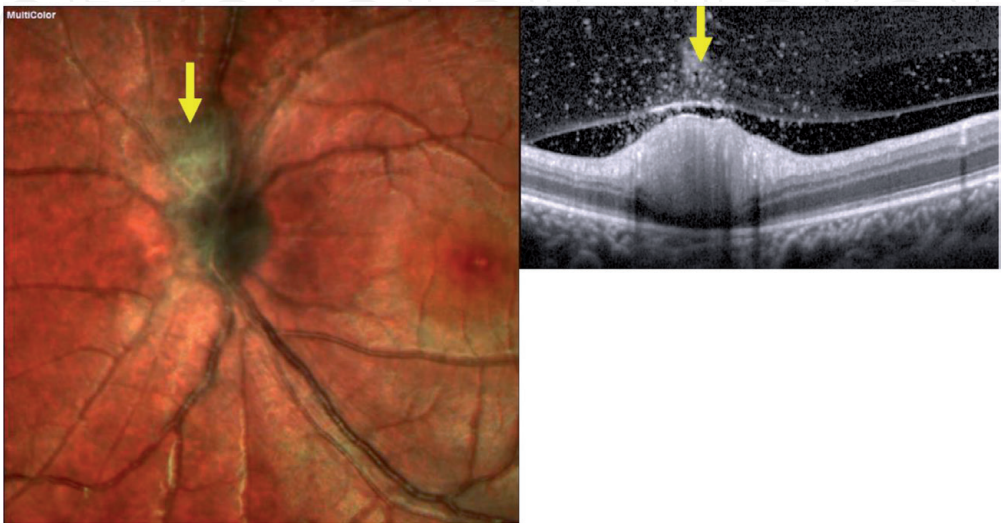In 35% of the cases, retinitis was juxtapapillary **Figure 11**. In pure papillitis, the parasite affects the optic disc directly, causing a swollen papilla with sheathing of the peripapillary veins and there may be no concurrent active retinochoroiditis



**Figure 9.**  
*Fundus fluorescein angiography (FFA) in the left image, exhibiting superior old hypofluorescent scar with adjacent active retinitis (white arrow) and supranasal active satellite lesion (yellow arrow). Perivenular leakage in the image on the right is evident supratemporally and infratemporally (white arrow) away from the actual foci of active retinitis.*



**Figure 10.**  
*Supratemporal thick toxoplasma retinitis along the supratemporal vessels (white arrow in the left side image) with occluded vessels distal to the lesion (yellow arrow). FFA performed after healing of the retinitis (right image), demonstrating an atrophic patch at previous site of retinitis (orange arrow) with occluded supratemporal vessels and a large area of retinal ischemia (red arrows).*



**Figure 11.**  
*Multicolored images (left side photo of superior peripapillary lesion (yellow arrow). OCT line scans through superior peripapillary lesion exhibiting almost full thickness retinitis with overlying localized dense vitritis (yellow arrow) in right side photo.*



lesion [50]. Optic nerve involvement may induce severe visual field defects as well as loss of color vision [6]. Neuroretinitis has also been described as a unique presentation of ocular toxoplasmosis [51, 52].

#### *3.2.4 Macular oedema in ocular toxoplasmosis*

Macular oedema has been reported in 12% of toxoplasma cases [10]. Subretinal fluid accumulation (SRF) of variable severity, adjacent to area of retinochoroiditis involving the macula, has been described **Figure 12**. This was explained by. Khairallah, as the disrupted outer blood retinal barrier, secondary to the adjacent inflammatory process. Ultimately the fluid regresses as the retinitis heals [53].

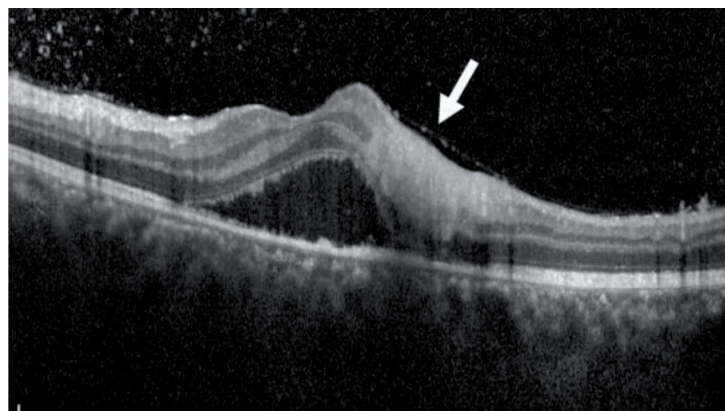
Cystoid macular oedema (CME) may occur in active ocular toxoplasmosis with different phenotypes. Ouyang et al. reported that 7.5% of the cases presented with CME, while 2.5% presented with a huge outer retinal cyst (HORC). Interestingly, the same study reported that 3.5% of the cases showed cystoid degeneration in the inner retina next to the retinal vessels without other any retinal/choroidal abnormality in the macula [54].

HORC was described to be intraretinal cyst with a membranous structure bordering the outer border of that cyst **Figure 13**. Ouyang et al., hypothesized that this structure represents the tissue between ELM and the inner boundary of the RPE (i.e., photoreceptor layer), which further suggests that the lesion represents an intraretinal rather than a subretinal fluid accumulation. With regression of the fluid, the membranous structure resumes its anatomical location in the macular layer architecture [55].

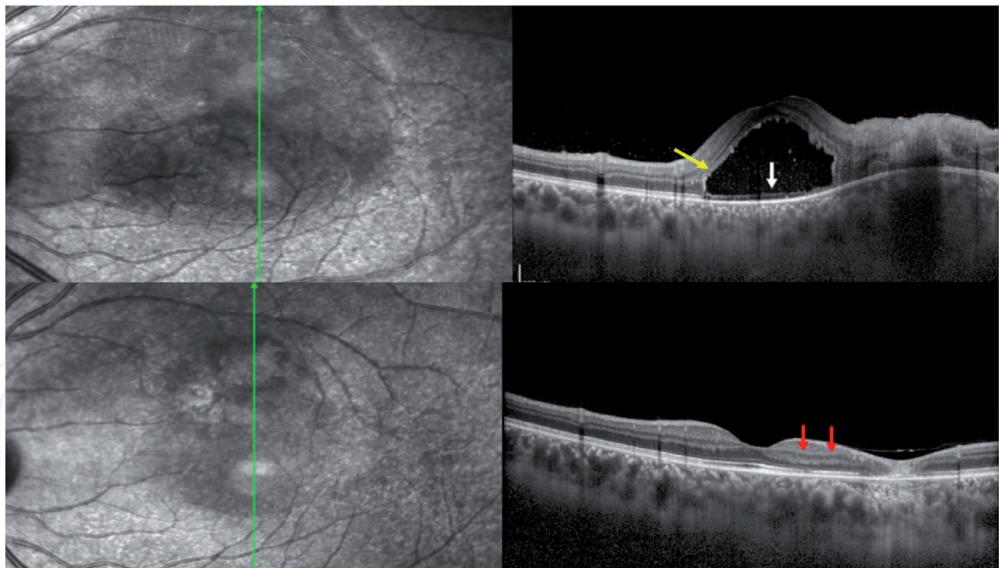
#### *3.2.5 Healing of toxoplasma retinocoroditis*

Toxoplasma lesions healing starts to be appreciated as the vitritis regresses and the toxoplasma lesion starts to show more defined borders, because cicatrization occurs from the periphery towards the center, with variable pigmentary hyperplasia [32].

OCT is a sensitivity tool that has been used to study toxoplasma lesions in the active and healed stage [55, 56]. In the acute stage, retinal necrosis is detected by OCT as hyporeflective disorganized thickening of the neurosensory retina. Underlying RPE clumping and disruption of the ELM and photoreceptors is seen. Choroidal inflammation may occasionally occur, and is detected by OCT appearing, hyporeflective thickening and, confined underneath area of retinitis. Overlying toxoplasma retinitis lesions, hyperreflective vitreous aggregates settling over inflamed retinal surface has also been reported [55].



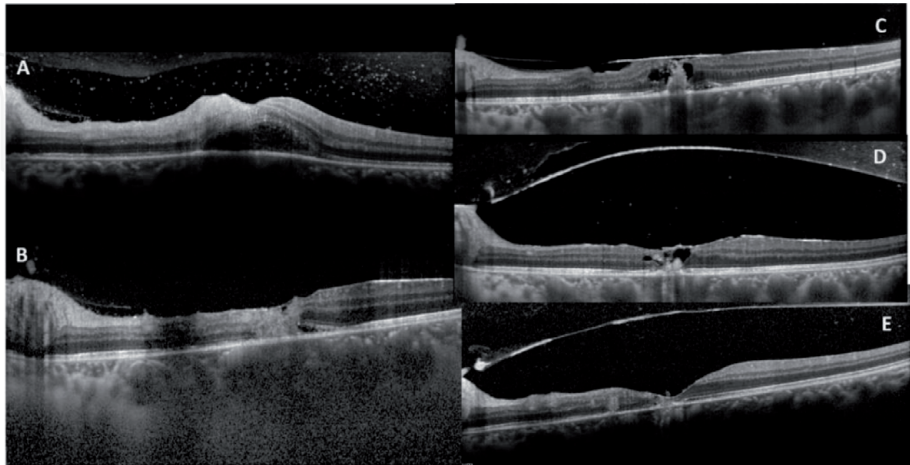
**Figure 12.**  
*Full thickness retinitis in OCT line scan indicated by the white arrow with adjacent foveal SRF.*



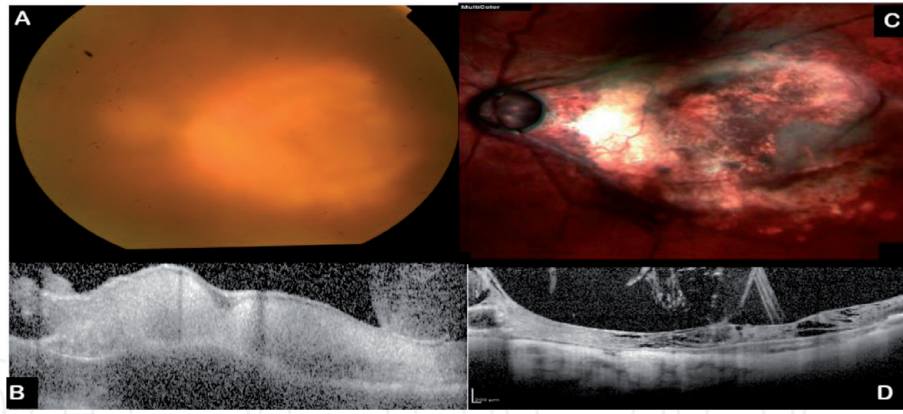
**Figure 13.**  
*Photo on the top: Superior parafoveal full thickness retinitis demonstrated by OCT line scan with adjacent large cystoid area within the outer plexiform layer (yellow arrow) and a thin membranous structure by the white arrow in the base of the cyst-. Photo in the bottom after resolution of the inflammation the cystoid space regresses, and the inner retinal layer resume the normal architecture (red arrow).*

As the retinitis starts to heal, the OCT scans show the hyperreflective area of retinitis, within the neurosensory retina starts to decrease in thickness with regressing of any adjacent SRF or CME. The RPE clumping starts to be more obvious and may show localized heaping which is likely the commencement of the pigmentary scar. As the hyperreflectivity of the retinitis recedes, degenerative cystoid spaces occasionally develop that resolves as healing reaches a final stage. The posterior hyaloid starts to get thicker, may exerts vitreomacular traction, which occasionally may spontaneously be released, with the separation of the posterior hyaloid from the macular surface **Figure 14**.

Occasionally, when retinitis is severe and recalcitrant to treatment, upon eventually evolving into the healing stage, the retinal layers exhibit severe,



**Figure 14.**  
*OCT scan through the fovea demonstrating toxoplasma necrotizing retinitis evolving from the active stage into an atrophic healed scar tissue. A: Full thickness retinitis. B: The retinitis has resolved remarkably with evolution of small deep residual area foveally with overlying appearance of the thick posterior hyaloid. C: Decreased size of the residual deep hyperreflective material with adjacent degenerative cystoid spaces and vitreofoveal tangential traction. D: As healing progresses, the posterior hyaloid detaches completely with release of the vitreofoveal traction. E: Complete resolution of the retinitis with atrophic appearance of the inner layers, resolved degenerative cyst and disrupted outer foveal layers.*



**Figure 15.** 55-year-old female patient with neglected toxoplasma retinitis *a* and *B*: Colored and OCT images respectively, exhibit large active retinitis involving all the macular area, with overlying dense vitritis. *C* and *D* multicolored and OCT images respectively, demonstrate photos after complete healing of the retinitis. *D* shows OCT image denoting complete disruption of the inner macular layers been replaced with laminated and split fibrosed tissue with focal area of traction parafoveally.

disorganization, thinning, with a fibrotic appearance, that may be laminated and splitted. Severe vitreomacular traction in such cases, can progress to retinal detachment **Figure 15**.

### 3.2.6 Ocular complications

Reported complications of ocular toxoplasmosis include isolated retinal tear (6%), retinal detachment, which is usually rhegmatogenous and/or tractional (6%), pre-retinal membrane (7%), choroidal neovascularization (<1%), vitreous hemorrhage (2%), optic atrophy (4%) and cataract (5%–13%) [10, 57].

### 3.2.7 Atypical toxoplasma retinitis in immunocompromised

Atypical manifestations include exceptionally large, multifocal, bilateral, diffuse retinal involvement or panophthalmitis. Elderly, AIDS, immunocompromised individual, or even rarely younger, immunocompetent patients as well [58] are likely to have specific defects in immune response that render them more at risk for atypical forms of toxoplasmosis [59]. This extensive toxoplasma retinitis presents similarly to necrotizing herpetic retinopathies, with large confluent full thickness areas of retinitis involving the peripheral retina and posterior pole. The thick, more densely yellow-white appearance of the lesion borders with a distinct, smooth contoured edge; and lack of hemorrhage, may distinguish these lesions from viral retinitis [60].

## 4. Recurrence and severity

### 4.1 Recurrence

Following an episode of toxoplasmic retinochoroiditis, the risk of recurrence is reportedly higher during the first year than during subsequent years: 29–32% of recurrences occur within 1 year, and 53–57% within 2 years [10, 32, 61].

Reasons for recurrences are not usually identified. They may arise from senescent changes in tissue cysts, with an accompanying release of parasites or antigens or as a result of trauma, hormonal fluctuations or even, transient immune responses of humoral or cellular nature [62]. Patients who are relatively



young at the first presentation are at increased risk of recurrence compared to older patients who have been independently confirmed [63]. A larger retinal parasite load in younger patients is one explanation that Holland et al. offered for this observation [64]. In AIDS patients, recurrence is the rule in the absence of long-term antiparasitic therapy [65].

Pregnancy and cataract surgery have both been associated with an increased risk of reactivation [62, 66]. Bosch-Driessen and associates [10], reported that 9% of women with ocular toxoplasmosis developed recurrences during pregnancy. It has been hypothesized that this relationship is attributable to hormonal or immunological changes that occur during pregnancy [67].

## 4.2 Severity

There is substantial variation in the severity of intraocular toxoplasma inflammation, attributable to multiple host- and disease-related factors.

Individuals less than 60 years showed significantly higher incidence of having lesions less than 1 disc area (DA) as compared to those above the age of 60, showing lesions more than 1DA in size with  $P = 0.02$ . The same study reported that larger lesions were associated with more severe vitreous humor inflammation [57]. Patients with AIDS develop extensive disease and frequently reactivate, if treatment is discontinued [68].

## 5. Diagnosis

Diagnosis of ocular toxoplasmosis starts at the point where the classic retinal manifestation is highly suggestive of the disease. However, in many instances the clinical findings cannot be sufficient to confirm a diagnosis, especially in the atypical form of presentation and thus laboratory investigations are necessary.

### 5.1 Serum serology

Ocular disease in the context of the presence of serum IgG and IgM antibodies against *Toxoplasma gondii* measured by screening tests such as the enzyme-linked immunosorbent assay (ELISA) or CLIA (Chemiluminescence immune assay) is compatible with acute or recent infection with toxoplasma supporting the diagnosis [69], yet can never be confirmatory, unless a definitive test like the dye test (Sabin-Feldman), IFAT (indirect fluorescent antibody test), immunoblot, and ISAGA (immunoglobulin-M immunosorbent agglutination assay) is performed. Nonetheless, these methods are performed only by specialized laboratories, they are complex and costly [70].

If retinitis develops within a year of an acquired systemic infection, anti-toxoplasma IgM should be detectable, but the variable rate of decline of this Ig isotype also limits the usefulness of such testing. The only exception is during pregnancy, when maternal IgM may herald acute infection of both the mother and foetus triggering urgent consultation with the obstetrician and neonatologist [71].

Since seropositivity is prevalent in most communities, the positive predictive value of IgG is low, and a positive IgG cannot be interpreted as indicative of active toxoplasmic infection. However, a rise in titer of specific IgG antibodies over a 3-week period has been used as an indicator of recent infection [72].

In immunosuppressed subjects, positive serological tests indicate infection, however, negative tests do not exclude previous or concurrent infections [73].

## **5.2 Goldman Witmer**

Levels of antibodies in aqueous humor and their relationship to serum antibodies may help in establishing the diagnosis of ocular toxoplasmosis [74, 75]. The Goldmann-Witmer coefficient (GWC) has been proposed as a valuable index of intraocular antibody production in active toxoplasmic retinochoroiditis in the immunocompetent subject [76].

(GWC) is calculated as the proportion of specific immunoglobulin (Ig)G in ocular fluid versus serum samples. It is determined as follows (anti-Toxoplasma IgG in aqueous humor/total IgG in aqueous humor)/(anti-Toxoplasma IgG in serum/total IgG in serum). Although a ratio over one should indicate intraocular antibody production, this also occurs in healthy controls, and therefore a ratio of at least three is often preferred for certain diagnosis [77].

## **5.3 Polymerase chain reaction**

The polymerase chain reaction (PCR) is an in-vitro method for exponentially replicating nucleic acids. PCR allows the detection and analysis of infinitesimal quantities of DNA. PCR of intraocular fluid has been extensively used to diagnosis infectious uveitis [78].

PCR testing of ocular sample can be useful in presumed toxoplasmosis in patients older than 50, in cases with inflammation (Tyndall  $\geq 1/2+$ , panuveitis), area of retinochoroiditis  $> 3$  DA, and when ocular sampling performed within 1 week of presentation after onset of symptoms and up to 4 months [79, 80].

GWC testing is of better sensitivity than real time PCR, and is the preferred diagnostic procedure in ocular toxoplasmosis, especially if the testing is carried out in younger patients with quiet eyes and with smaller sized chorioretinal lesions [79].

Real time PCR confirmed the clinical diagnosis of toxoplasmosis in 62.5% of the cases, while the GWC confirmed in 87.5% [79]. Other studies reported that for 25 patients who suffered from ocular toxoplasmosis, the GWC was positive in 90%, while PCR testing was positive in just 36% [80]. Also, Labalette et al., noted the aqueous PCR was positive in 60% when lesions were larger than three-disc areas, but in only 25% when lesions were smaller. Overall, GWC was more likely positive than PCR (i.e., 89% vs. 44%) in this group [81]. Also, the rates of positive PCR are high in aqueous humor, obtained from HIV-infected or elderly subjects presenting toxoplasma retinitis [82].

## **6. Management**

No drug has been proven to cure infection [5], therefore, the aim of antibiotic treatment is to reduce the duration and severity of symptoms of acute intraocular inflammation, the risk of permanent visual impairment (by reducing the size of the eventual retinochoroidal scar), and the risk of recurrent episodes [83].

### **6.1 Indication for treatment**

In immunocompetent individuals, toxoplasma retinochoroiditis typically resolves over a period of 1 to 2 months [84].

Previous reports indicated that toxoplasma treatment was employed if dense vitritis developed, retinitis is located close to the optic nerve, papillomacular area, or close proximity of lesions to major retinal vessels or if decreased vision occurs [5]. However, Holland reported the results of a survey from 1991 to 2001, where

members of the AUS showed a shift in management over 10 years, were in favor of treatment of both mild and severe disease [85].

Treatment of active ocular toxoplasmosis in immunocompromised individuals regardless of the severity is the recommended practice with less debate [85].

## 6.2 Medical treatment

### 6.2.1 Systemic treatment

Several antimicrobial drug combinations are used to treat ocular toxoplasmosis.

#### 6.2.1.1 Antiparasitic

Classic therapy is a combination of pyrimethamine 25 mg–50 mg daily orally with folinic acid 5 mg every other day and sulfadiazine 1 g four times daily orally with systemic corticosteroid [84]. Pyrimethamine side effects include gastrointestinal and dermatological manifestations as well as hematological adverse events, including leukopenia and thrombocytopenia, that mandate monitoring of the blood picture regularly throughout the treatment course. 26% of the patients on this regimen were reported to discontinue treatment due to complications from the drugs [5].

The alternate treatment regimen is trimethoprim-sulfamethoxazole 160 mg–800 mg twice daily orally with systemic corticosteroid, which is a well-tolerated combination although sulfonamide-related reactions may occur. The common side effects include mild gastrointestinal symptoms and mild maculopapular rash. However, this regimen is relatively well tolerated with side effects requiring discontinuation in 4% of patients [5].

Both pyrimethamine and sulfadiazine, as well as trimethoprim-sulfamethoxazole, have a similar mechanism of action, inhibiting tetrahydrofolate synthesis, thereby impacting nucleic acid synthesis of *Toxoplasma gondii*. No reported difference in treatment results was reported when the classic or alternate treatment was used, however, treatment with classic therapy showed a greater reduction in the size of the retinal lesion than patients receiving other treatments or no treatment [5]. Other reports comparing these two regimens showed different results and concluded that drug efficacies in terms of reduction in retinal lesion size and improvement in visual acuity were similar. Reduction in the size of the lesion was comparable between the two treatment groups been 59% for trimethoprim-sulfamethoxazole and 61% for classic therapy, and there was no significant difference in post-treatment visual acuity. Therefore, trimethoprim/sulfamethoxazole seems to be an acceptable alternative for the treatment of ocular toxoplasmosis [86, 87].

Clindamycin 300 mg orally four times daily [84], is often added to triple therapy, which is then referred to as ‘quadruple therapy’. Animal studies showed that clindamycin reduced numbers of tissue cysts [86]. However, experience has shown that it does not prevent recurrent disease in human beings [88]. Pseudomembranous colitis is a well-recognized potential complication of clindamycin, as well as diarrhea. Clindamycin continues to be the most popular supplemental agent for treatment of patients with severe or persistent disease.

Opremkak and associates reported a series of 16 patients who were treated for toxoplasmic retinochoroiditis with trimethoprim (160 mg)/sulfamethoxazole (800 mg). Four were treated with trimethoprim/sulfamethoxazole alone, four were treated with trimethoprim/sulfamethoxazole and clindamycin, and eight were treated with trimethoprim/sulfamethoxazole, clindamycin and oral prednisone. They concluded that trimethoprim/sulfamethoxazole accelerated the rate of



resolution of toxoplasmic retinochoroiditis and improved the visual outcomes of their patients, although the study was uncontrolled [89].

Atovaquone 750 mg three/four times daily orally or azithromycin 250 mg daily orally are two antiparasitic agents used for treatment of toxoplasma. However, these agents do not appear to prevent recurrent toxoplasmic retinochoroiditis in the human host convincing activity against encysted parasites in experiment systems [90, 91]. Atovaquone was well tolerated but reactivation was reported by Winterhalter et al., in 44% of the cases within an interval averaging 39 months. [92]. Azithromycin in treatment of ocular toxoplasmosis has shown regression of the retinitis within 1 month in 64% of the patients, however, 27% experienced recurrence within the first year of follow-up, thus debating the effectiveness in decreasing recurrences [91]. The effective potency of this drug with no reported side effects that needed stopping the drug while used in treatment of ocular toxoplasma has been reported [92].

#### *6.2.1.2 Oral steroids*

Recent research suggests that there is widespread variation for use of steroids in clinical practice for treating ocular toxoplasmosis. In a cross-sectional survey of uveitis specialists, 17% used oral corticosteroids in the treatment of ocular toxoplasmosis in immunocompetent patients, regardless of clinical findings. The other clinicians used corticosteroids for specific indications, such as severe vitreous inflammatory reaction (71%), decreased vision (59%), proximity of the lesions to the fovea or optic disc (35%), and for large lesions (5%) [93].

Oral corticosteroids are used during the active phase to reduce the retinal inflammation and thus further collateral tissue damage and also to prevent blood-retinal barrier breakdown. Furthermore, it can also reduce toxoplasma scarring. Steroids are usually started from 1 to 3 days after starting antiparasitic agent and continued for approximately 1 month. Indications for stopping therapy earlier include substantial improvement in the lesion appearance (“hardening” of lesion margins), substantial reduction of inflammatory reactions, marked improvement in vision, and adverse drug effects. Occasionally, antiparasitic agents are continued at least 2 days after stopping corticosteroids [84]. Oral corticosteroids are not used in immunocompromised individuals to treat ocular toxoplasma, thereby reducing the risk of further suppression of host defenses. Clinical series have shown that the signs of ocular toxoplasmosis, including inflammatory signs, can respond rapidly to antiparasitic therapy alone in immunocompromised patients [68, 94, 95].

#### *6.2.2 Prophylactic treatment*

Trimethoprim and sulfamethoxazole may be used in the prevention of recurrent attacks of ocular toxoplasmosis. Silveira et al. found that trimethoprim-sulfamethoxazole (160 mg–800 mg), taken orally every 3 days for 20 months, significantly reduced the risk of recurrent toxoplasmic retinochoroiditis from 23.8% in untreated control subjects to 6.6% [96].

The investigators suggested a role for such preventive treatment in patients with a history of frequent and severe recurrences or with toxoplasmic scars adjacent to the fovea where any reactivation can result in profound vision loss.

The rationale behind prophylactic treatment is the fact that recurrence rates decrease with duration of infection, even without treatment. If the frequency of recurrences decreases over time, it may be useful immediately after acquired infections to suppress recurrences during the period of greatest risk [96].

Recurrences of toxoplasmic retinochoroiditis may occur following LASIK and phacoemulsification with posterior chamber intraocular lens implantation [64, 97]. It is therefore recommended that prophylactic treatment be given to patients 2 days prior to surgery and to be continued for a period of 1 week.

### *6.2.3 Intravitreal treatment*

Intravitreal clindamycin (1 mg) and dexamethasone (400 µg) have been used, injections can be repeated at 2-week intervals, based on a 5.6-day half-life of intravitreal clindamycin.

Soheilian et al. reported the results of treating patients with ocular toxoplasmosis involving or threatening macula or optic nerve, or adjacent to a large vessel and/or associated with severe vitritis with intravitreal treatment versus oral treatment using pyrimethamine and sulfadiazine plus prednisolone [98].

The mean number of injections in the intravitreal clindamycin was 1.6. Mean reduction in lesion size, increase in visual acuity and decrease in vitreous inflammation were not significantly different between groups, however, significantly reduction in size of lesions in IgM-positive patients who received classic treatment versus those who received intravitreal treatment was reported. This can be explained by the fact that a patient with acquired toxoplasmosis confronts a systemic infection that is treated better with systemic therapy.

The authors stressed that intravitreal clindamycin is a better alternative for pregnant and pediatric patients. Furthermore, the results of this study cannot be generalized to immunocompromised patients, monocular cases, and eyes with lesions inside the fovea (500 µm). However, acquired toxoplasmosis confront systemic infection and, therefore, may benefit from systemic therapy as well, rather than just intravitreal injections [99].

### *6.2.4 Treatment of ocular toxoplasmosis during pregnancy*

Bosch-Driessen and associates, reported that seven (9%) of 82 women with ocular toxoplasmosis developed recurrences during pregnancy [10]. Some reported, recurrent toxoplasma retinochoroiditis in a pregnant woman poses minimal risk to the fetus, and treatment is not indicated for the sole purpose of preventing vertical transmission [100]. However, other studies stressed that infection by toxoplasma will need treatment using spiramycin 1 g orally every 8 hours if a seronegative pregnant patient gets infected up to 18 weeks into the pregnancy or within the 6 months prior to pregnancy [71]. Intravitreal clindamycin can be a reasonable choice of treatment in pregnant mothers.

## **6.3 Surgical management**

Vitreoretinal surgery may be indicated in cases of persistent vitreous opacities, tractional or rhegmatogenous retinal detachment. In the setting of severe refractory vitritis precluding fundus examination, pars plana vitrectomy may be used for both diagnostic and therapeutic purposes [85].

Retinal detachment was reported in 11.4% of the cases. 75% underwent pars plana vitrectomy and 25% underwent laser retinopexy. 50% presented with recurrent RD requiring scleral buckle. At final follow-up, all patients who underwent surgical repair had attached retinas; with severe vision loss of 20/200 or worse [101].

Cataract surgery with intraocular lens implantation is often indicated in cases of significant lens opacification, after resolution of inflammation.

## 7. Conclusion

Ocular toxoplasmosis presents in a myriad of manifestations in the eye with variable complications and can be vision depleting. Multimodal imaging is useful in carefully monitoring treatment response, detecting, regression or progression of toxoplasma lesions and also show complications such as vitreomacular traction, CNVs or even subtle SRF, that cannot be clinically detected early. Molecular biological advances have improved the ability for diagnosis. Though current treatment modalities are effective in healing active disease yet does not effectively prevent recurrence. Further studies could be dedicated to developing antimicrobials that can help eradicate the disease.

## Acknowledgements

Al Watany Eye Hospital Cairo Egypt, the hospital I have worked at and learnt a lot over the years. The hospital is very supportive of research work and all the images included in this chapter were either captured in the hospital or were in the patient's electronic medical record. Retinal imaging team WEH dedicated hard work.

## Conflict of interest

I have no financial disclosures or conflict of interest.

## Thanks


'Special thanks to my dear Mother **Laila**, who has been my supportive backbone and has been ever encouraging, all the way through.'

## Author details

Terese Kamal Gerges  
Al Watany Eye Hospital, Cairo, Egypt

\*Address all correspondence to: [teresekamal@yahoo.com](mailto:teresekamal@yahoo.com)

## IntechOpen

© 2021 The Author(s). Licensee IntechOpen. This chapter is distributed under the terms of the Creative Commons Attribution License (<http://creativecommons.org/licenses/by/3.0>), which permits unrestricted use, distribution, and reproduction in any medium, provided the original work is properly cited. 



## References

- [1] Montoya J, Liesenfeld O. Toxoplasmosis. *Lancet*. 2004; 363:1965-1976.
- [2] Holland GN. Ocular toxoplasmosis: a global reassessment: Part I: epidemiology and course of disease. *Am J Ophthalmol* 2003; 136:973-988.
- [3] Rothova A. Ocular manifestations of toxoplasmosis. *Curr Opin Ophthalmol*.2003;14:384-8.
- [4] Wilder HC. Toxoplasma chorioretinitis in adults. *Arch Ophthalmol* 1952;48: 127-36.
- [5] Rothova A, Meenken C, Buitenhuis HJ, et al. Therapy for ocular toxoplasmosis. *Am J Ophthalmol*.1993; 115:517-23. [PubMed: 8470726]
- [6] Ozgonul C and. Besirli C G. : Recent Developments in the Diagnosis and Treatment of Ocular Toxoplasmosis; *Ophthalmic Res* 2017;57:1-12
- [7] Glasner PD, Silveira C, Kruszon-Moran D, Martins MC, Júnior MB, Silveira S, Camargo ME, Nussenblatt RB, Kaslow RA, Júnior RB. An unusually high prevalence of ocular toxoplasmosis in southern Brazil. *Am J Ophthalmol* 1992; 114: 136-144.
- [8] Holland GN. Ocular toxoplasmosis: new directions for clinical investigation. *Ocul Immunol Inflamm* 2000; 8: 1-7.
- [9] Atmaca LS, Simsek T, Batioglu F. Clinical features and prognosis in ocular toxoplasmosis. *Jpn J Ophthalmol* 2003; 48: 386-391.
- [10] Bosch-Driessen LE, Berendschot TT, Ongkosuwito JV, Rothova A. Ocular toxoplasmosis: clinical features and prognosis of 154 patients. *Ophthalmology*. 2002; 109:869-78.
- [11] Jones JL, Kruszon-Moran D, Wilson M, McQuillan G, Navin T, McAuley JB. Toxoplasma gondii infection in the United States: seroprevalence and risk factors. *Am J Epidemiol*. 2001; 154:357-65.
- [12] Moorthy RS, Smith RE, Rao NA. Progressive ocular toxoplasmosis in patients with acquired immunodeficiency syndrome. *Am J Ophthalmol* 1993; 115:742-7
- [13] Chen KC, Jung JJ, Engelbert M. Single acquisition of the vitreous, retina and choroid with swept-source optical coherence tomography in acute toxoplasmosis. *Retin Cases Brief Rep*. 2016; 10:217-20.
- [14] Rothova A. Ocular involvement in toxoplasmosis. *Br J Ophthalmol*. 1993; 77:371.
- [15] Akstein RB, Wilson LA, Teutsch SM. Acquired toxoplasmosis. *Ophthalmology* 1982; 89:1299-302.
- [16] Mets MB, Holfels E, Boyer KM, Swisher CN, Roizen N, Stein M et al. Ey3 manifestations of congenital toxoplasmosis. *Am J Ophthalmol* 1996;122: 309-324.
- [17] Meenken C, Assies J, van Nieuwenhuizen O, Holwerda-van der Maat WG, van Schooneveld MJ, Delleman WJ et al. Long-term ocular and neurological involvement in severe congenital toxoplasmosis. *Br J Ophthalmol* 1995; 79: 581-584.
- [18] Dunn D, Wallon M, Peyron F, Petersen E, Peckham C, Gilbert R. Mother-to-child transmission of toxoplasmosis: risk estimates for clinical counseling. *Lancet* 1999; 353: 1829-1833.
- [19] Gilbert RE. Toxoplasmosis. In: Newel ML, McIntyre J (eds). *Congenital and Perinatal Infections*. Cambridge University Press: Cambridge, 2000, p 305.

- [20] Peyron F, Wallon M, Bernardoux C. Long-term follow-up of patients with congenital ocular toxoplasmosis. *N Engl J Med* 1996; 334: 993-994.
- [21] Orefice F, Pinheiro SRA, Ferreira CD. Calcificações no planocoroide –retina de pacientes com lesões cicatrizadas de toxoplasmose congênita diagnosticadas pela tomografia computadorizada. *Rev Bras Oftalmol* 1989; 48: 49-53.
- [22] Bahia MD, Orefice F, Andrade CMQ. Análise clínica das lesões de retinocoroidite em crianças portadoras de toxoplasmose congênita. *Rev Bras Oftalmol* 1992; 51: 265-271.
- [23] Vutova K, Peicheva Z, Popova A, Markova V, Mincheva N, Todorov T. Congenital toxoplasmosis: eye manifestations in infants and children. *Ann Trop Paediatr* 2002; 22: 213-218.
- [24] Kodjikian L, Wallon M, Fleury J, Denis P, Binquet C, Peyron F et al. Ocular manifestations in congenital toxoplasmosis. *Graefes Arch Clin Exp Ophthalmol* 2006; 244: 14-21
- [25] Melamed J, Eckert GU, Spadoni VS, Lago EG and Uberti F: Ocular manifestations of congenital toxoplasmosis: *Eye* 2010;24, 528-534
- [26] Koppe JG, Loewer Sieger DH, de Roever Bonnet H. Results of 20-year follow-up of congenital toxoplasmosis. *Lancet* 1986; 1: 254-255.
- [27] McAuley J, Boyer KM, Patel D, Mets M, Swisher C, Roizen N et al. Early and longitudinal evaluations of treated infants and children and untreated historical patients with congenital toxoplasmosis: the Chicago collaborative treatment trial. *Clin Infect Dis* 1994; 18: 38-72.
- [28] Brezin AP, Thulliez P, Couvreur J, Nobre R, McLeod R, Mets MB. Ophthalmic outcomes after prenatal and postnatal treatment of congenital toxoplasmosis. *Am J Ophthalmol* 2003; 135: 779-784.
- [29] McLeod R, Boyer K, Karrison T, Kasza K, Swisher C, Roizen N et al. Outcome of treatment for congenital toxoplasmosis, 1981-2004: The National Collaborative Chicago-based, Congenital Toxoplasmosis Study. *Clin Infect Dis* 2006; 42: 1383-1394.
- [30] Friedmann CT, Knox DL. Variations in recurrent active toxoplasmic retinochoroiditis. *Arch Ophthalmol*. 1969; 81:481-93. [PubMed: 5777756]
- [31] Montoya JG, Liesenfeld O. Toxoplasmosis. *Lancet*. 2004; 363:1965-76. [PubMed: 15194258]
- [32] Bonfioli AA, Orefice F. Toxoplasmosis. *Seminars in ophthalmology* 2005; 20: 129-141.
- [33] Westfall AC, Lauer AK, Suhler EB, Rosenbaum JT. Toxoplasmosis retinochoroiditis and elevated intraocular pressure: a retrospective study. *J Glaucoma*. 2005; 14:3-10
- [34] Holland GN, Muccioli C, Silveira C, Weisz JM, Belfort R Junior and O'Connor GR. Intraocular Inflammatory Reactions Without Focal Necrotizing Retinochoroiditis in Patients with Acquired Systemic Toxoplasmosis. *Am J Ophthalmol*. 1999; 128:413-420. PMID: 10577581
- [35] Doft BH, Gass JDM. Punctate outer retinal toxoplasmosis. *Arch Ophthalmol*. 1985;103(9): 1332-1336.
- [36] Doft BH, Gass JD. Outer retinal layer toxoplasmosis. *Graefes Arch Clin Exp Ophthalmol*. 1986; 224:78-82. [PubMed: 3943742]
- [37] Fujiwara T, Machida S, Hasegawa Y and Tazawa Y. Punctate outer retinal toxoplasmosis with multiple choroidal neovascularization. *Journal of Retina*

and Vitreous Disease 2006; 29: (3); 360-362.

[38] Eduardo Cunha de Souza, MD; Antonio M. B. Casella, MD. Clinical and Tomographic Features of Macular Punctate Outer Retinal Toxoplasmosis Arch Ophthalmol. 2009;127(10):1390-1394.

[39] Theodossiadis P, Kokolakis S, Ladas I, Kollia AC, Chatzoulis D, Theodossiadis G. Retinal vascular involvement in acute toxoplasmic retinochoroiditis. Int Ophthalmol. 1995; 19:19-24. [PubMed: 8537191]

[40] Kyrieleis W. Ueber atypische gefaessstuberkulose der netzhaut (Periarteritis 'nodosa' tuberculosa). Arch Augenheilkd 1933; 107: 182-90

[41] Gass JDM. Stereoscopic Atlas of macular disease: diagnosis and treatment. St Louis, CV Mosby Co, pp 464-466, 1987.

[42] Pakalin S, Arnaud B. Arterial occlusion associated with toxoplasmic chorioretinitis. J Fr Ophthalmol 1990; 13 (11-12): 554-6

[43] Braunstein RA, Gass JDM. Branch artery obstruction caused by acute toxoplasmosis. Arch Ophthalmol 1980; 98: 512-3.

[44] Morgan CM, Gragoudas E. Branch ~ retinal artery occlusion associated with recurrent toxoplasmic retinochoroiditis. Arch Ophthalmol 1987; 105: 130.

[45] Williamson TH, Meyer PA. Br J Ophthalmol (letter) 1991;75: 253.

[46] O'Connor GR. The influence of hypersensitivity on the pathogenesis of ocular toxoplasmosis. Trans Am Ophthalmol Soc 1970; 68: 501-47.

[47] O'Connor GR. Ocular toxoplasmosis. Jpn J Ophthalmol 1975; 19: 1-24.

[48] Borruat FX, Kapoor R, Sanders MD. Simultaneous retinal and optic nerve lesions in toxoplasmosis: the advantages of magnetic resonance imaging. Br J Ophthalmol. 1993; 77:450-2. [PubMed: 8343477]

[49] Song A, Scott IU, Davis JL, Lam BL. Atypical anterior optic neuropathy caused by toxoplasmosis. Am J Ophthalmol. 2002; 133:162-4. [PubMed: 11755864]

[50] Eckert GU, Melamed J, Menegaz B. Optic nerve changes in ocular toxoplasmosis. Eye (Lond). 2007; 21:746-51. [PubMed: 16575416]

[51] Roach ES, Zimmerman CF, Troost BT, Weaver RG. Optic neuritis due to acquired toxoplasmosis. Pediatr Neurol. 1985; 1:114-6. [PubMed: 3880394]

[52] Fish RH, Hoskins JC, Kline LB. Toxoplasmosis neuroretinitis. Ophthalmology 1993; 100:1177-1182.

[53] Khairallah M, Yahia SB, Zaouali S et al. Acute choroidal ischemia associated with toxoplasmic retinochoroiditis. Retina 2007; 27:947-951.

[54] Ouyang Y, Pleyer U, Shao Q, Keane PA, Stübiger N, et al. (2014) Evaluation of Cystoid Change Phenotypes in Ocular Toxoplasmosis Using Optical Coherence Tomography. PLoS ONE 9(2): e86626. DOI: 10.1371/journal.pone.0086626

[55] Park HJ, Lee S and Lee EK. Morphological characteristics of ocular toxoplasmosis and its regression pattern on swept-source optical coherence tomography angiography: a case report. BMC Ophthalmology 2019; 19:199 DOI:10.1186/s12886-019-1209-8

[56] Ammar F, Mahjoub A, Abdesslam N, Knani L, Ghorbel M, Mahjoub H. Spectral optical coherence tomography findings in patients with



- ocular toxoplasmosis: A case series study. *Annals of Medicine and Surgery* 54 (2020) 125-128. DOI; 10.1016/j.amsu.2020.04.008
- [57] Dodds EM, Holland GN, Stanford MR, et al. Intraocular inflammation associated with ocular toxoplasmosis: relationships at initial examination. *Am J Ophthalmol.* 2008; 146:856-65. e2. [PubMed: 19027421]
- [58] Moshfeghi DM, Lowder CY, Dodds EM, et al. Diagnostic approaches to severe, atypical toxoplasmosis mimicking acute retinal necrosis. *Ophthalmology* 2004; 111:716-725
- [59] Johnson MW, Greven CM, Jaffe GJ, et al. Atypical, severe toxoplasmic retinochoroiditis in elderly patients. *Ophthalmology* 1997; 104:48-57.
- [60] Elkins BS, Holland GN, Opremcak EM, et al. Ocular toxoplasmosis misdiagnosed as cytomegalovirus retinopathy in immunocompromised patients. *Ophthalmology* 1994;101: 499-507.
- [61] Amaro MH, Muccioli C, Abreu MT et al. Remote hypofluorescent dots in recurrent ocular toxoplasmosis on indocyanine green angiography. *Arq Bras Oftalmol* 2007;70:901-904
- [62] Holland GN. Ocular toxoplasmosis: a global reassessment. Part II: disease manifestations and management. *Am. J. Ophthalmol.* 2004; 137, 1-17. DOI: 10.1016/j.ajo.2003.10.032
- [63] Garweg JG, Scherrer JN, Halberstadt M. Recurrence characteristics in European patients with ocular toxoplasmosis. *Br J Ophthalmol.* 2008; 92:1253-6. [PubMed: 18211930]
- [64] Holland GN, Crespi CM, ten Dam-van Loon N, et al. Analysis of recurrence patterns associated with toxoplasmic retinochoroiditis. *Am J Ophthalmol.* 2008; 145:1007-13. [PubMed: 18343351]
- [65] Pivetti-Pezzi P, Accorinti M, Tamburi S, Ciapparoni V, Abdulaziz MA. Clinical features of toxoplasmic retinochoroiditis in patients with acquired immunodeficiency syndrome. *Ann Ophthalmol.* 1994; 26:73-84. [PubMed: 7944160]
- [66] Bosch-Driessen LH, Plaisier MB, Stilma JS, Van der Lelij A, Rothova A. Reactivations of ocular toxoplasmosis after cataract extraction. *Ophthalmology.* 2002; 109:41-5. [PubMed: 11772577]
- [67] O'Connor GR. Factors related to the initiation and recurrence of uveitis: XL Edward Jackson Memorial Lecture. *Am J Ophthalmol* 1983; 96:577-599.
- [68] Holland GN, Engstrom R, Glasgow BJ, et al. Ocular toxoplasmosis in patients with the acquired immunodeficiency syndrome. *Am J Ophthalmol* 1988; 106:653-667.
- [69] Liesenfeld O, Press C, Montoya JG et al. Falsepositive results in immunoglobulin M (IgM) toxoplasma antibody tests and importance of confirmatory testing: the Platelia Toxo IgM test. *J Clin Microbiol* 1997; 35:174-178
- [70] Montoya JG, Remington JS. Management of *Toxoplasma gondii* infection during pregnancy. *Clin Infect Dis.* 2008; 47:554-66. [PubMed: 18624630]
- [71] Villard, O., Cimon, B., Lollivier, C., Fricker-Hidalgo, H., Godineau, N., Houze, S., & Candolfi, E. (2016). Serological diagnosis of *Toxoplasma gondii* infection: recommendations from the French National Reference Center for Toxoplasmosis. *Diagnostic Microbiology and Infectious Disease*, 84(1), 22-33.

- [72] Ronday MJ, Luyendijk L, Baarsma GS, Bollemeijer JG, Van der Lelij A, Rothova A. Presumed acquired ocular toxoplasmosis. *Arch Ophthalmol*. 1995; 113:1524-9. [PubMed: 7487620]
- [73] Pinon JM, Foudrinier F, Mougeot G et al (1995) Evaluation of risk and diagnostic value of quantitative assays for anti-Toxoplasma gondii immunoglobulin A (IgA), IgE, and IgM and analytical study of specific IgG in immunodeficient patients. *J Clin Microbiol* 1995; 33:878-884.
- [74] Garweg JG. Determinants of immunodiagnostic success in human ocular toxoplasmosis. *Parasite Immunol* 2005; 27:61-68
- [75] Oliveira AA, Oréfi ce F, Nascimento E. The aqueous humor antibodies coefficient: part I. *Arq Bras Oftalmol* .1988;51:237-238
- [76] Desmonts G Definitive serological diagnosis of ocular toxoplasmosis. *Arch Ophthalmol*.1966; 76:839-851
- [77] De Boer JH, Luyendijk L, Rothova A, Kijlstra A. Analysis of ocular fluids for local antibody production in uveitis. *Br J Ophthalmol*. 1995; 79:610-6. [PubMed: 7626580]
- [78] Russell N. Van Gelder Henry J. Kaplan Application of the polymerase chain reaction to the diagnosis of uveitis *Ocular Immunology and Inflammation* –1998, Vol. 6, No. 2, pp. 129-134
- [79] Errera M, Goldschmidt P, Batellier L, Degorge S, Héron E, Laroche L. Real-time polymerase chain reaction and intraocular antibody production for the diagnosis of viral versus toxoplasmic infectious posterior uveitis *Graefes Arch Clin Exp Ophthalmol* 2011; 249:1837-1846
- [80] Westeneng AC, Rothova A, De Boer JH, de Groot-Mijnes JD. Infectious uveitis in immunocompromised patients and the diagnostic value of polymerase chain reaction and Goldmann– Witmer coefficient in aqueous analysis. *Am J Ophthalmol* 2007; 144:781-785.
- [81] Labalette P, Delhaes L, Margaron F, Fortier B, Rouland JF. Ocular toxoplasmosis after the fifth decade. *Am J Ophthalmol*. 2002; 133:506-15. [PubMed: 11931784]
- [82] Rothova A, de Boer JH, Ten Dam-van Loon NH, et al. Usefulness of aqueous humor analysis for the diagnosis of posterior uveitis. *Ophthalmology*. 2008; 115:306-11
- [83] Rothova A, Buitenhuis HJ, Meenken C, et al. Therapy of ocular toxoplasmosis. *Int Ophthalmol* 1989; 13:415-9.
- [84] Holland GN, Lewis KG. An update on current practices in the management of ocular toxoplasmosis. *Am J Ophthalmol*. 2002; 134:102-14. [PubMed: 12095816]
- [85] Smith JR, Cunningham ET Jr. Atypical presentations of ocular toxoplasmosis. *Curr Opin Ophthalmol*. 2002; 13:387-92.
- [86] Soheilian M, Sadoughi MM, Ghajarnia M, et al. Prospective randomized trial of trimethoprim/ sulfamethoxazole versus pyrimethamine and sulfadiazine in the treatment of ocular toxoplasmosis. *Ophthalmology*. 2005; 112:1876-82.
- [87] McMaster PR, Powers KG, Finerty JF, Lunde MN. The effect of two chlorinated lincomycin analogues against acute toxoplasmosis in mice. *Am J Trop Med Hyg* 1973; 22:14-17.
- [88] Lakhanpal V, Schocket SS, Nirankari VS. Clindamycin in the treatment of toxoplasmic retinochoroiditis. *Am J Ophthalmol* 1983; 95:605-613.

- [89] Opremcak EM, Scales DK, Sharpe MR. Trimethoprim-sulfamethoxazole therapy for ocular toxoplasmosis. *Ophthalmology* 1992; 99:920-925.
- [90] Pearson PA, Piracha AR, Sen HA, Jaffe GJ. Atova-quone for the treatment of toxoplasma retinochoroiditis in immunocompetent patients. *Ophthalmology*. 1999; 106:148-53. [PubMed: 9917796]
- [91] Rothova A, Bosch-Driessen LE, van Loon NH, Treffers WF. Azithromycin for ocular toxoplasmosis. *Br J Ophthalmol*. 1998; 82:1306-8
- [92] Winterhalter S, Severing K, Stammen J, Maier AK, Godehardt E, Jousen AM. Does atovaquone prolong the disease-free interval of toxoplasmic retinochoroiditis? *Graefes Arch Clin Exp Ophthalmol*. 2010; 248:1187-92.
- [93] Bosch-Driessen LH, Verbraak FD, Suttorp-Schulten MS, et al. A prospective, randomized trial of pyrimethamine and azithromycin vs pyrimethamine and sulfadiazine for the treatment of ocular toxoplasmosis. *Am J Ophthalmol*. 2002; 134:34-40. [PubMed: 12095805]
- [94] Gagliuso DJ, Teich SA, Friedman AH, Orellana J. Ocular toxoplasmosis in AIDS patients. *Trans Am Ophthalmol Soc* 1990; 88:63-86.
- [95] Cochereau-Massin I, Lehoang P, Lautier-Frau M, et al. Ocular toxoplasmosis in human immunodeficiency virus infected patients. *Am J Ophthalmol* 1992; 114:130-135.
- [96] Jasper S, Vedula SS, John SS, Horo S, Sepah YJ, Nguyen QD. Corticosteroids as adjuvant therapy for ocular toxoplasmosis. *Cochrane Database of Systematic Reviews* 2017, Issue 1. DOI: 10.1002/14651858.CD007417.
- [97] Silveira C, Belfort R Jr, Muccioli C, et al. The effect of long-term intermittent trimethoprim/sulfamethoxazole treatment on recurrences of toxoplasmic retinochoroiditis. *Am J Ophthalmol*. 2002; 134:41-6.
- [98] Soheilian M, Ramezani A, Azimzadeh A, et al. Randomized trial of intravitreal clindamycin and dexamethasone versus pyrimethamine, sulfadiazine, and prednisolone in treatment of ocular toxoplasmosis. *Ophthalmology*. 2011; 118:134-41.
- [99] Barbara A, Shehadeh-Masha'our R, Sartani G, Garzozzi HJ. Reactivation of ocular toxoplasmosis after LASIK. *J Refract Surg*. 2005;21(6):759-761.
- [100] Holland, GN.; O'Connor, GR.; Belfort, R., Junior; Remington, JS. Toxoplasmosis. In: Pepose, JS.; Holland, GN.; Wilhelmus, KR., editors. *Ocular Infection & Immunity*. St. Louis: Mosby; 1996. p.1183-223.
- [101] Ambar F, Steven Y, Eric SB, Justine SR and Christina F J. Retinal Detachment associated with ocular toxoplasmosis. *Retina*: 2015; 35: 2, 358-363