

# We are IntechOpen, the world's leading publisher of Open Access books Built by scientists, for scientists

6,900

Open access books available

186,000

International authors and editors

200M

Downloads

Our authors are among the

154

Countries delivered to

TOP 1%

most cited scientists

12.2%

Contributors from top 500 universities



WEB OF SCIENCE™

Selection of our books indexed in the Book Citation Index  
in Web of Science™ Core Collection (BKCI)

Interested in publishing with us?  
Contact [book.department@intechopen.com](mailto:book.department@intechopen.com)

Numbers displayed above are based on latest data collected.  
For more information visit [www.intechopen.com](http://www.intechopen.com)



# Liposuction for Fat Transfer: The “Island Technique”

*Roger E. Amar*

## Abstract

The material harvested during liposuction is discarded but the fat used for fat grafting must be preserved and not polluted by the products used for tumescent anaesthesia. The “Island technique” used for decades during the FAMI procedure (Fat autografting Muscle Injection), provides samples of fat which had no or little contact with the lidocaine. The first step of the injection is made between the muscle and fat deposit and the second step between the deep skin layers and the same fat deposit. It is one important factor of the successful outcome of our adipose SVF grafting in hundreds of cases of reconstructive and aesthetic surgeries since 1998.

**Keywords:** liposuction, harvesting fat, fat transfer, FAMI

## 1. Introduction

Autologous fat grafting has been used for over a century and is still considered as a technique of choice for soft tissue replacement in Aesthetic plastic and reconstructive surgery. However, the critical point of this technique was fat graft survival. The high percentage and variable amount of fat resorption were the main disadvantages of this procedure before the use from 1997 the FAMI technique, Facial Autologous Muscular Injection [1].

Autologous fat transfer has been subject to great evolution over the last century and became very popular after the fundamental clinical studies of Y.G. Illouz [2]. The material harvested during liposuction is discarded, but the fat tissues used in fat grafting needs to be preserved and not polluted by the products used during the tumescent local anaesthesia [3]. The presence of adipose stem cells in the harvesting samples found by Patricia Zuck and her team [4] emphasised the necessity of fat preservation during the harvesting process and some changes in the technique.

JA Klein, a Californian dermatologist [5], invented the tumescent liposuction which consists of infiltrating at the fat deposit with a local anaesthetic and a vasoconstrictor diluted in a large volume of saline. This technique allowed the patients to benefit from liposuction totally by local anaesthesia, thus avoiding the risks of general anaesthesia and promoting a short recovery time.

For providing samples of fat during fat transfer which no or little contact with the lidocaine, the “Island technique” was used for decades in the first step of the FAMI technique [6, 7].

This simple method will help all practitioner to harvest pure fat in the syringe with less saline mixed with Lidocaine.

## 2. Materials and methods

More than 1400 patients were injected with this protocol from 1997 to 2021. These patients were chosen in Group I and II of Ricardo Baroudi: Group I – Fat deposits with firm skin, and Group II – Fat deposits with moderate to flabby skin.

### 2.1 Anaesthesia

Loco-regional anaesthesia is commonly used with injection of Klein' Solution, (**Figure 1**). One litre of normal saline is mixed with 50 cc of 1% plain Lidocaine, 1 ml of 1:1000 epinephrine and 10 cc of physiological concentration of Sodium bicarbonate to reduce the acidity and therefore reduce the discomfort of injection.

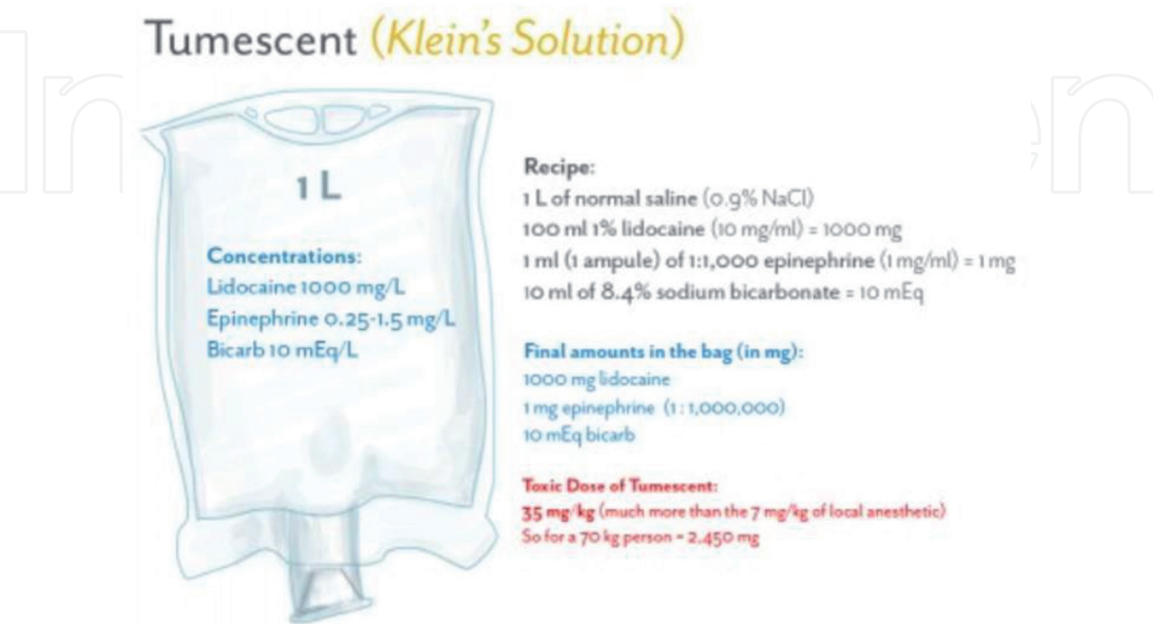
In conventional liposuction the fat is not preserved, conversely, in fat transfer or in FAMI it is necessary to use a very conservative method similar to a biopsy in order to preserve intact the fat cylinders inside the 10 cc syringe.

### 2.2 Technique of injection

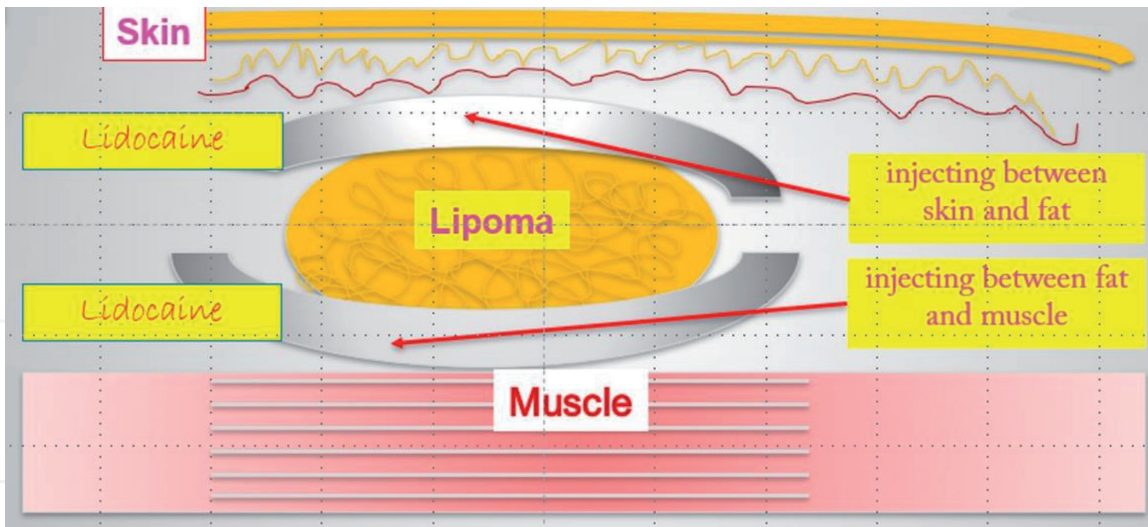
The adipose pads are wrapped by a relatively impermeable fascia that would prevent subcutaneous infections from spreading to the more fragile adipose tissue. It is therefore easy to inject above and under the fat pocket without “wetting” the fat.

As shown in (**Figure 2**), the first and most important injection put the anaesthetic solution in contact with the emerging nerves under the fat deposit just above the muscle aponeurosis using a 3-mm diameter cannula. The second very superficial of lower volume will use a thin 2 mm diameter cannula, immediately under the skin for a good vasoconstriction, under view control, above the fat pocket.

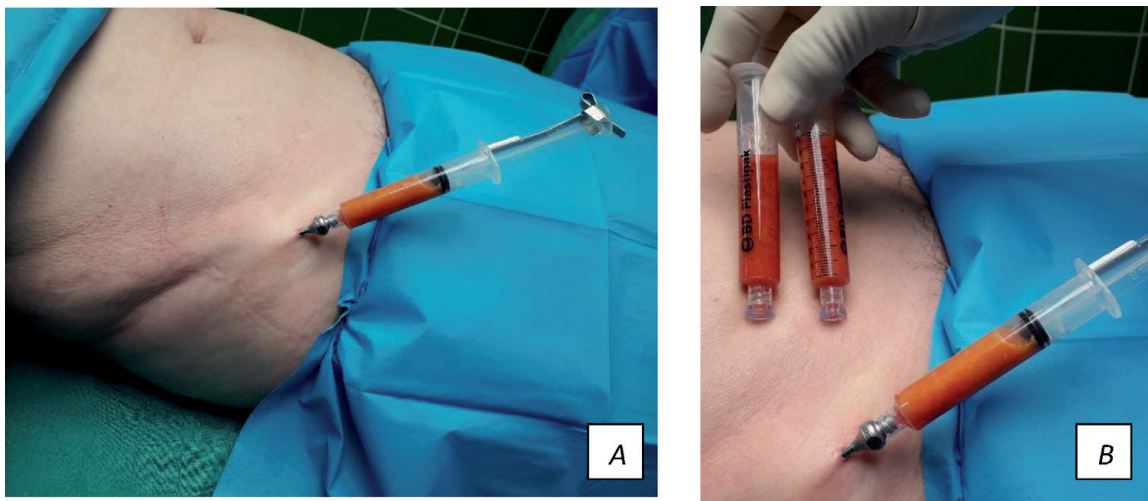
After few minutes the harvesting begins from the core of the fat deposit, generally free of liquids (**Figure 3A and B**).



**Figure 1.**  
A sketch to figure the Klein' solution composition. [<https://sketchymedicine.com/2016/01/tumescence-solution-for-burn-surgery-and-liposuction/>].



**Figure 2.**  
*The first injection is done under the fat along the muscle aponeurosis. The second injection is done immediately under the skin.*



**Figure 3.**  
*A and B: During the FAMI technique a virtually lidocaine free samples are harvested using 10 cc Luer lock syringes ready to be put in the centrifuge for purification.*

### 3. Discussion

Both men and women have attended consultations for fat transfer and more particularly for the FAMI procedure (Facial Autologous Muscular Injection) which was developed to avoid the two major disadvantages of the conventional lipofilling, the unpredictability and the longevity.

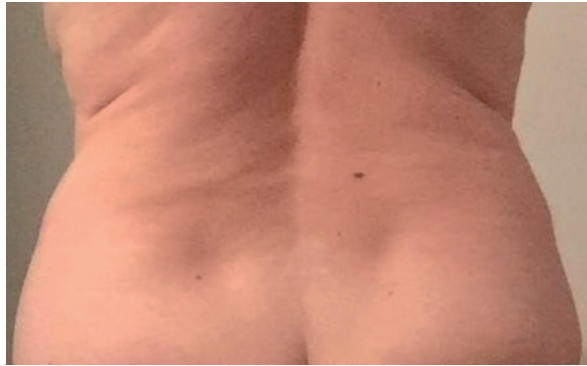When longevity is considered, every step of the technique becomes important, from the local anaesthesia and the anatomy of the fat deposit to injection of facial targets.

The choice of the candidates for lipo transfer is important and they must be chosen among the two first groups of the four described by Ricardo Baroudi.

*Group I – Fat deposits with firm skin. Patients are usually young, in their twenties with no flabbiness and no exaggerated volume.*

*Group II – Fat deposits with moderate to flabby skin. The fat deposit is not excessive and the skin is no longer firm. If a large amount of fat is removed the significant flaccidity may produce undulations, waves, grooves and dimples. The patients of group II are generally between 20 and 35 years of age (Figure 4).*





**Figure 4.**  
*Fat deposits with firm skin or with moderate to flabby skin are good candidates for fat harvesting in lipo transfer.*

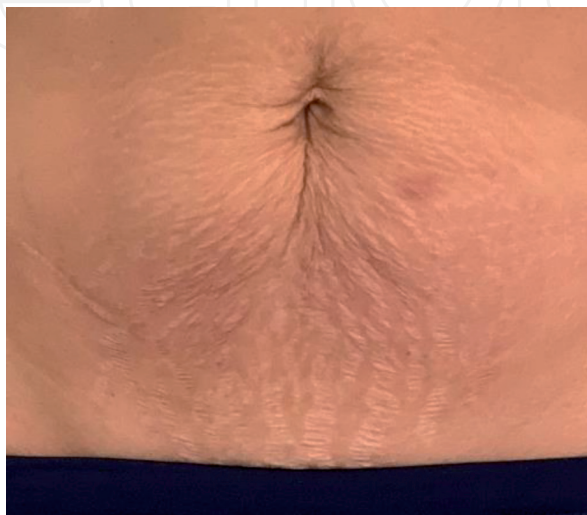We have to be very careful in choosing patients in the last 2 groups, to which I recommend the surgical approach (**Figure 5**).

*Group III – Fat deposits with marked skin flaccidity. The liposuction is generally associated to traditional surgery to tighten the skin.*

*Group IV – Skin flaccidity without fat deposit. In these particular cases we can find only the fat deep in gluteal area or in the flanks.*

The anatomy and histology of the adipose tissues were well described in his book by J.A. Klein [8].

- Fat cells are contained within fat lobules, which are within fat pearls, which are contained within fat sections, which are within fat compartments.
- The size and shape of these fat compartments are responsible for the differences in surface anatomy that exist between adult males and females.
- The fat compartments are surrounded and divided by fibrous formations or fasciae which are organised in tangential planes and oblique partitioning walls. The tangential planes above and under the fat compartment are made of connective laminated tissue, relatively dense, approximately oriented parallel and tangentially to the subjacent muscle fasciae. The more superficial subcutaneous fascia is a laminate of fibrous sheets, with each lamella a weblike, interwoven film of collagen and fibrocytes.



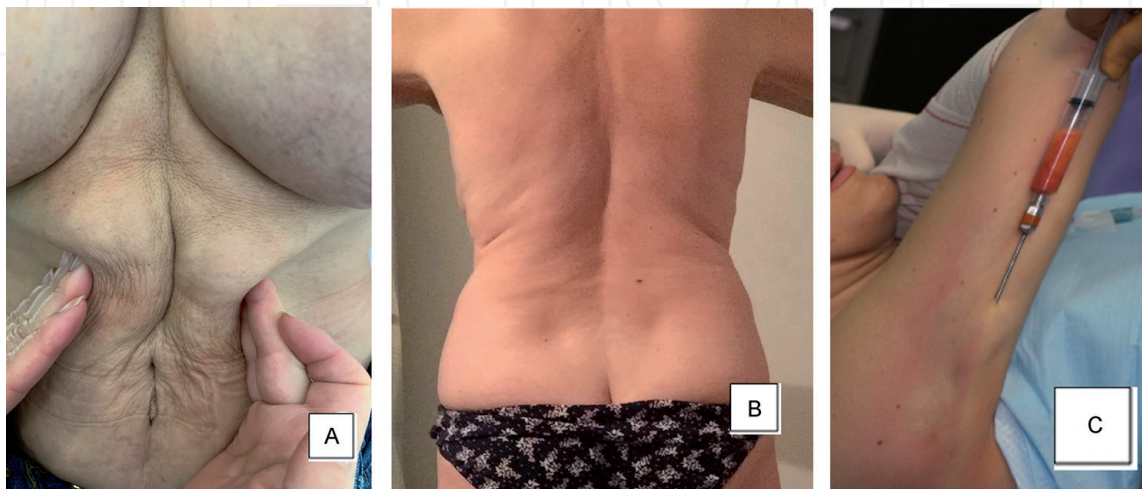
**Figure 5.**  
*Fat deposits with marked skin flaccidity with stretch marks are not good candidates for fat transfer.*

- In the “Island method” it is easy to find the right plane for introducing the infiltrating cannula, above or behind these no leaks fibrous planes and leave the anaesthetics work during few minutes.
- Fat Areas to harvest are multiple and can be chosen according to each patient.
- **Figure 6A, B, C** shows the best areas with no flabbiness to harvest for the “island technique” in fat transfer.

Lidocaine, the first amino amide-type local anaesthetic, was first synthesised under the name ‘xylocaine’ by Swedish chemist Nils Löfgren in 1943 [9]. The local anaesthesia (LA) with lidocaine presents a rapid onset and an intermediate duration of action. Although lidocaine is the oldest aminoamide, this drug is widely used all over the world in the context of autologous fat transfer.

The effects of local anaesthesia with lidocaine on the viability of fat obtained by syringe suction lipectomy was studied in 1995 by John H. Moore Jr. and Jerzy W. Kolaczynski [10]. They examined if adipose tissue viability is compromised by using syringe suction lipectomy and by infiltration of the tissue with lidocaine. They found that Lidocaine potently inhibited glucose transport and lipolysis in adipocytes and their growth in culture. That effect, however, persisted only as long as lidocaine was present; after washing, the cells were able to fully regain their function and growth regardless of whether the exposure was as short as 30 minutes or as long as 10 days. These preliminary results indicated that adipose tissue obtained by syringe lipectomy consists of fully viable and functional adipocytes, but local anaesthetics may halt their metabolism and growth.

Tao Wu and Jay Smith, published in 2018 an article on the Cytotoxicity of Local Anaesthetics in Mesenchymal Stem Cells [11] and found that local anaesthetics may have negative impact on Mesenchymal Stem Cells dosing because of cytotoxicity or other biological effects. They reviewed 11 studies that involve *in vitro* experimentation with MSCs using aminoamide-type anaesthetics including lidocaine, ropivacaine, mepivacaine, bupivacaine, articaine, and prilocaine and concluded lidocaine seems to have the most significant effects on stem cell viability. They conclude that local anaesthetic agents have time- and concentration-dependent detrimental effects on Mesenchymal stem cells (MSCs). They noticed that *in vivo* studies will be required to understand the interactions of these agents with MSCs, because *in vitro*



**Figure 6.**  
A, B and C shows the best areas for fat removal. Abdominal region, lateral parts of the waist, and brachial fat pad.

studies cannot replicate the pharmacokinetics of anaesthetics *in vivo* or the recovery of (MSCs) in a more physiological environment.

The most recent study came from Felix Grambow and Rico Rutkowski (2020) [12]. They made a clinical research on a series of cases to conclude that lidocaine has no negative impact on the distribution, cell number, and viability of Adipose derived stem cells (ASCs) and preadipocytes. After centrifugation, only the middle fatty portion of processed lipoaspirate (PLA) in the syringe will contain Adipose derived stem cells (ASCs), which are crucial for successful lipotransfer. Adipose stem cells, which are restricted to adipogenic evolvement, were found to be significantly more common inside the Processed liposuction (PLA) than inside the Processed liposuction aspirate fluid (LAF).

#### 4. Conclusion

The “Island” local anaesthesia followed by the mechanical purification with high-speed centrifuge, provide a bloodless and painless harvesting regardless of how much lidocaine is injected and its effect on the viability of ASC.

Collecting fat and obtaining SVF (Stromal Vascular Fraction) are the first steps of the FAMI technique that inject the surfaces and edges of the facial skeleton, the mimic muscles [13] and the deep fat pads. The precision in these two first steps in the technique are responsible for the excellent results obtained over the past 24 years with the technique FAMI full face or eclectic. Used on more than 1400 personal patients, this simple method of extraction will be useful to any surgeon who is beginning their experience in fat transfer.

#### Author details

Roger E. Amar<sup>1,2,3</sup>

1 FAMI International Academy, Carson City, Nevada, USA

2 Marbella Aesthetic Clinic, Marbella, Spain

3 London Cadogan Clinic, UK

\*Address all correspondence to: rogeramar@gmail.com

#### IntechOpen

© 2021 The Author(s). Licensee IntechOpen. This chapter is distributed under the terms of the Creative Commons Attribution License (<http://creativecommons.org/licenses/by/3.0>), which permits unrestricted use, distribution, and reproduction in any medium, provided the original work is properly cited. 

## References

- [1] Roger E. Amar. "Adipocyte microinfiltration in the face or tissue restructuration with fat tissue graft". *Ann Chir Plast Esthet*: (1999) 593-608.
- [2] Illouz YG. Present results of fat injection. *Aesthetic Plast Surg* (1988) 12: 175-181.
- [3] Girard AC, Festy F, Roche R (2013) Local Anesthetics: Use and Effects in Autologous fat Grafting. *Surgery Curr Res* 3: 142.
- [4] Zuk, P.A.; Zhu, M.; Ashjian, P.; de Ugarte, D.A.; Huang, J.I.; Mizuno, H.; Alfonso, Z.C.; Fraser, J.K.; Benhaim, P.; Hedrick, M.H. Human adipose tissue is a source of multipotent stem cells. *Mol. Biol. Cell* (2002), 13, 4279-4295.
- [5] Klein JA. The tumescent technique. Anesthesia and modified liposuction technique. *Dermatol Clin.* (1990), 8(3): 425-37.
- [6] FAMI -Facial Autologous Muscular Injection - Wikipedia
- [7] Amar, Roger; Fox, Donald "The facial autologous muscular injection (FAMI) procedure: an anatomically targeted deep multiplane autologous grafting technique using principles of adipose stem cell injection" *Aesthetic Plast Surg.* (2011). 35 (4): 502-10.
- [8] Klein, Jeffrey A. (2000). *Tumescent Technique : Tumescent Anesthesia & Microcannular Liposuction*. St. Louis: Mosby. pp. xvi, 470 p.
- [9] Löfgren N, Lundqvist B (1946). "Studies on local anaesthetics II". *Svensk Kemisk Tidskrift*. 58: 206-17.
- [10] John H. Moore Jr. M.D., Jerzy W. Kolaczynski M.D., Luz M. Morales M.Sc., Robert V. Considine Ph.D., Zbigniew Pietrzkowski Ph.D., Penny F. Noto R.N. & Jose F. Caro M.D. Viability of fat obtained by syringe suction lipectomy: effects of local anesthesia with lidocaine. *Aesthetic Plastic Surgery*. (1995). volume 19, pages 335-339
- [11] Wu, T.; Smith, J.; Nie, H.; Wang, Z.; Erwin, P.J.; van Wijnen, A.J.; Qu, W. Cytotoxicity of Local Anesthetics in Mesenchymal Stem Cells. *Am. J. Phys. Med. Rehabil.* 2018, 97, 50-55.
- [12] Felix Grambow, Rico Rutkowski, Fred Podmelle, Katrin Schmoeckel, Florian Siegerist, Grzegorz Domanski, Matthias W. Schuster and Grazyna Domanska. The Impact of Lidocaine on Adipose-Derived Stem Cells in Human Adipose Tissue Harvested by Liposuction and Used for Lipotransfer. *Int. J. Mol. Sci.* (2020), 21, 2869, 1-19
- [13] Amar, R.E.; Fox, D.M.; Balin, A. "Cannulation and injection of the muscles of facial expression: a cadaver study". *Dermatol Surg.* (2010). 36 (3): 331-338.