

We are IntechOpen, the world's leading publisher of Open Access books Built by scientists, for scientists

6,900

Open access books available

185,000

International authors and editors

200M

Downloads

Our authors are among the

154

Countries delivered to

TOP 1%

most cited scientists

12.2%

Contributors from top 500 universities



WEB OF SCIENCE™

Selection of our books indexed in the Book Citation Index
in Web of Science™ Core Collection (BKCI)

Interested in publishing with us?
Contact book.department@intechopen.com

Numbers displayed above are based on latest data collected.
For more information visit www.intechopen.com



Pseudophakic Presbyopic Corrections

Georgios Labiris and Eirini-Kanella Panagiotopoulou

Abstract

Presbyopia is a prevalent productivity-reducing, age-related visual disorder that results in a progressive near vision impairment. Conventional treatment modalities (ie. presbyopic spectacles or contact lenses) are associated with poor acceptance, productivity loss and negative impact on life quality. However, a variety of surgical methods are available to address presbyopia; among them, multifocal and multifocal toric intraocular lenses (IOLs) and monovision techniques. For the best possible refractive outcomes, the overall management of presbyopic patients is necessary. Specifically, patient selection according to personality and daily activities, topography, aberrometry, astigmatism, pupil and fundus assessment, ophthalmic surface, and premium lens selection should be taken into consideration. Additionally, image-guided surgery could increase the accuracy in multifocal/multifocal toric IOL implantation, and optimize the refractive outcome increasing patient satisfaction. Primary objective of this chapter is to analyze the fundamental preoperative, intraoperative and postoperative management of patients that undergo pseudophakic presbyopic corrections with conventional or digital-marking assisted techniques.

Keywords: presbyopia, cataract surgery, refractive lens exchange, multifocal intraocular lens, monovision, pseudophakic presbyopic correction

1. Introduction

Presbyopia is probably the most prevalent productivity-reducing, age-related visual disorder that results in a progressive impairment of near vision capacity. Presbyopia symptoms include blurry vision when targeting at near objects and fatigue when reading, especially in suboptimal lighting conditions. It is common for emmetropic populations above 40 years old. Almost every working person is expected to suffer from reduction of his/her near and intermediate vision capacity due to presbyopia [1, 2]. Taking into consideration the constantly increasing life-expectancy, conservative estimates suggest that by 2050, about 1.8 billion people will experience presbyopia symptoms [3]. Additionally, since computers, tablets, and smart phones have modified heavily working and social norms, presbyopia significantly limits the patient's productivity and reduces life quality [4, 5].

It is a truism that correction of presbyopia is among the most challenging unmet objectives in Ophthalmology. Conventional treatment modalities (ie. presbyopic spectacles or contact lenses) are associated with poor acceptance, productivity loss and significant negative impact on the quality of life [5]. Despite the fact that

the lens extraction surgery is the most frequent surgical operation in Medicine, [5, 6] the postoperative loss of accommodation is yet to be adequately addressed. Different surgical approaches for the correction of presbyopia have been developed targeting the cornea and/or the crystalline lens [7]. A variety of technologies have also been introduced, primarily in the ophthalmological lasers and in the intraocular lenses (IOLs) aiming to restore the pre-presbyopic functionality of the human eye [8]. The ultimate goal is a spectacle-free visual capacity that imposes no limits to the social, personal, working needs of each patient [9–12]. As regards pseudophakic presbyopic corrections, the “ideal” IOL should restore the patients' vision without complications or visual compromises at all distances [13]. Premium IOLs, such as multifocal, accommodating and extended-depth-of-focus (EDOF), as well as pseudophakic monovision techniques achieved by monofocal IOL implantation or implantation of a combination of premium IOLs, are some of the available surgical approaches. When presbyopia is combined with astigmatism, multifocal toric IOLs can be used.

However, for the best possible refractive outcomes, solid and up-to-date information on the overall management of presbyopic patients is necessary. In specific, patient selection (according to personality, daily activities, and expectations), astigmatism assessment, topography, aberrometry, pupil assessment, ophthalmic surface, fundus assessment, and premium lens selection should always be taken into consideration before a presbyopic correction. In addition, in case of implantation of multifocal or multifocal toric IOLs, image-guided surgery could increase the accuracy of IOL centration (in multifocal and multifocal toric IOLs) and alignment (in multifocal toric IOLs), and optimize the refractive outcome increasing patient satisfaction.

Primary objective of this chapter is to analyze the fundamental preoperative, intraoperative and postoperative management of patients that undergo pseudophakic presbyopic correction with conventional or digital-marking assisted techniques. In specific, this chapter aims to give an overview of the current IOL technologies for a pseudophakic presbyopic correction, patient selection criteria, benefits and limitations of each IOL technology.

2. Preoperative diagnostic evaluation

Accurate preoperative diagnostic evaluation is necessary for preoperative patient counseling, the selection of the most appropriate IOL type and surgical planning. Preoperative diagnostics are also essential for determining the anatomical success rates of IOL implantation [13].

A preoperative examination for patients intending to undergo a pseudophakic presbyopic correction should include: (i) taking of the medical history, (ii) basic ophthalmological examination, and (iii) additional diagnostic procedures:

2.1 Medical history

2.1.1 General medical history

As in the routine preoperative examination for a typical cataract surgery with implantation of a monofocal IOL, the routine preoperative examination for a pseudophakic presbyopic correction should include taking a detailed history for current or past medical conditions [eg. hypertension, diabetes, ischemic heart disease, pulmonary diseases, benign prostatic hyperplasia (BPH), bleeding disorders, history

of herpes libialis or autoimmune diseases, such as rheumatoid arthritis, Hashimoto's thyroiditis, and Sjogren syndrome].

In addition, the surgeon should be aware of the patient's former surgeries and current or prior use of systemic or topical pharmaceutical medications such as anticoagulant, alpha-blocker (tamsulosin) for BPH, steroid or immunosuppressant medication [14].

2.1.2 Ocular history

Glaucoma, former incisional surgery (eg. refractive, retinal, glaucoma, muscle surgery), eye trauma, amblyopia, herpes simplex keratitis, allergic conjunctivitis, uveitis, recurrent corneal erosions and prior or current topical medications should be taken into account.

2.1.3 Family eye history

Family history of eye disorders responsible for blindness or visual impairment (e.g. glaucoma, retinal or corneal disease, etc) should be considered.

2.1.4 Allergies

If the patient is allergic to medications, the type of medication and the exact reaction to that medication should be clarified (rash, anaphylaxis etc).

2.2 Basic ophthalmological examination

2.2.1 Visual acuity assessment

The evaluation of the Uncorrected Distance Visual Acuity (UDVA), Best Corrected Distance Visual Acuity (BCDVA), Uncorrected Near Visual Acuity (UNVA), Best Corrected Near Visual Acuity (BCNVA), Uncorrected Intermediate Visual Acuity (UIVA), Best Corrected Intermediate Visual Acuity (BCIVA) should be included in the ophthalmic examination. The contrast sensitivity should also be evaluated.

2.2.2 Slit lamp examination of the anterior segments of the eye

Eyelids, lacrimal drainage system, cornea, conjunctiva, iris, pupil, anterior chamber, and lens should be evaluated in the first preoperative examination. In detail, certain findings for each anatomical structure should be taken into account and could encourage surgeons to perform some types of presbyopic corrections or discourage them from performing other surgical techniques. In addition, some eye pathologies should be addressed before the surgery.

- *Eyelids:* Eyelid pathology, including ectropion, entropion, and blepharitis, should be addressed before the surgery.
- *Lacrimal drainage system:* The lacrimal drainage system is recommended to be open.
- *Cornea:* Ocular surface and cornea should be evaluated. Ocular surface disease such as dry-eye syndrome, exposure keratitis and meibomian gland

dysfunction should be treated preoperatively, since tear-film abnormalities may influence postoperative visual outcomes leading to suboptimal visual quality and performance, regardless of the type of IOL to be implanted. Slit lamp evaluation of corneal endothelium should not be omitted. Corneal dystrophies, such as Fuchs' corneal dystrophy, as well as corneal scars (central or peripheral), pterygium and keratoconus signs should be taken into consideration for the selection of the most appropriate presbyopia correction method.

- *Conjunctiva:* Conjunctival disorders should be assessed, such as conjunctival hyperemia, papillae, hyperplasia of lymphoid follicles, erosions, scarring and symblepharon.
- *Iris:* The pupil size and shape should be evaluated before and after mydriasis. Pupils with an irregular shape could interfere with desired refractive outcome. Inadequate mydriasis is a well-known risk factor associated with numerous intra- or postoperative complications [15]. In addition, anterior and/or posterior synechiae could increase the risk for inadequate mydriasis and intraoperative complications. Finally, iris neovascularization should not be overlooked.
- *Anterior chamber:* The anterior chamber depth (ACD) should be evaluated with slit lamp biomicroscopy. A shallow anterior chamber can be present in hypermetropic eyes with short axial length (AL). However, it might also be caused by an intumescent cataract or other pathological causes. Regardless of the cause, a shallow anterior chamber could increase the difficulty of a lens extraction surgery. Finally, gonioscopy could be performed, if considered necessary, to reveal angle abnormalities like synechiae and neovascularization.
- *Lens:* The cataract type and density should be evaluated in order to predict possible technical difficulties in performing cataract surgery. In addition, the presence of Pseudoexfoliation Syndrome (PEX), which is the most common cause of zonular weakness, should be identified. PEX can be better revealed after pupil dilation. This should be taken into account for the IOL type selection, since it increases the risk of a possible late decentration and misalignment of the IOL, that could influence the visual outcome negatively.

2.2.3 Slit lamp examination of the posterior segments of the eye (under pupil dilation)

- *Optic nerve:* Any abnormality of the optic nerve could influence the surgeon's decision for the IOL type selection.
- *Macula:* The macular anatomy should be assessed. The presence of acquired macular disorders including age-related macular degeneration (ARMD) findings and macular edema, or hereditary macular disorders, such as Stargardt's disease and retinitis pigmentosa, could be considered as relative or absolute contraindications for pseudophakic presbyopic corrections. The evaluation of the appropriateness of a pseudophakic presbyopic correction in the presence of a macular disease should depend on the stability of the disease, the expected progression over time, and the availability and usefulness of its treatment.
- *Rest fundus:* Retinal ischemia, vitreous retinal traction, lattice degeneration, and macular hole should be sought especially in diabetic patients.

2.2.4 Intraocular pressure (IOP) measurement

The measurement of the IOP should be part of the basic ophthalmological examination.

2.3 Additional diagnostic procedures

2.3.1 Automatic refraction

Measurements taken by an automatic kerato-refractometer can be co-evaluated with manifest refraction and corneal topography for the confirmation of the refractive error.

2.3.2 Optical biometry

Optical biometry, which is based on monochromatic light-emitting diodes, [16] including partial coherence interferometry (PCI) [e.g. IOLMaster 500 (Carl Zeiss Meditec AG, Jena, Germany)] and swept source OCT (ss-OCT) [eg. IOLMaster 700 (Carl Zeiss Meditec AG, Jena, Germany), Anterior (Heidelberg Engineering, Heidelberg, Germany)], serves as highly reliable method for AL (in mm), ACD (in mm) and keratometry (in diopters) determination. In comparison with standard keratometry, total keratometry measured with ss-OCT (IOLMaster 700) is a new measurement for the assessment of anterior and posterior corneal curvatures that seems to show higher accuracy in IOL power calculation and better refractive outcomes in eyes with or without previous laser refractive surgery [17–19]. As a result, it has been established as the most common preoperative examination performed to calculate the IOL power. According to the selected technique and patient, the postoperative refractive target is plano, low myopia or low hyperopia [20]. A variety of formulas have been used for the most accurate IOL power calculation. Since it has been found that inaccurate biometry is the most common cause of residual postoperative refractive error, [21] some factors should be taken into account; among them, interocular consistency in AL and K values, appropriate formula for each case, and outliers [22]. Last but not least, preoperatively, the surgeon should check and confirm that the biometry corresponds to the correct patient.

2.3.3 A-scan ultrasound biometry

Although A-scan biometry is less accurate and requires more operator skills to ensure consistent accuracy in comparison with optical biometry, it can be used in presence of dense cataract or corneal edema when the optical biometry cannot take measurements [23]. However, for the optimization of a-scan results, the immersion instead of the applanation (contact) technique could be chosen, since the former has better repeatability and higher accuracy than the latter [24, 25].

2.3.4 Corneal pachymetry

Ultrasonic pachymetry may contribute to the assessment of overall endothelial function in corneas with a diseased endothelium or with borderline low endothelial cell counts, however, corneal central thickness is not correlated with endothelial cell numerical density within the physiological range. Specifically, an increased preoperative thickness might increase the risk for postoperative clinical corneal edema [26].

2.3.5 Scheimpflug tomography/placido-based corneal topography

Scheimpflug tomography or, alternatively, placido-based corneal topography can determine patient's total or anterior-surface corneal astigmatism, respectively, and whether the astigmatism is regular or irregular, or even detect possible keratoconus. The corneal topographic analysis should be compared with optical biometry findings for the best possible accuracy in IOL power and astigmatism calculation, especially if a laser refractive surgery has been preceded.

2.3.6 Aberrometry

The routine preoperative examination should include the determination of the anterior aberration profile looking for elevations of 3rd- and 4th-order aberrations, such as coma and spherical aberrations (SA) [27]. Generally, cornea has an average positive SA of +0.28 μm (positive SA occurs when the peripheral rays entering the eye are focused in front of the central rays) [28]. Among the most common aberrometers are i-Trace aberrometer (Tracey Technologies Corp., Houston, TX), OPD-scan (ARK 10000; Nidek), and Pentacam (Oculus Optikgerate GmbH, Wetzlar, Germany), which calculate total ocular, lens or corneal wavefront aberrations [29, 30].

2.3.7 Pupillometry

Preoperative pupillometry can measure: (i) pupil diameter under photopic (small pupil) and mesopic (wide pupil) lighting conditions, (ii) distance between the pupil center and the visual axis (angle kappa), between the corneal center and the visual axis (angle alpha), and/or between the pupil center and the corneal center, and (iii) distance (spatial shift) from the photopic to the mesopic pupil center (pupil center shift - PCS) [31–33]. Regarding PCS, two types of PCS can be evaluated: (i) measured PCS, which results from the values measured under photopic and mesopic lighting conditions, and (ii) interpolated PCS, which depicts the predicted spatial shift between a photopic pupil of 2 mm to a scotopic pupil of 7 mm, and can contribute to the better comparability of the measurements [34].

2.3.8 Specular microscopy

Endotheliometry, especially in suspicion of endothelial dysfunction/dystrophy, is a very useful examination. The average endothelial cell density (ECD) in patients > 40 years old ranges between about 2500 and 2700 cells/mm² [35]. A central ECD decline of less than 1000 cells/mm² preoperatively, and 400 to 700 cells/mm² postoperatively might cause significant postoperative endothelial cell impairment and corneal edema. The hexagonality should also be assessed [36–38].

2.3.9 Macula and ONH OCT - OCTA

Since good macular and optic nerve function are necessary for a premium pseudophakic presbyopic correction, many surgeons perform an optical coherence tomography (OCT), or even an OCT angiography (OCTA), of the macula and optic nerve head (ONH) to confirm normal macular and optic nerve anatomy and microcirculation. Macular degeneration, subtle epiretinal membranes, early stages of macular hole or posterior vitreous separation with vitreal macular traction, but also glaucoma or vascular abnormalities in various optic neuropathies can be revealed.

2.3.10 Anterior segment OCT (AS-OCT)

The application of AS-OCT during the preoperative planning for cataract surgery could be useful in the accurate prediction of postoperative ACD and postoperative IOL position [39, 40].

2.3.11 B-mode ultrasonography

This examination could be performed to detect the posterior segment disorders, especially in suspicion of retinal detachment, vitreous opacity or posterior segment tumor, especially when the funduscopy is impossible due to mature cataract.

2.3.12 Image-guided systems – preoperative units

The size and the location of main and sideport incisions, the size and diameter of capsulorhexis, the centration of the capsulorhexis, as well as the alignment axis in case of toric or multifocal toric IOLs are predetermined in the preoperative examination with the measurement module of image-guided lens extraction surgery systems [41].

3. Surgical procedures – IOL types

The two most widely used methods for pseudophakic presbyopic correction are the monovision technique through bilateral implantation of monofocal IOLs and the bilateral implantation of multifocal IOLs [8].

3.1 Monovision techniques with bilateral monofocal IOL implantation

Pseudophakic, or IOL, monovision, which was first described by Boerner and Thrasher in 1984, [42] still remains the most common surgical management of presbyopia for cataract patients with good spectacle independence and high patient satisfaction [43, 44]. The 2016 clinical survey of the European Society of Cataract and Refractive Surgery (ESCRS) reported that 43% of cataract procedures are targeted for monovision or mini-monovision [45].

In traditional pseudophakic monovision, monofocal IOLs are implanted in both eyes. However, the recessive eye is intentionally defocused for myopia [8, 10, 12]. Myopic defocus of the recessive eye ranges from over 2 diopters (D) to less than 1 D (mini or micro monovision) [8, 10, 46]. In bilateral myopic monovision, the dominant eye defocus is targeted to -0.50 D, while the recessive one to -1.25 D [47]. However, recently, the crossed monovision has been suggested for high myopic cataract patients, which is to correct the dominant eye for near vision and the non-dominant eye for distance vision [8].

3.1.1 Patient selection

A careful patient selection with a specific determination of the inclusion and exclusion criteria is of paramount importance for an optimal refractive outcome and the highest possible patient satisfaction in case of pseudophakic monovision with bilateral monofocal IOL implantation.

Inclusion criteria: The most frequent inclusion criterion was the desire for spectacle independence [48]. One of the most important prerequisites for monovision success is the weak ocular dominance [49, 50].

Exclusion criteria: Several exclusion criteria have been reported in the literature. Some of them are the following:

- *Severe ocular diseases:* Patients with pathology of the optic nerve (eg. glaucoma or other optic neuropathies), macular or retinal pathology, corneal pathology or severe opacification of the rest refractive media other than cataract, previous history of ocular inflammation or surgery, amblyopia and other ocular pathology affecting visual performance are commonly excluded from monovision techniques [48], since the aforementioned diseases are believed to have suboptimal effect on visual rehabilitation [49].
- *Corneal astigmatism:* Patients with corneal astigmatism of ≥ 1.00 D, but also of ≥ 1.50 D or even ≥ 2.00 D are commonly excluded from monovision surgical methods with monofocal IOLs [48]. In fact, patients with high degree of corneal astigmatism do not benefit from monovision because their monocular and binocular UVA remains suboptimal. However, the implantation of toric IOLs could be considered. Moreover, patient satisfaction is related to the distance UVA of the dominant eye. Therefore, the correction of corneal astigmatism to less than 1.00 D is highly recommended [49].
- *Strong ocular dominance:* In patients with strong ocular dominance, the artificial anisometropia of monovision causes insufficient blur suppression and leads to reduction in visual performance [48, 50].
- *History of strabismus and abnormal ocular position (exophoria or esophoria):* Patients with a history of strabismus should be informed that monovision might lead to a recurrence of previous strabismus or asthenopic symptoms, and patients with a significant exophoria or esophoria should be informed that monovision might cause strabismus. Nevertheless, if patients wish to proceed to monovision, small levels of anisometropia, such as 1.25 to 1.50 D should be chosen to minimize the chance of strabismus [48, 51].
- *Age, lifestyle, work:* Patients younger than 60 years undergoing pseudophakic monovision seem to have lower postoperative satisfaction in comparison to patients older than 60 years. Some reasons for dissatisfaction are the higher rates of spectacle independence, asthenopia and difficulty mainly in near vision. This likely reflects the different age-related lifestyle activities between younger and older patients [52]. As a result, age lower than 60 years could be considered as an exclusion criterion, especially if it is combined with work requiring precise near vision. Pseudophakic monovision seems to be more beneficial for people older than 60 years [49, 52].
- *Nighttime driving, work under low illuminance:* In cases of weak ocular dominance, when the optical target appears highly contrasted with the background under mesopic lighting conditions, blur suppression does not function sufficiently. Therefore, pseudophakic monovision should be avoided in patients whose work requires precise vision under low illuminance levels or driving at night [52].
- *Inability to understand the concept of monovision design* [53]

In conclusion, regardless of the exclusion criteria, it is suggested that the procedure and possible outcomes of pseudophakic monovision, when selected,

should be thoroughly explained to patients in order the best possible visual outcome and patient satisfaction to be achieved.

3.1.2 Side effects of monovision technique

Although monovision is the most common surgical management of presbyopia for cataract patients with millions of people having monovision corrections, some important drawbacks of this method should be described.

First, although monovision is related with significant satisfaction, the highest percentages of satisfied patients have been found in age older than 70 years, while patients younger than 60 years have the highest percentages of dissatisfaction caused mainly by asthenopia and spectacle dependence [52].

Secondly, it has been reported that anisometropia and blur differences cause a motion illusion that leads to a significant misperception of the distance and three-dimensional direction of moving objects, since the blurred and sharp images are processed at different speeds. This phenomenon has a clinical impact on driving behavior, since these millisecond differences in processing speed could lead, for instance, to the misperception of the distance of cyclists by the width of a narrow street lane [54].

Finally, depth perception and distance stereopsis, especially for large disparities, may be compromised increasing the difficulty in navigation through the environment, obstacle avoidance, and stair walking. Reduction of distance stereopsis leads to a decrease in stability during locomotion, as well, increasing the risk factor for falls and hip fractures in aged population [55]. Near stereopsis is also reduced, although it remains within the normal range [52].

3.2 Multifocal IOLs

Multifocal IOLs have been designed to provide spectacle independence at near, intermediate, and distance vision tasks. The first concept of a truly multifocal IOL was conceived in 1983 by Hoffer, [56] and the first bifocal IOL implantation was performed by Pearce in 1986 [57]. Since then, many modifications and improvements in multifocal IOL concept have been made [58].

Before the analysis of the pre-, intra- and postoperative management of patients implanted with mIOLs, a brief description of the optical design and properties of mIOLs is required.

3.2.1 Optical design and properties of mIOLs

Two optical phenomena can be utilized to create multifocal optics: refraction and diffraction.

3.2.1.1 Fully refractive IOLs

Fully refractive multifocal IOLs direct light at different focal points using concentric zones of varying dioptric power within the optic. The optical power depends on the local surface curvature, with regions of differing curvatures achieving different powers within the lens. These IOLs are also called *multizonal refractive IOLs* (**Figure 1**) [59]. The central circular zone has a power corresponding to distance vision. The surrounding annular zones alternate between powers corresponding to near and distance to achieve the multifocal effect [60]. As the pupillary size changes, the number of zones that are utilized varies, and, subsequently, the relative proportion of light directed to the distant, near and/or intermediate focal points changes as well [59]. Thus, image quality can fluctuate depending on pupil size [61, 62].

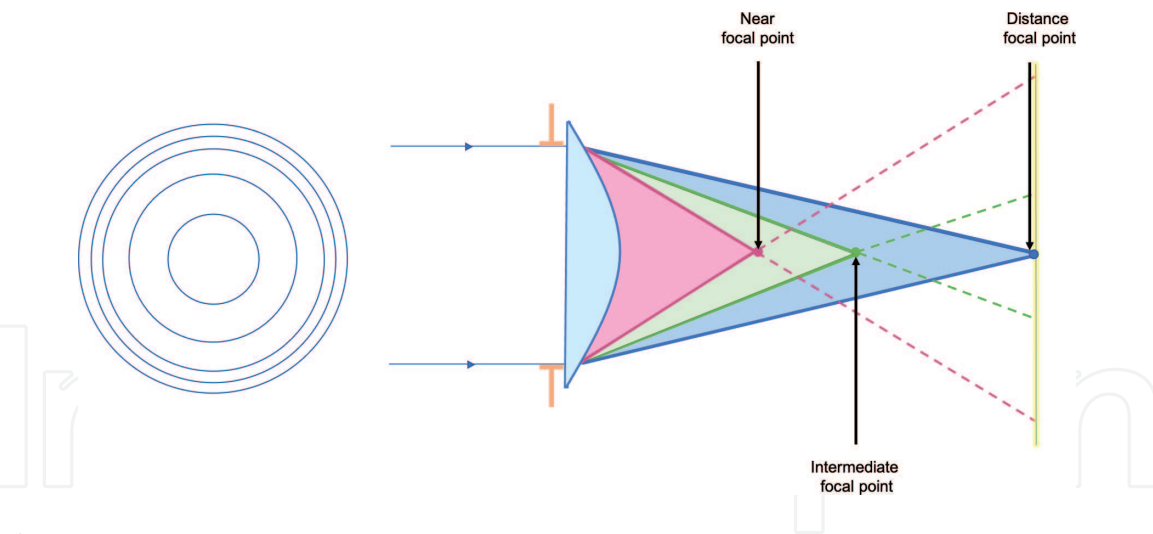


Figure 1.
Refractive IOL design – focal points.

3.2.1.2 Diffractive IOLs

To create multifocality, diffractive multifocal IOLs use the optical phenomenon of diffraction and take advantage of the wave nature of light by selectively delaying the optical path in selected areas and slightly changing its direction when encountering an edge or discontinuity [59–62]. Typical diffractive multifocal IOLs consist of concentric annular zones in their anterior or posterior surface that constitute an asymmetrical zone plate, also referred as “diffractive kinoform” (**Figure 2**) [63]. The spacing between the zones gets progressively smaller from the center towards the edge of the IOL. Abrupt steps appear at the junction of each zone. These microscopic steps on the diffractive surface of the IOL with height of a few microns have a specific phase delay. The area of each zone determines the add power of the IOL and the maximum height of the steps determines the relative amount of light energy distributed on each focus [60, 61]. In fact, the heights of each step are chosen in such a way that approximately 40 – 40.5% of the incident light contributes to the add portion, 40 – 40.5% of the incident light contributes to the distance portion and the remaining light goes into other diffractive foci. Alternative step heights can be chosen to shift more energy to either the distance or near focus. Therefore, the diffractive element of these IOLs enables the splitting of the incoming light into two or three foci for bifocal and trifocal IOLs, respectively [60, 61].

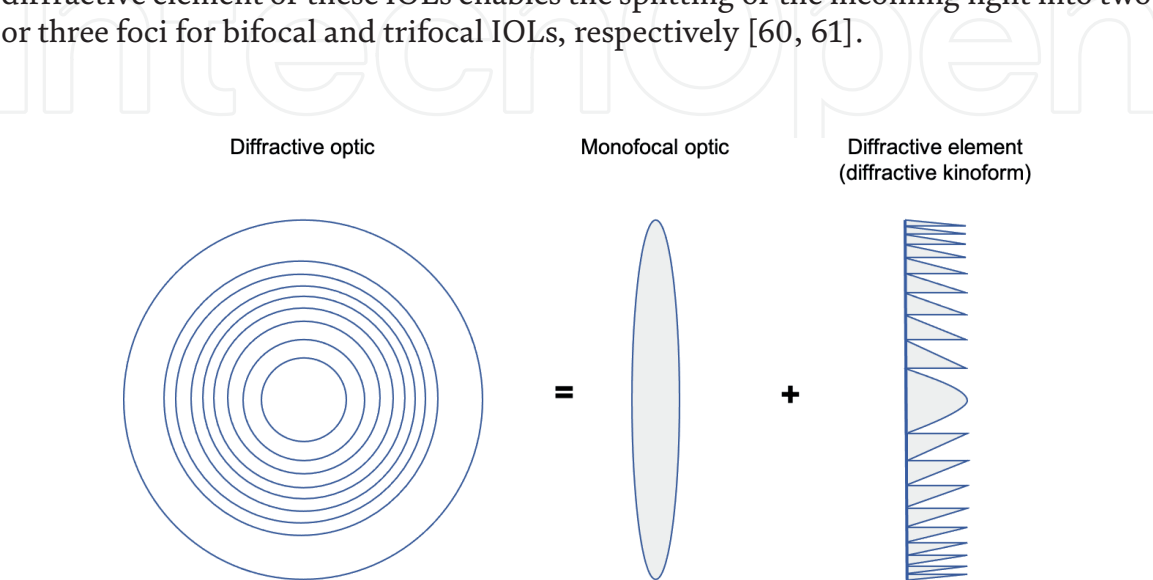


Figure 2.
Diffractive IOL design.

A further division of diffractive multifocal IOLs is based on *apodization*, which is the gradual decrease of the height of the steps from the center of the optic to its periphery [61]. Thus, diffractive IOLs can be classified into those with apodized and those with non-apodized diffractive optics (**Figure 3**).

3.2.1.2.1 Apodized diffractive IOLs

The characteristic of apodized diffractive IOLs is a decrease in height from the taller central to the shorter peripheral steps of the optic [59]. The lower steps of the periphery send more energy to the far and less to the near focal point. On the contrary, the higher central steps send equal energy to distance and near [64]. The clinical significance of this phenomenon is shown by the fact that the larger pupil diameter in scotopic light conditions, when only the distance vision is utilized, allows more energy to be directed to the distance focal point, while the smaller pupil diameter in photopic conditions, when both distance and near vision are utilized, allows energy to be directed equally to distance and near (**Figure 4**) [60, 64]. Additionally, apodized diffractive IOLs produce fewer optic phenomena (eg. glare, halos etc) than non-apodized IOL during distance vision through a large pupil [59].

Some characteristic apodized diffractive IOL models are the following:

- AcrySof IQ ReSTOR SN6AD1 (Alcon Laboratories, Inc., Fort Worth, TX, USA): a single-piece, bifocal, symmetric biconvex IOL with an aspheric diffractive, apodized, anterior surface (+3.0 D near add power at the IOL plane) [65].
- AcrySof IQ ReSTOR SN6AD2 [SV25T0] (Alcon Laboratories, Inc., Fort Worth, TX, USA): a single-piece, apodized, diffractive aspheric bifocal IOL with a central refractive zone (*hybrid IOL*) (+2.5 D near add power at the IOL plane) [66].
- FineVision IOL (PhysIOL, Liege, Belgium): a single-piece, apodized, diffractive trifocal (+1.75 D intermediate and +3.5 D near add power at the IOL plane), aspheric IOL (aspheric posterior surface and diffractive anterior surface) [67].

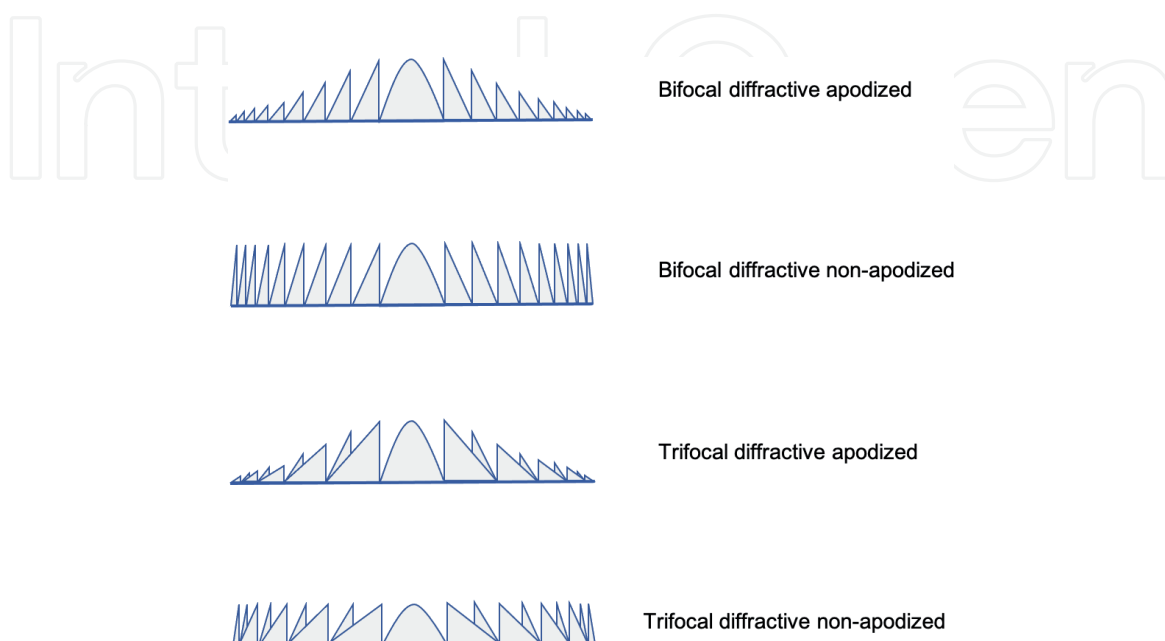


Figure 3.
 Examples of diffractive multifocal IOL designs.

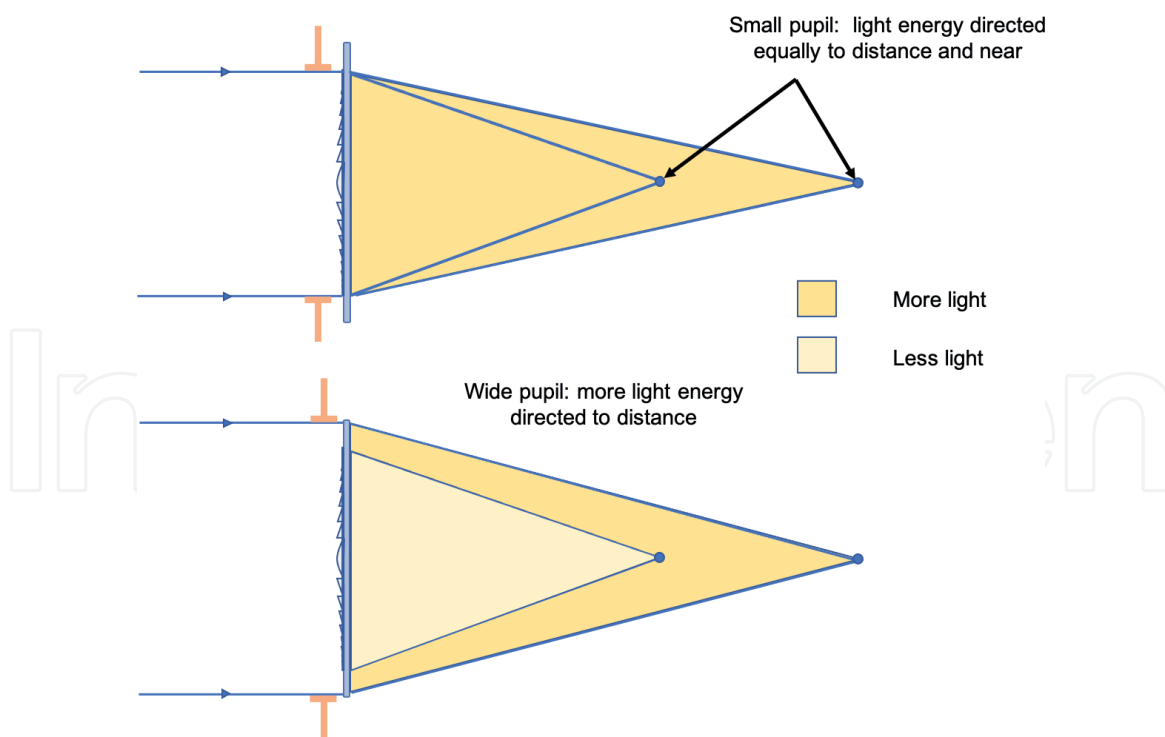


Figure 4.

Light distribution in photopic (A) and mesopic-scotopic (B) light conditions in diffractive apodized IOL designs. (A) The small pupil diameter in photopic conditions, when both distance and near vision are utilized, allows light energy to be directed equally to distance and near. (B) The wide pupil diameter in low light conditions, when only the distance vision is utilized, allows more energy to be directed to the distance focal point.

3.2.1.2.2 Non-apodized diffractive IOLs

In contrast to the apodized IOLs, the diffractive steps of non-apodized diffractive IOLs have uniform height from the center to the periphery. Therefore, these IOLs can distribute the light rays to near and distant focal points in constant proportions, irrespectively of the pupillary size [61, 68]. However, they sacrifice some intermediate vision, and may produce more photic phenomena than apodized diffractive IOLs [62].

Some characteristic non-apodized diffractive IOL models are the following:

- AcrySof IQ PanOptix (Alcon Laboratories, Inc., Fort Worth, TX, USA): a single-piece diffractive, non-apodized, aspheric (spherical posterior surface and aspheric anterior surface with a diffractive surface on the central 4.5 mm), trifocal IOL (+2.17 D intermediate and +3.25 D near add power at the IOL plane) [69].
- TECNIS multifocal IOL (AMO, Santa Ana, CA): a single-piece diffractive, non-apodized, aspheric (aspheric anterior surface, full-diffractive posterior surface), bifocal IOL (ZMB00: +4.00 D / ZLB00: +3.25 D / ZKB00: +2.75 D add power) [70].
- AT LISA 809 IOL (Carl Zeiss Meditec AG, Jena, Germany): a single-piece diffractive, non-apodized, aspheric bifocal (+3.75 D near add power at the IOL plane), biconvex IOL [71].
- AT LISA TRI 839MP IOL (Carl Zeiss Meditec AG, Jena, Germany): a single-piece diffractive, non-apodized, aspheric trifocal IOL (+1.66 D intermediate and +3.33 D near add power at the IOL plane) [72].

3.2.2 Preoperative counseling, preoperative examination and patient selection

Preoperative counseling and patient selection play a pivotal role in the success of pseudophakic presbyopic correction with implantation of mIOLs. It is well known that patients wishing to undergo presbyopic correction have high expectations for their visual and refractive outcome. Thus, it is common that some patients with a visual acuity of 0.0 logMAR are not fully satisfied usually due to photic phenomena at scotopic or mesopic light conditions (e.g. during nighttime driving) and difficulty in reading of very small letters or small letters under lower lighting levels. Some possible reasons of dissatisfaction are potential optical aberrations, residual astigmatism, large pupil and slow or no neuroadaptation [13]. For this reason, a good counseling and a thorough preoperative examination should be an integral part of the preoperative patient management for the best possible patient selection and determination of patient's expectations.

3.2.2.1 Clinical factors/exclusion criteria, contraindications

Before the discussion between patient and surgeon for an eventual pseudophakic presbyopic correction with implantation of a mIOL, a detailed patient history should be taken and a first general ophthalmologic examination (VA, slit-lamp biomicroscopy, IOP measurement) should be performed, which might reveal some clinical parameters that could rule out this type of surgery; among them, significant preexisting ocular pathology that could reduce the postoperative visual outcome, severe untreated dry eye disease, Fuch's endothelial dystrophy or other corneal dystrophies, keratoconus, corneal scars, macular degeneration, diabetic retinopathy or other retinal disease, advanced glaucoma or other optic nerve diseases, and amblyopia. In addition, mIOLs should be avoided in patients with pupillary abnormalities such as corectopia and colobomas, as well as in patients with phacodonesis zonular dialysis or pseudoexfoliation due to the high risk of IOL decentration [61, 64].

3.2.2.2 Patient factors/preoperative counseling

The history taking and the general ophthalmologic examination should be followed by a detailed preoperative counseling. As part of the counseling, each patient should be warned about the risks of the lens extraction surgery, but also for the specific risks of the implantation of a mIOL. The selection of both the proper patient and the proper mIOL results in high patient satisfaction rates. Specifically, the following aspects should be discussed:

The determination of each patient's personality type, lifestyle, hobbies, needs, occupation, and expectations should not be omitted.

- *Personality:* Surgeons should be cautious about selecting patients with a type A personality. Specifically, patients with neurotic personality traits are less likely to be satisfied with the postoperative outcome in comparison with patients whose dominant personality trait is conscientiousness and agreeableness [73]. Additionally, the personality characteristics of compulsive checking, orderliness, competence, and dutifulness have found to be related to subjective disturbance by glare and halos [74].
- *Lifestyle, hobbies, needs:* Patients who read a lot may benefit more from a mIOL that provides better near vision, while patients who use a computer may benefit more from a mIOL that provides better intermediate vision. Trifocal IOLs would be a good solution for patients that need both near and intermediate

vision [64]. In addition, patients who drive at night for long periods of time should not be considered as good mIOL candidates.

- *Occupation:* Patients with high occupational visual demands such as pilots and commercial (public service vehicle, taxi, or truck) drivers should be avoided from mIOL implantation [13, 61].
- *Expectations:* Hypercritical patients with unrealistic expectations are not suitable candidates for mIOL implant. For instance, people whose main concern is the sharpest clearest vision and who do not mind wearing near glasses even when reading very small letters or under low lighting conditions, should be ruled out from insertion of mIOLs.

The surgeon should never promise full spectacle independence, but they should explain to patients that there is a good chance that they will not need glasses for the majority of their activities of daily living and that no perfect IOL to simulate their pre-presbyopic continuous vision exists yet [61]. However, spectacles may be needed under highly demanding conditions or during reading under low lighting conditions. Additionally, patients should be counselled about the optimal level and direction of light for easier reading. Finally, patients should be counselled about adverse events including halo, glare, reduced contrast sensitivity as well as discussing neuroadaptation in greater detail [75]. If patients are able to understand all benefits and risks of mIOLs, they could be good candidates to continue the preoperative examination for a potential pseudophakic presbyopic correction with mIOL implantation.

3.2.2.3 Preoperative examination and patient selection

Some significant parameters that should be taken into account during *preoperative examination* for the patient selection for mIOL implantation and, then, for the selection of the appropriate type and power of the IOL are the following:

- *Optical biometry:* Careful biometry is crucial to accurate IOL power calculation and astigmatism management, since inaccurate biometry is the most common cause of residual refractive error postoperatively [76]. Third generation formulas such as the Holladay [77], SRK/T [78] and Hoffer Q [79] provide good outcomes for patients with average AL (22 – 25 mm) and keratometry. In cases of short eyes (AL < 22 mm) with a shallow ACD (< 2.40 mm), formulas that take preoperative ACD into account, such as Haigis, or alternatively Hoffer Q, could be used [80–82]. When dealing with long eyes (AL > 25–26 mm), SRK/T (with optimized constants), is still an accurate solution [83]. Haigis (with optimized constants) is accurate especially for eyes with AL < 30 mm [84]. Finally, new formulas such as Barrett Universal II and Olsen provide good results in long eyes [82, 85].
- *Dense cataract:* In case of dense cataracts when optical biometry measurements have low accuracy, the repetition of measurements could increase the accuracy in IOL power calculation. When no measurements can be taken, A-scan ultrasound biometry can be used. However, since the accuracy of this method is lower than the accuracy of optical biometry, [86–88] and taking into account that even a residual refractive error of 0.50 D, especially in mIOL implantation, can reduce the vision quality and increase photic phenomena, [89–91] the surgeon should be cautious with the choice of the mIOL or even with the decision for a possible

non-mIOL pseudophakic presbyopic correction when an ultrasound biometry is used for the IOL power calculation. The surgeon should discuss with the patient the risks caused by the measurement inaccuracy, and may choose an alternative surgical solution according to patient's visual needs and lifestyle.

- *Corneal astigmatism:* Patients undergoing multifocal IOL implantation may not tolerate residual astigmatism of > 1 D or even 0.75 D according to some studies, and a toric multifocal IOL may be required in such cases [92]. For the best possible calculation of the corneal astigmatism, the performance of more than one keratometry technologies is suggested, since no perfect method is available [13]. Ideally, rotary prism technology (auto-keratorefractometers), PCI, corneal Scheimpflug tomography (which also takes into account posterior corneal astigmatism) or Placido-based corneal topography, and keratometry taken by image-guided systems for lens extraction surgery could be used [16]. In case of agreement in corneal cylinder power and axis among the utilized technologies, the surgeon can safely choose the appropriate common cylinder power of the toric IOL and the alignment axis. If the different methods of measuring corneal cylinder produce inconsistent results, the treatment of the ocular surface should be considered and the measurements should be repeated. In addition, the proper patient positioning should be confirmed [93]. Online calculators are also available for the toric/multifocal toric IOL power calculation with very good results because most of them take IOL power and posterior corneal astigmatism into account [94].
- *Pupillary size:* Pupil size, but also pupil position in relation to the near and distance zones of the lens, seem to affect the optical performance of the implanted mIOLs in terms of VA, optical aberration, diffraction, and retinal luminance. Patients with wide pupils in scotopic light conditions who were implanted with mIOLs have a higher risk of poor postoperative contrast sensitivity under mesopic illuminance levels and optical phenomena such as glare, halos, and starbursts [95]. In fact, large pupil size is one of the most common causes of dissatisfaction and photic phenomena in patients with mIOLs [96–98]. Therefore, the pupillary size under photopic and mesopic light conditions before mydriasis must be determined preoperatively to minimize subjective postoperative side effects [95]. Everyday clinical practice has shown that a mesopic pupil size smaller than 5 mm can minimize photic phenomena. In case of pupil size larger than 5 mm, the surgeon should discuss with the patient the risks for dysphotopic phenomena and decide whether to proceed with the multifocal IOL implantation or not depending on the patient's visual needs and lifestyle. An alternative surgical solution could be proposed if multifocal IOLs are excluded. Nevertheless, in all cases regardless of the pupil size, patients should be informed about the possibility of appearance of some optical phenomena which, however, may be reduced with time through the process of neuroadaptation [99].
- *Visual axis, angle kappa:* In pseudophakic presbyopic corrections with implantation of mIOLs, the angle kappa (misalignment between the visual and pupillary axis) [100] should be taken into consideration, especially for hyperopic patients with a large angle kappa [101, 102]. It has been found that large angle kappa is correlated with more glare and halos after implantation of mIOLs [86, 103]. This happens because when decentration of mIOLs is present (intraoperatively or postoperatively), which is more common in eyes with large angle kappa, the light rays pass through a multifocal ring instead of the central optic zone, resulting in glare and halos [104]. Decentration higher than 0.75 mm

irrespectively of IOL design has shown both far and near visual function deterioration [96, 105]. Clinical practice and research has shown that inclusion of patients with an angle kappa and angle alpha < 0.5 mm, ideally < 0.3 mm, (primarily in vertical and secondarily in horizontal axis in the Cartesian coordinates plot) both in mesopic and photopic conditions of illumination can minimize the risk for mIOL decentration and postoperative photic phenomena [103]. On the other hand, when angle kappa and angle alpha are > 0.5 mm, multifocal IOLs should be avoided, and monofocal IOLs for binocular distance vision or monovision could be chosen [106].

- *Pupil center shift (PCS):* It has been found that not only the photopic kappa angle, but also the PCS is associated with dysphotopsia after mIOL implantation [102]. In case of patients having a PCS higher than 0.4 mm, surgeons should decide whether the optical zone of mIOL should be centered on the photopic or mesopic/scotopic pupil center. In fact, when interpolated (from photopic 2 mm to scotopic 7 mm pupil) PCS is higher than 0.7 mm, the implantation of mIOLs should be avoided and other types of IOLs should be preferred [34].
- *Aberrations – ocular scattering:* Although aberrations, such as coma, SA or first order astigmatism, contribute to the enlargement of the depth of focus, they can also result in a decrease in contrast sensitivity and quality of vision. For instance, it has been found that anterior corneal coma values higher than 0.32 or 0.33 mm may create intolerable photic phenomena when a diffractive mIOL is implanted, thus contraindication of mIOL implantation has been suggested in higher coma values [13, 107, 108]. Additionally, since angle kappa [109] and PCS [110] can influence ocular aberrations, they should also be co-evaluated with ocular aberrations in order to provide patients with the best possible vision quality. Apart from aberrations, ocular scattering may have an impact on the quality of retinal image, which may be overestimated when only aberrations are taken into account. Therefore, measurement of both aberrations and ocular scattering could contribute to a more accurate assessment of the visual and optical quality [111].
- *Dry eye disease:* Since dry eye disease and cataract are very common in the elderly population, but also the ocular surface and tear film play a significant role in the quality of vision, dry eye disease treatment should be considered as an integral part of the pre- and postoperative patient's management. It is well known that dry eye may reduce the vision quality after mIOL implantation [112]. Additionally, it has been observed that cataract surgery is also responsible for causing dry eye disease or aggravating existing dry eye symptoms [113, 114]. Therefore, artificial tears and eyelid hygiene, but also cyclosporine or autologous platelet-rich plasma (PRP) in more severe cases, should be used pre- and/or postoperatively [112, 115, 116].
- *Previous corneal refractive surgery:* Particular attention should be given to patients who have undergone a prior corneal refractive surgery and are considering a pseudophakic presbyopic correction with mIOL implantation.
 - It is assumed that corneas which have undergone a refractive surgery such as laser in situ keratomileusis (LASIK), photorefractive keratectomy (PRK) or radial keratotomomy (RK), have been rendered multifocal and show many

aberrations by the laser procedure. As a result, it also assumed that the implantation of a mIOL would further deteriorate the visual function.

- An additional difficulty is the inaccuracy in IOL power calculation that comes from the inaccuracy in the determination of the total corneal refractive power, [64, 117] and the inaccuracy in the estimation of the effective lens position by various IOL power calculation formulas when post-laser corneal powers are used [64, 118].
- Patients having corneas with irregular astigmatism, or more than 1 micron of higher corneal aberrations (HOA), especially if they are caused by high levels of coma, are not good candidates for mIOLs [64]. In addition, eyes with a large pupil (> 4 mm) have more possibilities to appear photic phenomena caused by existing aberrations in comparison with eyes with a small pupil (< 4 mm). As a result, a poorer visual quality under mesopic or glare conditions may occur [119].
- Although mIOLs are usually well tolerated and effective after corneal refractive surgery, refractive surprises can be common, especially in patients with myopia greater than 6.0 D or in those that have undergone LASIK [120, 121]. To increase the refractive predictability and reduce the risk of a suboptimal refractive outcome, the precise IOL power calculation is of paramount importance. Since keratometers are unable to measure accurately K values of the central post-laser cornea and the outer and inner corneal surfaces may change unpredictably after corneal refractive surgeries, a variety of IOL power calculation methods have been suggested [64]. The most accurate method is the *clinical history method*. To apply this method and calculate the central corneal power, the refractive error (spherical equivalent) and the K values prior to the keratorefractive surgery as well as the stable refractive error after the surgery must be available [122, 123]. Apart from the numerous methods and formulas that are available, some online calculators can also be used complementarily for the IOL power calculation [124–126].
- In general, patients that had a previous keratorefractive surgery and want to have an additional pseudophakic presbyopic correction with mIOLs have high expectations for spectacle-free good vision [127]. However, they should always be informed for the possibility of inaccurate measurements, residual refractive error, hyperopic shift, and/or aberrations resulting in photic phenomena especially in mesopic light conditions [128]. Additionally, the surgeon should explain to patients that there is a possibility that they will need to use a miotic agent postoperatively, especially in mesopic and scotopic light conditions, in case of photic phenomena, [129] and that an additional corneal refractive surgery or even a further surgery for exchanging the mIOL may be needed in the future [130]. Ideally, if the corneal surface is irregular with corneal aberrations and a second laser treatment is necessary to correct this irregularity, such a treatment should be better performed prior to the implantation of the mIOL [130].

3.2.3 Surgical technique

Phacoemulsification is the gold standard technique for cataract surgery and refractive lens exchange. Since mIOL implantation requires high precision and various factors should be taken into consideration, in addition to the common ones for the conventional cataract surgery with monofocal IOL implantation, a variety

of parameters for the conventional non-image-guided, but also for an image-guided surgical technique, will be discussed in the text below.

For the best possible refractive outcome during mIOL implantation surgery, the following practices are suggested:

3.2.3.1 Conventional non-image-guided surgical technique

- Topical anesthesia and mydriatic drops are instilled before the operation.
- Periorbital skin, eyelids, and the conjunctival sac are prepared with a solution of iodine povidone.
- The surgical technique is performed using a standard technique of sutureless (commonly 2.2-mm) cataract surgery.
- Intracameral anesthesia and potentially intracameral mydriatics are injected.
- Capsulorrhexis should have a diameter between 4.50 to 5.00 mm. Although a diameter larger than 5.00 mm also is recommended to facilitate nuclear and cortical removal, this increases the risk of postoperative optical phenomena caused by the involvement of more concentric rings when the light rays pass through the IOL's optic. Opacification of the remaining anterior capsule can reduce optical phenomena even in eyes with a pupil diameter larger than 5.00 mm (**Figure 5**).
- Another parameter that should be taken into account, especially in eyes with a large angle kappa, is the centration of capsulorrhexis. The capsulorrhexis is suggested to be centered around the microscope light reflection on the anterior capsule (patients' visual axis) rather than around the pupillary axis [131]. However, in the case of a mature cataract where the patient fails to fixate on the microscope light, but also on the lights of the biometry device during the preoperative examination, the implantation of a mIOL should be avoided, since the risk for a decentered implantation is very high. The centration on the pupil center or on the geometric center of the cornea is not considered as a safe alternative solution.

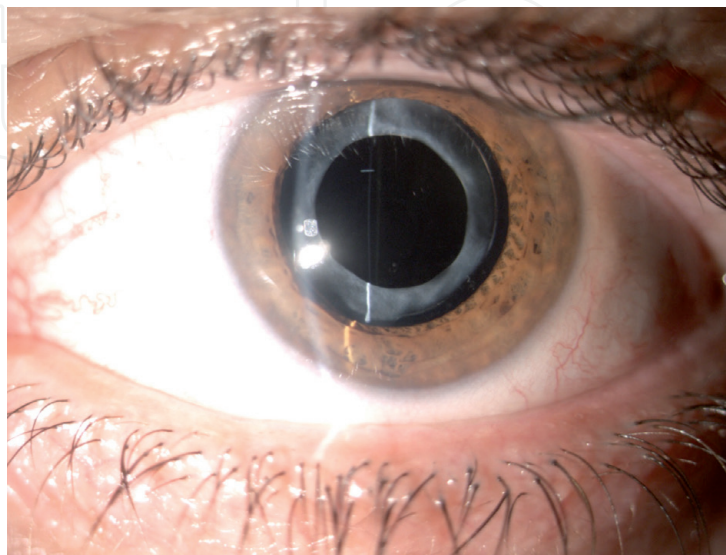


Figure 5.
Anterior capsule opacification following multifocal intraocular lens implantation: the opacification of the remaining anterior capsule contributes in the reduction of potential optical phenomena.

- The nucleus is aspirated with or without ultrasound phacoemulsification energy according to the hardness of the crystalline lens, and residual cortex removal and posterior capsule polishing are performed using commonly bimanual irrigation/aspiration.
- The mIOL is always inserted into the capsular bag through the main incision. The IOL should be injected directly in the capsular bag in order a possibly traumatic surgical manoeuvre to be avoided. For this reason, adequate dilation and an adequate capsulorrhexis of about 4.50 to 5.00 mm is necessary.
- For the optimal mIOL centration and the minimization of photic phenomena, especially for eyes with a large angle kappa, the mIOL is suggested to be decentered towards the visual axis, namely to be gently moved so as the microscope light reflex to fall within the central ring of the multifocal pattern [102]. This is an easy intraoperative manipulation that can effectively result in the desired centration on the visual axis. The centration of diffractive mIOLs on the visual axis is critical to their optimal performance. However, refractive mIOLs are also suggested to be centered on the visual axis because severe cases of decentration can increase the lens' effective power and induce astigmatism and dysphotopsia.
- Additionally, since, normally, the visual axis is nasal to the optical center (the geometric center of the cornea, crystalline lens, and bag after nuclear and cortical removal), positioning the haptics of especially diffractive, but also refractive, IOLs at the 12 and 6 o'clock position may facilitate the desirable nasal displacement of the IOL optic. On the other hand, positioning the IOL haptics horizontally leads to the return of IOL to the geometrically horizontal center [131].
- To stabilize the mIOL centered on the visual axis during the first postoperative days, in contrast to the literature, the authors suggest that a minimal amount of cohesive ophthalmic viscosurgical device (OVD) could be left in the capsular bag without increasing the risk for elevation of the postoperative IOP [132].
- Since mIOL patients usually benefit from having a small pupil, eyes with a small pupil after the instillation of mydriatics before the cataract surgery should be managed with special caution in order the pupil to remain functionally and morphologically intact, as in its preoperative status. Therefore, it is strongly recommended to cataract refractive surgeons to avoid surgical maneuvers such as synechiolysis, pupil stretching, iris cutting [133] and the use of mechanical devices such as iris hooks and pupil expansion rings (e.g. Malyugin ring etc.) because of the high risk of intraoperative disruption of the pupillary sphincter and postoperative pupil enlargement [134]. Thus, intracameral administration of mydriatic agent, combined intracameral use of mydriatic agent and local anesthetic or the injection of OVD into the anterior chamber (viscomydriasis) should be preferred for the pupil dilation [134]. For an experienced refractive cataract surgeon, a possible threshold of pupil size for a successful phacoemulsification ranges between 4.5 and 5.0 mm [134, 135]. In smaller pupils which cannot be dilated pharmacologically or with OVD use, the surgeon should weigh the benefits and the risks of the pupil dilation with surgical manoeuvres and mechanical devices and should consider the implantation of a non-mIOL.

- Videorecording of every surgery is suggested for refractive cataract surgeons and, generally, for ophthalmic surgeons in order to review their surgeries, criticize their technique, find mistakes that should have been avoided, explain unexpected outcomes and improve their surgical skills [136].

3.2.3.2 Image-guided surgery

Although the experience and the surgical skills of the refractive cataract surgeon play the most significant role in the final refractive outcome, image-guided lens extraction surgery, which has been recently introduced in phacoemulsification, can increase the surgical accuracy, decrease the risk of complications such as postoperative astigmatism, IOL decentration and photopic phenomena and improve the patient's quality of vision [41].

Image-guided systems such as Verion Digital Marker (Alcon Laboratories, Inc., Fort Worth, TX, USA) [137] and Zeiss Callisto Eye (Carl Zeiss AG, Dublin, CA) [138] are commonly used for the implantation of multifocal toric IOLs. However, since the high accuracy is also necessary during the implantation of multifocal non-toric IOLs for main and sideport incisions, the centration and the diameter of capsulorrhexis, as well as for the centration of the mIOL implantation, the authors suggest that digital image-guidance also during the implantation of multifocal non-toric IOLs could optimize the surgical accuracy and predictability, minimize the risk of complications, and maximize the refractive outcome. **Figure 6** presents the basic steps of lens extraction surgery (a. sideport incisions, b. main incision, c. capsulorrhexis, d. IOL centration, e. finalization) using the Verion image-guided system during the implantation of a multifocal non-toric IOL.

3.2.4 Complications

Implantation of mIOLs provide patients with a good visual acuity at more than one focal point depending on mIOL design. Patient satisfaction levels after mIOL implantation are high. However, the same characteristics that offer refractive correction at all distances can result in adverse effects at the same time [98].

For instance, light distribution mechanisms split the light to two or three focal points. As a result, less amount of light from each focal point reaches the retina worsening the contrast sensitivity, especially in mesopic light conditions [98, 139]. Therefore, two or three distinct images are produced, one sharp on focus and one blurred out of focus. The light of the latter image reduces the detectability of the on-focus image, resulting in the lower contrast sensitivity, however within the normal range of age-matched phakic individuals, and in the creation of dysphotopic phenomena such as halos [139–141]. These phenomena commonly diminish over time through the process of neuroadaptation.

The most common reason for patient dissatisfaction is *blurred vision* (approximately in 95% of the dissatisfied patients) caused by residual ametropia/astigmatism [98] or posterior capsular opacification (PCO), [97] although these subjective complains usually do not correspond to the objective VA [98, 142]. An additional cause of dissatisfaction is *dysphotopsia*, which is caused by the IOL itself or/and by a potential IOL decentration or IOL tilt or/and by a large pupil diameter. Refractive mIOLs appear to be related with higher levels of photic phenomena than diffractive mIOLs [143, 144]. Moreover, the existence of *dry eye disease* postoperatively found to be one of the patient complaints resulting in symptoms of discomfort, visual disturbance, and tear-film instability. Finally, *IOL explantation* has been reported in

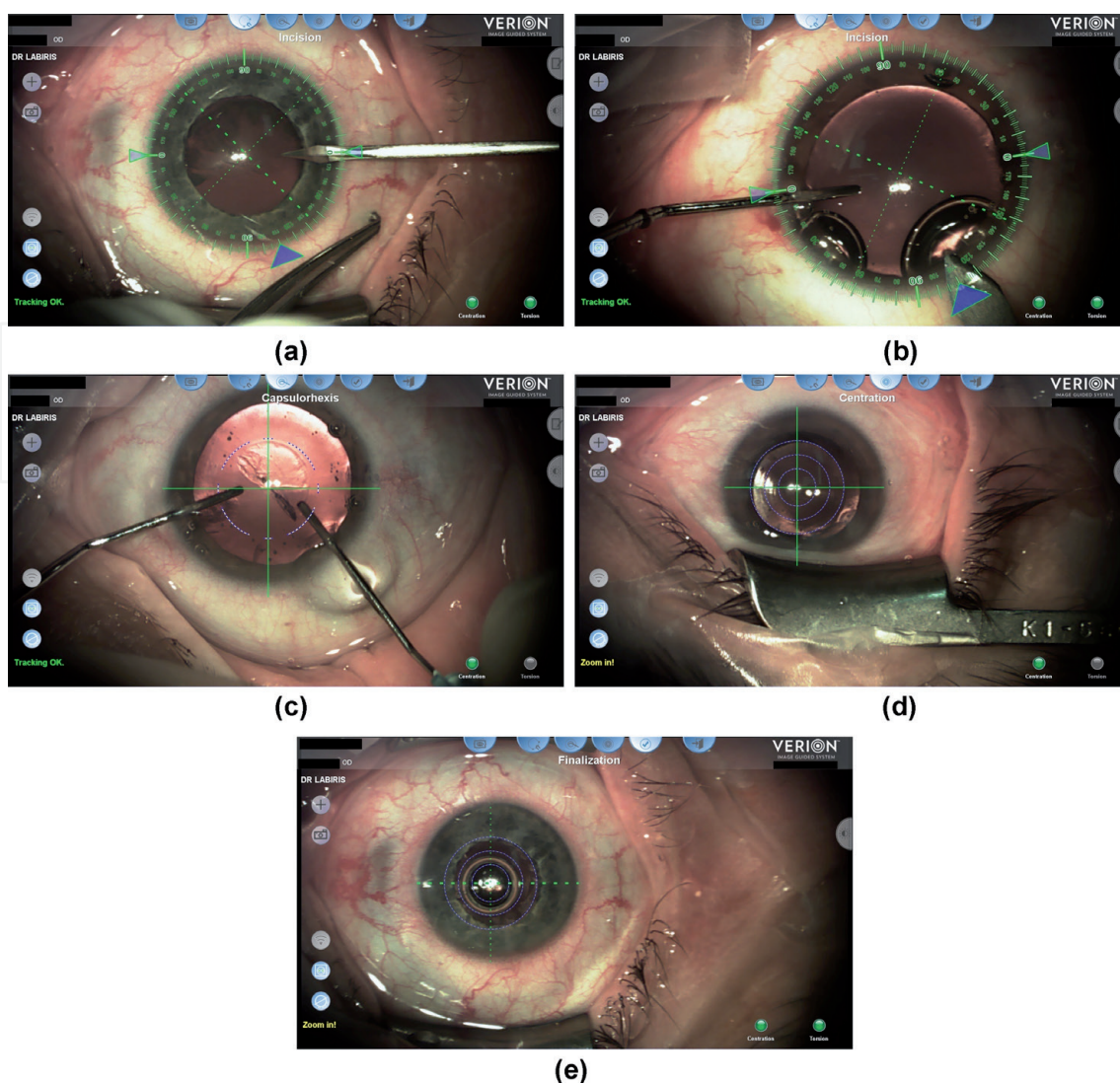


Figure 6.
 The basic steps of multifocal IOL implantation using the Verion image-guided system ((a) sideport incisions, (b) main incision, (c) capsulorhexis, (d) IOL centration, (e) finalization).

a frequency between 0.85% and 7 % [98, 145, 146] due to IOL dislocation, refractive error, PCO, failure to neuroadaptation [147] and, rarely, loss of normal color perception [148].

3.3 New IOL technologies for presbyopic correction

Apart from monovision technique with bilateral implantation of monofocal IOLs and bilateral implantation of multifocal IOLs, accommodative and EDOF IOL, as well as a combination of different IOL types and designs are some new alternative solutions of pseudophakic presbyopic correction. However, these options are beyond the scope of this chapter and they will not be analytically described.

3.3.1 Accommodative IOLs

Accommodative IOLs (aIOLs) are designed to simulate the mechanism of accommodation of the crystalline lens, which is capable of changing dynamically its dioptric power with accommodating effort, namely by modifying its shape after contraction of the ciliary muscle and providing functional vision at different distances [149].

AIOLs are still a developing field in the technology of premium IOLs where a variety of designs are still examined [150]. The mechanisms of action of the different types of aIOLs that are currently available are based on the three following principles: (a) change in axial position (i. single-optic aIOLs, and ii. dual-optic aIOLs), (b) change in shape or curvature, and (c) change in refractive index or power. Apart from the aforementioned aIOL designs, the following new design strategies of aIOLs, still in preclinical stage, have been proposed: (i) lens-filling aIOL techniques, and (ii) electroadaptive aIOLs [149, 151]. Another issue that remains to be solved is the best location for implantation of aIOLs. Implantation inside the capsular bag seem to be a less successful approach in comparison to the sulcus, since in sulcus, the dynamics from the ciliary body induce further movements of the IOL [149, 150].

Despite the significant development and evolution of aIOLs and the great variety of IOL designs, the majority of them are still in a development process and have shown some contradictory clinical data about their efficacy. The optimal aIOL with a broad range of accommodation still remains elusive, and different challenges exist for each lens design. However, new innovative and promising designs and technologies now exist having the restoration of accommodation as their common goal [149, 151].

3.3.2 Extended depth-of-focus (EDOF) IOLs

Extended depth-of-focus (EDOF) IOL is a new technology in the treatment of presbyopia-correcting IOLs. The basic optical principle of EDOF IOLs is to create a single elongated focal point, in contrast to monofocal IOLs, in which light is focused on one single point, and mIOLs, in which light is focused on two or three discrete points (**Figure 7**). In this way, EDOF IOLs eliminate the overlapping of far and near images caused by mIOLs, thus eliminating the halo effect. Specifically, EDOF IOLs provide a continuous focus range that extends from the far focus area until the intermediate distance, without the clearly asymmetric IOL power distribution that is provided by the mIOLs. In this way, EDOF IOLs avoid the presence of secondary out-of-focus images that originates the halos [152–154].

The idea of EDOF was first reported in 1984 by Nakazawa and Ohtsuki who measured an apparent 2.00 D accommodation in 39 pseudophakic eyes implanted with posterior chamber spherical IOLs and found a significant correlation between apparent accommodation and depth of field. This correlation was inversely proportional to the pupillary diameter [155]. After using multiple cornea- or IOL-based strategies, the first EDOF IOL (Symfony, Johnson and Johnson Vision, Jacksonville, FL) was introduced into the market receiving the European Economic Area

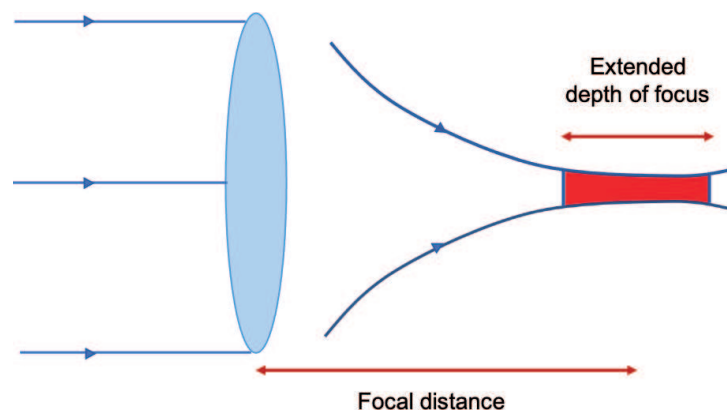


Figure 7.
EDOF IOL design.

certification mark in June 2014, and being approved by the United States Food and Drug Administration (FDA) in July 2016 [156].

Since then, a variety of EDOF-labeled IOLs have been released in the market and are based on the following 3 optical models: i) spherical aberration, ii) chromatic aberration, iii) pinhole effect, all of which allow obtaining greater depth of focus [157]. Apart from the pure EDOF IOLs, there are some IOLs that combine multifocality with low addition power and the EDOF technology, the so-called “hybrid IOLs” [157]. In general, EDOF IOLs provide better optical quality in comparison with monofocal and multifocal IOLs [158–160]. Additionally, EDOF IOLs provide high uncorrected intermediate vision, but inadequate near vision [161, 162], thus allowing a relative spectacle independence. A potential disadvantage of EDOF-IOLs is a decreased quality of retinal image if the aberrations are excessively increased. Finally, contrast sensitivity, glare and halos vary depending on the EDOF-IOL technology, however, they seem to be better when compared to mIOLs. [163] Since the literature results about the optical performance of EDOF-IOLs are promising but contraindicating, [164–166] new large-scale studies need to be performed.

In any case, patients should be counseled about potential photic phenomena and the need for low power reading spectacles postoperatively. Moreover, the IOL type decision should be made depending on their profile and preferences.

3.3.3 Monovision techniques with combination of IOLs

When a large anisometropia is targeted for an optimal near visual acuity, pseudophakic monovision with implantation of monofocal IOLs results in a relative decrease in near stereopsis [49, 153]. Therefore, a new type of monovision with implantation of different IOL types and IOL technologies in each eye has been introduced. For instance, the implantation of a monofocal IOL in the dominant eye and a premium lens such as mIOL (bifocal or trifocal/refractive, diffractive or hybrid diffractive-refractive) [167, 168] or EDOF IOL in the recessive one, the so-called “hybrid monovision” or “mix and match” or “blended vision”, has been applied and compared with the conventional myopic monovision techniques and with the binocular implantation of premium IOLs showing promising visual outcomes [153, 154, 169]. Additionally, the use of a refractive IOL in the dominant eye and a diffractive IOL in the recessive eye [170] or vice versa [171] has been reported showing very good visual outcomes including impressive spectacle independence at all distances and a contrast sensitivity being comparable with phakic patients. In general, it seems that hybrid monovision offers spectacle-free postoperative visual capacity at all distances with minimal optical phenomena.

4. Postoperative examination – follow-up

Apart from the full preoperative examination and the high-precision surgery that are necessary for optimal refractive outcomes in patients undergoing a pseudophakic presbyopic correction, especially with mIOLs, the postoperative follow-up plays an equally significant role in the best possible results. The most common follow-up timepoints are 1 day, 1 week, 1 month, 3 months, 6 months, 1 year, 2 years and so forth. Examination at the first postoperative day is commonly applied by many surgeons. However, the current literature supports that first-day examination after an uneventful phacoemulsification surgery is not necessary when patients have not posterior synechiae or chronic/recurrent uveitis and they are operated by experienced cataract surgeons. Thus, healthcare costs can be decreased without an increased risk to the patients [172].

A comprehensive postoperative examination should include primarily history, VA assessment, automatic (with auto-refractor) and manifest refraction, slit lamp biomicroscopy and IOP measurement. However, some additional examinations should be performed for the best possible evaluation of the visual performance and optical quality of vision, including defocus curves, contrast sensitivity assessment, corneal topography, aberrometry, pupillometry, and halometry or retinal straylight, if halos, glare and other photic phenomena are present [173]. Finally, patient satisfaction and potential photic phenomena should be assessed by history taking or, more specifically, through special quality of vision questionnaires [174–176]. Among them, some important aspects that should be taken into consideration are the following:

- *Visual acuity and refraction:* UDVA, BCDVA, UNVA, BCNVA, UIVA, and BCIVA should be included in the postoperative examination. Near and intermediate vision should be ideally evaluated with logarithmic printed or digital reading charts that evaluate not only reading acuity (RA), but also the maximum reading speed (MRS) and the critical print size (CPS), namely the smallest print size that can be read with the MRS [177–180]. *Defocus curves* could also be obtained. Apart from the manifest refraction, an auto-kerato-refractometer should be used.
- *Contrast sensitivity:* Contrast sensitivity under photopic and mesopic light conditions should ideally be assessed.
- *Slit lamp anterior segment examination:* Apart from the evaluation of the cornea (Seidel test, clarity), the anterior chamber (depth, inflammatory activity), and the pupil (shape, reactivity), in case of mIOL implantation, the centration of the mIOL should also be checked. Specifically, the coaxially sighted IOL light reflex (CSILR) should be identified by placing the slit illuminator in a coaxial position with the microscope, adjusting the narrow slit beam to a small rectangle and asking the patient to fixate on the slit lamp light. The light reflection on the mIOL indicates the position of the CSILR, which coincides with the visual axis, and ideally should fall on the central mIOL optic zone if the mIOL centration has been done according to the visual axis (**Figure 8**) [131].
- *Corneal topography and aberrometry:* Corneal topography and aberrometry are suggested to be performed postoperatively, since they might reveal potential residual astigmatism and aberrations, especially in case of postoperative dysphotopic phenomena at scotopic or mesopic light conditions.
- *Pupillometry:* Postoperative pupil diameter at photopic and mesopic light conditions and PCS are suggested to be measured, especially after implantation of mIOLs, in order potential dysphotopic phenomena to be explained and correlated with the objective pupil measurements.

As regards the surgery schedule of the fellow eye for a pseudophakic presbyopic correction, different factors described below should be taken into consideration:

- *Postoperative visual capacity (VA, reading speed, stereoscopic vision, dysphotopsia) and patient satisfaction:* After a successful lens extraction surgery, the surgeon should wait long enough for the patient's refraction to be stabilized and for the neuroadaptation process to take place, especially in case of dysphotopic phenomena. After this period of time, which can differ for each patient and each IOL design, [74] the surgeon could choose if and when the operation of

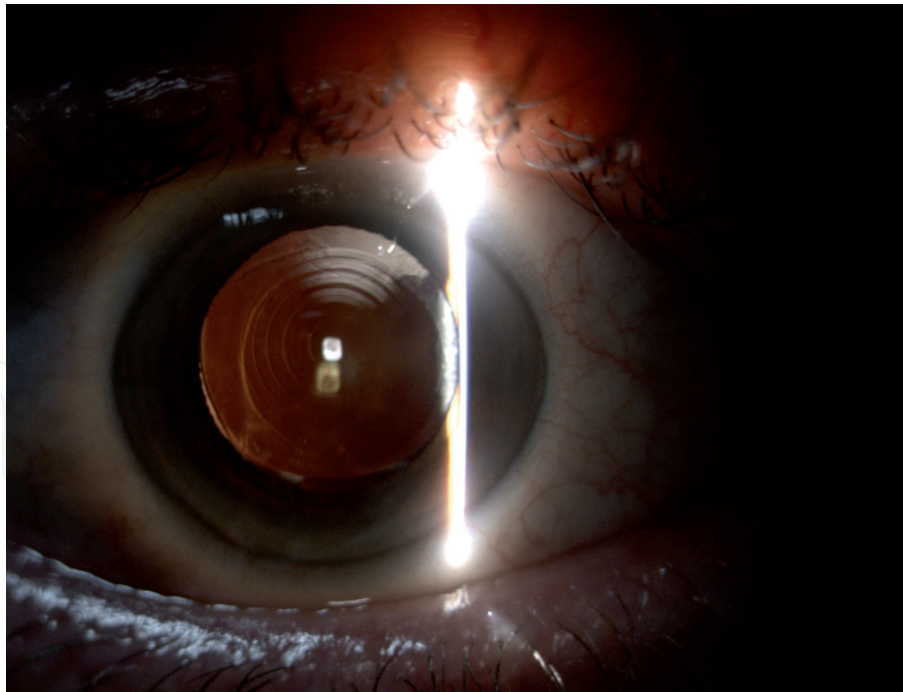


Figure 8.
Identification of the coaxially sighted IOL light reflex through slit lamp biomicroscopy following a multifocal IOL implantation.

the fellow eye could be performed, and the IOL design, as well. In addition, in case of patient dissatisfaction, the cause of dissatisfaction should be identified. If dysphotopsia or suboptimal near vision are the most serious patient's complaints, the surgeon should consider if the implantation of a different IOL design with fewer photic phenomena or with a near focus point could be the best option.

- *Patient's desire or not for lens extraction surgery at the fellow eye*
- *Crystalline lens clearance of the fellow eye:* In case of a clear crystalline lens, especially in young patients with unilateral cataract with a non-presbyopic fellow eye, the fellow eye may not require a lens extraction surgery for years or decades after the surgery of the first eye [181]. In fact, young people with a clear crystalline lens of the fellow eye seem to benefit from the avoidance of the fellow eye surgery, since the smooth transition among distant, intermediate and near vision that is provided by their clear non-presbyopic crystalline lens could not be equally replaced by an artificial IOL.

5. Conclusions

Pseudophakic presbyopic correction is now established as a safe and effective surgical method for the treatment of presbyopia, especially when it is combined with cataract. Pseudophakic presbyopic correction with monovision techniques, implantation of mIOL, aIOL or a combination of IOL designs is also related with excellent visual outcomes, improvement in vision and life quality, and high patient satisfaction. Rapid technological advances have led to an increase in the number of the available IOL technologies and presbyopia correction techniques. Additionally, advances and innovation in imaging and preoperative assessment, but also the high precision that is provided pre- and intraoperatively by image-guided systems, have

allowed customized selection of IOLs and presbyopia correction strategies according to visual demands and activities, personality and special anatomical eye characteristics. Finally, since the research on IOL technologies is constantly evolving, the introduction of new promising IOL designs and the improvement of the already existing IOLs are expected within the next decade.

Conflict of interest

The authors declare no conflict of interest.

Author details

Georgios Labiris* and Eirini-Kanella Panagiotopoulou
Department of Ophthalmology, University Hospital of Alexandroupolis,
Alexandroupolis, Greece

*Address all correspondence to: labiris@usa.net

IntechOpen

© 2021 The Author(s). Licensee IntechOpen. This chapter is distributed under the terms of the Creative Commons Attribution License (<http://creativecommons.org/licenses/by/3.0>), which permits unrestricted use, distribution, and reproduction in any medium, provided the original work is properly cited. 

References

- [1] Lu Q, Congdon N, He X, Murthy GVS, Yang A, He W. Quality of life and near vision impairment due to functional presbyopia among rural Chinese adults. *Invest Ophthalmol Vis Sci.* 2011;52(7):4118-4123. DOI: 10.1167/iov.10-6353
- [2] Alió JL, Plaza-Puche AB, Piñero DP, Amparo F, Jiménez R, Rodríguez-Prats JL, Javaloy J, Pongo V. Optical analysis, reading performance, and quality-of-life evaluation after implantation of a diffractive multifocal intraocular lens. *J Cataract Refract Surg.* 2011;37(1):27-37. DOI: 10.1016/j.jcrs.2010.07.035
- [3] Frick KD, Joy SM, Wilson DA, Naidoo KS, Holden BA. The global burden of potential productivity loss from uncorrected presbyopia. *Ophthalmology.* 2015;122(8):1706-1710. DOI: 10.1016/j.opthta.2015.04.014
- [4] Chou KL. Combined effect of vision and hearing impairment on depression in older adults: evidence from the English Longitudinal Study of Ageing. *J Affect Disord.* 2008;106(1-2):191-196. DOI: 10.1016/j.jad.2007.05.028
- [5] Luo BP, Brown GC, Luo SC, Brown MM. The quality of life associated with presbyopia. *Am J Ophthalmol.* 2008;145(4):618-622. DOI: 10.1016/j.ajo.2007.12.011
- [6] Sharma B, Abell RG, Arora T, Antony T, Vajpayee RB. Techniques of anterior capsulotomy in cataract surgery. *Indian J Ophthalmol.* 2019;67(4):450-460. DOI: 10.4103/ijo.IJO_1728_18
- [7] Gil-Cazorla R, Shah S, Naroo SA. A review of the surgical options for the correction of presbyopia. *Br J Ophthalmol.* 2016;100(1):62-70. DOI: 10.1136/bjophthalmol-2015-306663
- [8] Mahrous A, Ciralsky JP, Lai EC. Revisiting monovision for presbyopia. *Curr Opin Ophthalmol.* 2018; 29(4):313-317. DOI:10.1097/icu.0000000000000487
- [9] Labiris G, Ntonti P, Patsiamanidi M, Sideroudi H, Georgantzoglou K, Kozobolis VP. Evaluation of activities of daily living following pseudophakic presbyopic correction. *Eye Vis (Lond).* 2017;4:2. DOI: 10.1186/s40662-016-0067-1
- [10] Xiao J, Jiang C, Zhang M. Pseudophakic monovision is an important surgical approach to being spectacle-free. *Indian J Ophthalmol.* 2011;59(6):481-485. DOI: 10.4103/0301-4738.86318
- [11] Zhang F, Sugar A, Jacobsen G, Collins M. Visual function and spectacle independence after cataract surgery: bilateral diffractive multifocal intraocular lenses versus monovision pseudophakia. *J Cataract Refract Surg.* 2011;37(5):853-858. DOI: 10.1016/j.jcrs.2010.12.041
- [12] Zettl S, Reiß S, Terwee T, Guthoff RF, Beck R, Stachs O. Der Effekt der pseudophaken Minimonovision als Option einer Brillenunabhängigkeit im Alltag [Effect of pseudophakic mini-monovision as an option for independence of spectacles in everyday life]. *Klin Monbl Augenheilkd.* 2014;231(12):1196-1202. German. DOI: 10.1055/s-0034-1383367
- [13] Braga-Mele R, Chang D, Dewey S, Foster G, Henderson BA, Hill W, Hoffman R, Little B, Mamalis N, Oetting T, Serafano D, Talley-Rostov A, Vasavada A, Yoo S; ASCRS Cataract Clinical Committee. Multifocal intraocular lenses: relative indications and contraindications for implantation. *J Cataract Refract Surg.* 2014;40(2):313-322. DOI: 10.1016/j.jcrs.2013.12.011

- [14] Liu YC, Wilkins M, Kim T, Malyugin B, Mehta JS. Cataracts. *Lancet*. 2017;390(10094):600-612. DOI: 10.1016/S0140-6736(17)30544-5
- [15] Malyugin B. Cataract surgery in small pupils. *Indian J Ophthalmol*. 2017;65(12):1323-1328. DOI: 10.4103/ijo.IJO_800_17
- [16] Lin HY, Chen HY, Fam HB, Chuang YJ, Yeoh R, Lin PJ. Comparison of corneal power obtained from VERION image-guided surgery system and four other devices. *Clin Ophthalmol*. 2017;11:1291-1299. DOI: 10.2147/OPTH.S137878
- [17] Srivannaboorn S, Chirapapaisan C. Comparison of refractive outcomes using conventional keratometry or total keratometry for IOL power calculation in cataract surgery. *Graefes Arch Clin Exp Ophthalmol*. 2019;257(12):2677-2682. DOI: 10.1007/s00417-019-04443-7
- [18] Lawless M, Jiang JY, Hodge C, Sutton G, Roberts TV, Barrett G. Total keratometry in intraocular lens power calculations in eyes with previous laser refractive surgery. *Clin Exp Ophthalmol*. 2020;48(6):749-756. DOI: 10.1111/ceo.13760
- [19] Fabian E, Wehner W. Prediction Accuracy of Total Keratometry Compared to Standard Keratometry Using Different Intraocular Lens Power Formulas. *J Refract Surg*. 2019;35(6):362-368. DOI: 10.3928/1081597X-20190422-02
- [20] Jack T. Holladay, IOL Power Calculations for Multifocal Lenses. *Cataract & Refractive Surgery Today*, 2007. Available from: https://crstoday.com/articles/2007-aug/crst0807_11-php/ [Accessed: 2021-01-06]
- [21] Kelly SP, Jalil A. Wrong intraocular lens implant; learning from reported patient safety incidents. *Eye (Lond)*. 2011;25(6):730-734. DOI: 10.1038/eye.2011.22
- [22] Kansal V, Schlenker M, Ahmed IIK. Interocular Axial Length and Corneal Power Differences as Predictors of Postoperative Refractive Outcomes after Cataract Surgery. *Ophthalmology*. 2018;125(7):972-981. DOI: 10.1016/j.opthta.2018.01.021
- [23] Findl O, Kriechbaum K, Sacu S, Kiss B, Polak K, Nepp J, Schild G, Rainer G, Maca S, Petternel V, Lackner B, Drexler W. Influence of operator experience on the performance of ultrasound biometry compared to optical biometry before cataract surgery. *J Cataract Refract Surg*. 2003;29:1950-1955. DOI: 10.1016/s0886-3350(03)00243-8
- [24] Li Y, Li HX, Liu YC, et al. Comparison of immersion ultrasound and low coherence reflectometry for ocular biometry in cataract patients. *Int J Ophthalmol*. 2018;11(6):966-969. DOI:10.18240/ijo.2018.06.11
- [25] Ademola-Popoola DS, Nzeh DA, Saka SE, Olokoba LB, Obajolowo TS. Comparison of ocular biometry measurements by applanation and immersion A-scan techniques. *J Curr Ophthalmol*. 2016;27(3-4):110-114. DOI:10.1016/j.joco.2015.12.002
- [26] Ventura AC, Wälti R, Böhnke M. Corneal thickness and endothelial density before and after cataract surgery. *Br J Ophthalmol*. 2001;85(1):18-20. DOI: 10.1136/bjo.85.1.18
- [27] Beiko GH. The Fundamentals of Spherical Aberration. *Cataract & Refractive Surgery Today (Europe)*. 2012. Available from: <https://crstodayeurope.com/articles/2012-jul/the-fundamentals-of-spherical-aberration/> [Accessed: 2021-01-21]
- [28] Wang L, Dai E, Koch DD, Nathoo A. Optical aberrations of the

human anterior cornea. *J Cataract Refract Surg.* 2003;29(8):1514-1521. DOI: 10.1016/s0886-3350(03)00467-x

[29] Visser N, Berendschot TT, Verbakel F, Tan AN, de Brabander J, Nuijts RM. Evaluation of the comparability and repeatability of four wavefront aberrometers. *Invest Ophthalmol Vis Sci.* 2011;52(3):1302-1311. DOI: 10.1167/iov.10-5841

[30] Atchison DA, Suheimat M, Mathur A, Lister LJ, Rozema J. Anterior Corneal, Posterior Corneal, and Lenticular Contributions to Ocular Aberrations. *Invest Ophthalmol Vis Sci.* 2016 Oct 1;57(13):5263-5270. DOI: 10.1167/iov.16-20067

[31] Fu Y, Kou J, Chen D, Wang D, Zhao Y, Hu M, Lin X, Dai Q, Li J, Zhao YE. Influence of angle kappa and angle alpha on visual quality after implantation of multifocal intraocular lenses. *J Cataract Refract Surg.* 2019;45(9):1258-1264. DOI: 10.1016/j.jcrs.2019.04.003

[32] Mabed IS, Saad A, Guilbert E, Gatinel D. Measurement of pupil center shift in refractive surgery candidates with caucasian eyes using infrared pupillometry. *J Refract Surg.* 2014;30(10):694-700. DOI: 10.3928/1081597X-20140903-07

[33] Tchah H, Nam K, Yoo A. Predictive factors for photic phenomena after refractive, rotationally asymmetric, multifocal intraocular lens implantation. *Int J Ophthalmol.* 2017;10(2):241-245. DOI:10.18240/ijo.2017.02.10

[34] Fischinger I, Seiler TG, Schmidinger G, Seiler T. Verschiebung des Pupillenzentroids : Marketing oder klinisch relevanter Parameter? [Pupil centroid shift: Marketing tool or essential clinical parameter?]. *Ophthalmologie.* 2015;112(8):661-4. German. DOI: 10.1007/s00347-014-3170-5

[35] Duman R, Tok Çevik M, Görkem Çevik S, Duman R, Perente İ. Corneal endothelial cell density in healthy Caucasian population. *Saudi J Ophthalmol.* 2016;30(4):236-239. DOI: 10.1016/j.sjopt.2016.10.003

[36] Bamdad S, Bolkheir A, Sedaghat MR, Motamed M. Changes in corneal thickness and corneal endothelial cell density after phacoemulsification cataract surgery: a double-blind randomized trial. *Electron Physician.* 2018;10(4):6616-6623. DOI: 10.19082/6616

[37] Mishima S. Clinical investigations on the corneal endothelium-XXXVIII Edward Jackson Memorial Lecture. *Am J Ophthalmol.* 1982;93(1):1-29. DOI: 10.1016/0002-9394(82)90693-6

[38] Edelhauser HF. The balance between corneal transparency and edema: the Proctor Lecture. *Invest Ophthalmol Vis Sci.* 2006;47(5):1754-1767. DOI: 10.1167/iov.05-1139

[39] Yoo YS, Whang WJ, Kim HS, Joo CK, Yoon G. Preoperative biometric measurements with anterior segment optical coherence tomography and prediction of postoperative intraocular lens position. *Medicine (Baltimore).* 2019;98(50):e18026. DOI: 10.1097/MD.00000000000018026

[40] Goto S, Maeda N, Koh S, Ohnuma K, Hayashi K, Iehisa I, Noda T, Nishida K. Prediction of Postoperative Intraocular Lens Position with Angle-to-Angle Depth Using Anterior Segment Optical Coherence Tomography. *Ophthalmology.* 2016;123(12):2474-2480. DOI: 10.1016/j.ophtha.2016.09.005

[41] Panagiotopoulou EK, Ntonti P, Gkika M, Konstantinidis A, Perente I, Dardabounis D, Ioannakis K, Labiris G. Image-guided lens extraction surgery: a systematic review. *Int J Ophthalmol.* 2019;12(1):135-151. DOI: 10.18240/ijo.2019.01.21

- [42] Boerner CF, Thrasher BH. Results of monovision correction in bilateral pseudophakes. *J Am Intraocul Implant Soc.* 1984; 10:49-50. DOI: 10.1016/s0146-2776(84)80077-4
- [43] Zhang F. Potential Concerns and Contraindications for IOL Monovision. *Clin Surg.* 2016;1:1084.
- [44] Zhang F. Pseudophakic Monovision (A Clinical Guide). 1st ed. New York, Stuttgart, Delhi, Rio de Janeiro: Thieme; 2018.
- [45] European Society of Cataract and Refractive Surgery Clinical Survey Results, 2016. Available from: <http://www.eurotimes.org/escrs-clinical-survey-2016-results/> [Accessed: 2021-12-14]
- [46] Goldberg DG, Goldberg MH, Shah R, Meagher JN, Ailani H. Pseudophakic mini-monovision: high patient satisfaction, reduced spectacle dependence, and low cost. *BMC Ophthalmology* 2018;18(1):293. DOI: 10.1186/s12886-018-0963-3
- [47] Labiris G, Giarmoukakis A, Patsiamanidi M, Papadopoulos Z, Kozobolis VP. Mini-monovision versus multifocal intraocular lens implantation. *J Cataract Refract Surg* 2015;41(1):53-57.
- [48] Labiris G, Toli A, Perente A, Ntonti P, Kozobolis VP. A systematic review of pseudophakic monovision for presbyopia correction. *Int J Ophthalmol* 2017;10(6):992-1000. DOI: 10.1016/j.jcrs.2014.06.015
- [49] Ito M, Shimizu K. Pseudophakic monovision. Careful patient selection is crucial. *Cataract & Refractive Surgery Today (Europe)* 2009;(Oct):64-66. Available from: https://crstodayeurope.com/articles/2009-oct/1009_14-php/ [Accessed: 2021-01-21]
- [50] Handa T, Mukuno K, Uozato H, Niida T, Shoji N, Minei R, Nitta M, Shimizu K. Ocular dominance and patient satisfaction after monovision induced by intraocular lens implantation. *J Cataract Refract Surg.* 2004;30(4):769-774. DOI: 10.1016/j.jcrs.2003.07.013
- [51] American Academy of Ophthalmology, Monovision should be induced cautiously in patients with strabismus history. 2011. Available from: <https://www.aao.org/editors-choice/monovision-should-be-induced-cautiously-in-patient> [Accessed: 2021-01-17]
- [52] Ito M, Shimizu K, Amano R, Handa T. Assessment of visual performance in pseudophakic monovision. *J Cataract Refract Surg.* 2009;35(4):710-714. DOI: 10.1016/j.jcrs.2008.12.019
- [53] Finkelman YM, Ng JQ, Barrett GD. Patient satisfaction and visual function after pseudophakic monovision. *J Cataract Refract Surg.* 2009;35(6):998-1002.
- [54] Burge J, Rodriguez-Lopez V, Dorronsoro C. Monovision and the Misperception of Motion. *Curr Biol.* 2019;29(15):2586-2592.e4. DOI:10.1016/j.cub.2019.06.070
- [55] Smith CE, Allison RS, Wilkinson F, Wilcox LM. Monovision: Consequences for depth perception from large disparities. *Exp Eye Res.* 2019;183:62-67. DOI: 10.1016/j.exer.2018.09.005
- [56] Hoffer KJ. Personal history in bifocal intraocular lenses, (Chapter 12). In: Maxwell A, Nordan LT, eds. *Current Concepts of Multifocal Intraocular Lenses.* Thorofare: Slack, Inc; 1991:127e132.
- [57] Pearce JL. Multifocal intraocular lenses. *Curr Opin Ophthalmol.* 1997;8(1):2-5.
- [58] Zvorničanin J, Zvorničanin E. Premium intraocular lenses: The past,

present and future. *J Curr Ophthalmol.* 2018;30(4):287-296. DOI: 10.1016/j.joco.2018.04.003

[59] Davison JA, Simpson MJ. History and development of the apodized diffractive intraocular lens. *J Cataract Refract Surg.* 2006;32:849-858 DOI: 10.1016/j.jcrs.2006.02.006

[60] Schwiegerling J, Petznick A. Refractive and Diffractive Principles in Presbyopia-Correcting IOLs — An Optical Lesson. Alcon. Available from: <https://us.alconscience.com/wp-content/uploads/2020/10/Refractive-and-Diffractive-Principles-in-Presbyopia-Correcting-IOLs-An-Optical-Lesson-US-REF-1900001.pdf> [Accessed: 2021-01-17]

[61] Rampat R, Gatinel D. Multifocal and Extended Depth-of-Focus Intraocular Lenses in 2020. *Ophthalmology.* 2020;S0161-6420(20)30931-3. DOI: 10.1016/j.optha.2020.09.026

[62] Gooi P, Ahmed IK. Review of presbyopic IOLs: multifocal and accommodating IOLs. *Int Ophthalmol Clin.* 2012 Spring;52(2):41-50. DOI: 10.1097/IIO.0b013e31824b87be

[63] Moreno V, Román JF, Salgueiro JR. High efficiency diffractive lenses: Deduction of kinoform profile. *American Journal of Physics* 1997;65:556-562. DOI: 10.1119/1.18587

[64] Alió JL, Pikkel J. Multifocal Intraocular Lenses. The Art and the Practice. 2nd ed. Switzerland: Springer Nature; 2019. DOI: 10.1007/978-3-030-21282-7

[65] Acrysof IQ Restor, Model SN6AD1 – Product Information. Available from: <https://www.alcon.com/eye-care-products> [Accessed: 2021-02-08]

[66] Acrysof IQ Restor, Product information, Alcon Laboratories, Inc. Available from: <https://www>

accessdata.fda.gov/cdrh_docs/pdf4/P040020S050d.pdf. [Accessed: 2021-02-08]

[67] Intraocular lenses, PhysIOL. Available from: <https://www.physiol.eu/en-US/Products/Intraocular-lenses> [Accessed: 2021-02-08]

[68] Kim MJ, Zheleznyak L, Macrae S, Tchah H, Yoon G. Objective evaluation of through-focus optical performance of presbyopia-correcting intraocular lenses using an optical bench system. *J Cataract Refract Surg.* 2011;37(7):1305-1312. DOI: 10.1016/j.jcrs.2011.03.033

[69] AcrySof IQ PanOptix, Summary of Safety and Effectiveness data. Fort Worth, TX: Alcon Laboratories, Inc. 2019. Available from: https://www.accessdata.fda.gov/cdrh_docs/pdf4/P040020S087B.pdf [Accessed: 2021-02-08]

[70] Intraocular lenses. Precision Lens. Available from: <https://www.precisionlens.net/products/jj-vision-products/lenses/> [Accessed: 2021-02-08]

[71] Zeiss AT LISA 809M. Technical Specifications. Available from: <https://www.zeiss.com/meditec/int/product-portfolio/iols/multifocal-iols/at-lisa-809m.html> [Accessed: 2021-02-08]

[72] Zeiss AT LISA tri 839MP preloaded. Technical Specifications. Available from: <https://www.zeiss.com/meditec/int/product-portfolio/iols/multifocal-iols/at-lisa-tri-family.html> [Accessed: 2021-02-08]

[73] Rudalevicius P, Lekaviciene R, Auffarth GU, Liutkeviciene R, Jasinskas V. Relations between patient personality and patients' dissatisfaction after multifocal intraocular lens implantation: clinical study based on the five factor inventory personality evaluation. *Eye (Lond).* 2020;34(4):717-724. DOI: 10.1038/s41433-019-0585-x

- [74] Mester U, Vaterrodt T, Goes F, Huetz W, Neuhaus I, Schmickler S, Szurman P, Gekeler K. Impact of personality characteristics on patient satisfaction after multifocal intraocular lens implantation: results from the “happy patient study”. *J Refract Surg.* 2014;30(10):674-678. DOI: 10.3928/1081597X-20140903-05
- [75] Al-Shymali O, Alió JL. Neuroadaptation Failure Corrected by Exchanging with a Different Multifocal Intraocular Lens. In: Alió JL, Pikkil J, editors. *Multifocal Intraocular Lenses. The Art and the Practice.* 2nd ed. Switzerland: Springer Nature; 2019. p. 111-119. DOI: 10.1007/978-3-030-21282-7_11
- [76] Kelly SP, Jalil A. Wrong intraocular lens implant; learning from reported patient safety incidents. *Eye (Lond).* 2011;25(6):730-734. DOI: 10.1038/eye.2011.22
- [77] Holladay JT, Prager TC, Chandler TY, Musgrove KH, Lewis JW, Ruiz RS. A three part system for refining intraocular lens power calculations. *J Cataract Refract Surg.* 1988;13:17-24. DOI: 10.1016/s0886-3350(88)80059-2
- [78] Retzlaff JA, Sanders DR, Kraff MC. Development of the SRK/T intraocular lens implant power calculation formula. *J Cataract Refract Surg.* 1990;16:333-340. DOI: 10.1016/s0886-3350(13)80705-5
- [79] Hoffer KJ. The Hoffer Q formula: a comparison of theoretic and regression formulas. *J Cataract Refract Surg.* 1993;19:700-712. DOI: 10.1016/s0886-3350(13)80338-0
- [80] Eom Y, Kang SY, Song JS, Kim YY, Kim HM, Comparison of Hoffer Q and Haigis formulae for intraocular lens power calculation according to the anterior chamber depth in short eyes. *Am J Ophthalmol.* 2014;157(4):818-824. e2. DOI: 10.1016/j.ajo.2013.12.017
- [81] Moschos MM, Chatziralli IP, Koutsandrea C. Intraocular lens power calculation in eyes with short axial length. *Indian J Ophthalmol.* 2014;62(6):692-694. DOI:10.4103/0301-4738.129791
- [82] Savini G, Taroni L, Hoffer KJ. Recent developments in intraocular lens power calculation methods-update 2020. *Ann Transl Med.* 2020;8(22):1553. DOI:10.21037/atm-20-2290
- [83] Petermeier K, Gekeler F, Messias A, Spitzer MS, Haigis W, Szurman P. Intraocular lens power calculation and optimized constants for highly myopic eyes. *J Cataract Refract Surg.* 2009;35(9):1575-8151. DOI: 10.1016/j.jcrs.2009.04.028
- [84] Kane JX, Van Heerden A, Atik A, Petsoglou C. Intraocular lens power formula accuracy: Comparison of 7 formulas. *J Cataract Refract Surg.* 2016;42(10):1490-1500. DOI: 10.1016/j.jcrs.2016.07.021
- [85] Liu J, Wang L, Chai F, Han Y, Qian S, Koch DD, Weikert MP. Comparison of intraocular lens power calculation formulas in Chinese eyes with axial myopia. *J Cataract Refract Surg.* 2019;45(6):725-731. DOI: 10.1016/j.jcrs.2019.01.018
- [86] Dong J, Zhang Y, Zhang H, Jia Z, Zhang S, Wang X. Comparison of axial length, anterior chamber depth and intraocular lens power between IOLMaster and ultrasound in normal, long and short eyes. *PloS One.* 2018;13(3):e0194273. DOI: 10.1371/journal.pone.0194273
- [87] Cech R, Utíkal T, Juhászová J. Srovnání optické a ultrazvukové biometrie a zhodnocení užívání obou metod v praxi [Comparison of optical and ultrasound biometry and assessment of using both methods in practice]. *Cesk Slov Oftalmol.* 2014;70(1):3-9. Czech.

- [88] Kolega MŠ, Kovačević S, Čanović S, Pavičić AD, Bašić JK. Comparison of IOL—master and ultrasound biometry in preoperative intra ocular lens (IOL) power calculation. *Coll Antropol.* 2015;39(1):233-235.
- [89] KievalJZ, Al-HashimiS, DavidsonRS, Hamilton DR, Jackson MA, LaBorwit S, PattersonLE, StonecipherKG, Donaldson K; ASCRS Refractive Cataract Surgery Subcommittee. Prevention and management of refractive prediction errors following cataract surgery. *J Cataract Refract Surg.* 2020;46(8):1189-1197. DOI: 10.1097/j.jcrs.0000000000000269
- [90] Carones F. Residual astigmatism threshold and patient satisfaction with bifocal, trifocal, and extended range of vision intraocular lenses (IOLs). *Open J Ophthalmol.* 2017;7(1):1-7. DOI: 10.4236/ojoph.2017.71001
- [91] Eyeworld Supplements. The American Society of Cataract and Refractive Surgery Clinical Survey. 2018. Available from: <https://supplements.eyeworld.org/eyeworld-supplements/december-2018-clinical-survey> [Accessed: 2021-01-21]
- [92] Kaur M, Shaikh F, Falera R, Titiyal JS. Optimizing outcomes with toric intraocular lenses. *Indian J Ophthalmol.* 2017;65(12):1301-1313. DOI:10.4103/ijo.IJO_810_17
- [93] Bryan SL. IOL Power Calculations for Eyes With Astigmatism. *Advanced Clinical Cases.* Available from: <https://collaborativeeye.com/articles/advanced-clinical-cases-2/iol-power-calculations-for-eyes-with-astigmatism/> [Accessed: 2021-01-17]
- [94] Abulafia A, Barrett GD, Kleinmann G, et al. Prediction of refractive outcomes with toric intraocular lens implantation. *J Cataract Refract Surg.* 2015;41(5):936-944. DOI: 10.1016/j.jcrs.2014.08.036
- [95] Salati C, Salvetat ML, Zeppieri M, Brusini P. Pupil size influence on the intraocular performance of the multifocal AMO-Array intraocular lens in elderly patients. *Eur J Ophthalmol.* 2007;17(4):571-578. DOI: 10.1177/112067210701700415
- [96] Park CY, Oh SY, Chuck RS. Measurement of angle kappa and centration in refractive surgery. *Curr Opin Ophthalmol.* 2012;23(4):269-275. DOI: 10.1097/ICU.0b013e3283543c41
- [97] Woodward MA, Randleman JB, Stulting RD. Dissatisfaction after multifocal intraocular lens implantation. *J Cataract Refract Surg.* 2009;35(6):992-997. DOI: 10.1016/j.jcrs.2009.01.031
- [98] de Vries NE, Webers CA, Touwslager WR, Bauer NJ, de Brabander J, Berendschot TT, Nuijts RM. Dissatisfaction after implantation of multifocal intraocular lenses. *J Cataract Refract Surg.* 2011;37(5):859-865. DOI: 10.1016/j.jcrs.2010.11.032
- [99] Pepin SM. Neuroadaptation of presbyopia-correcting intraocular lenses. *Curr Opin Ophthalmol.* 2008;19(1):10-12. DOI: 10.1097/ICU.0b013e3282f31758
- [100] Tchah H, Nam K, Yoo A. Predictive factors for photic phenomena after refractive, rotationally asymmetric, multifocal intraocular lens implantation. *Int J Ophthalmol.* 2017;10(2):241-245. DOI:10.18240/ijo.2017.02.10
- [101] Rosales P, De Castro A, Jiménez-alfaro I, Marcos S. Intraocular lens alignment from purkinje and Scheimpflug imaging. *Clin Exp Optom.* 2010;93:400-408. DOI: 10.1111/j.1444-0938.2010.00514.x
- [102] Prakash G, Prakash DR, Agarwal A, Kumar DA, Agarwal A, Jacob S. Predictive factor and kappa angle analysis for visual satisfactions

- in patients with multifocal IOL implantation. *Eye (Lond)*. 2011;25:1187-1193. DOI: 10.1038/eye.2011.150
- [103] Fu Y, Kou J, Chen D, Wang D, Zhao Y, Hu M, Lin X, Dai Q, Li J, Zhao YE. Influence of angle kappa and angle alpha on visual quality after implantation of multifocal intraocular lenses. *J Cataract Refract Surg*. 2019;45(9):1258-1264. DOI: 10.1016/j.jcrs.2019.04.003
- [104] Moshirfar M, Hoggan RN, Muthappan V. Angle Kappa and its importance in refractive surgery. *Oman J Ophthalmol*, 2013;6:151-158. DOI: 10.4103/0974-620X.122268
- [105] Soda M, Yaguchi S. Effect of decentration on the optical performance in multifocal intraocular lenses. *Ophthalmologica*. 2012;227(4):197-204. DOI: 10.1159/000333820
- [106] Asim R. Piracha. Using angle alpha in premium IOL screening. A simple measurement can give you a better sense of how well the IOL will center over the visual axis postoperatively. Available from: https://crstoday.com/wp-content/themes/crst/assets/downloads/crst0316_cs_Piracha.pdf. [Accessed: 2021-02-08]
- [107] Visser N, Nuijts RMMA, de Vries NE, Bauer NJV. Visual outcomes and patient satisfaction after cataract surgery with toric multifocal intraocular lens implantation. *J Cataract Refract Surg*. 2011; 37:2034-2042. DOI: 10.1159/000333820
- [108] Hamza I, Aly MG, Hashem KA. Multifocal IOL dissatisfaction in patients with high coma aberrations. Presented at: ASCRS Symposium on Cataract, IOL and Refractive Surgery; 27 March 2011; San Diego, California, USA.
- [109] Velasco-Barona C, Corredor-Ortega C, Mendez-Leon A, Casillas-Chavarín NL, Valdepeña-López Velarde D, Cervantes-Coste G, Malacara-Hernández D, Gonzalez-Salinas R. Influence of Angle κ and Higher-Order Aberrations on Visual Quality Employing Two Diffractive Trifocal IOLs. *J Ophthalmol*. 2019;2019:7018937. DOI: 10.1155/2019/7018937
- [110] Atchison DA, Mathur A. Effects of pupil center shift on ocular aberrations. *Invest Ophthalmol Vis Sci*. 2014;55(9):5862-5870. DOI: 10.1167/iops.14-14212
- [111] Liao X, Lin J, Tian J, Wen B, Tan Q, Lan C. Evaluation of Optical Quality: Ocular Scattering and Aberrations in Eyes Implanted with Diffractive Multifocal or Monofocal Intraocular Lenses. *Curr Eye Res*. 2018;43(6):696-701. DOI: 10.1080/02713683.2018.1449220
- [112] Donnenfeld ED, Solomon R, Roberts CW, Wittpenn JR, McDonald MB, Perry HD. Cyclosporine 0.05% to improve visual outcomes after multifocal intraocular lens implantation. *J Cataract Refract Surg*. 2010;36:1095-1100. DOI: 10.1016/j.jcrs.2009.12.049
- [113] Garg P, Gupta A, Tandon N, Raj P. Dry Eye Disease after Cataract Surgery: Study of its Determinants and Risk Factors. *Turk J Ophthalmol*. 2020;50(3):133-142. DOI:10.4274/tjo.galenos.2019.45538
- [114] Li XM, Hu L, Hu J, Wang W. Investigation of dry eye disease and analysis of the pathogenic factors in patients after cataract surgery. *Cornea*. 2007;26:S16-S20. DOI: 10.1097/ICO.0b013e31812f67ca
- [115] Alio JL, Colecha JR, Pastor S, Rodriguez A, Artola A. Symptomatic dry eye treatment with autologous platelet-rich plasma. *Ophthalmic Res*. 2007;39:124-129. DOI: 10.1159/000100933

- [116] Alio JL, Arnalich-Montiel F, Rodriguez AE. The role of “eye platelet rich plasma” (E-PRP) for wound healing in ophthalmology. *Curr Pharm Biotechnol.* 2012;13:1257-1265. DOI: 10.2174/138920112800624355
- [117] Pepose JS. Maximizing satisfaction with presbyopia correcting intraocular lenses: the missing link. *Am J Ophthalmol.* 2008;146:641-648. DOI: 10.1016/j.ajo.2008.07.033
- [118] Makhotkina NY, Nijkamp MD, Berendschot TTJM, van den Borne B, Nuijts RMMA. Effect of active evaluation on the detection of negative dysphotopsia after sequential cataract surgery: discrepancy between incidences of unsolicited and solicited complaints. *Acta Ophthalmol.* 2018;96(1):81-87. DOI: 10.1111/aos.13508
- [119] Khor WB, Afshari NA. The role of presbyopia-correcting intraocular lenses after laser in situ keratomileusis. *Curr Opin Ophthalmol.* 2013;24(1):35-40. DOI: 10.1097/ICU.0b013e32835ab457
- [120] Vrijman V, Abulafia A, van der Linden JW, van der Meulen IJE, Mourits MP, Lapid-Gortzak R. ASCRS calculator formula accuracy in multifocal intraocular lens implantation in hyperopic corneal refractive laser surgery eyes. *J Cataract Refract Surg.* 2019;45(5):582-586. DOI: 10.1016/j.jcrs.2018.12.006
- [121] Vrijman V, van der Linden JW, van der Meulen IJE, Mourits MP, Lapid-Gortzak R. Multifocal intraocular lens implantation after previous hyperopic corneal refractive laser surgery. *J Cataract Refract Surg.* 2018;44(4):466-470. DOI: 10.1016/j.jcrs.2018.01.030
- [122] Hoffer KJ. Intraocular lens power calculation for eyes after refractive keratotomy. *J Refract Surg.* 1995;11(6):490-493.
- [123] Holladay JT. Consultations in refractive surgery. *Refract Corneal Surg.* 1989; 5:203
- [124] Wang L, Hill WE, Koch DD. Evaluation of intraocular lens power prediction methods using the American Society of Cataract and Refractive Surgeons post-keratorefractive intraocular lens power calculator. *J Cataract Refract Surg* 2010; 36:1466-1473. DOI: 10.1016/j.jcrs.2010.03.044
- [125] Vrijman V, Abulafia A, van der Linden JW, van der Meulen IJE, Mourits MP, Lapid-Gortzak R. Evaluation of Different IOL Calculation Formulas of the ASCRS Calculator in Eyes After Corneal Refractive Laser Surgery for Myopia With Multifocal IOL Implantation. *J Refract Surg.* 2019;35(1):54-59. DOI: 10.3928/1081597X-20181119-01
- [126] Vrijman V, Abulafia A, van der Linden JW, van der Meulen IJE, Mourits MP, Lapid-Gortzak R. ASCRS calculator formula accuracy in multifocal intraocular lens implantation in hyperopic corneal refractive laser surgery eyes. *J Cataract Refract Surg.* 2019;45(5):582-586. DOI: 10.1016/j.jcrs.2018.12.006
- [127] Panagiotopoulou EK, Ntonti P, Vlachou E, Georgantzoglou K, Labiris G. Patients' Expectations in Lens Extraction Surgery: a Systematic Review. *Acta Medica (Hradec Kralove).* 2018;61(4):115-124. DOI: 10.14712/18059694.2018.129
- [128] Baek T, Lee K, Kagaya F, Tomidokoro A, Amano S, Oshika T. Factors affecting the forward shift of posterior corneal surface after laser in situ keratomileusis. *Ophthalmology.* 2001 Feb;108(2):317-320. DOI: 10.1016/s0161-6420(00)00502-9
- [129] Christopher Kent. Choosing the Best IOL For a Nonstandard Eye. Review of Ophthalmology. 2016. Available from:

<https://www.reviewofophthalmology.com/article/choosing-the-best-iol-for-a-nonstandard-eye> [Accessed: 2021-01-20]

[130] Alió JL, Pikkel J. Multifocal Intraocular Lenses and Corneal Refractive Surgery. In: Alió JL, Pikkel J, editors. Multifocal Intraocular Lenses. The Art and the Practice. 2nd ed. Switzerland: Springer Nature; 2019. p. 67-72. DOI: 10.1007/978-3-030-21282-7_11

[131] Melki SA, Harissi-Dagher M. Coaxially sighted intraocular lens light reflex for centration of the multifocal single piece intraocular lens. *Can J Ophthalmol*. 2011;46(4):319-321. DOI: 10.1016/j.jcjo.2011.06.007

[132] Grzybowski A, Kanclerz P. Early postoperative intraocular pressure elevation following cataract surgery. *Curr Opin Ophthalmol*. 2019;30(1):56-62. DOI: 10.1097/ICU.0000000000000545

[133] Malyugin B. Review of surgical management of small pupils in cataract surgery: Use of the Malyugin ring. *Techn Ophthalmol*. 2010;8:104-118. DOI: 10.1097/ITO.0b013e318242c452

[134] Malyugin B. Cataract surgery in small pupils. *Indian J Ophthalmol*. 2017;65(12):1323-1328. DOI:10.4103/ijo.IJO_800_17

[135] Papaconstantinou D, Kalantzis G, Brouzas D, Kontaxakis A, Koutsandrea C, Diagourtas A, Georgalas I. Safety and efficacy of phacoemulsification and intraocular lens implantation through a small pupil using minimal iris manipulation. *Clin Interv Aging*. 2016;11:651-657. DOI: 10.2147/CIA.S97254

[136] Bhogal MM, Angunawela RI, Little BC. Use of low-cost video recording device in reflective practice in cataract surgery. *J Cataract Refract Surg*.

2010;36(4):542-546. DOI: 10.1016/j.jcrs.2009.10.053

[137] Verion Reference Unit. Alcon Laboratories. Fort Worth, Texas. Available from: http://crstoday.com/pdfs/0614_supp2.pdf [Accessed: 2020-12-31].

[138] CALLISTO Eye, Computer assisted cataract surgery, ZEISS. Available from: <https://www.zeiss.com/meditec/int/products/ophthalmology-optometry/cataract/visualization/computer-assisted-cataract-surgery/callisto-eye.html#highlights>. [Accessed: 2020-12-31].

[139] Alfonso JF, Puchades C, Fernandez-Vega L, Merayo C, Montes-Mico R. Contrast sensitivity comparison between AcrySof ReSTOR and Acri.LISA aspheric intraocular lenses. *J Refract Surg*. 2010;26:471-477. DOI: 10.3928/1081597X-20090728-04

[140] Alba-Bueno F, Vega F, Millán MS. Halos y lentes intraoculares multifocales: origen e interpretación [Halos and multifocal intraocular lenses: origin and interpretation]. *Arch Soc Esp Oftalmol*. 2014;89(10):397-404. Spanish. DOI: 10.1016/j.oftal.2014.01.002

[141] Montés-Micó R, España E, Bueno I, Charman WN, Menezo JL. Visual performance with multifocal intraocular lenses: mesopic contrast sensitivity under distance and near conditions. *Ophthalmology*. 2004;111(1):85-96. DOI: 10.1016/S0161-6420(03)00862-5

[142] Galor A, Gonzalez M, Goldman D, O'Brien TP. Intraocular lens exchange surgery in dissatisfied patients with refractive intraocular lenses. *J Cataract Refract Surg* 2009;35:1706-1710. DOI: 10.1016/j.jcrs.2009.05.022

[143] Schrecker J, Blass S, Langenbucher A. Silicone-diffractive versus acrylic-refractive supplementary

- iols: visual performance and manual handling. *J Refract Surg.* 2014;30(1):41-48. DOI: 10.3928/1081597x-20131217-05
- [144] Cillino S, Casuccio A, Di Pace F, Morreale R, Pillitteri F, Cillino G, Lodato G. One-year outcomes with new-generation multifocal intraocular lenses. *Ophthalmology.* 2008;115(9):1508-1516. DOI: 10.1016/j.opthta.2008.04.017
- [145] Woodward MA, Randleman JB, Stulting RD. Dissatisfaction after multifocal intraocular lens implantation. *J Cataract Refract Surg.* 2009;35:992-997. DOI: 10.1016/j.jcrs.2009.01.031
- [146] Venter JA, Pelouskova M, Collins BM, Schallhorn SC, Hannan SJ. Visual outcomes and patient satisfaction in 9366 eyes using a refractive segmented multifocal intraocular lens. *J Cataract Refract Surg.* 2013;39:1477-1484. DOI: 10.1016/j.jcrs.2013.03.035
- [147] Fernandez-Buenaga R, Alio JL, Munoz-Negrete FJ, Barraquer Compte RI, Alio-Del Barrio JL. Causes of IOL explantation in Spain. *Eur J Ophthalmol.* 2012;22:762-768.
- [148] Dwayne K. Logan. Halos With Multifocal IOLs. A surgeon explores neuroadaptation to reduce complications with these lenses. *Cataract and Refractive Surgery Today.* 2008. Available from: https://crstoday.com/articles/2008-sep/crst0908_08-php/ [Accessed: 2021-01-20].
- [149] Vega-Estrada A, Alió del Barrio JL, Alió JL. Accommodative Intraocular Lenses. In: Alió JL, Pikkell J, editors. *Multifocal Intraocular Lenses. The Art and the Practice.* 2nd ed. Switzerland: Springer Nature; 2019. p. 355-366. DOI: 10.1007/978-3-030-21282-7_11
- [150] Alió JL, Alió Del Barrio JL, Vega-Estrada A. Accommodative intraocular lenses: where are we and where we are going. *Eye Vis (Lond).* 2017;4:16. DOI: 10.1186/s40662-017-0077-7
- [151] Pepose JS, Burke J, Qazi M. Accommodating Intraocular Lenses. *Asia Pac J Ophthalmol (Phila).* 2017;6(4):350-357. DOI: 10.22608/APO.2017198
- [152] Kanclerz P, Toto F, Grzybowski A, Alio JL. Extended Depth-of-Field Intraocular Lenses: An Update. *Asia Pac J Ophthalmol (Phila).* 2020;9(3):194-202. DOI:10.1097/APO.0000000000000296
- [153] Zvorničanin J, Zvorničanin E. Premium intraocular lenses: The past, present and future. *J Curr Ophthalmol.* 2018;30(4):287-296. DOI: 10.1016/j.joco.2018.04.003
- [154] Breyer DRH, Kaymak H, Ax T, Kretz FTA, Auffarth GU, Hagen PR. Multifocal intraocular lenses and extended depth of focus intraocular lenses. *Asia Pac J Ophthalmol (Phila).* 2017;6(4):339-349. DOI: 10.22608/APO.2017186
- [155] Nakazawa M, Ohtsuki K. Apparent accommodation in pseudophakic eyes after implantation of posterior chamber intraocular lenses: optical analysis. *Invest Ophthalmol Vis Sci.* 1984;25(12):1458-1460.
- [156] Rocha KM. Extended depth of focus IOLs: the next chapter in refractive technology? *J Refract Surg.* 2017;33:146-149. DOI: 10.3928/1081597X-20170217-01
- [157] Kanclerz P, Toto F, Grzybowski A, Alio JL. Extended Depth-of-Field Intraocular Lenses: An Update. *Asia Pac J Ophthalmol (Phila).* 2020;9(3):194-202. DOI:10.1097/APO.0000000000000296
- [158] Gallego AA, Bará S, Jaroszewicz Z, Kolodziejczyk A. Visual Strehl performance of IOL designs with extended depth of focus. *Optom Vis Sci.* 2012;89(12):1702-1707. DOI: 10.1097/OPX.0b013e3182775e1a

- [159] Domínguez-Vicent A, Esteve-Taboada JJ, Del Águila-Carrasco AJ, Monsálvez-Romin D, Montés-Micó R. In vitro optical quality comparison of 2 trifocal intraocular lenses and 1 progressive multifocal intraocular lens. *J Cataract Refract Surg*. 2016;42(1):138-147. DOI: 10.1016/j.jcrs.2015.06.040
- [160] Domínguez-Vicent A, Esteve-Taboada JJ, Del Águila-Carrasco AJ, Ferrer-Blasco T, Montés-Micó R. In vitro optical quality comparison between the Mini WELL Ready progressive multifocal and the TECNIS Symphony. *Graefes Arch Clin Exp Ophthalmol*. 2016;254(7):1387-1397. DOI: 10.1007/s00417-015-3240-7
- [161] Alio JL. Presbyopic lenses: evidence, masquerade news, and fake news. *Asia Pac J Ophthalmol (Phila)*. 2019;8:273-274. DOI: 10.1097/01.APO.0000577792.28242.2d
- [162] Böhm M, Petermann K, Hemkeppler E, Kohnen T. Defocus curves of 4 presbyopia-correcting IOL designs: Diffractive panfocal, diffractive trifocal, segmental refractive, and extended-depth-of-focus. *J Cataract Refract Surg*. 2019;45(11):1625-1636. DOI: 10.1016/j.jcrs.2019.07.014
- [163] Kanclerz P, Toto F, Grzybowski A, Alio JL. Extended Depth-of-Field Intraocular Lenses: An Update. *Asia Pac J Ophthalmol (Phila)*. 2020;9(3):194-202. DOI:10.1097/APO.0000000000000296
- [164] Akella SS, Juthani VV. Extended depth of focus intraocular lenses for presbyopia. *Curr Opin Ophthalmol*. 2018;29(4):318-322. DOI: 10.1097/ICU.0000000000000490
- [165] Cochener B; Concherto Study Group. Clinical outcomes of a new extended range of vision intraocular lens: International Multicenter Concerto Study. *J Cataract Refract Surg*. 2016;42:1268-1275.
- [166] Gatinel D, Loicq J. Clinically relevant optical properties of bifocal, trifocal, and extended depth of focus intraocular lenses. *J Refract Surg* 2016; 32:273-280. DOI: 10.3928/1081597X-20160121-07
- [167] Studený P, Kacarovský M, Kacarovská J, Gajarová N, Straňák Z. HYBRIDNÍ MONOVISION [HYBRID MONOVISION]. *Cesk Slov Oftalmol*. 2017 Spring;73(1):13-16. Czech.
- [168] Iida Y, Shimizu K, Ito M. Pseudophakic monovision using monofocal and multifocal intraocular lenses: hybrid monovision. *J Cataract Refract Surg* 2011; 37(11):2001-2005. DOI: 10.1016/j.jcrs.2011.05.032
- [169] Yoon SY, Song IS, Kim JY, Kim MJ, Tchah H. Bilateral mix-and-match versus unilateral multifocal intraocular lens implantation: long-term comparison. *J Cataract Refract Surg*. 2013;39(11):1682-1690. DOI: 10.1016/j.jcrs.2013.04.043
- [170] Hütz WW, Bahner K, Röhrig B, Hengerer F. The combination of diffractive and refractive multifocal intraocular lenses to provide full visual function after cataract surgery. *Eur J Ophthalmol*. 2010;20(2):370-375. DOI: 10.1177/112067211002000217
- [171] Gunenc U, Celik L. Long-term experience with mixing and matching refractive array and diffractive CeeOn multifocal intraocular lenses. *J Refract Surg*. 2008;24(3):233-242. DOI: 10.3928/1081597X-20080301-04
- [172] Grzybowski A, Kanclerz P. Do we need day-1 postoperative follow-up after cataract surgery? *Graefes Arch Clin Exp Ophthalmol*. 2019;257(5):855-861. DOI: 10.1007/s00417-018-04210-0
- [173] Buckhurst PJ, Naroo SA, Davies LN, Shah S, Drew T, Wolffsohn JS. Assessment of dysphotopsia in pseudophakic subjects

with multifocal intraocular lenses. *BMJ Open Ophthalmol.* 2017;1(1):e000064. DOI: 10.1136/bmjophth-2016-000064

[174] Steinberg EP, Tielsch JM, Schein OD, Javitt JC, Sharkey P, Cassard SD, Legro MW, Diener-West M, Bass EB, Damiano AM, Steinwachs DM, Sommer A. The VF-14. an index of functional impairment in patients with cataract. *Arch Ophthalmol.* 1994;112:630-638. DOI: 10.1001/archophth.1994.01090170074026

[175] Mangione CM, Lee PP, Gutierrez PR, Spritzer K, Berry S, Hays RD; National Eye Institute Visual Function Questionnaire Field Test Investigators. Development of the 25-item National Eye Institute Visual Function Questionnaire. *Arch Ophthalmol.* 2001;119(7):1050-1058. DOI: 10.1001/archophth.119.7.1050.

[176] Lundström M, Pesudovs K. Catquest-9SF patient outcomes questionnaire: nine-item short-form Rasch-scaled revision of the Catquest questionnaire. *J Cataract Refract Surg.* 2009;35(3):504-513. DOI: 10.1016/j.jcrs.2008.11.038

[177] Radner W, Willinger U, Obermayer W, Mudrich C, Velikay-Parel M, Eisenwort B. A new reading chart for simultaneous determination of reading vision and reading speed. *Klin Monatsbl Augenheilkd.* 1998;213(3):174-181. DOI: 10.1055/s-2008-1034969

[178] Mansfield JS, Ahn SJ, Legge GE, Luebker A. A new reading acuity chart for normal and low vision. *Opt Soc Am Techn Digest.* 1993;3:232-235.

[179] Calabrèse A, To L, He Y, Berkholtz E, Rafian P, Legge GE. Comparing performance on the MNREAD iPad application with the MNREAD acuity chart. *J Vis.* 2018;18(1):8. DOI: 10.1167/18.1.8.

[180] Labiris G, Panagiotopoulou EK, Chatzimichael E, Tzinava M, Mataftsi A, Delibasis K. Introduction of a digital near-vision reading test for normal and low vision adults: development and validation. *Eye Vis (Lond).* 2020;7:51. DOI: 10.1186/s40662-020-00216-0

[181] Emily B. Worrall, BS, BA, and Hoon C. Jung, MD. Blended Vision With Multifocal Intraocular Lenses. *EyeNet Magazine.* American Academy of Ophthalmology. 2019. Available from: <https://www.aao.org/eyenet/article/blended-vision-with-multifocal-intraocular-lenses> [Accessed: 2021-01-08]