

# We are IntechOpen, the world's leading publisher of Open Access books Built by scientists, for scientists

6,900

Open access books available

185,000

International authors and editors

200M

Downloads

Our authors are among the

154

Countries delivered to

TOP 1%

most cited scientists

12.2%

Contributors from top 500 universities



WEB OF SCIENCE™

Selection of our books indexed in the Book Citation Index  
in Web of Science™ Core Collection (BKCI)

Interested in publishing with us?  
Contact [book.department@intechopen.com](mailto:book.department@intechopen.com)

Numbers displayed above are based on latest data collected.  
For more information visit [www.intechopen.com](http://www.intechopen.com)



# Hypomelanosis Secondary to Cutaneous Inflammation

*Behzad Dalvand*

## Abstract

Hypomelanosis is a prevalent skin disorder in individuals with dark skin. Numerous inflammatory skin disorders cause hypomelanosis, even depigmentation. Its pathogenesis remains unknown, but it can be attributed to changes in melanin production in response to inflammation. The clinical manifestations, often including lesions with ill-defined borders limited to the site of inflammation, mostly appear in individuals with dark skin. The most important way to manage PIH is to effectively treat the underlying skin disorder that has led to it, however, medical therapy and phototherapy can be helpful, as well.

**Keywords:** PIH, hypomelanosis secondary to inflammation, depigmentation, pathogenesis, melanocytes

## 1. Introduction

Hypomelanosis is a prevalent skin disorder in dark-skinned Individuals. The numerous skin diseases that cause hypomelanosis include psoriasis, mycosis fungoides, sarcoidosis, pityriasis lichenoides chronica, lichen striatus, lupus erythematosus and lichen sclerosus. Different clinical pictures of lesions and multiple factors in developing post-inflammatory hypopigmentation (PIH) constitute a diagnostic challenge for dermatologists.

### 1.1 Pathogenesis

Although many studies have addressed PIH, its exact etiology remains unknown and needs the assistance of cytologists. PIH is actually caused by a disorder in melanocyte-keratinocyte interactions. The release of inflammatory agents can be involved in the synthesis of melanin or transfer of melanin to keratinocytes, especially by inhibiting the transfer of melanin from melanocytes to keratinocytes. Melanocytes can respond by changing melanin production in response to posttraumatic stress and inflammation.

Individuals inherit chromatic tendency in the predominantly autosomal dominant form. Hypopigmentation can develop as a result of damage to melanocytes, especially in patients with weak melanocytes. It is worth noting that melanocytes can be weak even in individuals with fair skin. Different factors control melanogenesis as a complex process that involves the synthesis, transfer and release of melanin. PIH is mostly caused by the inhibition rather than destruction of melanocytes.

Moreover, severe inflammatory responses of the skin can cause melanocyte loss or death and thus pigmentation changes.

## **1.2 Clinical manifestations**

The clinical manifestations, often including lesions with ill-defined borders limited to the site of inflammation, mostly emerge in individuals with dark skin, especially in those prone to hypopigmentation or even depigmentation. They are associated with diagnostic challenges, especially in children, as they can be associated with minor or asymptomatic variations.

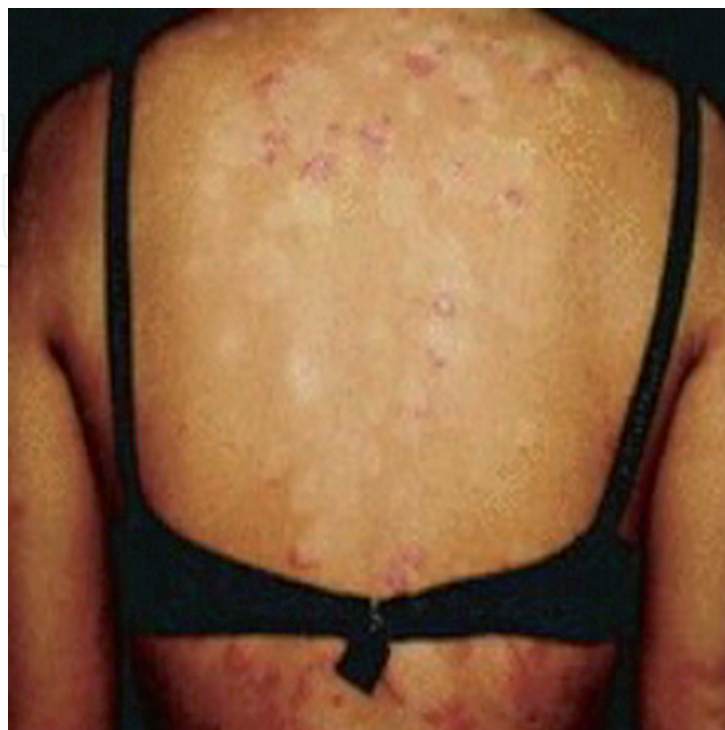The clinical features normally vary based on the primary skin lesions and the lesion margins are often blurred.

The rate of hypopigmentation varies with the age and severity of the cutaneous lesions and severity of the inflammation. Identifying the underlying cause of hypopigmentation can be difficult upon the patient admission, as inflammation of advanced lesions may decrease in severity or even gradually disappear (**Figure 1**). A complex description and frequent examinations are therefore required in these cases. Biopsy and histological examinations are also required in the absence of inflammatory symptoms.

## **1.3 Treatment**

The most important treatment is to effectively treat the underlying skin disorder that has led to PIH because PIH usually improves over time.

UVB phototherapy and epidermal melanocyte transplantation can help treat completely-destroyed or depigmented melanocytes. Photo protection, apply broad spectrum (UVAUVB) SPF 30 or 50 and reapply every 2–4 hours self-tanner (dihydroxyacetone). Applying topical ironoxide (3%) can effectively protect the skin against blue visible light, especially in dark-skinned patients with PIH.



**Figure 1.**  
*Psoriasis, showing multiple-well demarcated hypopigmented lesions.*

## 2. Diseases of PIH

### 2.1 Pityriasis alba

#### 2.1.1 Introduction

Pityriasis alba is a prevalent benign but chronic and inflammatory dermatosis and a minor skin feature of atopic dermatitis that mostly emerges in 3 to 16-year-old individuals. Its prevalence is 1.9%–9.9% in children and up to 5%, especially when coupled with atopic dermatitis.

#### 2.1.2 Pathogenesis

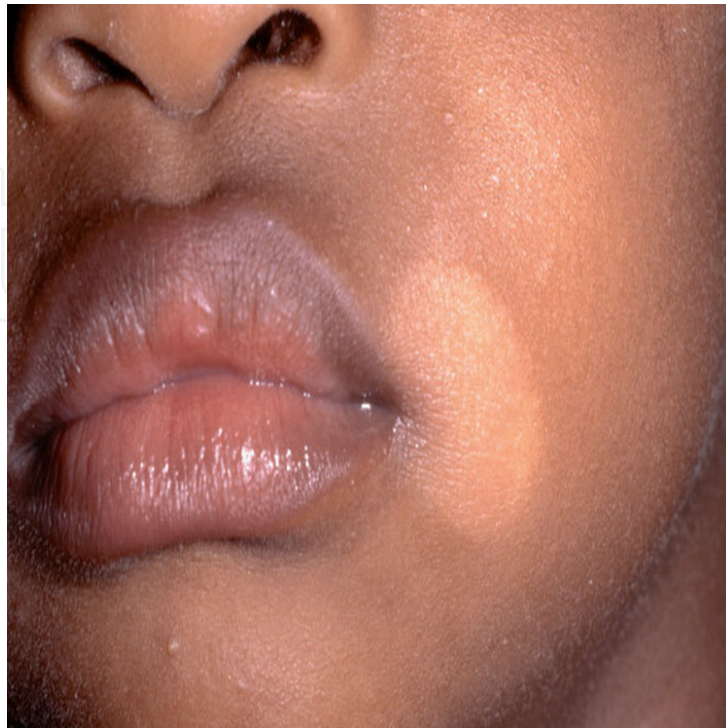Different mechanisms can be considered for explaining the still-unknown etiology of pityriasis alba. A history of atopic dermatitis constitutes a pathogenic factor in pityriasis alba.

A Positive Relationship between health habits and pityriasis alba, frequent bathing and excessive washing may contribute to the lesion.

Nutritional factors and copper deficiency are also effective. Tyrosine in dermal cells involved in producing melanin is activated by copper. Pathological examinations with electron microscopy and light microscopy showed decreases in the number and size of melanosomes in the affected skin [1].

#### 2.1.3 Clinical manifestations

The eruptions usually appear as round or oval macules or patches with an indistinct border with or without slight and often asymptomatic scales (**Figure 2**). The lesions normally become more visible in summer and may initially appear pink in



**Figure 2.**  
*Pityriasis alba: A common disfiguring hypomelanosis, which, as the name indicates, is a white area (alba) with very mild scaling (pityriasis). It is observed in a large number of children in the summer intemperate climates.*

a way that the erythema subsides and turns white with powdery appearance and a pink border within a few weeks. With a size of 5–30 mm, the lesions mostly involve the face. Direct examination of scrapings with 10% KOH and slit-skin smear are respectively used to diagnose tinea versicolor and leprosy, and Wood's lamp examinations are performed for distinguishing vitiligo and the diseases associated with hypopigmentation.

It is mostly a cosmetic problem in persons with brown or black skin and commonly occurs on the face, as in this child. Among 200 patients with pityriasis alba, 90% ranged from 6–12 years of age. In young adults, PA quite often occurs on the arms and trunk [2].

#### *2.1.4 Treatment*

If pityriasis alba is left untreated, it can turn chronic and recurrent, although it self-heals in most cases after puberty. Topical steroids class V help reduce the lesion inflammation caused by pityriasis alba. Calcineurin inhibitors such as pimecrolimus cream 1% and tacrolimus ointment 0.3% or 0.1% with anti-inflammatory properties can positively affect and activate tyrosinase and thus increase melanin synthesis [3]. Narrow-band UVB and excimer light or excimer laser treatment also yields proper responses through 5–10 treatments of 308 nm excimer laser.

## **2.2 Cutaneous lupus erythematosus**

### *2.2.1 Introduction*

Cutaneous lupus erythematosus is more prevalent in women with dark skin, especially in their fourth decade of life. One to five percent of the patients may progress to systemic lupus erythematosus.

### *2.2.2 Pathogenesis*

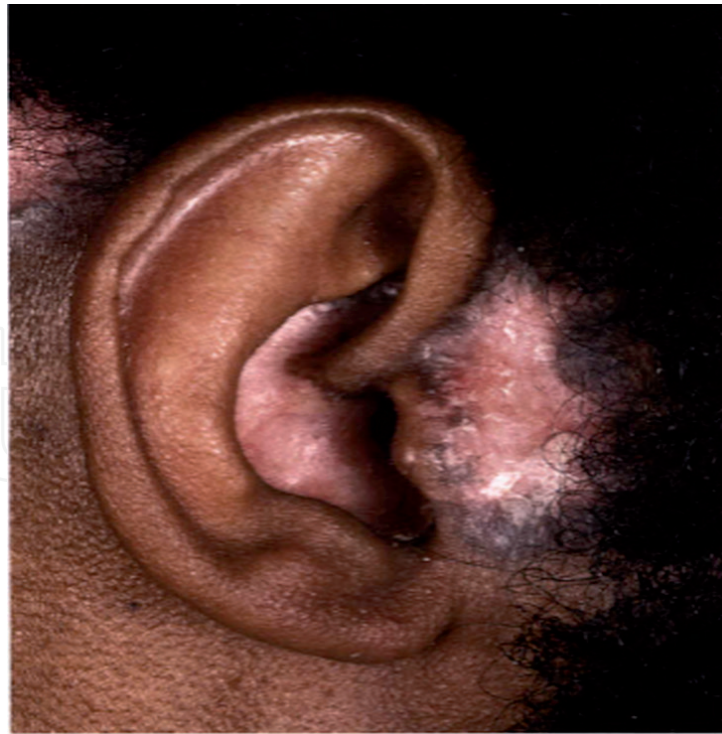Trauma and UVR may have been involved in the onset and exacerbation of symptoms in a person with a predisposed background. Photosensitivity is also observed in 50% of the patients. Histologic examinations can suggest lymphocytic interface dermatitis with basal layer degeneration (hydropic degeneration), keratinocyte apoptosis, basement membrane thickening (greatest in discoid lupus erythematosus), perivascular and periadnexal lymphohistiocytic infiltrate, follicular plugging, cutaneous mucinosis, epidermal atrophy, fibrosis, hypomelanosis and amelanosis, which are observed especially in the center of the lesions.

### *2.2.3 Clinical manifestations*

As the most prevalent manifestations, sharply demarcated lesions in discoid lupus erythematosus (DLE) can be round, justifying the term “discoid”. The face and scalp constitute the most commonly affected sites.

DLE lesions are usually asymmetric and asymptomatic with a well-defined and elevated margin, which explains their red to violaceous color. These lesions often appear atrophic and hypopigmented or depigmented, especially in black individuals with prominent follicular plugs (**Figure 3**). Their hypopigmented center is often surrounded by a hyperpigmented margin.

Systemic lupus erythematosus can be assessed by performing a complete blood count, an erythrocyte sedimentation rate and an antinuclear antibody test.



**Figure 3.**  
*Discoid lupus erythematosus; there are well-defined, erythematous, scaling lesions with a pigmented margin and central depigmentation and behind the ear in this west Indian.*

#### *2.2.4 Treatment*

Initial treatment options include topical steroids, intralesional steroids, anti-malarial medications such as Hydroxychloroquine, and acitretin. High-potency corticosteroids are recommended for the facial lesions.

Intralesional triamcinolone, commonly at a concentration of 4 to 5 mg/ml, can be very effective especially in active discoid lesions.

Reports suggest the successful application of new topical immunomodulators such as tacrolimus to cutaneous lesions.

### **2.3 Systemic sclerosis (scleroderma)**

#### *2.3.1 Introduction*

As a collagen vascular disease with cutaneous fibrosis as its skin manifestation, systemic sclerosis causes skin tightening and pigmentary changes. The incidence and prevalence of scleroderma are respectively below two per million and 25 per million [4, 5].

#### *2.3.2 Pathogenesis*

Abnormal immune responses, vascular dysfunction and activation of connective tissue cells have been reported in genetically-predisposed individuals. Different environmental and occupational factors such as silica and [6]. organic solvents can be involved.

Electron microscopy shows depigmentation, loss of melanocytes and degenerative changes.

### *2.3.3 Clinical manifestations*

The clinical patterns of the disease include limited cutaneous systemic sclerosis, which is limited to distal limbs, reaches up to the knees and elbows and usually involves the face.

The patients may present only with fibrosis of the fingers. The other pattern, diffuse cutaneous systemic sclerosis, involves the trunk in its early stages and facial involvement is uncommon. This type is often associated with more systemic involvements and a worse prognosis.

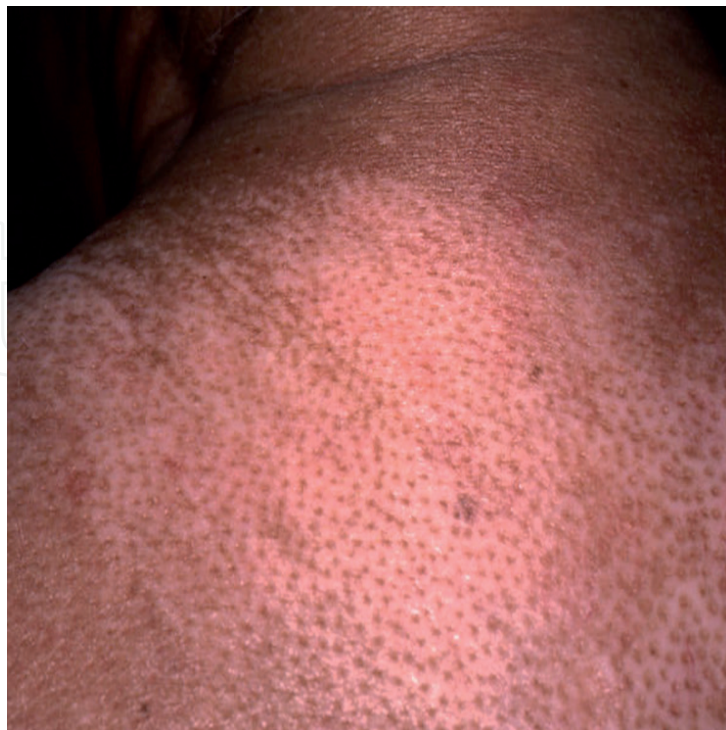Systemic sclerosis can cause diffuse hyperpigmentation that is exacerbated in sun-exposed areas, a specific manifestation of leukoderma. A combination of hypomelanosis and hypermelanosis can be present in the sclerotic and non-sclerotic skin areas of patients with systemic sclerosis, especially on their hands. Leukoderma emerging as complete depigmentation can be comorbid with supravenuous hyperpigmentation and perifollicular macules (**Figure 4**). This type of leukoderma can suggest suspected systemic scleroderma.

Histological examinations with an electron microscope shows complete or partial loss of melanocyte pigmentation coupled with degenerative changes.

It is actually a collagen vascular disease with some degree of cutaneous fibrosis that causes skin tightening.

### *2.3.4 Treatment*

Topical and intralesional steroids are recommended for the inflammatory stages. Topical tacrolimus, calcipotriol and imiquimod have been also used. Combination therapies used in the absence of responses include calcipotriol and betamethasone or imiquimod or low dose PUVA alone or with calcipotriol.



**Figure 4.**  
*“Salt and pepper” sign Leukoderma with the retention of perifollicular pigmentation in a patient with systemic sclerosis.*

## 2.4 Hypopigmented mycosis fungoides (HMF)

### 2.4.1 Introduction

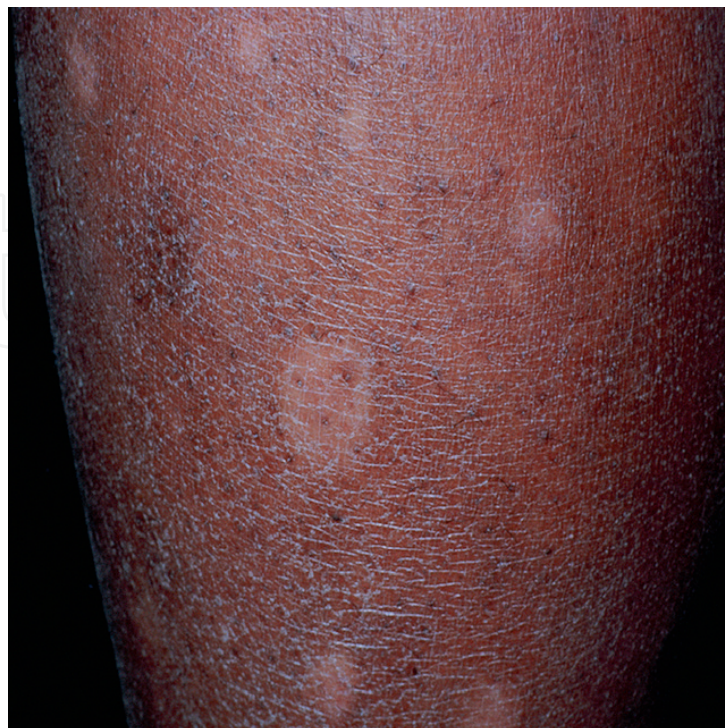
HMF is a variant of early MF, which is more prevalent in black individuals. HMF mostly affects ages of 30–40 years, although this type can involve 25–50% of children and adolescents. In fact, it is a prevalent type of MF in children. As a prevalent condition in the Middle East, HMF can be misdiagnosed as pityriasis alba or tinea versicolor in children. A study reported HMF in 18 out of 34 subjects and 29 out of 50 adolescents and children [7].

### 2.4.2 Pathogenesis

Mycosis fungoides is a cutaneous T-cell lymphoma with a major phenotype of C8+T cells and a pathogenic similarity to vitiligo. Given the absence of clinically hypopigmented lesions in the majority of patients with mycosis fungoides and T cells, presence of cytotoxic T cell phenotypes is not adequate for inducing hypopigmentation. Although electron microscopy shows melanosome degradation in melanocytes and keratinocytes, the large number of normal melanosomes found in melanocytes suggests a defect in melanosome transfer.

### 2.4.3 Clinical manifestations

Patients with mycosis fungoides may present with hypopigmented patches and plaques, usually associated with mild erythema and pruritus (**Figure 5**). The lesions are distributed more in the trunk and proximal areas of the limbs, especially in the non-exposed areas. Closer examinations show erythematous lesions.



**Figure 5.**  
*Mycosis fungoides, hypopigmented patches.*

#### *2.4.4 Treatment*

Repigmentation following treatments can be a sign of their effectiveness. Despite being the only manifestation of conventional mycosis fungoides, HMF is better in terms of its prognosis [8].

One year of treatment with a combination of steroids and tacrolimus, twice a week, was reported to significantly improve hypopigmented patches and cause no recurrence of lesions, and UVB phototherapy, 2–3 times a week, was found to yield proper responses [9].

### **2.5 Hypopigmented sarcoidosis**

#### *2.5.1 Introduction*

Hypopigmented sarcoidosis is a multisystem granulomatous disease that affects organs such as the lungs, eyes and skin as well as lymph nodes. The exact cause of hypopigmentation in sarcoidosis is unknown. Cutaneous manifestations have been reported in one-quarter to one-third of patients with systemic sarcoidosis. The prevalence of the lesions with different morphologies has been reported as high as 60% in black individuals. The prevalence is also twice in females than in males.

#### *2.5.2 Pathogenesis*

Sarcoidosis can be caused by autoimmune reactions or genetic processes given the existing racial and ethnic differences. HLA haplotype diversity patterns can explain different manifestations between different races. This disorder is histopathologically categorized as a granulomatous disease given the non-caseating granulomas found in the dermis. Electron microscopy also shows vacuolated melanocytes and decreases in the number of melanosomes in keratinocytes. Granulomas mainly include epithelioid cells and occasionally giant cells, with lymphocytic infiltration around granulomas in the absence of caseous necrosis.

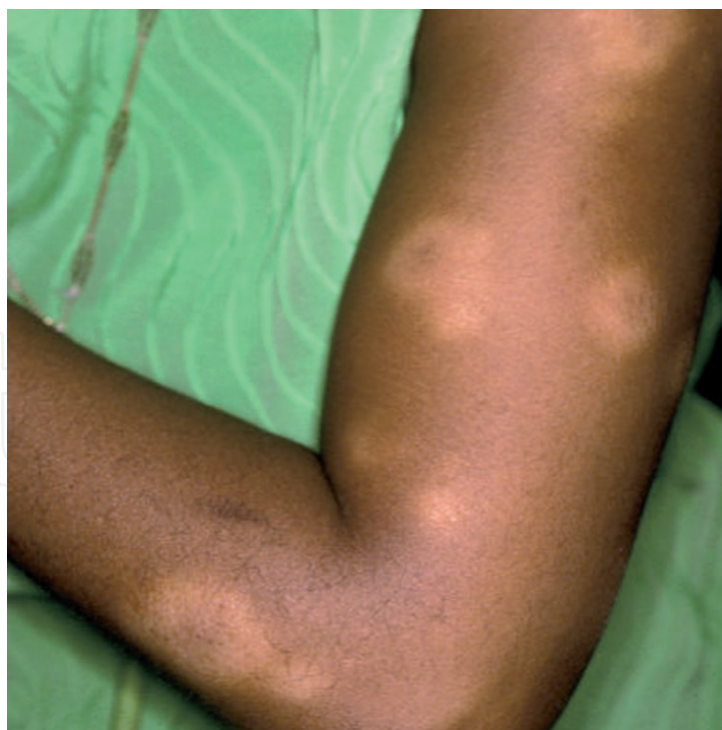#### *2.5.3 Clinical manifestations*

The most prevalent skin manifestations of sarcoidosis include small erythematous-violaceous papules 3–5 mm. Sarcoidosis often initiates in an acute state and then becomes chronic. With a peripheral scaly margin and a hypopigmented center (**Figure 6**), the annular lesions are usually limited to the head and neck with a poor prognosis. A rare cutaneous form with patches or plaques usually appearing 1–10 mm in size mainly involves the trunk and face. Erythematous papules in the center of the patches resemble a fried egg [10].

The patients are often asymptomatic and usually diagnosed through radiological examinations. A skin biopsy and pathological examinations may also be ultimately required.

#### *2.5.4 Treatment*

Although acute sarcoidosis is a self-healing condition, cutaneous sarcoidosis with systemic involvement can be treated with 1 mg/kg/day of prednisolone as an oral steroid to cleanse the skin lesions. The localized skin manifestations can be treated only with topical steroids or intralesional injections. Anti-TNF biologic medications can be used as alternatives to steroids, especially when steroids are



**Figure 6.**  
*Cutaneous sarcoidosis; clinical variants, the hypopigmented variant is more noticeable in individuals with a darkly-pigmented skin.*

contraindicated. Hypopigmented cutaneous sarcoidosis is responsive to minocycline [11] and can be treated with 8-methoxypsoralen [12] and long-wave ultraviolet light.

## 2.6 Lichen Striatus

### 2.6.1 Introduction

Lichen striatus is a benign self-limiting dermatosis with an unknown etiology. It is more prevalent in children than in other age groups, it is acquired and unilaterally occurs along the lines of blaschko. Although the lesions are often transient, they may be of a prolonged form.

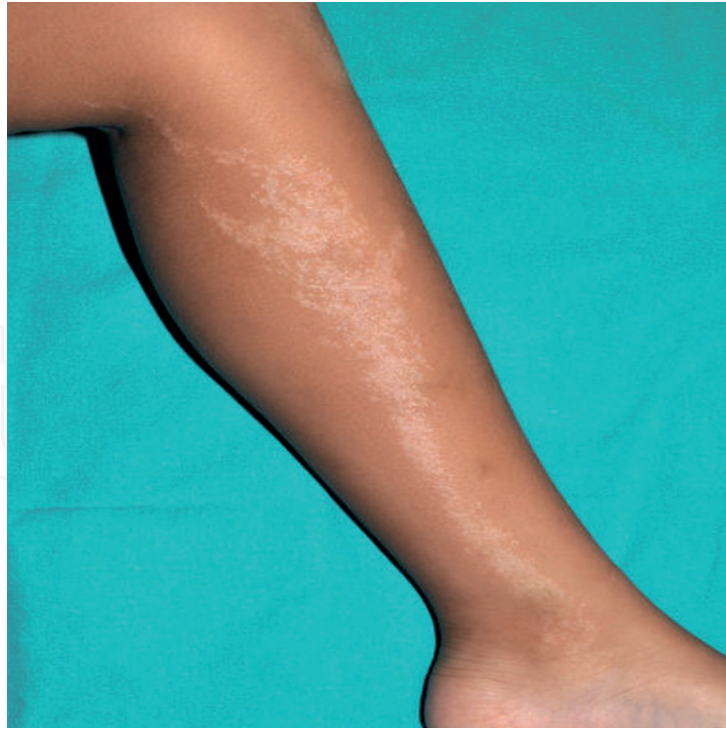Lichen striatus is associated with vitiligo or atopic dermatitis. It mainly affects children at an age of 3.5 years, although it may occur in children of 4 months to 10 years of age.

### 2.6.2 Clinical manifestations

Lichen striatus usually manifests itself as smooth and scaly or hypopigmented flat-topped papules, which are 2-4 mm in size and initially inflammatory (Figure 7). The lesions appear as continuous or interrupted flat papules along the lines of blaschko within 2–3 weeks. The eruptions, being mainly distributed in the limbs, especially the lower limbs, normally leave a long-lasting hypopigmentation in 50% of the cases. According to recent studies in India, lichen striatus causes hypopigmentation in approximately 1.7% of the patients [13].

### 2.6.3 Treatment

No treatments are normally required given the benign and self-limiting nature of the disease. Tacrolimus ointment has been found to speed up the relief and cause complete healing without skin sequelae.



**Figure 7.**  
*Lichen striatus: Linear streaks on the leg along the lines of Blaschko, comparing numerous small, flat-topped tan (hypopigmented) papules.*

### 3. Conclusion

Numerous inflammatory skin diseases can cause pigmentation disorders, which suggests that despite multiple inflammatory disease of skin, ultimately through the activation of inflammatory agents located in the skin, such as T cells, cytokines and other inflammatory cells that lead to dysregulation of melanogenesis system.

However, the exact mechanism of PIH is not known and further studies are needed. Despite advance in treating the cause of the hypomelanosis, but PIH is still a challenge for dermatologists. Appropriate treatment for PIH is to identify the underlying cause and treat it, with applying symptomatic therapy.

### Conflict of interest


The author declares no conflict of interest.

### Author details

Behzad Dalvand  
Artina Skin and Hair Clinic, Tehran, Iran

\*Address all correspondence to: dalvandb@yahoo.com

### IntechOpen

© 2021 The Author(s). Licensee IntechOpen. This chapter is distributed under the terms of the Creative Commons Attribution License (<http://creativecommons.org/licenses/by/3.0>), which permits unrestricted use, distribution, and reproduction in any medium, provided the original work is properly cited. 

## References

- [1] Bologna J, Shaffer J, Cerroni L. *Dermatology*. 4th ed. Toronto: Elsevier; 2018. 2880 p. ISBN: 9780702062759.
- [2] Dinalos J. Habib' clinical *Dermatology*. 7th ed. Toronto: Elsevier; 2020. 1086 p. E-ISBN: 9780323612708
- [3] Hoeger P, Kinsler V, Yan A, Harper J, Oranje A, Bodemer C, et al. Harper's *Textbook of pediatric Dermatology*. 4th ed. Blackwell: Willy; 2020. 2413 p. DOI:10.1002/9781119142812
- [4] Furst DE, Fernandes AVV, Lorga SR, Greth W, Bancroft T. Epidemiology of systemic sclerosis in a large US managed care population. *J Rheumatol*. 2012;89:784-786. DOI: 10.3899/jrheum.111106
- [5] Horimoto AMC, Matos ENN, da Costa MR, Takahashi F, Rezende MC, Kanomata LB, et al. Incidence and prevalence of systemic sclerosis in Compo Grande, São Paulo, Brazil. *Rev Bras Reumatol*. 2017;57:107-114. DOI: 10.1016/j.rbre.2016.09.005
- [6] Callen J, Jorizzo J, Zone J, Piette W, Rosenbach M, Vleugels RA. *Dermatological sign of systemic diseases*. 5th ed. Toronto: Elsevier; 2017. 480 p. ISBN: 9780323358293
- [7] Boulos S, Vaid R, Aladily TN, Ivan DS, Talpur R, Duvic M. Clinical presentation, immunopathology, and treatment of juvenile-onset mycosis fungoides; A case series of 34 patients. *J Am Acad Dermatol*. 2014;71(6):1117-1126. DOI:<https://doi.org/10.1016/j.jaad.2014.07.049>
- [8] Cerroni L. *Skin Lymphoma. The illustrated guide*. 4th ed. Chichester. Wiley-Blackwell; 2020. 425 p. ISBN: 9781119485919
- [9] Zaidi Z, Hussain K, Sudhakaran S. *Treatment of skin disease: A practical guide*. 1st ed. Switzerland: Springer; 2019. 551 p. DOI: 10.1007/978-3-319-89581-9
- [10] Condric RH, David J, Taylor SC. Sarcoidosis: Are there differences in your skin of color patients? *J Am Acad Dermatol*. 2012;66(1):121. DOI: 10.1016/j.jaad.2010.06.068
- [11] Schmitt CE, Fabi SG, Kukreja T, Feinberg JS. Hypopigmented cutaneous sarcoidosis responsive to minocycline. *J Drugs Dermatol*. 2012;11(3):385-9. PMID: 22395590
- [12] Patterson JW, Fitzwater JE. Treatment of hypopigmented sarcoidosis with 8-methoxypsoralen and long wave ultraviolet light. *Int J Dermatol*. 1982;21(8):476-80. DOI: 10.1111/j.1365-4362.1982.tb03187.x.
- [13] Chong JH, Mermin D, Goussot JF, Taieb A. Vitiligo co existing with lichen striatus: more than a co incidence? *J Eur Acad Dermatol Venereol*. 2017;31(4):e200-e202. DOI: 10.1111/jdv.13954.