

# We are IntechOpen, the world's leading publisher of Open Access books Built by scientists, for scientists

6,900

Open access books available

186,000

International authors and editors

200M

Downloads

Our authors are among the

154

Countries delivered to

TOP 1%

most cited scientists

12.2%

Contributors from top 500 universities



WEB OF SCIENCE™

Selection of our books indexed in the Book Citation Index  
in Web of Science™ Core Collection (BKCI)

Interested in publishing with us?  
Contact [book.department@intechopen.com](mailto:book.department@intechopen.com)

Numbers displayed above are based on latest data collected.  
For more information visit [www.intechopen.com](http://www.intechopen.com)



# Rolandic Epilepsy: Self-Limited Epilepsy with Centrotemporal Spikes

*Ulviyya Guliyeva, Nana Nino Tatishvili  
and Rauan Kaiyrzhanov*

## Abstract

Childhood epilepsy with centrotemporal spikes, had been previously considered as benign childhood epilepsy. According to the new classification proposed by Sheffer I. and colleagues the term “benign” has been changed to “self-limited”. Many studies reported that BECTS may cause transient or long lasting cognitive and behavioral disturbances. Rolandic epilepsy is the most frequent among the childhood focal epilepsy and may account for about 15–25% of all epileptic syndromes diagnosed between the ages of 5 to 15 years. The incidence range changes between 7.1–21 per 100000 in population younger than 15 years with male predominance. The age of onset in 90% of cases between 1 and 10 years with peak around 6–7 years. Seizures mainly occur during a night sleep, whereas the probability of awake seizures are less than 10%. The characteristic clinical features are: (1) focal motor seizure with unilateral orofacial tonic or clonic contractions; (2) speech arrest; (3) hypersalivation; (4) sensory symptoms represented by unilateral numbness or paresthesia of tongue, lips, gum and inner part of the cheek; (5) unilateral clonic jerk in leg and arm with postictal paresis; (6) generalized seizures. The EEG picture is distinctive in Rolandic epilepsy. The background activity is almost always preserved in awake state and during a sleep. The typical interictal EEG pattern is high voltage, diphasic spikes or sharp waves frequently with slow activity on central-midtemporal region. The centrotemporal spikes or rolandic spikes come from the lower rolandic region created a horizontal dipole with maximal electronegativity in the centrotemporal region and electropositivity in the frontal region usually seen unilateral or bilateral. In most cases children with RE have a good prognosis regarding both seizures and neurodevelopment. The remission of seizures usually occurs before the age of 18 years. The cognitive and behavior problem may happen in active period of disease which are reversible in most of patients.

**Keywords:** rolandic epilepsy, EEG, BECTS, epilepsy, atypical rolandic epilepsy, centrotemporal spikes, seizures, cognitive outcome

## 1. Introduction

Self-limited epilepsy with centrotemporal spikes (SECTS), well-known as Rolandic epilepsy is the most frequent among the childhood focal epilepsies and may account for about 15–25% of all epileptic syndromes diagnosed between the

ages of 5 to 15 years [1]. It is termed ‘rolandic’ epilepsy because the focal seizures are originated from the region around the lower part of the central gyrus of Rolando. The incidence range changes between 7.1–21 per 100000 in a population younger than 15 years with male predominance [2]. The age of onset in 90% of cases between 1 and 10 years with a peak around 6–7 years and recovery occurs before the age of 15–16 years [2–4].

Self-limited epilepsy with centrotemporal spikes is a syndrome of brief hemi-facial motor seizures, frequently having associated somatosensory symptoms, usually without impairment of consciousness which tend to evolve into GTCS [3–6]. Seizures are often related to sleep [7]. Genetic predisposition is frequent, and there is male predominance [3, 5, 8, 9]. An interictal EEG has normal background activity with biphasic high-voltage centrotemporal spikes, often followed by slow waves that are activated by sleep and tend to spread or shift from side to side [10]. Neurological and mental status before the debut of epilepsy is normal. There are no specific abnormalities on brain MRI or CT. Many studies reported that RE may cause transient or long-lasting cognitive and behavioral disturbances [4, 5, 11–40].

## **2. Terminology and classification**

Panayiotopoulos described a concept of benign childhood susceptibility syndrome (BCSSS) to unify RE, Panayiotopoulos syndrome (PS) and childhood occipital epilepsy of Gastaut (ICOE-G) outlined the common features, course of diseases, prognosis, and the possible genetic predisposition in this group of associated syndromes [5].

1989 ILAE classification recognized three “age-related and localization-related epilepsies and syndromes”: (1) benign childhood epilepsy with centrotemporal spikes (BCECTS); (2) childhood epilepsy with occipital paroxysms; (3) primary reading epilepsy [10].

ILAE Commission on Classification and Terminology lists three childhood idiopathic focal epilepsy syndromes: (1) benign childhood epilepsy with centrotemporal spikes (BCECTS); (2) Panayiotopoulos syndrome, and (3) late-onset childhood occipital epilepsy (Gastaut type) [13].

Rolandic epilepsy had undergone significant terminological and classification changes. RE had been previously considered as benign childhood epilepsy. Frequently reported cognitive and language impairments and behavioral disturbances in children with RE led to the replacement of the terms “benign” and “idiopathic” by the “self-limited” in the new classification proposed by Sheffer I. and colleagues [41].

## **3. Etiology**

The role of genetic factors in RE has been presumed since the first high incidence of centrotemporal spikes in family members of patients with RE was reported in 1964 [42]. RE and related syndromes with atypical features do not follow a Mendelian inheritance mode [43]. The clinical and genetic studies have shown complex inheritance [43–51].

The genetics of CTS is not the same as the clinical genetics of RE [52]. Although CTS is the primary EEG characteristics of RE or ARE, they are also observed in healthy children [53] or the children with autistic spectrum disorders without seizures [54]. Only 10% of EEG trait carriers had seizures [55, 56]. An autosomal dominant mode of

inheritance of CTS on EEG has been reported by several authors [42, 55, 56] but it is still debated [52]. The linkage of CTS to ELP4-PAX6 region on 11p13 and chromosome 15q13 [57], 16p12–11.2 [58], and 15q14 [59] have been identified.

Doose et al. investigated the broad spectrum clinical and EEG manifestation of 147 children with RE and their 1266 family members revealed a high incidence of febrile convulsion and afebrile GTCS in patients and their relatives suggested multifactorial inheritance. EEG recordings of probands and their siblings showed a high rate of generalized EEG traits [43].

A multicentral twin study of eighteen twin pairs (10 MZ, 8 DZ) based on a twin database done by Vadlamudi and colleagues demonstrated that the etiology of RE and its inheritance mode is much more complicated than considered before [44]. No twin pairs were concordant for RE. Only one monozygotic twin pair has shown centrotemporal spikes on EEG without seizures. Another intriguing finding from this twin data was that all twin pairs with atypical features RE, had a co-twin with seizures although discordant for RE, which emphasized that genetic factors may be more important in atypical cases of RE.

Mutations	Protein function	Special features	Reports
KCNQ2/KCNQ3	Voltage-gated potassium channel	BFNS plus RE	Maihara et al. [62]
		BFNS CTS trait	Coppola et al. [63]
		BFNS plus RE, RE, CTS trait	Neubauer et al. [64]
SRPX2	E2A/HLF fusion	RS, oral and speech dyspraxia, MR	Roll et al. [65]
ELP4	Elongator subunit	CTS trait, speech disorder, behavior disturbances, ADHD	Strug et al. [57]
GRIN2A	NMDAR subunit	Atypical RE (LKS/CSWS), intellectual disability, various dysmorphic features	Lemke et al. [66]
RBFXO1/3	ATAXIN 2-BINDING PROTEIN 1/HEXARIBONUCLEOTIDE-BINDING PROTEIN 3	RE, atypical RE, CTS trait	Lal et al. [67]
DEPDC5	GATOR complex	RE, atypical RE	Lal et al. [50]
GABRG2	GABA receptors	RE, atypical RE	Reinthalder et al. [68]
CAMK2A	Subunit of calcium/calmodulin-dependent protein kinase II	Atypical RE, intellectual disability and autism	Rudolf et al. [45]
GRIN2B	NMDAR subunit	Atypical RE, epileptic encephalopathy, intellectual disability	Rudolf et al. [45]
CHRNA4	Neuronal nicotinic acetylcholine receptor $\alpha$ 4 subunits	RE (familial case)	Neng et al. [69]

**Table 1.**  
*Genetic mutations associated with RE/ARE spectrum.*

The genetic basis of RE/ARE is polygenic and complex, the interaction of environmental factors or other genes should be considered in etiology of RE spectrum epilepsy syndromes [60, 61]. A number of genes were found to follow the Mendelian inheritance and be associated with RE/ARE (**Table 1**).

Lemke et al., have identified GRIN2A mutations in 20% of patients with ARE associated with neurocognitive disturbances [66].

Although mutations in PRRT2, KCNQ2, KCNQ3, RBFOX1, and DEPDC5 genes with an autosomal dominant transmission reported in patients with RE spectrum epilepsy syndromes, they have not been confirmed by the studies based on large case series [70].

With the exception of GRIN2A and ELP4, many genes currently associated with RE/ARE, including KCNQ2, KCNQ3, CHRNA4, DEPDC5, RBFOX1/3, BDNF, and GABAA-R, were initially linked to other neurogenetic conditions, and later their phenotypes were expanded to RE/ARE.

#### 4. Clinical features

The main seizure type in RE according to the ILAE 2017 seizure classification is focal aware seizure consisting of motor-hemifacial tonic or clonic contractions, oro-pharyngo-laryngeal symptoms, sensory symptoms represented by unilateral numbness or paresthesia of tongue, lips, gum, and inner part of the cheek, and associated with speech arrest, hypersalivation, and focal to bilateral seizures [2–4, 41, 71]. Hemiconvulsions and bilateral tonic-clonic seizures are less frequently observed ictal features, mainly seen in younger children due to rapid distribution of focal onset seizures [2–4, 6]. Hemiconvulsions may be followed by post-ictal Todd's hemiparesis in 10% of cases [8, 72].

Seizures are brief, usually last from 30 sec to 2–3 minutes or longer if turn into bilateral tonic-clonic seizures [6, 18, 72]. Seizures mainly occur during night sleep or drowsiness, whereas the probability of awake seizures is less than 10% [73, 74]. Seizure frequency is low, most patients have less than 10 seizures, 10%–20% of patients have a single seizure [75]. Consciousness is completely preserved in around 60% of patients with RE [5].

**Focal motor seizures** in approximately one-third of cases manifest as unilateral oral-facial tonic or clonic contractions. These are brief (few seconds –1 min), a sudden burst of clonic contractions of the face, which may be entirely localized in the lower lip or spread to the ipsilateral upper and very rare to the lower extremities [1–5, 71, 76].

Tonic deviation of the mouth is frequently observed ictal motor manifestation [5].

**Oro-pharyngo-laryngeal symptoms** are mostly motor ictal phenomena with the involvement of the (epi-) glottis and pharynx (> 50%) produce guttural bizarre sounds, resembling gargling, grunting, wheezing [72]. These may be accompanied by contractions of the respiratory and abdominal muscles (vomiting like contractions) which appear in more than half of seizures [77]. They consist of unilateral sensory and motor manifestations inside the mouth, tongue, inner cheek, gums, teeth, and pharyngolaryngeal regions [3].

**Speech arrest** occurs in >40% of seizures with dys - or anarthria [3, 72]. The child usually is aware, with preserved receptive language, attempts to communicate with gestures, but unable to produce a single intelligible word [3, 5]. Speech arrest is considered more as a motor ictal manifestation associated with the loss of the power and coordination for the articulation of words [3]. There is no impairment of the cortical language mechanisms [4, 5].

**Focal non-motor seizures** commonly observed in RE.



*Sensory symptoms* may manifest as unilateral numbness or paraesthesias like tingling, prickling, freezing and their variations in the parts (rarely involve the whole area) of oral-facial-pharyngeal area, usually tongue, inner cheek, gum, teeth, lips [3, 4, 6]. Sensory seizures often occur in combination with motor seizures and hypersalivation [3, 5, 72].

*Hypersalivation* is one of the most characteristic autonomic ictal symptoms of RE, occurs in one-third of cases [2–5, 71]. It is frequently associated with hemifacial motor symptoms. As well as the awareness is not disturbed in most of the cases, children usually are able to describe their sensations as sudden filling of the mouth with saliva and air, difficulty in pronouncing words, a lot of saliva flowing from the mouth [5].

Other autonomic ictal manifestations as *ictal emesis* and *ictal syncope* may observe rarely in RE. Although autonomic seizures are the cardinal symptom of Panayiotopoulos syndrome, they are reported in RE [74, 78–82]. The overlap of the clinical and EEG features of PS and RE has been widely investigated by several authors [5, 74, 79, 80]. The cases where two different types of childhood focal seizures presented at the same time or one form of epilepsy progressed to another have been thoroughly reported by different investigators [74, 79–85].

**Focal to bilateral tonic-clonic seizures** are a frequent seizure type present in one to two-thirds of children with RE. FBTCs mostly appear during night sleep [86].

**Status epilepticus** is seen rarely and usually associated with an atypical course of the disease [87].

Focal motor SE occurs more often than generalized convulsive SE [3]. This state consists of unilateral or bilateral hemifacial contraction, subtle perioral myoclonus, speech arrest, dysarthria, excessive drooling, swallowing difficulties [88–93].

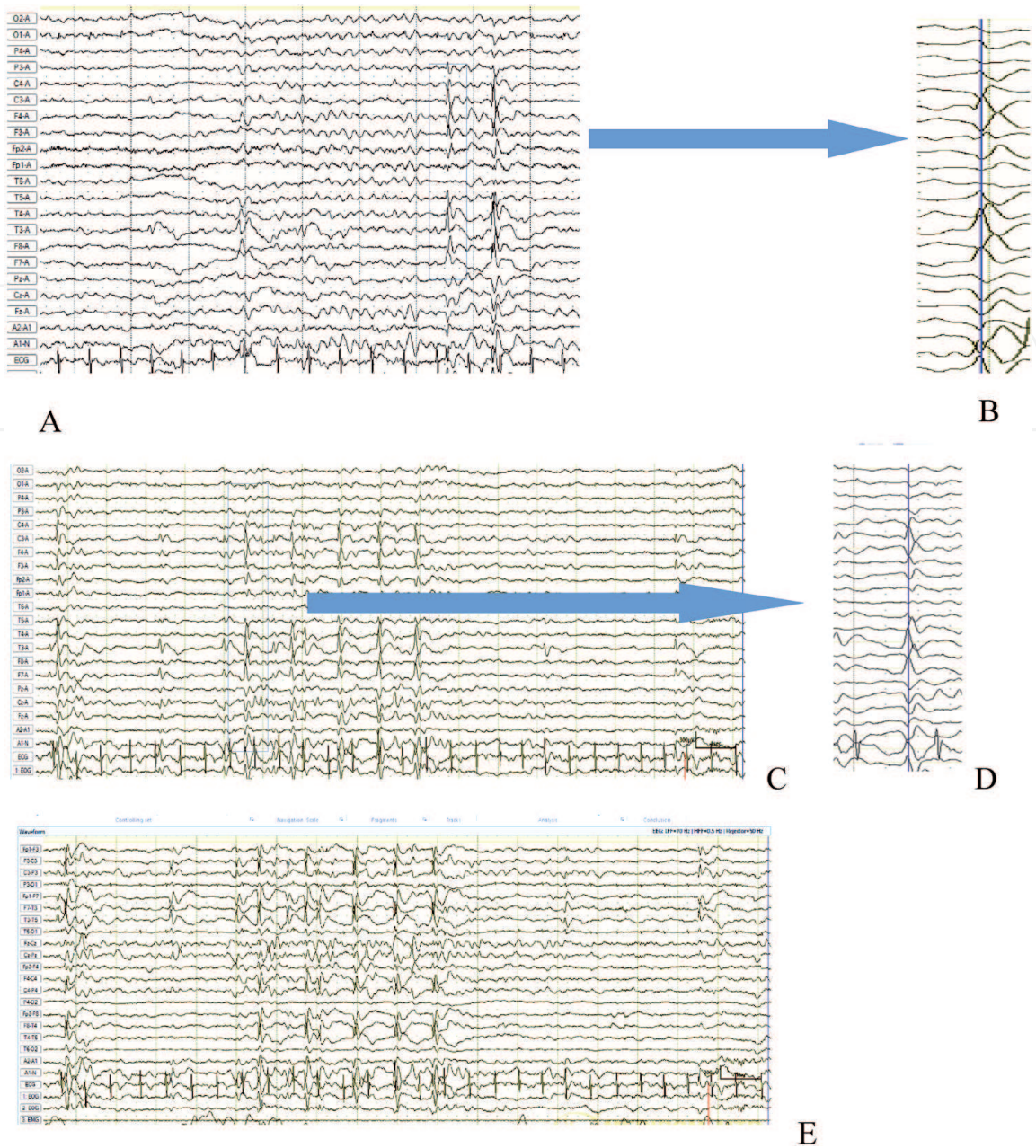
## 5. EEG patterns

### 5.1 Interictal EEG

The EEG picture is distinctive in Rolandic epilepsy. The background activity is almost always preserved in an awake state and during sleep [91]. The characteristic interictal EEG pattern- centrotemporal spikes (CTS) or rolandic spikes are regarded as the neurobiological markers of RE. CTS is high-amplitude (usually > than 150 mkV) biphasic spikes or sharp waves of ~ 70–80 milliseconds duration frequently followed by a slow activity on the central-mid temporal region (C3/C4, T3/T4) [2–4]. More posterior localization of CTS is often observed in the youngest patients [94]. The spikes may occur isolated or in clusters, in one or both hemispheres [95, 96] (**Figure 1A** and **B**). A focal rhythmic slow activity over the centrotemporal region is occasionally observed [2]. The most typical finding of the rolandic spikes is their significant increase in frequency during NREM sleep [74] (**Figure 1C–E**). The spikes appear only in sleep in about a third of children [97].

EEG and magnetoencephalography (MEG) studies show a stable horizontal dipole coming from the lower rolandic region with maximal electronegativity in the centrotemporal region and electropositivity in the frontal region, usually seen unilateral or bilateral [98–100]. Spikes may often appear in the central, parietal, midline, or even occipital regions which do not exclude a diagnosis of RE [98].

Somatosensory stimulation by the tapping of hands or feet or electrical stimulation of fingers at 1 Hz may activate CTS and somatosensory evoked potentials (SEPs) on the contralateral hemisphere [101].



**Figure 1.** 7y-old boy with rolandic epilepsy. (A) Interictal awake EEG. Left centrotemporal spikes with rapid spreading to the right frontal-anterior temporal region. with maximum negativity over the C3T3,F7 and maximum positivity on the right-midline frontal-parietal region F4Fp2FzPzCz (AV montage, sensitivity 20Mkv/mm, paper speed 30mm/sec, LFF 70 Hz, HFF 0.5 Hz, Rejector 50 Hz). (B) Increased paper speed clearly demonstrates propagation of left centrotemporal spikes to the right frontal-anterior temporal region (AV montage, sensitivity 20 Mkv/mm, paper speed 120 mm/sec, LFF 70 Hz, HFF 0.5 Hz, Rejector 50 Hz). (C and D) Interictal 1NREM sleep EEG. The frequency of CTS of the same distribution is increased. (E) The same EEG sample in bipolar longitudinal montage demonstrates phase reversal on both right and left centrotemporal region (C3C4T3T4).

Brief interictal generalized bursts of 3–5 Hz slow waves with intermixed small spikes distinctive than a pattern 3 Hz spike–wave seen in CAE may observe in about 4% of patients with RE [85, 102].

Many studies have tried to identify the source of rolandic discharges using topographic analysis, source modeling techniques, dipole tracing method, magnetoencephalography (MEG), and functional MRI (fMRI) investigations [99–101, 103–106]. The functional MRI (fMRI) triggered by EEG of the rolandic spikes as well as MEG showed activation of the sensorimotor area [104], mainly in the orofacial division of the primary sensorimotor cortex [105]. However, it



is challenging to distinguish the precentral or postcentral origin of CTS [103]. Ishitobi et al., suggested the precentral origin of rolandic spikes explained this theory by the continuity of cortical surface polarity from negative gyral cortex to the surface positive interhemispheric fissure based on the combination of scalp EEG and MEG [103]. Gregory and Wong analyzed 12 independent foci in 10 patients with RE assumed that the generator of a dipole discharge was located halfway between the maximum negative and positive poles, and was most likely situated at the depth of the lower rolandic fissure or Sylvian fissure [107]. The propagation pattern of rolandic spikes first studied by Jung et al., suggests that spike propagation was caused by intracortical spreading a single dipole across the central sulcus [108].

CTS are diagnostic markers of RE only in a suggestive clinical presentation [74]. It has been widely reported that 1.2 to 3.5% of normal healthy children population between 5 and 12 years old [109, 110], 6–34% of siblings and relatives of patients affected by RE [9, 111, 112], children with migraine, behavior disturbances, ADHD, variety of organic brain diseases with or without seizures, such as cerebral tumors, Rett syndrome, fragile X syndrome and focal cortical dysplasia [84, 113] also show CTS in routine EEG recording.

## 5.2 Ictal EEG

The first described ictal patterns are characterized by a quite monomorphic sequence of rhythmic sharp waves or spikes without significant post-ictal slowing [91, 114]. In 1990, Gutierrez et al. described an ictal event with speech arrest only characterized by a short train of ictal alpha activity, and then two multiple spikes and wave complexes originated from the left centrotemporal region followed by marked attenuation of the left hemispheric background [115]. Subclinical rhythmic discharges of spike and wave in the centrotemporal region have been documented by several authors in RE [116, 117]. Saint-Martin et al. in 2001 described a series of patients presenting with typical and also atypical ictal manifestations such as falls, negative myoclonus and observed that positive motor phenomenon correlated to the spike component preceding a negative motor phenomenon, correlated with the slow-wave component of the spike and wave complex [118].

Capovilla et al. recorded 34 seizures in 30 patients with RE and described four electrographic seizure patterns thus emphasizing that ictal pattern for RE is not unique [116]:

- low-voltage activity of fast rhythmic spikes, increasing in amplitude and decreasing in frequency observed in the majority of patients,
- a discharge of spikes intermixed with sharp waves increasing in frequency and amplitude,
- monomorphic theta which progressively formed a discharge increasing in amplitude and decreasing in frequency,
- initial focal depression of the electrical activity, followed by one of the three above described patterns.

Ictal EEG source analysis of 3 patients with RE demonstrated the activation of the opercula-insular area, time-locked to the contralateral focal myoclonic jerks [119].



## **6. Prognosis**

In most cases, children with RE have a good prognosis regarding both seizures and neurodevelopment [120, 121]. The remission of seizures usually occurs before the age of 18 years [11, 98]. The cognitive and behavior problem may happen in an active period of disease which is reversible in most patients [11, 12].

Rolandic seizures occur in a period of significant brain maturation. The dysfunction of neuronal network activities such as focal discharges may be associated with neuropsychological problems, including, linguistic, cognitive, and behavioral impairment [28–30, 122]. The frequent spike discharges in sleep may boost language and attention processing problems [120, 123–125].

Mood and behavioral disorders were present in nearly a third of children (30.9%) with RE [126–128]. Retrospective studies have proposed that early age at onset pretends a more aggressive seizure course [18, 129–131].

Functional MRI study revealed CTS density caused hemodynamic changes even during wakefulness can interfere with the normal brain-language network and the bilateral insular cortex [132].

The neuropsychological tests such as Wechsler Intelligence Scale for Children-III (WISC-3rd), verbal fluency test, Wisconsin card sorting test, attention deficit diagnostic scale, and child behavior checklist scale are usually administered to measure a wide range of skills and cognitive functions of RE patients [35–38, 133].

Many researchers showed a variety of neuropsychological deficits, behavioral and emotional difficulties in a limited cohort of patients with RE range from 19 to 67% [22–40, 134, 135]. The series of reported children with uncomplicated RE were described lower average results on neuropsychological tests involving visuo-motor coordination, some executive functions, sustained attention, and language issues like spelling, reading aloud, reading comprehension, memory, and learning of auditory-verbal material, delayed recall, and verbal fluency, compared with controls. However, the Full-Scale Intelligence Quotient (FSIQ) was not significantly low in most of them.

D'Alessandro et al. investigated the neuropsychological data of 44 children with RE who did not have a seizure for more than 6 months without treatment. Attention, language, and visuospatial coordination tasks problems were more severe in children with a bilateral epileptiform discharge. However, in a follow-up assessment for 4 years, a re-examination of 11 children had revealed the normalization of cognitive functions in all [21].

Several studies reported that cognitive abnormalities and behavioral impairments are associated with a high interictal spike frequency [24, 25, 35, 120], the number of interictal abnormalities in wake or sleep [136], activation of interictal spikes during sleep [118, 137], and the presence of non-tangential dipole spikes [73].

Piccinelli et al. [138], investigated the frequency of specific learning disabilities such as reading, writing, and calculation in patients with typical RE and possible related electroclinical findings. They reported children with RE who developed seizures before age 8 years and had epileptiform discharges more than 50% of the sleep EEG recording in several tracings over more than a year were at risk of developing academic difficulties [138].

EEG may predict educational and behavioral impairments in children with RE. The presence of an intermittent slow-wave focus during wakefulness, a high number of spikes in the first hour of sleep (and during whole night sleep), and multiple asynchronous bilateral spike-wave foci in the first hour of sleep are associated with learning problems in children with RE [16, 139].

## 7. Atypical rolandic epilepsy

RE can present or evolve to an atypical form, characterized by atypical ictal semiology, different EEG findings, and poor neuropsychological outcomes [19, 140, 141].

Massa et al. described 5 interictal EEG patterns that significantly correlated with atypical evolutions of RE: [41] intermittent slow-wave focus; [2] multiple asynchronous spike-wave foci; [3] long spike-wave clusters; [4] generalized 3-c/s “absence-like” spike-wave discharges; [1] conjunction of interictal paroxysms with negative or positive myoclonia, and abundance of interictal abnormalities during wakefulness and sleep [136].

Several studies have shown an association between atypical rolandic epilepsy and known genes (**Table 1**). The identification of de novo or inherited mutations of N-methyl-D-aspartate (NMDA) receptor subunit-encoding genes (GRIN2A and GRIN2B) linked to speech and language, cognitive impairment, and behavioral difficulties have been a significant breakthrough in the understanding of the nature of atypical RE [142–145]. Another relevant gene is elongation factor protein 4 (ELP4), which is associated with language impairment, autism spectrum disorder, mental retardation, and epilepsy with centrottemporal spikes on EEG [146].

**Atypical rolandic epilepsy (ARE)** is a severe epileptic condition especially with regards to cognitive consequences. The first description of atypical features of RE was published by Aicardi & Chevrie in 1982 showed rolandic epilepsy presenting periods with new types of seizures, mainly atonic and myoclonic, associated with continuous spike-and-waves in slow-sleep EEG (CSWS/ESES), and transitory learning difficulties [147]. Dooze and Baier described similar patients with atonic fits leading to daily falls which is the hallmark seizure type for Lennox–Gastaut syndrome and termed the condition “pseudo-Lennox syndrome” to differentiate this two distinct conditions [148]. Patients with ARE have significantly lower full-scale and verbal IQ than the patients with typical RE [149]. Neuropsychological impairment, which may sometimes be present before the onset of the disease, is constantly present during the clinical course, but in contrast to ESES and LKS, the cognitive outcome is always favorable [92, 150]. Clinical semiology consists of typical for RE focal seizures, generalized tonic-clonic seizures, atypical absences, myoclonic seizures, and atonic seizures. The atonic attacks may involve the whole axial musculature or be localized, causing repeated brief (0.5–2.0 s) atonic episodes in the head or a limb (epileptic negative myoclonus) that usually occur for periods lasting one to several weeks, separated by seizure-free intervals of weeks or months [6, 90, 92]. Such atonic attacks are associated with the slow-wave component of spike and wave complexes, and the location of the EEG discharges corresponds to that of the atonic episodes [151, 152]. Interictal awake EEG shows bilateral sharp and sharp-slow wave complexes with higher amplitude in the rolandic area, which increases during sleep with bilateral synchronization [90, 92, 116, 153].

Using carbamazepine may promote the diffusion of spike-wave activity from the rolandic focus to induce atonic seizures, atypical absences in patients with RE [154].

**Rolandic status epilepticus** refers to status epilepticus that can be convulsive or non-convulsive, and either generalized or focal lasting days or weeks including motor facial seizures, oromotor dyspraxia, anarthria with persistent drooling and swallowing problems [155]. The interictal EEG usually shows focally or bilaterally synchronous sharp waves or sharp and slow wave complexes predominant in the rolandic area with a tendency to become continuous during sleep [146, 155]. The condition can be resolved with a good neurocognitive outcome with appropriate treatment [146]. These seizures can persist for more than 1 month without treatment [156, 157].

## **8. Treatment**

The decision whether to treat children with RE or not requires a particularly careful risk–benefit analysis [2, 158–163]. Many authors suggest that drug treatment is not necessary for typical RE because of its good prognosis, and usually infrequent nocturnal seizures [114, 154]. Moreover, in 40–50% of cases, the seizures are difficult to control with drugs [148]. Besides, the treatment with AED usually does not influence the duration of active epilepsy [163].

However, treatment may be indicated in patients with frequently recurring day-time seizures, generalized tonic–clonic seizures, young age at onset [164], or when the ictal events are disruptive to the patient or family [161, 163]. Furthermore, the presence of cognitive and behavioral disturbances, either transitory or persistent has to be considered [2, 5, 91, 92]. There is no single solution supported by definitive evidence which AED is more effective in the treatment of RE.

Internationally, carbamazepine (CBZ 20–40 mg/kg/d [165]) and valproate (VPA 20–30 mg/kg/d [166]) are the most often prescribed AED for children newly diagnosed RE [167]. However, the possible worsening of EEG in rolandic epilepsy by some drugs and particularly by CBZ, increasing epileptiform abnormalities during sleep, and inducing epileptic negative myoclonus have been reported [154].

Sulthiame, levetiracetam, and gabapentin were studied in a randomized controlled trial [158, 159, 167–169]. Sulthiame administered varied between 3.1 and 5.7 mg/kg/day was effective in controlling seizures in children with RE [159].

A prospective, open-label, pilot trial evaluating the efficacy and tolerability of levetiracetam (LVT 20–30 mg/kg/d) or oxcarbazepine (OXC 20–35 mg/kg/d) as monotherapy in two parallel groups of newly diagnosed RE patients demonstrated effectiveness in controlling seizures a follow-up period up to 2 years [162].

A randomized controlled multicenter trial comparing the effects of either Levetiracetam or Sulthiame on EEG in RE showed a reduction of epileptiform discharges after 12 weeks of treatment [158]. Persistent epileptiform discharges after 12 weeks of treatment are associated with recurrent seizures [158].

When the presence of ESES associated or not with negative myoclonus, clinical status, or acquired aphasia is detected in children with RE, a change of antiepileptic drugs should be considered. Class IV studies suggest that sulthiame, benzodiazepines, ethosuximide, and, in most severe cases, corticosteroids might be useful [91, 92].

Duration of treatment in RE should not exceed 1 year following the last seizure, regardless of EEG changes [2].

## **Acknowledgements**

We are grateful to Dr. Sándor Beniczky for his valuable comments on EEG figures.

## **Disclosure**

None of the authors has any conflict of interest to disclose.



IntechOpen

## Author details

Ulviyya Guliyeva<sup>1\*</sup>, Nana Nino Tatishvili<sup>2</sup> and Rauan Kaiyrzhanov<sup>3</sup>

<sup>1</sup> MediClub Hospital, Baku, Azerbaijan

<sup>2</sup> Neuroscience Department, Central Children Hospital, Tbilisi, Georgia

<sup>3</sup> Department of Neurogenetics, Institute of Neurology, UCL, London, England

\*Address all correspondence to: [doctor.ulya@gmail.com](mailto:doctor.ulya@gmail.com)

## IntechOpen

© 2021 The Author(s). Licensee IntechOpen. This chapter is distributed under the terms of the Creative Commons Attribution License (<http://creativecommons.org/licenses/by/3.0>), which permits unrestricted use, distribution, and reproduction in any medium, provided the original work is properly cited. 

## References

- [1] Hauser WA, Annegers JF, Kurland LT. Incidence of epilepsy and unprovoked seizures in Rochester, Minnesota: 1935-1984. *Epilepsia*. 1993 May-Jun;34(3):453-468. doi: 10.1111/j.1528-1157.1993.tb02586.x. PMID: 8504780.
- [2] Federico Vigevano, Nicola Specchio, Natalio Fejerman, Chapter 61 - Idiopathic focal epilepsies, Editor(s): Olivier Dulac, Maryse Lassonde, Harvey B. Sarnat, Handbook of Clinical Neurology, Elsevier, Volume 111, 2013, p. 591-604
- [3] Koutroumanidis M, Panayiotopoulos CP. Benign childhood seizure susceptibility syndromes. In: Rugg-Gunn RJ, Smalls JE, editors. From channels to commissioning – a practical guide to epilepsy. London: International League Against Epilepsy (UK Chapter) and Epilepsy Society; 2015. p. 89-113.
- [4] Chrysostomos P. Panayiotopoulos, Michelle Bureau Roberto H. Caraballo, Bernardo Dalla Bernardina, Thalia Valeta. Idiopathic childhood focal epilepsies. In: Michelle Bureau, Pierre Genton, Charlotte Dravet, Antonio, Delgado-Escueta, Carlo Alberto Tassinari, Pierre Thomas, Peter Wolf, *Epileptic Syndromes in Infancy, Childhood and Adolescence – 5th updated edition*, JOHN LIBBEY EUROTTEXT, 2012. p. 217-224
- [5] Panayiotopoulos CP. Benign childhood partial epilepsies: benign childhood seizure susceptibility syndromes. *J Neurol Neurosurg Psychiatry*. 1993 Jan;56(1):2-5. doi: 10.1136/jnnp.56.1.2. PMID: 8429319; PMCID: PMC1014755.
- [6] Guerrini R, Pellacani S. Benign childhood focal epilepsies. *Epilepsia*. 2012 Sep;53 Suppl 4:9-18. doi: 10.1111/j.1528-1167.2012.03609.x. PMID: 22946717.
- [7] Deb.K.PaI et al, Idiopathic focal epilepsies: the “lost tribes”. *Epileptic Disorder* 2016,18(3):252-288
- [8] Shields W, Snead 3rd O. Benign epilepsy with centrotemporal spikes. *Epilepsia* 2009; 50:10-15. <https://doi.org/10.1111/j.1528-1167.2009.02229.x>.
- [9] Bray PF, Wiser WC. Hereditary characteristics of familial temporal-central focal epilepsy. *Pediatrics* 1965;36:207-211.
- [10] Commission on Classification and Terminology of the International League Against Epilepsy, 1989. Proposal for revised classification of epilepsies and epileptic syndromes *Epilepsia* 1989;30:389-399
- [11] Petra MC.Callenbach et.al, Long term outcome of benign childhood epilepsy with centrotemporal spikes: Dutch study of epilepsy in childhood. *Seizure* (19) 2010, 501-506
- [12] P.Piccinelli et al, Academic performance of children with Rolandic epilepsy. *Developmental medicine and Child Neurology*, 50; 353-356, 2008
- [13] Berg, A. T., Berkovic, S. F., Brodie, M. J., Buchhalter, J., Cross, J. H., van Emde Boas, W., ... Scheffer, I. E. (2010). Revised terminology and concepts for organization of seizures and epilepsies: Report of the ILAE Commission on Classification and Terminology, 2005-2009. *Epilepsia*, 51(4), 676-685. doi:10.1111/j.1528-1167.2010.02522.x
- [14] H. Goldberg-Stern et al, Neuropsychological aspects of benign childhood epilepsy with centrotemporal spikes. *Seizure* 19 (12-16), 2010
- [15] Sabine Völkl-Kernstock et al, Speech and school performance in children with benign partial epilepsy with centro-temporal spikes (BCECTS). *Seizure* 18 (320-326), 2009

- [16] Joost Nicolai et al, EEG Characteristics Related to Educational Impairments in Children with Benign Childhood Epilepsy with Centrottemporal Spikes. *Epilepsia*, 48(11):2093-2100, 2007
- [17] Beaussart M, Faou R. Evolution of epilepsy with rolandic paroxysmal foci: a study of 324 cases. *Epilepsia* 1978;19:337-342
- [18] Loiseau P, Duché B, Cordova S, et al. Prognosis of benign childhood epilepsy with centrottemporal spikes: a follow-up study of 168 patients. *Epilepsia* 1988;29:229-235.
- [19] Piccirilli M, D\_Alessandro P, Tiacci C, et al. Language lateralization in children with benign partial epilepsy. *Epilepsia* 1988;29:19-25.
- [20] D\_Alessandro P, Piccirilli M, Tiacci C, et al. Neuropsychological features of benign partial epilepsy in children. *Ital J Neurol Sci* 1990;11:265-269.
- [21] D\_Alessandro P, Piccirilli M, Sciarma T, et al. Cognition in benign childhood epilepsy: a longitudinal study. *Epilepsia* 1995;36(Suppl. 3):S124.
- [22] Piccirilli M, D\_Alessandro P, Sciarma T, et al. Attention problems in epilepsy: possible significance of the epileptic focus. *Epilepsia* 1994;35:1091-1096.
- [23] Morooka K, Arimoto K, Takagi K, et al. Developmental disabilities in benign childhood epilepsy with centrottemporal spikes. *Epilepsia* 1995;36(Suppl. 3):S127.
- [24] Weglage J, Demsky A, Pietsch M, et al. Neuropsychological, intellectual, and behavioral findings in patients with centrottemporal spikes with and without seizures. *Dev Med Child Neurol* 1997;39:646-651.
- [25] Staden U, Isaacs E, Boyd SG, et al. Language dysfunction in children with rolandic epilepsy. *Neuropediatrics* 1998;29:242-248.
- [26] Croona C, Kihlgren M, Lundberg S, et al. Neuropsychological findings in children with benign childhood epilepsy with centrottemporal spikes. *Dev Med Child Neurol* 1999;41:813-818.
- [27] Gunduz E, Demirbilek V, Korkmaz B. Benign rolandic epilepsy: neuropsychological findings. *Seizure* 1999;8:246-249.
- [28] Metz-Lutz MN, Kleitz C, De Saint-Martin A, et al. Cognitive development in benign focal epilepsies of childhood. *Dev Neurosci* 1999;21:182-190.
- [29] Deonna T, Zesiger P, Davidoff V, et al. Benign partial epilepsy of childhood: a longitudinal neuropsychological and EEG study of cognitive function. *Dev Med Child Neurol* 2000;42:595-603.
- [30] Yung AWY, Park YD, Cohen MJ, et al. Cognitive and behavioural problems in children with centrottemporal spikes. *Pediatr Neurol* 2000;23:391-395.
- [31] Chevalier H, Metz-Lutz MN, Segalowitz SJ. Impulsivity and control of inhibition in benign focal childhood epilepsy (BFCE). *Brain Cogn* 2000;43:86-90.
- [32] Schouten A, Oostrom K. Cognition and behaviour of schoolchildren with newly diagnosed idiopathic or cryptogenic epilepsy. Thesis, University Utrecht, 2001.
- [33] Nicolai J, Aldenkamp, A. P., Arends, J., Weber, J. W., & Vles, J. S. H. (2006). *Cognitive and behavioral effects of nocturnal epileptiform discharges in children with benign childhood epilepsy with centrottemporal spikes*. *Epilepsy & Behavior*, 8(1), 56-70. doi:10.1016/j.yebeh.2005.08.016
- [34] Hommet C, Billard C, Motte J, et al. Cognitive function in adolescents and



young adults in complete remission from benign childhood epilepsy with centro-temporal spikes. *Epileptic Disord* 2001;3:207-216.

[35] Fonseca LC, Tedrus GM, Tonelotto JM, et al. School performance in children with benign childhood epilepsy with centrottemporal spikes. *Arq Neuropsiquiatr* 2004;62:459-62. Epub 2004 jul.

[36] Lingren A, Kihlgren M, Melin L, et al. Development of cognitive functions in children with rolandic epilepsy. *Epilepsy Behav* 2004;5:903-910.

[37] Volkl-Kernstock S, Willinger U, Feucht M. Cognitive disabilities of children with a benign partial epilepsy. *Neuropediatrics* 2004;35. doi:10.1055/s-2004-819383.

[38] Monjauze C, Tuller L, Hommet C, et al. Language in benign epilepsy with centro-temporal spikes abbreviated form: Rolandic epilepsy and language. *Brain Lang* 2005;92:300-308.

[39] Papavasiliou A, Mattheou D, Bazigou H, et al. Written language skills in children with benign childhood epilepsy with centrottemporal spikes. *Epilepsia Behav* 2005;6:50-58.

[40] Northcott E, Connolly AM, Berroya A, et al. The neuropsychological and language profile of children with benign Rolandic epilepsy. *Epilepsia* 2005;46:924-930.

[41] Ingrid E. Scheffer et al, ILAE classification of the epilepsies: Position paper of the ILAE Commission for Classification and Terminology. *Epilepsia*, 58(4):512-521, 2017

[42] Bray, P. F., Wiser, W. C., Wood, M. C., & Pusey, S. B. (1964). Evidence for a Genetic Etiology of Temporal-Central Abnormalities in Focal Epilepsy. *New England Journal of*

*Medicine*, 271(18), 926-933. doi:10.1056/nejm196410292711803

[43] Dooze H, Brigger-Heuer B, Neubauer BA: Children with focal sharp waves: clinical and genetic aspects. *Epilepsia* 1997; 38: 788-796.

[44] Vadlamudi L, Kjeldsen MJ, Corey LA, Solaas MH, Friis ML, Pellock JM, et al. Analyzing the etiology of benign rolandic epilepsy: a multicenter twin collaboration. *Epilepsia* 2006;47:550-555.

[45] G. Rudolf et al., Exome sequencing in 57 patients with self-limited focal epilepsies of childhood with typical or atypical presentations suggests novel candidate genes, *European Journal of Paediatric Neurology*, <https://doi.org/10.1016/j.ejpn.2020.05.003>

[46] Gkampeta A, Fidani L, Clarimon J, Kalinderi K, Katopodi T, Zafeiriou D, et al. Association of brain-derived neurotrophic factor (BDNF) and elongator protein complex 4 (ELP4) polymorphisms with benign epilepsy with centrottemporal spikes in a Greek population. *Epilepsy Res* 2014;108:1734-1739.

[47] Dibbens LM, de Vries B, Donatello S, Heron SE, Hodgson BL, Chintawar S, et al. Mutations in DEPDC5 cause familial focal epilepsy with variable foci. *Nat Genet* 2013;45:546-551.

[48] Ishida S, Picard F, Rudolf G, Noe E, Achaz G, Thomas P, et al. Mutations of DEPDC5 cause autosomal dominant focal epilepsies. *Nat Genet* 2013;45:552-555.

[49] Baulac S. Genetics advances in autosomal dominant focal epilepsies: focus on DEPDC5. *Prog Brain Res* 2014;213:123-139.

[50] Lal D, Reinthaler EM, Schubert J, Muhle H, Riesch E, Kluger G, et al. DEPDC5 mutations in genetic focal

epilepsies of childhood. *Ann Neurol* 2014;75:788-792.

and gene mapping to chromosome 16p12-11.2. *Ann Neurol* 1999;45:344-352.

[51] van Kranenburg M, Hoogeveen-Westerveld M, Nellist M. Preliminary functional assessment and classification of DEPDC5 variants associated with focal epilepsy. *Hum Mutat* 2015;36:200-209.

[59] Neubauer BA, Fiedler B, Himmelein B, Kampf F, Lassker U, Schwabe G, et al. Centrottemporal spikes in families with rolandic epilepsy: linkage to chromosome 15q14. *Neurology* 1998;51:1608-1612.

[52] Vears, D. F., Tsai, M.-H., Sadleir, L. G., Grinton, B. E., Lillywhite, L. M., Carney, P. W., ... Scheffer, I. E. (2012). Clinical genetic studies in benign childhood epilepsy with centrottemporal spikes. *Epilepsia*, 53(2), 319-324. doi:10.1111/j.1528-1167.2011.03368.x

[60] Bobbili, D. R., Lal, D., May, P., Reinthaler, E. M., Jabbari, K., ... Neubauer, B. A. (2018). Exome-wide analysis of mutational burden in patients with typical and atypical Rolandic epilepsy. *European Journal of Human Genetics*, 26(2), 258-264. doi:10.1038/s41431-017-0034-x

[53] Eeg-Olofsson O, Petersen I, Sellden U. The development of the electroenceph-alogram in normal children from the age of 1 through 15 years. Paroxysmal activity. *Neuropadiatrie* 1971;2:375-404.

[61] Xiong, W., & Zhou, D. (2017). Progress in unraveling the genetic etiology of rolandic epilepsy. *Seizure*, 47, 99-104. doi:10.1016/j.seizure.2017.02.012

[54] Ballaban-Gil K, Tuchman R. Epilepsy and epileptiform EEG: association with autism and language disorders. *Ment Retard Dev Disabil Res Rev* 2000;6:300-308.

[62] Maihara T, Tsuji M, Higuchi Y, Hattori H. Benign familial neonatal convulsions followed by benign epilepsy with centrottemporal spikes in two siblings. *Epilepsia* 1999;40:110-113.

[55] Heijbel J, Blom S, Rasmuson M. Benign epilepsy of childhood with centrottemporal EEG foci: A genetic study. *Epilepsia* 1971; 16: 285-293.

[63] Coppola G, Castaldo P, Miraglia del Giudice E, Bellini G, Galasso F, Soldovieri MV, et al. A novel KCNQ2 K+ channel mutation in benign neonatal convulsions and centrottemporal spikes. *Neurology* 2003;61:131-134.

[56] Ottman R. Genetics of the partial epilepsies: a review. *Epilepsia* 1989; 30: 107-111.

[64] Neubauer BA, Waldegger S, Heinzinger J, Hahn A, Kurlmann G, Fiedler B, et al. KCNQ2 and KCNQ3 mutations contribute to different idiopathic epilepsy syndromes. *Neurology* 2008;71:177-183.

[57] L.J. Strug, T. Clarke, T. Chiang, et al., Centrottemporal sharp wave EEG trait in Rolandic epilepsy maps to Elongator Protein Complex 4 (ELP4), *Eur. J. Hum. Genet.* 17 (2009) 1171e1181, <https://doi.org/10.1038/ejhg.2008.267>.

[58] Guerrini R, Bonanni P, Nardocci N, Parmeggiani L, Piccirilli M, De Fusco M, et al. Autosomal recessive rolandic epilepsy with paroxysmal exercise-induced dystonia and writer's cramp: delineation of the syndrome

[65] Roll, P., Rudolf, G., Pereira, S., Royer, B., Scheffer, I. E., Massacrier, A., ... Szepetowski, P. (2006). SRPX2 mutations in disorders of language cortex and cognition. *Human Molecular Genetics*, 15(7), 1195-1207. doi:10.1093/hmg/ddl035

- [66] Lemke JR, Lal D, Reinthaler EM, et al. Mutations in GRIN2A cause idiopathic focal epilepsy with rolandic spikes. *Nat Genet* 2013;45: 1067-1072.
- [67] Lal, D., Reinthaler, E. M., Altmüller, J., Toliat, M. R., Thiele, H., Nürnberg, P., ... Neubauer, B. A. (2013). RBFOX1 and RBFOX3 Mutations in Rolandic Epilepsy. *PLoS ONE*, 8(9), e73323. doi:10.1371/journal.pone.0073323
- [68] Reinthaler, E. M., Dejanovic, B., Lal, D., Semtner, M., Merkler, Y., ... Reinhold, A. (2015). Rare variants in  $\gamma$ -aminobutyric acid type A receptor genes in rolandic epilepsy and related syndromes. *Annals of Neurology*, 77(6), 972-986. doi:10.1002/ana.24395
- [69] Neng, X., Xiao, M., Yuanlu, C., Qinyan, L., Li, S., & Zhanyi, S. (2020). Novel variant in CHRNA4 with benign childhood epilepsy with centrottemporal spikes and contribution to precise medicine. *Molecular Genetics & Genomic Medicine*. doi:10.1002/mgg3.1264
- [70] Scala, M., Bianchi, A., Bisulli, F., Coppola, A., Elia, M., Trivisano, M., ... Gambardella, A. (2020). Advances in genetic testing and optimization of clinical management in children and adults with epilepsy. *Expert Review of Neurotherapeutics*. Doi:10.1080/14737175.2020.1713101
- [71] Holmes GL. Rolandic epilepsy: clinical and electroencephalographic features. *Epilepsy Res Suppl.* 1992;6:29-43. PMID: 1418488.
- [72] Stephani U. Typical semiology of benign childhood epilepsy with centrottemporal spikes (BCECTS). *Epileptic Disord.* 2000;2 Suppl 1:S3–S4. PMID: 11231216.
- [73] Vinayan, K. P., Bijl, V., & Thomas, S. V. (2005). Educational problems with underlying neuropsychological impairment are common in children with Benign Epilepsy of Childhood with Centrottemporal Spikes (BECTS). *Seizure*, 14(3), 207-212. doi:10.1016/j.seizure.2005.01.009
- [74] Panayiotopoulos, C. P., Michael, M., Sanders, S., Valeta, T., & Koutroumanidis, M. (2008). Benign childhood focal epilepsies: assessment of established and newly recognized syndromes. *Brain*, 131(9), 2264-2286. doi:10.1093/brain/awn162
- [75] Bouma PA, Bovenkerk AC, Westendorp RG, Brouwer OF. The course of benign partial epilepsy of childhood with centrottemporal spikes: a meta-analysis. *Neurology*. 1997 Feb;48(2):430-437. doi: 10.1212/wnl.48.2.430. PMID: 9040734.
- [76] Ferrari-Marinho, T., Hamad, A. P. A., Casella, E. B., Yacubian, E. M. T., & Caboclo, L. O. (2020). Seizures in self-limited epilepsy with centrottemporal spikes: video-EEG documentation. *Child's Nervous System*. doi:10.1007/s00381-020-04763-8
- [77] Cortesi F, Gianotti F, Ottaviano S. Sleep problems and daytime behavior in childhood idiopathic epilepsy. *Epilepsia* 1999;40:1557-1565.
- [78] Panayiotopoulos, C. P. (2004). Autonomic seizures and autonomic status epilepticus peculiar to childhood: diagnosis and management. *Epilepsy & Behavior*, 5(3), 286-295. doi:10.1016/j.yebeh.2004.01.013
- [79] Yoshinaga, H., Kobayashi, K., Shibata, T., Inoue, T., Oka, M., & Akiyama, T. (2015). Manifestation of both emetic seizures and sylvian seizures in the same patients with benign partial epilepsy. *Brain and Development*, 37(1), 13-17. doi:10.1016/j.braindev.2014.01.013
- [80] Covanis A, Lada C, Skiadas K. Children with Rolandic spikes and ictal vomiting: Rolandic epilepsy or



- Panayiotopoulos syndrome? *Epileptic Disord.* 2003 Sep;5(3):139-143. PMID: 14684348.
- [81] Caraballo R, Cersosimo R, Medina C, Fejerman N. Panayiotopoulos-type benign childhood occipital epilepsy: a prospective study. *Neurology* 2000; 55: 1096-1100.
- [82] Ferrie CD, Beaumanoir A, Guerrini R, et al. Early-onset benign occipital seizure susceptibility syndrome. *Epilepsia* 1997; 38: 285-293.
- [83] Guerrini R, Belmonte A, Veggiotti P, Mattia D, Bonanni P. Delayed appearance of interictal EEG abnormalities in early onset childhood epilepsy with occipital paroxysms. *Brain* 1997; 19: 343-346.
- [84] Panayiotopoulos CP. Extraoccipital benign childhood partial seizures with ictal vomiting and excellent prognosis. *J Neurol Neurosurg Psychiatry* 1999; 66: 82-85.
- [85] Panayiotopoulos CP. *Benign childhood partial seizures and related epileptic syndromes*. London: John Libbey, Company Ltd, 1999.
- [86] Chrysostomos P. Panayiotopoulos, The Birth and Evolution of the Concept of Panayiotopoulos Syndrome, *Epilepsia* 48(6);1041-1043,2007
- [87] Colamaria, V., Sgro, V., Caraballo, R., Simeone, M., Zullini, E., Fontana, E., ... Bernardina, B. D. (1991). Status Epilepticus in Benign Rolandic Epilepsy Manifesting as Anterior Operculum Syndrome. *Epilepsia*, 32(3), 329-334. doi:10.1111/j.1528-1157.1991.tb04659.x
- [88] Fejerman N. Atypical rolandic epilepsy. *Epilepsia* 2009;50 Suppl 7:9-12.
- [89] Aicardi J. Atypical semiology of rolandic epilepsy in some related syndromes. *Epileptic Disord* 2000;2 Suppl 1:S5–S9.
- [90] Fejerman N, Caraballo R, Tenenbaum SN. (2000) Atypical evolutions of benign localization-related epilepsies in children: are they predictable? *Epilepsia* 41:380-390.
- [91] Fejerman N, Caraballo R, Dalla Bernardina B. (2007a) Benign childhood epilepsy with centrottemporal spikes. In Fejerman N, Caraballo RH (Eds) *Benign focal epilepsies in infancy, childhood and adolescence*. John Libbey, Montrouge, pp. 77-113.
- [92] Fejerman N, Caraballo R, Dalla Bernardina B. (2007b) Atypical evolutions of benign focal epilepsies in childhood. In Fejerman N, Caraballo RH (Eds) *Benign focal epilepsies in infancy, childhood and adolescence*. John Libbey, Montrouge, pp. 179-220.
- [93] Trinka, E., Cock, H., Hesdorffer, D., Rossetti, A. O., Scheffer, I. E., Shinnar, S., ... Lowenstein, D. H. (2015). A definition and classification of status epilepticus - Report of the ILAE Task Force on Classification of Status Epilepticus. *Epilepsia*, 56(10), 1515-1523. doi:10.1111/epi.13121
- [94] Donald Shields W, Snead III C. Benign epilepsy with centrottemporal spikes. *Epilepsia* 2009;50:10-15
- [95] Loiseau P, Duche B, Benign childhood epilepsy with centrottemporal spikes. *Cleve Clin J Med* 56: 17-22, 1989
- [96] Engel J, Fejerman N. Benign childhood epilepsy with centrottemporal spikes. In: J Engel, N Fejerman (Eds.), *MedLink Neurology (Section of Epilepsy)*. MedLink Corporation, San Diego. Available at <http://www.medlink.com>. 2006
- [97] Lombroso CT (1967). Sylvian seizures and midtemporal spike foci in children. *Arch Neurol* 17: 52-59.
- [98] Bouma PAD, Bovenkerk AC, Westendorp RGJ, Brouwer OF. The

course of benign partial epilepsy of childhood with centrottemporal spikes: a meta-analysis. *Neurology* 1997;48(2):430-437. <https://doi.org/10.1212/wnl.48.2.430>.

[99] Wong P.K. Stability of source estimates in rolandic spikes. *Brain Topogr.* 1989; 2: 31-36

[100] Yoshinaga, H., Amano, R., Oka, E., & Ohtahara, S. (1992). *Dipole tracing in childhood epilepsy with special reference to Rolandic epilepsy*. *Brain Topography*, 4(3), 193-199. doi:10.1007/bf01131150

[101] De Marco P, Tassinari CA (1981). Extreme somatosensory evoked potentials (ESEPs): an EEG sign forecasting the possible occurrence of seizures in children. *Epilepsia* 22: 569-585.

[102] Gelisse, P., Genton, P., Bureau, M., Dravet, C., Guerrini, R., Viallat, D., & Roger, J. (1999). *Are there generalised spike waves and typical absences in benign rolandic epilepsy?* *Brain and Development*, 21(6), 390-396. doi:10.1016/s0387-7604(99)00040-6

[103] Ishitobi M, Nakasato N, Yamamoto K, Inuma K. Opercular to interhemispheric source distribution of benign rolandic spikes of childhood. *Neuroimage* 2005;25:417-423.

[104] Archer, J.S., Briellman, R.S., Abbott, D.F., Syngeniotes, A., Wellard, R.M., Jackson, G.D., 2003. Benign epilepsy with centro-temporal spikes: spike triggered fMRI shows somatosensory cortex activity. *Epilepsia* 44, 200-204.

[105] Kubota M, Oka A, Kin S, Sakakihara Y: Generators of rolandic discharges identified by magnetoencephalography. *Electroencephalogr Clin Neurophysiol* 1996;(Suppl 47):393-401.

[106] Kubota, M., Takeshita, K., Sakakihara, Y., Yanagisawa, M., 2000.

Magnetoencephalographic study of giant somatosensory evoked responses in patients with rolandic epilepsy. *J. Child. Neurol.* 15, 370-379.

[107] Gregory DL, Wong PKH. Topographic analysis of the centrottemporal discharges in benign rolandic epilepsy of childhood. *Epilepsia* 1984; 25: 705-711.

[108] Jung, K.-Y., Kim, J.-M., & Kim, D. W. (2003). Patterns of Interictal Spike Propagation across the Central Sulcus in Benign Rolandic Epilepsy. *Clinical Electroencephalography*, 34(3), 153-157. doi:10.1177/155005940303400309

[109] Cavazutti GB, Cappella L, Nalin A. Longitudinal study of epileptiform EEG patterns in normal children. *Epilepsia*1980;21:43-55.

[110] Stephani U, Carlsson G. The spectrum from BCECTS to LKS: the rolandic EEG trait—impact on cognition. *Epilepsia* 2006;47:67-70.

[111] Heijbel J, Blom S, Rasmussen M. Benign epilepsy of childhood with centrottemporal EEG foci: a genetic study. *Epilepsia*1975;16:285-293.

[112] Mariam Tashkandi, Duaa Baarma, Andrea C. Tricco, Cyrus Boelman, Reem Alkhater, EEG of asymptomatic first-degree relatives of patients with juvenile myoclonic, childhood absence and rolandic epilepsy: a systematic review and meta-analysis, *Epileptic Disorders*, Vol 21, Issue 1, p 30-41, 2019, <https://doi.org/10.1684/epd.2019.1024>

[113] Kellaway P. The electroencephalographic features of benign centrottemporal (rolandic) epilepsy of childhood. *Epilepsia* 2000; 41: 1053-1056.

[114] Dalla Bernardina B, Tassinari CA. EEG of a nocturnal seizure in a patient with “Benign Epilepsy of Childhood

with Rolandic Spikes". *Epilepsia* 1975;16:497-501.

[115] Gutierrez AR, Brick JF, Bodensteiner J. Dipole reversal: an ictal feature of benign partial epilepsy with centrotemporal spikes. *Epilepsia* 1990;31:544-548.

[116] Capovilla, G., Beccaria, F., Bianchi, A., Canevini, M. P., Giordano, L., Gobbi, G., ... Pruna, D. (2011). Ictal EEG patterns in epilepsy with centro-temporal spikes. *Brain and Development*, 33(4), 301-309. doi:10.1016/j.braindev.2010.06.007

[117] Oliveira de Andrade D. Padrao eletrografico ictal subclinico em um caso de epilepsia parcial benigna da infancia com pontascentro-temporais. *Arq Neuropsiquiatr* 2005;63(2A):360-363.

[118] Saint-Martin AD, Carcangiu R, Arzimanoglou A, Massa R, Thomas P, Motte J, et al. Semiology of typical and atypical Rolandic epilepsy: a video-EEG analysis. *Epil Disord* 2001;3:173-182.

[119] Alving, J., Fabricius, M., Rosenzweig, I., & Beniczky, S. (2017). Ictal source imaging and electroclinical correlation in self-limited epilepsy with centrotemporal spikes. *Seizure*, 52, 7-10. doi:10.1016/j.seizure.2017.09.006

[120] Dean P.Sarco et al., Benign Rolandic epileptiform discharges are associated with mood and behavior problems. *Epilepsy Behav.*2011 Oct.22(2):298-303

[121] Nicolai J. et al., Cognitive and behavioral effects on nocturnal epileptiform discharges in children with benign childhood epilepsy with centrotemporal spikes. *Epilepsy Behav.*8 2006, 56-70

[122] Garcia-Ramos, C., Dabbs, K., Lin, J. J., Jones, J. E., Stafstrom, C. E., Hsu, D. A., ... Hermann, B. P. (2019). Network analysis of prospective brain

development in youth with benign epilepsy with centrotemporal spikes and its relationship to cognition. *Epilepsia*. doi:10.1111/epi.16290

[123] Baglietto MG, Battaglia FM, Nobili I, et al. Neuropsychological disorders relate to interictal epileptic discharges during sleep in benign epilepsy of childhood with centrotemporal or Rolandic spikes. *Dev Med Child Neurol* 2001;43:407-412.

[124] Vannest J. Tenney JR.et al. Impact of frequency and lateralization of interictal discharges on neuropsychological and fine motor status in children with benign epilepsy with centrotemporal spikes *Epilepsia*, 57(8):e161–e167, 2016 doi: 10.1111/epi.13445

[125] Smith AB, Bajomo O, Pal DK. A meta-analysis of literacy and language in children with rolandic epilepsy. *Dev Med Child Neurol* 2015;57:1019-1026.

[126] Ross, E. E., Stoyell, S. M., Kramer, M. A., Berg, A. T., & Chu, C. J. (2019). The natural history of seizures and neuropsychiatric symptoms in childhood epilepsy with centrotemporal spikes (CECTS). *Epilepsy & Behavior*, 106437. doi:10.1016/j.yebeh.2019.07.038

[127] Besag FMC. Cognitive and behavioral outcomes of epileptic syndromes: implications for education and clinical practice. *Epilepsia* 2006;47(s2):119-25. <https://doi.org/10.1111/j.1528-1167.2006.00709.x>.

[128] Samaitienė R, Norkūnienė J, Jurkevičienė G, Grikinienė J. Behavioral problems in children with benign childhood epilepsy with centrotemporal spikes treated and untreated with antiepileptic drugs. *Medicina* 2012;48(7):50. <https://doi.org/10.3390/medicina48070050>.

[129] Hughes JR. Benign epilepsy of childhood with centrotemporal



spikes (CECTS): to treat or not to treat, that is the question. *Epilepsy Behav* 2010;19(3):197-203. <https://doi.org/10.1016/j.yebeh.2010.07.018>.

[130] Kramer U, Zelnik N, Lerman-Sagie T, Shahar E. Benign childhood epilepsy with centrotemporal spikes: clinical characteristics and identification of patients at risk for multiple seizures. *J Child Neurol* 2002;17(1):17-19. <https://doi.org/10.1177/088307380201700104>.

[131] You SJ, Kim DS, Ko TS. Benign childhood epilepsy with centrotemporal spikes (BCECTS): early onset of seizures is associated with poorer response to initial treatment. *Epileptic Disord* 2006;8(4):285-288. <https://doi.org/10.1684/epd.2006.0049>.

[132] Anna Elisabetta Vaudano, Pietro Avanzini, Gaetano Cantalupo, Melissa Filippini, Andrea Ruggieri, Mapping the Effect of Interictal Epileptic Activity Density During Wakefulness on Brain Functioning in Focal Childhood Epilepsies With Centrotemporal Spikes. *Front. Neurol.* 2019; 10: 131.doi:10.3389/fneur.2019.01316

[133] Kwon, S., Seo, H.-E., & Hwang, S. K. (2012). Cognitive and other neuropsychological profiles in children with newly diagnosed benign rolandic epilepsy. *Korean Journal of Pediatrics*, 55(10), 383. doi:10.3345/kjp.2012.55.10.383

[134] Wickens S. et al. Cognitive functioning in children with self-limited epilepsy with centrotemporal spikes: A systematic review and meta-analysis, *Epilepsia*, 58(10):1673-1685, 2017 doi: 10.1111/epi.1385

[135] Carmen Silvia Molleis Galego Miziara et al, Impact of benign childhood epilepsy with centrotemporal spikes (BECTS) on school performance. *Seizure* 21 (87-91), 2012

[136] Massa R, de Saint-Martin A, Carcangiu R, Rudolf G, Seegmuller C, Kleitz C, et al. EEG criteria predictive of complicated evolution in idiopathic rolandic epilepsy. *Neurology* 2001;57:1071-1079.

[137] Dalla Bernardina B. Partial epilepsies of childhood, bilateral synchronization continuous spike-wave during slow sleep. In: Manelis J, Bental E, Loeber JN, Dreifuss FE, eds. *Advances in Epileptology*, New York: Raven Press, 1989; XVII:295-302.

[138] Piccinelli, P., Borgatti, R., Aldini, A., Bindelli, D., Ferri, M., Perna, S., ... Balottin, U. (2008). Academic performance in children with rolandic epilepsy. *Developmental Medicine & Child Neurology*, 50(5), 353-356. doi:10.1111/j.1469-8749.2008.02040.x

[139] Kim H, Yoo IH et al. Averaged EEG spike dipole analysis may predict atypical outcome in Benign Childhood Epilepsy with Centrotemporal Spikes (BCECTS). 22 January 2018

[140] E.Tovia et al, The prevalence of atypical presentations and comorbidities of benign childhood epilepsy with centrotemporal spikes. *Epilepsia* 52(8): 1483-1488, 2011

[141] Parisi P, Paolino MC, Raucci U, Ferretti A, Villa MP, Trenite DK. "Atypical forms" of benign epilepsy with centrotemporal spikes (BECTS): How to diagnose and guide these children. A practical/scientific approach. *Epilepsy Behav.* 2017 Oct;75:165-169. doi: 10.1016/j.yebeh.2017.08.001. Epub 2017 Sep 1. PMID: 28866336.

[142] Kai Gao, Anel Tankovic et al, A de novo loss-of-function GRIN2A mutation associated with childhood focal epilepsy and acquired epileptic aphasia. *PLOS ONE* | DOI:10.1371, 2017

[143] Dheeraj R. Bobbili. Exome-wide analysis of mutational burden in



patients with typical and atypical Rolandic epilepsy. *European Journal of Human Genetics* volume 26, pages 258-264, 2018

[144] Reutlinger, C., Helbig, I., Gawelczyk, B., Subero, J. I. M., Tönnies, H., Muhle, H., ... Caliebe, A. (2010). Deletions in 16p13 including GRIN2A in patients with intellectual disability, various dysmorphic features, and seizure disorders of the rolandic region. *Epilepsia*, 51(9), 1870-1873. doi:10.1111/j.1528-1167.2010.02555.x

[145] Dimassi S, Labalme A, Lesca G, Rudolf G, Bruneau N, Hirsch E, et al. A subset of genomic alterations detected in rolandic epilepsies contains candidate or known epilepsy genes including GRIN2A and PRRT2. *Epilepsia* 2014;55:370-378.

[146] Yun Jeong Lee et.al, The clinical spectrum of benign epilepsy with centro-temporal spikes; a challenge in categorization and predictability. *Journal of epilepsy research* Vol7, N1, 2017

[147] Aicardi J, Chevrie JJ. Atypical benign partial epilepsy of childhood. *Dev Med Child Neurol*. 1982 Jun;24(3):281-292. doi: 10.1111/j.1469-8749.1982.tb13620.x. PMID: 6807733.

[148] Dooze H, Baier WK. Benign partial epilepsy and related conditions: multifactorial pathogenesis with hereditary impairment of brain maturation. *Eur J Pediatr*. 1989 Dec;149(3):152-158. doi: 10.1007/BF01958268. PMID: 2693093.

[149] Pesántez-Ríos G, Martínez-Bermejo A, Arcas J, Merino-Andreu M, Ugalde-Canitrot A. Las evoluciones atípicas de la epilepsia rolandica son complicaciones predecibles [The atypical developments of rolandic epilepsy are predictable complications]. *Rev Neurol*. 2015

Aug 1;61(3):106-13. Spanish. PMID: 26178515.

[150] Japaridze, N., Menzel, E., von Ondarza, G., Steinmann, E., & Stephani, U. (2014). Risk factors of cognitive outcome in patients with atypical benign partial epilepsy/pseudo-Lennox syndrome (ABPE/PLS) and continues spike and wave during sleep (CSWS). *European Journal of Paediatric Neurology*, 18(3), 368-375.

[151] Guerrini, R., Dravet, C., Genton, P., Bureau, M., Roger, J., Rubboli, G. and Tassinari, C.A. Epileptic negative myoclonus. *Neurology*, 1993, 43: 1078-1083.

[152] Kanazawa, O. and Kawai, I. Status epilepticus characterized by repetitive asymmetrical atonia: two cases accompanied by partial seizures. *Epilepsia*, 1990, 31: 536-543

[153] Tassinari CA, Rubboli G. Cognition and paroxysmal EEG activities: from a single spike to electrical status epilepticus during sleep. *Epilepsia* 2006;47:40-43.

[154] Caraballo R, Fontana E, Michelizza B, Zullini B, Sgro V, Pajno-Ferrara F, Dalla Bernardina B, Esposito S. (1989) Carbamazepine inducing atypical absences, atonic seizures and continuous spike and waves during slow wave sleep. *Boll Lega It Epil* 66/67:379-381.

[155] Kramer, U. (2008). Atypical Presentations of Benign Childhood Epilepsy With Centrottemporal Spikes: A Review. *Journal of Child Neurology*, 23(7), 785-790. doi:10.1177/0883073808316363

[156] Fejerman N, Di Blasi M. Status epilepticus of benign partial epilepsies in children: report of two cases. *Epilepsia*. 1987;28: 351-355.

[157] Salas-Puig J, Perez-Jimenez A, Thomas P, et al. Opercular epilepsies

with oromotor dysfunction. In: Guerrini R, Aicardi J, Andermann F, Hallet R, eds. *Epilepsy and Movement Disorders*. London: Cambridge University Press; 2002:251-268

[158] Tacke, M., Borggraefe, I., Gerstl, L., Heinen, F., Vill, K., Bonfert, M., ... Baethmann, M. (2018). Effects of Levetiracetam and Sulthiame on EEG in benign epilepsy with centrotemporal spikes: A randomized controlled trial. *Seizure*, 56, 115-120. doi:10.1016/j.seizure.2018.01.015

[159] Dietz Rating, Christian Wolf, and Thomas Bast. Sulthiame as monotherapy in children with benign childhood epilepsy with centrotemporal spikes: A 6-month randomized, double-blind, placebo-controlled study. *Epilepsia*, 41(10):1284-1288, 2000.

[160] Bruria Ben-Zeev, Nathan Watemberg, Pinchas Lerman, Itshak Barash, Nathan Brand, and Tally Lerman-Sagie. Sulthiame in childhood epilepsy. *Pediatr. int.*, 46(5):521-524, 2004.

[161] A Verrotti, G Coppola, R Manco, G Ciambra, P Iannetti, S Grosso, P Balestri, E Franzoni, and F Chiarelli. Levetiracetam monotherapy for children and adolescents with benign rolandic seizures. *Seizure*, 16(3):271-275, 2007.

[162] Coppola G, Franzoni E, Verrotti A, Garone C, Sarajlija J, Operto F, Pascotto A. Levetiracetam or oxcarbazepine as monotherapy in newly diagnosed benign epilepsy of childhood with centrotemporal spikes (BECTS): an open-label, parallel group trial. *Brain Dev*. 2007 Jun;29(5):281-284. doi: 10.1016/j.braindev.2006.09.008. Epub 2006 Oct 20. PMID: 17055681.

[163] Hamada Y, Okuno T, Hattori H, Mikawa H. Indication for antiepileptic drug treatment of benign childhood epilepsy with centro-temporal spikes. *Brain Dev* 1994;16:159—161.

[164] Bourgeois BF. Drug treatment of benign focal epilepsies of childhood. *Epilepsia* 2000;41:1057-1058

[165] Reed, M. D., & Gilman, J. T. (1991). Carbamazepine Dosing for Pediatric Seizure Disorders: The Highs and Lows. *DICP*, 25(10), 1109-1112. doi:10.1177/106002809102501017

[166] Guerrini, R. (2006). Valproate as a Mainstay of Therapy for Pediatric Epilepsy. *Pediatric Drugs*, 8(2), 113-129. doi:10.2165/00148581-200608020-00004

[167] Glauser TA, Ayala R, Elterman RD et al. (2000). Double-blind placebo-controlled trial of adjunctive levetiracetam in pediatric partial seizures. *Neurology* 66: 1654-1660.

[168] George L. Morris, Gabapentin, *Epilepsia*, 40 (Suppl 5), 1999

[169] Bourgeois B, Brown LW, Pellock JM, et al. Gabapentin monotherapy in children with benign childhood epilepsy with centro-temporal spikes (BECTS): a 36-week, double-blind. placebo-controlled study. *Am Proc Epilepsy Soc Meef* 1998.