

# We are IntechOpen, the world's leading publisher of Open Access books Built by scientists, for scientists

6,900

Open access books available

186,000

International authors and editors

200M

Downloads

Our authors are among the

154

Countries delivered to

TOP 1%

most cited scientists

12.2%

Contributors from top 500 universities



WEB OF SCIENCE™

Selection of our books indexed in the Book Citation Index  
in Web of Science™ Core Collection (BKCI)

Interested in publishing with us?  
Contact [book.department@intechopen.com](mailto:book.department@intechopen.com)

Numbers displayed above are based on latest data collected.  
For more information visit [www.intechopen.com](http://www.intechopen.com)



# Abdominal Compartment Syndrome among Medical Patients

*Kejal Gandhi, Pahnwat Taweasedt, Munish Sharma,  
Dweep Barbhaya and Salim Surani*

## Abstract

Abdominal compartment syndrome and intra-abdominal hypertension (IAH) has been widely studied in surgical and trauma patients, even though the incidence of IAH in medical intensive care unit (MICU) remains high. Studies have shown that the time to decision making regarding diagnosis and management of IAH is twice in MICU compared to the corresponding surgical side. MICU patients often require large volume resuscitation such as in sepsis, hemorrhage, or an inflammatory condition such as acute pancreatitis, which increases the risk of development of IAH. It is often underdiagnosed and undertreated in MICU due to a lack of awareness of the consequences and mortality associated with it. Elevated intra-abdominal pressure has systemic effects causing atelectatic lungs, decreased cardiac output, and renal insufficiency. IAH, if not recognized early, can quickly progress to compartment syndrome causing multiorgan failure and death. Approach to ACS management between medical and surgical intensivists varies largely because of lack of experience with surgical decompression. This article provides an overview of definitions, incidence, pathophysiology, clinical presentation, diagnosis, and management of IAH and abdominal compartment syndrome in critically in medical patients.

**Keywords:** abdominal compartment syndrome, intra-abdominal hypertension, intra-abdominal pressure, medical intensive care unit, bladder pressure, multiorgan failure, decompression laparotomy

## 1. Introduction

A progressive increase in intra-abdominal pressure initially results in intra-abdominal hypertension and later, affects end-organ perfusion resulting in abdominal compartment syndrome. It is often under-diagnosed as the end-organ perfusion caused by intra-abdominal hypertension in this patient population can also be explained by their overall critical condition. Thus, clinicians must have a high suspicion for intra-abdominal hypertension to prevent it from progressing to compartment syndrome and death.

2. Definitions

2.1 Intra-abdominal pressure

The abdomen is a closed cavity with a steady state pressure within it. This pressure is called Intra-abdominal pressure (IAP). Intra-abdominal pressure depends on the abdominal wall compliance and volume of the organs within the abdominal cavity. Thus, it is affected by the conditions that decreases the compliance of the wall (burn eschars or third spacing) or by additional volume of organs (such as fecal matter, presence of ascites, or space-occupying lesions such as tumors) [1].

Normal IAP varies between 5–7 mmHg [2]. Body Mass Index positively affects IAP with pressure being high in pregnant and morbidly obese individuals. Similarly, recent abdominal surgery can also affect the IAP.

2.2 Abdominal perfusion pressure (APP)

Abdominal perfusion pressure (APP) is measured by subtraction of intra-abdominal pressure from the mean arterial pressure (MAP) [3].

$$APP = MAP - IAP \tag{1}$$

With the increase in IAP, APP decreases, and thereby, causing decreased perfusion to the abdominal viscera. APP is a better maker than arterial pH, base deficit, arterial lactate and hourly urine output, as an endpoint for resuscitation.

2.3 Intra-abdominal hypertension (IAH)

The World Society of Abdominal Compartment Syndrome (WSACS) established the definition of IAH and ACS in 2004 [4]. Intra-abdominal hypertension (IAH) is defined as intra-abdominal pressure (IAP) greater than or equal to 12 mmHg.

IAH is further graded based on the IAP as shown in **Table 1**.

IAH can also be divided as follows based on duration:

- Hyperacute IAH refers to the transient elevation of the intra-abdominal pressure lasting for seconds such as while laughing, sneezing, straining, coughing.
- Acute IAH refers to the sustained elevation of IAP over hours such as in intra-abdominal trauma or hemorrhage and has the potential to progress to ACS.
- Subacute IAH refers to the elevation of IAP over days and is mostly seen in the MICU patients receiving large volume resuscitation and also has potential to progress to ACS.

Grades	IAP
Grade I	12–15 mmHg
Grade II	16–20 mmHg
Grade III	21–25 mmHg
Grade IV	>25 mmHg

**Table 1.**  
*IAH classification based on IAP value [5].*

- Chronic IAH refers to the elevation of IAP over months to years such as in patients with increased abdominal wall compliance (pregnant or morbidly obese). These patients are at high risk for development of ACS if they have superimposed acute or subacute IAH [6].

**2.4 Filtration gradient (FG)**

Oliguria is most often the first sign of IAH. FG is measured as glomerular filtration pressure (GFP) – PTP (proximal tubular pressure) and is a measure of pressure across the glomerulus.

$$GFP = MAP - IAP = APP \tag{2}$$

Since,  $PTP = IAP$  (3)

Therefore,  $FG = GFP - PTP = (MAP - IAP) - IAP$  (4)

Thus,  $FG = MAP - 2 \times IAP$  (5)

This equation shows that changes in IAP have a higher effect on renal function and urine production than changes in MAP [7].

**2.5 Abdominal compartment syndrome (ACS)**

Abdominal compartment syndrome (ACS) is defined as sustained IAP above 20 mmHg with evidence of end-organ dysfunction. ACS is further classified into primary, secondary, and recurrent based on the etiology and duration of end-organ failure.

Primary: ACS occurring due to etiology primarily within the abdominopelvic cavity is termed as primary; for example, abdominal trauma, pancreatitis, abdominal surgery, hemoperitoneum, liver transplantation. It frequently requires early surgical or interventional radiology intervention [8].

Secondary: ACS occurring due to extra-abdominal etiology; example: fluid resuscitation, sepsis, burns.

Recurrent: Development of ACS again after the early resolution of the previous either primary or secondary ACS. It can occur despite the presence of an open abdomen or after abdominal closure following the resolution of the first episode. It is associated with significant morbidity and mortality [9].

**3. Incidence**

Abdominal compartment syndrome has been studied widely in surgical and trauma patients. However, very few studies are available on the MICU patients. Many patients in MICU undergo large-volume resuscitation common conditions such as sepsis, hemorrhage, systemic inflammatory response syndrome, and are at high risk for the development of IAH. An incidence study done on MICU patients receiving large-volume resuscitation showed that 85% of patients enrolled

developed IAH with IAP > 12 mmHg, 33% developed IAP > 20 mmHg and 25% met the criteria for ACS. These patients had median fluid balance of +6.9 L and Acute Physiology and Chronic Health Evaluation II (APACHE II) score of 23. Thus, data emphasized the high incidence of IAH in MICU patients receiving large-volume resuscitation [10]. In another prospective multi-institutional study done in 15 ICUs, of 491 patients enrolled, IAH occurred in almost half of all the patients and was twice as common in mechanically ventilated patients compared to those who were breathing spontaneously. The study revealed that intra-abdominal hypertension proportionally increased the 28 and 90-day mortality [11]. Given the prevalence of IAH/ACS and associated mortality, it is important to be vigilant regarding the ACS development in MICU, especially in patients receiving the large-volume resuscitation.

4. Etiology

The abdomen is a closed cavity surrounded by rigid (pelvic bones, rib cage, spine) and flexible borders (Visceral organs, abdominal wall, diaphragm). There is an extent to which abdominal girth can increase and after an extent, the girth does not increase and results in intra-abdominal hypertension and thus, progressing to abdominal compartment syndrome.

Risk factors for IAH and ACS development can be divided as follows **Table 2:**

Risk factors for IAH and ACS
1. Decrease in abdominal wall compliance <ul style="list-style-type: none"><li>Burn Eschars</li><li>Rectus sheath hematoma</li><li>Obesity (BMI &gt; 30 kg/m2)</li><li>Ascites</li><li>Abdominal surgery</li><li>Mechanical ventilation with high PEEP</li><li>Prone positioning</li></ul>
2. Increase in intra-abdominal volume <ul style="list-style-type: none"><li>2.1 Increase in intra-luminal volume<ul style="list-style-type: none"><li>Fecal matter/air/fluid within the organs</li><li>Intestinal/Gastric distention such as colonic pseudo-obstruction, ileus, gastroparesis</li><li>Damage control laparotomy</li></ul></li><li>2.2 Increase in extra-luminal content<ul style="list-style-type: none"><li>Retroperitoneal tumor or hemorrhage</li><li>Pancreatitis</li><li>Abdominal abscess</li><li>Hemo/Pneumoperitoneum</li><li>Liver transplantation</li><li>Peritoneal dialysis</li><li>Peritonitis</li></ul></li></ul>
3. Secondary ACS <ul style="list-style-type: none"><li>Large volume resuscitation (&gt; 5 L fluids in 24 hours)</li><li>Hypothermia (core temperature less than 33 degree Celsius)</li><li>Acidosis (pH &lt; 7.2)</li><li>Massive blood transfusion (&gt;10 PRBC in 24 hrs)</li><li>Coagulopathy (platelets &lt;55,000 or prothrombin time &gt; 15 secs or INR &gt;1.5)</li><li>Sepsis</li><li>Major burns</li></ul>

**Table 2.**  
*Risk factors predisposing to IAH and ACS [12].*

## 5. Pathophysiology

Like any other compartment syndrome, an increase in IAH, causes the decrease in perfusion of the contents within the abdominal cavity due to increased venous resistance, causing decreased capillary perfusion. However, IAH is an area of particular significance given the multi-systemic effect involving cardiac, pulmonary, and renal systems. Patients with underlying cardiomyopathy, renal insufficiency, pulmonary diseases are at high risk of decompensation [13].

### 5.1 Cardiovascular

Increase in IAP causes cephalad movement of the diaphragm leading to increased intrathoracic pressure. This phenomenon results in the following:

**Decrease venous return:** Increase in IAP, increases the pressure in the IVC and with the cephalad motion of the diaphragm, the thoracic inlet of the IVC constricts; thus, decreasing the venous return and the preload, thereby, affecting a component of cardiac output. Decreased venous return increases the hydrostatic pressure in lower extremities resulting in peripheral edema and increased risk for development of deep vein thrombosis [14].

**Increase SVR:** Increase in IAP causes increased pressure in systemic and aortic vasculature and also, increase pulmonary vascular resistance secondary to increased intrathoracic pressure. These factors thus increase SVR and thereby, decreasing the cardiac output [15].

**Impaired cardiac function:** Elevation of the diaphragm and increased intrathoracic pressure caused by IAH also causes cardiac compression, thus, decreasing ventricular compliance and contractility.

In conclusion, the MAP is affected by both SVR and Cardiac output. In absence of severe IAH, SVR increases, and cardiac output decreases (due to decreased preload). Thus, MAP remains stable despite a decrease in both preload and cardiac output. However, in patients with decreased intravascular volume or with poor cardiac function, even a mild to moderate increase in IAP can result in decreasing MAP. Therefore, preload augmentation with volume resuscitation appears to be beneficial to compensate for the increasing systemic vascular resistance. In ventilated patients, high PEEP or auto-PEEP can further decrease the venous return and thus, are also at risk of decompensation at the lower elevation of IAP.

### 5.2 Pulmonary

An increase in the IAP compresses the lung parenchyma by direct transmission of IAP and cephalad deviation of the diaphragm. Compression of lung parenchyma thus results in atelectasis, which results in increasing shunting of the blood and causes ventilation-perfusion mismatch. The atelectatic lung is also at higher risk for infection. In mechanically ventilated patients, increased IAP causes the peak inspiratory pressure and mean airway pressure to increase, thus causing the alveolar barotrauma. These patients also have decreased chest wall compliance and spontaneous tidal volume, causing hypoxemia and hypercarbia, which are the clinical features of ACS [16].

### 5.3 Renal

IAH significantly decreases the renal function and thus urine output by significantly affecting the renal blood flow. In comparison with superior mesenteric and celiac blood flow, studies have shown preferential decrease in renal blood flow with elevated IAP [17]. IAH results in renal arterial constriction and an increase in renal



venous resistance, thus causing decrease in the venous drainage from the kidney. Secondly, a decrease in cardiac output also results in activation of the renin-angiotensin-aldosterone system, thus causing renal arterial vasoconstriction. As mentioned above an increase in IAP affects the filtration gradient and thus, resulting in a net decrease in urine output. A study has shown development of oliguria at IAP of approximately 15 mmHg, whereas elevation of IAP to 30 mmHg results in anuria [18].

#### **5.4 Gastrointestinal system**

The gut is most sensitive to increased IAP. It affects the gut in the following ways:

**Decreasing mesenteric blood flow:** Mesenteric blood flow is decreased at IAP as low as 10 mmHg. A study showed 43% decrease in the celiac artery blood flow and 69% decrease in superior mesenteric artery blood flow when IAP is elevated to 40 mmHg. This is accentuated by shock and hypotension [17].

**Compressing mesenteric veins:** IAH compresses mesenteric veins in the intestinal wall causing impaired venous flow from the intestine and thus, causing intestinal edema. This edema in turn causes an elevation in the IAP, thus initiating a vicious cycle. This results in worsened hypoperfusion leading to elevation of lactic acid and intestinal ischemia.

**Loss of intestinal mucosa:** Gut hypoperfusion results in the loss of protective intestinal mucosal barrier, leading to gut bacterial translocation and results, in sepsis with multi-organ failure [19].

#### **5.5 Hepatic**

Elevation in IAP causes decreased hepatic arterial flow and increases the portal venous and hepatic venous resistance, thus, resulting in decreased microcirculatory blood flow in the liver. This results in decreased mitochondrial function and production of ATPs. Overall, the liver's capacity to clear lactic acid decreases. This has been seen at IAP elevation to as low as 10 mmHg in presence of normal cardiac output and MAP [20].

#### **5.6 Central nervous system**

Elevation in IAP causes increase in intracranial pressure (ICP) by decreasing the lumbar venous plexus blood flow and decreasing the cerebral venous outflow. Overall increase in partial pressure of carbon dioxide results in cerebral venous constriction resulting in increased ICP. This, in turn, decreases the cerebral perfusion pressure and function [21].

#### **5.7 Abdominal wall**

Increased IAP can cause a decrease in blood flow to the abdominal wall, leading to wall ischemia and edema. Rectus sheath blood flow decreases in proportion to increase in the intra-abdominal pressure. It decreases by approximately 58% from baseline with IAP as low as 10 mmHg. This further reduces the abdominal wall compliance and exacerbates the IAH [22].

### **6. Clinical presentation**

Early identification of IAH is imperative to prevent further progression to ACS. Most patients with ACS are critically ill and unable to express the symptoms, therefore, identifying the signs of IAH or developing ACS is very important.

Signs of ACS
<ul style="list-style-type: none"><li>• Abdominal distention and elevated IAP</li><li>• Oliguria refractory to volume resuscitation</li><li>• Hypoxia</li><li>• Hypercarbia</li><li>• Increased peak inspiratory pressure and PEEP</li><li>• Refractory metabolic acidosis</li><li>• Elevated ICP</li></ul>

**Table 3.**  
*Clinical signs of abdominal compartment syndrome [23].*

### 6.1 Signs of abdominal compartment syndrome

Intraabdominal hypertension through its delirious effect on multi-organ system including kidney, lungs and cardiovascular system results in following clinical entities as mentioned in **Table 3** [23]. These clinical signs are seen commonly in critically ill patients having multiple comorbidities. Thus, it is very important to measure IAP at early stage and have high suspicion for ACS.

### 6.2 Imaging findings

These are not diagnostic for ACS, however, can be used as signs for early identification for developing abdominal compartment syndrome. Chest X-ray significant for elevated hemidiaphragm, pulmonary atelectasis and decreased lung volumes. CT scan findings are consistent with abdominal distention, tense infiltration of retroperitoneum out of proportion to the retroperitoneal disease, extrinsic compression of IVC or renal displacement, bowel wall thickening [24].

## 7. IAP measurement

In multiple prospective studies, the sensitivity of clinical examination in the diagnosis of IAH is only 40–60% [25, 26]. Abdomen being a hollow cavity filled with viscera, IAP can be measured by measuring the pressure within various viscera. However, IAP is typically measured via trans-bladder pressure measurement as recommended by the World Society of Abdominal Compartment Syndrome (WSACS) in 2006 due to ease of measurement [27]. Other ways to measure IAP include manometry from the abdominal drain, measuring pressure from central venous catheter inserted into inferior vena cava, measuring pressure via nasogastric tube, measuring rectal/uterine pressure [28]. Advanced modalities such as measuring abdominal wall thickness via ultrasound are also currently being investigated.

### 7.1 Intravesical pressure

Measurement of intravesical pressure has evolved over the years to decrease complications including the need for repeat measurements, urinary tract infection, and to decrease the incidence of needlestick injuries. The most common technique used is as follows:

- A three-way stopcock is used to decrease the number of times an aspiration port is accessed.



- A saline infusion set with 1000 ml normal saline bag is inserted in the first stopcock.
- A 50 ml syringe is attached to the 2nd stopcock.
- The third stopcock is attached to the pressure transducer and it is zeroed at a point where the mid-axillary line crosses the iliac crest.
- The urine drainage port of the foley is clamped.
- Instill 25 ml normal saline at room temperature into the bladder. Given that this normal saline can also result in detrusor muscle contraction and falsely increased the measured IAP, it is advisable to wait 30–60 seconds after saline administration to measure the pressure. Also, the patient should be in the complete supine position with a measurement done at end-expiration to ensure no abdominal muscle contraction is present. The measurement is done after the stopcocks to the pressure transducer is opened.

Although, intravesical pressure measurement is the gold standard to measure the intra-abdominal pressure, it has many technical difficulties. Though the evolution of technique has decreased the risk of needlestick injuries, this technique still is cumbersome, intermittent and carries potential risk of urinary tract infection. Most of the ventilated patients in MICU have head of bed elevated to prevent aspiration risk and studies have shown that the intravesical pressure increases significantly even with mild head of bed elevation [29].

## **7.2 Intra-gastric pressure**

This method involves measurement of the pressure within the stomach using the nasogastric tube. It can be used when the patient does not have a foley catheter or intravesical pressure measurement is not possible due to bladder trauma, pelvic hematoma, peritoneal adhesions or neurogenic bladder. The use of tonometer to measure the intragastric pressure has been validated and showed good correlation with the IAP [30]. However, the IAP measured via nasogastric tube is affected by the migrating motor complex and the effects of enteral tube feeding on the IAP measurement are still unknown. The intra-gastric pressure measurement can also be used to monitor continuous intra-abdominal pressure. The most advanced method involves the air-pouch system where the tip of the nasogastric tube contains a pressure transducer which can automatically calibrate every hour and provides continuous intra-abdominal pressure measurement, however, this method is not validated in humans yet.

## **7.3 Inferior vena cava pressure**

IVC catheter placed via femoral cannulation can be connected to the pressure transducer to provide IVC pressure measurement. A study validating the indirect methods of IAP measurement in rabbits showed good correlation of IVC and transvesical pressure with direct intraperitoneal pressure measurements. However, IVC catheter are associated with increased risk of infection and sepsis. A multicenter observational study showed that femoral vein pressure has good correlation with the IAP when intra-abdominal pressure is >20 mmHg and can be used as a surrogate to bladder pressure, thus, allowing continuous measurement of IAP [31].

7.4 Rectal and uterine pressure

Rectal and transvaginal pressure measurement is less practical given the pressure can be affected by the residual fecal mass or gynecological bleeding. Both these techniques have not been validated in the ICU setting [32].

8. Management

Management of ACS involves early recognition of IAH and/or end-organ failure and prompt interventions. It has been outlined by WSACS as shown in Figures 1 and 2. Management can be divided into medical and surgical interventions.

8.1 Non-surgical management

Non-surgical measures include decreasing the IAP by decreasing the content within the visceral organs that might be causing the IAH. Ileus is a common post-abdominal surgical complication and is also common amongst patients receiving large volume resuscitation, in patients with peritonitis, electrolyte imbalance and those receiving narcotic medications. These factors are independently associated to increase risk for IAH/ACS. Thus, treating ileus by nasogastric suction and rectal suction, use of prokinetic agents, colonoscopic decompression, and frequent enemas helps to decrease IAP by decreasing the volume of intra-luminal contents.

In patients where extra-luminal factors are leading to elevated IAH, alleviating the cause is most advisable to improve the abdominal wall compliance. If any space-occupying lesion is contributing to the IAH, thorough investigation including Ultrasound and CT scan should be done to identify the nature of space occupying lesion (SOL) and if indicated, either percutaneous drainage or surgical removal of the SOL can help with reducing the IAP. If ascites is contributing to the IAH, then

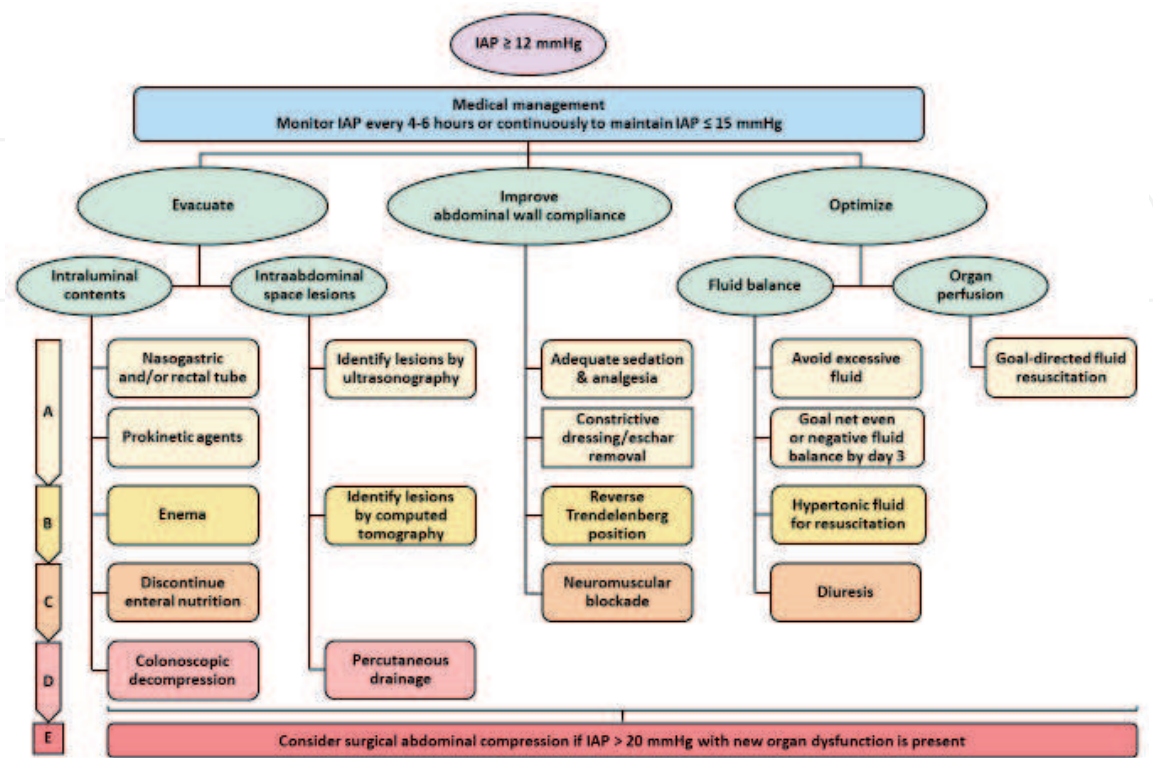
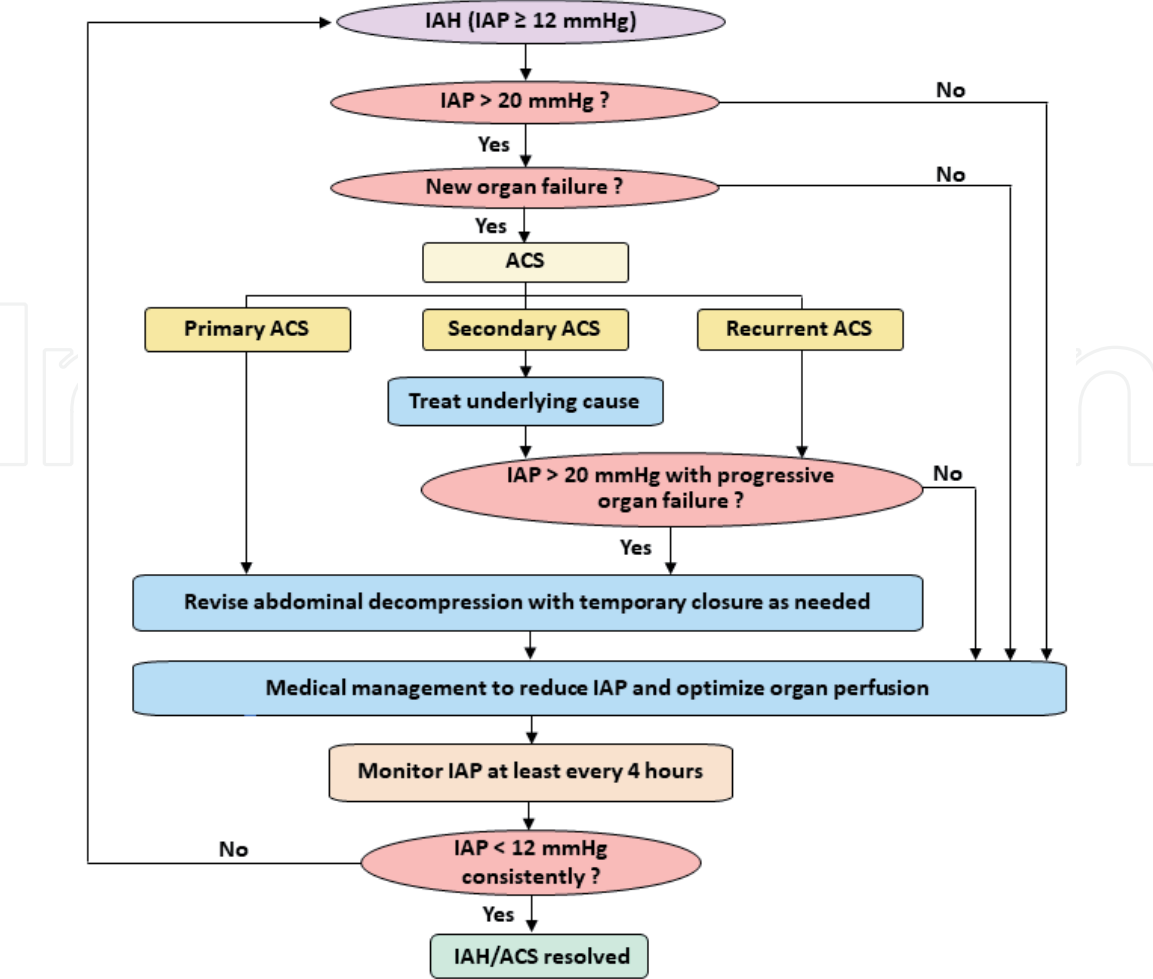


Figure 1.  
Medical management for intra-abdominal hypertension [27].



**Figure 2.**  
*Evaluation and management of abdominal compartment syndrome [4].*

therapeutic paracentesis can help. However, in patients with progressive IAH or not responding to therapeutic paracentesis, continuous percutaneous drainage guided by Ultrasound or CT scan should be considered. Studies have shown that continuous percutaneous drainage decreases the rate of open abdominal decompression in 81% of the patients treated. However, if percutaneous drain fails to drain at least 1 L of fluid and decrease the intra-abdominal pressure by at least 9 mmHg in first four hours, the likelihood for requirement of surgical decompression increases [33].

Abdominal compliance can also be improved by adequate sedation and analgesia, removal of constrictive dressing, and eschars. Supine positioning or reverse Trendelenburg position also helps alleviate the abdominal muscle contracture. Low evidence is available but neuromuscular blockade should be considered per WSACS guidelines [27].

Managing the volume status of the patient is equally important, as hypovolemia can further exacerbate the effects of IAH and the large volume resuscitation can also similarly be shown as a predictive factor for progression to ACS. Thus, it's important to judge the volume status of the patient and maintain euvolemia. Hemodynamic monitoring is advisable for judicious administration of fluids. Recent study in burn patients receiving large volume resuscitation has shown that hypertonic saline or colloid solution effectively decreases the risk for developing IAH/ACS [34].

Despite adequate fluid resuscitation, some patients with IAH/ACS develop total body fluid overload secondary to capillary leakage and excessive third spacing with significant elevation in IAP [35]. Diuretics are generally contraindicated as

these patients are intravascularly volume depleted. However, once these patients become hemodynamically stable with resolution of shock, diuretics along with colloid administration helps to the fluid from the third space. Continuous renal replacement therapy to remove excess fluid judiciously and increase abdominal wall compliance can also help decrease the IAP. However, it's important to ensure that intra-vascular volume is adequately maintained for appropriate organ perfusion and avoidance of multi-organ failure development secondary to inadequate perfusion.

## 8.2 Surgical management

When the non-surgical methods fail to consistently decrease the IAP, surgical abdominal decompression via laparotomy is the treatment of choice. Decompressive laparotomy results in a decrease in intra-abdominal volume and thus decreases the IAP. Delay in surgical decompression in surgical and non-surgical patients is associated with increased mortality [36]. There is also an increased risk of ischemia-reperfusion syndrome especially in patients with significantly high IAP for a prolonged period. Abdominal laparotomy with negative peritoneal pressure therapy is preferred given that it improves visceral perfusion and also decreases bacterial translocation. In multiple studies, surgical decompression has been shown to decrease IAP and improve respiratory, cardiac, and renal function [37]. However, studies on the mortality related to ACS requiring decompressive laparotomy are inconclusive as there is a significant difference in when the decision to do decompression is made by the intensivist based on their specialty. Studies have shown that medical intensivists prefer diuresis and dialysis more and take double the time than surgical intensivists to decide on decompressive laparotomy. Surgical decompression, though a life-saving procedure, has significant morbidity and mortality associated with it. In a study, three out of four patients of severe acute pancreatitis who underwent surgical decompression died and two of them from uncontrollable retroperitoneal hemorrhage [38].

Decompressive laparotomy can result in excess loss of fluids from the exposed tissue resulting in exsanguination or can result in a large ventral hernia or fistula [39]. The open abdomen also increases risk for bacterial translocation and sepsis. Thus, steps should be taken to close the abdomen as soon as possible with most surgeons planning staged closure every 48 hours. Continued manometric measurement of IAP even after abdominal closure is necessary.

## 9. Prognosis

ACS is associated with high mortality and hence, it's imperative to identify the early signs of intra-abdominal hypertension. Presence of IAH on day 1 of ICU is not an independent risk factor for mortality, however, occurrence and persistence of IAH during the ICU stay has significant associated with mortality [40]. Studies have shown that mortality increases proportionally with abdominal hypertension. A study showed 45.1% mortality in ACS patients compared to 21% mortality in patients with increased IAP [41]. Most common cause leading to death includes sepsis and multi-organ failure.

## 10. Conclusion

Intra-abdominal hypertension and abdominal compartment syndrome are prevalent amongst critically ill medical patients and associated with high mortality.

Thus, medical staff should have a high suspicion of ACS in critically ill patients. Large volume resuscitation should be rationalized, and early surgical decompression must be considered if indicated.

### **Conflict of interest**

The authors declare no conflict of interest.

### **Author details**

Kejal Gandhi<sup>1</sup>, Pahnwat Taweeseedt<sup>2</sup>, Munish Sharma<sup>2</sup>, Dweep Barbhaya<sup>1</sup> and Salim Surani<sup>3\*</sup>

1 Georgetown University/Medstar Washington Hospital Center, Washington, DC, USA

2 Corpus Christi Medical Center, Texas, USA

3 Christus Spohn Hospital Corpus Christi – Memorial, Corpus Christi, Texas, USA

\*Address all correspondence to: srsurani@hotmail.com

### **IntechOpen**

© 2021 The Author(s). Licensee IntechOpen. This chapter is distributed under the terms of the Creative Commons Attribution License (<http://creativecommons.org/licenses/by/3.0>), which permits unrestricted use, distribution, and reproduction in any medium, provided the original work is properly cited. 



## References

- [1] Bailey J, Shapiro MJ. Abdominal compartment syndrome. *Crit Care* [Internet]. 2000;4(1):23. Available from: <https://doi.org/10.1186/cc646>
- [2] De Keulenaer BL, De Waele JJ, Powell B, Malbrain M. What is normal intra-abdominal pressure and how is it affected by positioning, body mass and positive end-expiratory pressure? *Intensive Care Med*. 2009;35(6):969-976.
- [3] Cheatham ML, White MW, Sagraves SG, Johnson JL, Block EFJ. Abdominal Perfusion Pressure: A Superior Parameter in the Assessment of Intra-abdominal Hypertension. *J Trauma Acute Care Surg* [Internet]. 2000;49(4). Available from: [https://journals.lww.com/jtrauma/Fulltext/2000/10000/Abdominal\\_Perfusion\\_Pressure\\_\\_A\\_Superior\\_Parameter.8.aspx](https://journals.lww.com/jtrauma/Fulltext/2000/10000/Abdominal_Perfusion_Pressure__A_Superior_Parameter.8.aspx)
- [4] Cheatham ML, Malbrain MLNG, Kirkpatrick A, Sugrue M, Parr M, De Waele J, et al. Results from the International Conference of Experts on Intra-abdominal Hypertension and Abdominal Compartment Syndrome. II. Recommendations. *Intensive Care Med* [Internet]. 2007;33(6):951-62. Available from: <https://doi.org/10.1007/s00134-007-0592-4>
- [5] Malbrain MLNG, De laet IE, De Waele JJ, Kirkpatrick AW. Intra-abdominal hypertension: Definitions, monitoring, interpretation and management. *Best Pract Res Clin Anaesthesiol* [Internet]. 2013;27(2):249-270. Available from: <http://www.sciencedirect.com/science/article/pii/S152168961300044X>
- [6] Malbrain MLNG, De Keulenaer BL, Oda J, De Waele J, Roberts DJ, Kirkpatrick AW, et al. Intra-abdominal hypertension and abdominal compartment syndrome in burns, obesity, pregnancy, and general medicine. *Anaesthesiol Intensive Ther*. 2015;47(3):228-240.
- [7] Dalfino L, Tullo L, Donadio I, Malcangi V, Brienza N. Intra-abdominal hypertension and acute renal failure in critically ill patients. *Intensive Care Med* [Internet]. 2008;34(4):707-13. Available from: <https://doi.org/10.1007/s00134-007-0969-4>
- [8] Tons C, Schachtrupp A, Rau M, Mumme T, Schumpelick V. Abdominal compartment syndrome: avoidance and treatment. *Der Chir*. 2000;71(8):918-926.
- [9] Rajasurya V, Surani S. Abdominal compartment syndrome: Often overlooked conditions in medical intensive care units. *World J Gastroenterol*. 2020;26(3):266.
- [10] Daugherty EL, Liang H, Taichman D, Hansen-Flaschen J, Fuchs BD. Abdominal Compartment Syndrome Is Common in Medical Intensive Care Unit Patients Receiving Large-Volume Resuscitation. *J Intensive Care Med* [Internet]. 2007 Sep 1;22(5):294-9. Available from: <https://doi.org/10.1177/0885066607305247>
- [11] Reintam Blaser A, Regli A, De Keulenaer B, Kimball EJ, Starkopf L, Davis WA, et al. Incidence, Risk Factors, and Outcomes of Intra-Abdominal Hypertension in Critically Ill Patients-A Prospective Multicenter Study (IROI Study). *Crit Care Med*. 2019 Apr;47(4):535-542.
- [12] Malbrain MLNG, De laet IE. Intra-Abdominal Hypertension: Evolving Concepts. *Clin Chest Med* [Internet]. 2009;30(1):45-70. Available from: <http://www.sciencedirect.com/science/article/pii/S0272523108000919>
- [13] Papavramidis TS, Marinis AD, Pliakos I, Kesisoglou I, Papavramidou N.

Abdominal compartment syndrome—Intra-abdominal hypertension: Defining, diagnosing, and managing. *J Emergencies, Trauma Shock*. 2011;4(2):279.

[14] Kashtan J, Green JF, Parsons EQ, Holcroft JW. Hemodynamic effects of increased abdominal pressure. *J Surg Res* [Internet]. 1981;30(3):249-255. Available from: <http://www.sciencedirect.com/science/article/pii/0022480481901566>

[15] Luca A, Cirera I, García-Pagán JC, Feu F, Pizcueta P, Bosch J, et al. Hemodynamic effects of acute changes in intra-abdominal pressure in patients with cirrhosis. *Gastroenterology*. 1993 Jan;104(1):222-227.

[16] Pelosi P, Quintel M, Malbrain MLNG. Effect of intra-abdominal pressure on respiratory mechanics. *Acta Clin Belg*. 2007;62 Suppl 1:78-88.

[17] Barnes GE, Laine GA, Giam PY, Smith EE, Granger HJ. Cardiovascular responses to elevation of intra-abdominal hydrostatic pressure. *Am J Physiol Integr Comp Physiol* [Internet]. 1985 Feb 1;248(2):R208-13. Available from: <https://doi.org/10.1152/ajpregu.1985.248.2.R208>

[18] Richards WO, Scovill W, Shin B, Reed W. Acute renal failure associated with increased intra-abdominal pressure. *Ann Surg*. 1983 Feb;197(2):183-187.

[19] De Laet IE, Malbrain M. Current insights in intra-abdominal hypertension and abdominal compartment syndrome. *Med intensiva*. 2007;31(2):88-99.

[20] Diebel LN, Wilson RF, Dulchavsky SA, Saxe J. Effect of increased intra-abdominal pressure on hepatic arterial, portal venous,

and hepatic microcirculatory blood flow. *J Trauma* [Internet]. 1992 Aug;33(2):279—82; discussion 282—3. Available from: <https://doi.org/10.1097/00005373-199208000-00019>

[21] Bloomfield GL, Ridings PC, Blocher CR, Marmarou A, Sugerman HJ. Effects of Increased Intra-abdominal Pressure upon Intracranial and Cerebral Perfusion Pressure before and after Volume Expansion. *J Trauma Acute Care Surg* [Internet]. 1996;40(6). Available from: [https://journals.lww.com/jtrauma/Fulltext/1996/06000/Effects\\_of\\_Increased\\_Intra\\_abdominal\\_Pressure\\_upon.12.aspx](https://journals.lww.com/jtrauma/Fulltext/1996/06000/Effects_of_Increased_Intra_abdominal_Pressure_upon.12.aspx)

[22] Diebel, L., Saxe, J. M., & Dulchavsky S. Effects of Intra-Abdominal Pressure on Abdominal Wall Blood Flow. *Am Surg* [Internet]. 1992;58(9):573-576. Available from: <https://corescholar.libraries.wright.edu/surg/134>

[23] Ivatury RR, Diebel L, Porter JM, Simon RJ. INTRA-ABDOMINAL HYPERTENSION AND THE ABDOMINAL COMPARTMENT SYNDROME. *Surg Clin North Am* [Internet]. 1997;77(4):783-800. Available from: <http://www.sciencedirect.com/science/article/pii/S0039610905705843>

[24] Pickhardt PJ, Shimony JS, Heiken JP, Buchman TG, Fisher AJ. The abdominal compartment syndrome: CT findings. *AJR Am J Roentgenol*. 1999 Sep;173(3):575-579.

[25] Kirkpatrick AW, Brenneman FD, McLean RF, Rapanos T, Boulanger BR. Is clinical examination an accurate indicator of raised intra-abdominal pressure in critically injured patients? *Can J Surg* [Internet]. 2000 Jun;43(3):207-211. Available from: <https://pubmed.ncbi.nlm.nih.gov/10851415>

- [26] Blaser AR, Sarapuu S, Tamme K, Starkopf J. Expanded Measurements of Intra-Abdominal Pressure Do Not Increase the Detection Rate of Intra-Abdominal Hypertension: A Single-Center Observational Study\*. *Crit Care Med* [Internet]. 2014;42(2). Available from: [https://journals.lww.com/ccmjournal/Fulltext/2014/02000/Expanded\\_Measurements\\_of\\_Intra\\_Abdominal\\_Pressure.18.aspx](https://journals.lww.com/ccmjournal/Fulltext/2014/02000/Expanded_Measurements_of_Intra_Abdominal_Pressure.18.aspx)
- [27] Kirkpatrick AW, Roberts DJ, De Waele J, Jaeschke R, Malbrain MLNG, De Keulenaer B, et al. Intra-abdominal hypertension and the abdominal compartment syndrome: updated consensus definitions and clinical practice guidelines from the World Society of the Abdominal Compartment Syndrome. *Intensive Care Med* [Internet]. 2013;39(7):1190-206. Available from: <https://doi.org/10.1007/s00134-013-2906-z>
- [28] Malbrain MLNG. Different techniques to measure intra-abdominal pressure (IAP): time for a critical re-appraisal. *Appl Physiol intensive care Med*. 2006;105-119.
- [29] Cheatham ML, De Waele JJ, De Laet I, De Keulenaer B, Widder S, Kirkpatrick AW, et al. The impact of body position on intra-abdominal pressure measurement: A multicenter analysis\*. *Crit Care Med* [Internet]. 2009;37(7). Available from: [https://journals.lww.com/ccmjournal/Fulltext/2009/07000/The\\_impact\\_of\\_body\\_position\\_on\\_intra\\_abdominal.8.aspx](https://journals.lww.com/ccmjournal/Fulltext/2009/07000/The_impact_of_body_position_on_intra_abdominal.8.aspx)
- [30] Sugrue M, Buist MD, Lee A, Sanchez DJ, Hillman KM. Intra-abdominal pressure measurement using a modified nasogastric tube: description and validation of a new technique. *Intensive Care Med* [Internet]. 1994;20(8):588-590. Available from: <http://europepmc.org/abstract/MED/7706574>
- [31] Howard AE, Regli A, Litton E, Malbrain MM, Palermo A-M, De Keulenaer BL. Can Femoral Venous Pressure be Used as an Estimate for Standard Vesical Intra-Abdominal Pressure Measurement? *Anaesth Intensive Care* [Internet]. 2016 Nov 1;44(6):704-11. Available from: <https://doi.org/10.1177/0310057X1604400604>
- [32] Sugrue M, De Waele J, De Keulenaer BL, Roberts DJ, Malbrain MLNG. A user's guide to intra-abdominal pressure measurement. *Anaesthesiol Intensive Ther*. 2015;47(3):241-251.
- [33] Cheatham ML, Safcsak K. Percutaneous catheter decompression in the treatment of elevated intraabdominal pressure. *Chest*. 2011 Dec;140(6):1428-1435.
- [34] O'Mara MS, Slater H, Goldfarb IW, Caushaj PF. A prospective, randomized evaluation of intra-abdominal pressures with crystalloid and colloid resuscitation in burn patients. *J Trauma*. 2005 May;58(5):1011-1018.
- [35] Cordemans C, De laet I, Van Regenmortel N, Schoonheydt K, Dits H, Huber W, et al. Fluid management in critically ill patients: the role of extravascular lung water, abdominal hypertension, capillary leak, and fluid balance. *Ann Intensive Care* [Internet]. 2012;2(1):S1. Available from: <https://doi.org/10.1186/2110-5820-2-S1-S1>
- [36] Mentula P, Hienonen P, Kemppainen E, Puolakkainen P, Leppäniemi A. Surgical Decompression for Abdominal Compartment Syndrome in Severe Acute Pancreatitis. *Arch Surg* [Internet]. 2010 Aug 1;145(8):764-9. Available from: <https://doi.org/10.1001/archsurg.2010.132>
- [37] Rogers WK, Garcia L. Intraabdominal Hypertension, Abdominal Compartment Syndrome,

and the Open Abdomen. Chest  
[Internet]. 2018;153(1):238-250.  
Available from: <http://www.sciencedirect.com/science/article/pii/S0012369217313193>

[38] De Waele JJ, Hoste E, Blot SI, Decruyenaere J, Colardyn F. Intra-abdominal hypertension in patients with severe acute pancreatitis. Crit Care [Internet]. 2005;9(4):R452. Available from: <https://doi.org/10.1186/cc3754>

[39] De Waele JJ, Kimball E, Malbrain M, Nesbitt I, Cohen J, Kaloiani V, et al. Decompressive laparotomy for abdominal compartment syndrome. Br J Surg. 2016;103(6):709.

[40] Malbrain MLNG, Chiumello D, Pelosi P, Bihari D, Innes R, Ranieri VM, et al. Incidence and prognosis of intraabdominal hypertension in a mixed population of critically ill patients: a multiple-center epidemiological study. Crit Care Med. 2005;33(2):315-322.

[41] Parsak CK, Seydaoglu G, Sakman G, Acarturk TO, Karakoc E, Hanta I, et al. Abdominal Compartment Syndrome: Current Problems and New Strategies. World J Surg [Internet]. 2008;32(1):13-9. Available from: <https://doi.org/10.1007/s00268-007-9286-x>