

We are IntechOpen, the world's leading publisher of Open Access books Built by scientists, for scientists

6,900

Open access books available

186,000

International authors and editors

200M

Downloads

Our authors are among the

154

Countries delivered to

TOP 1%

most cited scientists

12.2%

Contributors from top 500 universities



WEB OF SCIENCE™

Selection of our books indexed in the Book Citation Index
in Web of Science™ Core Collection (BKCI)

Interested in publishing with us?
Contact book.department@intechopen.com

Numbers displayed above are based on latest data collected.
For more information visit www.intechopen.com



Percutaneous Treatment of Tricuspid Regurgitation

*Carlos Minguito-Carazo, Tomás Benito-González,
Rodrigo Estévez-Loureiro, Carmen Garrote-Coloma,
Julio Echarte-Morales, Armando Pérez de Prado
and Felipe Fernández-Vázquez*

Abstract

Tricuspid valve regurgitation is one of the most common valvular disorders and moderate to severe tricuspid regurgitation is consistently associated to an increased morbidity and mortality. From an etiopathological perspective, tricuspid regurgitation can be classified in primary, due to the organic disease of any of the valve components, or secondary, as a result of tricuspid valve annulus dilatation, adverse right ventricular remodeling and tricuspid valve leaflet tethering. Despite its poor prognosis, most patients with tricuspid insufficiency are managed conservatively and only those with concomitant left heart valvular disease do finally go surgery in the real-world setting. In fact, outcomes of conventional surgery in patients with isolated tricuspid regurgitation are poor and this approach has not proven yet any survival benefit over stand-alone medical therapy. Given this unmet need, new transcatheter techniques have been developed in the last years, including leaflet plication, percutaneous annuloplasty and valve implantation in either the tricuspid position (orthotopic implantation) or in a different position such as the vena cava (heterotopic implantation). These techniques, with promising outcomes, are seen as an interesting alternative to open-heart surgery given the much lower periprocedural risk.

Keywords: percutaneous tricuspid valve repair, transcatheter tricuspid valve replacement, tricuspid valve insufficiency, tricuspid regurgitation, tricuspid valve

1. Introduction

Moderate or severe tricuspid regurgitation (TR) is a common disorder affecting over 1.6 million people in the United States and close to 70 million worldwide [1, 2]. In the vast majority of cases, the underlying mechanism is functional, due to right ventricular (RV) remodeling in patients with left-side heart disease, atrial fibrillation, primary pulmonary hypertension (PH) or RV dysfunction [3]. Although TR has been traditionally considered to be a benign valve disorder in comparison with left valve disease, it is conversely associated to a poorer prognosis. Furthermore, this finding has been consistently reported in different clinical scenarios, even in the absence of PH or right-side heart failure (HF) [4, 5]. However, most patients with significant TR only receive medical treatment and very few undergo invasive surgical

approach if no concomitant coronary or left valvular disease is present [6]. Thus, surgical tricuspid valve (TV) repair or replacement in isolated TR is fairly indicated and reported periprocedural mortality can be as high as 20% [7, 8]. Recently, new percutaneous techniques have shown promising results for the treatment of TR and appear as an alternative to conventional surgery in those cases where only conservative management could be offered in the past due to high surgical risk. In this chapter we will review the different devices that are currently available and to date published evidence for these approaches.

2. Tricuspid regurgitation

2.1 Anatomy of the tricuspid valve

The TV is a complex structure composed of three leaflets (septal, anterior and posterior), a fibrous TV annulus (TVA) in which these leaflets are inserted, at least two papillary muscles with multiple tendinous cords and the adjacent atrial and RV myocardium. Despite these general considerations, anatomical interindividual variability is high, and it is not so rare to find four or even five TV leaflets instead of three [9–11]. The anterior leaflet is usually more prominent and extends from the infundibular region to the inferolateral wall. The posterior leaflet is smaller and, in some cases, hypoplastic, and it is inserted along the posterior margin of the TVA from the septum to the inferolateral basal segment. Lastly, the septal leaflet is fixed along the interventricular septum from the infundibulum to the posterior ventricular margin.

The fibrous TVA is not a flat structure but elliptic in shape under normal preloading conditions, with the posterolateral portion at a lower or more apical position and the antero-septal portion in a higher or more atrial situation. Like the mitral valve annulus, the TVA is dynamic and changes shape and size during the cardiac cycle. TV is the largest and the most apically positioned heart valve, and can measure up to 9 cm² in size in healthy subjects.

The subvalvular apparatus is composed of the tendinous cords and the papillary muscles. Usually, there are two different papillary muscles, anterior and posterior, but not infrequently, a third septal papillary muscle can be found. The anterior papillary muscle is the largest of these muscles and gives rise to cords that sustain the anterior and posterior leaflets, while the posterior papillary muscle supports mainly the posterior and the septal leaflets. The septal leaflet is normally directly fixed to the septal ventricular wall by third order tendinous cords, resulting in reduced displacement during the cardiac cycle.

From an interventional perspective, some issues should be highlighted that may pose technical difficulties for an invasive approach [12–14]:

- The TV has a close anatomical relationship with other structures such as the non-coronary sinus of Valsalva (adjacent to the antero-septal commissure), the atrioventricular node and the bundle of His (along the intramembranous portion of the septum) or the right coronary artery (which runs parallelly to the TVA).
- The distance between the outfall of inferior vena cava, the most frequent access for percutaneous TV intervention, and the TV is small, and this can challenge the achievement of coaxiality with the TV coaptation plane.
- Implantable cardiac devices can be frequently found in patients with TR and, even if not related to the mechanism of TR, right atrial and RV leads can difficult an adequate percutaneous approach.

- The anterior position of the tricuspid valve significantly impairs echocardiographic window by transesophageal echocardiography, which has become the main imaging technique for guiding structural and valve transcatheter interventions.
- Severe RV remodeling and systemic congestion can lead to huge dilatation of TVA and tethering of TV leaflets causing very wide gaps, which can limit reliable TV percutaneous intervention.

2.2 Etiology

Competence of the TV depends on the integrity of all its components (leaflets, TVA and subvalvular apparatus). The dysfunction of any of these structures can cause TR and we can differentiate two types according to the mechanism of the valve insufficiency:

- a. Primary (10–20%): due to organic disease affecting mainly the TV leaflets and/or the subvalvular apparatus (**Table 1**). This heterogeneous group includes congenital diseases, systemic and local inflammatory or infiltrative disorders, and traumatic damage of the valve [15].
- b. Functional (80–90%): this is by far the most common type of TR and it is secondary to any of the following diseases [16–18]:
 - Left-side HF with either preserve or not preserve left ventricular ejection fraction: ischemic heart disease, hypertension, dilated cardiomyopathy, mitral or aortic valvular disease... leading to increased left atrial pressure and postcapillary PH.
 - Precapillary PH and/or primary RV dysfunction.
 - Atrial fibrillation (AF).

From a physiopathological perspective, all these disorders are closely related to each other and frequently two or more of them can coexist in the same patient. In fact, all of them end in a common pathway characterized by progressive TVA dilatation, RV dilatation and dysfunction, and TV leaflet tethering. These changes increase the TR regurgitation, thus, worsening RV adverse remodeling that further impairs the coaptation gap of TV leaflets [19]. Moreover, systemic congestion and

Congenital	Ebstein anomaly Other corrected or non-corrected CHD
Acquired	Infectious Endocarditis Carcinoid syndrome Rheumatic disease Myxomatous degeneration Endomyocardial fibrosis Traumatism (blunt chest trauma) Iatrogenic (ICD leads, EMD, drugs, radiation, surgery)

Table 1.
Causes of primary tricuspid regurgitation. CHD: congenital heart disease, ICD: implantable cardiac devices; EMB: endomyocardial biopsy.

chronic neuro-hormonal activation also contribute to this self-perpetuating mechanism that, if untreated, conducts to irreversible end-stage right HF.

2.3 Diagnosis

To date, transthoracic echocardiography is the gold standard for diagnosis of TR. Current guidelines highlight the importance of a comprehensive evaluation of the TV in order to improve the quality of the diagnosis, but also, the decision-making process, including [20]:

- a. TR severity: qualitative, semi-quantitative and quantitative parameters should support the grading of TR.
- b. Etiology: primary vs. functional.
- c. Mechanism: TVA dilatation, TV leaflet tethering, organic TV disease.
- d. Complementary key information:
 - Left heart size, function and valve disease.
 - Pulmonary artery pressure (PAP).
 - RV size and function: tricuspid annular plane systolic excursion (TAPSE), 2D longitudinal strain, RV-PA coupling).
 - Fluid status (size of inferior vena cava).

It should be noted that most of these measurements can be significantly affected by the preload conditions of the patient at the time the study is performed. Therefore, intensive intravenous diuretic therapy should be considered in patients with an over-volume status in order to perform the study in an as close to euvolemic state as possible. In this regard, vena contracta width is becoming one of the most used parameters for TR severity grading given its higher independency from preload conditions. Recently, a 5-degree scheme for grading TR based on the vena contracta and the effective regurgitation orifice area has been suggested pointing out the prognosis additive significance of massive or torrential TR in patients with huge regurgitant orifices compared to severe TR [21] (**Table 2**). In this regard, patients with massive or torrential TR showed a lower survival, higher cardiovascular mortality and more admissions for heart failure than those with severe TR [22].

Echocardiographic parameter	Mild	Moderate	Severe	Massive	Torrential
VC (biplane)	<3 mm	3-6.9 mm	7-13 mm	14-20 mm	≥ 21 mm
EROA (PISA)	<20 mm ²	20-39 mm ²	40-59 mm ²	60-79 mm ²	≥ 80 mm ²
3D VCA or quantitative EROA			75-94 mm ²	95-114 mm ²	≥ 115 mm ²

Table 2.
New classification for grading the severity of TR. VC: vena contracta; EROA: effective regurgitant orifice area; 3D VCA: three-dimensional vena contracta area.

In addition, right ventricular systolic function assessment is essential when evaluating TR. This has been traditionally addressed by the TAPSE and the fractional area change (FAC). However, recently the RV free wall longitudinal strain ($> -23\%$) has been proposed as an independent risk factor for all-cause mortality and incremental to TAPSE and FAC [23]. In addition, although 3D- echocardiogram could evaluate accurately the RV ejection fraction, cardiac magnetic resonance is still the gold standard method to assess the RV function and volumes.

Together with the development of new percutaneous techniques, advance imaging of TR is also growing, and this evolution will probably contribute to a better understanding of the anatomy and mechanism of this disease. To date, both, transthoracic and, more specifically, transesophageal echocardiography play a key role in the indication of intervention, the selection of candidates for each percutaneous or surgical technique, and as guidance for transcatheter procedures [24]. In the following years, probably the magnetic resonance imaging and computed tomography will provide further insights in this pathology. Furthermore, we expect that all the advances in the field of TV imaging will help to find the optimal timing for intervention, which nowadays is one of the major challenges of this disease.

2.4 Prognosis

Up to mild TR can be oftenly found in healthy individuals. Moreover, the prevalence of moderate to severe TR has increased in the last years and will probably continue to rise given the expected aging of worldwide population. To date, it is frequently associated with other cardiac disorders and can be found in around 15–40% of patients with AF, HF or severe left-side heart valve disease. The presence of significant TR is associated to an increased mortality in different series and this negative impact on outcomes is related to the severity of the TV insufficiency. In a retrospective study including more than 5000 patients, the survival rates at one year were 92% in patients without TR and 90%, 79% and 64% in those with mild, moderate or severe TR, respectively [25]. Likewise, Chorin et al. analyzed over 33.000 echocardiograms performed in a 5-year period. In this large single center cohort, moderate [HR 1.15, 95% CI 1.02–1.3, $p = 0.024$] and severe TR (HR 1.43, 95% CI 1.08–1.88, $p = 0.011$) had a worse prognosis than those with no or minimal TR [26].

Topilsky et al. observed similar findings when analyzed a cohort of 353 patients with isolated TR [27]. They concluded that severe isolated TR was an independent predictor of all-cause mortality and found that an effective regurgitant orifice over 40 mm² was significantly related to a reduced survival independently of other characteristics. It should be highlighted that adverse prognosis impact of moderate or severe TR has been reported in a wide range of diverse clinical scenarios, such as HF with either preserved or reduced left ventricular ejection fraction, atrial fibrillation without left-side HF or mitral or aortic valve disease. Interestingly, a recent meta-analysis including 70 studies and 32601 patients followed during a mean of over 3 years reported that moderate or severe TR was associated with a two-fold increased mortality risk compared to mild or no TR (RR 1.95, 95% CI 1.75–2.17) [4]. This association remained statistically significant when adjusted for systolic pulmonary artery pressure, RV dysfunction, left ventricular ejection fraction, AF or grade of mitral regurgitation.

2.5 Surgical approach

Several surgical approaches to treat TR have been suggested in the last decades. Among them, TV repair has been related to superior outcomes compared to TV

replacement [28]. Furthermore, ring annuloplasty offers a consistent reduction in TR in long-term follow up and is nowadays the first line technique in the TV anatomy is suitable [29].

Despite the increasing prevalence of significant TR and its adverse prognosis impact on survival, evidence to date of clinical benefit of open-heart surgery is scarce. Current guidelines in Europe and USA showed a consensual indication for symptomatic primary TR despite medical therapy and for functional TR in patients undergoing left heart valve disease. However, these recommendations have a C level of evidence.

On the contrary, the indication of TV surgery in patients with isolated functional TR is still controversial. Some aspects should be highlighted regarding this issue. First, functional TR is a heterogeneous group including patients at very different stages of TV disease, PH and RV remodeling/function, which might not benefit from the same therapeutical approach. Second, the evaluation of clinical status and its impairment related to TR is oftenly challenging, especially in elderly patients or those with comorbidities. Third, to date, TV surgery has not proven any benefit in hard outcomes compared to conservative management in this population. In this regard, Axtell et al. assessed outcomes in a retrospective cohort of 3276 patients with isolated TR. In this study, there were no differences in survival between patients who received medical versus surgical therapy (HR: 1.34; 95% CI 0.78–2.30; $p = 0.288$). And four, reported outcomes of isolated TV surgery are poor. Alqahtani et al. recently reviewed trends and outcomes of isolated TV surgery in USA during over a decade [8]. They concluded that isolated repair was associated with high in-hospital mortality (8.1%) and significant rates of permanent pacemaker implantation (10.9%) and new dialysis (4.4%). Morbidity and mortality were even worse among those patients who underwent TV replacement (10.9%, 34.1% and 5.5%, respectively). Similarly, Dreyfus reported an in-hospital mortality of 10% and 19% of major complications during admission in a series of 241 patients who underwent isolated TV surgery in France during a 2 years period [30]. Authors suggested that patients are oftenly referred to late to surgery and that an earlier intervention may improve immediate and possibly midterm outcomes. Nevertheless, this hypothesis has not been proved yet. As a result, in the real-world setting, TV surgery for isolated TR is rarely performed and therefore, most patients are managed conservatively.

3. Transcatheter therapies for tricuspid regurgitation

Given the unmet need for invasive correction of TR with an assumable procedural risk, different percutaneous devices have been developed in recent years based on previous surgical techniques and percutaneous devices dedicated for the treatment of left-side valve disease. **Table 3** summarizes anatomical target and surgical background, if any, of current available devices for transcatheter treatment of TR, including percutaneous TV repair (PTVR) techniques and orthotopic and heterotopic transcatheter TV valve implantation (TTVI). To date, only 3 devices have already obtain the CE mark for clinical practice [12, 31].

3.1 Percutaneous tricuspid valve repair

3.1.1 Percutaneous coaptation devices

These devices are designed to ultimately minimize the coaptation gap, including: 1) MITRACLIP in the tricuspid position or TRICLIP that approximate the leaflets

	Anatomical target	Surgical background	CE mark
MITRACLIP/TRICLIP	Leaflets	Edge-to-edge Clover suture	Yes
PASCAL			Yes
FORMA			No
MISTRAL	Leaflets + tendinous cords	No	No
CARDIOBAND	Tricuspid valve annulus	Annuloplasty ring	Yes
IRIS MILLIPEDE			No
DA VIGNI			No
TRIALIGN		Kay bicuspidization suture	No
TRICINCH			No
PASTA			No
MIA		Suture annuloplasty	No
TRAIPTA		No	No
NAVIGATE		TVR	No
LUX-VALVE	Tricuspid valve	TVR	No
TRISOL VALVE		TVR	No
SAPIEN		No	No
TRICVALVE	Vena cava	No	No
TRICENTO		No	No

Table 3.
Transcatheter therapies for tricuspid regurgitation.

increasing its coaptation surface; 2) FORMA device, comprising a spacer that occupies the regurgitant orifice; 3) PASCAL, that combines clipping of leaflets with a minor spacer; and 4) the MISTRAL device that approaches leaflets’ coaptation edge by stretching the subvalvular apparatus (**Figure 1**).

a. MITRACLIP/TRICLIP

MitraClip (Abbott Vascular, Santa Clara, CA, USA) is a polyester-coated chromium-cobalt device with two arms that open and close in a controlled manner through the release system. The device can be repositioned and more devices can be implanted until an adequate reduction of the valve insufficiency is achieved. This device was initially designed for the percutaneous treatment of mitral regurgitation and has already been used in over 100.000 for this purpose. With this back up of experience gained in the treatment of mitral regurgitation, it began to be used as an off-label therapy for TR and become the most widely used PTVR device (70% of all procedures).

The TriValve registry evaluated the results of MitraClip at 1-year follow-up in a series of 249 patients with TR [32]. Concomitant treatment of the mitral valve was carried out in 52% of the cases and two or more clips were implanted in 69.1% of the patients received, most of them (65%) at the anteroseptal commissure (65%). Procedural success, defined as TR reduction to grade $\leq 2+$, was achieved in 77% of cases and an improvement in functional class to NYHA \leq II

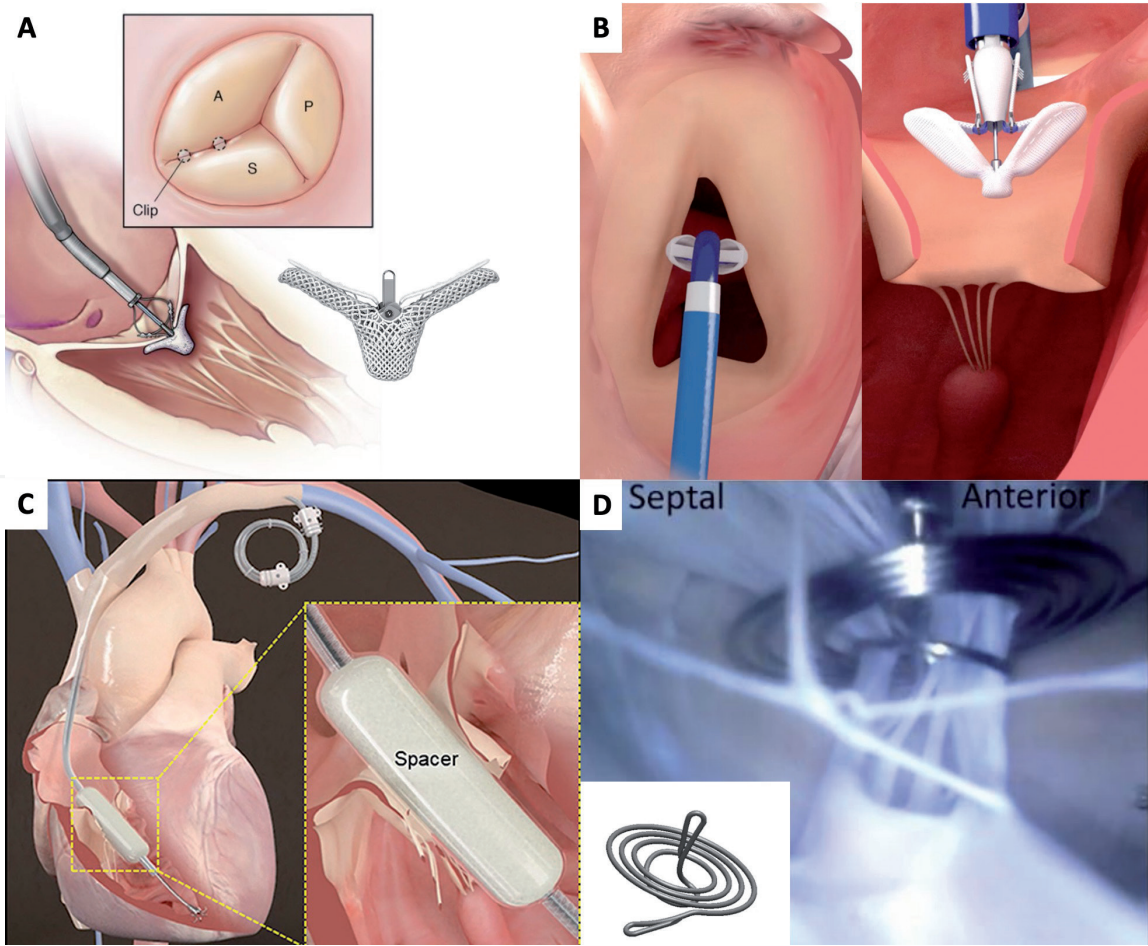


Figure 1.
Tricuspid coaptation devices. A: TRICLIP, B: PASCAL, C: FORMA, D: MISTRAL.

was observed in 69% of patients. The following factors were identified as independent predictors for procedural failure: tenting area > 3.15 cm², non-central jet, regurgitation through the anteroposterior or posteroseptal commissure, coaptation gap >6.5 mm and regurgitant area > 0.695 cm².

From a technical point of view, two approaches have been described for reducing TR with MitraClip: the triple-orifice technique in which the clips are positioned centrally between the septal and the anterior leaflets, as well as between the septal and the posterior leaflets; and the bicuspidization procedure in which clips are deployed between the anterior and the septal leaflets [33] (**Figure 2**). Clipping of the anteroposterior commissure can be challenging and, sometimes, this may distort the valve and worsen TR [34].

The TriClip (Abbott Vascular, Santa Clara, CA, USA) is a dedicated MitraClip device for the TV. The prospective single-arm multicenter TRILUMINATE study evaluated the safety and feasibility of this system for treating TR. The 6-month results involving 85 patients have recently been published [35]. Patients with severe PH or relevant mitral valve insufficiency were excluded. Technical success was achieved in all the patients and most clips were deployed between the anterior and septal leaflets (77%) with a reduction of at least one grade in the severity of TR in 91% of the cases. At 6-month follow-up, 86% of the patients presented moderate or less TR and were in NYHA functional class was I-II, and a significant improvement in the 6-minute walking test was observed.

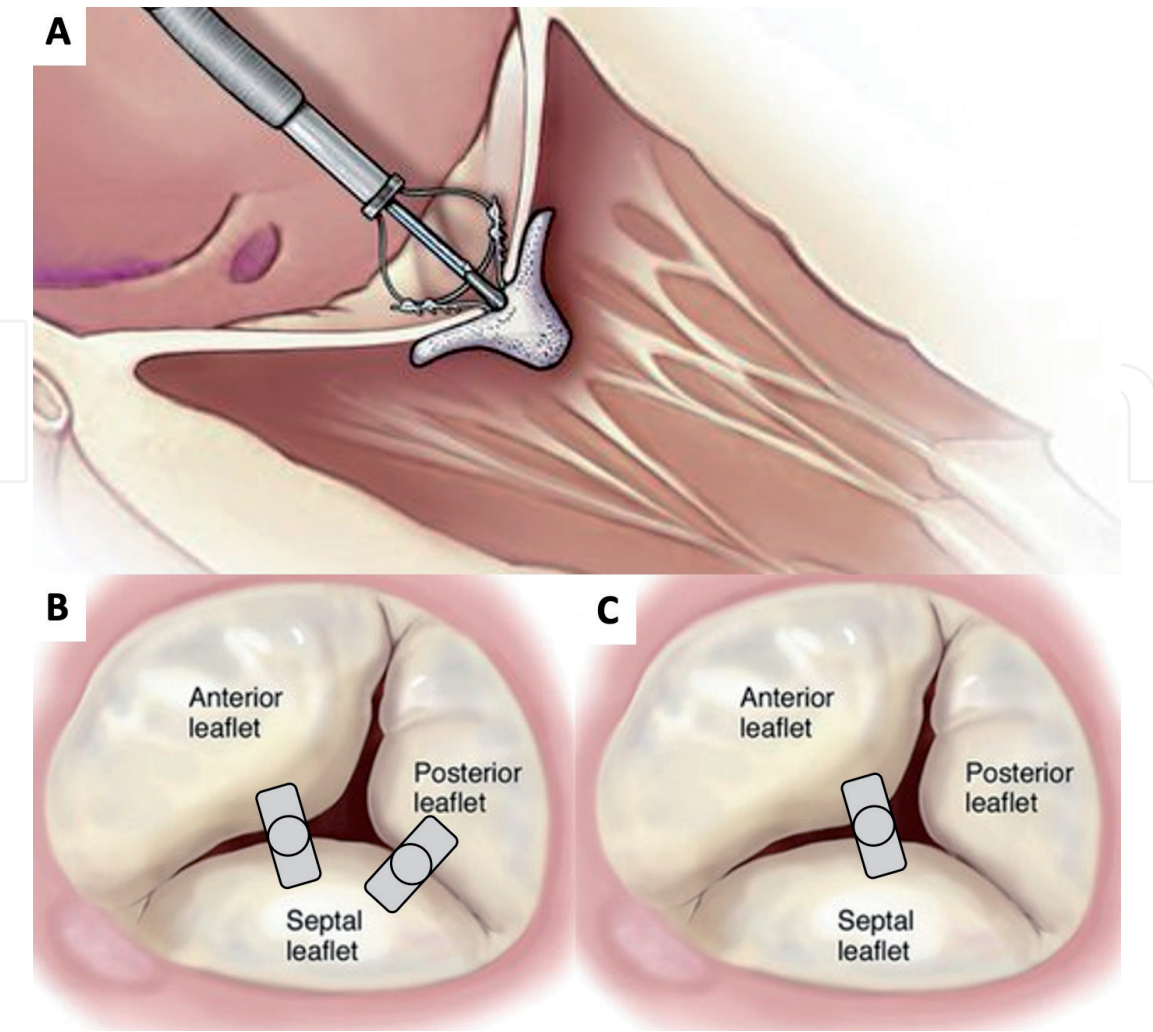


Figure 2.
A: Percutaneous tricuspid valve repair with MitraClip. B: Triple-orifice technique. C: Bicuspidization approach.

Patients with significant TR and implantable cardiac devices represent a particularly challenging population. In a cohort of the TriValve registry, PTVR was performed in 121 patients with an intracardiac RV electrodes. Most of these patients, 106 (87%), were treated with MitraClip and compare to those without intracardiac devices, no significant differences were documented in procedural success, TR reduction ($TR \leq 2+$ 73.7% vs. 70.8%, $p = 0.6$), clinical improvement or survival [36].

b. PASCAL

The Pascal system combines the possibility of grasping the leaflets as with the MitraClip device with the use of a spacer. This affords improved coaptation and better outcomes following percutaneous repair of TR. The first experience targeted to the tricuspid valve in humans have recently been published [37]. Out of 28 patients (98% with functional TR), the procedure success rate was 86%, with no complications in any case. Forty devices were implanted - mostly in the anteroseptal position (70%). Detachment of the device was recorded in two patients, and 85% of the subjects presented $TR \leq 2+$ after 30 days.

Although no clinical trials have compared any of these therapies versus placebo in patients with TR, an observational study has compared the use of the MitraClip with the PASCAL system in the treatment of this valve disease. In

this study published by Braun et al., in which 88 patients were treated with the MitraClip and 32 received the PASCAL system, no differences were observed between the two devices in terms of success of the procedure, the reduction of TR or detachment of the device (11% with MitraClip versus 6% with PASCAL). The authors concluded that both devices are similar in terms of efficacy and safety in reducing TR [38].

c. FORMA

The FORMA system (Edwards Lifesciences, Irvine, CA, USA) is designed to increase leaflet coaptation, occupying the regurgitant orifice with a spacer [39]. A guide is advanced through the subclavian or axillary vein and anchored in the apex of the right ventricle. The spacer is then advanced to the tricuspid valve plane. Finally, the excess guide is implanted in a subcutaneous pouch. The results after 2–3 years of the first cohort of 19 patients treated with this system have recently been published [40]. The procedure proved successful in 89% of the patients, with the recording of one case of right ventricle perforation. After four months another patient suffered thrombosis of the device, and pulmonary thromboembolism was also evidenced in another subject. Although functional class improvement was observed in 93% of the cases, at last follow-up only one-third of the patients presented moderate or lesser TR. The FORMA early feasibility study reported two right ventricle perforations in the cohort of 29 patients. A decrease in TR was seen in 49% of the cases [40]. Despite these outcomes, most of the patients experienced improvement of their functional class. The single-arm SPACER trial is currently ongoing and will evaluate mortality after 30 days with this device.

d. MISTRAL

The results of the first experience in humans with the Mistral device (Mitratrix, Yokneam, Israel) have recently been published [41]. This device consists of a spiral nitinol guide that grasps the tendinous cords, approximating them to the leaflets and thus increasing coaptation. This study included 7 patients with severe functional TR; one of them required two devices. No adverse events related to the procedure were recorded after 30 days, and a significant decrease in effective regurgitant orifice area (EROA), vena contracta and regurgitant volume was achieved, together with improved functional class.

3.1.2 Percutaneous annuloplasty devices

As it has been explained above, the basic mechanism underlying functional TR is TVA dilatation, which mainly occurs in its anteroposterior diameter. TV annuloplasty is currently the surgical treatment of choice in this scenario. Based on this surgical technique, different percutaneous annuloplasty devices have been developed in recent years with the fundamental aim of reducing the annular dimensions and prevent further TVA dilatation. These devices can be classified into rings (CARDIOBAND, IRIS MILLIPEDE, DA VIGNI, TRAIPTA) or direct suture devices (TRIALIGN, TRICINCH, PASTA, MIA) (**Figure 3**).

a. CARDIOBAND

The CARDIOBAND (Edwards Lifesciences, Irvine, CA, USA) is an annuloplasty system consisting of an adjustable surgical-like Dacron ring that is im-

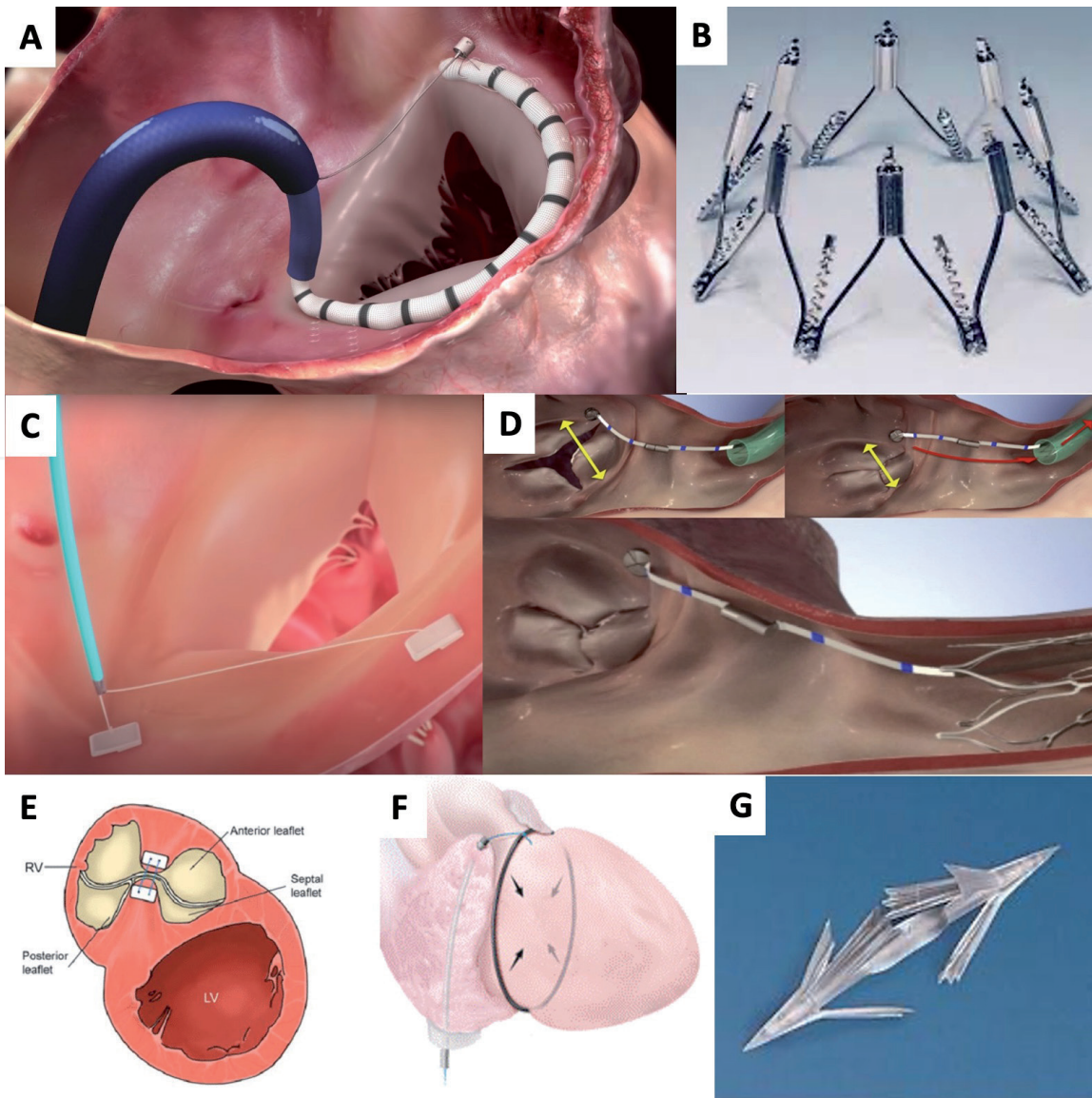


Figure 3.
A: CARDIOBAND, B: *Iris MILLIPEDE*, C: TRIALIGN, D: TRICINCH, E: *Pasta*, F: TRAIPTA, G: *Mia*.

planted on the atrial side of the tricuspid TVA and fixed with multiple anchors. Once the last anchoring has been placed, the device is cinched until enough TR reduction is achieved. The two-year results of the TRI-REPAIR study have recently been published. This trial evaluated the efficacy and safety of this system in 30 patients with symptomatic functional TR (83% in NYHA functional class III-IV) [42]. The procedure was successful in all patients and related to a significant reduction in TR (72% of the subjects presented TR \leq moderate) and TVA dimension, and to an improvement in functional status (82% of the subjects were in NYHA class I-II), 6-minute walk distance and quality of life at 24-months follow-up. The Early Feasibility Study of CARDIOBAND included 22 patients with severe symptomatic TR in which this treatment was carried out [43]. The procedure success rate was 96%, with improvement of both the severity of TR and of the NYHA functional class.

b. IRIS MILLIPEDE

The IRIS transcatheter annuloplasty system (Boston Scientific, Marlborough, MA), is a complete semirigid ring that is placed in a supra-annular position and anchored through 7–9 screws. The ring can be adjusted to reduce the

TVA diameter and thus the severity of TR. Although this system was initially designed to be used in the mitral valve, Rogers et al. presented the results obtained in two patients that received this device in the tricuspid position in a combined procedure with the mitral valve annuloplasty [44]. For the TV treatment, only 7 of the 9 anchors were used in order to avoid the risk of atrioventricular block. The results in these patients were good showed no need for a pacemaker and a 40% reduction of the TVA size after 12 months, with no residual significant TR.

c. DA VINGI

The DA VINGI is a percutaneous annuloplasty device designed to treat the mitral and tricuspid valves. This device allows complete annuloplasty with a single-step implant. Following a healing period (90 days), the ring is adjusted percutaneously. The device has been successfully implanted to date in 6 patients [45].

d. TRIALING

The TRIALING (Mitralign Inc., Tewksbury, MA, USA) is a direct suture device that reproduces the Kay tricuspid bicuspidization surgical technique leading to the obliteration of the posterior leaflet of the TV. Through a transjugular percutaneous access, two pledgets are inserted in the anteroposterior and posteroseptal commissures. The pledgets are then approximated with a cinching mechanism, bringing both commissures together and obliterating the posterior leaflet. The first published experience corresponds to 14 patients with moderate to severe functional TR, achieving a 51% decrease in EROA and a 34% reduction of the TVA area [46]. The early feasibility SCOUT I trial included 15 patients with functional TR and the device was successfully implanted in all patients [47]. One patient required right coronary angioplasty due to extrinsic compression. At 30-days follow-up, 3 single-pledget annular detachment were documented without reintervention. In the remaining 12 cases, a significant reduction in the TVA area and EROA were observed, together with clinical improvement in functional status [47]. After 12 months, only one patient required surgery. The SCOUT II study is currently ongoing and will include 60 patients [48].

e. TRICINCH

The TriCinch (4Tech Cardio, Galway, Ireland) is an annuloplasty system that consists of a screw for anchoring to the TVA at its supra-ventricular anterior area and a Dacron band attached to an expandable stent that is placed at the inferior vena cava (IVC), generating tension and thus reducing the diameter of the septolateral diameter of the TVA. In the PREVENT study, 24 patients were treated with the first generation of this device. Implantation success was achieved in 81% of the patients, with a reduction of one grade or more in the severity of TR in 94% of the cases, together with functional class improvement. However, two patients suffered hemopericardium and 5 late detachments were recorded. Because of this, the second-generation TriCinch was developed, incorporating an improved anchoring coil system that is inserted in the pericardial space with two hemostatic seals. The first in-human experience suggests that the device is safe.

f. PASTA

Lastly, the Pledget-assisted suture tricuspid annuloplasty (PASTA) device is an annuloplasty system that reproduces Hetzer's double orifice suture technique. Two sutures are placed at ring level in its anterolateral and posteroseptal portion, with tightening and approximation of the extremities, creating a tricuspid valve with two orifices similar to the final outcome obtained after percutaneous mitral valve repair with the MitraClip device. The first experience was obtained in a porcine model, with good results [49]. The first experience in humans has recently been published, evidencing a marked reduction in valve area - though dehiscence of the device occurred after two days, with the recurrence of TR [50].

g. MIA

The Minimally Invasive Annuloplasty (MIA, Micro Interventional Devices, Newtown, PA, USA) system is a sutureless device with two anchorages that allow reduction of the tricuspid ring. The STTAR study will include 40 patients and will evaluate the efficacy and safety of this device [51].

h. TRAIPTA

The transatrial intrapericardial tricuspid annuloplasty (TRAIPTA) system is an external indirect annuloplasty device. It consists of an adjustable nitinol guide that is advanced through the inferior vena cava to the atrium and penetrating the pericardium through a puncture in the right appendage. Once within the pericardial space, it is positioned in the atrioventricular sulcus, adjusting its size and thus reducing the diameter of the tricuspid ring and improving coaptation of the leaflets. The first experience was with a porcine model, in which a decrease in TR was achieved, with improvement of coaptation and reduction of the diameter of the ring, without serious complications [52]. The puncture zone was sealed with an atrial septal occluder (Amplatzer, St. Jude Medical, St. Paul, Minnesota or Lepu Medical, Beijing, China) in all cases. Although no results in humans are yet available, a new version of the device will be evaluated in a feasibility trial in the coming years.

3.2 Percutaneous tricuspid valve replacement

3.2.1 Orthotopic tricuspid valve implantation

Orthotopic TTVI implies TV replacement and the prosthesis is anchored to the native ring and leaflets. To date, there are three devices available: GATE, LUX-VALVE, TRISOL and EVOQUE (**Figure 4A-C**).

a. GATE

The GATE (NaviGate Cardiac Structures, Lake Forest, CA, USA) is a self-expanding valve dedicated for placement in the tricuspid position. This is a conical shaped device with three pericardial leaflets surrounded by a nitinol stent that has twelve atrial winglets and ventricular graspers to ensure anchoring. The device comes in 5 different sizes (36, 40, 44, 48 and 52 mm in diameter) and the procedure can be performed via transjugular or through a minithoracot-

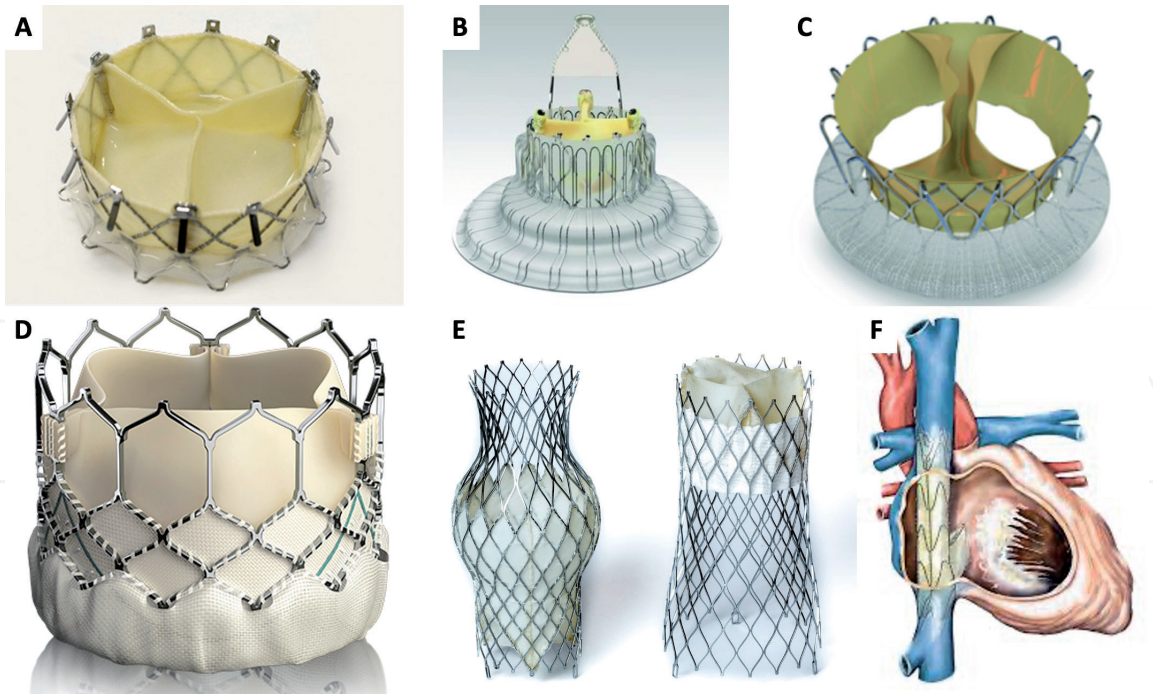


Figure 4.
A: Gate, B: Lux-valve, C: TRISOL, D: Edwards SAPIEN, E: TRICVALVE, F: TRICENTO.

omy access. The first reported compassionate use of this system in 35 patients recorded a procedural success rate of 76%, with residual TR $\leq 2+$ in all cases, and need for surgery in 14% with a 14% 30-day mortality [53]. A multicenter registry has been recently published including 30 patients with severe TR and right ventricular dysfunction in which the GATE system [54]. Technical success was achieved in 87%, but device malpositioning occurred in 4 patients, with conversion to open heart surgery in 2 of them (5%). Among those who received the device, 76% had mild or less TR at discharge with an in-hospital mortality was 10%. In addition, at 6-months follow-up, 62% of the patients were in NYHA I or II with no late device-related adverse events were documented.

b.LUX-VALVE

LUX-Valve (Jenscare Biotechnology, Ningbo, China) is a self-expanding valve that is inserted through the right atrium via a minithoracotomy and anchored through a dedicated mechanism to the leaflets and the interventricular septum. Lu et al. published their first-in-human experience in 12 patients with severe TR and functional class IV [55]. The procedure was successful in all patients, but one patient required surgery due to bleeding and another died of an acute myocardial infarction. A decrease in TR was observed in all cases, with only one of them with a residual moderate leak. The largest series to date with results from 35 patients with severe TR and functional class III/IV has recently been communicated [56]. The mortality rate at 30 days was 5.7%, with significant clinical improvement in NYHA functional class and a decrease in right ventricle volume.

c. TRISOL

The TriSol (TriSol Medical, Yokneam, Israel) is a valve specifically designed for the treatment of TR that is still in the preclinical development phase.

d. EVOQUE

The EVOQUE valve (Edwards Lifesciences, Irvine, CA) was recently evaluated in 25 symptomatic (96% NYHA III or IV) patients with severe TR. At 30 days 76% of the patients were in NYHA I/II and 96% had a TR 2+ with a 92% of technical success [57].

3.2.2 Heterotopic tricuspid valve implantation

Heterotopic TTVI refers to the implantation of a competent valve in a position different from the native tricuspid valve. The inferior vena cava (IVC), generally in combination with the superior vena cava (SVC), are the sites of choice, leading to the ventricularization of the right atrium [17]. Therefore, this approach does not address the TR itself, but prevents from severe systemic venous congestion related to right HF. As a palliative therapy, is it usually indicated in severely symptomatic patients with end-stage HF and massive or torrential TR not deemed candidates for other invasive approaches. Compared with orthotopic TTVI, this procedure is simpler, avoids the introduction of prosthetic material in the inlet of the RV and the position of the valve does not interfere with pacemaker or defibrillator electrodes, if present [58]. On the contrary, clinical impact of untreated TR, right atrial ventricularization, persistent right atrial volume overload and potentially increased RV afterload is unknown. This group of devices includes SAPIEN, TRICVALVE and TRICENTO (**Figure 4D–F**).

a. SAPIEN

The SAPIEN (Edwards Lifesciences, Irvine, CA, USA) is a triple-leaflet bovine pericardium valve initially designed for aortic valve replacement in patients with severe aortic stenosis. The first off-label use of the SAPIEN XT in the IVC was published in 2013 in three patients [59]. After that initial experience, this technique was tested in a randomized controlled trial that included 28 patients comparing medical treatment versus percutaneous implantation of this valve in the IVC. The main endpoint of the trial was the exercise capacity evaluated by cardiopulmonary exercise test. Nevertheless, this study had to be suspended prematurely due to futility and to the recording of numerous complications in the device group [60]. The analysis of available data evidenced a systolic decrease in the hepatic vein flow, without reverse RV remodeling [61]. In a recent retrospective multicenter registry enrolling 25 patients with severe symptomatic TR undergoing heterotopic TTVI (72% SAPIEN XT/3, 24% TRICVALVE and 4% DIRECTFLOW) in the IVC (76%) or both VC (24%), the procedure was successful in 96% of the patients although in-hospital mortality was 16% [62].

b. TRICVALVE

The TRICVALVE (P&F Products & Features, Vienna, Austria) is a device specifically designed for its implantation in VC. It consists of two self-expanding bovine pericardium valves on a nitinol stent, one for each VC. Lauten et al. published first in-human experience in 2011 in a patient that showed clinical functional improvement after 8 weeks [63]. The TRICUS feasibility study is currently ongoing and will include 10 patients in order to evaluate of clinical and adverse events using this device [NCT03723239].

c. TRICENTO

The Tricento (NVT, Muri, Switzerland) is a coated bicaval covered stent with a bicuspid valve positioned laterally that allows inflow into the right atrium. Since the first experience reported in 2018 [64], isolated cases have been published, with good periprocedural results [65, 66].

3.3 Outcomes after transcatheter tricuspid valve therapies

3.3.1 Clinical benefits

Most feasibility studies and observational registries have shown a significant clinical improvement in terms of NYHA functional class, quality of life or 6-minute walk test in patients undergoing PTVR or TTVI. These changes were observed even after conservative reductions of TR of 1 or 2 grades after PTVR. Nevertheless, no data are available from randomized controlled trials comparing percutaneous approach with medical management, and current reported follow-up does not exceed 1 or 2 years after the invasive procedure.

With regard to cardiovascular events, Orban et al. evaluated rates of admissions due to HF in 119 patients undergoing isolated PTVR (MitraClip 97%) comparing the year before and after the procedure [67]. PTVR was associated with a significant reduction in the grade of TR to moderate or less in 72% of the cases and with a significant lesser incidence of HF admissions ($p = 0.02$).

Recently, results from the TriValve registry that included 312 patients mostly treated with MitraClip device, reported that 30-day mortality was significantly lower among those with procedural success (1.9% vs. 6.9%, $p = 0.04$) [68]. Furthermore, more recently, Taramasso et al. published a retrospective propensity matched case–control study that included 268 patients from the same registry who underwent PTVR and observed significant lower 1-year mortality ($23 \pm 3\%$ vs. $36 \pm 3\%$, $p = 0.001$) and rehospitalization ($26 \pm 3\%$ vs. $47 \pm 3\%$, $p < 0.0001$) rates when compared to controls managed conservatively [69]. In addition, those patients treated with PTVR had higher survival after adjusted for sex, NYHA functional class, right ventricular dysfunction and AF. Although these results are encouraging, potential survival benefit of transcatheter tricuspid valve interventions over stand-alone medical therapy needs to be tested in clinical trials. Currently, diverse ongoing randomized trials will assess this issue in patients receiving TriClip, Pascal, Cardioband, and other PTVR devices.

3.3.2 Predictors of outcomes

One of the major limitations of TV surgery is reported high periprocedural mortality. Despite transcatheter approaches seem to significantly reduce this risk, patient selection remains key to achieve optimal procedural and clinical results. In this regard, some important determinants of outcomes have been already suggested:

- a. PH and RV function: Lurz et al. evaluated invasive pulmonary artery pressures and echocardiographic parameters in 243 patients who underwent PTVR [70]. The presence of invasive PH, defined as pulmonary artery systolic pressure > 50 mmHg, together with discordant absence of PH by echocardiographic estimation, was associated with the combined primary endpoint of all-cause mortality, need for repeat hospitalization for HF and reintervention during follow-up. This could be explained because in advanced stages of TR associated with adverse RV remodeling with severe dilation of the TV annulus,

pulmonary hypertension may be severely underestimated by echocardiography. Moreover, Stocker et al. observed in a multicenter study including 236 patients that invasive mean pulmonary artery pressure, transpulmonary gradient, pulmonary vascular resistance and RV stroke work were significant predictors of 1-year mortality, and that patients with pre-capillary PH had the worse prognosis [71]. Similarly, the ratio between TAPSE/invasive PH <0.29 mm/mmHg has also shown adverse prognosis impact [72]. This finding points out the close relationship between the RV function and PH. So-called RV-PA coupling refers to the fact that RV contractility should “match” the RV afterload.

b. Nutritional status: from a clinical perspective, a recent study reported that an impaired nutritional status is also associated with an increased risk of death and rehospitalization for heart failure after PTVR [73]. This finding is important since to date most patients were referred to invasive management at an advance stage of RV failure in which nutritional status might be already impaired and this can impact outcomes.

3.3.3 Patient and device selection

The decision-making process for patient and device selection in these early stages of percutaneous approaches to treat TR prompts exhaustive clinical evaluation, specifically guided right heart catheterization and transesophageal hemodynamic and anatomical evaluation, and heart team meeting. **Figure 5** summarizes a theoretical approach.

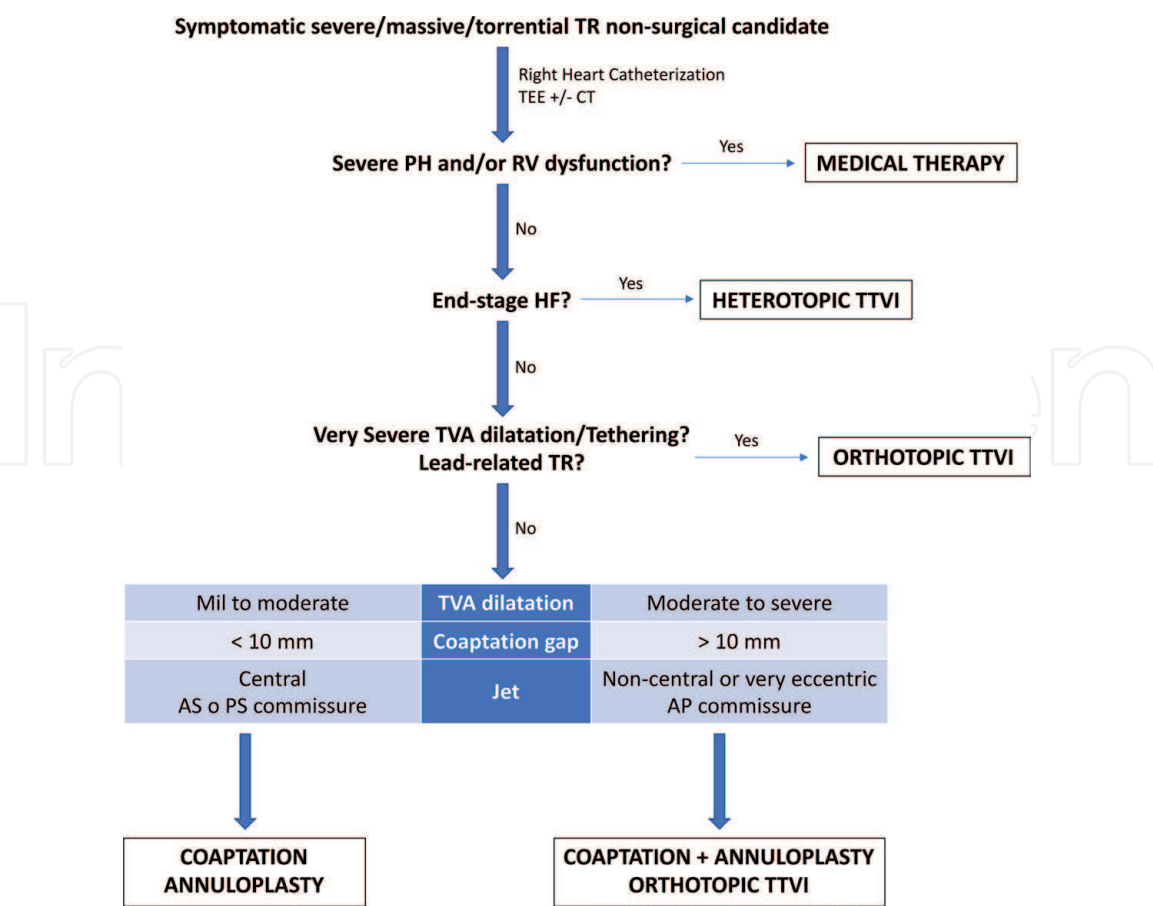


Figure 5.
Theoretical algorithm for device selection. TTVI: Transcatheter tricuspid valve implantation, AP: Anteroseptal, PS: Posteroseptal, AP: Anteroposterior.

4. Conclusions

TR is a common heart valve disease associated with high morbidity and mortality when conservatively managed. Surgery is currently the treatment of choice, though very few patients with isolated TR undergo TV surgery in the real-world setting due to high surgical risk. In recent years, different percutaneous treatment devices have been developed offering promising results with much lower procedural adverse outcomes. Further studies are needed to find which will benefit the most from these therapies.

Conflict of interest

Rodrigo Estévez and Carmen Garrote are proctors for MitraClip.

Appendices and Nomenclature

AF	Atrial Fibrillation
CHD	Congenital Heart Disease
EMB	Endomyocardial biopsy
EROA	Effective Regurgitant Orifice Area
FAC	Fractional Area Change
ICD	Implantable Cardiac Device
MIA	Minimally Invasive Annuloplasty
PAP	Pulmonary Artery Pressure
PASTA	Pledget-assisted suture tricuspid annuloplasty
PH	Pulmonary hypertension
PTVR	Percutaneous Tricuspid Valve Repair
RV	Right ventricle
TAPSE	Tricuspid Annular Plane Systolic Excursion
TR	Tricuspid Regurgitation
TRAIPTA	Transatrial Intrapericardial Tricuspid Annuloplasty
TTVI	Transcatheter Tricuspid Valve Implantation
TV	Tricuspid valve
TVA	Tricuspid Valve Annulus
VC	vena contracta
3D VCA	three-dimensional vena contracta área

IntechOpen

Author details

Carlos Minguito-Carazo¹, Tomás Benito-González^{1*}, Rodrigo Estévez-Loureiro²,
Carmen Garrote-Coloma¹, Julio Echarte-Morales¹, Armando Pérez de Prado¹
and Felipe Fernández-Vázquez¹

1 Department of Cardiology, University Hospital of León, León, Spain

2 Department of Cardiology, University Hospital Alvaro Cunqueiro, Vigo, Spain

*Address all correspondence to: tomasbenito@outlook.com

IntechOpen

© 2021 The Author(s). Licensee IntechOpen. This chapter is distributed under the terms of the Creative Commons Attribution License (<http://creativecommons.org/licenses/by/3.0>), which permits unrestricted use, distribution, and reproduction in any medium, provided the original work is properly cited. 

References

- [1] Demir OM, Regazzoli D, Mangieri A, Ancona MB, Mitomo S, Weisz G, et al. Transcatheter Tricuspid Valve Replacement: Principles and Design [Internet]. Vol. 5, *Frontiers in Cardiovascular Medicine*. Frontiers Media S.A.; 2018 [cited 2020 Dec 10]. Available from: <https://pubmed.ncbi.nlm.nih.gov/30283790/>
- [2] Singh JP, Evans JC, Levy D, Larson MG, Freed LA, Fuller DL, et al. Prevalence and clinical determinants of mitral, tricuspid, and aortic regurgitation (The Framingham Heart Study). *Am J Cardiol* [Internet]. 1999 Mar 15 [cited 2020 Dec 10];83(6):897-902. Available from: <https://pubmed.ncbi.nlm.nih.gov/10190406/>
- [3] Rodés-Cabau J, Taramasso M, O’Gara PT. Diagnosis and treatment of tricuspid valve disease: current and future perspectives [Internet]. Vol. 388, *The Lancet*. Lancet Publishing Group; 2016 [cited 2020 Dec 10]. p. 2431-42. Available from: <https://pubmed.ncbi.nlm.nih.gov/27048553/>
- [4] Wang N, Fulcher J, Abeysuriya N, McGrady M, Wilcox I, Celermajer D, et al. Tricuspid regurgitation is associated with increased mortality independent of pulmonary pressures and right heart failure: A systematic review and meta-analysis. *Eur Heart J* [Internet]. 2019 [cited 2020 Dec 10];40(5):476-84. Available from: <https://pubmed.ncbi.nlm.nih.gov/30351406/>
- [5] Topilsky Y, Nkomo VT, Vatury O, Michelena HI, Letourneau T, Suri RM, et al. Clinical outcome of isolated tricuspid regurgitation. *JACC Cardiovasc Imaging* [Internet]. 2014 [cited 2020 Dec 10];7(12):1185-94. Available from: <https://pubmed.ncbi.nlm.nih.gov/25440592/>
- [6] Stuge O, Liddicoat J. Emerging opportunities for cardiac surgeons within structural heart disease [Internet]. Vol. 132, *Journal of Thoracic and Cardiovascular Surgery*. J Thorac Cardiovasc Surg; 2006 [cited 2020 Dec 10]. p. 1258-61. Available from: <https://pubmed.ncbi.nlm.nih.gov/17140937/>
- [7] Zack CJ, Fender EA, Chandrashekar P, Reddy YNV, Bennett CE, Stulak JM, et al. National Trends and Outcomes in Isolated Tricuspid Valve Surgery. *J Am Coll Cardiol* [Internet]. 2017 Dec 19 [cited 2020 Dec 10];70(24):2953-60. Available from: <https://pubmed.ncbi.nlm.nih.gov/29241483/>
- [8] Alqahtani F, Berzingi CO, Aljohani S, Hijazi M, Al-Hallak A, Alkhouli M. Contemporary Trends in the Use and Outcomes of Surgical Treatment of Tricuspid Regurgitation. *J Am Heart Assoc* [Internet]. 2017 Dec 22 [cited 2020 Dec 10];6(12). Available from: <https://pubmed.ncbi.nlm.nih.gov/29273638/>
- [9] Kawada N, Naganuma H, Muramatsu K, Ishibashi-Ueda H, Bando K, Hashimoto K. Redefinition of tricuspid valve structures for successful ring annuloplasty. *J Thorac Cardiovasc Surg* [Internet]. 2018 Apr 1 [cited 2020 Dec 10];155(4):1511-1519.e1. Available from: <https://pubmed.ncbi.nlm.nih.gov/29366576/>
- [10] Athavale S, Deopujari R, Sinha U, Lalwani R, Kotgirwar S. Is tricuspid valve really tricuspid? *Anat Cell Biol* [Internet]. 2017 Mar 1 [cited 2020 Dec 10];50(1):1-6. Available from: <https://pubmed.ncbi.nlm.nih.gov/28417048/>
- [11] Lama P, Tamang BK, Kulkarni J. Morphometry and aberrant morphology of the adult human tricuspid valve leaflets. *Anat Sci Int* [Internet]. 2016 Mar 1 [cited 2020 Dec 10];91(2):143-50. Available from: <https://pubmed.ncbi.nlm.nih.gov/25677415/>

- [12] Santaló-Corcoy M, Asmarats L, Li C-H, Arzamendi D. Catheter-based treatment of tricuspid regurgitation: state of the art. *Ann Transl Med* [Internet]. 2020 Aug [cited 2020 Dec 10];8(15):964-964. Available from: <https://pubmed.ncbi.nlm.nih.gov/32953764/>
- [13] Taramasso M, Maisano F. Novel Technologies for percutaneous treatment of tricuspid valve regurgitation. *Eur Heart J* [Internet]. 2017 Sep 21 [cited 2020 Dec 10];38(36):2707-10. Available from: <https://pubmed.ncbi.nlm.nih.gov/29044389/>
- [14] Chang CC, Veen KM, Hahn RT, Bogers AJJC, Latib A, Oei FBS, et al. Uncertainties and challenges in surgical and transcatheter tricuspid valve therapy: A state-of-the-art expert review [Internet]. Vol. 41, *European Heart Journal*. Oxford University Press; 2020 [cited 2020 Dec 10]. p. 1932-40. Available from: <https://pubmed.ncbi.nlm.nih.gov/31511897/>
- [15] Rogers JH, Bolling SF. The tricuspid valve: Current perspective and evolving management of tricuspid regurgitation. *Circulation* [Internet]. 2009 May 26 [cited 2017 Jan 29];119(20):2718-25. Available from: <http://www.ncbi.nlm.nih.gov/pubmed/19470900>
- [16] Badano LP, Muraru D, Enriquez-Sarano M. Assessment of functional tricuspid regurgitation [Internet]. Vol. 34, *European Heart Journal*. *Eur Heart J*; 2013 [cited 2020 Dec 10]. p. 1875-84. Available from: <https://pubmed.ncbi.nlm.nih.gov/23303656/>
- [17] Mangieri A, Montalto C, Pagnesi M, Jabbour RJ, Rodés-Cabau J, Moat N, et al. Mechanism and Implications of the Tricuspid Regurgitation: From the Pathophysiology to the Current and Future Therapeutic Options [Internet]. Vol. 10, *Circulation: Cardiovascular Interventions*. Lippincott Williams and Wilkins; 2017 [cited 2020 Dec 10]. Available from: <https://pubmed.ncbi.nlm.nih.gov/28698289/>
- [18] Utsunomiya H, Itabashi Y, Mihara H, Berdejo J, Kobayashi S, Siegel RJ, et al. Functional Tricuspid Regurgitation Caused by Chronic Atrial Fibrillation: A Real-Time 3-Dimensional Transesophageal Echocardiography Study. *Circ Cardiovasc Imaging* [Internet]. 2017 Jan 1 [cited 2020 Dec 10];10(1). Available from: <https://pubmed.ncbi.nlm.nih.gov/28073806/>
- [19] Taramasso M, Calen C, Guidotti A, Kuwata S, Bieffer HRC, Nietlispach F, et al. Management of tricuspid regurgitation: The role of transcatheter therapies. *Interv Cardiol Rev* [Internet]. 2017 Mar 1 [cited 2020 Dec 10];12(1):51-5. Available from: <https://pubmed.ncbi.nlm.nih.gov/31511897/>
- [20] Zoghbi WA, Adams D, Bonow RO, Enriquez-Sarano M, Foster E, Grayburn PA, et al. Recommendations for Noninvasive Evaluation of Native Valvular Regurgitation: A Report from the American Society of Echocardiography Developed in Collaboration with the Society for Cardiovascular Magnetic Resonance. *J Am Soc Echocardiogr* [Internet]. 2017 Apr [cited 2018 Mar 11];30(4):303-71. Available from: <http://www.ncbi.nlm.nih.gov/pubmed/28314623>
- [21] Hahn RT, Zamorano JL. The need for a new tricuspid regurgitation grading scheme [Internet]. Vol. 18, *European Heart Journal Cardiovascular Imaging*. Oxford University Press; 2017 [cited 2020 Dec 10]. p. 1342-3. Available from: <https://pubmed.ncbi.nlm.nih.gov/28977455/>
- [22] Santoro C, Marco Del Castillo A, González-Gómez A, Monteagudo JM, Hinojar R, Lorente A, et al. Mid-term outcome of severe tricuspid

regurgitation: Are there any differences according to mechanism and severity? *Eur Heart J Cardiovasc Imaging* [Internet]. 2019 Sep 1 [cited 2020 Dec 10];20(9):1035-42. Available from: <https://pubmed.ncbi.nlm.nih.gov/30830219/>

[23] Prihadi EA, Van Der Bijl P, Dietz M, Abou R, Vollema EM, Marsan NA, et al. Prognostic Implications of Right Ventricular Free Wall Longitudinal Strain in Patients With Significant Functional Tricuspid Regurgitation. *Circ Cardiovasc Imaging* [Internet]. 2019 Mar 1 [cited 2020 Dec 10];12(3). Available from: <https://pubmed.ncbi.nlm.nih.gov/30879327/>

[24] Khalique OK, Cavalcante JL, Shah D, Guta AC, Zhan Y, Piazza N, et al. Multimodality Imaging of the Tricuspid Valve and Right Heart Anatomy [Internet]. Vol. 12, *JACC: Cardiovascular Imaging*. Elsevier Inc.; 2019 [cited 2020 Dec 10]. p. 516-31. Available from: <https://pubmed.ncbi.nlm.nih.gov/30846125/>

[25] Nath J, Foster E, Heidenreich PA. Impact of Tricuspid Regurgitation on Long-Term Survival. *J Am Coll Cardiol* [Internet]. 2004 Feb 4 [cited 2020 Dec 10];43(3):405-9. Available from: <https://pubmed.ncbi.nlm.nih.gov/15013122/>

[26] Chorin E, Rozenbaum Z, Topilsky Y, Konigstein M, Ziv-Baran T, Richert E, et al. Tricuspid regurgitation and long-term clinical outcomes. *Eur Heart J Cardiovasc Imaging* [Internet]. 2020 Sep 23 [cited 2020 Dec 10];21(2):157-65. Available from: <https://academic.oup.com/ehjci/advance-article/doi/10.1093/ehjci/jez216/5572606>

[27] Topilsky Y, Nkomo VT, Vatury O, Michelena HI, Letourneau T, Suri RM, et al. Clinical outcome of isolated tricuspid regurgitation. *JACC Cardiovasc Imaging* [Internet]. 2014 Dec [cited 2017 Jan

29];7(12):1185-94. Available from: <http://linkinghub.elsevier.com/retrieve/pii/S1936878X14007372>

[28] Wang TKM, Griffin BP, Miyasaka R, Xu B, Popovic ZB, Pettersson GB, et al. Isolated surgical tricuspid repair versus replacement: Meta-analysis of 15 069 patients. *Open Hear* [Internet]. 2020 Mar 17 [cited 2020 Dec 10];7(1):1227. Available from: <http://openheart.bmj.com/>

[29] Parolari A, Barili F, Piloizzi A, Pacini D. Ring or suture annuloplasty for tricuspid regurgitation? A meta-analysis review [Internet]. Vol. 98, *Annals of Thoracic Surgery*. Elsevier USA; 2014 [cited 2020 Dec 10]. p. 2255-63. Available from: <https://pubmed.ncbi.nlm.nih.gov/25443026/>

[30] Dreyfus GD, Corbi PJ, Chan KMJ, Bahrami T. Secondary tricuspid regurgitation or dilatation: Which should be the criteria for surgical repair? *Ann Thorac Surg* [Internet]. 2005 Jan [cited 2020 Dec 10];79(1):127-32. Available from: <https://pubmed.ncbi.nlm.nih.gov/15620928/>

[31] Kolte D, Elmariah S. Current state of transcatheter tricuspid valve repair [Internet]. Vol. 10, *Cardiovascular Diagnosis and Therapy*. AME Publishing Company; 2020 [cited 2020 Dec 11]. p. 89-97. Available from: <https://pubmed.ncbi.nlm.nih.gov/32175231/>

[32] Mehr M, Taramasso M, Besler C, Ruf T, Connelly KA, Weber M, et al. 1-Year Outcomes After Edge-to-Edge Valve Repair for Symptomatic Tricuspid Regurgitation: Results From the TriValve Registry. *JACC Cardiovasc Interv* [Internet]. 2019 Aug 12 [cited 2020 Dec 11];12(15):1451-61. Available from: <https://pubmed.ncbi.nlm.nih.gov/31395215/>

[33] Braun D, Orban M, Orban M, Hagl C, Massberg S, Nabauer M, et al. Transcatheter Edge-to-Edge Repair

for Severe Tricuspid Regurgitation Using the Triple-Orifice Technique Versus the Bicuspidalization Technique [Internet]. Vol. 11, JACC: Cardiovascular Interventions. Elsevier Inc.; 2018 [cited 2020 Dec 11]. p. 1790-2. Available from: <https://pubmed.ncbi.nlm.nih.gov/30170957/>

[34] Overtchouk P, Piazza N, Granada J, Soliman O, Prendergast B, Modine T. Advances in transcatheter mitral and tricuspid therapies [Internet]. Vol. 20, BMC Cardiovascular Disorders. BioMed Central Ltd.; 2020 [cited 2020 Dec 11]. p. 1. Available from: <https://bmccardiovascdisord.biomedcentral.com/articles/10.1186/s12872-019-01312-3>

[35] Nickenig G, Weber M, Lurz P, von Bardeleben RS, Sitges M, Sorajja P, et al. Transcatheter edge-to-edge repair for reduction of tricuspid regurgitation: 6-month outcomes of the TRILUMINATE single-arm study. *Lancet* [Internet]. 2019 Nov 30 [cited 2020 Dec 10];394(10213):2002-11. Available from: <http://www.thelancet.com/article/S0140673619326005/fulltext>

[36] Taramasso M, Gavazzoni M, Pozzoli A, Alessandrini H, Latib A, Attinger-Toller A, et al. Outcomes of TTVI in Patients With Pacemaker or Defibrillator Leads: Data From the TriValve Registry. *JACC Cardiovasc Interv* [Internet]. 2020 Mar 9 [cited 2020 Dec 11];13(5):554-64. Available from: <https://pubmed.ncbi.nlm.nih.gov/31954676/>

[37] Fam NP, Braun D, von Bardeleben RS, Nabauer M, Ruf T, Connelly KA, et al. Compassionate Use of the PASCAL Transcatheter Valve Repair System for Severe Tricuspid Regurgitation: A Multicenter, Observational, First-in-Human Experience. *JACC Cardiovasc Interv* [Internet]. 2019 Dec 23 [cited 2020 Dec 11];12(24):2488-95. Available

from: <https://pubmed.ncbi.nlm.nih.gov/31857018/>

[38] Braun D, Löw K, Orban M, Mehr M, Gmeiner J, Massberg S, et al. MITRACLIP XTR VS. PASCAL TRANSCATHETER VALVE REPAIR SYSTEM FOR EDGE-TO-EDGE REPAIR OF SEVERE TRICUSPID REGURGITATION. *J Am Coll Cardiol*. 2020;

[39] Muntané-Carol G, Alperi A, Faroux L, Bédard E, Philippon F, Rodés-Cabau J. Transcatheter Tricuspid Valve Intervention: Coaptation Devices. *Front Cardiovasc Med* [Internet]. 2020 Aug 13 [cited 2020 Dec 11];7:139. Available from: <https://www.frontiersin.org/article/10.3389/fcvm.2020.00139/full>

[40] Asmarats L, Perlman G, Praz F, Hensey M, Chrissoheris MP, Philippon F, et al. Long-Term Outcomes of the FORMA Transcatheter Tricuspid Valve Repair System for the Treatment of Severe Tricuspid Regurgitation: Insights From the First-in-Human Experience. *JACC Cardiovasc Interv* [Internet]. 2019 Aug 12 [cited 2020 Dec 11];12(15):1438-47. Available from: <https://pubmed.ncbi.nlm.nih.gov/31395213/>

[41] Planer D, Beerli R, Danenberg HD. First-in-Human Transcatheter Tricuspid Valve Repair: 30-Day Follow-Up Experience With the Mistral Device. *JACC Cardiovasc Interv* [Internet]. 2020 Sep 28 [cited 2020 Dec 11];13(18):2091-6. Available from: <https://pubmed.ncbi.nlm.nih.gov/32972568/>

[42] Nickenig G, Weber M, Schüler R, Hausleiter J, Nabauer M, von Bardeleben RS, et al. Two-year Outcomes with the Cardioband Tricuspid System from the Multicentre, Prospective TRI-REPAIR Study. *EuroIntervention* [Internet]. 2020 Oct 13 [cited 2020 Dec 11]; Available from: <https://europepmc.org/article/med/33046437>

- [43] Davidson C, Lim S, Smith R, Kodali S, Kipperman R, Eleid M, et al. EARLY FEASIBILITY STUDY OF CARDIOBAND TRICUSPID SYSTEM FOR FUNCTIONAL TRICUSPID REGURGITATION: 30 DAY OUTCOMES. *J Am Coll Cardiol*. 2020;
- [44] Rogers JH, Boyd WD, Smith TWR, Ebner AA, Grube E, Bolling SF. Transcatheter Annuloplasty for Mitral Regurgitation with an Adjustable Semi-Rigid Complete Ring: Initial Experience with the Millipede IRIS Device. *Struct Hear*. 2018;
- [45] FiH Study of the DaVinciTM TR System in the Treatment of Patients With Functional Tricuspid Regurgitation.
- [46] Yzeiraj E, Sievert H, Nickenig G, Latib A, Hahn R, Schofer J. TCT-86 Early Experience with the Trialign System for Transcatheter Tricuspid Valve Repair: A Multicenter Experience. *J Am Coll Cardiol*. 2016;
- [47] Hahn RT, Meduri CU, Davidson CJ, Lim S, Nazif TM, Ricciardi MJ, et al. Early Feasibility Study of a Transcatheter Tricuspid Valve Annuloplasty: SCOUT Trial 30-Day Results. *J Am Coll Cardiol* [Internet]. 2017 Apr 11 [cited 2020 Dec 11];69(14):1795-806. Available from: <https://pubmed.ncbi.nlm.nih.gov/28385308/>
- [48] Safety and Performance of the Trialign Percutaneous Tricuspid Valve Annuloplasty System (PTVAS) (SCOUT-II).
- [49] Khan JM, Rogers T, Schenke WH, Greenbaum AB, Babaliaros VC, Paone G, et al. Transcatheter pledget-assisted suture tricuspid annuloplasty (PASTA) to create a double-orifice valve. *Catheter Cardiovasc Interv* [Internet]. 2018 Sep 1 [cited 2020 Dec 11];92(3):E175-84. Available from: <https://pubmed.ncbi.nlm.nih.gov/29405564/>
- [50] Greenbaum AB, Khan JM, Rogers T, Babaliaros VC, Eng MHK, Wang DD, et al. First-in-human transcatheter pledget-assisted suture tricuspid annuloplasty for severe tricuspid insufficiency. *Catheter Cardiovasc Interv* [Internet]. 2020 [cited 2020 Dec 11]; Available from: <https://pubmed.ncbi.nlm.nih.gov/32385950/>
- [51] Study of Transcatheter Tricuspid Annular Repair (STTAR).
- [52] Rogers T, Ratnayaka K, Sonmez M, Franson DN, Schenke WH, Mazal JR, et al. Transatrial intrapericardial tricuspid annuloplasty. *JACC Cardiovasc Interv* [Internet]. 2015 Mar 1 [cited 2020 Dec 11];8(3):483-91. Available from: <https://pubmed.ncbi.nlm.nih.gov/25703872/>
- [53] Elgharably H, Harb SC, Kapadia S, Svensson LG, Navia JL. Transcatheter innovations in tricuspid regurgitation: Navigate. *Progress in Cardiovascular Diseases*. 2019.
- [54] Hahn RT, Kodali S, Fam N, Bapat V, Bartus K, Rodés-Cabau J, et al. Early Multinational Experience of Transcatheter Tricuspid Valve Replacement for Treating Severe Tricuspid Regurgitation. *JACC Cardiovasc Interv* [Internet]. 2020 Nov 9 [cited 2020 Dec 11];13(21):2482-93. Available from: <https://linkinghub.elsevier.com/retrieve/pii/S1936879820314989>
- [55] Lu F, Qiao F, Lv Y, An Z, Liu X, Cao P, et al. A radial force-independent bioprosthesis for transcatheter tricuspid valve implantation in a preclinical model. *Int J Cardiol* [Internet]. 2020 Nov 15 [cited 2020 Dec 11];319:120-6. Available from: <http://www.internationaljournalofcardiology.com/article/S0167527320334483/fulltext>
- [56] F. L, Z. X, X. M, H. Z, F. Q, Z. S, et al. TCT-94 A Radial Force-Independent Bioprosthesis for Transcatheter Tricuspid Valve Implantation:

First-in-Man Clinical Trial. *J Am Coll Cardiol*. 2019;

Dec 11];11(2). Available from: <https://pubmed.ncbi.nlm.nih.gov/29445001/>

[57] TRISCEND Study.

[58] Kolte D, Elmariah S. Transcatheter Tricuspid Valve Therapy. *Curr Treat Options Cardiovasc Med* [Internet]. 2019 Jun 18 [cited 2020 Dec 11];21(6):26. Available from: <http://link.springer.com/10.1007/s11936-019-0730-7>

[59] Laule M, Stangl V, Sanad W, Lembcke A, Baumann G, Stangl K. Percutaneous transfemoral management of severe secondary tricuspid regurgitation with edwards sapien XT bioprosthesis: First-in-man experience [Internet]. Vol. 61, *Journal of the American College of Cardiology*. *J Am Coll Cardiol*; 2013 [cited 2020 Dec 11]. p. 1929-31. Available from: <https://pubmed.ncbi.nlm.nih.gov/23500268/>

[60] Dreger H, Mattig I, Hewing B, Knebel F, Lauten A, Lembcke A, et al. Treatment of Severe TRICuspid regurgitation in patients with advanced heart failure with caval vein implantation of the edwards sapien XT valve (TRICAVAL): A randomised controlled trial. *EuroIntervention* [Internet]. 2020 Apr 1 [cited 2020 Dec 11];15(17):1506-13. Available from: <https://pubmed.ncbi.nlm.nih.gov/31929100/>

[61] Mattig I, Knebel F, Hewing B, Stangl V, Stangl K, Laule M, et al. Impact of inferior caval valve implantation on severity of tricuspid regurgitation and right heart function. *Echocardiography* [Internet]. 2020 Jul 14 [cited 2020 Dec 11];37(7):999-1007. Available from: <https://onlinelibrary.wiley.com/doi/abs/10.1111/echo.14760>

[62] Lauten A, Figulla HR, Unbehauen A, Fam N, Schofer J, Doenst T, et al. Interventional Treatment of Severe Tricuspid Regurgitation. *Circ Cardiovasc Interv* [Internet]. 2018 Feb 1 [cited 2020

[63] Lauten A, Ferrari M, Hekmat K, Pfeifer R, Dannberg G, Ragooschke-Schumm A, et al. Heterotopic transcatheter tricuspid valve implantation: First-in-man application of a novel approach to tricuspid regurgitation. *Eur Heart J* [Internet]. 2011 May [cited 2020 Dec 11];32(10):1207-13. Available from: <https://pubmed.ncbi.nlm.nih.gov/21300731/>

[64] Toggweiler S, De Boeck B, Brinkert M, Buhmann R, Bossard M, Kobza R, et al. First-in-man implantation of the Tricento transcatheter heart valve for the treatment of severe tricuspid regurgitation. *EuroIntervention* [Internet]. 2018 Sep 1 [cited 2020 Dec 11];14(7):758-61. Available from: <https://pubmed.ncbi.nlm.nih.gov/29969434/>

[65] Montorfano M, Beneduce A, Ancona MB, Ancona F, Sgura F, Romano V, et al. Tricento Transcatheter Heart Valve for Severe Tricuspid Regurgitation: Procedural Planning and Technical Aspects. *JACC Cardiovasc Interv* [Internet]. 2019 Nov 11 [cited 2020 Dec 11];12(21):e189-91. Available from: <https://linkinghub.elsevier.com/retrieve/pii/S1936879819315213>

[66] Werner P, Russo M, Scherzer S, Aref T, Coti I, Mascherbauer J, et al. Transcatheter Caval Valve Implantation of the Tricento Valve for Tricuspid Regurgitation Using Advanced Intraprocedural Imaging. *JACC Case Reports* [Internet]. 2019 Dec [cited 2020 Dec 11];1(5):720-4. Available from: <https://linkinghub.elsevier.com/retrieve/pii/S2666084919304735>

[67] Orban M, Rommel KP, Ho EC, Unterhuber M, Pozzoli A, Connelly KA, et al. Transcatheter Edge-to-Edge Tricuspid Repair for Severe Tricuspid Regurgitation Reduces Hospitalizations

for Heart Failure. *JACC Hear Fail*. 2020 Apr 1;8(4):265-76.

[68] Taramasso M, Alessandrini H, Latib A, Asami M, Attinger-Toller A, Biasco L, et al. Outcomes After Current Transcatheter Tricuspid Valve Intervention: Mid-Term Results From the International TriValve Registry. *JACC Cardiovasc Interv* [Internet]. 2019 Jan 28 [cited 2020 Dec 11];12(2):155-65. Available from: <https://pubmed.ncbi.nlm.nih.gov/30594510/>

[69] Taramasso M, Benfari G, van der Bijl P, Alessandrini H, Attinger-Toller A, Biasco L, et al. Transcatheter Versus Medical Treatment of Patients With Symptomatic Severe Tricuspid Regurgitation. *J Am Coll Cardiol* [Internet]. 2019 Dec 17 [cited 2020 Dec 11];74(24):2998-3008. Available from: <https://pubmed.ncbi.nlm.nih.gov/31568868/>

[70] Lurz P, Orban M, Besler C, Braun D, Schlotter F, Noack T, et al. Clinical characteristics, diagnosis, and risk stratification of pulmonary hypertension in severe tricuspid regurgitation and implications for transcatheter tricuspid valve repair. *Eur Heart J* [Internet]. 2020 Aug 1 [cited 2020 Dec 11];41(29):2785-95. Available from: <https://pubmed.ncbi.nlm.nih.gov/32176280/>

[71] Stocker TJ, Hertell H, Orban M, Braun D, Rommel K-P, Ruf T, et al. Cardiopulmonary Hemodynamic Profile Predicts Mortality After Transcatheter Tricuspid Valve Repair in Chronic Heart Failure. *JACC Cardiovasc Interv* [Internet]. 2020 Dec [cited 2020 Dec 11]; Available from: <https://linkinghub.elsevier.com/retrieve/pii/S1936879820319713>

[72] D'Alto M, Naeije R. Transcatheter tricuspid valve repair in patients with pulmonary hypertension [Internet]. Vol. 41, *European Heart Journal*. Oxford University Press; 2020 [cited 2020

Dec 11]. p. 2811-2. Available from: <https://academic.oup.com/eurheartj/article/41/29/2811/5865473>

[73] Besler C, Unterhuber M, Rommel KP, Unger E, Hartung P, von Roeder M, et al. Nutritional status in tricuspid regurgitation: implications of transcatheter repair. *Eur J Heart Fail* [Internet]. 2020 Oct 26 [cited 2020 Dec 11];22(10):1826-36. Available from: <https://onlinelibrary.wiley.com/doi/10.1002/ejhf.1752>