

We are IntechOpen, the world's leading publisher of Open Access books Built by scientists, for scientists

6,900

Open access books available

185,000

International authors and editors

200M

Downloads

Our authors are among the

154

Countries delivered to

TOP 1%

most cited scientists

12.2%

Contributors from top 500 universities



WEB OF SCIENCE™

Selection of our books indexed in the Book Citation Index
in Web of Science™ Core Collection (BKCI)

Interested in publishing with us?
Contact book.department@intechopen.com

Numbers displayed above are based on latest data collected.
For more information visit www.intechopen.com



Cervicogenic Headache Hypothesis and Anterior Cervical Decompression as a Treatment Paradigm

Amir Goodarzi, Edwin Kulubya, Tejas Karnati and Kee Kim

Abstract

Cervicogenic headaches are a controversial clinical entity that affect many patients suffering from cervical spondylosis. Understanding the pathogenesis and identifying the nociceptive sources of cervicogenic headaches is critical to properly treat these headaches. A multimodal approach is necessary to treat these headaches using a variety of medical tools. Surgical interventions are reserved for patients that fail maximal medical therapy. The anterior cervical spine surgery has shown promise in the treatment of cervicogenic headaches and this success has hinted at a ventral source of nociceptive pathology. Continued research and development are required to improve outcomes in patients suffering from cervicogenic headaches.

Keywords: cervicogenic, headache, sinovertebral nerve, neck pain, referred pain

1. Introduction

Cervicogenic headaches (CGH) were first recognized as a distinct pathologic entity in the 1980's to describe a group of patients suffering from headaches that occurred in the presence of cervical spondylosis and neck pain. The diagnostic criteria and pathogenesis of CGH have remained contentious with many competing hypotheses described in recent years. However, despite the knowledge gap and lack of a comprehensive understanding of the underlying pathogenesis, significant clinical evidence has been published on successful treatment paradigms for CGH. Clinicians have used a variety of approaches in treating cervicogenic headaches including both medical and surgical techniques. Anterior cervical decompressive surgery is a minimally invasive procedure that has demonstrated promising and durable results for symptom relief in CGH. In this chapter we review the pathogenesis, diagnosis, and some of the minimally invasive surgical techniques used to treat cervicogenic headaches.

2. Current understanding of cervicogenic headache pathogenesis

The term cervicogenic headache (CGH) was first conceived in 1983 by Sjaastad et al. to describe patients experiencing episodic headaches that were triggered by

stereotypical neck movements in the setting of cervical pathology (e.g. radiculopathy, myelopathy, soft tissue lesions) [1]. Sjaasted et al. observed that these headaches were accompanied by neck pain, neck rigidity, and dysautonomia. The dysautonomic symptoms included unilateral lacrimation, rhinorrhea, tinnitus, blurred vision, flushing of the face, photophobia, phonophobia, nausea, and vomiting [1, 2]. Most peculiarly, many patients noted myofascial trigger points in the neck, ipsilateral to the headaches, that could precipitate their symptoms with great intensity [1–3].

Over the last decade, there has been continued controversy regarding a consistent definition for CGH. However, a common framework has recently been established by the International Headache Society's Headache classification (ICHD-3). The ICHD-3 defines CGH as headaches in the presence of neck pain and pathology of the cervical spine, including disease related to bone, disc, and/or soft tissue [3]. The ICHD-3 diagnostic criteria require clinical and/or imaging evidence of cervical pathology (bone or soft tissue) and at least two of the following criteria: 1. temporal relation of headache onset and the spinal pathology; 2. headache improvement or resolution in parallel to improvement or resolution of spinal pathology; 3. reduced neck mobility and provocation of headache by stereotypical neck movements; 4. resolution of headaches after diagnostic cervical spine injections or associated nerve blocks [3].

These ICHD-3 criteria allow for a more standardized method of diagnosing CGH, however, given the relative lack of their use in prior publications, it is not surprising that there is tremendous variability in the reported rates of CGH prevalence. The estimated prevalence of CGH is reported to be 0.4–4% in the general population. However, in patients diagnosed with cervical pathology, greater than 85% may experience CGH, with a significant impact on patient morbidity, and quality of life [4–8]. Thus, given the high prevalence, and substantial influence on patient outcomes, it is imperative to formulate an understanding of the pathogenesis of CGH to develop appropriate treatment strategies.

3. Pathogenesis

The details of the pathogenesis of cervicogenic headaches remain elusive. As we review the current understanding of the pathogenesis of CGH, it is worth noting that most of the proposed theories rely on clinical findings and the underlying anatomic associations between the cervical spine and cranial nociceptive pathways. Although the origin of pain generators in the cervical spine remains speculative, neuroforaminal compression and uncovertebral joint arthropathy secondary to cervical spondylosis are likely contributors [6, 8–12]. There is some consensus regarding the transmission of the nociceptive stimulus from these potential pain generators. It is postulated that CGH are mediated through the convergence of nociceptive fibers from the upper cervical nerves (C1–C3) onto the trigeminal spinal nucleus, resulting in pain stimulus via the trigeminal afferents pathways [6, 8, 9, 13, 14]. This convergence of nociceptive stimuli can lead to the perception of fronto-temporal headaches and dysautonomia secondary to upper cervical spondylosis [8, 15].

The trigeminal afferent pathways are composed of three main nuclei and tracts: the mesencephalic nucleus and tract, the chief/principal sensory nucleus, and the spinal trigeminal nucleus and tract [16]. The spinal trigeminal tract conducts pain, temperature, and crude touch of the head, and is continuous caudally with the tract of Lissauer in the cervical spine. In the spine, the tract of Lissauer is formed by nociceptive fibers ascending and descending one to two levels in the dorsolateral

white matter before entering the gray matter and decussating to join the ascending spinothalamic tract [17]. The convergence of the trigeminal spinal tract and the tract of Lissauer is a potential point of convergence between upper cervical spine (C1-C3) pain generators and ipsilateral CGH. However, this hypothesis cannot adequately explain cases of CGH in patients with spondylosis of the lower cervical spine [18, 19]. Several hypotheses have been proposed attempting to clarify the source of CGH from the lower cervical spine. One theory proposes that CGH are referred from the lower cervical spine by abnormal muscle and spinal kinematics caused by spondylosis [12, 20]. Cadaveric studies have demonstrated that the ligamentum nuchae and suboccipital muscles can be adherent to the occipital dura in a small subset of the population. This relationship could act as a mechanical conduit for the transformation of abnormal cervical spinal kinematics into nociceptive signals transferred to the dura in patients afflicted by spondylosis [15, 21]. Another theory postulates that aberrant connections between the spinal trigeminal tract and the spinothalamic tract could result in transmission of pain stimulus from the lower cervical region to the upper cervical region and ultimately perceived as fronto-temporal headaches [12, 20]. However, none of these theories have an adequate anatomical basis to clearly support their role in CGH. We hypothesize that CGH due to spondylosis of the lower cervical spine are likely referred through the sinuvertebral nerves (SVN) [6]. The SVN innervates the uncovertebral joints, the dura of the nerve root sleeve, and the nearby intervertebral discs. It travels medio-laterally from the uncovertebral joint towards the disc space in close association with the sympathetic and vascular plexus. Most notably, the SVN sends descending collaterals up to 3-disc spaces below its level of origin to communicate with the SVN of adjacent spinal levels (**Figure 1**). Thus, this anatomic pathway can account for neurovascular irritation in the lower cervical spine being referred to C1-C3 and in turn resulting in CGH [6]. The SVN plexus, cervical vasculature, and cervical nerve root are in proximity near the neural foramina that is formed by the uncovertebral joint, and facet joint (**Figure 1**). This region, coined the unco-vasculo-radicular (UVR) junction, is a likely candidate as a pain generator in CGH [6].

The SVN and neuroforaminal compression at the UVR junction do not adequately explain the associated dysautonomia that is commonly seen in CGH. However, autonomic pathways do connect the cervical plexus and the hypoglossal and vagal nerves through the C1 and C2 nerve roots. Moreover, C1-C4 are linked through the superior

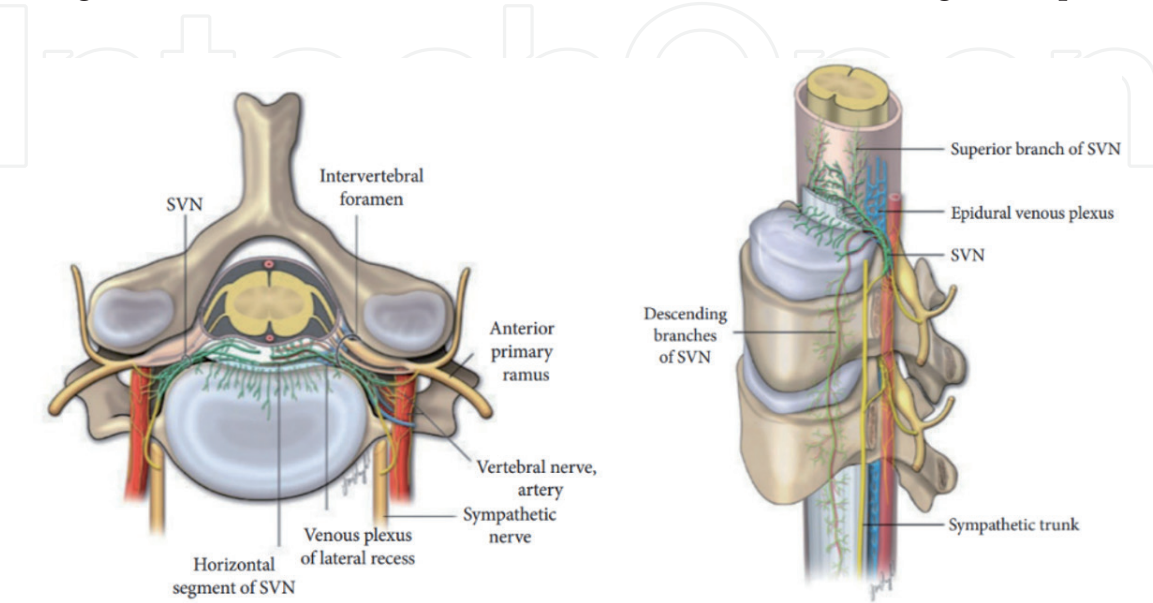


Figure 1. Axial (left) and parasagittal (right) illustration of the course of the sinuvertebral nerve and its relationship to the ventral dura mater, nerve root, and sympathetic trunk.

cervical sympathetic ganglion (**Figure 1**). Thus, irritation of the dura, or nerve root sleeve in cervical spondylosis can cause aberrant activity in the sympathetic afferent pathways resulting in autonomic symptoms [6, 22].

Admittedly the pathogenesis of CGH is still not completely understood and is likely multifactorial, however, to date, no other hypothesis has laid out a clearer pathway for the cause of CGH due to spondylosis of the upper and lower cervical spine. To further clarify this theory, we will discuss the neurovascular anatomy of the SVN in the following section.

4. Relevant anatomy

The course of the sinuvertebral nerve (SVN) and sympathetic innervation of the cervical spine including the ventral dura, disc, and facet joints are essential to understanding the potential mechanism of CGH. The SVN plays a key role in the transmission of the pain in CGH [6].

The SVN, also known as the ramus meningismus or recurrent meningeal nerve of Luschka, was first described by Von Luschka in 1850 as he noted the nerve passing through the intervertebral foramen into the spinal canal and branches that remained outside of the dura mater. Its course was further revealed through cadaveric studies by Drs. Edgar and Nundy in the 1960's [23]. The SVN, a branch of the anterior primary ramus of the cervical nerve root, travels from outside the vertebral foramen, posterolateral to the uncovertebral joint, into the spinal canal where its middle branches innervate the ventral dura, posterior longitudinal ligament, and the intervertebral disc. Near its origin it receives fibers from the sympathetic trunk through the gray ramus communicantes. It also receives sympathetic input from the vertebral nerve which courses along the vertebral artery. The SVN has ascending and descending branches that traverse up to three vertebral levels [10]. Within the foramen and lateral recess there is a close relationship with the epidural venous plexus (**Figure 1**). This region is coined the unco-vasculo-radicular (UVR) junction, a narrow pathway where the SVN plexus, cervical vasculature, and the cervical nerve root join.

Potential sources of pain generation in cervicogenic headaches include paraspinal muscles, ligamentous injury, intervertebral disc, and spondylotic changes such as uncovertebral and facet arthropathy [22]. CGH is associated with tenderness of cervical paraspinal muscles and there are myofascial trigger points that can instigate pain [24]. Facet joint instability or hypertrophy at upper cervical segments (C1 to C3) can irritate the nerves that converge at the spinal segment of the trigeminal nucleus. Spondylotic changes and disc bulges throughout the rest of the cervical spine can lead to SVN irritation through compression at the UVR junction. Cervical stenosis and kyphosis can also generate pain from placing tension on the dura [6]. Mechanical traction on suboccipital tissues, the ligamentum nuchae and rectus posterior capitis minor muscle have been postulated to place tension on the dura which can lead to CGH [25, 26].

5. Differential diagnosis and work up

Cervicogenic headaches due to spondylosis are a diagnosis of exclusion that require physicians to rule out other intracranial and intraspinal pathologies such as neoplasms, tumors, inflammatory disease, and vascular pathologies. As previously mentioned, the ICHD-3 diagnostic criteria for CGH require clinical and/or imaging evidence of cervical pathology (bone or soft tissue) and at least two of the following

criteria: 1. temporal relation of the onset of headache and the spinal pathology; 2. headache improvement or resolution in parallel to improvement or resolution of spinal pathology; 3. reduced neck mobility and provocation of headache by stereotypical neck movements; 4. resolution of headaches after diagnostic cervical spine injections or associated nerve blocks [3].

The differential diagnosis for CGH is broad, and frequently includes chronic paroxysmal headaches (CPH), C2 neuralgia, tension type headaches (TTH), and migraine headaches (MH). Differentiating CGH from these other entities can be challenging, and generally relies on symptomatology, presence of cervical pathology, and clinical response to treatment [6, 8, 27]. Patients with CGH typically experience 1 or 2 headaches per day, whereas those with CPH complain of more than 15 headaches daily; and unlike CGH, CPH patients report symptom relief with indomethacin therapy [1, 6]. C2 neuralgia presents with stereotypical pain in the occipital region and does not require the presence of unilateral neck pain often seen in CGH. Tension headaches can be bilateral, and MH can have side shifts, whereas CGH symptoms are usually unilateral on the side of the cervical pathology. Nausea/vomiting and photophobia can be present in both CGH and MH, however, their frequency and severity are much less pronounced in CGH as compared to MH. Moreover, MH symptoms may respond to ergotamine derivatives and sumatriptan whereas CGH symptoms do not [28–30].

Cervicogenic headaches typically present with episodic, and unilateral headaches that originate in the occipital area and generalize to involve fronto-temporal regions and the entire hemicranium. Unilaterality, without shifting of sides, is a hallmark presenting feature of CGH, although in severe cases bilateral symptoms have been reported [6, 31]. CGH patients will have associated radiculopathy such as pain, numbness, tingling, or weakness along the course of the involved nerve. They will often complain of reduced neck mobility. Finally, resolution of headaches after cervical and occipital nerve blocks is a defining feature of CGH.

As for radiographic features of CGH, there are no imaging characteristics that can assist in the differentiating CGH from other pathologies. Findings on computed tomography (CT), CT myelography, and magnetic resonance imaging (MRI) can include spondylosis, osteochondrosis, and disc osteophyte complex with foraminal or spinal stenosis; however, none of these features are unique to CGH [8, 32].

Neuro-interventional procedures such as intra-articular injections, nerve root blocks, and epidural injections can serve as both a diagnostic and therapeutic interventions [33, 34]. Bogduk et al. reported on 161 patients that were treated with cervical nerve root blocks and observed a reduction in CGH symptoms in 59% of patients [10]. Similarly, Persson et al. presented a series of 275 consecutive patients with cervical radiculopathy and identified 161 with CGH. Following cervical nerve root blocks, 69% of the patients in this series reported relief from CGH symptoms [7]. These series highlight the value of neuro-interventional procedures in the armamentarium of clinicians for diagnosing and treating CGH.

6. Surgical management of cervicogenic headaches

The management of patients suffering from cervicogenic headaches is a challenging task and requires a multifaceted approach. The first steps in the treatment process involve medical therapies such as multimodal analgesia, physical therapy, and neuro-interventional procedures (e.g. intra-articular/epidural injections). If the patients' symptoms fail to respond to maximal medical therapies, surgical interventions may be considered if the headache is accompanied by other signs of radiculopathy [34, 35]. There are numerous reports in the literature attesting to

successful and durable treatment of CGH with both anterior and posterior surgical approaches [6, 8, 36–40]. The common thread among the successful surgical treatments appears to be adequate decompression of the neurovascular structures at the unco-vasculo-radicular (UVR) junction. The anterior surgical approach is a minimally invasive technique that provides a direct route for ventral decompression of the UVR junction and addresses all of the potential nociceptive sources (e.g. disc, dura mater, posterior longitudinal ligament, foraminal stenosis) [38]. Conversely, the posterior approach relies on indirect decompression of the UVR junction dorsally and does not address the ventral nociceptive sources [38]. In following section we will review the existing literature for the posterior and anterior surgical techniques and describe the technical nuances of the anterior cervical surgical approach.

6.1 Posterior cervical decompressive surgery

The optimal surgical approach for the treatment of cervicogenic headaches remains controversial, with both anterior and posterior approaches reported to have an impact on symptom relief [41, 42]. Much of the surgical decision making still relies on clinical acumen and anecdotal surgeon experience, leading to variability in treatment paradigms [8, 37–39]. Despite this lack of consensus, there is some clinical evidence in support of posterior cervical decompressive surgery. Jansen et al. reported positive results on 8 patients that were successfully treated for CGH using posterior cervical laminoplasties. Six of the patients had complete relief of symptoms and 2 patients experienced improvement of their preoperative symptoms [38]. Although symptom relief appears to be considerable with posterior decompression, the durability of relief remains questionable. The durability of pain relief appears especially less pronounced as compared to the anterior approaches, with higher rates of delayed recurrence reported at 1 year [20]. Shimohata et al. noted that recurrence is typically less severe than the original symptoms and may be related to the disruption of the posterior cervical tension band resulting in abnormal spinal kinematics [20]. Similarly, Thind et al. theorized that a posterior approach can only achieve an indirect decompression of the UVR junction and fails to adequately address the irritation from the ventral dura mater and disc osteophytes [6]. Notwithstanding that the quality of the existing evidence is lacking, clinical trends appear to favor anterior cervical approaches in the treatment of CGH. Our group also advocates for the anterior cervical surgical approach when treating CGH. We believe that the anterior approach allows for a minimally invasive approach to the ventral spine, while preserving the posterior ligamentous and muscular tension band.

6.2 Anterior cervical decompressive surgery

The anterior cervical approach for addressing cervicogenic headaches is comprised of the anterior cervical discectomy and fusion (ACDF), and cervical disc arthroplasty (CDA). Similar to the posterior cervical approach, the literature on anterior approaches is heterogenous and difficult to generalize. However, there is convincing support for both ACDF and CDA in providing significant clinical relief of CGH symptoms. The anterior cervical discectomy and fusion is a well-established approach that has been applied to the treatment of CGH with favorable results. Jansen et al. presented a series of 51 patients treated with ACDF. Their results demonstrated 85% complete relief and 15% partial relief of CGH symptoms postoperatively [37]. Similarly, Liu et al. reported 34 patients undergoing ACDF with significant pain relief in all patients postoperatively [40]. Jansen et al. further

demonstrated the long-term efficacy of ACDF when reporting 86% complete and 14% partial symptom relief in a series of 56 patients diagnosed with CGH [37–39]. This long-term relief of CGH symptoms after ACDF was again demonstrated when Schofferman et al. reported long term follow up (mean 37 months) for 9 patients with CGH and associated symptoms of nausea, arm pain, dizziness, and visual disturbances. Postoperatively 56% of patients reported complete relief of headaches and 44% reported partial relief. The mean Oswestry Disability Index for these patients significantly improved from 62 to 35, and all patients stated that they would choose to undergo the same surgery again to achieve similar outcomes [43].

Cervical disc arthroplasty is a contemporary addition to the surgical armamentarium of spine surgeons that allows for the preservation of spinal motion. Recent data suggests that CDA could provide longer lasting symptom relief than ACDF when treating CGH [4, 6, 35, 41]. Riina et al. performed a post hoc analysis of two randomized, controlled, multicenter clinical trials involving 1004 patients with CGH treated by ACDF or CDA [35]. Headaches were evaluated using the Neck Disability Index (NDI) questionnaire, with 865 (86.2%) patients complaining of headaches. Mild (grade 1, 2) headaches were reported in 342 patients (34.1%), and severe (grade 3, 4, 5) headaches were reported in 523 patients (52.1%). After the 24 months follow up period, 280 (34.9%) patients reported complete relief of headaches (grade 0), 375 (46.7%) patients reported mild headaches (grade 1 or 2), and 148 patients reported severe headaches (18.4%). The majority of both ACDF (58.5%) and CDA (64%) groups demonstrated statistically significant improvements from baseline symptoms at all time points during the follow up period. Notably, 13.7% of patients in the ACDF group and 8.4% in the CDA group experienced worsening headaches. Riina and colleagues concluded that CDA patients had more frequent improvements in headaches than patients treated with ACDF. However, they found no difference in headache scores, or in overall improvement of headache severity between the two groups at 24 months follow up [35]. Schrot et al. presented slightly different findings in a post hoc analysis of 260 patients treated with single-level ACDF or CDA followed for 24 months [36]. Eighty eight percent of patients reported baseline headaches, with 52% reporting severe headaches (NDI 3 or greater) preoperatively. Unlike the results from Riina et al., the authors found no significant differences in headache relief between ACDF and CDA groups. Interestingly, Schrot et al. noted that spinal pathology of the upper cervical spine was associated with greater preoperative headache scores, although the authors failed to show any correlation between the level of operation and post-operative headache scores [36]. Liu et al. performed a more nuanced analysis of patients that underwent single and two-level ACDF or CDA and evaluated headache response to each treatment [44]. For the single level group, after 60 months of follow up, both ACDF and CDA cohorts demonstrated similar statistically significant improvements in mean NDI headache scores. For the two-level groups both ACDF and CDA cohorts showed significant improvements from baseline headache scores, however, the CDA group demonstrated a greater magnitude of relief from baseline during early to moderate follow up period, although this difference disappeared after 18 months. Liu and colleagues concluded that both ACDF and CDA provide meaningful relief of cervicogenic headaches but highlighted a potential for higher degree of relief after two level CDA [44]. One explanation for the disappearance of the difference between ACDF and CDA over time may be the eventual progression of abnormal kinematics of the cervical spine [6]. Most recently, Thind et al. completed an exhaustive 7 year post hoc analysis of 437 patients that underwent one-level or two-level ACDF or CDA for symptomatic cervical spondylosis [6]. One hundred and eighty-five patients were identified for the one-level group and 252 patients in the two-level group. Approximately 50% of patients in the one-level and two-level

groups reported NDI headache scores of 3 or greater at baseline. Results for both one level and two-level ACDF and CDA groups demonstrated statistically significant headache relief after 7 years of follow up. However, in contrast to findings by Liu et al. regarding two-level CDA, Thind et al. noticed a more profound improvement in headache scores in the CDA group as compared to ACDF patients at 7 year follow up. The authors concluded that relief from CGH is durable up to 7 years after both ACDF and CDA. To explain the observed superior long-term outcomes in the CDA group, Thind et al. emphasized the importance of the preservation of normal spinal kinematics resulting in a reduction of irritation at the UVR [6].

As demonstrated by the lack of consensus among authors, the optimal surgical option regarding ACDF or CDA remains complex and nuanced. However, reviewing the current literature reiterates the success of both anterior cervical approaches in the management of CGH, and supports the hypothesis of a ventral source for the pain generators (e.g. *dura*, disc, UVR zone). Ultimately, surgeon comfort and access to proper surgical equipment will dictate which approach is optimal.

6.3 Anterior cervical surgical technique

The anterior surgical corridor to the cervical spine has been a workhorse in the armamentarium of spine surgeons since the 1950's when first described by Robison, Smith, and Cloward [45, 46]. This approach allows for a minimally invasive technique to address ventral spinal pathology without the disruption of the posterior spinal tension band. In this section we will briefly review the critical steps in the anterior cervical approach for the decompression of the unco-vasculo-radicular junction in patients diagnosed with cervicogenic headaches.

After performing an appropriate surgical pause during which we administer antibiotics and steroids in non-diabetic patients, the patient is intubated, and proper vascular access is obtained. A standard supine position is used with the head slightly extended and firmly positioned in a foam ring. A small shoulder roll is inserted to allow for adequate extension and expansion of the surgical corridor. Care must be taken to avoid hyperextension or and rotation of the neck, especially if arthrodesis is planned. For access to the lower cervical levels, the shoulders may be taped down to allow for intraoperative visualization with fluoroscopy. External landmarks such as the hyoid bone (C3), thyroid bone (C4), or cricoid bone (C6) can be used to approximate the level of interest, however, we advocate for the use of fluoroscopy to ensure appropriate placement of the incision. We routinely approach the anterior cervical spine using a left sided approach, as there is some anecdotal evidence to suggest a lower risk of injury to the recurrent laryngeal nerve, however, either side is an acceptable choice [47–50]. If a redo operation is performed, care must be taken to approach from the same side as the prior surgery to avoid bilateral injury to the vagal nerve and vocal cord paralysis. The incision is placed in a transverse orientation extending from the midline to the medial border of the sternocleidomastoid muscle. Incorporating the incision within a skin crease results in the best cosmetic outcome. Our skin incision is typically 2–4 cm in length depending on the number of levels involved. Two to three mLs of Bupivacaine with 1:200,000 epinephrine is injected subcutaneously prior to skin incision. A scalpel is used to incise the dermis and a small self-retaining retractor is used to spread the soft tissue making the platysma muscle evident. Meticulous hemostasis is achieved at each tissue layer to avoid run down during surgery. Blunt dissection is used to spread the platysma, followed by monopolar cautery to cut through the muscle in a transverse orientation. Care must be taken to avoid injury to the vascular structures that run deep to the platysma. Aggressive subplatysmal dissection is used to allow

for mobilization of the investing superficial cervical fascia. At this time, the sternocleidomastoid (SCM) muscle is identified laterally, and the cervical strap muscles are identified medially. The carotid artery is palpated and identified early on and kept lateral to the plane of dissection. An avascular tissue plane is developed bluntly between the SCM and the cervical strap muscles. This dissection is carried through the pre-tracheal fascia and continued medially towards the pre-vertebral fascia and the ventral spine. The longus coli muscles and the intervertebral discs are identified at this time, and a clamp is placed on the suspected disc space. Intraoperative fluoroscopy is used to confirm the level of interest. With the use of hand-held Cloward retractors, the longus coli muscles are elevated laterally using a subperiosteal technique as to avoid injury to the sympathetic cervical plexus. Self-retaining retractors are inserted deep to the longus coli muscles to retract the esophagus medially and the carotid sheath laterally. Distraction pins may be used if the disc space is collapsed, but care must be taken to avoid over distraction and injury to the posterior spinal elements. Using the microscope, a complete discectomy is performed followed by posterior longitudinal ligament resection, and bilateral unco-foraminotomies.

For arthrodesis, many different interbody and plating systems are available that allow for similar rates of arthrodesis. Meticulous care must be taken to decorticate the end plates and remove any disc material to maximize the chance of successful arthrodesis. However, one must avoid overzealous disruption of the endplates as this would increase the risk of subsidence. After placement of the interbody and screws intraoperative fluoroscopy is utilized to confirm appropriate placement of the implants.

As with arthrodesis, disc arthroplasty can be achieved with a variety of different artificial disc systems. At our institution, we have used the Mobi-C Cervical Disc (Zimmer Biomet, Westminster, Colorado) with good results. The preservation of the endplates is extremely important for arthroplasty as subsidence can lead to reduced range of motion and inadvertent arthrodesis. Moreover, the positioning of the artificial disc is of utmost importance, and intraoperative fluoroscopy is utilized to ensure the disc is midline and recessed appropriately inside the disc space. After adequate placement of the artificial disc, we apply a small amount of bone wax to the ventral surface of the adjacent vertebral bodies to reduce the risk for heterotopic ossification.

Upon completion of instrumentation, hemostasis is achieved, and the platysma and the dermis are reapproximated.

7. Conclusion

Cervicogenic headaches are a debilitating pathology that can cause a significant burden on patient quality of life. Given the relatively recent recognition of cervicogenic headaches, there remains considerable controversy regarding the underlying pathogenesis and optimal treatment strategies. There is a clear need for further research aimed at identifying the underlying pain generators in cervicogenic headaches. Moreover, high quality clinical trials are necessary to discern between treatment options. Importantly, medical management should be exhausted for headache control and headaches alone should not be the reason for recommending surgery. The anterior cervical surgical approach is a minimally invasive technique that has demonstrated promising results in relieving symptoms related to cervicogenic headaches and should be considered in the appropriate patient population.

Acknowledgements

Figure 1 courtesy of Neurospine Journal.

Disclosures

The corresponding author receives royalties and is a consultant for Zimmer Biomet.

Abbreviations

ACDF	anterior cervical discectomy and fusion
CDA	cervical disc arthroplasty
CGH	cervicogenic headaches
CPH	chronic paroxysmal headaches
ICHD-3	International Headache Society’s Headache classification (ICHD-3)
MH	migraine headaches
SCM	sternocleidomastoid
SVN	sinuvertebral Nerves
TTH	tension type headaches
UVR	unco-vasculo-radicular (UVR)

Author details

Amir Goodarzi, Edwin Kulubya, Tejas Karnati and Kee Kim*
University of California Davis Department of Neurological Surgery,
Sacramento, USA

*Address all correspondence to: kdkim@ucdavis.edu

IntechOpen

© 2021 The Author(s). Licensee IntechOpen. This chapter is distributed under the terms of the Creative Commons Attribution License (<http://creativecommons.org/licenses/by/3.0>), which permits unrestricted use, distribution, and reproduction in any medium, provided the original work is properly cited. 

References

- [1] O. Sjaastad, C. Saunte, H. Hovdahl, H. Breivik, E. Grønbæk, "Cervicogenic" headache. An hypothesis, *Cephalalgia*. 3 (1983) 249-256. <https://doi.org/10.1046/j.1468-2982.1983.0304249.x>.
- [2] O. Sjaastad, Cervicogenic headache the controversial headache, *Clinical Neurology and Neurosurgery*. 94 (1992) 147-149. [https://doi.org/10.1016/0303-8467\(92\)90053-6](https://doi.org/10.1016/0303-8467(92)90053-6).
- [3] J. Olesen, Headache Classification Committee of the International Headache Society (IHS) The International Classification of Headache Disorders, 3rd edition, *Cephalalgia*. 38 (2018) 1-211. <https://doi.org/10.1177/0333102417738202>.
- [4] J. Riina, P.A. Anderson, L.T. Holly, K. Flint, K.E. Davis, K.D. Riew, The effect of an anterior cervical operation for cervical radiculopathy or myelopathy on associated headaches, *Journal of Bone and Joint Surgery - Series A*. 91 (2009) 1919-1923. <https://doi.org/10.2106/JBJS.H.00500>.
- [5] R.J. Schrot, J.S. Mathew, Y. Li, L. Beckett, H.W. Bae, K.D. Kim, Headache relief after anterior cervical discectomy: Post hoc analysis of a randomized investigational device exemption trial: Clinical article, *Journal of Neurosurgery: Spine*. 21 (2014) 217-222. <https://doi.org/10.3171/2014.4.SPINE13669>.
- [6] H. Thind, D. Ramanathan, J. Ebinu, D. Copenhaver, K.D. Kim, Headache relief is maintained 7 years after anterior cervical spine surgery: Post hoc analysis from a multicenter randomized clinical trial and cervicogenic headache hypothesis, *Neurospine*. 17 (2020) 365-373. <https://doi.org/10.14245/ns.2040004.002>.
- [7] L.C.G. Persson, J.Y. Carlsson, L. Anderberg, Headache in patients with cervical radiculopathy: A prospective study with selective nerve root blocks in 275 patients, *European Spine Journal*. 16 (2007) 953-959. <https://doi.org/10.1007/s00586-006-0268-8>.
- [8] S. Haldeman, S. Dagenais, Cervicogenic headaches: A critical review, *Spine Journal*. 1 (2001) 31-46. [https://doi.org/10.1016/S1529-9430\(01\)00024-9](https://doi.org/10.1016/S1529-9430(01)00024-9).
- [9] C.R. Hunter, F.H. Mayfield, Role of the upper cervical roots in the production of pain in the head, *The American Journal of Surgery*. 78 (1949) 743-751. [https://doi.org/10.1016/0002-9610\(49\)90316-5](https://doi.org/10.1016/0002-9610(49)90316-5).
- [10] N. Bogduk, M. Windsor, A. Inglis, The innervation of the cervical intervertebral discs, *Spine*. 13 (1988) 2-8. <https://doi.org/10.1097/00007632-198801000-00002>.
- [11] M.A. Edgar, S. Nundy, Innervation of the spinal dura mater, *BMJ Publishing Group*, 1966. <https://www.ncbi.nlm.nih.gov/pmc/articles/PMC496104/> (accessed October 5, 2020).
- [12] N. Bogduk, Cervicogenic headache: anatomic basis and pathophysiologic mechanisms., *Current Pain and Headache Reports*. 5 (2001) 382-386. <https://doi.org/10.1007/s11916-001-0029-7>.
- [13] F.W.L. Kerr, R.A. Olafson, Trigeminal and Cervical Volleys: Convergence on Single Units in the Spinal Gray at C-1 and C-2, *Archives of Neurology*. 5 (1961) 171-178. <https://doi.org/10.1001/archneur.1961.00450140053005>.
- [14] F.W.L. Kerr, Central relationships of trigeminal and cervical primary afferents in the spinal cord and medulla, *Brain Research*.

- 43 (1972) 561-572. [https://doi.org/10.1016/0006-8993\(72\)90408-8](https://doi.org/10.1016/0006-8993(72)90408-8).
- [15] M.E. Alix, D.K. Bates, A proposed etiology of cervicogenic headache: The neurophysiologic basis and anatomic relationship between the dura mater and the rectus posterior capitis minor muscle, *Journal of Manipulative and Physiological Therapeutics*. 22 (1999) 534-539. [https://doi.org/10.1016/S0161-4754\(99\)70006-0](https://doi.org/10.1016/S0161-4754(99)70006-0).
- [16] S. Price, D.T. Daly, *Neuroanatomy, Trigeminal Nucleus*, StatPearls Publishing, 2020. <http://www.ncbi.nlm.nih.gov/pubmed/30969645> (accessed October 12, 2020).
- [17] D. Purves, G.J. Augustine, D. Fitzpatrick, L.C. Katz, A.-S. LaMantia, J.O. McNamara, S.M. Williams, *Central Pain Pathways: The Spinothalamic Tract*, (2001). <https://www.ncbi.nlm.nih.gov/books/NBK10967/> (accessed October 12, 2020).
- [18] G. Gondo, T. Watanabe, J. Kawada, M. Tanaka, K. Yamamoto, S. Tanaka, S. Endo, A case of cervicogenic headache caused by C5 nerve root derived schwannoma: Case report, *Cephalalgia*. 37 (2017) 902-905. <https://doi.org/10.1177/0333102416658713>.
- [19] R. -P Michler, G. Bovim, O. Sjaastad, Disorders in the Lower Cervical Spine. A Cause of Unilateral Headache? A Case Report, *Headache: The Journal of Head and Face Pain*. 31 (1991) 550-551. <https://doi.org/10.1111/j.1526-4610.1991.hed3108550.x>.
- [20] K. Shimohata, K. Hasegawa, O. Onodera, M. Nishizawa, T. Shimohata, The Clinical Features, Risk Factors, and Surgical Treatment of Cervicogenic Headache in Patients With Cervical Spine Disorders Requiring Surgery, *Headache*. 57 (2017) 1109-1117. <https://doi.org/10.1111/head.13123>.
- [21] B.S. Mitchell, B.K. Humphreys, E. O'Sullivan, Attachments of the ligamentum nuchae to cervical posterior spinal dura and the lateral part of the occipital bone., *Journal of Manipulative and Physiological Therapeutics*. 21 (1998) 145-8. <http://www.ncbi.nlm.nih.gov/pubmed/9567232>.
- [22] K. Kim, Kee; Ramanathan, Dinesh; Provoost, Cervicogenic Headache - Review of Pathogenesis and Management, *Journal of Neurosurgery Imaging and Techniques*. 3 (2018) 193-196.
- [23] S. Edgar, MA; Nundy, Innervation of the spinal dura mater, *J Neurol Neurosurg Psychiatry*. (1966) 530-534.
- [24] B.J. Freund, M. Schwartz, Treatment of whiplash associated with neck pain with botulinum toxin-A: A pilot study, *Journal of Rheumatology*. 27 (2000) 481-484.
- [25] M.E. Alix, D.K. Bates, A proposed etiology of cervicogenic headache: The neurophysiologic basis and anatomic relationship between the dura mater and the rectus posterior capitis minor muscle, *Journal of Manipulative and Physiological Therapeutics*. 22 (1999) 534-539. [https://doi.org/10.1016/S0161-4754\(99\)70006-0](https://doi.org/10.1016/S0161-4754(99)70006-0).
- [26] B.S. Mitchell, B.K. Humphreys, E. O'Sullivan, Attachments of the ligamentum nuchae to cervical posterior spinal dura and the lateral part of the occipital bone., *Journal of Manipulative and Physiological Therapeutics*. 21 (1998) 145-148.
- [27] N. Bogduk, J. Govind, Cervicogenic headache: an assessment of the evidence on clinical diagnosis, invasive tests, and treatment, *The Lancet Neurology*. 8 (2009) 959-968. [https://doi.org/10.1016/S1474-4422\(09\)70209-1](https://doi.org/10.1016/S1474-4422(09)70209-1).
- [28] O. Sjaastad, G. Bovim, L.J. Stovner, Laterality of pain and other migraine criteria in common migraine. A comparison with cervicogenic headache, *Functional Neurology*. 7 (1992) 289-294.

- [29] O. Sjaastad, T. Fredriksen, J.A. Pareja, A. Stolt-Nielsen, M. Vincent, Coexistence of cervicogenic headache and migraine without aura (?), *Functional Neurology*. 14 (1999) 209-218.
- [30] O. Sjaastad, G. Bovim, Cervicogenic headache. The differentiation from common migraine. An overview, *Functional Neurology*. 6 (1991) 93-100.
- [31] N. Merskey, H; Bogduk, Classification of Chronic Pain, Classification of Chronic Pain. IASP Press, Seattle. (1994).
- [32] T.A. Fredriksen, R. Fougner, A. Tangerud, O. Sjaastad, Cervicogenic Headache. Radiological Investigations Concerning Head/Neck, *Cephalalgia*. 9 (1989) 139-146. <https://doi.org/10.1046/j.1468-2982.1989.0902139.x>.
- [33] N. Bogduk, The clinical anatomy of the cervical dorsal rami, *Spine*. 7 (1982) 319-330. <https://doi.org/10.1097/00007632-198207000-00001>.
- [34] E. Wang, D. Wang, Treatment of Cervicogenic Headache with Cervical Epidural Steroid Injection, *Current Pain and Headache Reports*. 18 (2014). <https://doi.org/10.1007/s11916-014-0442-3>.
- [35] J. Riina, P.A. Anderson, L.T. Holly, K. Flint, K.E. Davis, K.D. Riew, The Effect of an Anterior Cervical Operation for Cervical Radiculopathy or Myelopathy on Associated Headaches, *The Journal of Bone and Joint Surgery-American Volume*. 91 (2009) 1919-1923. <https://doi.org/10.2106/JBJS.H.00500>.
- [36] R.J. Schrot, J.S. Mathew, Y. Li, L. Beckett, H.W. Bae, K.D. Kim, Headache relief after anterior cervical discectomy: Post hoc analysis of a randomized investigational device exemption trial: Clinical article, *Journal of Neurosurgery: Spine*. 21 (2014) 217-222. <https://doi.org/10.3171/2014.4.SPINE13669>.
- [37] J. Jansen, Surgical treatment of non-responsive cervicogenic headache, *Clin Exp Rheumatol*. 18(2 Suppl (n.d.) S67-70.
- [38] J. Jansen, Laminoplasty--a possible treatment for cervicogenic headache? Some ideas on the trigger mechanism of CeH, *Funct Neurol*. 14(3) (n.d.) 163-5.
- [39] J. Jansen, Surgical treatment of cervicogenic headache, *Cephalalgia*. 28 (2008) 41-44. <https://doi.org/10.1111/j.1468-2982.2008.01620.x>.
- [40] H. Liu, A. Ploumis, S. Wang, C. Li, H. Li, Treatment of Cervicogenic Headache Concurrent with Cervical Stenosis by Anterior Cervical Decompression and Fusion, *Clinical Spine Surgery*. 30 (2017) E1093–E1097. <https://doi.org/10.1097/BSD.0000000000000291>.
- [41] H.C. Diener, M. Kaminski, G. Stappert, D. Stolke, B. Schoch, Lower cervical disc prolapse may cause cervicogenic headache: Prospective study in patients undergoing surgery, *Cephalalgia*. 27 (2007) 1050-1054. <https://doi.org/10.1111/j.1468-2982.2007.01385.x>.
- [42] J. Jansen, E. Markakis, B. Rama, J.J. Hildebrandt CEPHALALGIA Jansen, H.J. Hemicranial, J. Jansen, E. Markakis, B. Rama, Hemicranial attacks or permanent hemicrania-a sequel of upper cervical root compression, n.d.
- [43] J. Schofferman, K. Garges, N. Goldthwaite, M. Koestler, E. Libby, Upper cervical anterior discectomy and fusion improves discogenic cervical headaches, *Spine*. 27 (2002) 2240-2244. <https://doi.org/10.1097/00007632-200210150-00011>.
- [44] J.J. Liu, G. Cadena, R.R. Panchal, R.J. Schrot, K.D. Kim, Relief of

Cervicogenic Headaches after Single-Level and Multilevel Anterior Cervical Discectomy: A 5-Year Post Hoc Analysis, *Global Spine Journal*. 6 (2016) 563-570. <https://doi.org/10.1055/s-0035-1570086>.

[45] R.B. Cloward, The anterior approach for removal of ruptured cervical disks., *Journal of Neurosurgery*. 15 (1958) 602-617. <https://doi.org/10.3171/jns.1958.15.6.0602>.

[46] R.A. Robinson, G.W. Smith, Anterolateral cervical disc removal and interbody fusion for cervical disc syndrome, *SAS Journal*. 4 (2010) 34-35. <https://doi.org/10.1016/j.esas.2010.01.003>.

[47] M. Miscusi, A. Bellitti, S. Peschillo, F.M. Polli, P. Missori, R. Delfini, Does recurrent laryngeal nerve anatomy condition the choice of the side for approaching the anterior cervical spine?, *Journal of Neurosurgical Sciences*. 51 (2007) 61-4. <http://www.ncbi.nlm.nih.gov/pubmed/17571036>.

[48] A.M. Thomas, D.K. Fahim, J.M. Gemechu, Anatomical Variations of the Recurrent Laryngeal Nerve and Implications for Injury Prevention during Surgical Procedures of the Neck., *Diagnostics (Basel, Switzerland)*. 10 (2020). <https://doi.org/10.3390/diagnostics10090670>.

[49] A. Arantes, S. Gusmão, F. Rubinstein, R. Oliveira, Microsurgical anatomy of the recurrent laryngeal nerve: Applications on the anterior approach to the cervical spine, *Arquivos de Neuro-Psiquiatria*. 62 (2004) 707-710. <https://doi.org/10.1590/s0004-282x2004000400026>.

[50] N.A. Ebraheim, J. Lu, M. Skie, B.E. Heck, R.A. Yeasting, Vulnerability of the recurrent laryngeal nerve in the anterior approach to the lower cervical spine, in: *Spine, Spine (Phila Pa 1976)*, 1997: pp. 2664-2667. <https://doi.org/10.1097/00007632-199711150-00015>.