

We are IntechOpen, the world's leading publisher of Open Access books Built by scientists, for scientists

6,900

Open access books available

185,000

International authors and editors

200M

Downloads

Our authors are among the

154

Countries delivered to

TOP 1%

most cited scientists

12.2%

Contributors from top 500 universities



WEB OF SCIENCE™

Selection of our books indexed in the Book Citation Index
in Web of Science™ Core Collection (BKCI)

Interested in publishing with us?
Contact book.department@intechopen.com

Numbers displayed above are based on latest data collected.
For more information visit www.intechopen.com



Cataract Surgery Combined with Trabecular MIGS (Minimally Invasive Glaucoma Surgery)

*Marina Aguilar González, Jorge Vila Arteaga
and Jose Marí Cotino*

Abstract

Cataract surgery decreases significantly and with maintained effect intraocular pressure (IOP) in both normal eyes as in eyes with glaucoma. In patients with cataracts and glaucoma, it can be performed, isolated or in combination with other techniques, such as the following: minimally invasive glaucoma surgery (MIGS) in patients with mild/moderate glaucoma that do not require a high tensional decrease; and conventional glaucoma surgery techniques in patients with advanced glaucoma. Although lower than with conventional techniques, MIGS trabecular surgery has a good IOP lowering effect and provides some of the following advantages: a more physiological approach; little traumatic; without bleb; and it does not limit other techniques in the future. Different techniques that combined or not with cataract surgery facilitate the exit of aqueous humor through the trabecular meshwork (TM) have been described. Our aim in this chapter is to review the newest of them, such as the following: iStent; ELT (Excimer Laser Trabeculostomy); kahook; ABiC; and OMNI.

Keywords: cataract surgery, glaucoma surgery, MIGS, iStent, ELT, Kahook, ABiC, OMNI

1. Introduction

It has been shown that after phacoemulsification in eyes with and without glaucoma, there is a decrease in IOP in relation to the preoperative one, with a decrease of up to 8.5 mmHg, 34% of the preoperative IOP, in eyes with glaucoma and IOP between 29 and 23 mmHg and 3.4 mmHg; and 18% of the IOP in eyes with preoperative IOP lower than 20 mmHg [1]. Moreover, the decrease in IOP is maintained up to 10 years follow-up without influence of the age of the patients [1]. Therefore, we can affirm that the cataract extraction, regardless of the surgical technique used, provides a reduction in preoperative IOP, maintained during follow-up, which is related to preoperative, both in normal eyes and in ocular hypertensive with or without treatment, and even in eyes with glaucoma and hypotensive medical treatment. Therefore, cataract surgery can be considered as an antiglaucomatous surgical technique, which could be the indicated treatment in hyperopic eyes and adequate glaucoma control with medical treatment and in glaucomatous patients, with correct medical control, if we do not pursue a large decrease in IOP [2].

However, when a big IOP decrease is required or in the case of advanced glaucomas, we will use the classic surgical techniques for the treatment of glaucoma: trabeculectomy

or nonpenetrating glaucoma surgery, as they present the highest hypotensive efficacy (but also a higher rate of complications than other less invasive techniques).

As an intermediate step, in mild or moderate glaucomas that do not require a high tensional decrease but in which an additional decrease in IOP than that obtained with isolated cataract surgery is needed, we can associate MIGS techniques with cataract surgery, since they offer good tensional responses (although smaller than those obtained with classical glaucoma surgeries) with a lower complication rate (both in number and severity) than with classical surgical techniques. All MIGS have in common a better postoperative recovery compared to other more invasive filtering procedures, the absence of complications associated with the bleb, the respect of the conjunctiva that will allow future techniques if required and the possibility of being performed easily in combination with cataract surgery.

In the following chapter, we are going to talk about the role of the trabecular approach and the MIGS techniques that use this approach associated with cataract surgery.

2. Anatomy of the trabecular meshwork

As we know, there are three ways of draining the aqueous humor [3]:

1. The conjunctival pathway.
2. The trabecular pathway.
3. The suprachoroidal pathway.

All three routes can be surgically approached both ab interno and ab externo.

The trabecular pathway is the physiological drainage pathway and it is where most of the keys of the pathophysiology of many types of glaucoma lie.

The trabecular pathway allows the aqueous humor to pass from the anterior chamber to the systemic circulation and we should see it like a dynamic mechanism instead of like a static mechanism.

1. The first structure in contact with the aqueous humor is the trabecular meshwork (TM). In the TM we differentiate three zones [3]:
 - a. The uveal TM (**Figure 1**): it is located adjacent to the anterior chamber and is arranged in bands that extend from the root of the iris and the ciliary body to the peripheral cornea.
 - b. The corneo-scleral TM (**Figure 1**): it consists of trabecular sheets that extend from the scleral spur to the lateral wall of the scleral groove.
 - c. The juxtacanalicular TM (**Figure 1**): it forms the inner wall of the canal of Schlemm and the aqueous humor moves through and between the endothelial cells that line the inner wall of the canal of Schlemm. As we advance in these areas, the difficulty of the aqueous humor outflow increases, so it is believed that the juxtacanalicular TM is the main site of resistance to the outflow of the aqueous humor.

The TM is a pressure sensitive drainage site and acts as a one-way valve, regardless of the energy. Furthermore, its cells are phagocytic and can exhibit this function in the presence of inflammation and after laser trabeculoplasty [3].

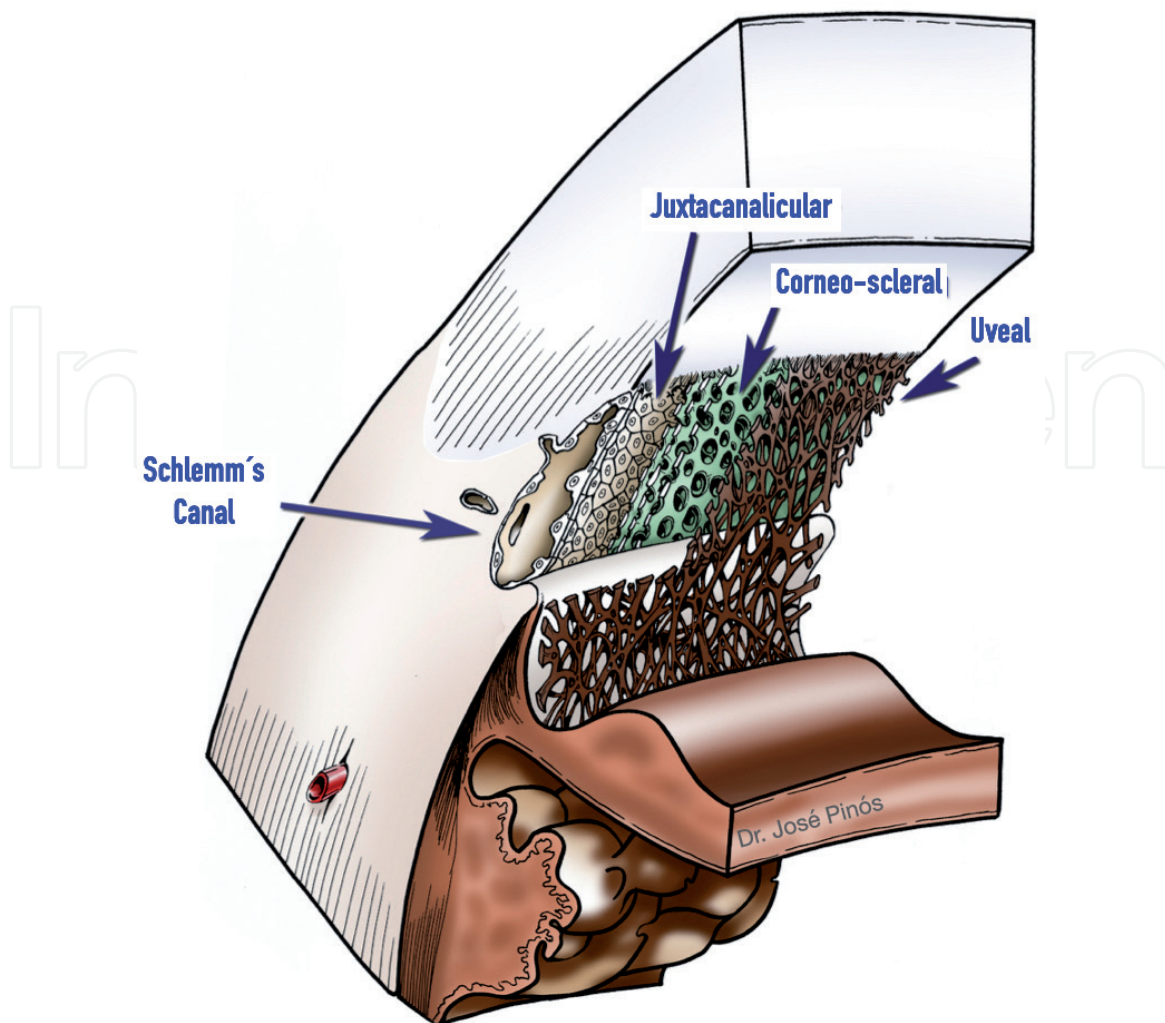


Figure 1.
 Trabecular meshwork (uveal, corneo-scleral and juxtacanalicular); Schlemm's canal.

We should not understand this system as a succession of static networks. We should understand it as a tissue embedded in an extracellular matrix in which there is a continuous intra and extracellular filtration towards the Schlemm's canal (SC), in which there is a progressive deterioration in the case of eyes with glaucoma. Thus, in eyes with glaucoma, there are some alterations that will produce rigidity of this tissue diffculting the drainage of the aqueous humor.

2. The SC (**Figure 1**) is a single canal that surrounds the anterior chamber 360° and has a diameter of 200–300 μm [3]. SC is lined with an endothelial layer that rests on a discontinuous basement membrane [3]. It is not a homogeneous or rigid conduit. Microscopically it is a complex structure, as it is crossed by tubules and has partitions and duplications and has some structures such as cylindrical anchoring structures that communicate the trabecular face with the mouth of the collecting tubules that perform a valve-like function [3]. The outer wall of the Schlemm's canal is made up of single-layered cells of endothelium without pores [3]. With OCT we can also appreciate how the canal and the trabecular meshwork modifies with changes in IOP [4].
3. Finally we have the complex formed by the collectors, venous plexuses and the aqueous veins [3]. It is a complex system of vessels with abundant arterio-venous anastomoses, in which the transmission of the heartbeat is essential, and whose function is to carry the aqueous humor from SC to the systemic

circulation (it connects SC with the episcleral veins, that drain into the anterior and superior ciliary ophthalmic veins, which drain into the cavernous sinus) [3]. The organization of the collectors is not homogeneous, since they are mainly found in the lower nasal area.

In summary:

- The trabecular pathway is a dynamic tissue that has a pumping system towards the systemic circulation and is influenced by IOP changes (especially blinking, ocular pulse, eye movements).
- In glaucoma there are some ultrastructural alterations that will produce a loss of elasticity of the trabecular pathway and therefore a decrease in aqueous humor filtration.
- These changes are more important in the juxtacanalicular portion of the TM.
- It is logical that the trabecular pathway is more or less affected depending on the type of glaucoma. A mild, incipient glaucoma, with a few years of evolution, will have less structural alterations than an advanced glaucoma, with more years of evolution and that requires 2–3 drugs for its control.
- In the same way, the different anatomical alterations will produce a greater or lesser alteration of the TM. For example, a glaucoma that does not present any alteration in gonioscopy is different than a pseudoexfoliative glaucoma, in which the pigment enters in the TM and the rest of the angular structures, or a pigment dispersion glaucoma, in which the pigment permeates very intensively the entire TM.

3. Types of migs techniques in the trabecular pathway

All the surgical routes of the trabecular route seek the same aim (to facilitate the exit of aqueous humor from the anterior chamber to the systemic circulation) but they achieve it in different ways.

- a. Some techniques perform microperforations, either with an implant (iStent) or with a laser (ELT).
- b. Others perform a rupture of the internal wall of the shlemm canal and the trabecular meshwork (trabectome, Kahook, OMNI).
- c. Others perform a viscodilation of the SC, leading to the distension of the Schlemm canal, of the trabecular meshwork and of the collecting canals (ABiC, OMNI).

We can also differentiate the surgeries based on the area that they treat:

- a. Some provide a punctual treatment (iStent).
- b. Others treat a sector, normally 90° (ELT, trabectome, Kahook).
- c. Others treat the entire circumference (360°) of the SC (OMNI, ABiC, GATT).

Some of these techniques are detailed below.

3.1 iStent

3.1.1 Definition

It is an ab-interno MIGS technique in which two implants are applied in a specific way on the TM [5]. iStent is the smallest device ever implanted in humans [5]. It is a titanium implant surrounded by a layer of heparin, which allows better passage of the aqueous humor through the lumen of the iStent [5]. It has a long portion that enters the Schlemm's canal and a short portion that crosses the TM and connects with the anterior chamber [5]. The distal portion is beveled and tapered to facilitate penetration through the TM tissue and on the external surface it has three ridges that prevent its expulsion once inserted [5]. The Glaukos® GTS-400 trabecular implant has an applicator and a button to release the device and comes preloaded with two iStent, allowing the implantation of both iStent with a single applicator [5].

3.1.2 Indications and contraindications

This implant is ideal for surgery combined with phacoemulsification, since the angle is easier to visualize in pseudophakic eyes [5]. Thus, iStent is indicated in combined use with cataract surgery for reduction of IOP in adult patients with mild-moderate open angle glaucoma (OAG) under treatment with topical hypotensive drugs and cataract in surgical stage [5].

It is contraindicated in patients with both primary and secondary angle closure glaucoma, including neovascular glaucoma, as well as in patients with retrobulbar tumors, thyroid orbitopathy, Sturge-Weber Syndrome or any other situation that may cause elevated episcleral venous pressure [5].

A gonioscopy should be performed prior to surgery to exclude peripheral anterior synechiae, rubeosis or any other abnormality of the chamber angle that may hinder a correct visualization of the angle that could produce a possible incorrect placement of the iStent [5].

3.1.3 Surgical technique

For a safe surgery, it is essential to obtain a good visualization of the chamber angle by turning the patient's head 45° towards the opposite side of the operated eye and tilting the head of the surgical microscope 30° [5]. Intracameral acetylcholine injection is first performed to constrict the pupil and the anterior chamber (AC) is filled with cohesive viscoelastic [5]. The main incision made for phacoemulsification is used to introduce the implant through the AC into the TM, while viewing the angle with gonioscopy and, once the insertion site is located, the tip of the implant (bevelled) is inserted into the TM, at an angle of about 15°, which facilitates penetration into the tissue, with the iStent tip pointing towards the patient's feet [4]. When it is verified that the TM covers the entire implant, it is released with the button of the applicator [5]. A small backflow of blood from the SC is frequent and reflects the proper position of the iStent [5]. Finally, the applicator is removed, the viscoelastic is washed and the corneal incision is sealed by hydrating the stroma [4]. In **Figure 2(A)** we can see two iStent correctly implanted in the TM.

3.1.4 Security

Trabecular stent implantation is a safe procedure with limited complications and no severe adverse events [5]. The most common of complications is implant obstruction and malposition [5]. The appearance of minimal hyphema during surgery is a sign of correct implant placement [5].

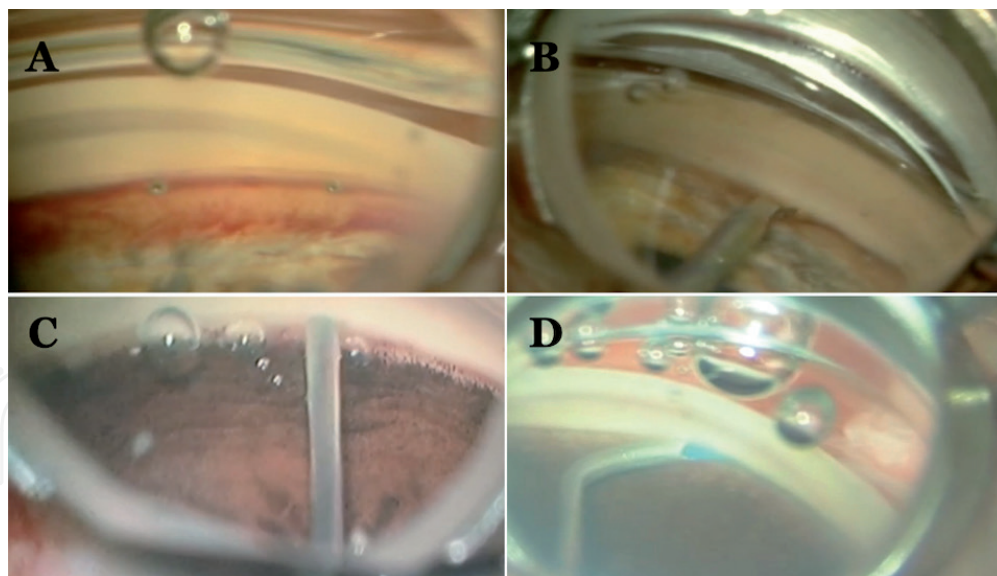


Figure 2.

Surgical procedures. (A) Two iStent correctly implanted in the TM. (B) Kahook makes a cut along the TM in a clockwise direction, followed by another cut in an anti-clockwise direction. (C) During the application of the laser in ELT, the whitening of the TM and the appearance of one or more bubbles are observed. (D) OMNI introduces the blue microcatheter in the SC, first for 180° of the SC and then the process is repeated for the second 180°.

3.2 ELT

3.2.1 Definition

ELT is an ab-interno MIGS technique in which microperforations or trabeculotomies are performed in the TM in order to facilitate the drainage of aqueous humor towards the SC using excimer laser impacts in a sectorial way (90°) of the TM [5]. Excimer laser photocoagulation allows the ablation of the juxtacanalicular wall of the TM and the internal wall of the Schlemm canal (avoiding injury to the external wall of the Schlemm canal containing fibroblasts, whose preservation is important for the drainage of the aqueous humor) with local and adjacent temperature control avoiding thermal damage to surrounding tissues [5].

3.2.2 Indications and contraindications

The effectiveness of ELT is greater when performed in combination with cataract surgery [6]. Therefore, it is indicated alone or in combination with cataract surgery in most patients with OAG with hypotensive treatment and cataract in surgical stage to reduce IOP and medication [5].

It is not indicated in glaucomas with increased episcleral venous pressure or in those requiring very low target IOPs below episcleral venous pressure [5].

3.2.3 Surgical technique

The AC is filled with viscoelastic using the corneal incision made for cataract surgery and the probe is positioned in contact with the TM, which can be visualized by gonioscopy (**Figure 2(C)**) or by endoscopy, depending on the generation of the laser used [5]. Between 8 and 10 laser microperforations are made per 90° sector of the TM [5]. The parameters used by the laser are: 200 µm spot, 1.2 mJ pulse energy, 80 ns duration [5]. During the application of the laser, the whitening of the TM and the appearance of one or more bubbles are observed.

(**Figure 2(C)**), sometimes associated with a slight reflux of blood that confirms the opening of the SC [5]. Finally, the probe is removed, the viscoelastic is washed, and the corneal incision is sealed by hydrating the stroma [5].

3.2.4 Security

This is a simple technique with a low incidence of complications. The main complications include hemorrhage in the immediate postoperative period and the fact that, due to the small size of the perforations, they are more easily obstructed than larger openings obtained with other procedures [5].

ELT can be performed on eyes that have previously undergone filtering surgery [5].

Its application in only 90° per session allows retreatment in the 3 remaining sectors in future interventions [5].

3.3 Kahook

3.3.1 Definition

It is a sectoral (90°) ab-interno MIGS technique in which the TM and the internal wall of the canal are bundled (similar to the procedure performed with the trabectome) with a device that is inserted into the TM and consists of a ramp in the distal end that, as we advance in the cut, raises the TM tissue and directs it towards 2 blades at the ends of the ramp that allow the cutting and extraction of this tissue [5].

3.3.2 Indications and contraindications

Thanks to its approach, it can be easily combined with cataract surgery and the combination of both surgeries increases hypotensive efficacy [7, 8]. Therefore, it is indicated in different types of OAG (primary, secondary to pseudoexfoliation and pigment dispersion, corticosteroid and uveitic), with mild or moderate glaucoma damage in a stage prior to conventional surgery, combined with cataract surgery in patients with cataract in the surgical stage in whom a decrease in IOP and/or a reduction in topical hypotensive medication is desired [5].

It should not be used in patients with advanced glaucoma or with a target IOP lower than episcleral venous pressure [5].

3.3.3 Surgical technique

The patient's head should be turned to the opposite side of the eye to be treated [5]. The corneal incision of cataract surgery is used to inject cohesive viscoelastic and introduce the kahook, which advances through the anterior chamber towards the nasal angle sector, which is visualized by gonioscopy [5]. The tip of the kahook is inserted through the TM into SC, and a cut is made along the TM in a clockwise direction, followed by another cut in an anti-clockwise direction, using the insertion site as a point of attachment reference (**Figure 2(B)**) [5]. The reflux of blood confirms the opening of the SC [5]. Finally, the device is removed, the viscoelastic is washed, and the corneal incision is sealed by hydrating the stroma [5].

3.3.4 Security

The complication rate is low and comparable to that of Trabectome™, highlighting the bleeding in the anterior chamber [9].

3.4 ABiC

3.4.1 Definition

Ab-interno canaloplasty (ABiC) is an ab-interno MIGS that viscodilate de TM, SC and the collector channels 360° inserting a microcatheter [10].

3.4.2 Indications and contraindications

ABiC is effective at reducing IOP and medication use in eyes with uncontrolled primary open-angle glaucoma (POAG) with or without cataract surgery [9]. It is useful in combination with cataract surgery as incisions resemble those of a typical cataract extraction and the IOP lowering effect of both procedures is enhanced [10]. Moreover, the addition of ABiC to phacoemulsification could be considered astigmatically neutral [10].

As in the resto of MIGS, the episcleral venous-resistant floor limits the IOP-lowering effect, so ABiC seems to be indicated such as a minimal invasive technique that does not affect future conjunctival bleb surgeries in patients with or without cataracts and POAG that need a modest IOP-lowering effect in order to reduce IOP or medication [10].

3.4.3 Surgical technique

After cataract surgery, the side port corneal incision is used in order to introduce viscoelastic and the microcatheter towards the nasal angle [10]. A side port incision for the iTrack™ microcatheter is created approximately 90° away from de nasal drainage angle, wich is inserted into the AC with te catheter tip guided towards the nasal angle [10]. A 25 G needle or a Cystotome® is used to perform a micro-goniotomy in the nasal TM under visualization using a gonioscope [9]. The microcatheter is held by a micro-surgical forceps and the SC is intubated inserting the catheter through the goniotomy until complete the circumferential intubation of SC 360° [10]. After that, the catheter is slowly withdrawn while infusing viscoelastic every clock hour [9]. Finally, the catheter is removed, the viscoelastic is washed, and the corneal incision is sealed by hydrating the stroma [10].

3.4.4 Security

ABiC shows no serious adverse events and less complications compared to more invasive conventional techniques; adverse events are limited to intraoperative bleeding at the goniotomy site and postoperative microhyphema [10].

3.5 OMNI

3.5.1 Definition

OMNI™ Surgical System is an ab-interno MIGS that combines two functions into one device: microcatherization and vasodilation in up to 360° of the SC (open distal outflow pathway) and cutting of the TM (controlled and Customizable trabeculotomy that removes the resistance of the TM) using a single fully integrated handheld system [11]. The system has got a luer fitting that allows for efficient priming of the device with viscoelastic, a priming lock, a reservoir where microcatheter is retracted, the gears whose movilization with the finger facilitate

microcatheter deployment and retraction, a cannula with a beveled tip that allows for precise access to target tissues, viscoelastic fluid and a blue microcatheter.

3.5.2 Indications and contraindications

As other MIGS techniques, OMNI can be used isolated or easily in conjunction with cataract surgery, in mild or moderated POAG that do not require a big IOP-lowering effect, with a minimal invasive approach and avoiding bleb complications and without conditioning future conjunctival bleb surgeries [11].

3.5.3 Surgical technique

The head of the patient and the microscope are tilted 30–40° and OMNI is introduced using the temporal clear corneal incision of the cataract surgery towards the nasal angle [11]. A small (<1 mm) goniotomy is created with the cannula tip in order to introduce the microcatheter for 180° of the SC under gonioscopic visualization (**Figure 2(D)**) [11]. Viscoelastic is delivered for viscodilation while microcatheter is retracted [11]. Microcatheter is again advanced and withdrawn with a 90° traction causing the unroof the SC (trabeculotomy) [11]. The process is repeated for the second 180° [10]. This technique allows varying the intensity of the treatment: for example, we can perform a 360° viscodilation and a 180° trabeculotomy.

3.5.4 Security

Adverse events are generally mild, nonserious and transient and include anterior chamber inflammation, posterior capsular opacification, IOP > 10 mmHg above baseline more than 30 days postoperatively, cystoid macular edema, corneal edema and hyphema [11].

4. Scientific evidence

Some techniques perform a more aggressive treatment than others. It is logical to think that the less aggressive techniques will be used in eyes with glaucoma where the involvement of the TM is smaller, and that, on the contrary, the more aggressive techniques, such as the trabeculotomy with viscodilation, will be used in cases where the involvement of the TM is much more intense.

If we review the literature in order to compare the different surgical techniques [12–21], we see that, except in some surgical techniques, in the most of the techniques, most of the studies present biases: they are not randomized, they are not prospective, they are simple series, they do not have washout, they use personal criteria, they do not record complications ... therefore, we can affirm that the scientific evidence for MIGS surgery in comparison with other techniques is very limited, although it has been demonstrated a decrease in IOP, a decrease in the number of drugs and a decrease in complications.

If we focus on surgical success, understanding it such as a IOP reduction greater than 20%, most techniques reach a rate success of 60–80% (**Table 1**). Evidence A and B can only be found with the iStent, the Hydrus and the trabectome, while in OMNI and Kahook the grade of recommendation is C (**Table 1**).

If we focus on the IOP that these surgical techniques achieve, we see that in the most of the cases the IOP reached is between 15 and 17 mmHg (**Table 2**), a limitation that is given by the episcleral venous pressure.

iStent + cataract	66% (12 M)	
iStent + cataract	45% (24 M)	
iStent inject + cataract	76% (12 M)	A
iStent inject	88% (12 M)	
Hydrus + cataract	88% (12 M)	A-B
Hydrus + cataract	80% (24 M)	
Trabectome	61% (12 M)	B
Trabectome + cataract	85% (24 M)	
ABiC	82% (12 M)	C
ABiC + cataract	88% (12 M)	
Trab 360	87% (12 M)	C
OMNI	68% (12 M)	
OMNI + cataract	87% (12 M)	
Kahook + cataract	57% (12 M)	C
Kahook + cataract	69% (35 M)	
ELT	52% (24 M)	C
ELT + cataract	91% (12 M)	

JM Navarro. MIGS trabeculares. Evidencia científica. SEO 2019.

Table 1.
Surgical success achieved with different MIGS techniques.

Trabectome	16 mmHg	
Kahook	15 mmHg	16 mmHg
iStent Inject	17 mmHg	
Hydrus	17 mmHg	
ABiC	15 mmHg	
OMNI	16 mmHg	
ELT	16 mmHg	

JM Navarro. MIGS trabeculares. Evidencia científica. SEO 2019.

Table 2.
IOP achieved with different MIGS techniques.

5. Conclusion

Taking all together, we can conclude with the following question: what can we expect from trabecular MIGS?

- MIGS are surgeries with a short learning technique, little aggressive and with a fast execution.
- They have few and little severe complications.
- They do not influence the possibility of performing surgeries with conjunctival bleb in the future if required.
- If we focus on the results, we will have a decrease greater than 20% in almost two thirds of surgeries, with a decrease of one or two drugs.

- However, the target pressure they achieve is approximately 16 mmHg. This means that they can be useful in eyes with mild or moderate glaucoma that do not require a big IOP decrease, but that in eyes with advanced glaucoma, where we look forward an IOP below 15 mmHg, trabecular MIGS techniques are not the most appropriate.

IntechOpen


IntechOpen

Author details

Marina Aguilar González*, Jorge Vila Arteaga and Jose Marí Cotino
Hospital Universitario y Politécnico la Fe, Calle Fernando Abril Martorell,
106, 16026, Valencia, Spain

*Address all correspondence to: aguilarmarina.oft@gmail.com

IntechOpen

© 2020 The Author(s). Licensee IntechOpen. This chapter is distributed under the terms of the Creative Commons Attribution License (<http://creativecommons.org/licenses/by/3.0>), which permits unrestricted use, distribution, and reproduction in any medium, provided the original work is properly cited. 

References

- [1] Poley BJ, Lindstrom RL, Samuelson TW, Schulze R Jr. Intraocular pressure reduction after phacoemulsification with intraocular lens implantation in glaucomatous and nonglaucomatous eyes: evaluation of a causal relationship between the natural lens and open-angle glaucoma. *Journal of Cataract and Refractive Surgery*. 2009;**35**:1946-1955
- [2] Mansberger SL. A need for glaucoma surgery (with o without cataract). American Academy of Ophthalmology: The case for cataract surgery alone. Subspecialty day Glaucoma; 2012
- [3] Christopher A Girkin MD, Chair AMB, MD JGC, MBBS PD, Giacony JAA, MD FAM, et al. Section 10: Glaucoma. In: American Academy of Ophthalmology (AAO). 2018
- [4] Gillmann K, Bravetti GE, Mermoud A, Mansouri K. A Prospective Analysis of iStent Inject Microstent Positioning: Schlemm Canal Dilatation and Intraocular Pressure Correlations. *Journal of Glaucoma*. 2019 Jul;**28**(7):613-621
- [5] Cosme Lvin Dapena, Pablo Alcocer Yuste. Cirugía microincisional del glaucoma. N°1 edición. Sociedad Española de Oftalmología (SEO). 2016.
- [6] Francis BA, Singh K, Lin SC, Hodapp E, Jampel HD, Samples JR, et al. Novel glaucoma procedures: a report by the American Academy of Ophthalmology. *Ophthalmology*. 2011;**118**(7):1466-1480
- [7] Francis BA. Trabectome combined with phacoemulsification versus phacoemulsification alone: a prospective, nonrandomized, controlled trial. *Clinical & Surgical Ophthalmology*. 2010;**28**:10
- [8] Francis BA, Winarko S. Combined Trabectome and cataract surgery versus combined trabeculectomy and cataract surgery in open-angle glaucoma. *Clinical & Surgical Ophthalmology*. 2011;**29**:2/3
- [9] Nakasato H, Uemoto R, Isozaki M, Meguro A, Kawagoe T, Mizuki N. Trabeculotomy ab interno with internal limiting membrane forceps for open-angle glaucoma. *Graefe's Archive for Clinical and Experimental Ophthalmology*. 2014;**252**(6):977-982
- [10] Gallardo MJ, Supnet RA, Ahmed IIK. Viscodilation of Schlemm's canal for the reduction of IOP via an ab-interno approach. *Clinical Ophthalmology*. 2018;**23**(12):2149-2155
- [11] Vold SD, Williamson BK, Hirsch L, Aminlari AE, Cho AS, Nelson C, Dickerson JE Jr. Canaloplasty and Trabeculotomy with the OMNI System in Pseudophakic Patients with Open-Angle Glaucoma: The ROMEO Study. *Ophthalmol Glaucoma*. 2020;**S2589-4196**(20)30264-7.
- [12] Samuelson TW, Sarkisian SR Jr, Lubeck DM, Stiles MC, Duh YJ, Romo EA, Giamporcaro JE, Hornbeak DM, Katz LJ; iStent inject Study Group. Prospective, Randomized, Controlled Pivotal Trial of an Ab Interno Implanted Trabecular Micro-Bypass in Primary Open-Angle Glaucoma and Cataract. Two-Year Results. *Ophthalmology*. 2019;**126**(6):811-821
- [13] Craven ER, Katz LJ, Wells JM, Giamporcaro JE, iStent Study Group. Cataract surgery with trabecular micro-bypass stent implantation in patients with mild-to-moderate open-angle glaucoma and cataract: two-year follow-up. *Journal of Cataract and Refractive Surgery*. 2012;**38**(8):1339-1345

- [14] Samuelson TW, Sarkisian SR Jr, Lubeck DM, Stiles MC, Duh YJ, Romo EA, Giamporcaro JE, Hornbeak DM, Katz LJ; iStent inject Study Group. Prospective, Randomized, Controlled Pivotal Trial of an Ab Interno Implanted Trabecular Micro-Bypass in Primary Open-Angle Glaucoma and Cataract. Two-Year Results. *Ophthalmology*. 2019;**126**(6):811-821
- [15] Fea AM, Belda JI, Rękas M, Jünemann A, Chang L, Pablo L, et al. Prospective unmasked randomized evaluation of the iStent inject (®) versus two ocular hypotensive agents in patients with primary open-angle glaucoma. *Clinical Ophthalmology*. 2014;**8**:875-882
- [16] Pfeiffer N, Garcia-Feijoo J, Martinez-de-la-Casa JM, Larrosa JM, Fea A, Lemij H, et al. Randomized Trial of a Schlemm's Canal Microstent with Phacoemulsification for Reducing Intraocular Pressure in Open-Angle Glaucoma. *Ophthalmology*. 2015;**122**(7):1283-1293
- [17] Gallardo MJ, Supnet RA, Ahmed IIK. Viscodilation of Schlemm's canal for the reduction of IOP via an ab-interno approach. *Clinical Ophthalmology*. 2018;**23**(12):2149-2155
- [18] Dorairaj SK, Seibold LK, Radcliffe NM, Aref AA, Jimenez-Román J, Lazcano-Gomez GS, et al. 12-Month Outcomes of Goniotomy Performed Using the Kahook Dual Blade Combined with Cataract Surgery in Eyes with Medically Treated Glaucoma. *Advances in Therapy*. 2018;**35**(9):1460-1469
- [19] Pache M, Wilmsmeyer S, Funk J. Laserchirurgie und Glaukom: Excimer-Laser-Trabekulotomie [Laser surgery for glaucoma: excimer-laser trabeculotomy]. *Klinische Monatsblätter für Augenheilkunde*. 2006;**223**(4):303-307
- [20] Pache M, Wilmsmeyer S, Funk J. Laserchirurgie und Glaukom: Excimer-Laser-Trabekulotomie [Laser surgery for glaucoma: excimer-laser trabeculotomy]. *Klinische Monatsblätter für Augenheilkunde*. 2006;**223**(4):303-307
- [21] Babighian S, Caretti L, Tavalato M, Cian R, Galan A. Excimer laser trabeculotomy vs 180 degrees selective laser trabeculoplasty in primary open-angle glaucoma. A 2-year randomized, controlled trial. *Eye (London, England)*. 2010;**24**(4):632-638