

We are IntechOpen, the world's leading publisher of Open Access books Built by scientists, for scientists

6,900

Open access books available

186,000

International authors and editors

200M

Downloads

Our authors are among the

154

Countries delivered to

TOP 1%

most cited scientists

12.2%

Contributors from top 500 universities



WEB OF SCIENCE™

Selection of our books indexed in the Book Citation Index
in Web of Science™ Core Collection (BKCI)

Interested in publishing with us?
Contact book.department@intechopen.com

Numbers displayed above are based on latest data collected.
For more information visit www.intechopen.com



Extra-Uterine Fibroids

Rakesh Kumar Gupta and Poonam Wasnik

Abstract

Leiomyomas are the most common gynecologic and uterine neoplasms. Uterine leiomyomas present in approximately 25% of women during reproductive age. Extrauterine leiomyomas (EULs) are rarer and usually arise in the genitourinary tract, however, may arise at nearly any anatomic location and possess a great diagnostic challenge. Moreover, the EULs may also present with unusual growth patterns such as disseminated peritoneal leiomyomatosis, intravenous leiomyomatosis, benign metastasizing leiomyoma, parasitic leiomyoma, and retroperitoneal mass. However, the cell of origin from smooth muscle cells and histological benign characteristics is similar to their uterine counterpart. The presence of a synchronous uterine leiomyoma or history of previous hysterectomy is a considerable evidence for the diagnosis of these abnormally located and unusual growth pattern displaying EULs. Different imaging modalities like ultrasonography, computed tomography, and magnetic resonance imaging are helpful in the diagnosis of EULs, however, sometimes a histopathological examination is required for the confirmation.

Keywords: Extrauterine, leiomyoma, disseminated peritoneal leiomyomatosis, benign metastasizing leiomyoma, parasitic leiomyoma, genitourinary tract

1. Introduction

Leiomyomas are benign smooth muscle tumours usually arise from the uterus [1]. Classical uterine leiomyoma manifest as firm, well circumscribed mass, and localized to the pelvic cavity [2]. Extrauterine leiomyomas (EULs) are very rare and their etiology is not clear [1]. They grow in unusual patterns and locations, thus possess greater diagnostic challenge. Different presentations of EUL are disseminated peritoneal leiomyomatosis (DPL), parasitic leiomyoma (PL), uterine-like mass lesions, adenomyoma and endometriosis [3]. Unusual sites involvement like vulval and rectovaginal leiomyomas are also found [4]. EULs arising in the gastrointestinal tract, genitourinary tract, as well as other rare locations including sinonasal cavities, orbits, and skin are also described in some case reports.

Uterine leiomyoma is a benign tumour which originates from smooth muscle cells. Leiomyomas can present in abnormal growth patterns and tend to occur in extrauterine location especially in cases with prior history of hysterectomy or surgery for uterine leiomyomas.

2. Types of EULs

2.1 Disseminated peritoneal leiomyomatosis

Multifocal proliferation of multiple smooth nodules throughout the peritoneal surface histologically similar to uterine myomas is known as leiomyomatosis peritonealis disseminate (LPD) or disseminated peritoneal leiomyomatosis (DPL) [3, 5, 6]. The peritoneal cavity shows multiple nodules of smooth muscle (**Figure 1**) [6, 7]. DPL usually occurs in reproductive age group with an indolent course, and are mostly detected incidentally [6]. Uterine myoma morcellation is a known risk factor for the development of DPL with an incidence rate around 0.12 to 0.95% after morcellation [5, 6]. Morcellation may lead to spreading of cellular materials of the myoma fragments. These morcellated tissues get disseminated if they are not removed and may become infarcted, necrotic or even parasitic [3]. Other causes which can contribute in the pathogenesis of DPL includes; hormonal, genetic, and sub-peritoneal mesenchymal stem cells metaplasia.

Pelvic region is the commonest site especially in pouch of douglas, may also spread to entire abdomen to involve omentum and mesentery. DPL is very invasive and very difficult for complete surgical excision, which may invade into bladder, retroperitoneal space, liver and small bowel [5]. They present as numerous subcentimetric grey -white firm nodules, sometimes with solid cystic hemorrhagic changes [5]. DPL can presents with ascites and adenopathy, which can be confused with peritoneal carcinomatosis. Sometimes, DPL may evolve into leiomyosarcoma, though it is extremely rare and possess high mortality rate [5, 6]. Due to unusual multifocal presentation, peritoneal myomas mimic malignant peritoneal tumor, so aggressive treatment at first surgical line should be avoided [6].

Some cases of gastrointestinal tract (GIT) leiomyomas have been reported with intestinal obstruction or bleeding without past or present history of uterine fibroid. But GIT leiomyomas are different from LPD. GIT leiomyomas can develop from intestinal wall and may reach the lumen whereas LPD mostly reach peritoneal cavity and omentum [5]. But disseminated GIT leiomyoma could be related to LPD, if there is no evidence of uterine myomas [5].

2.2 Benign metastasizing leiomyoma

Benign metastasizing leiomyoma (BML) is a rare condition that affects women with a history of uterine myomectomy, which is found to metastasize to extra-uterine sites. The disease is characterized by monoclonal proliferation of smooth muscle cells and haematogenous spread from uterine leiomyoma to distant locations, most commonly

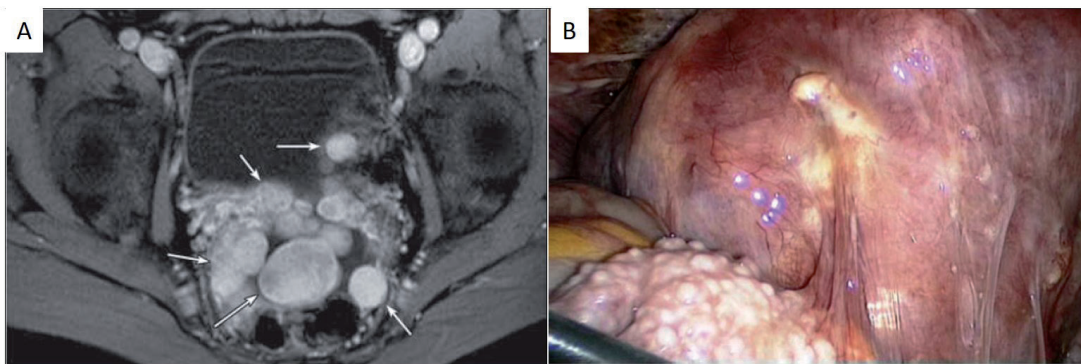


Figure 1.
(A) Contrast-enhanced T1-weighted fat-suppressed fast spin echo magnetic resonance image shows multiple homogeneously enhancing peritoneal leiomyomas (arrows), (B) Intra-operative gross image showing multiple variably sized peritoneal nodules representing disseminated peritoneal leiomyomatosis.

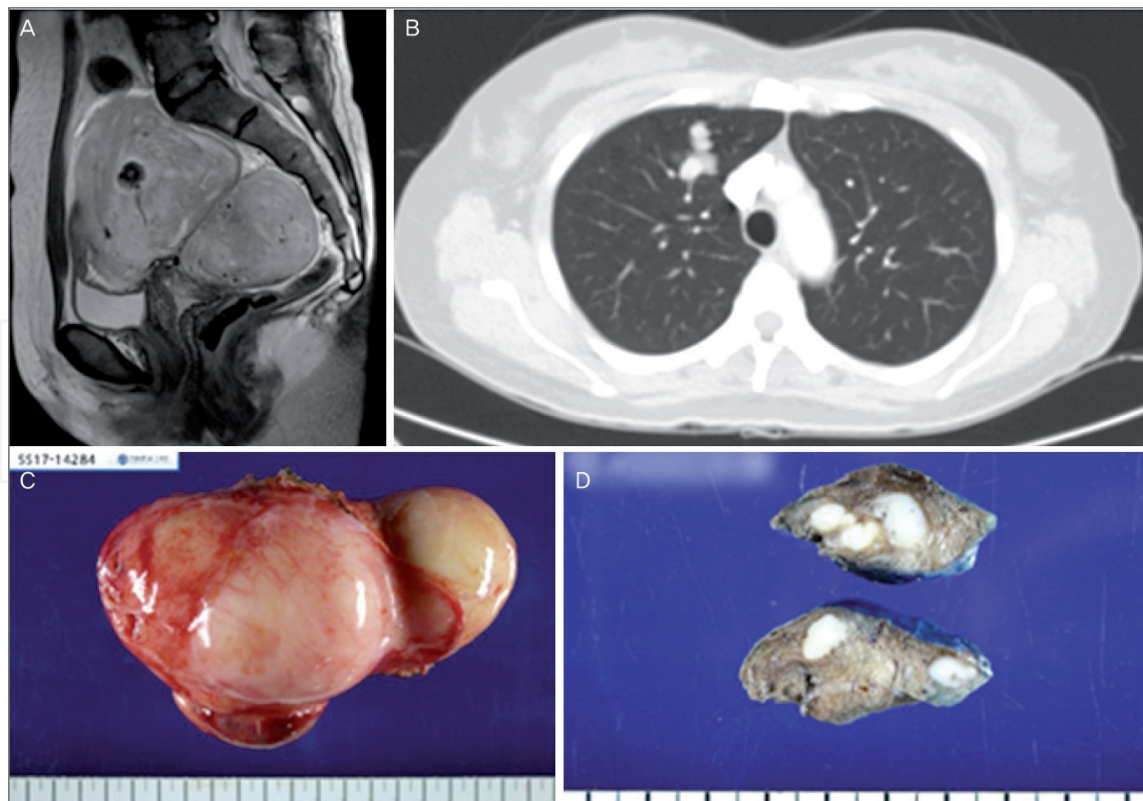


Figure 2.
 (A) Abdomino-pelvic computed tomography showing a large pelvic mass, and (B) thoracic computed tomography showing bilateral lung nodules, Gross specimens (C) pelvic mass excision and (D) video-assisted thoracoscopic guided surgical resection of bilateral basal lung nodule in an operated case of total abdominal hysterectomy with bilateral salpingo-oophorectomy.

the lungs (**Figure 2**) [2, 8]. The other uncommon site of metastasis includes heart and spinal cord [2]. Metaplastic transformation of the coelomic epithelium may explain BML in almost any place where mesothelial mesenchyme exists [2]. BML commonly occur during peri-menopausal period. Surgical excision is the treatment of choice.

2.3 Intravenous leiomyomatosis

Intravenous leiomyomatosis (IVL) also included under smooth muscle tumours with unusual growth pattern like that of benign metastasizing leiomyoma (BML) and diffuse peritoneal leiomyomatosis (DPL) and difficult to distinguish from them [2]. IVL is very rare variant of benign leiomyomas. It presents as fragile and mal-leable leiomyoma that extends through adjacent venous structures in a worm-like fashion (**Figure 3**) [2]. Rarely, IVL may infiltrate into the right heart chamber and the lungs [6]. Due to wide range of clinical manifestation, IVL is difficult to diagnose pre-operatively [2].

2.4 Parasitic leiomyoma

Parasitic leiomyoma is termed when leiomyoma especially subserous fibroid is pedunculated off the uterine serosa or when fragments of a fibroid detach, get implanted and grow within the peritoneal cavity or becomes adherent to other structures, especially the omentum (**Figure 4**) [3]. They obtain their blood supply from nearby organ and the uterine pedicle either or become avascular and disappear completely. These are also known as ectopic leiomyoma [3]. Cucinella et al. suggested morcellated hysterectomies or myomectomies as an important cause for development of parasitic leiomyoma [9].

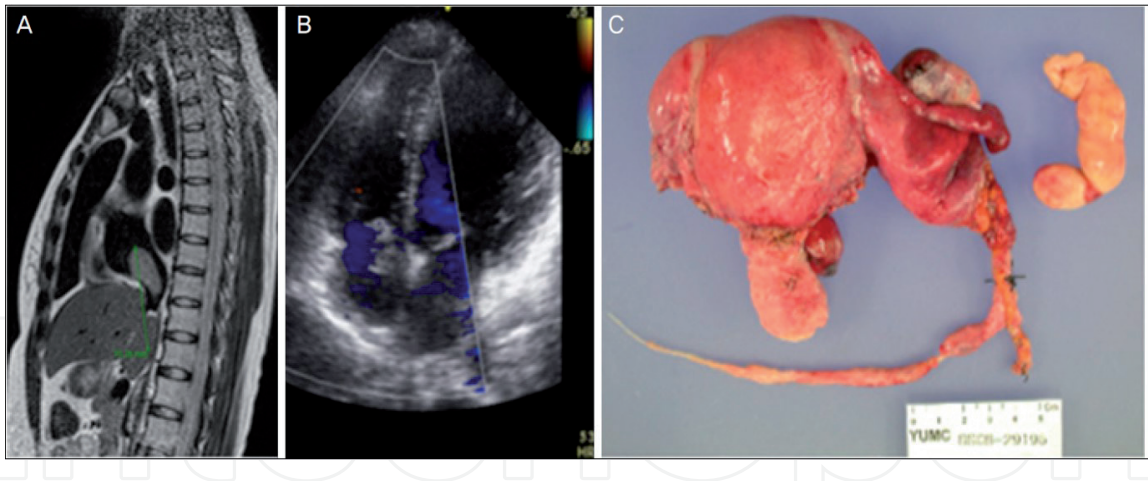


Figure 3.
(A) Magnetic resonance image showing a 'comma' shaped thrombosis, extending from the intrahepatic portion of inferior vena cava (IVC) to the right atrium, (B) Echocardiography showing an intracardiac mass with dynamic movement past the tricuspid valve into the right ventricle, (C) Gross specimen of total abdominal hysterectomy with left salpingo-oophorectomy, and IVC and intracardiac mass.

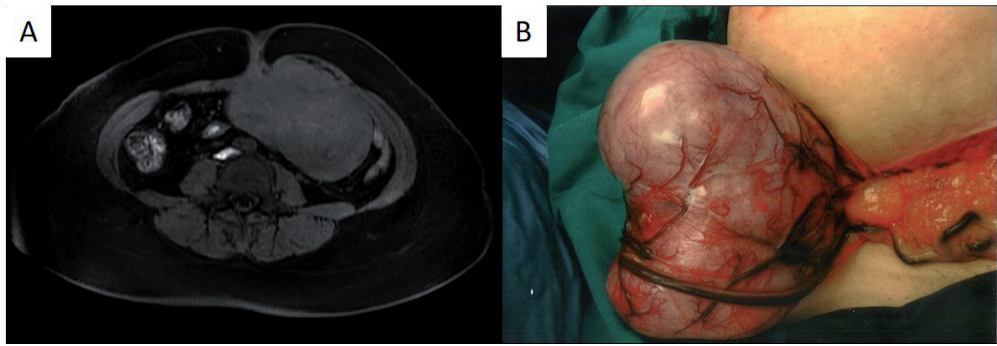


Figure 4.
(A) Magnetic resonance image showing two large lobulated peritoneal masses with similar signal and enhancement characteristics, (B) Gross specimen of peritoneal fibroid vascularized by omental vessels in a patient underwent laparoscopic myomectomy 5 years earlier.

2.5 Extrauterine adenomyoma

Extrauterine adenomyomas (EUA) are benign tumours composed of smooth muscles, endometrial glands and endometrial stroma (**Figure 5**) [10]. In the literature, four hypotheses have been proposed for the development of EUA which includes (1) Müllerian duct fusion defect - the failure of fusion of Müllerian ducts result in either duplication or atresia of the uterus which is suggested by the formation of uterine-like masses, (2) Subcoelomic mesenchyme transformation - Subcoelomic mesenchyme is a layer of tissue that lies underneath the mesothelial surface of the peritoneum. It also lies underneath the subserosal stroma of uterus, uterine ligaments, ovaries and fallopian tubes, (3) Müllerianosis - It is a heterotopic Müllerian rests incorporated into other organs during organogenesis which may proliferate in response to hormones and (4) Endomyometriosis - along with endomyometriosis, smooth muscle hyperplasia or metaplasia leads to EUA [11, 12].

3. Role of hormones

Leiomyomas are clonal neoplasm and express more number of estrogen and progesterone receptors in comparison to normal myometrium [1, 2]. Circulating estrogen, progesterone and other growth factors like epidermal growth factor and

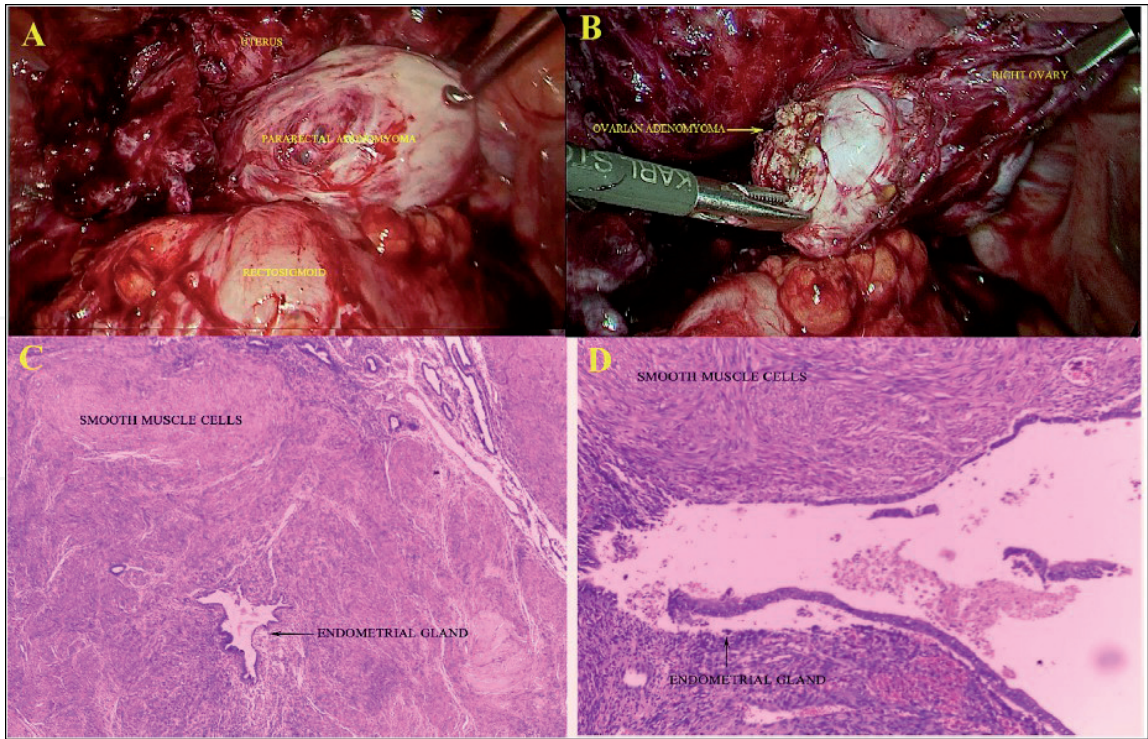


Figure 5.
Intra-operative laparoscopic images of (A) pararectal adenomyoma and (B) right ovarian adenomyoma, histopathology images of ovarian adenomyoma (C) low power and (D) high power delineating smooth muscle bundles with embedded endometrial glands in a patient underwent laparoscopic myomectomy 5 years earlier.

insulin like growth factors are involved in the growth of uterine leiomyomas [1]. Estrogen stimulates the growth of leiomyoma independent of its location whether uterine or extrauterine [1]. However, the role of progesterone remains uncertain in extrauterine leiomyoma and its serum levels are either normal or low. Withdrawal of progesterone and of sex steroid down regulates expression of estrogen receptors (ER) in both leiomyomas and myometrium. This indicates that progesterone and progestins have a dual role on leiomyomas. First, limitation of the tissue response due to blocking of ER replacement and leading to unopposed estrogenic growth effect either by direct stimulation or by increased expression of progesterone receptors (PR). Second, progesterone may leads to an intrinsic growth-stimulation [1]. Progesterone causes increased mitotic division causing myoma growth and leads to the higher propensity for development of the somatic mutations in the myomas. It is suggested that PR is highly expressed in leiomyomas occurring in the reproductive period [1]. Such hormones influence rapid increase in size of leiomyoma in pregnancy which may lead to fetal wastage. However, there is lower expression of PR in EUL than in UL suggesting that different factors may contribute to the development of these tumours. Sen et al found a significant difference for labeling indices of PR between UL and EUL, however it was not significant for ER. Thus, therapeutic models targeting PRs may not be effective on EUL.

4. Diagnosis

Patient may present with menorrhagia, or diagnosed incidentally with the history of previous myoma or myomectomy [3]. Ultrasound is useful for diagnosis of uterine fibroid. Prior diagnosis of extra-uterine fibroids is often difficult owing to non-specific clinical and radiological findings. MRI is very helpful when ultrasound shows poor delineation, and in case of rapidly growing fibroid suspicious for

malignant transformation. MRI is also very useful for the diagnosis of DPL as well as to determine its extent of spread for surgical planning (**Figure 1A**) [3]. In case of IVL, apart from trans-vaginal ultrasound, and other modalities such as pelvic MRI, trans-thoracic echocardiography, abdomen or chest computed tomography (CT), and positron emission tomography (PET) are beneficial [2]. But there is limitation of MRI in locating retroperitoneal leiomyoma in which exact anatomical location can be often ascertained only intraoperatively [3]. Few cases may turn into leiomyosarcoma. Peritoneal cytology should be done in case of ascites [3].

Despite the extrauterine manifestation of leiomyoma, benign leiomyomas can be distinguished from leiomyosarcoma histologically. Sarcoma is marked by high grade cellular atypia, mitotic index of greater than 10, and presence of coagulative tumor cell necrosis [2]. IVL, usually found within uterine venous channels and microscopically shows benign appearing smooth muscle cells with low mitotic activity which stain for actin and desmin [2].

Recent investigations showed that IVL and BML share the same cytogenetic origin, demonstrated by comparative genomic hybridization, clonal number, and copy variance [2]. Leiomyoma and leiomyosarcoma both shows smooth muscle differentiation, however biologically they are different in relation to clinical, cytogenetic, and molecular features [13]. MED12, the mediator complex subunit 12 gene, is a recently described oncogene found in both primary and metastatic leiomyosarcoma. It is detected in as many as 70% of sporadic uterine leiomyoma [13]. Oncogenic roles of MED 12 gene is also detected in smooth muscle tumours arising in extrauterine locations, however, further validating studies required for confirming its exact role in their pathogenesis [13].

5. Treatment

Complete surgical excision is considered the mainstay and definitive treatment for EULs [14]. LPD mimics carcinomatosis, so total abdominal hysterectomy along with bilateral oophorectomy is often the preferred surgical treatment [5]. However, spontaneous regression has been also described in few case reports in the literature [5]. Surgical treatment affects reproductive ability in pre-menopausal women, so it should always be planned considering the family planning of the patient. In such situation diagnosis by intra-operative frozen section is very helpful [5]. Young patient in child bearing age group, especially who shows positivity for ER or PR markers in EUL, should be subject to ovary-sparing procedures and might be benefited from adjuvant therapy using GnRH agonist [2]. In histological proven DPL cases, debulking is very effective for relieving symptoms, provided the appropriate evaluation of general health conditions of the patient [5]. In unresectable cases of EULs, a medical treatment with aromatase inhibitors, chemotherapeutic agents or a gonadotropin agonist can be considered [2, 6]. During morcellation, falling pieces of myoma fragments should be avoided and proper attention should be given during removal via the port site. Post morcellation, reverse trendelenburg position should be attempted and thorough inspection with copious peritoneal lavage is recommended to aid the removal of remnant myoma pieces [3]. The Food and Drug Administration guidelines discourage the uses of laparoscopic power morcellation during hysterectomy or myomectomy for the treatment of uterine fibroids [3].

6. Follow-up

A routine follow-up is advised in all the patients of uterine fibroid undergoing morcellation for the development of EUL. Similarly, a long-term follow-up is

essential in all the operated cases of EUL, particularly, DPL. In EULs, recurrence, if any, usually occur within 6 months after surgical resection. Since, these tumours are hormone sensitive, they usually show regression after reduction in estrogen exposure like after attainment of menopause. Repeat surgeries for recurrent EULs usually entail greater surgical difficulty and risks including visceral injuries [3].

7. Complications

DPL may leads to peritonitis and bowel obstruction which can result into sepsis and gangrene. Also, recurrence is not unusual in DPL cases due extensive involvement of peritoneal cavity. Sometimes, malignant transformation may occur in long standing cases.

8. Conclusions

EULs possess a great diagnostic challenge due to abnormal locations as well as their unusual growth patterns and more commonly associated with the complications in comparison to uterine leiomyomas. Though, histologically they show similarities with their uterine counter parts, however their pathogenesis is different and yet not well understood. These EULs, are hormone sensitive and may regress automatically after the recession of hormonal sources, however, this phenomenon is not universal in all cases. Due to their higher propensity for recurrence and rare malignant transformation a close follow-up is required. A peritoneal cytology and/or frozen section examination is recommended before major surgical procedures in EULs.

Source of financial support and conflict of interest

None to declare.

Declarations


Authors declare that all the necessary permissions has been obtained for using the images from the corresponding authors/editors of the concerned articles and all the papers from which these images reproduced has been cited.

Author details

Rakesh Kumar Gupta* and Poonam Wasnik
Department of Pathology and Laboratory Medicine, AIIMS, Raipur, C.G., India

*Address all correspondence to: rakesh.newjobi@gmail.com

IntechOpen

© 2020 The Author(s). Licensee IntechOpen. This chapter is distributed under the terms of the Creative Commons Attribution License (<http://creativecommons.org/licenses/by/3.0>), which permits unrestricted use, distribution, and reproduction in any medium, provided the original work is properly cited. 

References

- [1] Sen N, Demirkan NC, Colakoglu N, Duzcan SE. Are there any differences in the expression of hormonal receptors and proliferation markers between uterine and extrauterine leiomyomas? *International Journal of Surgical Pathology*. 2008;**16**(1):43-47
- [2] Kim YN, Eoh KJ, Lee JY, Nam EJ, Kim S, Kim SW, et al. Aberrant uterine leiomyomas with extrauterine manifestation: intravenous leiomyomatosis and benign metastasizing leiomyomas. *Obstet Gynecol Sci*. 2018;**61**(4):509-519
- [3] Chin H, Ong XH, Yam PK, Chern BS. Extrauterine fibroids: a diagnostic challenge and a long-term battle. *BMJ Case Rep*. 2014;2014:bcr2014204928.
- [4] Parry-Smith W. Extrauterine leiomyoma. *Journal of Obstetrics and Gynaecology*. 2010;**30**(3):317
- [5] Gaichies L, Fabre-Monplaisir L, Fauvet R, Alves A, Mulliri A. Leiomyomatosis peritonealis disseminata: Two unusual cases with literature review. *J Gynecol Obstet Hum Reprod*. 2018;**47**(2):89-94
- [6] Turlakakis D, Tas B, Van Herendael B. Disseminated peritoneal leiomyomatosis. *Gynecological Surgery*. 2010;**7**:241-243
- [7] Fasih N, Prasad Shanbhogue AK, Macdonald DB, Fraser-Hill MA, Papadatos D, Kielar AZ, et al. Leiomyomas beyond the uterus: unusual locations, rare manifestations. *Radiographics*. 2008;**28**(7):1931-1948
- [8] Barnaś E, Książek M, Raś R, Skręt A, Skręt-Magierło J, Dmoch-Gajzlerska E. Benign metastasizing leiomyoma: A review of current literature in respect to the time and type of previous gynecological surgery. *PLoS One*. 2017;**12**(4):e0175875
- [9] Cucinella G, Granese R, Calagna G, Somigliana E, Perino A. Parasitic myomas after laparoscopic surgery: an emerging complication in the use of morcellator? Description of four cases. *Fertility and Sterility*. 2011;**96**(2):e90-e96
- [10] Paul PG, Gulati G, Shintre H, Mannur S, Paul G, Mehta S. Extrauterine adenomyoma: a review of the literature. *European Journal of Obstetrics, Gynecology, and Reproductive Biology*. 2018;**228**:130-136
- [11] Moghadamfalahi M, Metzinger DS. Multiple extrauterine adenomyomas presenting in upper abdomen and pelvis: a case report and brief review of the literature. *Case Reports in Obstetrics and Gynecology*. 2012;**2012**:565901
- [12] Huanwen W, Hui Z, Xiaowei X, Zhaohui L. Extrauterine adenomyoma of the liver with a focally cellular smooth muscle component occurring in a patient with a history of myomectomy: case report and review of the literature. *Diagnostic Pathology*. 2013;**8**:131
- [13] Ravegnini G, Mariño-Enriquez A, Slater J, Eilers G, Wang Y, Zhu M, et al. MED12 mutations in leiomyosarcoma and extrauterine leiomyoma. *Modern Pathology*. 2013;**26**(5):743-749
- [14] Sewell CA, Russo ML. Retroperitoneal leiomyoma: a case report. *The Journal of Reproductive Medicine*. 2011;**56**:515-517