

# We are IntechOpen, the world's leading publisher of Open Access books Built by scientists, for scientists

6,900

Open access books available

186,000

International authors and editors

200M

Downloads

Our authors are among the

154

Countries delivered to

TOP 1%

most cited scientists

12.2%

Contributors from top 500 universities



WEB OF SCIENCE™

Selection of our books indexed in the Book Citation Index  
in Web of Science™ Core Collection (BKCI)

Interested in publishing with us?  
Contact [book.department@intechopen.com](mailto:book.department@intechopen.com)

Numbers displayed above are based on latest data collected.  
For more information visit [www.intechopen.com](http://www.intechopen.com)



# Acute Hydrops and Its Management

*Praveen Subudhi, Sweta Patro and Nageswar Rao Subudhi*

## Abstract

Acute hydrops is a well-known complication of keratoconus. It usually manifests as sudden onset loss of vision. Mostly presents in the pubertal age group. Allergic conjunctivitis associated with eye rubbing is the most substantial risk factor. Primary pathology being stromal lysis, which triggers the progression of cone, causing an undue stretch on Descemet Membrane, eventually resulting in its splitting and stromal imbibition of aqueous through these ruptures. Clinical signs are circumcillary congestion and thick/edematous cornea with obscuration of the anterior segment. Conservative therapy delays wound healing; hence early surgical intervention is recommended globally for faster resolution of stromal edema. Long-standing corneal edema mounts to corneal perforation and neovascularisation of cornea. Compressive suture, non expansile intracameral gas injection, Deep anterior lamellar keratoplasty, and mini Descemet membrane keratoplasty are various management modalities reported in literature. Acute hydrops could be well prevented with early identification of progressive keratoconus and halting its progression.

**Keywords:** acute hydrops, keratoconus, compressive sutures, intracameral gas, ocular allergy

## 1. Introduction

### 1.1 Epidemiology

Acute hydrops is a well-known complication of progressive keratoconus. It has also been reported in other noninflammatory ectatic disorders such as pellucid marginal degeneration and keratoglobus. The incidence of acute hydrops is minimal but varies according to race. A 2011 UK census reported higher number of cases among the South Asian and Black ethnic groups, compared with that in the general population. The reported incidence rates among the white, South Asian, and black population are 0.07/100,000, 0.32 /100,000, and 0.37/100,000, respectively [1]. According to numerous studies, the trend in acute hydrops Incidence among patients with keratoconus has been shown to be decreasing; Tuft et al. and Amsler M et al. reported the prevalence of acute hydrops as 2.6% and 2.8%, respectively [2, 3]. Acute hydrops can occur at any age but is commonly reported in individuals aged between 20 and 30 years, whereas the broad age range is 10 to 47 years. It has a significant gender disparity; men are more susceptible to this condition compared with women, with a ratio of 1.2:1 according to the Auckland Keratoconus Study [4], 3:1 according to a UK prospective study [1], and 2.9:1 according to an American study [5].

## **2. Predisposing factors**

Ocular allergy is frequently associated with keratoconus ranging from 7 to 35% [6–9]. Bawazeer et al. in a case control study demonstrated a positive correlation between keratoconus and atopy [10]. Any form of ocular allergy instigates itching, foreign body sensation, and eye rubbing [11]. This triggers a corneal intra-stromal inflammation because of the increased levels of histamine, tumor necrosis factor-alpha, and interleukins [12]. It coaxes to stromal lysis and corneal thinning because of the increased levels of lysosomal and proteolytic enzymes with a simultaneous reduction in the levels of protease inhibitors [12]. This vicious cycle of inflammation and stromal lysis is exacerbated by recurrent eye rubbing [13], and the stable keratoconus eventually becomes progressive which increases the risk of acute hydrops [14].

A history of having worn the contact lenses, specially the rigid gas permeable lens, is also considered an important risk factor for acute hydrops [15]. Contact lens usage triggers ocular inflammation because of hypoxia of the corneal surface [16]. A study showed that the level of inflammatory markers present in the tear film increases after the use of contact lens [17]. This inflammation initiates the progression of keratoconus that eventually leads to acute hydrops [18].

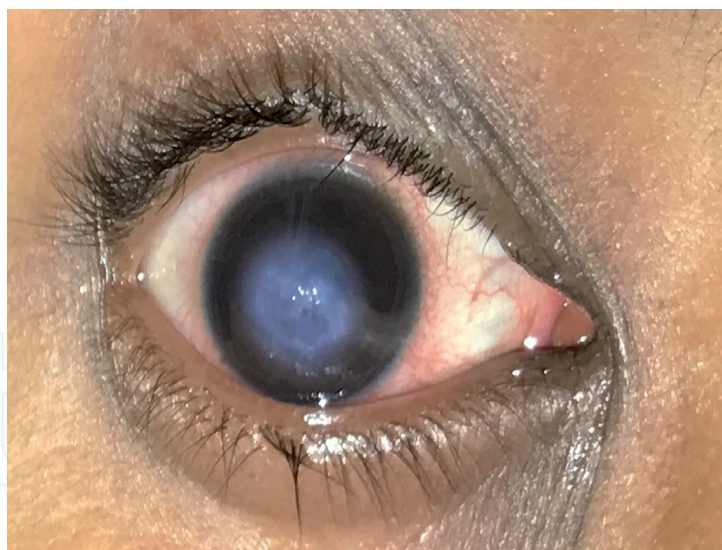A trivial ocular trauma plays a significant role in the rupturing of already stressed-out descemet membrane (DM) [19]. Advanced keratoconus, eccentric cone, and poor visual acuity are other important risk factors for acute hydrops in patients with keratoconus. Down syndrome increases the risk of keratoconus progression, thereby increasing the risk of acute hydrops [20]. Retinitis pigmentosa, Leber Congenital Amaurosis (LCA), floppy eye lid syndrome, and Ehler-Danlos syndrome are other risk factors for progressive keratoconus, which are followed by the incident of hydrops [21–24]. Pregnancy and lactation are also the critical but temporary risk factors [25]. However, a positive family history has been reported to have a negative correlation with the acute hydrops incidence [26].

## **3. Corneal topography and acute hydrops**

Corneal topography plays a critical role in identifying patients with keratoconus progression [27]. Various parameters are available in pentacam that must be reinvestigated after every 3 month to accurately diagnose the progression; parameters, namely, maximum keratometry, minimum pachymetry, pachymetric progression index, elevation indices of corneal front and back surfaces, anterior radius of curvature taken 3 mm surrounding the thinnest pachymetry, posterior radius of curvature taken 3 mm surrounding the thinnest pachymetry, and deviation index, must be scrutinized during every visit. Any evidence of progression should be intervened to prevent or halt the deterioration to eventually decrease the risk of acute hydrops incidence [28].

## **4. Pathophysiology**

The progression of keratoconus initiates because of stretching of the DM that is adhered strongly to the periphery, which leads to circumferential stretching of the membrane and increased risk of its rupture [29, 30]. If the stretching extends beyond a limit, the membrane tends to rupture at the center, which leads to the seepage of aqueous fluid into the stroma and thereby causes acute hydrops [31].



**Figure 1.**  
*Showing a case of acute hydrops.*

## 5. Clinical examination and manifestations

Acute hydrops initiates with a sudden onset of poor vision and discoloration of the cornea [32]. The disease is confined to the central and paracentral regions and rarely manifests in the peripheral region in case of coexistent pellucid marginal degeneration [33]. In addition to a defective vision, pain and redness are the typical symptoms of this disease [34]. The patients exhibit a definite history of persisting poor vision since childhood and experience progressive vision loss [35]. History of spectacle use should be investigated by reviewing the old optical prescriptions or old spectacles. Past history of high astigmatism, oblique axis and poor best corrected visual acuity are considered as corroborative clinical signs of acute hydrops following progressive keratoconus. Meticulous medical history of ocular allergy, atopic dermatitis, contact lens usage, eye rubbing, and ocular trauma should be documented [36]. Contact lens history, with emphasis on the type, duration of usage, overnight usage while sleeping, and expiry date of the contact lens, is also considered essential [37]. Ocular trauma history, with emphasis on the blunt trauma not withstanding its impact or severity, should also be documented (**Figure 1**) [38].

Examination using a diffused torchlight reveals a whitish lesion over the central or paracentral regions with intense photophobia (**Figure 1**). Conjunctiva shows a sign of circumciliary congestion, and palpebral conjunctiva may be congested depending upon the presence of allergic conjunctivitis. In the absence of oculi allergy, eyes are less susceptible to palpebral congestion. The iris or anterior segment is not visible in case of central hydrops but in cases of paracentral hydrops, the anterior segment is clearly visible through the clear cornea [35].

Slit lamp examination with an oblique slit shows an abnormally thick cornea with clefts in the intrastromal area and Obscuration of Descemet Membrane (DM) due to the blockage of light rays by the edematous cornea [39, 40].

## 6. Grading of acute hydrops

Acute hydrops can be graded depending on the corneal region involved. Corneal edema can be graded by drawing an imaginary circle around the cornea [41].

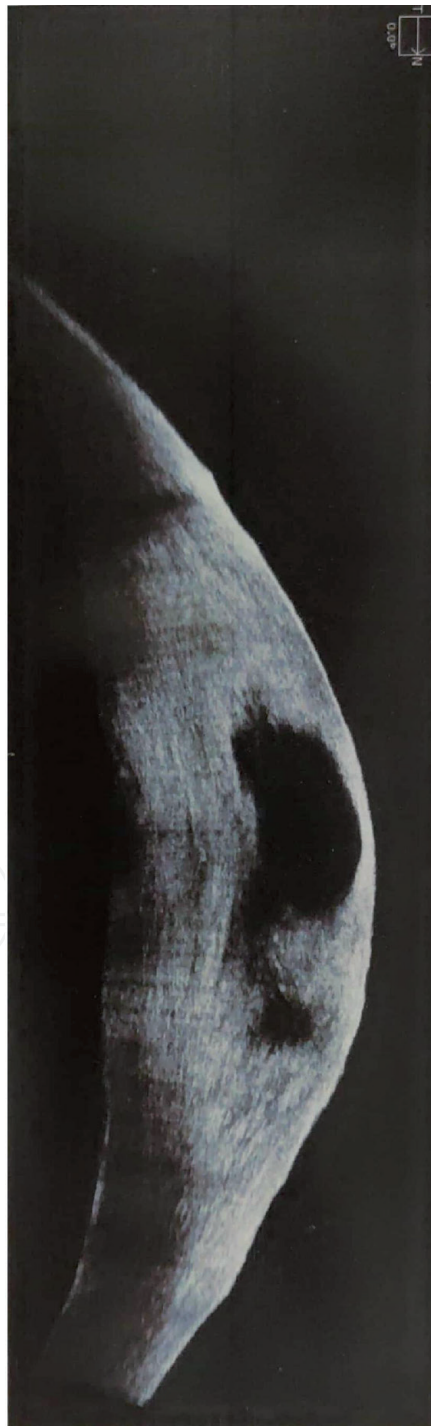Grade 1: Involves 3-mm diameter of cornea.

Grade 2: Between 3- and 5-mm diameter of cornea.

Grade 3: More than 5 m-diameter of cornea.

## 7. Investigations

Though acute hydrops is mostly diagnosed clinically, anterior segment OCT (ASOCT) can be performed to assess the severity and pattern of the resolution (**Figure 2**), [42]. ASOCT manifests as hypo reflective areas in the presence of fluid, hyper-reflective areas in the presence of fibrous tissues. In the early phase of corneal edema, epithelial micro cysts with pseudocysts formation in the intrastromal area are



**Figure 2.**  
ASOCT showing corneal edema, clefts and cysts (courtesy-Dr.Sridevi Gunda).

witnessed as hyporeflective areas [43]. Pseudocysts develop due to fluid accumulation in the intrastromal spaces separating the stromal lamellae because of the sudden egress of the fluid. The word “pseudocyst” was coined because the cyst wall formation does not involve epithelium. These pseudocysts are initially small in size and multiple in number but eventually they fuse to become a large cyst [44]. Sometimes, the fluid reaches the anterior stroma leading to bullous swelling of the corneal surface, referred as “epitheliocoele” in literature [45]. High-resolution ASOCT can demonstrate a breach in the continuity of the DM and stromal access to the aqueous humor [46]. ASOCT can also demonstrate a slow healing process of polygonal defects in the DM that is caused by its rupture. Healing of DM takes place slowly than that of the corneal epithelium. Hence, decrease in the size of DM defect can be witnessed after a week, and in the due course, the corneal edema which is seen as hypo-reflective/dark areas gets reduced eventually allowing the visibility of hyper-reflective shadows in the sub epithelial area marks the healing of acute hydrops [46].

Confocal microscopy is a new modality in the investigation process; though it is more useful for academic purpose, it gives an insight into the pathology of the disease [47]. Confocal microscope acts like an *in vivo* electron microscope; hence, the technique is termed as *in vivo* confocal microscopy (IVCM). It analyses the anterior and middle parts of the cornea. Bullae are seen in the superficial and wing layers of the corneal epithelium. Stromal area shows hyper-reflective band-shaped structures in the anterior stroma, and microfilms are seen in the mid and anterior stroma. Hyper-reflective cells are seen in the anterior stroma and epithelium, which are presumed to be inflammatory cells [48].

## 8. Complications

Acute hydrops commonly resolves spontaneously over a period of 4–8 weeks; however, it can be delayed because of large DM deficit or poor functionality of the corneal endothelial cells [49].

The risk of corneal perforation in cases of extreme penetration of fluid into the anterior stromal space is also present, which results in the formation of the epithelial bullae [50]. Any trivial trauma or ocular rubbing causes the rupture of the bullae, which may lead to shallowing of an anterior chamber and the formation of an anterior synechiae. Upon healing, it forms a dense vascularized corneal scar with extremely poor prognosis [51].

Corneal vascularization can be accentuated with a delay in the process of corneal edema reduction. Long-term cornea edema is associated with a risk of the release of vascular endothelial growth factors that induces corneal vasculogenesis from the peripheral corneal vessels, eventually leading to the formation of a vascularized corneal scar [51].

Bullous rupture of the corneal surface exposes raw stroma to the tear film and ocular commensals. Poor hygienic practices may lead to infectious keratitis [52]. Mostly bacterial keratitis has been reported; however, fungal keratitis has also been reported in the tropical countries. In developing countries such as India, the use of over-the-counter topical corticosteroids without clinical consultation is rampant that has led to the development of debilitating infectious keratitis [53].

## 9. Differential diagnosis

Penetrating ocular trauma may mimic acute hydrops; however, it has a recent background history of trauma and entry wound [54].

Calotropis keratitis commonly seen in the Indian subcontinent seen after accidental fall of whitish fluid while plucking the flower of the plant [55]. It may be localized or diffused and mostly presents as emergency having a perfectly normal vision before the fall. Upon slit lamp examination, a typical DM folds with the corneal edema are visible, and no breach in the continuity of DM is detected.

Post-herpetic endothelial dysfunctions are seen typically after an episode of herpetic keratitis or most likely after herpes zoster ophthalmicus. Clinically, it is seen as the localized corneal edema with pigment dusting of the endothelium and the presence of sectoral iris atrophy in case of herpes zoster [56, 57].

CMV keratitis is another rarely seen condition of the cornea that can be considered for the differential diagnosis of acute hydrops, and it typically manifests as a focal corneal edema and appears as a coin-shaped lesion [58].

Nuclear fragment retention after cataract surgery is a rare but a significant differential diagnosis, which manifests as on- and off-focal corneal edema mostly in the inferior quadrant. A careful clinical examination of an anterior segment reveals the presence of nuclear fragments and a positive history of recurrent anterior uveitis [59].

Bullous keratopathy due to Fuchs endothelial corneal dystrophy can be ruled out by seeing the other eye [60].

## **10. Medical management**

Medical management is mostly supportive and not definitive [61]. Pressure bandages may be helpful in reducing the corneal edema; however, it increases the risk of bullous rupture with vascularized corneal scar. A study reported that the use of bandage contact lens decreases the corneal edema but increases the corneal hypoxia, which delays the process of corneal healing and causes dense scar [62]. Topical hypertonic saline (5%) eye drops are used to treat acute corneal edema to enhance dryness of the cornea, and these eye drops work by pulling the water out of the cornea thorough an osmotic pattern. Additionally, the risk of epithelial breakage is decreased, which in turn decreases the risk of secondary infection. However, the patients experience a severe burning sensation and discomfort after using the eye drop. Hence, the efficacy of these eye drops is questionable. Topical corticosteroid eye drops can be used to decrease the inflammation and improve the endothelial functioning. These may also decrease the corneal neovascularization and symptomatic ocular discomfort. However, the topical corticosteroid eye drop usage is associated with an increased risk of steroid-induced glaucoma, cataract, and infectious keratitis over the ruptured bullae. Hence, it should be used cautiously with close follow-ups [61].

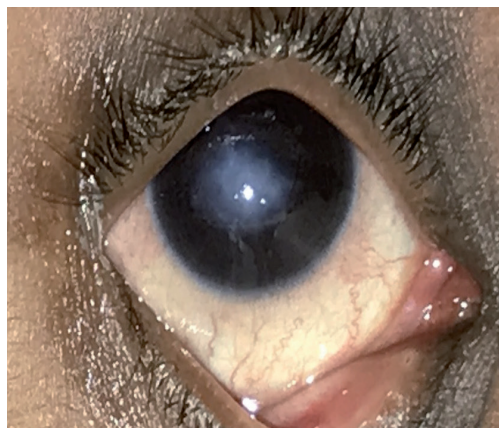
## **11. Surgical management**

Various modalities of surgical management have been mentioned in literature to augment the process of corneal healing. All the methods mentioned in literature are equally efficient, providing a favorable visual outcome and preventing the formation of the corneal vascularization.

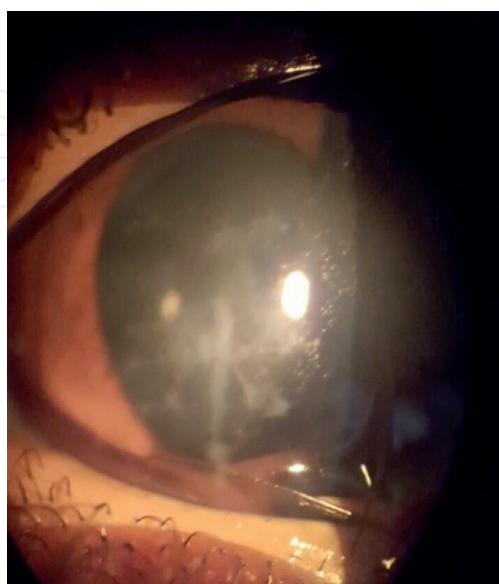
Primary surgical intention for acute hydrops is not to restore or confer a normal vision but hasten the resolution of corneal edema which eventually leads to a non-vascularised scar improving the prognosis for corneal transplantation.

Surgical modalities are as follows:

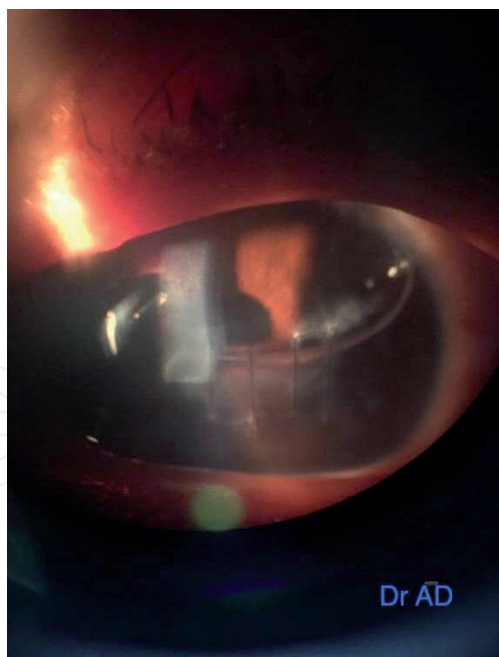
- Compressive sutures (**Figures 3 and 4**)
- Intracameral gas
- Combination of compressive sutures and intracameral gas (**Figure 5**)
- Deep anterior lamellar keratoplasty (DALK)
- Mini Descemet membrane endothelial keratoplasty (mini-DMEK)



**Figure 3.**  
*Showing resolution of corneal edema after application of compressive sutures.*



**Figure 4.**  
*Complete resolution of corneal edema with clear visualization of anterior segment structures.*



**Figure 5.**  
*Combination of compressive sutures with intracameral SF<sub>6</sub> gas (Dr.Devi Aiswarya Das).*

## 12. Intracameral gas

It is considered a treatment of choice for acute hydrops. Gas or air in an anterior chamber has 2 distinct advantages: first, it aids in the unrolling of the DM, and second, it provides compression of the DM to the swollen stroma [63, 64]. An injection of air was tried but it got absorbed in 3 days without giving enough tamponade to the DM. Hence, a nonexpansile mixture of the expansile gas with air is used to maintain the tamponade effect for a minimum period of 10 days. Sulfur hexafluoride (SF<sub>6</sub>) and perfluoropropane (C<sub>3</sub>F<sub>8</sub>) are commonly used by the corneal surgeons worldwide to produce a prolonged tamponade effect. SF<sub>6</sub> (0.1 mL, 20%) was used by Panda et al. in their study of 9 cases that showed only marginal improvement in 3 cases and the remaining 6 cases required reintroduction of the gas twice or more for complete resolution of the corneal edema [63]. Basu et al. performed a comparative study on patients with acute hydrops [64]. One arm of the patients was treated with 14% nonexpansile perfluoropropane (C<sub>3</sub>F<sub>8</sub>), whereas the other arm was treated with conventional medical therapy. A faster resolution of the corneal edema was observed in the eyes of patients who were surgically treated, and the improvement was statistically significant. All the patients were advised to rest in a supine position for a period of 10 days to augment the tamponade effect. Histopathological studies on resolved hydrops have confirmed that DM adherence to the stroma is superior with intracameral gas compared with that without any treatment. All authors in the referred studies have recommended the continuation of conventional medical therapy of hypertonic saline eye drops, corticosteroids, and antiglaucoma drugs in the postoperative period. Nevertheless, acute hydrops treated using intracameral gas poses a high risk of pupillary block glaucoma, Urrets-Zavala syndrome, stromal cleft, and accidental seepage of air bubbles into the cornea stroma resembles a 'fish egg' in appearance in a slit lamp experiment. Hence, an inferior surgical iridectomy is recommended to prevent any instances of acute congestive glaucoma. Moreover, the intracameral gas should be introduced along the iris plane and in a single bubble because faulty introduction of the gas may lead to the bursting of the bubble into multiple bubbles that will nullify the tamponade effect and cause accidental damage to the corneal endothelium and seepage of the bubbles into the stroma.

### **13. Compressive sutures**

Full-thickness corneal sutures involving the edematous part of the cornea have facilitated decrease in the corneal edema [30]. Here a 10–0 nylon suture is used to tamponade the Descemet membrane to corneal stroma. Initially a small paracentesis is created at the limbus of cornea followed by injection of intracameral pilocarpine to constrict the pupil. Viscoelastics are injected into the anterior chamber next to protect iris and crystalline lens. A 10–0 nylon suture is introduced at the junction of edematous and non-edematous cornea, the curved needle once enters the anterior chamber is taken out from the farthest end of the needle with a distance equivalent to the length of the needle and is tied over the corneal surface. The knot of a suture is buried into the cornea. Multiple sutures can be applied depending on the extent of the edema. The basic purpose of compressive sutures is not to oppose the torn DM ends but just to provide a support to the DM by bringing it near to the stroma. Once DM is opposed to the stromal endothelial cells, it starts pumping out a fluid from the stroma by active filtration and thereby helps in faster resolution of the corneal edema. Subudhi et al. demonstrated an excellent visual outcome associated with the use of compressive sutures alone in the management of acute hydrops; visual acuity of the patient improved from hand movements to 6/24 by the end of 2 months with a minimal scar at the center and no evidence of any corneal vascularization. Compressive sutures can be applied in a linear manner in case of small hydrops, but if hydrops is large enough to cover nearly all portions of the cornea, then a rectangular pattern involving all the quadrants can be applied. Pads and bandages can be given for a period of 24 hours to prevent any egress of fluid from the anterior chamber and its shallowing. Intracameral antibiotics can be given as prophylactic measures. These sutures stay for a period of 2 to 3 weeks; loosening of the sutures causes loss in the tamponade effect and should be removed in an operating room under strict aseptic precautions. Adverse effects observed are the shallow anterior chamber on Post-Operative Day 1; however, they got resolved in 24 hours without any further intervention. Nonetheless, these patients were advised to perform their routine activity after 5 days of rest. No patients were advised to have a mandatory supine position as in the treatment with intracameral gas injection.

### **14. Combination of intracameral gas and compressive sutures**

In a view of complications associated with the single use of the intracameral gas or compressive sutures, Rajaraman and associates suggested a combination of compressive sutures and intracameral gas to incorporate the advantages of both the procedures [64]. Compressive sutures prevent the seepage of air bubbles into the intrastromal space and the intracameral gas prevents the shallowing of the anterior chamber in an immediate postoperative period following the application of the full-thickness compressive sutures.

### **15. Anterior chamber paracentesis with thermokeratoplasty**

In this procedure paracentesis is done to reduce the intraocular pressure so that the tension of aqueous humor over Descemet membrane is eliminated subsequently thermokeratoplasty is done to induce stromal contraction thus outward expansion of stroma due to edematous cornea is reduced. Hence eventually hastening the resolution of acute hydrops [65].

## **16. DALK**

Anterior lamellar keratoplasty [66] in the pretext of acute hydrops is a difficult and complex procedure. Susan et al. recommended a modified DALK method for the treatment of acute hydrops. Small aliquots of air are injected into the stroma, immediately above the predescemetica layer and away from the site of the descemet rupture. Subsequently, a lamellar dissection with the help of a blunt crescent is performed carefully in the peripheral cornea, while avoiding the site of the DM tear initially, and then dissected at the center by slowly peeling the stroma. A donor cornea of the same size or 0.25 mm oversize is placed over the raw recipient corneal surface and anchored with the help of twelve or sixteen 10-0 nylon sutures. This averts the two-step procedure, which is normally adopted for acute hydrops, and thus, the visual rehabilitation is gained with a single procedure. However, because of edematous cornea, the risk of augmentation of the DM tear is increased and locating a correct plane for dissection becomes difficult for the surgeons. Therefore, surgeons are advised to become well-versed with anterior lamellar keratoplasty before advocating this procedure.

## **17. Mini-DMEK**

It is another [67] procedure described in literature. Bachmann and associates described a novel technique of replacing the torn DM with a well-circumscribed donor DM. In this technique, the peripheral torn DM is trimmed and stripped up to the center of the cornea. But the crux of the matter here is that all the maneuvers are performed with an intraoperative OCT-enabled microscope. The donor DM is prepared depending on the defect and is introduced into the anterior chamber with the help of the lens cartridge. Rolled DM enters into the anterior chamber and is unrolled with the help of 2 Sinsky hooks by pressing one end and ironing the other end of corneal lenticule over the anterior corneal surface. Determination of the correct orientation of the lenticule in the anterior chamber is essential for surgeons, which is not possible with a routine microscope because the visibility of the anterior chamber remains poor. With the dense corneal edema, this procedure is highly inappropriate in the routine clinical settings. Hence, approaching through the anterior surface of cornea rather than posterior corneal surface is preferable.

## **18. Conclusion**

Management of acute hydrops influences a long-term visual outcome. ASOCT provides a superior insight into the pathogenesis of acute hydrops. An early intervention is essential for preventing the vascularization of the corneal scar and eventually improving the prognosis of penetrating keratoplasty. Compression sutures, intra cameral gas, and a combination of both are efficient techniques described in the literature with a proven efficacy in hastening the resolution of the corneal edema. DALK and mini-DMEK are highly skillful procedures with questionable reproducibility by multiple surgeons. Prevention of acute hydrops should be a primary goal of all corneal surgeons in the future. An early identification and management of progressive keratoconus, prevention of eye rubbing, and avoidance of the professional sports may decrease the incidence of acute hydrops.

IntechOpen

IntechOpen

### **Author details**

Praveen Subudhi\*, Sweta Patro and Nageswar Rao Subudhi  
Ruby Eye Hospital, Berhampur, Ganjam, Odisha, India

\*Address all correspondence to: [subudhipraveen@gmail.com](mailto:subudhipraveen@gmail.com)

### **IntechOpen**

© 2020 The Author(s). Licensee IntechOpen. This chapter is distributed under the terms of the Creative Commons Attribution License (<http://creativecommons.org/licenses/by/3.0>), which permits unrestricted use, distribution, and reproduction in any medium, provided the original work is properly cited. 

## References

- [1] Barsam A, Petrushkin H, Brennan N, et al. Acute corneal hydrops in keratoconus: a national prospective study of incidence and management. *Eye (Lond)*. 2015; 29(4):469-474. doi:10.1038/eye.2014.333
- [2] Tuft SJ, Gregory WM, Buckley RJ. Acute corneal hydrops in keratoconus. *Ophthalmology*. 1994;101(10):1738-1744. doi:10.1016/s0161-6420(94)31110-9
- [3] AMSLER M. *Bull Soc Belge Ophtalmol*. 1961;129:331-354
- [4] Fan Gaskin JC, Good WR, Jordan CA, Patel DV, McGhee CNj. The Auckland keratoconus study: identifying predictors of acute corneal hydrops in keratoconus. *Clin Exp Optom*. 2013;96(2):208-213. doi:10.1111/cxo.12048
- [5] Grewal S, Laibson PR, Cohen EJ, Rapuano CJ. Acute hydrops in the corneal ectasias: associated factors and outcomes. *Trans Am Ophthalmol Soc*. 1999;97:187-203.
- [6] Krachmer JH, Feder RS, Belin MW. Keratoconus and related non-inflammatory corneal thinning disorders. *Surv Ophthalmol*. 1984;28: 293-322.
- [7] Brunsting LA, Reed WB, Blair HL. Occurrence of cataract and keratoconus with atopic dermatitis. *Arch Dermatol* 1955;72:237-41
- [8] Galin MA, Berger R. Atopy and keratoconus. *Am J Ophthalmol* 1958;45: 904-6
- [9] Spencer WH, Fisher JJ. The association of keratoconus with atopic dermatitis. *Am J Ophthalmol* 1959;47:332-4.
- [10] Bawazeer AM, Hodge WG, Lorimer B. Atopy and keratoconus: A multivariate analysis. *Br J Ophthalmol*. 2000;84:834-6
- [11] Weed KH, MacEwen CJ, Giles T, Low J, McGhee CN. The Dundee University Scottish Keratoconus study: Demographics, corneal signs, associated diseases, and eye rubbing.
- [12] Balasubramanian SA, Mohan S, Pye DC, Willcox MD. Proteases, proteolysis and inflammatory molecules in the tears of people with keratoconus. *Acta Ophthalmol*. 2012;90:e303-9.
- [13] Balasubramanian SA, Pye DC, Willcox MD. Effects of eye rubbing on the levels of protease, protease activity and cytokines in tears: Relevance in keratoconus. *Clin Exp Optom*. 2013;96:214-8.
- [14] Ben-Eli H, Erdinest N, Solomon A. Pathogenesis and complications of chronic eye rubbing in ocular allergy. *Curr Opin Allergy Clin Immunol*. 2019;19(5):526-534. doi:10.1097/ACI.0000000000000571
- [15] Barr JT, Zadnik K, Wilson BS, et al. Factors associated with corneal scarring in the Collaborative Longitudinal Evaluation of Keratoconus (CLEK) Study. *Cornea*. 2000;19(4):501-507. doi:10.1097/00003226-200007000-00020
- [16] di Martino E, Ali M, Inglehearn CF. Matrix metalloproteinases in keratoconus - too much of a good thing? *Exp Eye Res* 2019; 182:137-143.
- [17] Masterton SAM. Mechanobiology of the corneal epithelium. *Exp Eye Res* 2018; 177:122-129
- [18] Korb DR, Finnemor VM, Herman JP. Apical changes and scarring in keratoconus as related to contact lens fitting techniques. *J Am Optom Assoc* 1982; 53:199-205.

- [19] Sharma R, Titiyal JS, Prakash G, Sharma N, Tandon R, Vajpayee RB. Clinical profile and risk factors for keratoplasty and development of hydrops in north Indian patients with keratoconus. *Cornea*. 2009;28:367-70.
- [20] Stoiber J, Muss W, Ruckhofer J, Grabner G. Acute keratoconus with perforation in a patient with Down's syndrome. *Br J Ophthalmol*. 2003;87:120.
- [21] Robertson I. Keratoconus and the Ehlers-Danlos syndrome: a new aspect of keratoconus. *Med J Aust*. 1975;1(18):571-573.
- [22] Tsang SH, Sharma T. Leber Congenital Amaurosis. *AdvExp Med Biol*. 2018;1085:131-137. doi:10.1007/978-3-319-95046-4\_26
- [23] Freedman J, Gombos GM. Bilateral macular coloboma, keratoconus, and retinitis pigmentosa. *Ann Ophthalmol*. 1971;3(6):
- [24] Idowu OO, Ashraf DC, Vagefi MR, Kersten RC, Winn BJ. Floppy eyelid syndrome: ocular and systemic associations. *Curr Opin Ophthalmol*. 2019;30(6):513-524. doi:10.1097/ICU.0000000000000617
- [25] Bilgihan K, Hondur A, Sul S, Ozturk S. Pregnancy-induced progression of keratoconus. *Cornea*. 2011;30(9):991-994. doi:10.1097/ICO.0b013e3182068adc
- [26] Fan Gaskin JC, Good WR, Jordan CA, Patel DV, McGhee CNj. The Auckland keratoconus study: identifying predictors of acute corneal hydrops in keratoconus. *Clin Exp Optom*. 2013;96(2):208-213. doi:10.1111/cxo.12048
- [27] Choi JA, Kim MS. Progression of keratoconus by longitudinal assessment with corneal topography. *Invest Ophthalmol Vis Sci*. 2012;53(2):927-935. Published 2012 Feb 23. doi:10.1167/iops.11-8118
- [28] Shajari M, Steinwender G, Herrmann K, et al. Evaluation of keratoconus progression. *Br J Ophthalmol*. 2019;103(4):551-557. doi:10.1136/bjophthalmol-2017-311651
- [29] Bron AJ. Keratoconus. *Cornea*. 1988;7(3):163-169.
- [30] Subudhi P, Khan Z, Subudhi BNR, Sitaram S. To show the efficacy of compressive sutures alone in the management of acute hydrops in a keratoconus patient. *BMJ Case Rep*. 2017;2017:bcr2016218843. Published 2017 May 4. doi:10.1136/bcr-2016-218843
- [31] Laing RA, Sandstrom MM, Berrospi AR, Leibowitz HM. The human corneal endothelium in keratoconus: A specular microscopic study. *Arch Ophthalmol*. 1979;97(10):1867-1869. doi:10.1001/archopht.1979.01020020315005
- [32] Cameron JA, Al-Rajhi AA, Badr IA. Corneal ectasia in vernal keratoconjunctivitis. *Ophthalmology*. 1989;96(11):1615-1623.
- [33] Taboureaux E, Berthout A, Turut P, Milazzo S. Dégénérescence marginale pellucide compliquée d'un hydrops cornéenaigusponané [Acute spontaneous corneal hydrops in a patient with pellucid marginal corneal degeneration]. *J Fr Ophthalmol*. 2006;29(6):e13. doi:10.1016/s0181-5512(06)73830-x
- [34] Rychener RO, Kirby DB. Acute hydrops of the corneal complicating keratoconus. *Arch Ophthalmol* 1940; 24(2): 326-343.
- [35] Tuft SJ, Gregory WM, Buckley RJ. Acute corneal hydrops in keratoconus. *Ophthalmology* 1994;101(10):1738-1744.
- [36] Fan Gaskin JC, Good WR, Jordan CA, Patel DV, McGhee C. The Auckland keratoconus study: identifying predictors of acute corneal hydrops

in keratoconus. *ClinExpOptom* 2013;96(2):208-213.

[37] Zadnik K, Barr JT, Gordon MO, Edrington TB. Biomicroscopic signs and disease severity in keratoconus. Collaborative Longitudinal Evaluation of Keratoconus (CLEK) Study Group. *Cornea* 1996; 15: 139-146

[38] Grewal S, Laibson PR, Cohen EJ, Rapuano CJ. Acute hydrops in the corneal ectasias: associated factors and outcomes. *Trans Am Ophthalmol Soc* 1999; 97: 187-198; discussion 198-203.

[39] Rowson NJ, Dart JK, Buckley RJ. Corneal neovascularisation in acute hydrops. *Eye* 1992;6(4):404-406.

[40] Fuentes E, Sandali O, El Sanharawi M, et al. Anatomic Predictive Factors of Acute Corneal Hydrops in Keratoconus: An Optical Coherence Tomography Study. *Ophthalmology*. 2015;122(8):1653-1659. doi:10.1016/j.ophtha.2015.04.031

[41] Lockington D, Fan Gaskin JC, McGhee CN, Patel DV. A prospective study of acute corneal hydrops by in vivo confocal microscopy in a New Zealand population with keratoconus. *Br J Ophthalmol*. 2014;98(9):1296-1302. doi:10.1136/bjophthalmol-2013-304145

[42] Basu, Sayan MS; Vaddavalli, Pravin K. MS; Vemuganti, Geeta K. MD; Hasnat Ali, Md MBA; Murthy, Somasheila I. MS Anterior Segment Optical Coherence Tomography Features of Acute Corneal Hydrops, *Cornea*: May 2012 - Volume 31 - Issue 5 - p 479-485 doi: 10.1097/ICO.0b013e318223988e

[43] Kallel S, Tahiri Joutei Hassani R, Liang H, Baudouin C, Labbé A. Apport de l'OCT de segment antérieur « en face » dans le kératocône aigu ["En face" anterior segment optical coherence tomography findings in acute corneal hydrops]. *J Fr Ophtalmol*. 2014;37(8):605-612

[44] Margo CE, Mosteller MW. Corneal pseudocyst following acute hydrops. *Br J Ophthalmol*. 1987;71(5):359-360. doi:10.1136/bjo.71.5.359

[45] Sharma N, Mannan R, Jhanji V, et al. Ultrasound biomicroscopy-guided assessment of acute corneal hydrops. *Ophthalmology* 2011;118(11):2166-2171. 22.

[46] Feder RS, Wilhelmus KR, Vold SD, O'Grady RB. Intrastromal clefts in keratoconus patients with hydrops. *Am J Ophthalmol* 1998;126(1):9-16.

[47] Labbé A, Kallel S, Denoyer A, Dupas B, Baudouin C. Imagerie de la cornée [Corneal imaging]. *J Fr Ophtalmol*. 2012;35(8):628-634. doi:10.1016/j.jfo.2012.02.008

[48] Cruzat A, Qazi Y, Hamrah P. In Vivo Confocal Microscopy of Corneal Nerves in Health and Disease. *Ocul Surf*. 2017;15(1):15-47. doi:10.1016/j.jtos.2016.09.004

[49] Fuentes E, Sandali O, El Sanharawi M, Basli E, Hamiche T, Goemaere I, Borderie V, Bouheraoua N, Laroche L. Anatomic Predictive Factors of Acute Corneal Hydrops in Keratoconus: An Optical Coherence Tomography Study. *Ophthalmology*. 2015 Aug;122(8):1653-9. doi: 10.1016/j.ophtha.2015.04.031. Epub 2015 Jun 2. PMID: 26045363.

[50] Rubsamen PE, McLeish WM. Keratoconus with acute hydrops and perforation. Brief case report. *Cornea*. 1991 Jan;10(1):83-4. PMID: 2019114

[51] .Sharif Z, Sharif W. Corneal neovascularization: updates on pathophysiology, investigations & management. *Rom J Ophthalmol*. 2019 Jan-Mar;63(1):15-22. PMID: 31198893; PMCID: PMC6531773.

[52] Gonçalves ED, Campos M, Paris F, Gomes JA, Farias CC.

- Ceratopatiabolhosa: etiopatogênese e tratamento [Bullous keratopathy: etiopathogenesis and treatment]. *Arq Bras Oftalmol*. 2008 Nov-Dec;71(6 Suppl):61-4. Portuguese. doi: 10.1590/s0004-27492008000700012. PMID: 19274413
- [53] Henry CR, Flynn HW Jr, Miller D, Forster RK, Alfonso EC. Infectious keratitis progressing to endophthalmitis: a 15-year study of microbiology, associated factors, and clinical outcomes. *Ophthalmology*. 2012 Dec;119(12):2443-9. doi: 10.1016/j.ophtla.2012.06.030. Epub 2012 Aug 1. PMID: 22858123; PMCID: PMC3490005
- [54] Connon CJ, Meek KM. The structure and swelling of corneal scar tissue in penetrating full-thickness wounds. *Cornea*. 2004 Mar;23(2):165-71. doi: 10.1097/00003226-200403000-00010. PMID: 15075886
- [55] Pandey N, Chandrakar AK, Garg ML, Patel SS. Calotropisprocera-induced keratitis. *Indian J Ophthalmol*. 2009 Jan-Feb;57(1):58-60. doi: 10.4103/0301-4738.44492. PMID: 19075415; PMCID: PMC2661522
- [56] Arenas E, Mieth A, Muñoz D. Combined intrastromal injection of ganciclovir and depot betamethasone for the management of nummular keratitis: Case series. *Arch SocEspOftalmol*. 2019 Jul;94(7):347-351. English, Spanish. doi: 10.1016/j.oftal.2019.01.009. Epub 2019 Mar 4. PMID: 30846248
- [57] Messmer EM. Keratitis - infektiösoderautoimmun? [Keratitis - Infectious or Autoimmune?]. *KlinMonblAugenheilkd*. 2016 Jul;233(7):808-12. German. doi: 10.1055/s-0042-105155. Epub 2016 Jul 28. PMID: 27468096
- [58] Faith SC, Durrani AF, Jhanji V. Cytomegalovirus keratitis. *Curr Opin Ophthalmol*. 2018 Jul;29(4):373-377. doi: 10.1097/ICU.0000000000000481. PMID: 29708927
- [59] Zhuang M, Fan W, Xie P, Yuan ST, Liu QH, Zhao C. Evaluation of the safety and quality of day-case cataract surgery based on 4151 cases. *Int J Ophthalmol*. 2019 Feb 18;12(2):291-295. doi: 10.18240/ijo.2019.02.17. PMID: 30809487; PMCID: PMC6376245
- [60] Yuen HK, Rassier CE, Jardeleza MS, Green WR, de la Cruz Z, Stark WJ, Gottsch JD. A morphologic study of Fuchs dystrophy and bullous keratopathy. *Cornea*. 2005 Apr;24(3):319-27. doi: 10.1097/01.ico.0000148288.53323.b2. PMID: 15778606.
- [61] Grewal S, Laibson PR, Cohen EJ, Rapuano CJ. Acute hydrops in the corneal ectasias: associated factors and outcomes. *Trans Am Ophthalmol Soc* 1999;97:187-198
- [62] Carter JB, Jones DB, Wilhelmus KR. Acute hydrops in pellucid marginal corneal degeneration. *Am J Ophthalmol* 1989; 107: 167-170
- [63] Panda A, Aggarwal A, Madhavi P, et al. Management of acute corneal hydrops secondary to keratoconus with intracameral injection of sulfur hexafluoride (SF6). *Cornea* 2007;26(9): 1067-1069.
- [64] Basu S, Vaddavalli PK, Ramappa M, Shah S, Murthy SI, Sangwan VS. Intracameral perfluoropropane gas in the treatment of acute corneal hydrops. *Ophthalmology* 2011;118(5):934-939.
- [65] Li S, Liu M, Wang Q, Wang T, Shi W. Lamellar keratoplasty following thermokeratoplasty in the treatment of acute corneal hydrops. *Am J Ophthalmol*. 2014 Jul;158(1):26-31.e1. doi: 10.1016/j.ajo.2014.03.011. Epub 2014 Mar 31. PMID: 24699158.
- [66] Jacob S, Narasimhan S, Agarwal A, Sambath J, Umamaheshwari G,

Saijimol AI. Primary Modified  
Predescemet Deep Anterior Lamellar  
Keratoplasty in Acute Corneal Hydrops.  
*Cornea*. 2018 Oct;37(10):1328-1333.  
doi: 10.1097/ICO.0000000000001693.  
PMID: 30001263.

[67] Bachmann B, Händel A,  
Siebelmann S, Matthaei M, Cursiefen C.  
Mini-Descemet Membrane Endothelial  
Keratoplasty for the Early Treatment of  
Acute Corneal Hydrops in Keratoconus.  
*Cornea*. 2019 Aug;38(8):1043-1048.  
doi: 10.1097/ICO.0000000000002001.  
PMID: 31276462