

We are IntechOpen, the world's leading publisher of Open Access books Built by scientists, for scientists

6,900

Open access books available

186,000

International authors and editors

200M

Downloads

Our authors are among the

154

Countries delivered to

TOP 1%

most cited scientists

12.2%

Contributors from top 500 universities



WEB OF SCIENCE™

Selection of our books indexed in the Book Citation Index
in Web of Science™ Core Collection (BKCI)

Interested in publishing with us?
Contact book.department@intechopen.com

Numbers displayed above are based on latest data collected.
For more information visit www.intechopen.com



Interventional Treatment of Endometriosis

Yang Xiaomin, Han Jun, Feng Pin and Yang Xiaojun

Abstract

Patients with endometriosis and adenomyosis naturally improve after menopause. Therefore, some patients only need to relieve symptoms, especially those near menopause, and they prefer to be treated by conservative methods. We summarized several minimally invasive interventional methods: uterine artery intervention (Uterine artery embolization, UAE), nerve intervention (upper and lower abdominal plexus block, SHPB), ultrasound intervention (puncture sclerotherapy; high intensity focused ultrasound treatment).

Keywords: superior hypogastric plexus block, uterine artery embolization, ultrasound interventional

1. Introduction

Adenomyosis and endometriosis are common gynecological diseases. Most of the patients are primipara aged 35–50 years old. About half of the patients have hysteromyoma at the same time. Clinical manifestations are dysmenorrhea, menstrual disorders, and enlargement of the uterine body. Secondary dysmenorrhea and Menorrhagia are the most typical symptoms of this disease [1].

The main symptom of endometriosis is progressive secondary dysmenorrhea which severely affects patient's quality of life. Menorrhagia caused by adenomyosis may lead to severe anemia in some patients. The treatment is often personalized and optimized according to disease severity and patient age. At present, there are several non-surgical conservative treatments for secondary dysmenorrhea and menorrhagia.

2. Minimally invasive interventional therapies

2.1 Uterine artery embolization (UAE)

UAE is the treatment of symptomatic uterine fibroids by embolizing the vascular network of the lesion after reaching the uterine artery through the intervention, which blocks the blood supply of the lesion [2]. It was first reported in 1995 by Ravina et al. This technique has the characteristics of uterus preservation, easy operation, rapid postoperative recovery, and less postoperative complications and has become one of the effective minimally invasive alternatives in the treatment of symptomatic uterine adenomyosis. The American College of Obstetricians and Gynecologists (ACOG) has recommended UAE as a safe and effective treatment

option for patients with uterine fibroids who wish to preserve the uterus (level A evidence) [3]. Therefore, UAE has been widely used in the treatment of uterine leiomyoma, and then UAE has achieved significant effect in the treatment of pain and anemia symptoms of adenomyosis, but there is controversy in the use of adenomyosis, which may recur after a period of time due to symptoms [4]. In recent years, more and more literatures show that UAE is effective in the treatment of adenomyosis, especially in the short term [5–7]. UAE treatment alleviated the symptoms of adenomyosis and made most adenomyosis patients retain the uterus [8].

2.1.1 Rationale for UAE in uterine adenomyosis

Adenomyosis is a diffuse or local proliferation of surrounding smooth muscle and fibrous connective tissue caused by glandular and stromal invasion of the basal layer of the endometrium, and the ectopic endometrium is in the proliferative phase due to its origin from the basal layer of the endometrium. The above lesions have a relatively rich network of new blood vessels and poor tolerance to ischemia and hypoxia, but the normal uterine tissue has a rich vascular traffic network, and the normal uterus has a strong tolerance to ischemia and hypoxia. Embolization of the vascular network of the lesion through the uterine artery blocks the blood supply of the lesion (after), resulting in ischemic necrosis of the lesion, followed by dissolution and absorption, and finally the lesion shrinks or even disappears, while the reduction of the lesion reduces the uterine volume and uterine cavity area, which can effectively reduce the menstrual volume, so as to achieve the purpose of relieving symptoms.

2.1.2 Indications and contraindications of UAE

2.1.2.1 Indications

(1) Patients are willing to undergo UAE treatment and understand the relevant possible complications. (2) Symptomatic adenomyosis without fertility requirements, including dysmenorrhea and heavy menstrual bleeding. (3) Patients with uterine adenomyosis who fail non-surgical treatment or refuse surgery or have a history of multiple surgeries and are difficult to treat by reoperation. (4) Patients with pelvic endometriosis (including ovarian endometrioma) at the same time, need to inform UAE is ineffective for the above disease, in patients with full understanding and requirements, the option of UAE treatment of adenomyosis combined with laparoscopic treatment of pelvic endometriosis (including ovarian endometrioma). (5) Patients with symptomatic uterine adenomyosis who have fertility requirements should use UAE with caution. In terms of indications, we have repeatedly stressed that UAE should be carefully selected for patients with adenomyosis who have fertility requirements. The reason is that the medium- and long-term effects of UAE on endometrial microcirculation or intrauterine environment is still uncertain. UAE needs to be performed under X-ray. The skill level of the operator and the vascular condition of the patient are linear, which will affect the amount of radiation received by the patient, and the effect of radiation on the fertility rate is also uncertain. This kind of research is rare, because it involves ethical review and cannot be passed.

2.1.2.2 Contraindications

(1) Pregnant women; (2) combined with genitourinary system infection; (3) known or suspected gynecological malignant tumors coexist; (4) general contraindications of interventional embolization therapy, such as contrast agent allergy,

puncture site skin infection, renal insufficiency, or severe immunosuppression of the body; and (5) patients with uterine fibroids or adenomyosis whose lesions are mainly supplied by the ovarian artery [9].

2.1.3 Preoperative evaluation of UAE

2.1.3.1 History and evaluation

These include detailed gynecological history, such as menstrual history, previous pregnancy, fertility plan, gynecological disease, and previous pelvic surgery, medical history to identify various comorbidities, and previous use of anticoagulants. Adequate informed consent is required, and informed consent for surgical procedures is signed to understand the advantages and disadvantages of treatment, expected effects, and potential complications.

2.1.3.2 Evaluation of dysmenorrhea

A comprehensive assessment of the degree of recent and long-term dysmenorrhea in patients with adenomyosis was performed using the visual analog scale (VAS) for pain and the chronic pain rating scale. The clinical evaluation standard of dysmenorrhea symptoms: the degree of dysmenorrhea was evaluated by chronic pain rating scale before and after operation. We used VAS to evaluate the degree of dysmenorrhea at each follow-up time point, and VAS weighted calculation method to evaluate the efficacy of UAE in the treatment of dysmenorrhea in adenomyosis. Effective: the postoperative dysmenorrhea disappeared or the postoperative dysmenorrhea symptoms existed, but the score of chronic pain rating scale decreased by two or more levels, (1) cured: $(\text{preoperative VAS score} - \text{postoperative VAS score}) / \text{preoperative VAS score} \times 100\% \geq 75\%$; (2) effective: $(\text{preoperative VAS score} - \text{postoperative VAS score}) / \text{preoperative VAS score} \times 100\% \geq 50\%$ and $< 75\%$; (3) effective: $(\text{preoperative VAS score} - \text{postoperative VAS score}) / \text{preoperative VAS score} \times 100\% \geq 25\%$ and $< 50\%$. No effect: the symptoms of dysmenorrhea after operation exist, the score of chronic pain rating scale is only reduced by one grade, or the dysmenorrhea is not relieved or even continues to increase, or $(\text{preoperative VAS score} - \text{postoperative VAS score}) / \text{preoperative VAS score} \times 100\% < 25\%$.

2.1.3.3 Clinical evaluation criteria for menstrual volume

Menorrhagia was defined as menstrual flow >80 ml per menstrual cycle (more than 20 sanitary napkins were used); oligomenorrhea was defined as menstrual flow <5 ml per menstrual cycle (less than 1 sanitary napkin was used). Clinical evaluation standard of menstrual volume: subjective symptoms of patients. Significant effect: after UAE treatment, menstrual volume decreased significantly. Effective: after UAE treatment, menstrual volume decreased. No effect: after UAE treatment, the menstrual volume was not significantly reduced.

2.1.3.4 Examination before treatment

In addition to routine preoperative examinations, sex hormone levels were measured to assess ovarian function. Because the influence of uterine artery embolization on ovarian function is uncertain. Blood CA125 levels were measured for follow-up, CA125 was used as a follow-up index because we found that most patients with adenomyosis have different degrees of increase in this index.

The reason is that the serum CA125 antigen of patients with this disease is secreted by ectopic endometrium between muscles, and CA125 molecules on the surface of endometrial cells are released into the blood circulation, which increases the concentration of CA125 antigen in the blood. Several studies [10] also show that serum CA125 assay is of great assistance to the diagnosis of uterine adenomyosis. Blood CA125 levels were measured for follow-up. Venous color Doppler ultrasonography of both lower limbs is particularly important to assess the presence or absence of preoperative thrombosis.

2.1.3.5 Imaging evaluation

MRI examination, ultrasonography, CT, and other assessments, which perform the planning of the surgical approach and reduce the blindness of the procedure, can improve the success rate of surgery. By contrast, most studies recommend MRI as the main preoperative evaluation method.

2.1.4 Operating process of UAE

The patient was placed in supine position. Routine disinfection and draping were performed. After local anesthesia, the right femoral artery was punctured by Seldinger method. The catheter sheath was placed. A 5F Cobra catheter was inserted into the opening of bilateral uterine arteries for DSA. The dosage of contrast medium on each side was 6 ml and the flow rate was 2 ml/s. The uterus was significantly enlarged, the uterine artery was significantly thickened and tortuous, and the staining in the uterus was thickened. If there was uterine fibroids, the angiography showed the presence of “holding ball” abnormal vascular mass. The 3F microcatheter was used to superselect to the distal end of the main uterine artery, avoiding the ovarian artery. The uterine artery was embolized with embolic agent. The DSA was reexamined. The abnormal staining of the uterus disappeared, and the main uterine artery was retained. The operation could be ended.

2.1.4.1 Selection of embolic agent

There are many embolization agents available for UAE. Generally, particle embolization agents are selected. Generally, they can be divided into absorbable and non-absorbable. Absorbable embolization agents are represented by gelatin sponge particles, and non-absorbable embolization agents are represented by polyvinyl alcohol embolization microspheres (embosphere). However, the commonly used embolic agents of other organs, such as steel ring, absolute ethanol, and super-liquid iodized oil, are not recommended for use in UAE. For the selection of embolic agent particle size, “sandwich embolization” should be used for embolization of uterine adenomyosis due to the small inner vascular network. First, particles with a diameter of 100–300 μm are selected for embolization of the inner vascular network, particles with a diameter of 300–500 μm are used for embolization of the outer vascular network, and finally particles with a diameter of 500–700 μm are used for trunk embolization [11]. The effect of arterial embolization is inversely proportional to the embolic agent particle size.

2.1.4.2 Degree of embolism

Embolization is divided into two types: complete embolization and incomplete embolization. Patients with uterine adenomyosis require complete embolization of the inner vascular network of the uterus, and in DSA, imaging findings show complete disappearance of focal staining, visualization of the main trunk of the uterine artery, retention of contrast agent, and no clearance of contrast agent in five cardiac cycles.

2.1.5 Postoperative management of UAE

For hemostasis by compression at the puncture site, the lower limbs were immobilized for 6 h. If a vascular sealer was used, the immobilization time could be shortened. After operation, it is necessary to observe the skin color and skin temperature of lower limbs, ask the dorsalis pedis artery pulse and mark it, and make regular observation to prevent thrombosis. Antibiotics were not routinely applied postoperatively.

2.1.6 Complications of UAE

2.1.6.1 Intraoperative complications

1. Local bleeding or hematoma: bleeding or hematoma at the puncture site is a more common complication, and severe cases can cause large pelvic retroperitoneal hematoma. Hemostasis by compression was given for symptomatic treatment.
2. Arterial spasm: repeated stimulation of blood vessels or long operation time during surgery may cause arterial spasm, cause limb numbness and pain, affect intraoperative operation, and in severe cases, lead to limb ischemic necrosis. Analgesic drugs can be used to relieve pain and intraoperative application of 2% lidocaine 5 ml local intra-arterial injection.
3. Arterial puncture injury: although arterial puncture injury caused by improper operation or traumatic operation is rare during the operation, because the pelvic artery is located in the retroperitoneum, once it occurs, it will be difficult to compress and stop bleeding, which can form retroperitoneal hematoma. Failure to timely detect it will threaten the patient's life and require emergency laparotomy for hemostasis. Therefore, intraoperative manipulation should be gentle, and the direction of the vessel should be identified when resistance is encountered, homeopathic.

2.1.6.2 Postoperative complications

1. Pain: almost all patients experience pain after surgery. At present, it is believed that pain is associated with ischemia of the lesion and uterus after UAE. The degree of pain varies from mild to severe colic. Analgesic methods depend on the severity of pain and preemptive non-steroidal anti-inflammatory drugs, patient-controlled analgesia, oral or parenteral administration of opioids using analgesic pumps are optional. The duration of pain varies and is generally gradually relieved 2 to 5 days after surgery. If the pain is more than 1 week and more severe, we should be alert to the possibility of serious complications such as secondary infection and thrombosis.
2. Post-embolization syndrome: post-embolization syndrome is characterized by pelvic pain, nausea, vomiting, fever, fatigue, myalgia, discomfort, and leukocytosis. Most of them occurred within 24 h after surgery and gradually improved within 7 days. It is a common postoperative complication. Postoperative fever is generally no higher than 38°C, which is postoperative absorption fever, and antibiotic treatment is usually not required.
3. Arterial rupture or arterial dissection: it is a serious complication and requires surgical repair.

4. **Misthrombosis of blood vessels:** because the anterior trunk of the internal iliac artery not only gives off the uterine artery but also the bladder artery, vaginal artery, and internal pudendal artery, when the iliac artery and the above arteries are misembolized, complications such as labia majora and minora necrosis and local bladder necrosis may occur.
5. **Infection:** the operation of UAE is a type I incision, and incision infection is rare, mainly necrosis of the lesion after embolization, forming aseptic inflammation. After uterine artery interventional therapy, uterine ischemic focus atrophied and vaginal secretion increased. At that time, the uterus is prone to secondary bacterial infection, and in the worst case, hysterectomy is needed to control sepsis. Intrauterine adhesions can be seen in long-term complications.
6. **Allergic reactions or rashes:** anti-allergic treatment may be given.
7. **Bloody vaginal discharge:** usually within 2 weeks, a very small number may also last for months.
8. **Oligomenorrhea:** after surgery, some patients have partial endometrial necrosis due to uterine artery vascular network embolization, and menstrual volume may be significantly reduced, but hormone examination shows no significant abnormality. If there is no fertility requirement, this part of patients can be observed without treatment.
9. **Amenorrhea:** it is a long-term complication of UAE and is divided into ovarian amenorrhea and uterine amenorrhea. Ovarian amenorrhea is mainly caused by ovarian ischemia and necrosis due to blocking of blood flow in the arteries supplying the ovary, such as the ovarian branch of the uterine artery or the ovarian artery and amenorrhea due to ovarian failure, requiring long-term oral administration of hormone drugs to maintain the level of hormones in the body. Uterine amenorrhea is caused by endometrial ischemic necrosis and impaired endometrial growth, which does not affect hormone secretion and can be observed, but the patient is unable to have children.
10. **Others:** other serious complications are rare. The incidence of venous thromboembolic complications is approximately 0.4%. Rare complications such as fatal sepsis, femoral nerve injury, iliac artery embolism, uterine ischemic infarction, labia majora and minora necrosis, local bladder necrosis, vesico-uterine fistula, uterine wall injury, and necrosis of both toes or heels due to extravasation of embolic agents associated with the UAE procedure also occur. Readmission was required in 2.4 to 3.5% of patients and unplanned surgery in 1.0 to 2.5% of patients. However, overall mortality from UAE was not increased compared with hysterectomy [9].

2.1.7 Follow-up time and efficacy evaluation after UAE treatment

2.1.7.1 Follow-up time

After UAE treatment, reexamination assessment is required at 1, 3, and 6 months, and once a year thereafter. The contents of follow-up included change of lesion size, menstruation, sex hormone level, change of dysmenorrhea degree, and CA125 level in patients with adenomyosis.

2.1.7.2 Clinical efficacy evaluation

A large number of clinical trial data [11, 12] showed that 97–100% of patients could tolerate and complete the operation, 77–97.4% of patients had improvement of dysmenorrhea symptoms, and amenorrhea happens occasionally. About 20% of patients need operation or second UAE because of unsatisfactory effect or recurrence of symptoms.

2.2 Nerve intervention: The superior hypogastric plexus block

2.2.1 Rationale for SHPB in uterine adenomyosis

The superior hypogastric plexus consists of the lumbar splanchnic nerves (from the L3–L4 sympathetic ganglia) and the abdominal aortic plexus, which distributes its fibers to the anterior sacral promontory of the L5 vertebral body below the iliac bifurcation of the abdominal aorta [13]. The superior and inferior ventral nerve block was derived from the sacral neurotomy 20 years ago. Under the guidance of CT, the puncture needle was placed around the superior and inferior ventral nerve in front of the cone, and anhydrous alcohol or other nerve blockers were used to block the nerve so that local pain cannot be transmitted back to the brain through the nerve, to achieve the purpose of analgesia [14].

2.2.2 Indications and contraindications of SHPB

2.2.2.1 Indications

(i) An ultrasonogram indicated uterine adenomyosis, with a slight increase of the cancer antigen (CA)-125 or (ii) there was a history of relevant endometriosis operation along with the absence of surgical indications for immediate reoperation. Patients who satisfied either criterion were then included if they met all the following additional criteria: (iii) periodic hypogastric pain during menstruation, with a visual analog scale (VAS) score >6 (severe); (iv) age >40 years; (v) absence of menorrhagia and significant pelvic mass; and (vi) absence of dysmenorrhea due to intrauterine devices. Among the patients who satisfied these criteria, we enrolled those who provided written informed consent to undergo an operation.

2.2.2.2 Contraindications

The contraindications were as follows: (i) Nulliparous; (ii) Complications due to other pelvic diseases; (iii) Acute appendicitis, acute pelvic inflammatory disease; (iv) Deep endometriosis; (v) Allergic to alcohol or iohexol.

2.2.3 Operating process of SHPB

The patient was asked to lie on the CT table with a suitable pillow under the abdomen. After confirming the absence of any contraindications to a neural block, an intravenous infusion channel was opened. CT scans are used to confirm the location of the L5 and S1 intervertebral spaces, which are the target regions for puncture. Then, the coronal CT scan is obtained by taking the puncture space as the midline, including the upper, lower and central sections with a thickness of 3 mm. Select the best puncture section from CT images and plan the puncture path. The anterolateral margin of the lumbar 5 was the left margin and the anterior margin of the psoas major was the right margin. After planning the puncture route and bilateral puncture points, the angle and depth of puncture points were measured with CT ruler. According to the

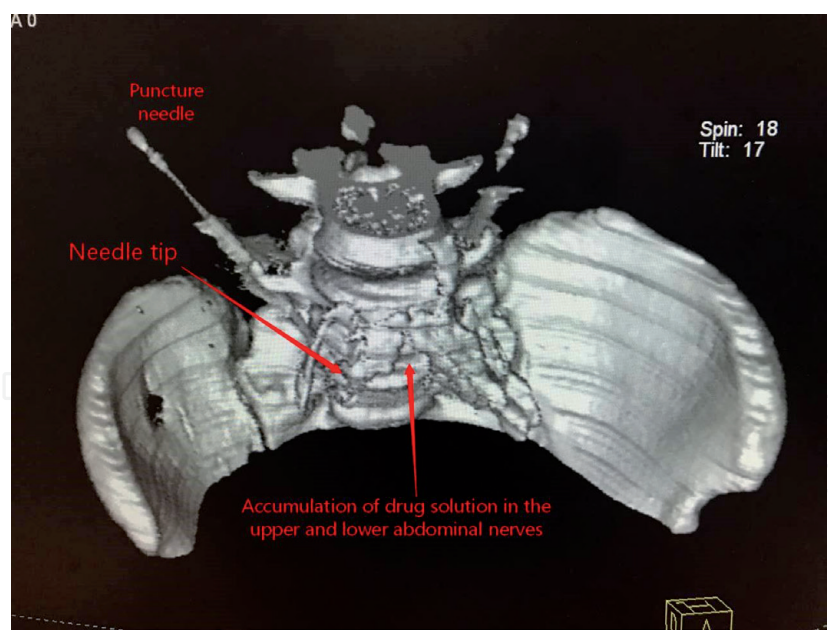


Figure 1.
The upper and lower abdominal nerve block was performed by puncture and injection (Three-dimensional reconstruction by CT).

measurement results, place the puncture needle to the target (**Figure 1**). A solution of 2% lidocaine containing iohexol (a contrast agent) was injected, and its distribution was observed on a CT rescans. An injection site is determined as appropriate if: (i) the lidocaine-iohexol solution is distributed along the anteromedial margin of the psoas major muscle and the anterior vertebral body (**Figure 2**) and (ii) a loss of sensation bilaterally in the lower limbs without dyskinesia is observed after 15 min. With the injection site confirmed, a contrast medium of dehydrated alcohol solution (4 mL) containing 3% iohexol (0.5 mL) is injected bilaterally to achieve a neurolytic block of the superior hypogastric plexus. This is followed by repeated CT, and three-dimensional

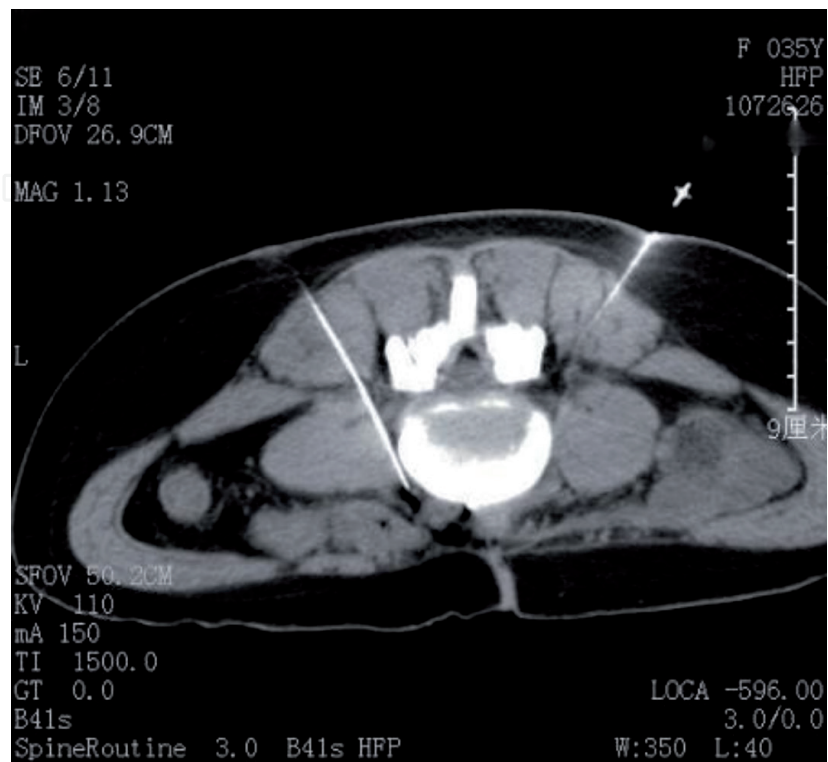

Figure 2.
Upper and lower abdominal nerve block by puncture injection.

reconstruction to observe the distribution of the dehydrated rate, blood pressure. At the same time blood oxygen saturation level is recorded. Any complications are also recorded.

2.2.4 Follow-up time and efficacy evaluation after SHPB treatment

At present, there is no reliable follow-up data of big data, but according to the existing experience, the effective rate is 70%, the duration is 1–3 years, and there is no serious complications related to nerve block. Sacral neurotomy as the predecessor of nerve block treatment appeared 20 years ago, but the technology of nerve block by drugs is still very young. The improvement methods can be as follows: to study the characteristics and efficacy of different nerve blockers, to improve the puncture approach and the position of the blocking point, etc. [15]. SHPB is a new way of treatment. There are no data about future fertility. The upper and lower abdominal nerves are the proximal part of sacral nerves. The same reason is that there are few data at present, which cannot explain the effect of nerve block on fertility, sexual function and urination function.

2.3 Ultrasound interventional therapy for endometriosis

2.3.1 Pelvic endometriosis

Ultrasound-guided puncture sclerotherapy [16], sclerosing agent selection includes anhydrous ethanol, lauryl alcohol, etc. Anhydrous ethanol is less used due to easy to cause low fever, sharp pain, allergies and drunk-like reactions and other adverse reactions poly(lauryl alcohol), the scientific name of polyoxyethylene lauryl alcohol ether, is called polydocanol in Europe. After the injection into the cyst, the protein of the cell will be precipitated quickly, the double molecular layer of the cell wall will be destroyed, the epithelial cells of the cyst wall will be necrotic, the secretion of the fluid of the cell will be inhibited, and the aseptic inflammation will be produced to make the fibrosis of the cyst wall, so as to achieve the purpose of curing the cyst. The drug is widely used. Before the operation, the number and nature of the cyst were confirmed. Under the guidance of real-time ultrasound positioning, the puncture needle entered the center of the cyst, extracted the fluid from the cyst, rinsed the wall of the cyst repeatedly with normal saline, and finally injected with poly(lauryl alcohol) for retention, with a total volume of <50 ml. The results showed that the total effective rate of ultrasound intervention was 93.75%, which had little effect on ovarian reserve function.

2.3.2 Adenomyosis

High intensity (frequency < 1 MHz) focused ultrasound can be used to treat adenomyosis [17]. High intensity focused ultrasound (HIFU) can promote low-frequency and high-energy ultrasound to reach the target tissue through the body surface fat. It makes use of the cavitation, mechanical and thermal effects of ultrasound to induce irreversible damage and degeneration of adenomyosis cells. After the operation, the volume of the lesion was reduced, the symptoms of the patients were relieved, and the treatment process was safe.

3. Conclusions

The symptoms of endometriosis and adenomyosis are different from each other; so, individualized treatment according to different needs of patients is of great significance.

This chapter provides three kinds of conservative treatment methods commonly used in recent years for readers' reference. These three methods either reduce menstrual volume or relieve dysmenorrhea, so that patients avoid surgery; the effect is positive.

Acknowledgements

First and foremost, I would like to show my deepest gratitude to my supervisor, Dr. Yang Xiaojun, a respectable, responsible, and resourceful scholar, who has provided me with valuable guidance in every stage of the writing of this thesis.

I would also like to thank Dr. Huang Bing for his work and research in the treatment of endometriosis with nerve block. Neuromodulation therapy is a new subject. Dr. Huang and his team are studying the use of neuromodulation to treat various refractory diseases in various systems.

Thanks to the first hospital of Jiaxing City, Zhejiang Province, China. They have given some support to complete this chapter. It has contributed to the promotion of conservative treatment of endometriosis.

Conflict of interest

The authors declare no conflict of interest.

Nomenclature

UAE uterine artery embolization

SHPB nerve intervention: the superior hypogastric plexus block

Author details

Yang Xiaomin¹, Han Jun², Feng Pin² and Yang Xiaojun^{3*}

1 Jiaxing Hospital of Traditional Chinese Medicine, Zhejiang Chinese Medical University Affiliated Jiaxing TCM Hospital, Jiaxing University Affiliated TCM Hospital, Jiaxing, Zhejiang, China

2 The First Hospital of Jiaxing, Affiliated Hospital of Jiaxing University, Jiaxing, Zhejiang, China

3 The First Affiliated Hospital of Soochow University, Suzhou, Jiangsu, China

*Address all correspondence to: 12203681@qq.com

IntechOpen

© 2020 The Author(s). Licensee IntechOpen. This chapter is distributed under the terms of the Creative Commons Attribution License (<http://creativecommons.org/licenses/by/3.0>), which permits unrestricted use, distribution, and reproduction in any medium, provided the original work is properly cited. 

References

- [1] Zondervan KT et al. Endometriosis. *Nature Reviews. Disease Primers*. 2018;**4**(1):9
- [2] Reidy JF. Uterine artery embolization. *Journal of Radiology Nursing*. 2008;**27**(2):82-83
- [3] ACOG practice bulletin. Alternatives to hysterectomy in the management of leiomyomas. *Obstetrics and Gynecology*. 2008;**112**(2Pt 1):387-400. DOI: 10.1097/AOG.0b013e318183fbab
- [4] Bratby MJ, Walker WJ. Uterine artery embolisation for symptomatic adenomyosis—Mid-term results. *European Journal of Radiology*. 2009;**70**:128-132
- [5] Levгур M. Therapeutic options for adenomyosis: A review. *Archives of Gynecology and Obstetrics*. 2007;**276**:1-15
- [6] Jha RC, Takahama J, Imaoka I, et al. Adenomyosis: MRI of the uterus treated with uterine artery embolization. *American Journal of Roentgenology*. 2003;**181**:851-856
- [7] Lohle PN, De Vries J, Klazen CA, Boekkooi PF, Vervest HA, Smeets AJ, et al. Uterine artery embolization for symptomatic adenomyosis with or without uterine leiomyomas with the use of calibrated tris-acryl gelatin microspheres: Midterm clinical and MR imaging follow-up. *Journal of Vascular and Interventional Radiology*. 2007;**18**:835-841
- [8] Smeets AJ, Nijenhuis RJ, Boekkooi PF, et al. Long-term follow-up of uterine artery embolization for symptomatic adenomyosis. *Cardiovascular and Interventional Radiology*. 2012;**35**:815-819
- [9] Bulman JC, Ascher SM, Spies JB. Current concepts in uterine fibroid embolization. *Radiographics*. 2012;**32**(6):1735-1750. DOI: 10.1148/rg.326125514
- [10] Kil K, Chung J-E, Pak HJ, et al. Usefulness of CA125 in the differential diagnosis of uterine adenomyosis and myoma. *European Journal of Obstetrics, Gynecology, and Reproductive Biology*. 2015;**185**:131-135
- [11] Wang S, Xiaomei M, Dong Y. The evaluation of uterine artery embolization as a nonsurgical treatment option for adenomyosis. *International Journal of Gynaecology and Obstetrics*. 2016;**133**:202-205
- [12] Shu S, Tsuyoshi H, Megumi T, et al. Unique learning system for uterine artery embolization for symptomatic myoma and adenomyosis for obstetrician-gynecologists in cooperation with interventional radiologists: Evaluation of UAE from the point of view of gynecologists who perform UAE. *Journal of Minimally Invasive Gynecology*. 2018;**25**:84-92
- [13] Worthington-Kirsch R, Spies JB, Myers ER, et al. The fibroid registry for outcomes data (FIBROID) for uterine embolization: Short-term outcomes. *Obstetrics and Gynecology*. 2005;**106**(1):52-59. DOI: 10.1097/01.AOG.0000165828.68787.a9
- [14] Yang X, You J, Tao S, et al. Computed tomography-guided superior hypogastric plexus block for secondary dysmenorrhea in perimenopausal women. *Medical Science Monitor: International Medical Journal of Experimental and Clinical Research*. 2018;**24**:5132-5138
- [15] Cranney R, Condous G, Reid S. An update on the diagnosis, surgical management, and fertility outcomes for women with endometrioma. *Acta Obstetrica et Gynecologica Scandinavica*. 2017;**96**(6):633-643

[16] Chia-Lin H, Chii-Shinn S, Liang-Ming L, et al. Effectiveness of ultrasound-guided aspiration and sclerotherapy with 95% ethanol for treatment of recurrent ovarian endometriomas. *Fertility and Sterility*. 2009;**91**:2709-2713

[17] Philip C-A, Warembourg S, Dairien M, et al. Transrectal high-intensity focused ultrasound (HIFU) for the management of rectosigmoid deep infiltrating endometriosis: Results of phase I clinical trial. *Ultrasound in Obstetrics & Gynecology*. 2019;**56**(3)