

We are IntechOpen, the world's leading publisher of Open Access books Built by scientists, for scientists

6,900

Open access books available

186,000

International authors and editors

200M

Downloads

Our authors are among the

154

Countries delivered to

TOP 1%

most cited scientists

12.2%

Contributors from top 500 universities



WEB OF SCIENCE™

Selection of our books indexed in the Book Citation Index
in Web of Science™ Core Collection (BKCI)

Interested in publishing with us?
Contact book.department@intechopen.com

Numbers displayed above are based on latest data collected.
For more information visit www.intechopen.com



Umbilical Hernias in Adults: Epidemiology, Diagnosis and Treatment

*Ibrahima Konaté, Abdourahmane Ndong
and Jacques N. Tendeng*

Abstract

The literature on umbilical hernias in adults remains less extensive compared to other types of hernias. Adult umbilical hernias are frequently asymptomatic. The most frequent reasons for consultation are pain and esthetic discomfort. The diagnosis is most often evident on physical examination of the abdomen with tumefaction in the umbilicus. Despite the recent advances in terms of mesh varieties and minimally invasive surgery (laparoscopic and robotic surgery), there is still no real consensus on the optimal method for repair of umbilical hernia. Based on the patient characteristics and the context, “tailored and optimized surgery” should always be used to have the best results.

Keywords: umbilicus, hernia, adult, abdominal wall, surgery

1. Introduction

An umbilical hernia is defined as a midline hernia located at or near the umbilicus [1]. Umbilicus is a frequent site of hernia because it represents a natural weak spot of the abdominal wall, being the attachment site of the umbilical cord during the fetal period.

The literature on umbilical hernias in adults remains less extensive compared to other types of hernias. In fact, in adults, groin hernias are more frequent, since umbilical hernias are more studied in children.

The risk of strangulation is important, estimated at up to 17% in umbilical hernias, up to three times higher than in femoral hernia [2]. To avoid these complications, a surgical treatment is required. Despite the recent advances in terms of mesh varieties and minimally invasive surgery (laparoscopic and robotic surgery), there is still no consensus on the optimal method for repair of umbilical hernia.

2. Epidemiology

It is estimated that every year, 20 million abdominal wall hernias surgeries are performed worldwide [3]. Umbilical hernia is the second most frequent type of hernia and accounts for 6–14% of all abdominal wall hernias in adults, after inguinal hernias [1].

It is a very common condition in children, occurring in one of every six children [4]. It represents an important part in the practice of pediatric surgeons, especially in sub-Saharan Africa [5]. However, in adults, nearly 90% of umbilical hernias are acquired with no indication of hernia in childhood [6]. The risk factors are the same as for other abdominal wall hernias and are caused predominantly by intra-abdominal hyper pressure and/or parietal weakness. The repetitive action on the abdominal wall due to increased intraabdominal pressure favor microscopic tears of tissue. This will lead in time to hernia formation.

The risk factors are physical labor, obesity, ascites, constipation, pregnancies, excessive coughing, or dysuria. A female predominance is however noted with a sex ratio of 3:1 [7]. This is explained by the different distribution of risk factors according to sex. Indeed, obesity is more common in women and pregnancy is a factor noted exclusively in women. This female predominance is also due to the distension of the umbilicus associated with childbirth.

3. Diagnosis

3.1 Clinical presentation

Umbilical hernias occur more often above or below the umbilicus rather than directly through the umbilicus [8]. This is why, according to the classification of the European Hernia Society, hernias whose rings are located between 3 cm on either side of the umbilicus on the linea alba, are considered as umbilical hernias (**Figure 1**) [9].

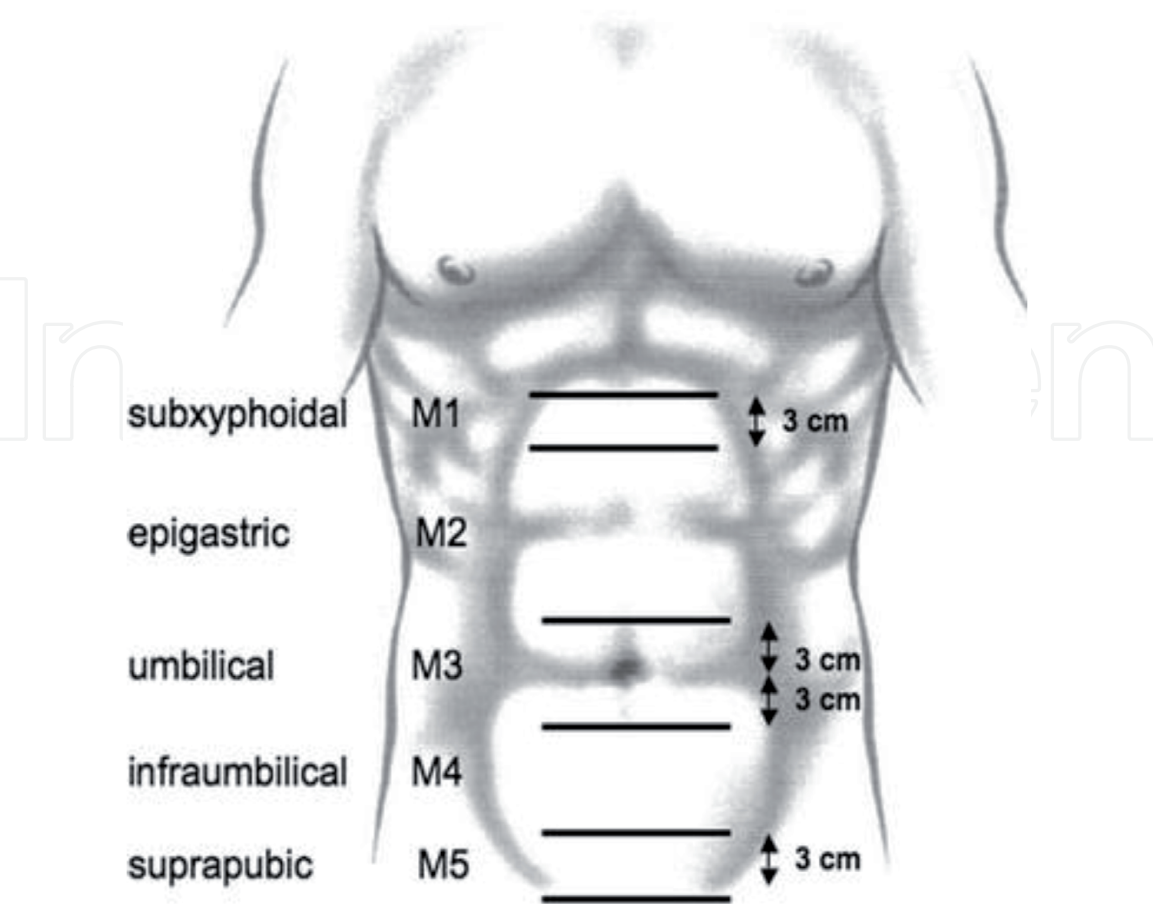


Figure 1.
Localization of umbilical hernias according to the classification of the European hernia society [9].

Adult umbilical hernias are frequently asymptomatic. The most frequent reasons for consultation are intermittent pain and esthetic discomfort when the size is important [2].

Palpation helps assess the size of the neck and the reducibility of the hernia. When there is a complication, the abdominal pain is constant. The main complication is strangulation (occurrence of ischemia due to a compromised blood supply). In most cases, patients with a strangulated hernia have previously experienced incarceration seizures with spontaneous reduction.

On physical examination, palpation reveals an irreducible and painful umbilical swelling. **Figure 2** shows a strangulated umbilical hernia with irreducible swelling. When the small intestines are in the hernia sac, signs of intestinal obstruction appear (vomiting, lack of gas or stool).

Another complication that can occur is loss of domain. It represents a chronic large irreducible hernia reducing the volume of the abdominal cavity and creating a “second abdomen” [10].

The diagnosis of umbilical hernia is most often evident on physical examination of the abdomen with tumefaction in the umbilicus.

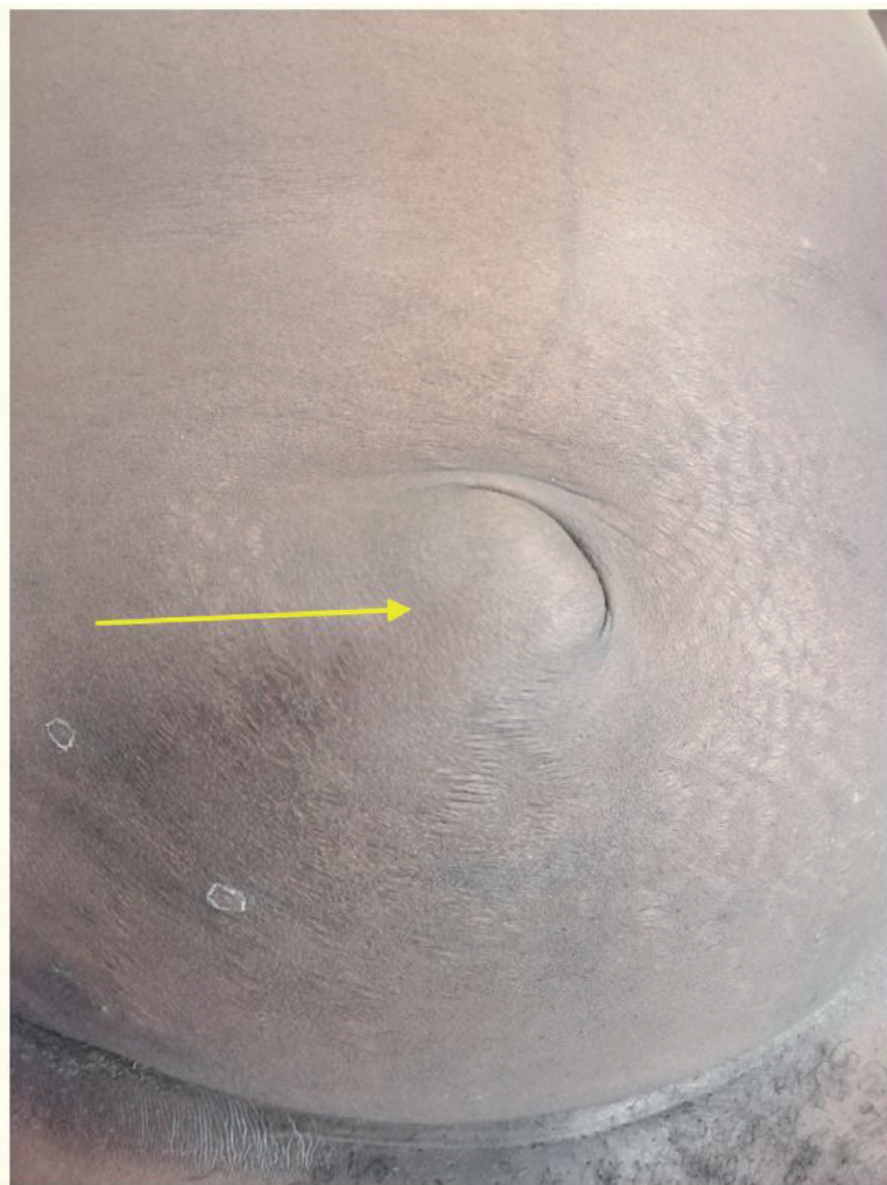

Figure 2.
Non-reducible umbilical tumefaction (image of the Department of Surgery, Gaston Berger University, Saint-Louis, Senegal).

However, the clinical presentation depends mainly on the size of the hernia (neck and sac) and the patient's BMI. In fact, hernias with a small neck or occurring in obese subjects can go unnoticed, especially in an emergency context. In these cases, performing imaging tests is important for an accurate diagnosis.

3.2 Radiological diagnosis

Imaging has an important role in the definitive diagnosis. In fact, clinical examination alone cannot exclude the diagnosis of hernia [11].

Indeed, many hernias are only detectable on imaging (ultrasound or computed tomography) especially when the defect is small or the abdominal fat tissue is important. Besides, imaging can also look for other abdominal wall hernias and more accurately determine the size of the wall defect for an optimization of the treatment.

Imaging also allows to make the differential diagnosis with other, more rare conditions such as abscesses, hematomas or tumors.

Ultrasound is cost effective and efficient. A study has shown that up to 25% of the general population present umbilical hernia when ultrasound is used for diagnosis [12]. This confirms the fact that ultrasound has a much greater sensitivity in detecting umbilical hernias than clinical examination alone. On the other hand, ultrasounds are dependent on the skills of the operator and have a limited contribution when the hernias are large or even with loss of domain. In these cases, the CT scan is of great help. With sagittal and axial reconstructions, CT scan gives more precise information on umbilical hernias (**Figures 3 and 4**).

More recently, some studies have shown that MRI has the best sensitivity and specificity of 92% and 95%, respectively, in the definitive diagnosis of abdominal wall hernias. Indeed, CT and ultrasound cannot completely rule out the presence of a hernia [14]. However, the main drawback of MRI remains the cost-effectiveness and its unavailability in resource limited context.

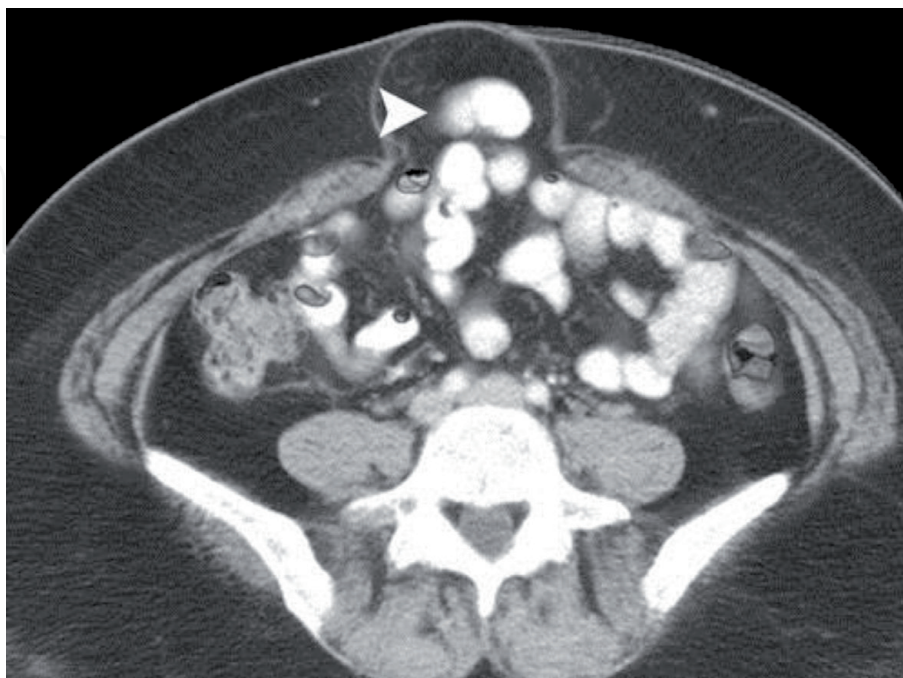


Figure 3.
Axial contrast-enhanced reformatted CT image of an uncomplicated umbilical hernia with small bowel as contents (arrowhead) during Valsalva maneuver [13].

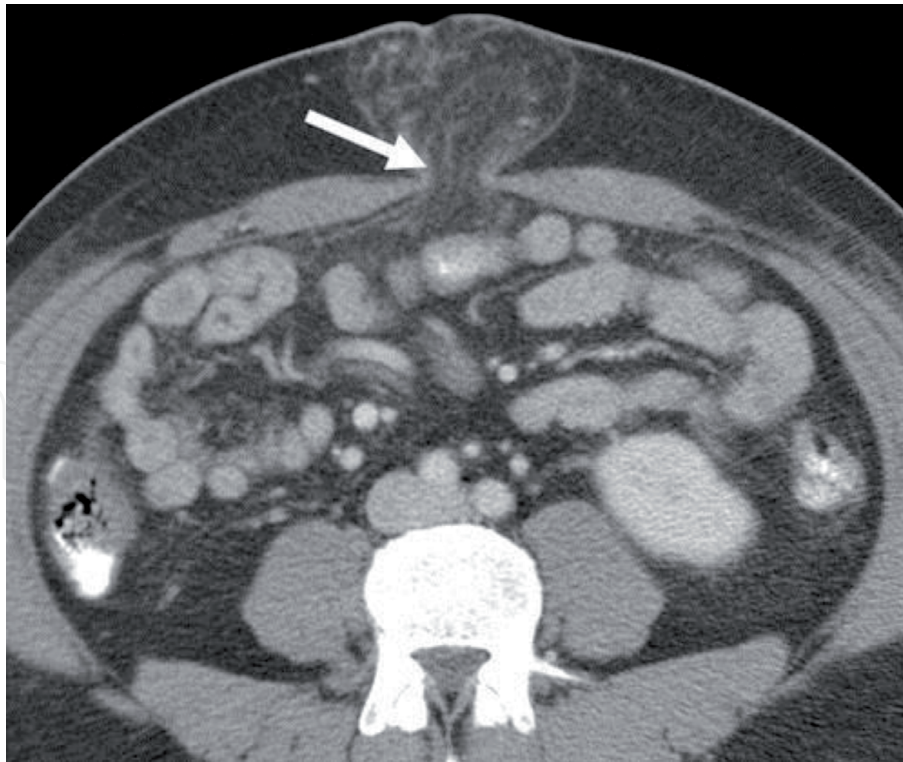


Figure 4.
Axial contrast-enhanced reformatted CT image of an incarcerated umbilical hernia with omental fat as contents (arrow) [13].

4. Treatment

4.1 Preparation of surgery

The treatment of umbilical hernia in adult is surgical. The preparation of the patient is very useful to decrease complications after elective umbilical hernia surgery. In fact, it is recommended smoking cessation for 4–6 weeks and weight loss to a BMI below 35 kg/m² before surgery [15]. In fact, controlling these factors can reduce the rate of post-operative complications and improve the recovery.

4.2 Anesthesia

All types of anesthesia are possible in umbilical hernia surgery (local, spinal or general anesthesia).

Local anesthesia is feasible in selected patients. Its main advantages lie in the reduction of complications associated with general anesthesia, the reduction of the length of hospital stay (ambulatory surgery) and its cost effectiveness [16, 17]. However, in large hernias or in obese subjects, its use can be difficult.

Rachi-anesthesia is also feasible but often requires a high block which is often incomplete [2].

Thus, general anesthesia is preferred because it allows surgery under better conditions. However, the best technique should be the one based on shared decision-making [15].

4.3 Non operative management

Recently, in developed countries there is an increased interest in “watchful waiting” due to the small risk of strangulation, less than 1% per year [18]. However,

a study comparing watchful waiting to surgery showed that, despite no significant difference in terms of mortality in readmission, 19% of non-operated patients will require surgery in the follow up [19]. Due to the risk of complications (strangulation), a watchful waiting approach is not recommended in umbilical hernia and this approach cannot be generalized and depends on the context of care. There is a lack of evidence on the safety of this approach, especially since an adequate follow up is not always possible in resource limited context. Even if watchful waiting is chosen, only asymptomatic umbilical hernia with no esthetic compromise should be non-operatively treated [15].

4.4 Open approach

Open approach is realized with different surgical techniques.

These surgical techniques depend mainly on the use or not of prosthetic material (suture repair or mesh repair).

The suture repairs most performed are simple primary closure and the technique of overlapping the fascia. This second technique was first described by William Mayo and was commonly used [8]. It consists of a plasty of the abdominal wall fascia in “vest-over-pants” (Paletot). However, with a high incidence of recurrence, this approach is less used now.

According to the Guidelines from the European Hernia Society and Americas Hernia Society, it is strongly recommended to use a mesh. In fact, it significantly decreases the rate of recurrence [15]. A randomized clinical trial showed that this rate can be reduced to 1% when mesh is used when compared to suture repair (11%) [20].

Mesh repair is now considered the “gold standard” for umbilical hernia in adults with no associated morbidity factors [21, 22]. In a selected group of patients, suture repair can be performed if the umbilical hernia defect is less than 1 cm.

4.5 Laparoscopic approach

The laparoscopic approach makes it possible to reduce esthetic damage by maintaining the appearance of the umbilicus and avoiding extensive dissections.

In addition, laparoscopy can diagnose other missed hernia during pre-operative procedures, evaluating all of the abdominal wall. Another advantage is the precise evaluation of the umbilical defect in order to use a mesh with the adequate size and overlap of the borders of the defect [23].

The technique consists in the placement of a mesh with a sufficient overlap (3 cm). The recommended site of the mesh placement is pre peritoneal or retro muscular due to the risk of adhesion with intra peritoneal mesh [15].

The prior primary closure of the umbilical defect is not mandatory but its realization may reduce the recurrence rate [24].

The most used mesh is polypropylene because it is cost effective and more available than others. However other types of mesh can also be used (light weight macroporous, composite or dual sides) [8].

Laparoscopic surgery is mainly suggested if the umbilical hernia is large (over 4 cm) [15]. This can decrease the risk of wound infections, post-operative pain, length of hospital stay, and other complications, mostly in patients at risk (obesity, smoking).

4.6 Robotic approach

The use of robotic surgery can improve the results of conventional laparoscopy. Indeed, it allows additional degrees of movement, 3D visualization and better

ergonomics for the surgeon. Besides, the attachment of the prosthesis to the anterior abdominal wall, which can be tedious in laparoscopy, is made even easier with the robotic approach [25]. However, longer learning curve, prolonged operative time and cost may be the main limitations of its use.

Hence, in low resource settings, open mesh repair is more feasible. This explains why “tailored surgery” should be the best approach according to the type of patient, the type of hernia, and the context of practice [26].

4.7 Approach in strangulation

The additional morbidity and mortality in emergency surgery require elective surgery whenever it is possible [27]. Evaluation of the contents is mandatory to assess its viability. When there is only ischemia and recoloration after reduction, a simple reduction and parietal repair are done (**Figure 5**). Bowel resection is performed when there is necrosis.

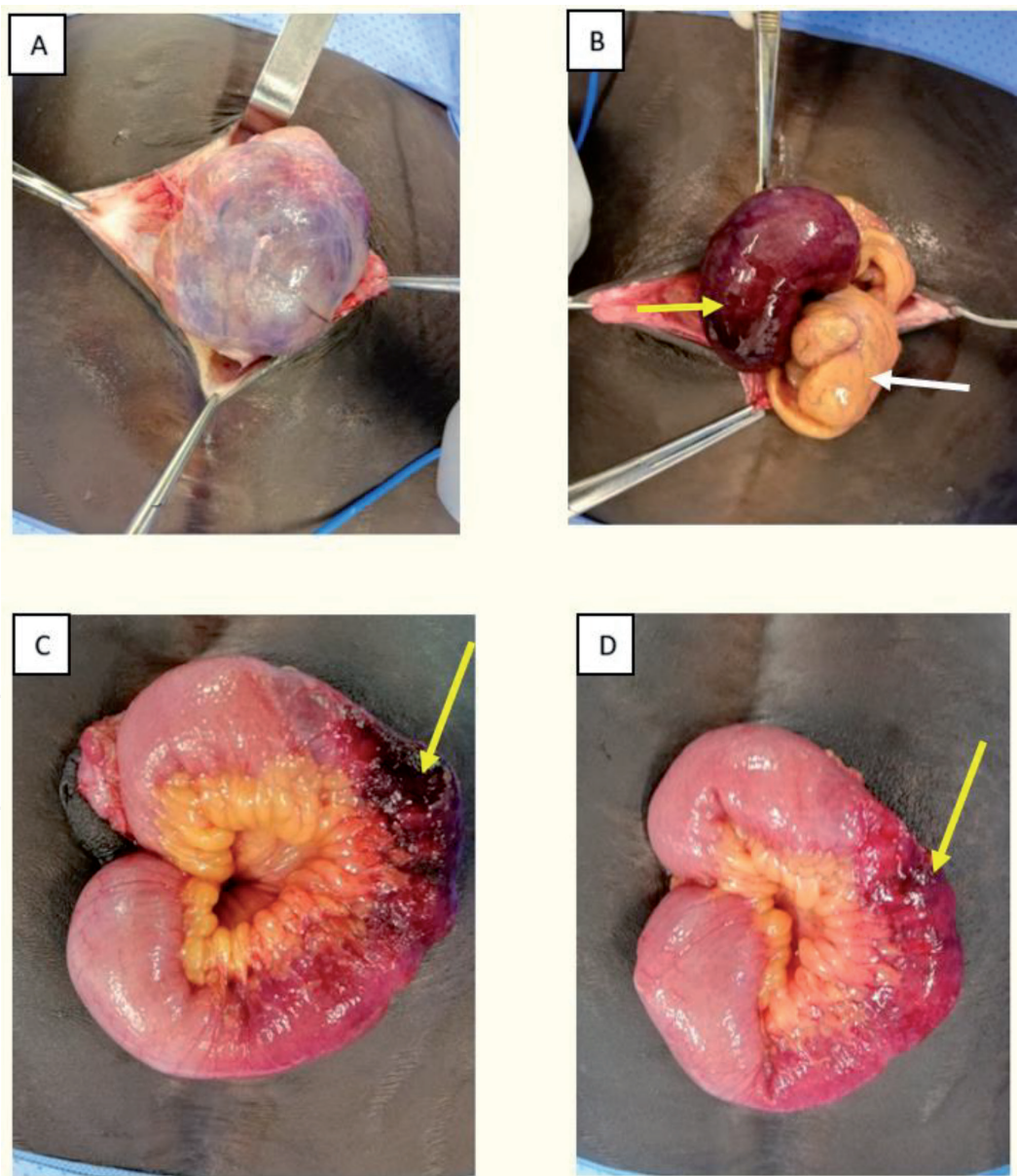


Figure 5.
Per operative image of open approach for a strangulated umbilical hernia: (A) Aspect of the unopened sac; (B) Contents of the hernia with small bowel with ischemia (yellow arrow) and omental fat (white arrow); (C) and (D) Resolution of the small bowel ischemia with recoloration (yellow arrows) (images of the Department of Surgery, Gaston Berger University, Saint-Louis, Senegal).

Both open or laparoscopic approaches are feasible but the open approach is recommended due to the possible necessity of bowel resection and the relative contra-indication of mesh use.

Considering the World Society of Emergency Surgery (WSES) guidelines, the use of mesh will depend on the contamination of the surgical field according to the Centers for Disease Control (CDC) classification. For clean (Class I) or clean-contaminated (Class II) procedures, a mesh can be used. However, for contaminated or infected wounds (Class III and Class IV), suture repair is preferred [28].

4.8 Complications

The most common post-operative complications regardless of the surgical technique are recurrence, superficial surgical site infection and chronic pain or discomfort [29].

Recurrence rate is now low (less than 1%) since the widespread use of mesh. However, mesh related complications are possible and not infrequent (seroma, adhesion, infection, migration or rejection). The removal of the mesh, if possible, should always be considered when mesh related complications occur.

The frequency of these complications is mainly related to co-morbidities, the kind of mesh, the surgical technique and the strategy used to prevent infections [30]. Hence, these complications can be prevented by patient optimization. In fact, obesity, excessive weight and smoking are the main risk factor for the occurrence of complications [31]. Controlling these factors help reduce the rate of complications.

5. Conclusion

Umbilical hernia remains a relatively common disease in adults. Its diagnosis is clinical and imaging can be used for small defects or in patients with excessive weight. Mesh repair should be preferred for uncomplicated hernia with a defect of more than 1 cm.

Minimally invasive surgery (laparoscopy and robotic) presents important advantages in terms of cosmetic outcome, wound infections, post-operative pain and length of hospital stay.

According to the emergency, the patient characteristics, or the context, “tailored and optimized surgery” should always be used to have the best short and long terms outcomes.

Conflict of interest

“The authors declare no conflict of interest.”

IntechOpen

IntechOpen

Author details

Ibrahima Konaté*, Abdourahmane Ndong and Jacques N. Tendeng
Department of Surgery, Gaston Berger University, Saint Louis, Senegal

*Address all correspondence to: ibrahima.konate@ugb.edu.sn

IntechOpen

© 2020 The Author(s). Licensee IntechOpen. This chapter is distributed under the terms of the Creative Commons Attribution License (<http://creativecommons.org/licenses/by/3.0>), which permits unrestricted use, distribution, and reproduction in any medium, provided the original work is properly cited. 

References

- [1] Coste AH, Jaafar S, Misra S, Parmely JD. Umbilical hernia. InStatPearls [Internet] 2019 Sep 29. StatPearls Publishing.
- [2] Velasco M, Garcia-Urena MA, Hidalgo M, Vega V, Carnero FJ. Current concepts on adult umbilical hernia. *Hernia*. 1999;3(4):233-239.
- [3] Kingsnorth A, LeBlanc K. Hernias: inguinal and incisional. *Lancet Lond Engl*. 2003;362(9395):1561-71.
- [4] Al-Salem AH. Abdominal Wall Hernias and Hydroceles. In *Atlas of Pediatric Surgery 2020* (pp. 79-98). Springer, Cham.
- [5] Ngom G. Umbilical hernia in African children: Same attitude than that of inguinal hernia. *J Indian Assoc Pediatr Surg*. 2006;11(4):255.
- [6] Shankar DA, Itani KMF, O'Brien WJ, Sanchez VM. Factors Associated With Long-term Outcomes of Umbilical Hernia Repair. *JAMA Surg*. 2017;152(5):461-6.
- [7] Dabbas N, Adams K, Pearson K, Royle GT. Frequency of abdominal wall hernias: is classical teaching out of date?. *JRSM short reports*. 2011 ;2(1):1-6.
- [8] Kulaçoğlu H. Current options in umbilical hernia repair in adult patients. *Ulus Cerrahi Derg*. 2015;31(3):157-61.
- [9] Muysoms FE, Miserez M, Berrevoet F, Campanelli G, Champault GG, Chelala E, et al. Classification of primary and incisional abdominal wall hernias. *Hernia*. 2009;13(4):407-14.
- [10] Parker SG, Halligan S, Blackburn S, Plumb AAO, Archer L, Mallett S, et al. What Exactly is Meant by "Loss of Domain" for Ventral Hernia? Systematic Review of Definitions. *World J Surg*. 2019;43(2):396-404.
- [11] Bedewi MA, El-sharkawy M. Imaging of Hernias. *Hernia*. 2017;30:31.
- [12] Bedewi MA, El-Sharkawy MS, Al Boukai AA, Al-Nakshabandi N. Prevalence of adult paraumbilical hernia. Assessment by high-resolution sonography: a hospital-based study. *Hernia J Hernias Abdom Wall Surg*. 2012;16(1):59-62.
- [13] Aguirre DA, Santosa AC, Casola G, Sirlin CB. Abdominal Wall Hernias: Imaging Features, Complications, and Diagnostic Pitfalls at Multi-Detector Row CT. *RadioGraphics*. 2005;25(6):1501-20.
- [14] Miller J, Cho J, Michael MJ, Saouaf R, Towfigh S. Role of Imaging in the Diagnosis of Occult Hernias. *JAMA Surg*. 2014;149(10):1077.
- [15] Henriksen NA, Montgomery A, Kaufmann R, Berrevoet F, East B, Fischer J, et al. Guidelines for treatment of umbilical and epigastric hernias from the European Hernia Society and Americas Hernia Society. *BJS Br J Surg*. 2020;107(3):171-90.
- [16] Jairam AP, Kaufmann R, Muysoms F, Jeekel J, Lange JF. The feasibility of local anesthesia for the surgical treatment of umbilical hernia: a systematic review of the literature. *Hernia*. 2017;21(2):223-231.
- [17] Menon VS, Brown TH. Umbilical hernia in adults: day case local anaesthetic repair. *J Postgrad Med*. 2003;49(2):132.
- [18] Leubner KD, Chop WM, Ewigman B, Loven B. What is the risk of bowel strangulation in an adult with an untreated inguinal hernia?. *Clinical Inquiries*, 2007 (MU). 2007.
- [19] Kokotovic D, Sjølander H, Gögenur I, Helgstrand F. Watchful

waiting as a treatment strategy for patients with a ventral hernia appears to be safe. *Hernia J Hernias Abdom Wall Surg.* 2016;20(2):281-7.

[20] Arroyo A, Garcia P, Perez F, Andreu J, Candela F, Calpena R. Randomized clinical trial comparing suture and mesh repair of umbilical hernia in adults. *Br J Surg.* 2001;88(10):1321-1323.

[21] Sebastian AA, Perez F, Serrano P, Costa D, Oliver I, Ferrer R, et al. Is prosthetic umbilical hernia repair bound to replace primary herniorrhaphy in the adult patient? *Hernia.* 2002;6(4):175-177.

[22] Kaufmann R, Halm JA, Eker HH, Klitsie PJ, Nieuwenhuizen J, van Geldere D, et al. Mesh versus suture repair of umbilical hernia in adults: a randomised, double-blind, controlled, multicentre trial. *The Lancet.* 2018;391(10123):860-869.

[23] Lau H, Patil NG. Umbilical hernia in adults. *Surg Endosc Interv Tech.* 2003;17(12):2016-2020.

[24] Gonzalez AM, Romero RJ, Seetharamaiah R, Gallas M, Lamoureux J, Rabaza JR. Laparoscopic ventral hernia repair with primary closure versus no primary closure of the defect: potential benefits of the robotic technology. *Int J Med Robot.* 2015;11(2):120-5.

[25] Chen YJ, Huynh D, Nguyen S, Chin E, Divino C, Zhang L. Outcomes of robot-assisted versus laparoscopic repair of small-sized ventral hernias. *Surg Endosc.* 2017;31(3):1275-9.

[26] Guttadauro A. Introductory Chapter: State of the Art in Hernia Surgery. In *Techniques and Innovation in Hernia Surgery* 2020 May 27. IntechOpen.

[27] Rind GH, Soomro AH, Ayoob M, Bhatti ZA, Sohu KM. Presentation and

Outcome of Strangulated External Abdominal Hernias. *JLUMHS.* 2010;9(01):04.

[28] Birindelli A, Sartelli M, Di Saverio S, Coccolini F, Ansaloni L, van Ramshorst GH, et al. 2017 update of the WSES guidelines for emergency repair of complicated abdominal wall hernias. *World J Emerg Surg.* 2017;12(1):37.

[29] Westen M, Christoffersen MW, Jorgensen LN, Stigaard T, Bisgaard T. Chronic complaints after simple sutured repair for umbilical or epigastric hernias may be related to recurrence. *Langenbecks Arch Surg.* 2014;399(1):65-9.

[30] Falagas ME, Kasiakou SK. Mesh-related infections after hernia repair surgery. *Clin Microbiol Infect.* 2005;11(1):3-8.

[31] Venclauskas L, Silanskaite J, Kiudelis M. Umbilical hernia: factors indicative of recurrence. *Med Kaunas Lith.* 2008;44(11):855-9.