

We are IntechOpen, the world's leading publisher of Open Access books Built by scientists, for scientists

6,900

Open access books available

186,000

International authors and editors

200M

Downloads

Our authors are among the

154

Countries delivered to

TOP 1%

most cited scientists

12.2%

Contributors from top 500 universities



WEB OF SCIENCE™

Selection of our books indexed in the Book Citation Index
in Web of Science™ Core Collection (BKCI)

Interested in publishing with us?
Contact book.department@intechopen.com

Numbers displayed above are based on latest data collected.
For more information visit www.intechopen.com



Application of Photodynamic Therapy in the Treatment of Osteonecrosis of the Jaw

Marko Vuletić, Božana Lončar Brzak, Igor Smojver, Luka Marković, Mato Sušić and Dragana Gabrić

Abstract

Osteonecrosis as term represents the death of bone tissue in the body and causes of necrosis can be different. Medication-related osteonecrosis of the jaws (MRONJ) is nowadays known as an inability of the alveolar bone to respond to a local trauma and it can result in severe local and systemic complications. In the etiology of medication-related osteonecrosis there are antiangiogenic and antiresorptive agents which have great effect on alveolar bone, producing an imbalance between resorption (osteoclastic activity) and deposition (osteoblastic activity). The exact mechanisms of development are not today completely resolved. It is thought that it is a result from combination of medication interactions, microbiological contamination of the area and local tissue trauma. Typical signs and symptoms are painful mucosal lesions, swelling, exposed necrotic bone in the jaws, discomfort and dysesthesias. There is currently no gold standard or clearly defined treatment protocol for the disease itself. Process of treatment is demanding and main goal is to eliminate pain, control infection of soft and hard tissue and minimize progression of osteonecrosis. Besides the conventional surgical treatment, photodynamic therapy can be a viable supportive tool of initial and advanced stages of osteonecrosis and may contribute to improvements of patient's quality of life.

Keywords: osteonecrosis, osteoclasts, bone, surgical procedure, photodynamic therapy

1. Introduction

Osteonecrosis as term represents the death of bone tissue in the body and causes of necrosis can be different. If it is associated with a reduced or complete absence of blood supply, this process is called avascular necrosis of the bone and is most commonly associated in the literature with the femur bone [1].

Radiotherapy (radiation) can also adversely affect bone tissue due to compromised angiogenesis resulting in avascular necrosis with hypoxic, hypocellular, and hypovascular lesions, termed osteoradionecrosis [1]. In 2003, when 36 cancer patients receiving treatment with pamidronate or zoledronate developed a painful bone exposure of the mandible, of the maxilla or both, which was unresponsive to medical and surgical treatment, a new type of osteonecrosis of the jawbone associated with bisphosphonate was called osteonecrosis of the jaw (BRONJ) [2].

Over time, precisely in 2010, new drugs have been identified, such as denosumab for causing osteonecrosis, that do not belong to the group of bisphosphonates so the name has changed to medication-related osteonecrosis of the jaw (MRONJ) [3]. MRONJ is an uncommon condition that can occur after exposure to medication to prevent bone complications, such as bisphosphonates or denosumab or other agents as angiogenesis inhibitors [4]. In most cases it manifests as exposed bone in the maxillofacial region, although non-exposed MRONJ has also been recognized [5–8].

The purpose of this chapter was to describe medication-related osteonecrosis of the jaw, the theory of its development, clinical picture, classification, epidemiology and modalities of treatment, including biostimulative and antimicrobial photodynamic therapy, of medication-related osteonecrosis of the jaw.

2. The process of bone remodeling

Bone remodeling is a physiological process that lasts lifetime and is characterized by the interaction of bone-forming cells - osteoblasts and bone-resorbing cells - osteoclasts. The remodeling process begins with the activation of osteoclasts (multinuclear cells of the monocyte–macrophage system) which are located on the bone surface and with the formation of acidic medium, they dissolve mineralized bone with the breakdown of proteins of the remaining bone matrix. This resorption process takes between two and four weeks. After the resorption process, osteoblasts replace osteoclasts (cells of mesenchymal origin) which synthesize osteoid and organic matrix over a period of two to four months, as a prerequisite for bone mineralization or calcium hydroxyapatite mineral investment [2]. Finally, when osteoblasts are implanted in the bone matrix, they become osteocytes [3]. The presence of osteocytes is extremely important for bone vitality because they can recognize and respond to a variety of mechanical stimuli by regulating the differentiation of osteoblasts and osteoclasts. The remodeling process is regulated by various mechanisms, of which the most important is the RANK/RANKL/Osteoprotegerin system. Osteoblasts secrete osteoprotegerin, which prevents osteoclast differentiation from precursor cells and thus inhibits resorption. On the other hand, RANKL (Receptor Activator of NF- κ B Ligand) along with M-CSF (Macrophage Colony-Stimulating Factor) stimulates osteoclast differentiation and maturation from precursor cells [4]. If this physiological process is disturbed, and this is especially important with increased expression of RANKL, resorption occurs. RANKL is produced by osteoblasts and activated T lymphocytes.

During remodeling and healing of bone fractures, osteoblasts activate various bone morphogenetic proteins that stimulate the production of VEGF (Vascular Endothelial Growth Factor) factor, which is necessary for the formation of new blood vessels, or angiogenesis [5].

The process of physiological remodeling can be disrupted in a variety of diseases and conditions associated with hyperactivated osteoclasts that have a high potential for bone destruction, which can result in hypercalcemia, decreased bone density, and consequent spontaneous fractures. The most common metabolic disease of the skeletal system is osteoporosis which is characterized by osteoclast hyperactivity with loss of bone quality. Malignant diseases of the breast, prostate, lungs, kidneys and thyroid often metastasize to bone. Complications of bone metastases include bone pain, fractures, hypercalcemia, and cachexia. Once formed in the bones, malignant cells stimulate bone resorption where various growth factors, released during bone destruction from the bone matrix, serve them for further growth and proliferation. In addition to growth factors, VEGF factor is also important for later tumor growth. Multiple myeloma, a malignant hematological disease, which is

manifested by the presence of lytic lesions in the bone, has a similar mechanism of bone destruction. In the treatment of these diseases, antiresorptive drugs that directly or indirectly inhibit osteoclasts and antiangiogenic drugs that inhibit VEGF are used.

3. Medications-related osteonecrosis of the jaw (MRONJ)

There are two groups of drugs that may cause medication-related osteonecrosis of the jaw. The first group includes antiresorptive drugs, specifically bisphosphonates and denosumabs, and the second group consists of antiangiogenic drugs that include bevacizumab (Avastin) which is humanized monoclonal antibody and also sunitinib (Sutent) which acts as a tyrosine kinase inhibitor [9–13].

3.1 Antiresorptive drugs

The first type of drugs is antiresorptive drugs, which include bisphosphonates and denosumabs. They have a similar mechanism of action and a similar potency of causing osteonecrosis.

3.1.1 Bisphosphonates

Bisphosphonates are medications that act as analogs of pyrophosphate, which is a natural inhibitor of bone metabolism. The mechanism of their action has not yet been fully elucidated, but they are inhibitors of osteoclast activity and inducers of their apoptosis, reducing the process of bone remodeling. Bisphosphonates are incorporated into the hydroxyapatite bone matrix, at the site of the OH group of bisphosphonates, using the P-C-P compound, which alters bone microstructure by slowing bone growth and reducing the amount of mineral dissolution in bone. Unlike osteoclasts, osteoblastic activity does not decrease, but remains preserved, which results in an increase in bone mass. There are currently three generations of bisphosphonates on the market. The first generation of nitrogen-free bisphosphonates has the least potential for jaw osteonecrosis. The main side effect of bisphosphonate therapy is osteonecrosis of the jaw [2]. Other side effects that may occur in bisphosphonate therapy are: gastrointestinal disorders (nausea and vomiting), atypical femoral fractures, esophageal inflammation with consequent mucosal erosions, secondary hyperparathyroidism, atrial fibrillation, eye outbursts, muscle pain and others [14–17]. Bisphosphonates are excreted by the kidneys, after accumulation at sites of active remodeling (both jaws). Their characteristic is also rapid deposition in the bones and their long retention in the same (the half-life of zoledronic acid is 11.2 years in the bones) [18]. There are two types of bisphosphonate administration, oral and intravenously.

Oral bisphosphonates are medications that are most commonly prescribed in the treatment of osteoporosis and osteopenia, also they are the medications of choice for bone diseases that occur less frequently, such as Paget's disease, osteogenesis imperfecta, chronic recurrent multifocal osteomyelitis and for prevention heterotopic ossifications mostly of the spinal cord [19, 20]. They are also indicated in treatment of chronic kidney disease, kidney transplantation, in rheumatoid diseases related with systemic bone loss such as rheumatoid arthritis, spondylarthritis or SAPHO (synovitis, acne, pustulosis, hyperostosis, osteitis) syndrome and in non-inflammatory rheumatoid diseases, as aseptic osteonecrosis, neuropathic osteoarthropenia, and fibrous dysplasia [21]. Unlike intravenous bisphosphonates, have a lower potential for osteonecrosis.

Intravenous bisphosphonates are the most potent in causing osteonecrosis [22]. They are used in the treatment of various conditions associated with malignant diseases such as hypercalcemia caused by cancer and for treatment of bone metastases (secondaryism) [23]. Secondaryism in bones are releasing cytokines and growth factors, which enhance the effectiveness of osteoclasts and consequently bone resorption, which favors tumor growth. Intravenous bisphosphonates stimulate antitumor immune mechanisms, which inhibit growth, migration, and secondary formation, most commonly in breast and prostate cancer. This type of bisphosphonates is very common used in treatment of lytic lesion and for prevention of massive bone resorption in multiple myeloma. Patients with this diagnosis are often treated with aggressive chemotherapy which one of many side-effects is osteonecrosis. Despite the mentioned facts, these medications have positive effect on patient's quality of life [24].

3.1.2 Denosumab

Denosumab are humanized monoclonal antibodies directed to a RANK ligand (modeling regulator) that inhibit osteoclasts and reduce bone resorption [25]. It is used for treatment of osteoporosis in which there is an increased risk of bone fractures, in osteoporosis where there is bone loss due to the use of various drugs and in the treatment of malignant bone lesions diseases. Denosumab therapy is a better option than bisphosphonate therapy, especially with renal dysfunction. The potency of denosumabs to induce osteonecrosis alone has been shown to be approximately similar to the potency of zoledronic acid which is the most potent bisphosphonate [26, 27].

Denosumabs are administered subcutaneously and, unlike bisphosphonates, do not accumulate in bone, so that their effect on bone remodeling is reversible and lasts approximately six months [28].

3.2 Antiangiogenic drugs

Antiangiogenic medications prevent the formation of new blood vessels binding to various signaling molecules that inhibit angiogenesis.

3.2.1 Bevacizumab

Bevacizumab is humanized monoclonal antibody that binds selectively to a protein called vascular endothelial growth factor (VEGF) in the blood and lymph vessels. It is used in the treatment of malignant diseases of the kidneys, gastrointestinal tract, lungs and glioblastoma [9, 10].

3.2.2 Sunitinib

Sunitinib is used in the treatment of gastrointestinal tumors, metastatic renal cell carcinomas cells and neuroendocrine tumors of the pancreas. It works by inhibiting thyroxine kinase function. In combination with chemotherapy or bisphosphonates, they have high risk of inducing osteonecrosis [29].

4. Mechanism of development MRONJ

The exact mechanisms of development MRONJ are not today's completely resolved. It is thought that its development is a result from combination of

medication interactions, microbiological contamination of the area and local tissue trauma [30]. In the literature there are few hypotheses of the development of this specific disease.

4.1 Inhibition of bone resorption and remodeling

Antiresorptive medications inhibit osteoclast function and differentiation, leading to their apoptosis, and this results in reduced bone remodeling [31]. In addition to acting on osteoclasts, antiresorptive medications also reduce the activity of osteoblasts, keratinocytes and fibroblasts [32, 33]. Of all the bones, the jaws are the most susceptible to remodeling, so osteonecrosis specifically occurs on them.

4.2 Inflammation or infection

In the pathogenesis of medication-related osteonecrosis, inflammation plays a significant role development. Advanced periodontal disease and tooth extraction are one of the main triggers for occurrence of necrosis. Pathohistological analysis of bone parts, which are affected with osteonecrosis, decontamination with various bacteria is present, especially *Actinomyces* species in 70–100% of cases [34]. The main role in development of MRONJ has bacterial decontamination [35, 36]. Bisphosphonates have synergistic effect with bacteria because they increase the possibility of bacterial adhesion to hydroxyapatite found in the bone, resulting in the invasion of microorganisms into the bone itself afterwards the bone loses blood supply, becomes avascular and necrotic.

4.3 Inhibition of angiogenesis

Inhibition of angiogenesis means inhibition of growth, migration and differentiation of new endothelial cells in forming blood vessels. Medications that inhibit angiogenesis, due to ischemia or lack of blood supply to the bone secondary create osteonecrosis [37].

4.4 Soft tissue toxicity

One of theory of medication-related osteonecrosis is that drugs directly negatively affect fibroblasts producing toxicity of the oral mucosa. In vitro studies, increased apoptosis has been reported, especially in oral epithelial cells, after application bisphosphonates. Bone exposure and impaired healing caused by tissue toxicity play an important role in the development of osteonecrosis [38].

4.5 Immune dysfunction

Antiresorptive drugs together with other immunosuppressants such as corticosteroids, chemotherapy or methotrexate increases the possibility of osteonecrosis [3]. Ruggiero et al. [3] stated that in the beginning of investigating the influence of bisphosphonates on wound healing in animal models, to induce osteonecrosis, steroids were combined with bisphosphonates. Inflammation, delayed healing, mucosal ulceration, exposed bone, fistula and histologic necrosis are well documented symptoms in different animal species and in humans exposed to surgical procedures after application chemotherapy with antiresorptive drugs. Methotrexat is standard or first line drug for therapy of rheumatoid arthritis. It can be an iatrogenic cause of lymphoproliferative disorders in immunodeficient or immunosuppressed patients, resulting with osteonecrosis of the jaw in some cases [35].

4.6 Low pH values

Depending on the pH value, bisphosphonates can bind to hydroxyapatite in the bone or leave it and activate. At neutral pH the bisphosphonates are bound to hydroxyapatite and at reduced pH values bisphosphonates are released and activated from it [37, 38]. Bone resorption mechanism takes place in the Howship's lacunae. In situations when the pH remains low, potentially leads to toxic levels of bisphosphonates which have a negative effect on osteoclasts and other cells as well. By acting on different types of cells, there is suppression of remodeling, suppression of angiogenesis, increasing the toxicity of the oral mucosa, which contributes creating an infection with developing the osteonecrosis [38].

5. Epidemiology of development MRONJ

The incidence of drug osteonecrosis depends on a variety of factors.

5.1 Method of application

The way of medication administration is an important factor in assessing the risk of developing osteonecrosis. Bisphosphonates taken orally have been shown to be more benign than bisphosphonates administered intravenously [3, 39]. The prevalence of medication related osteonecrosis in oral bisphosphonates is much lower (ranging from 0.1% to 0.05%) than the prevalence of intravenous bisphosphonates and denosumab (ranging from 2% to 10). Prevalence increases after invasive surgical procedure and also increases with the duration of therapy. The largest prevalence of medication-related osteonecrosis has been described in patients with multiple myeloma [22, 40].

5.2 Duration of therapy

An important factor in the development of medication related osteonecrosis is the duration of the antiresorptive therapy. The literature states that after each year of therapy, the risk of medication osteonecrosis doubles [41].

5.3 Dosage

Medications that cause MRONJ can be prescribed every day, once weekly, once a month, once every three months or once every six months. Incidence of osteonecrosis increases with a higher dose [42–45].

5.4 Potency

Almost every antiresorptive medication shows its potency in causing osteonecrosis [42].

5.5 Accumulation in the body

Zoledronic acid and denosumab have similar potency of inducing osteonecrosis. They are different in the time of accumulation in the body. Bisphosphonates accumulate in bones, where they persist for a long time, their half-life last up to 11.2 years,

while unlike bisphosphonates, denosumabs do not accumulate in the bones and are eliminated from the body after only 6 months [28, 46].

5.6 Local factors

Dental procedures that are invasive, such as dentoalveolar surgery, increase the risk of MRONJ up to seven times [3]. From local factors dentoalveolar surgery is considered the most risky factor for the development of medication-related osteonecrosis with an incidence of 60 to 65% [31, 47]. In other dental procedures such as endodontic or periodontal, the incidence of medication-related osteonecrosis is less. Dental diseases that the patient has already overcome, such as periodontitis, peri-implantitis, various inflammatory conditions of the jaw and poor oral hygiene are among the additional risk factors conducive to the development of MRONJ [47, 48].

5.7 Anatomical factors

It is known that medication related osteonecrosis occurs more often in the lower jaw in 73% of cases relative to the upper jaw, where it occurs in 22.5% of cases, while the incidence of osteonecrosis in both jaws simultaneously only in 4.5% of cases [3]. It also turned out that MRONJ more often develops in places with the thinnest layer of mucosa, and these are the lingual side of the lower jaw and the various exostoses and toruses found in the oral cavity [3, 47]. Wearing a prosthesis is also doubling the risk of developing MRONJ.

5.8 Systemic factors

A significant risk factor for the development of MRONJ is the patient's basic disease [49]. An increased risk of medication-related osteonecrosis has been shown in women, mostly due to osteoporosis or breast cancer. A risk of MRONJ significantly increases if, in addition to antiresorptive therapy are added additional drugs that act immunosuppressively, such as chemotherapeutics or corticosteroids. Studies show that MRONJ occurs in 40% of cases in patients who have been or are still on chemotherapy, in 25% cases of patients on corticosteroid therapy and in 10% of patients with diabetes [50, 51]. Anemia, systemic lupus, hypothyroidism, renal failure, rheumatoid arthritis, hypertension and smoking are also conditions that contribute to an increased risk of osteonecrosis [52, 53].

5.9 Genetics

The risk of developing osteonecrosis is also associated with gene predisposition. Some studies have shown an association between the FDPS (farnesyl diphosphate synthase gene) which encodes a key enzyme of the mevalonate pathway and the development of osteonecrosis of the jaw. That is why are tested rs2297480, a SNP region on the FDPS gene. Studies have been conducted in patients who have suffered from multiple myeloma or metastatic carcinomas and have been treated with zoledronate acid [54].

5.10 Biomarkers for risk assessment

Bone markers have been shown to be useful for assessing the risk of developing osteonecrosis [47]. C-terminal telopeptide (CTX) and N-terminal telopeptide (NTX) are demonstrated as the two main bone markers that measure osteoclast activity, i.e., degradation of osteoclasts and osteoblasts [47].

6. Prevention of MRONJ

6.1 Before starting antiresorptive therapy

Before starting antiresorptive therapy, it is important to make an initial dental examination with a detailed history and radiologically and clinically evaluate the patient's condition. An orthopantomogram is recommended of the radiological techniques. The goal of preventive screening is to remove any potential conditions that could lead to the formation of osteonecrosis during therapy. It is necessary to remove all incurable teeth or teeth with a poor prognosis, cure acute or chronic infections, cysts, tumors and other pathological conditions of the jaw. If the patient has a prosthesis, it is necessary to examine the sharp edges or possible painful areas ("blistering") that may adversely affect the mucosa. If teeth need to be extracted, it is advisable to wait a minimum of three weeks to achieve acceptable soft tissue healing, or preferably four to six weeks to achieve sufficient bone healing before initiating antiresorptive therapy [3].

Patients need to be educated about the risk of developing osteonecrosis, motivate them to strengthen oral hygiene and more frequent control (at least four times a year).

6.2 After therapy/during therapy

Depending on the duration and manner of taking antiresorptive drugs, it is necessary to make a detailed treatment plan that includes a consultation with a competent doctor for possible withdrawal of therapy.

Invasive surgical procedures (extraction, endodontic surgery) are reported as an increased risk of creating necrosis itself. In high-risk patients (high-potency drugs, adjunctive therapy), for the development of osteonecrosis, tooth extraction is not recommended and instead of extraction, endodontic treatment is recommended with root smoothing and cement coating. However, if invasive surgery is required as indicated for severe periodontitis, movable teeth, root fractures, then it is advisable to use the recommended guidelines [3].

A. Oral bisphosphonates.

1. If the patient is on therapy for less than four years and is not on adjunctive therapy (corticosteroids or angiogenic drugs), antiresorptive therapy does not need to be removed.
2. If the patient is on therapy for less than four years and prescribes adjunctive therapy (corticosteroids or angiogenic drugs) or is on therapy for more than four years or without adjunctive therapy, then consultation with a physician is required to discontinue bisphosphonate therapy at least two months before surgical treatment and continuation of bisphosphonate therapy when adequate bone healing is achieved (usually three months after the surgical treatment) [3].

B. Denosumabs.

Denosumabs are most commonly taken subcutaneously every six months. If invasive surgery is required, it is recommended to do it three weeks before the next application of the drug itself. It should be in mind that denosumabs are extremely potent drugs for the formation of osteonecrosis, but they, unlike bisphosphonates, are eliminated from the tissues after six months [3].

C. Parenteral bisphosphonates.

The previous recommendation was to discontinue therapy six months before the procedure and three months after, but this is especially difficult in malignant patients (due to the severity of the underlying disease) and discontinuation of therapy has not been scientifically proven to reduce the risk of osteonecrosis. It is recommended that the patient be referred to a specialist institution for the most at-risk group. Poor soft tissue healing should be in mind in patients receiving chemotherapy, especially three to four weeks after chemotherapy when mucositis of the oral mucosa is most common [3].

7. Clinical aspect of MRONJ

To diagnose medication related osteonecrosis of the jaws the following criteria must be filled:

1. Current or previous therapy with antiresorptive or antiangiogenic medications;
2. Exposed bone or appearance of a fistula in the jaw (intraoral or extraoral) that persists longer from eight weeks;
3. The patient is not irradiated and has no proven metastasis in the jaw bones [3, 55].

Medication-related osteonecrosis significantly impairs the quality of life of the patient and represents problems with speech, chewing, swallowing, feeding, often there is pain in the swollen mucosa, as well as chronic sinusitis [3]. In almost 94% of cases of medication-related osteonecrosis, exposed bone is present [56]. It is also the main feature of osteonecrosis (**Figure 1**). Variations can be different, from the small exposed edges around the empty alveoli all the way to complete involvement of one or both jaws [57]. We often find next to the exposed bone and signs of inflammation of the surrounding soft tissues that present as swelling that may or may not be purulent. The most lesions are asymptomatic, and when the patient develops pain,

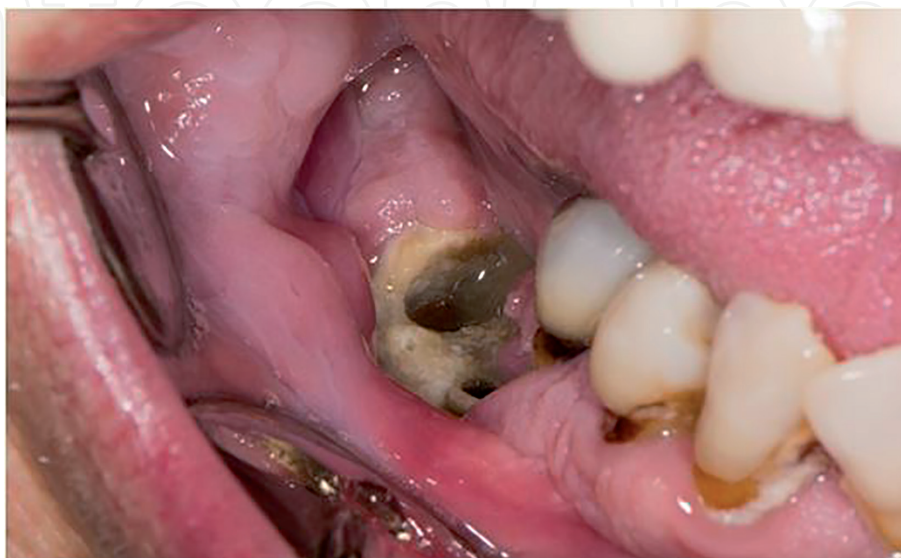

Figure 1.
Clinical appearance of MRONJ-exposed bone (Zometa).

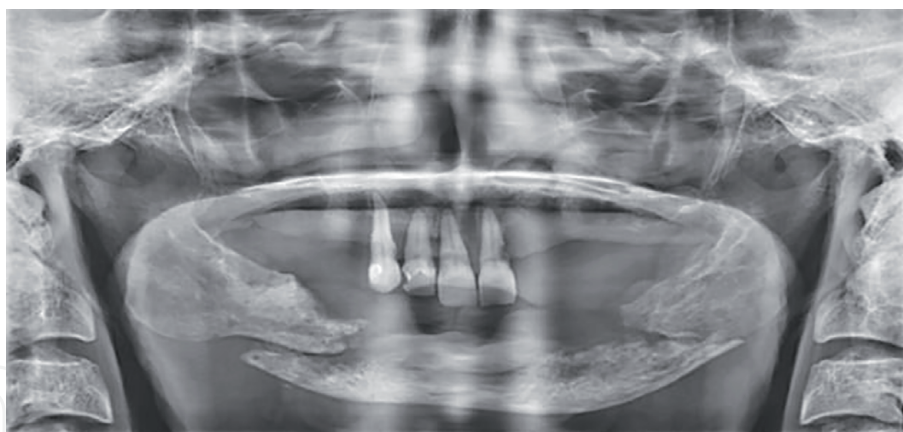


Figure 2.
Spontaneous bilateral mandibular fracture (Aredia).

we often find signs of acute inflammation in the surrounding tissue. In two-thirds of cases, medication-related osteonecrosis is found in the lower jaw [58]. The reason for this is a thinner mucosa than in the upper jaw and poorer blood supply to the lower jaw. Patients suffering from malignant diseases are most predisposed to MRONJ so it is very important to estimate whether the symptoms of progression are consequences osteonecrosis itself or are symptoms of secondaryism. After removal of the necrotic part of the bone, it is recommended to send materials for pathohistological analysis to determine the persistence of necrosis or some other lesions.

7.1 The course of the disease

The course of the disease itself can vary. Lesions can be limited and at dormancy stage or can spread to surrounding structures. MRONJ can spread all the way to the mandibular canal or maxillary sinus. In such cases, there are symptoms such as numbness, sinus infection and even the formation of oroantral communication. By spreading necrotic lesions it can also lead to pathological fractures of the jaw, which are serious, therapeutic and functional problems. Pathological fractures (**Figure 2**) are not common, they occur in 3% of patients who are treated from MRONJ [3].

8. Radiological characteristics of MRONJ

The involvement of the region by medication-related osteonecrosis can be assessed by radiographic analysis. This type of imaging is also useful in monitoring the disease and in diagnosing complications that occur in osteonecrosis such as fractures and sinusitis. By radiological analysis we can detect different stages of the disease and even the zero stage. Two-dimensional panoramic images (**Figure 3**) are recommended as an initial radiographic technique that give an excellent overview of the bones, teeth and the surrounding structure. Sclerosis found in the lamina dura of the alveolar ridge, after radiological examination, is the most common radiological change at risk patients. We can also find others radiological changes that are not so common, namely: sclerosis of the marginal parts of the jaw (most commonly in the mandible), narrowing of the mandibular canal, difficult or complete absence of healing of postextraction alveoli, radiolucent regions around the bone corresponding to osteolysis and necrotic bone sequesters that occur in the later stages of medication-related osteonecrosis [59–61]. More precisely, the lesion can be represented by one of the three-dimensional display techniques such as computed

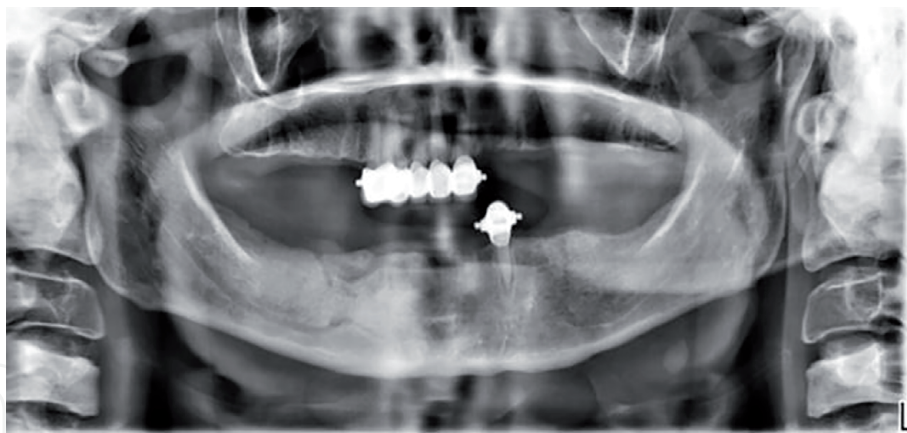


Figure 3.
MRONJ in a patient with multiple myeloma and treated with zoledronic acid (Zometa).

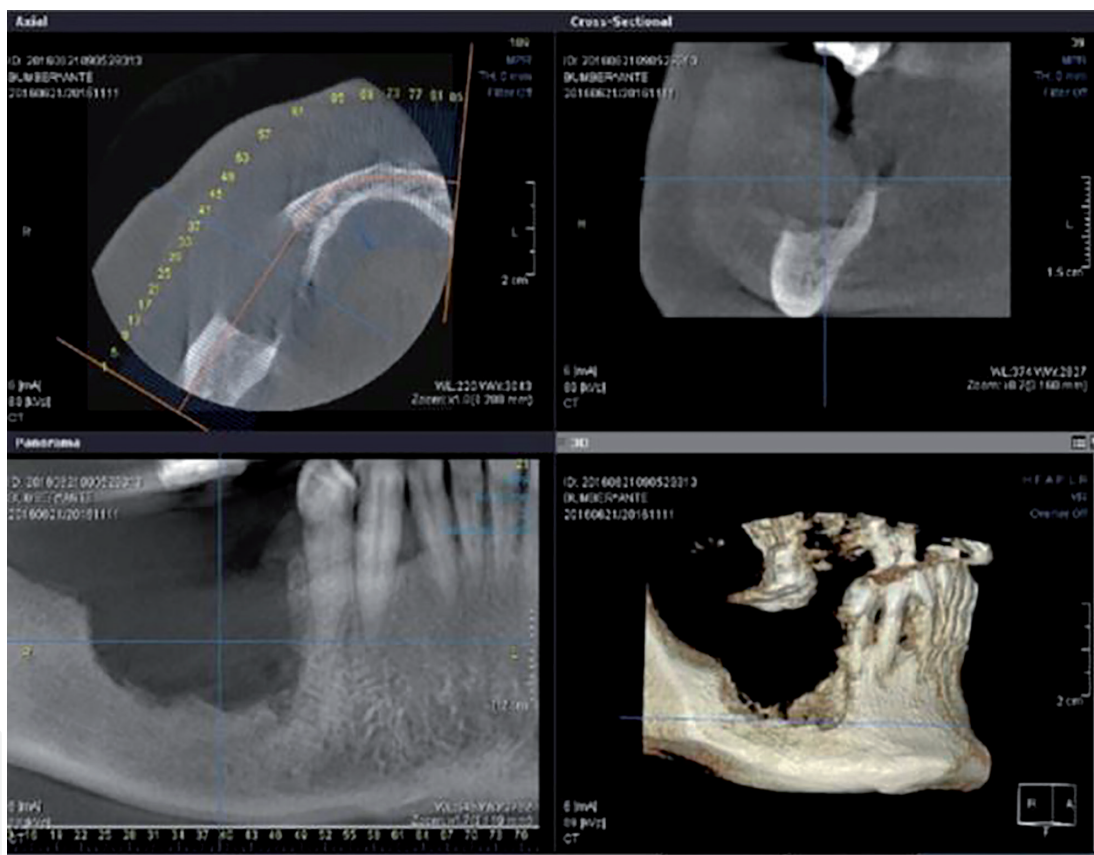


Figure 4.
CBCT scan (of same patient as in Figure 1) after surgical treatment.

tomography or cone-beam computed tomography. In the CBCT scan (**Figure 4**) we can get more precise data on the localization and on the progression of the disease and useful data on the surrounding bone structures. At early diagnosis of MRONJ, magnetic resonance (MRI), single-photon emission computed tomography (SPECT) and positron emission tomography with computed tomography (PET/CT) were also proved as an excellent diagnostic tool [59, 62–67].

9. Classification of MRONJ

The disease, according to the clinical picture and the appearance of symptoms of osteonecrosis, is classified into four stages [3].

9.1 Stage 0

This stage of disease includes patients who have not clinically developed osteonecrosis but have nonspecific symptoms or radiological signs that may be associated with therapy. Symptoms associated with stage zero are: unexplained odontalgia, dull pain of lower jaw extending toward the temporomandibular joint, sinus pain that may be associated with inflammation and narrowing of the bone wall toward the sinus [3]. Clinical findings that may indicate stage zero are: unexplained tooth loss unrelated to chronic periodontal disease, periapical/periodontal fistula unrelated to pulp necrosis or caries, unexplained gingival swelling. Radiological signs are: loss of alveolar bone or resorption not related to chronic periodontitis, changes in the composition of the trabeculae, difficult (delayed) wound healing after tooth extraction, sclerosing regions of the alveolar part (thickening of the lamina dura, or reduction of the space belonging to the periodontal ligament) or surrounding part of the bone [66–68].

Zero-stage therapy is symptomatic and conservative, aimed at remediation of predisposing conditions that can cause osteonecrosis (remediation of caries, periodontal diseases, other pathological conditions, inadequate dentures). It is also necessary to exclude other diseases such as fibroseal lesions, chronic sclerosing osteomyelitis and others.

Patients need to be educated about the disease, about adequate oral hygiene and encouraged to have more frequent check-ups (at least every two months).

9.2 Stage 1

Stage one of the disease describes clinically exposed necrotic bone or the appearance of a fistula that forms from the bone, however patients have no symptoms and no signs of acute infection. The time required for proper diagnosis of the first stage of disease is eight weeks from appearance of exposed bone or fistula [3].

First-stage therapy is primarily aimed at monitoring the lesion. If necrotic bone sequesters or sharp bone margins occur, they should be removed. Monitoring the condition of the surrounding mucosa is extremely important for further prognosis of the disease.

It is also necessary to educate and motivate patients for frequent checkups.

9.3 Stage 2

Stage two describes clinically exposed necrotic bone or the appearance of a fistula that forms from bone with signs of acute infection accompanied by pain [3].

Stage two therapy is initially aimed at repairing the inflammation and antibiotic therapy is often attributed to it in combination with antimicrobial washes (most commonly chlorhexidine). Necrotic bone is often contaminated with bacteria to form biofilms that may be resistant to antibiotic therapy. After repairing the inflammation, it is necessary to remove the necrotic part of the bone and the inflamed mucosa.

9.4 Stage 3

Stage three describes clinically exposed necrotic bone or the appearance of a fistula that forms from bone with signs of acute infection accompanied by pain and at least one of these signs: spreading necrosis outside the dental alveolus (lower edge and ascending part of mandible, maxillary sinus, toward the cheekbone), the appearance of extraoral fistula, osteolysis of the lower border of the lower jaw and

the bottom of the maxillary sinus with the appearance of oroantral communication and the appearance of pathological fractures [3].

Third-stage therapy focuses on palliative therapy that includes debridement or resection of the lesion in combination with antibiotic therapy to eliminate acute infection and pain. Therapy directly depends on the health condition of the patient. If larger resections are performed, reconstruction is performed by different reconstructive methods (fibula graft) with or without obturator.

10. MRONJ treatment protocol

There is currently no gold standard or clearly defined treatment protocol for the disease itself.

If osteonecrosis of the jaw occurs, it is recommended that the patient be referred to an oral or maxillofacial surgery specialist for further treatment.

The goals of therapy are aimed at eliminating inflammation and pain by preventing or slowing the progression of the disease. Before treatment, it is necessary to take a detailed medical and dental history and consult a doctor about the possible removal of the drug. Treatment depends on the degree of the disease and is initially focused on antibiotic therapy in combination with antimicrobial therapy and analgesics. Surgical techniques for removing the necrotic part of the bone include sequestration, ridge modeling, resection of the jaw with various reconstructive methods [3].

American Association of Oral and Maxillofacial Surgeons (AAOMS) recommends starting conservative therapy before surgery [3]. Conservative therapy serves to control the disease itself and is achieved by antibiotic therapy and chlorhexidine rinsing. They believe that elective surgery can lead to further disease progression. If the disease progresses then surgery needs to remove the necrotic lesion. On the other hand, European guidelines recommend the initial surgical removal of the necrotic part of the bone regardless of the degree of the disease for several reasons: the necrotic part of the bone cannot be revitalized and it is the entrance door for colonization of bacteria and fungi [69–71]. Histological processing is recommended to demonstrate necrosis and differential diagnosis in the form of bone metastases, osteomyelitis (inflammatory bone condition) or osteoradionecrosis (radiation-related ischemic bone necrosis) [72].

Surgical procedures have been scientifically proven to perform better compared to a conservative approach [73–76]. Conservative treatment consists of more frequent follow-up examinations (once or twice a week) for months, which is a burden for patients. It should be in mind that frequent check-ups are difficult for oncology patients.

The success of the therapy is achieved when the necrotic part of the bone is removed and when the mucosal integrity of the tissue is established. Treatment of MRONJ should be divided into bone and soft tissue repair. After removal of the necrotic part of the bone or tooth extraction, it is necessary to keep in mind the smoothing or modeling of sharp sclerotic bone edges of the wound because they remodel very slowly and can potentiate the development of necrosis (**Figure 5**). After removal of the necrotic part, it is necessary to process the soft tissue. The aim is to achieve optimal marginal closure of the wound in the form of preventing the penetration of microorganisms, i.e., contamination of the surrounding bone. Mucosal integrity is achieved by primary suturing of the wound without tension. Some surgeons recommend double covering the exposed portion of the bone with a muscle flap (*m. mylohyoideus*) or buccal fat pad flap [77–79]. For larger defects, reconstruction with a microvascular skin or bone graft is recommended, however, it

should be considered that the transplanted bone is also rich in antiresorptive drugs. Major reconstructions depend on the health status of the patients.

The necrotic portion of the bone relative to the surrounding healthy bone tissue may be clearly limited (sequestration formation) or may be diffusely incorporated into healthy bone tissue. Clearly demarcated sequestrars are easily removed during surgery, while diffuse parts are difficult to remove due to the unclear boundary of necrotic from vital bone tissue [80, 81]. Bone bleeding was previously thought to be a sign of vitality (which makes it easier for surgeons to work) however, this has proven to be wrong. For the treatment of diffuse lesions, the use of fluorescence in combination with tetracycline is recommended [82, 83].

11. Photodynamic therapy and MRONJ

There are various additional methods of treatment, in addition to surgical treatment, that promote healing of the lesion. For this purpose oxygen therapy (ozone, hyperbaric chamber), hormone therapy (parathyroid hormone), growth factor (Figure 6) therapy (PRP, PRF, PRGF, BMP), mesenchymal stem cell therapy and a combination of pantophilin and tocopherol [84–88] are used.

Vescovi et al. [89] in 2006 described the application of low-level-laser therapy (LLLT) as possible treatment of osteonecrosis of the jaw. The effect of lasers is classified in two categories, regarding its mW range: biostimulation (LLLT) and photodynamic therapy (PDT). Main difference between this two types is that in biostimulation therapy (LLLT) the laser acts directly on the tissue and aims to

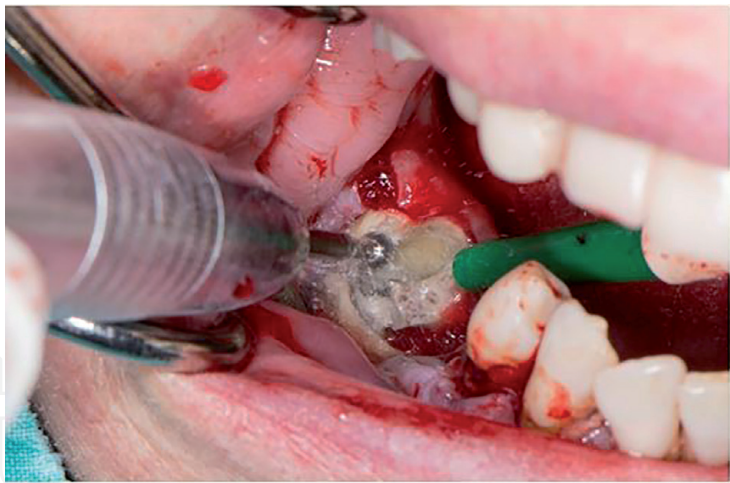

Figure 5.
Surgical treatment- modeling of sharp sclerotic bone edges.

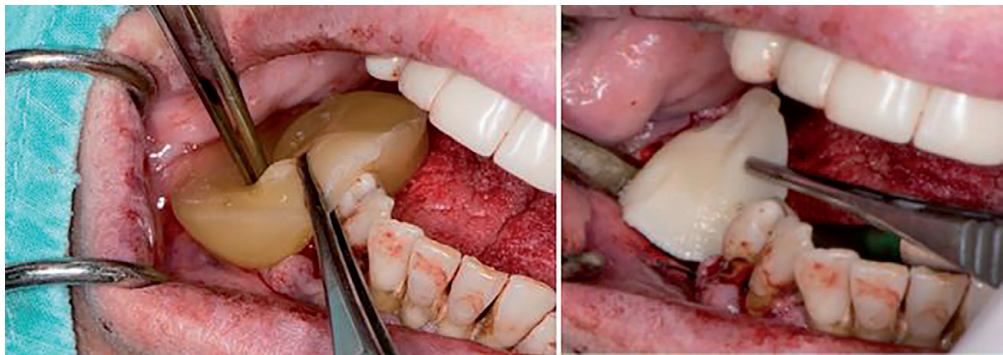


Figure 6.
Augmentation using autologous growth factors; PRGF technique, F2 and F1 phase.

support tissue healing, while in photodynamic therapy (PDT) it acts on chemical medium (photosensitizer) (**Figure 7**) which induces cell (e.g. bacteria) and tissue damage as a chemical effect [90].

LLLT has from clinical point of view become adjuvant medical tool for enhancing wound-healing process, so some clinical studies reported laser-induced stimulation especially of soft tissue healing such as ulcers and postoperative wound dehiscences [91, 92]. Stein et al. [93]. in their *in vitro* study confirmed that low energy laser irradiation promotes proliferation and maturation of human osteoblasts, while stimulating effect of LLLT is explained by an increase of ATP in affected cells [94].

Photodynamic therapy (PDT) is being increasingly used in the management of MRONJ in combination with other therapeutic choices [90].

In the beginning photodynamic therapy (PDT) was used particularly to treat cancer and several studies have shown its antimicrobial potency [95–98]. Analyzing the effects of PDT on osteoblasts growth, study by Zancanela et al. [99] showed that PDT results in biostimulation of osteoblastic cell cultures or a cytotoxic effect depends of the applied dose. PDT has well documented clinical impact as adjuvant local treatment of ulcers and infected wounds, and potential indications for therapy of periodontitis and peri-implantitis, but treatment of MRONJ still in phase of collecting clinical results [100–105]. Treatment concept of MRONJ with PDT describes its use for symptomatic treatment in stage 0, preoperatively to reduce bacterial load and in cases with healing deficiencies, while in stages 1, 2 and 3 it is used after surgical treatment. Also it may be used as adjuvant conservative intervention for palliative therapy of compromised patients or in cases to avoid progression of disease when patients refuse surgery.

While application of LLLT for therapy of MRONJ has been described in numerous studies, there are few studies mainly focused on impact of photodynamic therapy of preventing occurrence of MRONJ. Vescovi et al. [89] used Nd:YAG laser biostimulation in addition to medical and surgical therapy and demonstrate a better healing tendency due to bony ablation, bactericidal and detoxification effect [106, 107]. Da Guarda et al. [108] reported a case of successful MRONJ treatment with the GaAlAs diode laser in combination with bone curettage. Summarizing the literature, use of LLLT is beneficial for treatment of MRONJ, although till today there are no large studies that proves significant improvement.

One of promoting factor in mechanism of MRONJ is presence of microflora. Species such as *Fusobacterium*, *Eikenella*, *Bacillus*, *Actinomyces*, *Staphylococcus*, and *Streptococcus* are predisposed to survive in oxygen depleted areas of necrotic bone that lack blood supply [109, 110]. Although the identification of microbial biofilms

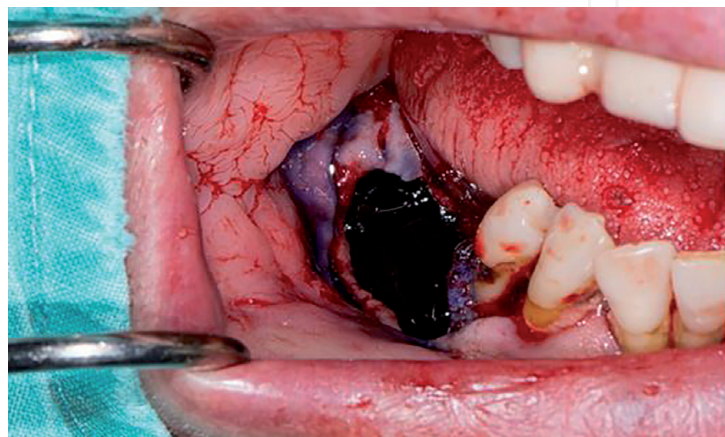


Figure 7.
Application of chemical medium (photosensitizer)- toluidine blue.

and *Actinomyces* species as the leading bacterial pathogen isolated from patients with MRONJ, there is unclear definitive treatment and no data referring to bactericidal activity of laser therapy against *Actinomyces* species in MRONJ lesions.

The most used PDT system is one with mobile diode laser and dye (HELBO) with methylene blue (MB) (**Figure 8**). It has shown very promising results during surgical procedures or as adjuvant therapy in cases of postoperative wound dehiscences in patients with MRONJ. Photosensitizers's antimicrobial activity is mediated by singlet oxygen, which has high chemical reactivity and results with a direct effect on extracellular molecules. The polysaccharides present in extracellular matrix of a bacterial biofilm are sensitive to photodamage, so breaking biofilms can interrupt colonization and prevent antibiotic resistance [111].

Although is surgical treatment first option to deal with MRONJ, appliance of photodynamic therapy has several advantages. Before surgery usually we treat symptoms of MRONJ infection, such as swelling, purulent discharge and pain. They can be managed by bio-stimulative effect of the laser, especially those with advanced primary disease or those suffering from other sickness resulting in a general poor health [90]. PDT might be very sufficient in early stages of osteonecrosis promoting secondary granulation and formation of mucosal coverage, so surgery can be avoid. Unfortunately there are no controlled studies opposing PDT and LLLT to evaluate use of photosensitizer. Appliance of photodynamic therapy immediately after surgery could decrease complications of impaired healing of the wound (**Figure 9**).

In conclusion, although MRONJ is considered difficult to treat and may even be recalcitrant to therapy, photodynamic therapy can be a viable supportive tool

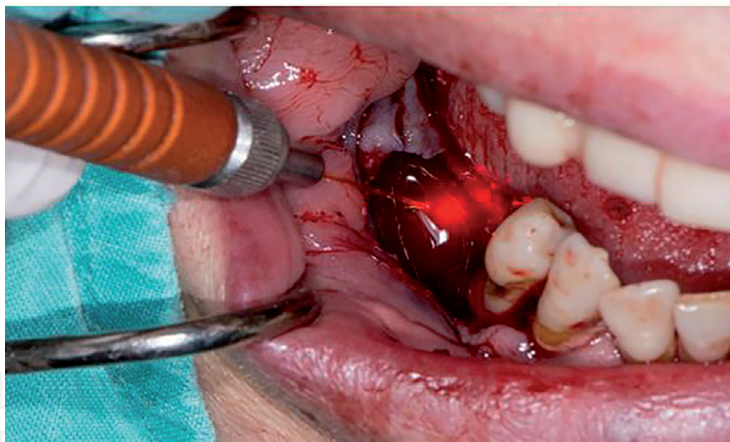

Figure 8.
Antimicrobial photodynamic therapy using low-power diode laser (aPDT mode, LaserHF, HagermannWerken).

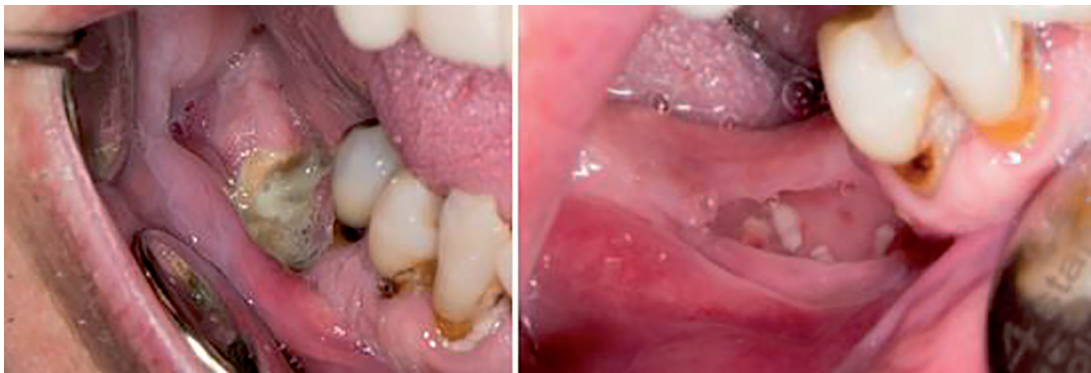

Figure 9.
MRONJ before and 2 months after treatment with combined therapy (surgery/aPDT/PRGF).

of initial and advanced stages of MRONJ, as an adjuvant treatment before or after surgery or primary treatment in cases without surgery indicated.

Conflict of interest

The authors declare no conflict of interest.

Author details

Marko Vuletić¹, Božana Lončar Brzak², Igor Smojver³, Luka Marković⁴, Mato Sušić¹ and Dragana Gabrić^{1*}

¹ Department of Oral Surgery, School of Dental Medicine, University of Zagreb, Clinical Hospital Center Zagreb, Croatia

² Department of Oral Medicine, School of Dental Medicine, University of Zagreb, Clinical Hospital Center Zagreb, Croatia

³ Special Hospital St. Catherine, Zagreb, Croatia

⁴ Department of Periodontology, School of Dental Medicine, University of Zagreb, Private Dental Clinic, Pula, Croatia

*Address all correspondence to: dgabric@sfzg.hr

IntechOpen

© 2020 The Author(s). Licensee IntechOpen. This chapter is distributed under the terms of the Creative Commons Attribution License (<http://creativecommons.org/licenses/by/3.0>), which permits unrestricted use, distribution, and reproduction in any medium, provided the original work is properly cited. 

References

- [1] Marx RE. Pamidronate (Aredia) and zoledronate (Zometa) induced avascular necrosis of the jaws: a growing epidemic [Letter]. *J Oral Maxillofac Surg.* 2003;61:1115.
- [2] Bartl R, Frisch B, von Tresckow E, Bartl C. Bisphosphonates in medical practice actions, side effects, indication, strategies. Berlin/New York; Springer: 2007.
- [3] Ruggiero SL, Dodson TB, Fantasia J, et al. American Association of Oral Maxillofacial Surgeons position paper on medication-related osteonecrosis of the jaw-2014 update. *J Oral Maxillofac Surg.* 2014; 72:1938-1956.
- [4] Khan AA, Morrison A, Hanley DA, et al. Diagnosis and management of osteonecrosis of the jaw: a systematic review and international consensus. *J Bone Miner Res.* 2015;30:3-23.
- [5] Fassio A, Bertoldo F, Idolazzi L, Viapiana O, Rossini M, Gatti D. Drug-induced osteonecrosis of the jaw: the state of the art. *Reumatismo.* 2017;69:9-15.
- [6] Fedele S, Bedogni G, Scoletta M, et al. Up to a quarter of patients with osteonecrosis of the jaw associated with antiresorptive agents remain undiagnosed. *Br J Oral Maxillofac Surg.* 2015;53:13-17.
- [7] Schiodt M, Reibel J, Oturai P, Kofod T. Comparison of nonexposed and exposed bisphosphonate-induced osteonecrosis of the jaws: a retrospective analysis from the Copenhagen cohort and a proposal for an updated classification system. *Oral Surg Oral Med Oral Pathol Oral Radiol.* 2014;117:204-213.
- [8] Patel S, Choyee S, Uyanne J, et al. Non-exposed bisphosphonate-related osteonecrosis of the jaw: a critical assessment of current definition, staging, and treatment guidelines. *Oral Dis.* 2012;18:625-632.
- [9] Troeltzsch M, Woodlock T, Kriegelstein S, Steiner T, Messlinger K. Physiology and pharmacology of nonbisphosphonate drugs implicated in osteonecrosis of the jaw. *J Can Dent Assoc.* 2012;78:c85.
- [10] Ortega J, Vigil CE, Chodkiewicz C, Current progress sin targeted therapy for colorectal cancer. *Cancer control.* 2010;17:7-15.
- [11] Hopp RN, Pucci J, Santos-Silva AR, Jorge J. Osteonecrosis after administration of intravitreal bevacizumab. *J Oral Maxillofac Surg.* 2011;70:632-635.
- [12] Estilo CL, Fornier M, Farooki A, Carlson D, Bohle 3rd G, Huryn JM. Osteonecrosis of the jaw related to bevacizumab. *J Clin Oncol.* 2008;26:4037-4038.
- [13] Mena AC, Pulido EG, Guillen-Ponce C. Understanding the molecular-based mechanism of action of the tyrosine kinase inhibitor: sunitinib. *Anticancer Drugs.* 2010;21:S3-11.
- [14] Diel IJ, Bergner R, Grötz KA. Adverse effects of bisphosphonates: current issues. *J Support Oncol.* 2007;5:475-482.
- [15] Honig S, Chang G. Osteoporosis: an update. *Bull NYU Hosp Jt Dis.* 2012;70:140-144.
- [16] Shkolnikova J, Flynn J, Choong P. Burden of bisphosphonate-associated femoral fractures. *ANZ J Surg.* 2013;83:175-181. doi:10.1111/ans.12018
- [17] Orozco C, Maalouf NM. Safety of bisphosphonates. *Rheum Dis Clin North*

Am. 2012;38:681-705. doi:10.1016/j.rdc.2012.09.001

[18] Lasseter KC, Porras AG, Denker A, Santhanagopal A, Daifotis A. Pharmacokinetic considerations in determining the terminal elimination half-lives of bisphosphonates. Clin Drug Investig. 2005;25:107-114. doi:10.2165/00044011-200525020-00003

[19] Hampson G, Fogelman I. Clinical role of bisphosphonate therapy. Int J Womens Health. 2012;4:455-469. doi:10.2147/IJWH.S24783

[20] Abdelmoula LC, Ben M'barek R, Ben Hadj Yahia C, et al. Indications des bisphosphonates dans les affections osseuses autres que l'ostéoporose [Bisphosphonates: indications in bone diseases other than osteoporosis]. Tunis Med. 2011;89:511-516.

[21] Otto S, Pautke C, Van den Wyngaert T, Niepel D, Schiødt M. Medication-related osteonecrosis of the jaw: Prevention, diagnosis and management in patients with cancer and bone metastases. Cancer Treat Rev. 2018;69:177-187. doi:10.1016/j.ctrv.2018.06.007

[22] Then C, et al. Incidence and risk factors of bisphosphonate related osteonecrosis of the jaw in multiple myeloma patients having undergone autologous stem cell transplantation. Onkologie. 2012;35:658-664.

[23] Zavras AI. The impact of bisphosphonates on oral health: lessons from the past and opportunities for the future. Ann NY Acad Sci. 2011;1218:55-61.

[24] Berenson JR, Hillner BE, Kyle RA, et al. American Society of Clinical Oncology clinical practice guidelines: the role of bisphosphonates in multiple myeloma. J Clin Oncol. 2002;20:3719-3736. doi:10.1200/JCO.2002.06.037

[25] Cummings SR, San Martin J, McClung MR, Siris ES, Eastell R, Reid IR, et al. Denosumab for prevention of fractures in postmenopausal women with osteoporosis. N Engl J Med. 2009;361:756-765.

[26] Van den Wyngaert T, Claeys T, Huizing MT, Vermorken JB, Fossion E. Initial experience with conservative treatment in cancer patients with osteonecrosis of the jaw [ONJ] and predictors of outcome. Ann Oncol. 2009;20:331-336.

[27] Henry DH, Costa L, Goldwasser F, Hirsh V, Hungria V, Prausova J, et al. Randomized, double-blind study of denosumab versus zoledronic acid in the treatment of bone metastases in patients with advanced cancer [excluding breast and prostate cancer] or multiple myeloma. J Clin Oncol. 2011;29:1125-1132.

[28] Rx List Inc. Denosumab. [Internet] Available at: www.rxlist.com/prolia-drug/clinicalpharmacology.htm. Accessed 2020. August 10 th.

[29] Estilo CL, Fornier M, Farooki A, Carlson D, Bohle G 3rd, Huryn JM. Osteonecrosis of the jaw related to bevacizumab. J Clin Oncol. 2008;26:4037-4038. doi:10.1200/JCO.2007.15.5424

[30] Wimalawansa SJ. Insight into bisphosphonate-associated osteomyelitis of the jaw: pathophysiology, mechanisms and clinical management. Expert Opin Drug Saf. 2008;7:491-512.

[31] Marx RE, Sawstari Y, Fortin M, et al. Bisphosphonate-induced exposed bone [osteonecrosis/osteoporosis] of the jaws: risk factors, recognition, prevention, and treatment. J Oral Maxillofac Surg. 2005 Nov; 63:1567-1575.

[32] Walter C, Klein MO, Pabst A, Al-Nawas B, Duschner H,

- Ziebart T. Influence of bisphosphonates on endothelial cells, fibroblasts, and osteogenic cells. *Clin Oral Investig*. 2010;14:35-41.
- [33] Walter C, Pabst A, Ziebart T, Klein M, Al-Nawas B. Bisphosphonates affect migration ability and cell viability of HUVEC, fibroblasts and osteoblasts in vitro. *Oral Dis*. 2011;17:194-199.
- [34] Hansen T, Kunkel M, Springer E, Walter C, Weber A, Siegel E, Kirkpatrick CJ. Actinomycosis of the jaws-histopathological study of 45 patients shows significant involvement in bisphosphonate-associated osteonecrosis and infected osteoradionecrosis. *Virchows Arch*. 2007;451:1009-1017.
- [35] Landesberg R, Woo V, Cermers S, et al. Potential pathophysiological mechanisms in osteonecrosis of the jaw. *Ann NY Acad Sci*. 2011;1218:62-79.
- [36] Yoneda T. Bisphosphonate-related osteonecrosis of jaw: position paper from the Allied Task Force Committee of Japanese Society for Bone and Mineral Research, Japan Osteoporosis Society, Japanese Society of Periodontology, Japanese Society of Oral and Maxillofacial Radiology, and Japanese Society of Oral and Maxillofacial Surgeons. *J Bone Miner Metab*. 2010;28:365-383.
- [37] Thumbigere-Math V, Sabino MC, Gopalakrishnan R, et al. Bisphosphonate-related osteonecrosis of the jaw: clinical features, risk factors, management, and treatment outcomes of 26 patients. *J Oral Maxillofac Surg*. 2009;67:1904-1913. doi:10.1016/j.joms.2009.04.051
- [38] Otto S, Hafner S, Grötz KA. The role of inferior alveolar nerve involvement in bisphosphonate-related osteonecrosis of the jaw. *J Oral Maxillofac Surg*. 2009;67:589-592. doi:10.1016/j.joms.2008.09.028
- [39] Khosla S, Burr D, Cauley J, et al. Bisphosphonate-associated osteonecrosis of the jaw: report of a task force American Society for Bone and Mineral Research. *J Bone Miner Res*. 2007 Oct; 22:1479-1491.
- [40] Lo JC, O’Ryan FS, Gordon NP, Yang J, Hui RL, Martin D, et al. Prevalence of osteonecrosis of the jaw in patients with oral bisphosphonate exposure. *J Oral Maxillofac Surg*. 2010;68:243-253.
- [41] Jadu F, Lee L, Pharoah M, Reece D, Wang L. A retrospective study assessing the incidence, risk factors and comorbidities of pamidronate-related necrosis of the jaws in multiple myeloma patients. *Ann Oncol*. 2007;18:2015-2019.
- [42] Thumbigere-Math V, Tu L, Huckabay S, Dudek AZ, Lunos S, Basi DL, et al. A retrospective study evaluating frequency and risk factors of osteonecrosis of the jaw in 576 cancer patients receiving intravenous bisphosphonates. *Am J Clin Oncol*. 2012;35:386-392.
- [43] Hoff AO, Toth BB, Altudag K, Johnson MM, Warneke CL, Hu M, et al. Frequency and risk factors associated with osteonecrosis of the jaw in cancer patients related with intravenous bisphosphonates. *J Bone Miner Res*. 2008;23:826-836.
- [44] Fehm T, Beck V, Banys M, Lipp HP, Hairass M, Reinert S, et al. Bisphosphonate-induced osteonecrosis of the jaw [ONJ]: incidence and risk factors in patients with breast cancer and gynecological malignancies. *Gynecol Oncol*. 2009;112:605-609.
- [45] Then C, Harauf N, Otto S, Pautke C, von Tresckow E, Rohnisch T, et al. Incidence and risk

factors of bisphosphonate-related osteonecrosis of the jaw in multiple myeloma patients having undergone autologous stem cell transplantation. *Onkologie*. 2012;35:658-664.

[46] Lasseter KC, Porras AG, Denker A, et al. Pharmacokinetic considerations in determining the terminal elimination half-lives of bisphosphonates. *Clin Drug Investig*. 2005;25:107-114.

[47] Marx RE, Cillo JE, Jr., Ulloa JJ. Oral bisphosphonate-induced osteonecrosis: risk factors, prediction of risk using serum CTX testing, prevention, and treatment. *J Oral Maxillofac Surg*. 2007;65:2397-2410.

[48] Aghaloo TL, Kang B, Sung EC, et al. Periodontal disease and bisphosphonates induced osteonecrosis of the jaws in the rat. *J Bone Miner Res*. 2011;26:1871-1882.

[49] Neviaser AS, Lane JM, Lenart BA, et al. Low-energy femoral shaft fractures associated with alendronate use. *J Orthop Trauma*. 2008; 22:346-350.

[50] O’Ryan FS, Lo JC. Bisphosphonate-related osteonecrosis of the jaw in patients with oral bisphosphonate exposure: clinical course and outcomes. *J Oral Maxillofac Surg*. 2012;70:1844-1853.

[51] Di Fede O, Fusco V, Matranga D, Solazzo L, Gabriele M, Gaeta GM, et al. Osteonecrosis of the jaws in patients assuming oral bisphosphonates for osteoporosis: a retrospective multi-hospital-based study of 87 Italian cases. *Eur J Intern Med*. 2013;11.

[52] Malden N, Lopes V. An epidemiological study of alendronate-related osteonecrosis of the jaws. A case series from the south-east of Scotland with attention given to case definition and prevalence. *J Bone Miner Metab*. 2012;30:171-182.

[53] Diniz-Freitas M, Lopez-Cendrun JL, Fernandez-Sanroman J, Garcia-Garcia A, Fernandez-Feijoo J, Diz-Dios P. Oral bisphosphonate-related osteonecrosis of the jaws: clinical characteristics of a series of 20 cases in Spain. *Med Oral Patol Oral Cir Bucal*. 2012;17:751-758.

[54] Zhong DN, Wu JZ, Li GJ. Association between CYP2C8 [rs1934951] polymorphism and bisphosphonate-related osteonecrosis of the jaws in patients on bisphosphonate therapy: a meta-analysis. *Acta Haematol*. 2013;129:90-95. doi:10.1159/000342120

[55] American Association of Oral and Maxillofacial Surgeons. Position paper on bisphosphonate-related osteonecrosis of the jaws. *J Oral Maxillofac Surg*. 2007;65:369-376.

[56] Otto S, Schreyer C, Hafner S, Mast G, Ehrenfeld M, Stürzenbaum S, et al. Bisphosphonate-related osteonecrosis of the jaws- characteristics, risk factors, clinical features, localization and impact on oncological treatment. *J Craniomaxillofac Surg*. 2012;40:303-309

[57] Otto S. Medication Related Osteonecrosis of the Jaw: Bisphosphonates, Denosumab, and New Agents. Berlin, Heidelberg. Springer 2015; 220 p.

[58] Assaf AT, Zrnc TA, Riecke B, Winker J, Zustin J, Friedrich RE, et al. Intraoperative efficiency of fluorescence imaging by Visually Enhanced Lesion Scope [VELscope®] in patients with bisphosphonate related osteonecrosis of the jaw [MRONJ]. *J Craniomaxillofac Surg*. 2013;42:157-164.

[59] Arce K, Assael LA, Weissman JL, et al. Imaging findings in bisphosphonate-related osteonecrosis of jaws. *J Oral Maxillofac Surg*. 2009;67:S75-84.

- [60] Bedogni A, Blandamura S, Lokmic Z, et al. Bisphosphonate-associated jaw bone osteonecrosis: a correlation between imaging techniques and histopathology. *Oral Surg Oral Med Oral Pathol Oral Radiol Endod.* 2008;105:358-364
- [61] Bianchi SD, Scoletta M, Cassione FB, et al. Computerized tomographic findings in bisphosphonate-associated osteonecrosis of the jaw in patients with cancer. *Oral Surg Oral Med Oral Pathol Oral Radiol Oral Endod.* 2007;104:249-258.
- [62] Chiandussi S, Biasotto M, Dore F, Cavalli F, Cova MA, Di Lenarda R. Clinical and diagnostic imaging of bisphosphonate-associated osteonecrosis of the jaws. *Dentomaxillofac Radiol.* 2006;35:236-243.
- [63] O’Ryan FS, Khoury S, Liao W, Han MM, Hui RL, Baer D, et al. Intravenous bisphosphonate-related osteonecrosis of the jaw: bone scintigraphy as an early indicator. *J Oral Maxillofac Surg.* 2009;67:1363-1372.
- [64] Tsao C, Darby I, Ebeling PR, Walsh K, O’Brien-Simpson N, Reynolds E, et al. Oral health risk factors for bisphosphonate-associated jaw osteonecrosis. *J Oral Maxillofac Surg.* 2013;71:1360-1366.
- [65] Saad F, Brown JE, Van Poznak C, Ibrahim T, Stemmer SM, Stopeck AT, et al. Incidence, risk factors, and outcomes of osteonecrosis of the jaw: integrated analysis from three blinded active-controlled phase III trials in cancer patients with bone metastases. *Ann Oncol.* 2012; 23:1341-1347.
- [66] Hutchinson M, O’Ryan F, Chavez V, Lathon PV, Sanchez G, Hatcher DC, et al. Radiographic findings in bisphosphonate-treated patients with stage 0 disease in the absence of bone exposure. *J Oral Maxillofac Surg.* 2010;68:2232-2240.
- [67] Aghaloo TL, Dry SM, Mallya S, Tetradis S. Stage 0 osteonecrosis of the jaw in a patient on denosumab. *J Oral Maxillofac Surg.* 2014;72:702-716.
- [68] Farias DS, Zen Filho EV, de Oliveira TF, Tinôco-Araújo JE, Sampieri MB, Antunes HS, et al. Clinical and image findings in bisphosphonate-related osteonecrosis of the jaws. *J Craniofac Surg.* 2013;24:1248-1250.
- [69] Groetz KA, Piesold JU, Al-Nawas B. Bisphosphonatassoziierte Kiefernekrose [BP-ONJ] und andere Medikamenten-assoziierte Kiefernekrosen. AWMF online www.awmf.org. 2012.
- [70] Schipmann S, Metzler P, Rossle M, Zemmann W, von Jackowski J, Obwegeser JA, et al. Osteopathology associated with bone resorption inhibitors – which role does *Actinomyces* play? A presentation of 51 cases with systematic review of the literature. *J Oral Pathol Med.* 2013;42:587-593.
- [71] Sedghizadeh PP, Kumar SK, Gorur A, Schaudinn C, Shuler CF, Costerton JW. Identification of microbial biofilms in osteonecrosis of the jaws secondary to bisphosphonate therapy. *J Oral Maxillofac Surg.* 2008;66:767-775.
- [72] Otto S, Schuler K, Ihrler S, Ehrenfeld M, Mast G. Osteonecrosis or metastases of the jaw or both? Case report and review of the literature. *J Oral Maxillofac Surg.* 2010;68:1185-1188.
- [73] Lesclous P, Grabar S, Abi Najm S, Carrel JP, Lombardi T, Saffar JL, et al. Relevance of surgical management of patients affected by bisphosphonate-associated osteonecrosis of the jaws. A prospective clinical and

radiological study. Clin Oral Investig. 2014;18:391-399.

[74] Stockmann P, Vairaktaris E, Wehrhan F, Seiss M, Schwarz S, Spriewald B, et al. Osteotomy and primary wound closure in bisphosphonate-associated osteonecrosis of the jaw: a prospective clinical study with 12 months follow-up. Support Care Cancer. 2010;18:449-460.

[75] Voss PJ, Joshi Oshero J, Kovalova-Muller A, Veigel Merino EA, Sauerbier S, Al-Jamali J, et al. Surgical treatment of bisphosphonate-associated osteonecrosis of the jaw: technical report and follow up of 21 patients. J Craniomaxillofac Surg. 2012;40:719-725.

[76] Carlson ER, Basile JD. The role of surgical resection in the management of bisphosphonate-related osteonecrosis of the jaws. J Oral Maxillofac Surg. 2009;67:85-95.

[77] Lemound J, Eckardt A, Kokemuller H, von See C, Voss PJ, Tavassol F, et al. Bisphosphonate-associated osteonecrosis of the mandible: reliable soft tissue reconstruction using a local myofascial fl ap. Clin Oral Investig. 2012;16:1143-1152.

[78] Mast G, Otto S, Mucke T, Schreyer C, Bissinger O, Kolk A, et al. Incidence of maxillary sinusitis and oroantral fistulae in bisphosphonate-related osteonecrosis of the jaw. J Craniomaxillofac Surg. 2012;40:568-571.

[79] Gallego L, Junquera L, Pelaz A, Hernando J, Megias J. The use of pedicled buccal fat pad combined with sequestrectomy in bisphosphonate-related osteonecrosis of the maxilla. Med Oral Patol Oral Cir Bucal. 2012;17:236-241.

[80] Advisory Task Force on Bisphosphonate-Related Osteonecrosis of the Jaws, American Association of Oral and Maxillofacial Surgeons. J Oral Maxillofac Surg. 2007;65:369-376.

[81] Khosla S, Burr D, Cauley J, Dempster DW, Ebeling PR, Felsenberg D, et al. Bisphosphonate-associated osteonecrosis of the jaw: report of a task force of the American Society for Bone and Mineral Research. J Bone Miner Res. 2007;22:1479-1491.

[82] Wang J, Goodger NM, Pogrel MA. Osteonecrosis of the jaws associated with cancer chemotherapy. J Oral Maxillofac Surg. 2003;61:1104-1107.

[83] Harris WH. A microscopic method of determining rates of bone growth. Nature. 1960;188:1039-1049.

[84] Cella L, Oppici A, Arbasi M, Moretto M, Piepoli M, Vallisa D, et al. Autologous bone marrow stem cell intralesional transplantation repairing bisphosphonate related osteonecrosis of the jaw. Head Face Med. 2011;7:16.

[85] Curi MM, Cossolin GS, Koga DH, Zardetto C, Christianini S, Feher O, et al. Bisphosphonate-related osteonecrosis of the jaws—an initial case series report of treatment combining partial bone resection and autologous platelet-rich plasma. J Oral Maxillofac Surg. 2011;69:2465-2472.

[86] Dayisoğlu EH, Ungor C, Tosun E, Ersoz S, Duman MK, Taskesen F, et al. Does an alkaline environment prevent the development of bisphosphonate-related osteonecrosis of the jaw? An experimental study in rats. Oral Surg Oral Med Oral Pathol Oral Radiol. 2014;117:329-334.

[87] Cheung A, Seeman E. Teriparatide therapy for alendronate-associated osteonecrosis of the jaw. N Engl J Med. 2010;363:2473-2474.

- [88] Dayisoğlu EH, Senel FC, Ungor C, Tosun E, Cankaya M, Ersoz S, et al. The effects of adjunctive parathyroid hormone injection on bisphosphonate-related osteonecrosis of the jaws: an animal study. *Int J Oral Maxillofac Surg*. 2013;42:1475-1480.
- [89] Vescovi P, Merigo E, Meleti M, Manfredi M. Bisphosphonate-associated osteonecrosis [BON] of the jaws: a possible treatment? *J Oral Maxillofac Surg* 2006;64:1460-1462.
- [90] Rugani P, Truschnegg A, Acham S, Kirnbauer B, Jakse N. Use of Photodynamic Therapy in Treatment of Bisphosphonate-related Osteonecrosis of the Jaws: Literature Review and Case Series. *J Anal Bioanal Tech*. 2013;S1:006. doi:10.4172/2155-9872.S1-006
- [91] Mester E, Mester AF, Mester A. The biomedical effects of laser application. *Lasers Surg Med*. 1985;5:31-39.
- [92] Liao HF, Chen QJ, Yi JL, Feng Z, Zhang XR, et al. Semiconductor low level laser irradiation for exposure of hydroxyapatite orbital implants. *Zhonghua Zheng Xing Wai Ke Za Zhi*. 2004;20:177-179.
- [93] Stein A, Benayahu D, Maltz L, Oron U. Low-level laser irradiation promotes proliferation and differentiation of human osteoblasts in vitro. *Photomed Laser Surg*. 2005;23:161-166.
- [94] Karu T, Pyatibrat L, Kalendo G. Irradiation with He-Ne laser increases ATP level in cells cultivated in vitro. *J Photochem Photobiol B*. 1995;27:219-223.
- [95] Hamblin MR, Hasan T. Photodynamic therapy: a new antimicrobial approach to infectious disease? *Photochem Photobiol Sci*. 2004;3:436-450.
- [96] Meisel P, Kocher T. Photodynamic therapy for periodontal diseases: state of the art. *J Photochem Photobiol B*. 2005;79:159-170.
- [97] Komerik N, MacRobert AJ. Photodynamic therapy as an alternative antimicrobial modality for oral infections. *J Environ Pathol Toxicol Oncol*. 2006;25:487-504.
- [98] Donnelly RF, McCarron PA, Tunney MM, David Woolfson A. Potential of photodynamic therapy in treatment of fungal infections of the mouth. Design and characterisation of a mucoadhesive patch containing toluidine blue O. *J Photochem Photobiol B*. 2007;86:59-69.
- [99] Zancanela DC, Primo FL, Rosa AL, Ciancaglini P, Tedesco AC. The effect of photosensitizer drugs and light stimulation on osteoblast growth. *Photomed Laser Surg*. 2011;29:699-705.
- [100] Morley S, Griffiths J, Philips G, Moseley H, O'Grady C, et al. Phase IIa randomized, placebo-controlled study of antimicrobial photodynamic therapy in bacterially colonized, chronic leg ulcers and diabetic foot ulcers: a new approach to antimicrobial therapy. *Br J Dermatol*. 2013;168:617-624.
- [101] Peplow PV, Chung TY, Baxter GD. Photodynamic modulation of wound healing: a review of human and animal studies. *Photomed Laser Surg*. 2012;30:118-148.
- [102] Simonetti O, Cirioni O, Orlando F, Alongi C, Lucarini G, et al. Effectiveness of antimicrobial photodynamic therapy with a single treatment of RLP068/Cl in an experimental model of *Staphylococcus aureus* wound infection. *Br J Dermatol*. 2011;164:987-995.
- [103] Haas R, Dörtbudak O, Mensdorff-Pouilly N, Mailath G. Elimination of bacteria on different implant surfaces through photosensitization and soft laser. An in vitro study. *Clin Oral Implants Res*. 1997;8:249-254.

[104] Takasaki AA, Aoki A, Mizutani K, Schwarz F, Sculean A, et al. Application of antimicrobial photodynamic therapy in periodontal and peri-implant diseases. *Periodontol* 2000. 2009;51:109-140.

[105] Raghavendra M, Koregol A, Bhola S. Photodynamic therapy: a targeted therapy in periodontics. *Aust Dent J*. 2009;54 Suppl 1:102-109.

[106] Sasaki KM, Aoki A, Ichinose S, Ishikawa I. Ultrastructural analysis of bone tissue irradiated by Er:YAG Laser. *Lasers Surg Med*. 2002;31:322-332.

[107] Pourzarandian A, Watanabe H, Aoki A, Ichinose S, Sasaki KM, et al. Histological and TEM examination of early stages of bone healing after Er:YAG laser irradiation. *Photomed Laser Surg*. 2004; 22:342-350.

[108] da Guarda MG, Paraguassú GM, Cerqueira NS, Cury PR, Farias JG, et al. Laser GaAlAs [λ 860 nm] photobiomodulation for the treatment of bisphosphonate-induced osteonecrosis of the jaw. *Photomed Laser Surg*. 2012;30:293-297.

[109] Hansen T, Kunkel M, Springer E, Walter C, Weber A, et al. Actinomycosis of the jaws--histopathological study of 45 patients shows significant involvement in bisphosphonate-associated osteonecrosis and infected osteoradionecrosis. *Virchows Arch*. 2007;451:1009-1017.

[110] Sedghizadeh PP, Yooseph S, Fadrosh DW, Zeigler-Allen L, Thiagarajan M, et al. Metagenomic investigation of microbes and viruses in patients with jaw osteonecrosis associated with bisphosphonate therapy. *Oral Surg Oral Med Oral Pathol Oral Radiol*. 2012;114:764-770.

[111] Konopka K, Goslinski T. Photodynamic therapy in dentistry. *J Dent Res*. 2007;86:694-707.