

We are IntechOpen, the world's leading publisher of Open Access books Built by scientists, for scientists

6,900

Open access books available

186,000

International authors and editors

200M

Downloads

Our authors are among the

154

Countries delivered to

TOP 1%

most cited scientists

12.2%

Contributors from top 500 universities



WEB OF SCIENCE™

Selection of our books indexed in the Book Citation Index
in Web of Science™ Core Collection (BKCI)

Interested in publishing with us?
Contact book.department@intechopen.com

Numbers displayed above are based on latest data collected.
For more information visit www.intechopen.com



Laparoscopic Right Colectomy. Intracorporeal Anastomosis Is Associated with Better Outcome

Giulio Aniello Santoro, Simone Novello, Ugo Grossi, Martino Zucchella, Andrea Kazemi Nava and Giacomo Zanusi

Abstract

Colon cancer is the third most common cancer in man and woman in the developed world. Laparoscopic right colectomy is the standard of care for right colon cancer. Since the first report on laparoscopic approach in 1991, the surgical technique has been improved and currently all procedure is performed intracorporeally. The ileo-colic anastomosis can be performed either intracorporeal and extracorporeal: the differences in clinical outcome, complications rate, hospital stay and quality of life between that two techniques are not still clear and a large number of studies has been published about that. According to most recent meta-analysis, intracorporeal anastomosis have showed better outcome in anastomotic leakage rate, surgical site infection rate, development of incisional hernia, postoperative pain and recovery of gastrointestinal function.

Keywords: right colectomy, laparoscopy, intracorporeal anastomosis, cancer, anastomotic leakage

1. Introduction

Cancer of the colon is the third most common cancer in men and women in the developed world, and resection is the only curative treatment. Traditionally, cancers of the colon were removed through large abdominal incisions. The first report on laparoscopic right colectomy appeared in 1991 [1], since then a large number of studies was performed to define technical and oncological safety of the laparoscopic approach. However, reports of tumor recurrence at the port sites after laparoscopic resection for colon cancer have questioned the oncological safety of mini-invasive approach in patients with bowel cancer. In 2008, the Colon Cancer Laparoscopic or Open Resection Study Group carried out a randomized clinical trial, with the primary end point being disease-free survival at 3 years after laparoscopic and open surgery for colon cancer. The results showed no differences in disease-free survival and overall survival between the two groups; moreover, no differences in tumor recurrence were reported [2].

A large number of subsequent randomized and non-randomized studies confirmed the short-term advantages of laparoscopy as compared to traditional treatment in terms of cosmesis, pain control, bowel function, postoperative morbidity, and hospital stay. Long-term follow-up data provided by the CLASSIC and COLOR

trials showed comparable outcomes between open and laparoscopic surgery in terms of overall survival and disease-free survival [3].

From a technical point of view, various operative factors - such as extent of resection, number of lymph nodes sampled, length of bowel and mesentery resected, and bowel margins – do not differ significantly between patients who underwent laparoscopic surgery and those who underwent open colectomy. With regards to intra-abdominal staging accuracy, laparoscopy allied with solid-organ imaging offers adequate staging information [4].

Laparoscopic right hemicolectomy is currently considered the standard of care in benign and malignant right colon disease [2].

This chapter describes the technique for laparoscopic right colectomy technique, with a focus on ileo-colic anastomosis, highlighting the differences between intra-corporeal and extracorporeal anastomosis fashions in terms of clinical outcome and surgical safety.

2. Surgical technique

With the patient placed supine in neutral position, the surgeon and first assistants stand on left and the laparoscopic tower is situated on the right. Second assistant, if present, stand on the right. It is important that the patient is well secured to the operating table to avoid incidents during bed movement.

After surgical site disinfection, the pneumoperitoneum is established using open technique (our preferred method) or Veress needle. The first trocar is placed next to the navel. Once pneumoperitoneum has reached target pressure (12 mmHg), the exploratory laparoscopy is performed in order to assess the presence of carcinomatosis or metastases to solid organs missed by imaging on pre-operative staging, which may preclude tumor resectability. Two working trocar for surgeon are subsequently placed: one (10 mm) in the left upper quadrant and the other (10 mm) in the left lower quadrant. A fourth trocar (5 mm) can be positioned in right middle quadrant for further assistance (**Figure 1**).

Sliding and left shifting of the patient in Trendelenburg positioning (i.e. head lower than legs) facilitates optimal exposure of the operating field. This leads to a shift of greater omentum over the stomach and small bowel 'descent' towards the left upper quadrant allowing adequate exposure of cecum, ascending colon, right portion of mesocolon, ileocolic vessels and right colic vessels.

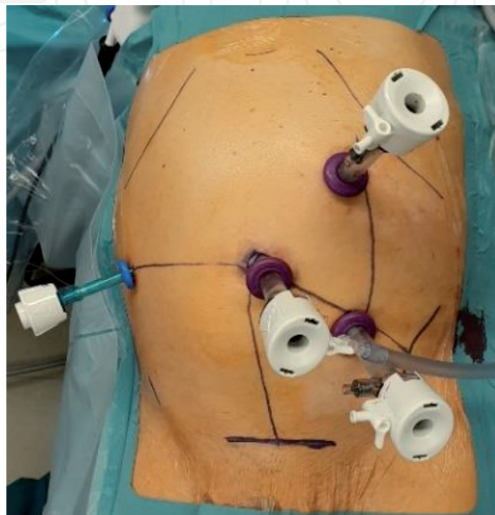

Figure 1.
Trocars position.

Using laparoscopic forceps, the assistant lifts up the ascending colon to expose the right portion of mesocolon that is straightened by the surgeon: this step allows visualization of ileocolic vessels (**Figure 2**).

In case of malignant disease, it is mandatory to performed lymphadenectomy simultaneously with the resection of vascular stem. In order to do that, ileocolic and right colic vessels must be ligated and sectioned at their origin.

Once vascular stem has been sectioned, visceral peritoneum is cut on ileocolic vessels axis in front of duodenum, so the colic dissection can be performed under a “tent” formed by Toldt’s fascia and prerenal fascia from medial-to-lateral. The dissection must be continued up to cecum in distal direction and up to hepatic flexure in cranial direction paying attention to avoid to open retroperitoneum and to damage genital vessels or ureter (**Figure 3**).

This procedure is continued until the horizontal part of the duodenum comes into view. The hepatocolic ligament is sectioned to allow separation of the ascending colon from the duodenum. Access into the omental bursa is facilitated by gentle caudal retraction of the transverse colon and incision of the gastocolic ligament. Partial removal of the mesotransverse colon is performed towards the right colonic angle.

In this way the colon limb can be eviscerated or approached in a tension-free manner. At this point, using laparoscopic stapler, colon and ileum are sectioned (**Figure 4**) and the specimen is extracted using endobag.

Until this moment, surgical procedure is the same for both totally intracorporeal and extracorporeal (i.e. with bowel transection and anastomosis performed out of abdomen).

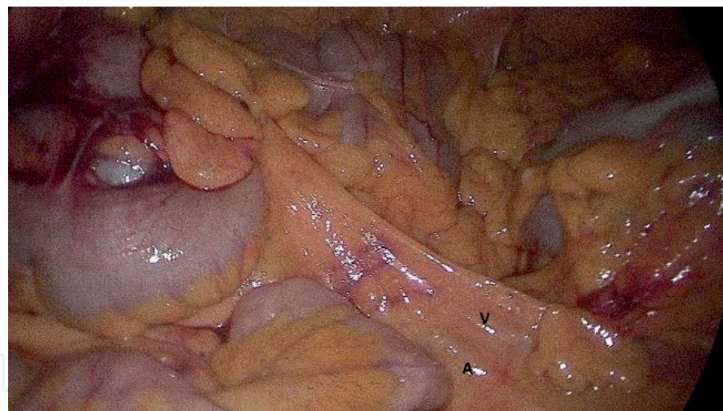


Figure 2.
A-artery, V-vein.

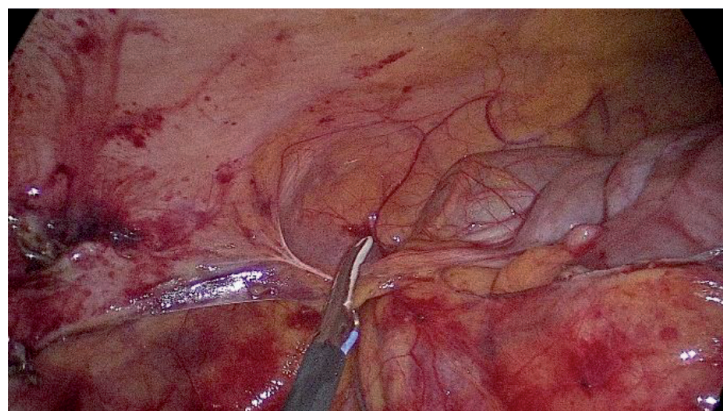


Figure 3.
Dissection of colon from abdominal wall.

2.1 Anastomotic techniques

There are two ways to perform ileocolic anastomosis: extracorporeal anastomosis (EA) and intracorporeal anastomosis (IA). In the EA a Kocher or middle-line or Pfannenstiel incision is made, protected with an Alexis device. The ileum and the colon are extracted, the dissection of the mesocolon is continued and, if necessary, the isolation of the arcade vessels is finished; the transection of ileum and colon is performed with a 60 mm GIA stapler, and the specimen is separated. A side-to-side

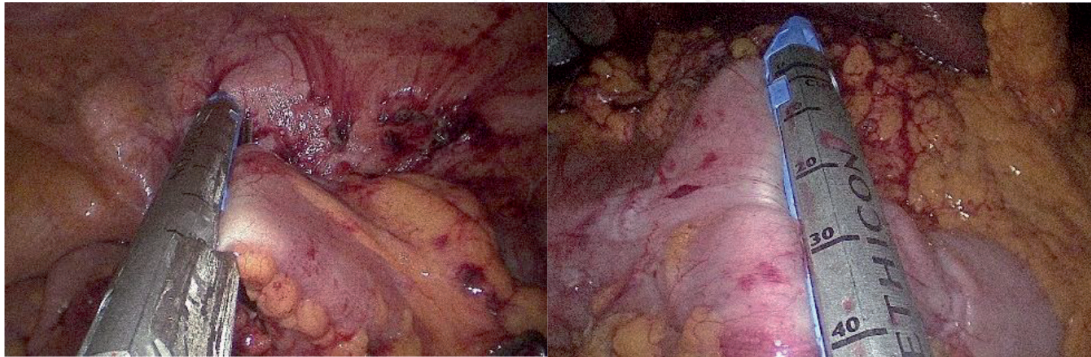


Figure 4.
Section of ileum (left) and colon (right).

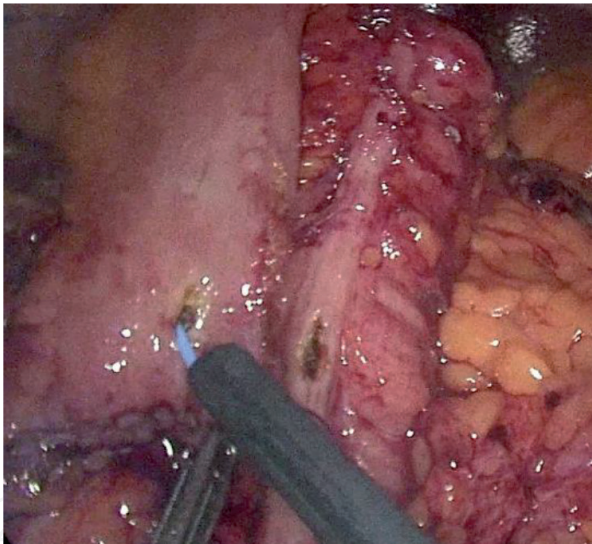


Figure 5.
Enterotomy for insertion of stapling device.

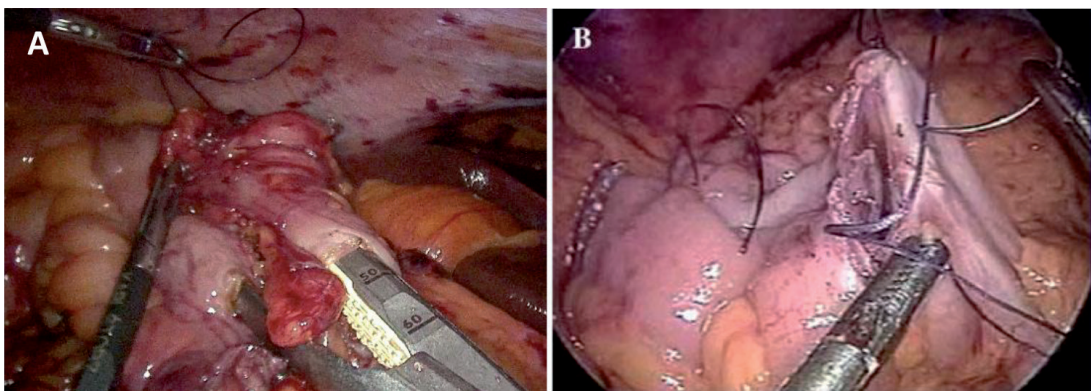


Figure 6.
(A) Stapled ileocolic anastomosis; (B) Hand-sewing of enterotomy after stapler removal.

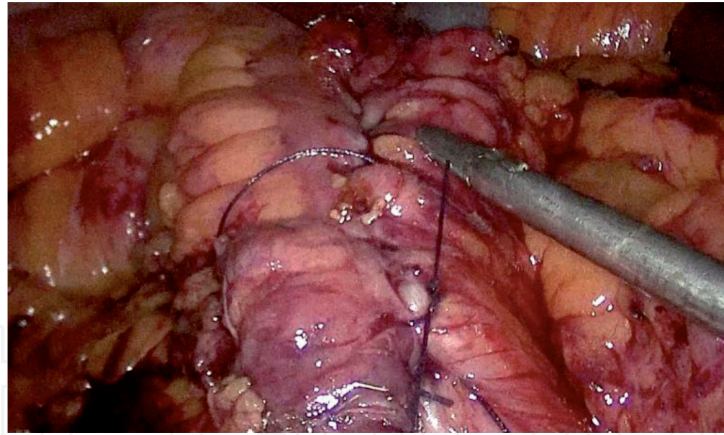


Figure 7.
Completed side-to-side intracorporeal ileocolic anastomosis.

isoperistaltic or antiperistaltic anastomosis is created with a 60 mm GIA stapler and it is reinforced with continuous suture. In IA, the entire procedure (vascular ligation, colon and ileum section and anastomosis) is performed intracorporeally: ileum and the transverse colon are transected using an Endo-GIA stapler and the piece is placed over the liver. Ileum and colon are moved close, an enterotomy is performed (**Figure 5**) to allow insertion of stapler.

A side-to-side isoperistaltic or antiperistaltic anastomosis is created with the 60 mm endostapler; after that, the enterotomy is closed with continuous suture as shown in **Figure 6** (by Stein and Bergamaschi [5]). In this phase, we usually use 2-0 prolene). In **Figure 7** is showed the final result of intracorporeal ileocolic anastomosis.

The specimen is extracted through a Pfannenstiel incision, which is protected with an Alexis device. After performing anastomosis, 2 tubular drainages are placed: one of them near to anastomosis and the other in pelvic cavity. These devices can be removed, if no complications occurred, 3–5 days after surgery [6].

3. Intracorporeal or extracorporeal anastomosis: differences in clinical outcome

When an anastomosis has been performed, the main complication that surgeons try to avoid is anastomotic leakage (AL) which means that bowel content can move from bowel lumen into abdominal space. In EA, despite the entire operation is carried out laparoscopically, the anastomosis is comparable to that performed during open surgery. The IA has been proved safe by several study, showing no statistically significant difference in AL rate between IA and EA [7]. A recent international snapshot audit [8] has identified 3 surgeon-dependent variables significantly associated with AL: duration of surgery, surgical approach, and anastomotic technique. Regarding duration of surgery, operating time varied widely: Magistro et al. [9] reported a significant longer duration of surgery for IA. Although the IA technique is retained faster by some [10], most studies showed no significant difference. However, it has been shown that the learning curve plays a major role in reducing the operative time [11].

Laparoscopic approach decreases morbidity and mortality after colorectal resection [4, 12]. Similarly, a laparoscopic approach is associated also with a lower AL rate compared with an open approach [8]. Considering anastomotic technique, the last Cochrane review [13] concluded that stapled ileocolic anastomosis was associated with fewer leaks than handsewn anastomosis. Two large observational

studies [14, 15] showed that the stapled technique is an independent risk factor for ileocolic anastomotic leak. Future large, randomized controlled trials are needed to identify the best anastomotic technique. To the authors' knowledge in 2018 has been proposed a study protocol for a randomized controlled trial IA versus EA in which primary endpoint is to compare hospital stay and secondary endpoints are intraoperative and postoperative events included AL. The results of this study will be available in 2021, depending on the volume of patients.

Surgical site infection (SSI) is reported in several case series; a meta-analysis by Ricc et al. reported a reduced risk of wound infection in favor of IA. The higher incidence of infection at the extraction site incision in EA anastomosis may be due to wound contamination during exteriorization of the bowel ends and performing the anastomosis through the incision [16].

The length of incision is another factor that influence morbidity after laparoscopic surgery: patients who had an EA were more likely to develop incisional hernia due to the longer incision required for specimen extraction and anastomosis: in EA group the extraction site is about 2.2 cm longer than IA group. Beside its length, the location of the extraction site incision may favor the development of incisional hernia. This was most frequently observed in cases of midline incision in the EC group, as compared to the IC group, where a Pfannenstiel incision was preferred [17]. Moreover, shorter incision is associated to less postoperative pain which result in early recovery after surgery [18].

Gastrointestinal function, demonstrated by time to first flatus and time to bowel movement, resume sooner in IA group than EA.

The technical challenges of EA may explain the earlier recover observed in the IA group. Indeed, delayed recovery of GI function may arise from traction on the bowel ends and mesentery needed to allow complete mobilization of the transverse colon during EA [17]. A recent RCT supports this hypothesis [19] by showing a significantly less surgical stress response after IA. Interleukin-6 and C-reactive protein levels were indeed markedly lower in this group.

Another aspect of intracorporeal ileocolic anastomosis which deserve to be studied is the configuration between ileum and colon. The anastomosis can be carried out in isoperistaltic or antiperistaltic configuration. ISOVANTI randomized clinical trial, performed in 2017 and published in 2018, has compared iso- and antiperistaltic configuration in order to understand if there is any difference in postoperative outcome. The results show that no differences were found in conversion rate, total operative time, and global complication rates after applying Clavien-Dindo's classification. Regarding functional results, the antiperistaltic group showed better results than the isoperistaltic group with less time to first flatus, less time to first stool and shorter time to satisfactory oral intake with statistically significant differences in all cases. However, this fact did not reduce hospital stay and there was no difference between both groups [20].

4. Conclusions

In the last few years a large number of studies was performed to understand if intracorporeal anastomosis were safe and associated with less morbidity and mortality. As we exposed above, IA is now considered safe from surgical and oncological point of view as long as colorectal surgeon had trained on it. Regarding morbidity and mortality, **Table 1** summarizes differences in IA and EA group published by Ricci et al. [16].

Regarding duration of surgery, some studies report that IA is associated with longer operating time but others found no differences between IA and EA group.

Outcome of interest	Intracorporeal	Extracorporeal	P value
Anastomotic leakage (%)	29 (3.4)	39 (4.6)	0.120
Operative time (min)	129 ± 32	121 ± 38	0.460
SSI (%)	39 (4.9)	71 (8.9)	0.030
Internal hernia (%)	0 (0)	3 (2.3)	0.440
First flatus (days)	2 ± 1	2 ± 1	0.110
First defecation (days)	3 ± 1	4 ± 1	0.110
Hospital stay (days)	5 ± 5	5 ± 4	0.004
Overall morbidity	176	231	0.009
Overall mortality	0	5	0.320

Table 1.
Differences in IA and EA group.

This variance could be explained with different level in laparoscopic surgery training in addition to various number of patient treated per year: when anastomosis is performed by trained colorectal surgeon, there is no significant difference in duration of surgery.

IA showed better outcome in anastomotic leakage rate, surgical site infection rate, development of incisional hernia, postoperative pain and recovery of gastrointestinal function. All these aspects can explain the difference in length of hospital stay, that is reported shorter in IA as compared to EA by all most recent meta-analysis and clinical trial [7, 16, 17, 21, 22].

Unfortunately, all currently available data are too uneven to be compared; further randomized controlled trial with homogeneity in surgeons training and large number of patient should be performed to understand the real advantage of IA.

Author details

Giulio Aniello Santoro*, Simone Novello, Ugo Grossi, Martino Zucchella, Andrea Kazemi Nava and Giacomo Zanus
IV Division of General Surgery, Regional Hospital of Treviso – Padua University (DISCOG), Italy

*Address all correspondence to: giulioasantoro@yahoo.com

IntechOpen

© 2020 The Author(s). Licensee IntechOpen. This chapter is distributed under the terms of the Creative Commons Attribution License (<http://creativecommons.org/licenses/by/3.0>), which permits unrestricted use, distribution, and reproduction in any medium, provided the original work is properly cited. 

References

- [1] Schlinkert RT. Laparoscopic-assisted right hemicolectomy. *Dis Colon rectum* [Internet]. 1991 Nov;34(11):1030-1. Available from: <http://journals.lww.com/00003453-199134110-00015>
- [2] Colon T, Laparoscopic C, Study R. Survival after laparoscopic surgery versus open surgery for colon cancer: long-term outcome of a randomised clinical trial. *Lancet Oncol* [Internet]. 2009;10(1):44-52. Available from: [http://dx.doi.org/10.1016/S1470-2045\(08\)70310-3](http://dx.doi.org/10.1016/S1470-2045(08)70310-3)
- [3] Ringressi MN, Boni L, Freschi G, Scaringi S, Indennitate G, Bartolini I, et al. Comparing laparoscopic surgery with open surgery for long-term outcomes in patients with stage I to III colon cancer. *Surg Oncol* [Internet]. 2018 Jun 1 [cited 2020 Aug 5];27(2):115-22. Available from: <https://pubmed.ncbi.nlm.nih.gov/29937160/>
- [4] Nelson H, Sargent DJ, Wieand HS, Fleshman J, Anvari M, Stryker SJ, et al. A Comparison of Laparoscopically Assisted and Open Colectomy for Colon Cancer. *N Engl J Med* [Internet]. 2004 May 13 [cited 2020 Aug 4];350(20). Available from: www.nejm.org
- [5] Stein SA, Bergamaschi R. Extracorporeal versus intracorporeal ileocolic anastomosis. *Tech Coloproctol*. 2013;17(SUPPL.1):35-9.
- [6] Bretagnol F, Alves A, Panis Y. Tecniche della colectomia destra in laparoscopia. *EMC - Tec Chir Addom* [Internet]. 2007;13(3):1-7. Available from: [http://dx.doi.org/10.1016/S1283-0798\(07\)70482-5](http://dx.doi.org/10.1016/S1283-0798(07)70482-5)
- [7] Allaix ME, Degiuli M, Bonino MA, Arezzo A, Mistrangelo M, Passera R, et al. Intracorporeal or Extracorporeal Ileocolic Anastomosis After Laparoscopic Right Colectomy: A Double-blinded Randomized Controlled Trial. *Ann Surg*. 2019;270(5):762-7.
- [8] Predictors for anastomotic leak, postoperative complications, and mortality after right colectomy for cancer: Results from an international snapshot audit. In: *Diseases of the Colon and Rectum* [Internet]. Lippincott Williams and Wilkins; 2020 [cited 2020 Aug 6]. p. 606-18. Available from: <https://pubmed.ncbi.nlm.nih.gov/32032201/>
- [9] Magistro C, Lernia S Di, Ferrari G, Zullino A, Mazzola M, De Martini P, et al. Totally laparoscopic versus laparoscopic-assisted right colectomy for colon cancer: Is there any advantage in short-term outcomes? A prospective comparative assessment in our center. *Surg Endosc* [Internet]. 2013 [cited 2020 Aug 6];27(7):2613-8. Available from: <https://pubmed.ncbi.nlm.nih.gov/23397503/>
- [10] Roscio F, Bertoglio C, De Luca A, Frattini P, Scandroglio I. Totally laparoscopic versus laparoscopic assisted right colectomy for cancer. *Int J Surg* [Internet]. 2012 [cited 2020 Aug 6];10(6):290-5. Available from: <https://pubmed.ncbi.nlm.nih.gov/22564829/>
- [11] Marchesi F, Pinna F, Percalli L, Cecchini S, Riccò M, Costi R, et al. Totally laparoscopic right colectomy: theoretical and practical advantages over the laparo-assisted approach. *J Laparoendosc Adv Surg Tech A* [Internet]. 2013 [cited 2020 Aug 6];23(5):418-24. Available from: <https://pubmed.ncbi.nlm.nih.gov/23414125/>
- [12] Cerdán Santacruz C, Frasson M, Flor-Lorente B, Ramos Rodríguez JL, Trallero Anoro M, Millán Scheiding M, et al. Laparoscopy may decrease morbidity and length of stay after elective colon cancer resection, especially in frail patients: results from an observational real-life study. *Surg Endosc* [Internet]. 2017 Dec 1 [cited 2020 Aug 6];31(12):5032-42. Available from: <https://pubmed.ncbi.nlm.nih.gov/28455773/>

- [13] Neutzling CB, Lustosa SAS, Proenca IM, da Silva EMK, Matos D. Stapled versus handsewn methods for colorectal anastomosis surgery. *Cochrane database Syst Rev* [Internet]. 2012 [cited 2016 Jul 6];(2):CD003144. Available from: <http://www.ncbi.nlm.nih.gov/pubmed/22336786>
- [14] Jessen M, Nerstrøm M, Wilbek TE, Roepstorff S, Rasmussen MS, Krarup PM. Risk factors for clinical anastomotic leakage after right hemicolectomy. *Int J Colorectal Dis* [Internet]. 2016 Sep 1 [cited 2020 Aug 7];31(9):1619-24. Available from: <https://pubmed.ncbi.nlm.nih.gov/27392778/>
- [15] Gustafsson P, Jestin P, Gunnarsson U, Lindfors U. Higher frequency of anastomotic leakage with stapled compared to hand-sewn ileocolic anastomosis in a large population-based study. *World J Surg* [Internet]. 2015 Jul 5 [cited 2020 Aug 7];39(7):1834-9. Available from: <https://pubmed.ncbi.nlm.nih.gov/25708508/>
- [16] Ricci C, Casadei R, Alagna V, Zani E, Taffurelli G, Pacilio CA, et al. A critical and comprehensive systematic review and meta-analysis of studies comparing intracorporeal and extracorporeal anastomosis in laparoscopic right hemicolectomy. *Langenbeck's Arch Surg* [Internet]. 2017;402(3):417-27. Available from: <http://dx.doi.org/10.1007/s00423-016-1509-x>
- [17] Emile SH, Elfeki H, Shalaby M, Sakr A, Bassuni M, Christensen P, et al. Intracorporeal versus extracorporeal anastomosis in minimally invasive right colectomy: an updated systematic review and meta-analysis [Internet]. Vol. 23, *Techniques in Coloproctology*. Springer; 2019 [cited 2020 Aug 7]. p. 1023-35. Available from: <https://pubmed.ncbi.nlm.nih.gov/31646396/>
- [18] Leung ALH, Cheung HYS, Fok BKL, Chung CCC, Li MKW, Tang CN. Prospective randomized trial of hybrid NOTES colectomy versus conventional laparoscopic colectomy for left-sided colonic tumors. *World J Surg* [Internet]. 2013 Nov [cited 2020 Aug 7];37(11):2678-82. Available from: <https://pubmed.ncbi.nlm.nih.gov/23942527/>
- [19] Mari GM, Crippa J, Costanzi ATM, Pellegrino R, Siracusa C, Berardi V, et al. Intracorporeal anastomosis reduces surgical stress response in laparoscopic right hemicolectomy: A prospective randomized trial. *Surg Laparosc Endosc Percutaneous Tech* [Internet]. 2018 [cited 2020 Aug 7];28(2):77-81. Available from: <https://pubmed.ncbi.nlm.nih.gov/29360701/>
- [20] Ibáñez N, Abrisqueta J, Luján J, Hernández Q, Rufete MD, Parrilla P. Isoperistaltic versus antiperistaltic ileocolic anastomosis. Does it really matter? Results from a randomised clinical trial (ISOVANTI). *Surg Endosc* [Internet]. 2019;33(9):2850-7. Available from: <http://dx.doi.org/10.1007/s00464-018-6580-7>
- [21] Wu Q, Jin C, Hu T, Wei M, Wang Z. Intracorporeal Versus Extracorporeal Anastomosis in Laparoscopic Right Colectomy: A Systematic Review and Meta-Analysis [Internet]. Vol. 27, *Journal of Laparoendoscopic and Advanced Surgical Techniques*. Mary Ann Liebert Inc.; 2017 [cited 2020 Aug 7]. p. 348-57. Available from: <https://pubmed.ncbi.nlm.nih.gov/27768552/>
- [22] van Oostendorp S, Elfrink A, Borstlap W, Schoonmade L, Sietses C, Meijerink J, et al. Intracorporeal versus extracorporeal anastomosis in right hemicolectomy: a systematic review and meta-analysis. *Surg Endosc* [Internet]. 2017 Jan 1 [cited 2020 Aug 6];31(1):64-77. Available from: <https://pubmed.ncbi.nlm.nih.gov/27287905/>