

We are IntechOpen, the world's leading publisher of Open Access books Built by scientists, for scientists

6,900

Open access books available

186,000

International authors and editors

200M

Downloads

Our authors are among the

154

Countries delivered to

TOP 1%

most cited scientists

12.2%

Contributors from top 500 universities



WEB OF SCIENCE™

Selection of our books indexed in the Book Citation Index
in Web of Science™ Core Collection (BKCI)

Interested in publishing with us?
Contact book.department@intechopen.com

Numbers displayed above are based on latest data collected.
For more information visit www.intechopen.com



Chapter

The Contribution of Uterine Artery Embolization as a Safe Treatment Option for Uterine Fibroids

Panagiotis Tsikouras, Anastasia Bothou, Xanthoula Anthoulaki, Anna Chalkidou, Spyridon Michalopoulos, Nistikoulis George, Ioannis Tsirkas, Fotini Gaitatzi, Selma Gyroglou, Irene Babageorgaka, Natalia Sachnova, Michael Koutsogiannis, Apostolos Lazarou, Arsou Chalil Bouratzan, Theopi Nalbanti, Panagiotis Peitsidis, Konstantinos Nikolettos, George Dragoutsos, Thedasia Vogaitzaki, Stefanos Zervoudis, George Iatrakis, Werner Rath, Nikolaos Nikolettos and Vasileios Souftas

Abstract

Uterine fibroids have remarkably heterogeneous clinical characteristics with unknown exact etiology. The treatment of fibroids should be individualized based on their size, location, growth rate, the symptoms that they cause, the desire to have children and the age of the woman. Embolization is currently the most advanced non-surgical technique. The majority of women report satisfactory post-treatment results like shorter hospitalization period and recovery time in comparison to hysterectomy and improvement or complete remission of clinical symptoms. Complications include amenorrhea (in the majority of cases: recurrence after three months) and infections that are generally treated with antibiotics. The results from most clinical studies and our published experience indicate that embolization improves pelvic symptoms related to uterine fibroids. Collaborative efforts between gynecologists and interventional radiologists are necessary in order to optimize the safety and efficacy of this procedure. In the future, embolization could be generally recommended as treatment option for women who desire future fertility/pregnancy.

Keywords: uterine fibroids, treatment, uterine artery embolization

1. Introduction

Uterine fibroids are high prevalent benign tumors that originate from muscle cells of the uterus with remained incompletely understood incidence, progression disease and natural history [1]. The above mentioned tumors may appear single or multiple but usually remain asymptomatic [1, 2]. Fibroids appear in various areas of uterus, different sizes and exist not a general accepted classification system for fibroid evaluation [3, 4]. They represent a tremendous public health problem with multiple difficulties and financial cost on society [1–4].

Treatment strategies to prevent the fibroid limit growth and non-surgical treatment are needed [5–8]. Minimally invasive methods like uterine artery embolization (UAE) as treatment option of fibroids by retaining the uterus among the women during middle or late reproductive years is the summarized goal of this literature review with detailed 12 years results report of Department Obstetrics and Gynecology in cooperation with Interventional Radiology Unit of Radiology Department, Democritus University of Thrace in Greece. The aim of this retrospective study was to investigate the contribution of UAE and the occurrence of transient, or permanent amenorrhea as well as reappearance of regular menstruation, inflammation, pain in premenopausal women up to one year of postoperative follow-up UAE.

2. Incidence

The fibroids occur in a phenotype in wide of genetic diseases, clinically not as single disease entity and their progression varies and based on the various types of disease in different national groups [9, 10]. The incidence of asymptomatic but sonographically fibroids detected as remarkably high and the incidence depending on women age and race. Their prevalence is 9% in white women, three to nine times higher prevalence in African American, diagnosed in 3.3% of 25 to 32 year olds, 7.8% of the 33 to 40 year olds and increased 20-fold to 6.20 per 1000 women years by ages 45 to 50 [9–14]. Familial aggregation studies confirm heritability of fibroids 2.5 times more at risk in first degree relatives, increasing to 5.7 for women with an affected first degree relative of less than 45 years old. The grow and recur rate of fibroids after abdominal myomectomy reported as 5 year risk 62% with 9% risk an additional major surgical procedure. Relapses of 27% over a period of 10 years are reported with increasing frequency rate approaching to premenopausal period [9, 14, 15].

The recurrence risk is lower in women with single fibroid with small size and in those women who noticed a subsequent successful pregnancy. Oral contraceptives administration decreased the occurrence of fibroids depending to the duration of oral contraceptives use [16–18]. Moreover, early menarche and high body mass index (approximately 18% for each 19 kg increase) are some other factors that lead to the development of fibroids [9, 14, 15, 19]. Clinically fibroids occur at least three distinct phenotypes like: single, multiple varying size and in association with adenomyosis or alone [9]. Fibroids interfere not only with implantation but also with successful labor and if there are not existing, is for a woman more likely to be pregnant. Pregnancy prevents the development of fibroids, because is associated with fibroid inflated effect [9, 14, 16–18]. The risk of fibroids decrease with parity up to fivefold [9, 14]. Although subfertility may be caused by fibroids, however the detected fibroids during pregnancy not influence the age of delivery of the first child, but change the age of last term labor. The presence of fibroids in the majority are not associated to any symptoms but is poorly explain their contribution to symptoms menstrual disorders heavy menstrual flow or longer duration of menses, pelvic pain and infertility. Based on the published literature is demonstrated a

relationship between diastolic pressure and fibroids [9, 16–20]. High diastolic blood pressures led to atherogenesis, cause injury and damage of muscle cells like a similar mechanism as in vascular muscle system, release cytokine in uterus muscle, which led to promotion of fibroid growth [9, 16–20]. Approximately 10 mm Hg increasing of blood pressure led to 8–10% increased fibroid risk. Myometrial injury based either on ischemia, hypertension or atheromatic type mechanisms are associated positively also to pelvic inflammatory disease [9, 16–20]. The risk of fibroids is low, if the estrogen levels are low and this could be explain the low risk associated with smoking, alcohol and caffeine consumption.

3. Heritable disease associated to fibroids

Some fibroids reflected genetic syndromes feature fibroids development such Reed's, Bannayan Zonana, Cowden syndrome, hereditary leiomatosis and renal cell cancer (HLRCC). Reed's syndrome is well known as familial leiomyomatosis cutis and uteri (MIM150800) is an autosomal dominant trait with reduced penetrance associated with cutaneous fibroids. Bannayan Zonana (MIM153480), Cowden (MIM158350) syndromes are autosomal dominant hamartomatous polyposis disorders included lipomas, interstitial hamartomatous polyps and various nonneoplastic manifestations [21–24].

Intracellular mutation such as chromosomal translocations and deletions are reported. None of the mentioned patterns of inheritance have been clearly proved in fibroids as a solitary phenotype.

In addition, different genetic subtypes can be found in different fibroids of the same patient. Many fibroids in a uterus may be of different cytological origin. The heterogeneity from growth and development of fibroids based on enzyme glucose-6-phosphate dehydrogenase (G6PD) isoenzyme analysis and using androgen receptor (AR) gene assays reveal that fibroids are monoclonal lesions arise independently from the same uterus and may associated to various chromosomal abnormalities which results in a distinct fibroid is a monoclonal lesion in the origin of the monoclonal independent lesion [25–28].

In uterus referred high rate of estrogen receptors, which comprised spiral linear muscle fibers separated from the natural surrounding uterine muscle tissue by a pseudocapsule of connective tissue.. Many distinct factors contribute to tumor progression [25–28].

Approximately 40% of fibroids are karyotypically abnormal which compared to normal fibroids are generally more cellular and have a greater mitotic index lower DNA content. The most prevalent types of chromosomal aberrations are as following: t(12,14), (q14-q15,q23-q24), rearrangement of 6p21, del(7)(q22q32), 1p36, 10q22, 13q21–22 nad of x chromosome partial deletion 3q, trisomy 12. [29–32]. Fibroids with abnormal karyotypes are associated to anatomically positions 12% of submucosal, 29% of subserosal and 35% of intramural. Based on low frequency of karyotypic rearrangement is the explanation that submucosal fibroids are highly symptomatic and led to menorrhagia. Further research in the genetics of fibroids is needed to investigate the heritability based on their clonal mosaic nature to correlate genotypic and clinically characteristics [29–34].

4. Adenomyosis

In UAE practice for therapy of symptomatic types adenomyosis either of pure (diffuse, focal) or mix form (coexistence with fibroids) in 70% and 30% of cases

respectively depending on size and number of fibroids (adenomyosis dominance, fibroid dominance) is reported a ratio 7:2:1 between the treated women [35].

Adenomyosis is characterized by the development of ectopic endometrial glands and a stroma in the myometrium, at a depth > 2.5 mm from the endometrial-myometrial separation surface and moreover by hypertrophy or hyperplasia of the smooth muscles of the myometrium [36–39]. An older description is given by Rokintasky 1860 adenoid cystosarcoma of the uterus and for the first time by Frankl 1925 the term of adenomyosis of the uterus [36–39]. Clinical diagnosis of adenomyosis is only hypothetical, histological examination poses diagnosis of the disease after hysterectomy [36–39]. It is diffuse (adenomyosis) or focal (adenomyoma), asymmetrically affects the uterine wall of premenopausal women (usually the posterior) and often coexists with myomas [36–39]. The disease is common (5% - 70% in the surgical series, using strict criteria 10% - 18%), progressing and manifested with non-specific symptoms, which are similar to the symptoms caused by myomas (bleeding - anemia, pain, dysmenorrhea, dyspareunia, pelvic load (bulk symptoms) - sensitive uterus or a combination of the above), so it is difficult to diagnose only by clinical criteria [36–39]. An incidence of 10% -30% is described, in hysterectomy preparations it was found in a percentage of 10% - 18%. 80% of women with adenomyosis have another uterine condition like pelvic endometriosis and endometrial polyps (2% - 20%) endometrial hyperplasia, adenocarcinoma [36–39]. In 35% of women with adenomyosis do not show any symptoms and the diagnosis of the disease is random [38–41]. The pathogenesis of adenomyosis remains unknown. Etiology: According to various studies the endometrial glands of the disease express more in immunochemical examinations the ratio of HCG/ LH receptors found in endometrial cancers and trophoblastic disease, compared to natural [36–39]. Other theories of pathogenesis include elevated estrogen levels, endometrial injuries in surgeries such as scraping, fibromyectomy, cesarean section, and residual of Muller Duct. Adenomyosis occurs mainly in multiparas with an incidence of 5–70%. Symptoms of adenomyosis (menorrhagia (50%), dysmenorrhea (30%), uterine bleeding (20%), dyspareunia (sporadic additional symptom) [38–41]. The clinical diagnosis of adenomyosis is only hypothetical and only histological diagnosis makes the diagnosis of the disease after hysterectomy. Preoperative transvaginal ultrasonography (TVUS) and magnetic resonance (MRI) are useful diagnostic examinations Main diagnostic TVUS criteria are as following: asymmetrical uterine enlargement, subendometrial halo thickening, indistinct endometrial myometrial border, myometrium is thickened ventrally and associated to heterogeneous echotexture. MRI is another recommend imaging examination preprocedural of UAE with higher specificity compared to TVUS approximately (86–96%) and excellent to recognize fibroids, adenomyomas if the myometrial thickness is increased or the myometrium occur anatomical area changes In focal adenomyosis occurs low signal intensity within the myometrium, while in diffuse adenomyosis appear the junctional zone diffuse thickening also with low signal intensity in T2 weighted MRI The treatment options are: Drug treatment (usually ineffective), Presence of estrogen receptors in fibroids promote the increase in fibroid size. Progesterooids such as medroxyprogesterone acetate, norethindrone in GnRH-suppressed patients may increase in size. Stimulation of fibroid enlargement is a complex process involving the interaction of estrogen-progestogens in combination with local growth factors [38–41]. Antiprogesterooids such as mifepristone RU-486 reduce fibroid size. Invasive treatment of fibroids: myomectomy (open - intra-abdominal, laparoscopic, hysteroscopic), hysterectomy, myolysis - catalysis cryocatalysis, thermal catalysis by microwave or radio frequency (RF-ablation), ultrasound focus catalysis (FUS) and laser photocatalysis] and uterine artery percutaneous embolization (UAE) [38–42].

5. Clinical symptoms of fibroids

The majority of 60–70% are asymptomatic. The clinical recognized significantly underestimates the true occurrence due to the fact that the routine ultrasound screening is not obligatory indicated [43–46].

Approximately 62% of women with symptomatic fibroids visit the gynecologists due to multiple symptoms depending on their anatomical location, (subserosal, intramural, submucosal or intracavity) size number and associated degenerative morphological changes [43–46]. The referred symptoms are as following: abnormal vaginal bleeding (most common), anemia, pelvic mass, frequent urination, possible incontinence constipation tenesmus rectal pressure, pelvic pain and infertility [43–46]. Pregnancy related fibroid behavior: growth which is reported controversy concerning to increasing or remain the same the uterus size, degeneration, pain, spontaneous abortions, obstetric complication (premature labor in 15%, intrauterine restriction in 10% and malpresentation in 20%) [43–46]. The pregnancy in coexisting of fibroids depending on their anatomical location and the distance to placental site. Other rare associations are as following: Ascites development due the transudation of fluid after torsion and obstruction of vessels in floating fibroids, Polycythemia secondary detected, familial syndromes with renal cell carcinoma, intravenous leiomatosis and benign metastasizing uterine fibroids [43–46].

The most common symptom in the majority of cases in clinical practice is the abnormal vaginal bleeding. This symptom in association with myomas occurs either as menorrhagia or hypermenorrhea, while metrorrhagia is not typical for fibroids and need more investigation to rule out malignancies. The exact mechanism of abnormal bleeding from fibroids is not yet well known. Fibroids alter the nature of uterine muscle contractions and prevent the uterus from controlling the degree and intensity of bleeding during menstruation. The submucosal fibroids due to total or partial protrusion in uterus cavity led most likely to menorrhagia while the intramural myomas have obstructive effect on uterine vessels and subsequent led to endometrial vessels ectasia with profuse menstrual bleeding [43–46].

Hypermenorrhea occur most likely in endometritis in association to submucous myomas. The palpation of myomas based on enlarged irregular uterine contour can be useful to clinically diagnosis of fibroids and the findings described as uterus size like in pregnancy [43–48]. If the uterus size is more than 12–20 week can be palpated on abdominal examination. In cases of increased size of uterus arise pelvic pressure on adjacent organs like urinary tract, rectosigmoid with frequent urination, ureteral obstruction tenesmus due to incarceration of enlarged uterus in Douglas pouch and dysmenorrhea [43–48].

The incidence of malignant mutation in sarcomas is reported to be 0.1–0.29% of diagnosed fibroids [43, 49, 50]. Leiomyosarcoma is an independent malignant tumor in the absolutely majority and arises *de novo*, however recently published studies reveal that in very rare cases is possible in fibroids with chromosome deletions to develop in leiomyosarcoma most common in the 5th–6th decade of life. Γλωσσική επιμέλεια.

It is characterized by extensive abnormal bleeding and a rapid increase in uterine size in postmenopausal patients [43, 49, 50]. The main microscopic features which are significant predictors of leiomyosarcoma clinical course included: coagulative tumor cell necrosis, degenerating hyperchromatic, pleomorphic nuclei, cytologic atypia, mitotic index MI (MI denotes definite mitotic figures (mf) per 10 high power field (hpf) $MI \geq 5mf/10hpf$, differentiation. In case of fibroids, the $MI < 5mf/10hpf$ no atypia and necrosis and in the subgroup of leiomyosarcoma or smooth muscle of uncertain malignant potential (STUMP) [43, 49, 50]. In STUMP

tumors the main diagnostic criterion associated to prognosticate biologic behavior is the MI < 5mf/10hpf but is presence of moderate to severe atypia without necrosis [43, 49, 50]. The least subgroup of tumors is accompanied by lymph nodes in the lung or other sites with histopathological occurrence similar to the original tumor approximately 15 years after hysterectomy. Immunostaining for expression of cell cycle regulatory proteins like Ki-67, cyclins E, A, cdk2, cdc2, p16, progesterone receptors, p53 Her-2/neu based on significant elevated levels in leiomyosarcomas can be useful in discriminating and identifying STUMP tumors, leiomyosarcoma and fibroids [43, 49, 50].

6. Treatment options

The uterine fibroids is the most common uterine pathology with a prevalence more than 25% of all reproductive years and approximately 1.6 million women in United States diagnosed with uterus myomatosis. Asymptomatic fibroids could be found incidentally on pelvic imaging and management therapeutical strategy depending on their causing clinical symptoms [51]. If cases which are asymptomatic need not any treatment and after menopause due to their regression expectant management is the recommended therapy option. In symptomatic fibroids based on the most common symptoms, heavy menstrual bleeding and painful menstruation is very useful. Fibroid classification system based on the fact that the above mentioned symptoms caused by fibroids which distort the uterine cavity [49].

Fibroid classification system is referred as following:

Type 0 completely intracavity fibroids.

Type 1 $\geq 50\%$ in the cavity intramural.

Type 2 < 50% in the cavity intramural.

Type 3 intramural but approach endometrium.

Type 4 intramural.

Type 5 subserosal but at least 50% intramural.

Type 6 subserosal but less than 50% intramural.

Type 7 subserosal pedunculated.

Type 8 cervical [51].

According to Donnez [52, 53] staging, submucosal fibroids are classified as following:

Grade I Fibroids with the largest diameter in the endometrial cavity.

Grade II Fibromyomas with the largest diameter in the myometrium.

Grade III Appearance of multiple fibroids > 2.

7. Medical treatment

Medical therapies based on therapeutical manipulating the fibroid hormonal environment. Steroid hormones, especially estrogen and progesterone are associated to fibroids behavior, proved by clinical molecular biological pharmacological models and play an important role to their medical treatment. The combination of estrogen progestin or progestin alone is the first line medical therapy for uterine fibroids.

GnRH (gonadotropin releasing hormone)-agonists led to down regulation of GnRH receptors at level of pituitary after initially increase the release of gonadotropins flare effect of heavy vaginal bleeding, reduce the FSH (follicle stimulating hormone) LH (luteinizing hormone) and ovarian steroid hormone and produce a hypoestrogenic menopause state [52–56]. Subsequent results amenorrhea and

reduction of the size of fibroids pronounced within three months after beginning of treatment [54–58]. The reduction can reach 40–50% of the tumor in 3 months but is reversible after stopping treatment. This effect is more pronounced in submucosal fibroids due to a higher number of estrogen and progesterone receptors.

GnRH antagonists often used to treat myomas before surgical procedure, block pituitary receptors and led immediately to declination of FSH, LH levels and fibroid, uterus volume reduction within 3 weeks of therapy beginning. Their directly promptly block gonadotropin effect has rapid clinical character and is associated to initial flare effect. They are currently indicated only for ovulation induction [54–58].

The presence of aromatase in fibroids and additional to ovarian estrogen activity, interleukin 1 β c AMP analogue, prostaglandin E2 led to estrogen production in fibroids cells [54–58]. Fibroids express aromatase higher levels compared to surrounding intact myometrium. In these cells occur significant conversion of androstendione to estrone and subsequent to estradiol which has full biologic activity and act positively to significant stimulation of proliferation of fibroids cells [54–58].

Aromatase inhibitors inhibit ovarian and peripheral estrogen production due to cellular proliferation inhibition, androstendione inhibition and reduce estradiol levels after 24 hours of treatment. SERMs (selective estrogen receptor modulator) are nonsteroidal agents who bind estrogen receptor and based on target tissue show estrogen agonist or antagonist effect [51, 59, 60]. While the SERM Tamoxifen has agonist effect in endometrium, Raloxifen exhibit no agonist activity and decrease the fibroid size. Antiprogesterone agents act at the level of progesterone receptors (PR-A PR-B), which are abundant in the fibroid. It is reported that progesterone induce proliferation, up regulate growth factors, antiapoptotic proteins like EGF in fibroid cells [51, 59, 60]. Mifepristone is the most studied antagonist of progesterone and due to high progesterone affinity led to amenorrhea, reduction of fibroid size and improvement the clinical symptoms [51, 59, 60]. The administration of ulipristal acetate, who is a selective progesterone receptor modulator, has proved successful effects on therapy of fibroids with clinical symptoms reduction of their size and endometrium cystic glandular changes. Danazol (19a nortestosterone derivate) inhibits pituitary gonadotropin secretion, led to ovarian steroid production and suppression of endometrial growth after 6 months treatment [51, 59, 60]. The use of progestin containing intrauterine contraceptive device (LNG -IUDs) as local therapy for menorrhagia and symptomatic uterine fibroids has been studied and confirmed a significant reduction in bleeding and fibroid size. However uterus myomatosis with a distorted uterine cavity or a submucosal fibroid is a contraindication for LNG -IUD [51, 59, 60].

8. Surgical treatment

Although the traditional treatment for uterine fibroids remains the hysterectomy either abdominal or vaginal classical, total laparoscopic assisted vaginal hysterectomy, robotic assisted laparoscopic hysterectomy as the predominant surgical procedure, however is preferred only in women who have completed their family planning [61–65].

In late reproductive age and premenopausal period available therapeutic options to preserve the uterus allow possible an attempt at conception and are surgical or conservative options. Over the past decade, the hysterectomy rate has decreased while alternative therapy options for symptomatic fibroids have been increased. The surgical procedures include myomectomy, abdominal myomectomy, laparoscopic myomectomy, laparoscopic thermal ablation, percutaneous ablative methods,

hysteroscopic myomectomy, myolysis, laparoscopic morcellation and finally uterine artery ligation and occlusion performed either as surgical ligation during laparoscopy [61–65]. (παρακάτω θα μπορούσε να μπει παράγραφος για τους κινδύνους της σε περίπτωση STUMP tu).

In cases of laparoscopic morcellation is of great importance to exclude based on evaluations criteria like presence of coagulations necrosis, no significant atypia and mitotic index ≤ 10 STUMP tu due to unknown malignant potential behavior. Minimally invasive therapies non-surgical procedures are as following: Magnetic resonance guided focused ultrasound ablation (MRgFUS) and UAE. MRgFUS based on ultrasound energy through the abdominal layers without requirement of incisions under real time MRI monitoring to reduce fibroid size [66]. Γλωσσική επιμέλεια UAE blocks selective the uterine artery blood flow led to shrink of fibroids [67]. The goal of this review was to report our 12 years of experience from the impact of UAE on ovarian reserve (OR) (which refer to number and quality of the follicles left in the ovaries) of normal menstruating premenopausal women and to estimate the degree of pain and inflammation caused by UAE in our patients based on AMH levels and inflammatory parameters (CRP, temperature, white blood cells) respectively.

9. UAE uterine artery embolization as treatment option

UAE to treatment of fibroids as alternative to surgical procedure was reported for first time by Ravina in 1995 [67]. This is not only treatment option for fibroids but used successfully also in refractory postpartum bleeding, or after gynecologic surgery, abnormal malignancy suspicious vaginal bleeding or in cases with uterine arteriovenous malformation. Although several reports confirm satisfactory results of treatment of symptomatic fibroids without necessity of surgical procedure based on the optimal cooperation between gynecologist and interventional radiologist, however the absolutely majority is retrospective and exist no prospective randomized trials to prove the effectiveness of this procedure compared to other therapy options [67–70]. The UAEs were performed in the Department of Radiology by an experienced interventional radiologist.

9.1 Preprocedural management

All study participants were normal menstruating premenopausal women aged between of 38–50 years old (42.6 ± 7 years on average), had attended the department of obstetrics and gynecology of our University hospital complaining of serious symptoms of uterine fibroids (menorrhagia, anemia, pelvic pain, bulky symptoms, pressure effects) underwent UAE for uterus fibromyomas and/or adenomyosis (pure or mix type). The enrolled premenopausal women diagnosed with and normal ovarian reserve as defined by AMH and FSH measurements (serum FSH concentration > 10 IU/L (on day 3 of menstrual cycle), serum AMH (2–8 pg./l). In all patients were available cervical pap smear test and previously performed fractional curettage. Exclusions criteria: Women with pelvic infection, pregnant (or willing to be pregnant) women, cases suspicious of any pelvic malignancy, postmenopausal women, women with resistant clotting disorders or severe allergy to contrast media, ovulatory problems, previous ovarian surgery, PCOS (polycystic ovarian syndrome) or coagulopathy, immunocompromised, previous pelvic irradiation or women who had been offered hormonal therapy for fibroids with GnRh agonists, were excluded. All patients underwent MR Imaging on a 1.5 Tesla (Multiva, Koninklijke Philips N.V.) or an 1 Tesla equipment (GE Healthcare, Milwaukee, USA) up to 60 days before UAE,

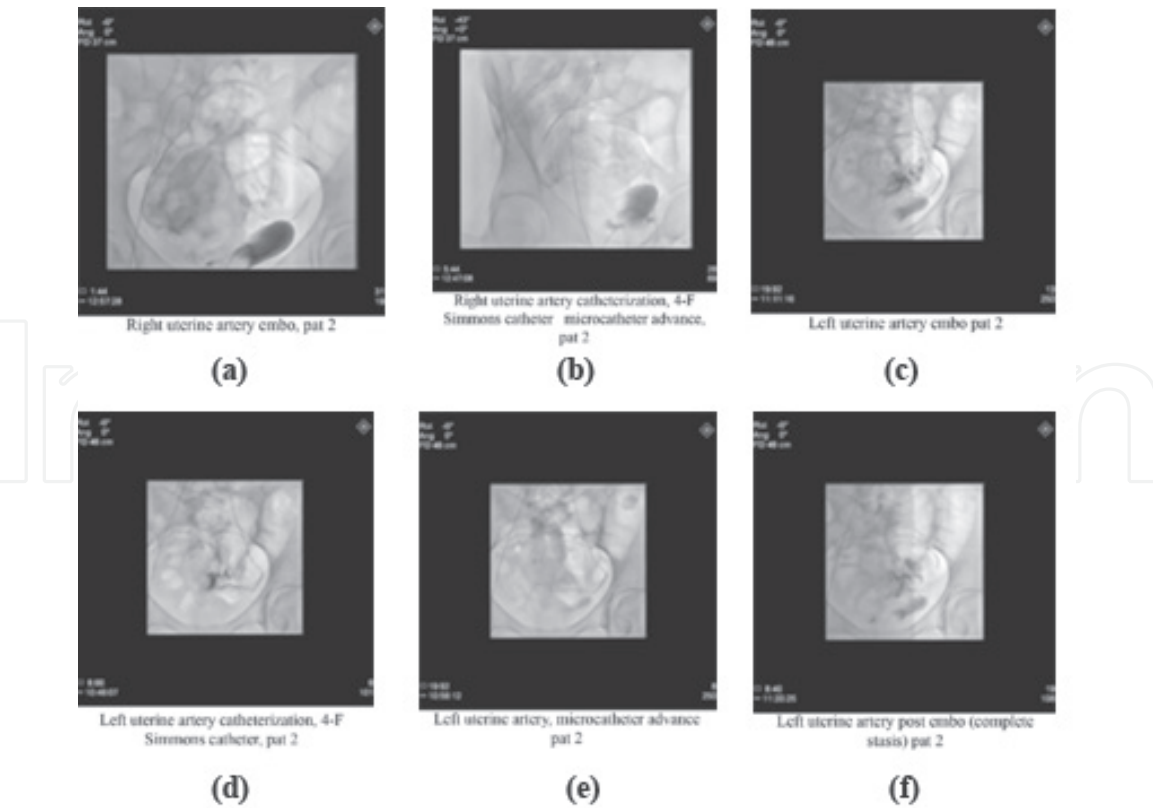


Figure 1.
Description of UAE procedure course.

using phased-array pelvic coils (**Figure 1a-f**). MR imaging included at least sagittal, coronal and transverse T2-weighted images, T2*-weighted images, T2-weighted fat saturated images, Diffusion-weighted images, T1-weighted images, and sagittal, coronal and transverse fat saturated T1-weighted images pre and post contrast. AMH, FSH, TSH, LH, fT 4 E, PROG, PROL, TESTOST and DHEAS were measured on day 3 of the menstrual cycle before UAE. C reactive protein (CRP) and white blood cell count lab exams were carried out prior to and after UAE. Two patients that had undergone fibromyectomy and with fibromyoma recurrence were included. Preoperative imaging management enhances the ability to diagnosis and to identify pathology induced anatomic changes and is crucial in optimizing information to treatment.

Transvaginal ultrasonography (TVUS) has an efficacy of 65–99% and consists the gold standard for imaging of the woman's pelvis. MRI is crucial in the diagnosis. Differential diagnosis with MRI has a sensitivity of 88% - 93% and a specificity of 66% - 91%. MRI examination is important to rule out malignancy in the uterus, eg sarcoma and to identify nondegenerated fibroids. Degenerated fibroids occur as hyalinized fibroids, cystic changes as hypertense, myxoid degeneration as high signal intensity, necrotizing has components of necrotizing or coagulative necrosis.

9.2 UAE

All patients had signed a written consent before the UAE. The UAE procedures were performed in the hybrid angiography suite of Radiology Department using a biplane angiography system (Philips Allura Xper Cath/angio system, Koninklijke Philips N.V.).

Bilateral UAE was performed, under local anesthesia, i.v. antibiotic prophylaxis, and sedation when required. In all cases a bladder catheter has been placed.

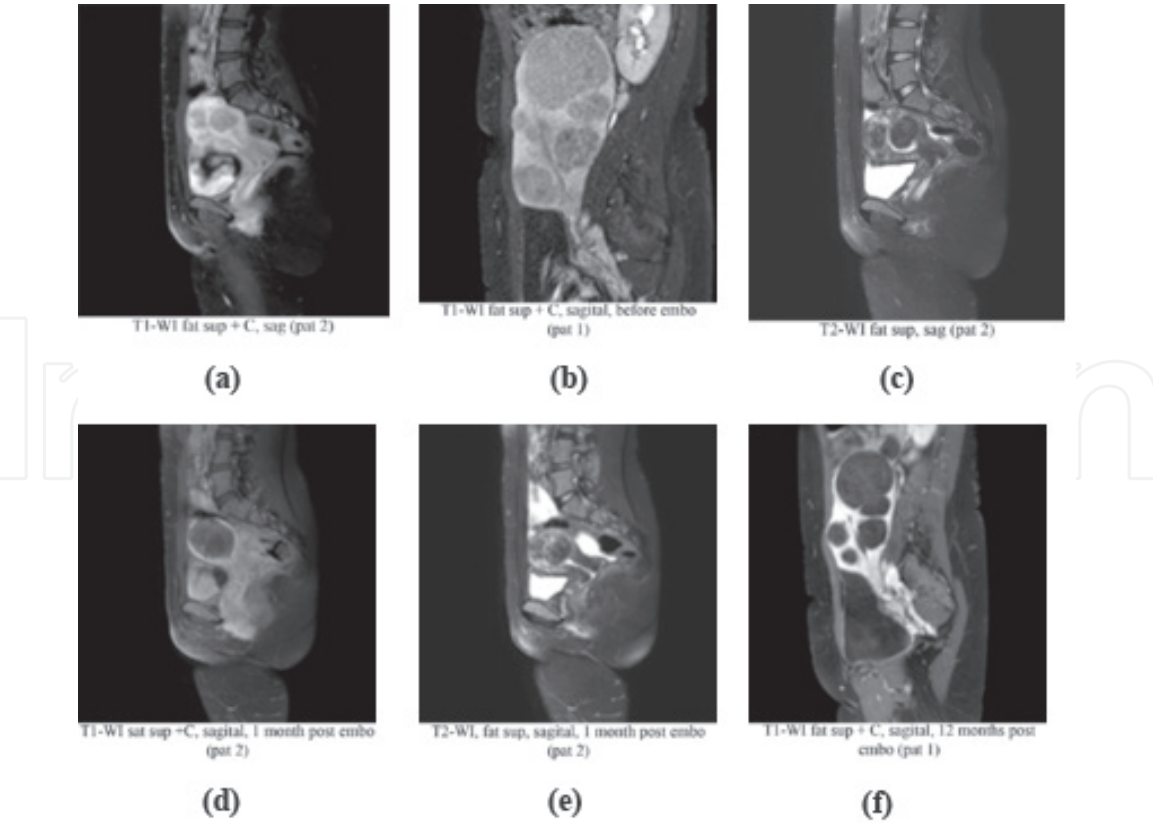


Figure 2.
MRI imaging of fibroid course pre- and post embolization.

The procedure included a single percutaneous puncture of the right common femoral artery, selective crossover contralateral and unilateral advance of a 4-French flush angiographic catheter (Simmons 1 or Cobra 1) to both uterine arteries. When the catheter bypassed the arteries for the vagina and cervix, administration of the embolic particles started. In the most of the cases a 2.7-Frence or 2.8-Frence micro-catheter (Progreat, Terumo Europe, Leuven, Belgium) has then been positioned away from the cervicovaginal branches (**Figure 2a-f**).

Special radiation protection care was taken, using fluoroscopic guidance of the catheterizations, fluoroscopy time reduction to the minimal possible and, mostly, fluoroscopic imaging of contrast angiography opacifications.

Fibroid ischemia was achieved by using of spherical, tightly calibrated, bio-compatible, non-resorbable, hydrogel coated microspheres, 700 μm and 900 μm in diameter (Embozene, CeloNova BioSciences Inc./Boston Scientific, San Antonio, USA). The angiographic embolization endpoint was defined as complete stasis of contrast agent in the ascending segment of the uterine artery during selective digital subtraction angiography at the end of the embolization procedure. Adenomyosis patients were embolized with the use of 500 μm and/or 700 μm Embozene microspheres. Criterion for the particle administration stop in adenomyosis cases was the fluoroscopic finding of “almost complete stasis”.

9.3 Postprocedural management

Regarding pain treatment, post-intervention 50 mg of pethidine was intramuscular administered, and after 4 hours the dosage was repeated by intramuscular injection in the first 24 hours. 100 mg tramadol was taken every 6 hours and anti-inflammatory tablets were taken every 12 hours for a week. Pain assessment results were determined based on a visual analogue scale (0 min-10max). After daily stay

at the hospital, patients were discharged and administered broad spectrum antibiotics for one week. Clinical, laboratory and imaging follow up examinations by trans-vaginal ultrasonography and MRI scans of the patients were performed at the 1st, 3rd, 6th and 12th month after the procedure (**Figure 1e-f**).

Main outcome measures were menstruation, hormonal status and presence of menopausal symptoms. Hormonal status and ovarian reserve were evaluated by means of AMH and FSH serum levels on 1st, 3rd, 6th and 12th month after UAE. Subsequently, FSH and LH levels began to decrease and reached the base line values on the 12th month after UAE (**Figure 3**) [71]. The AMH levels showed a decrease on the 1st month, reaching the minimum values on the 3rd month and retaining the base line values on the 3rd month in contrary to the other examined hormones. No Case of amenorrhea was noted in women ≤ 45 years old, while 0.6% of women > 45 years old experienced amenorrhea only the first 3 months after UAE (**Figure 4**) [71] According to our findings, a leukocytosis value of up to 16,000 K/ μ l and an increase in CRP level of up to 8 mg/dl, are not alarming [70]. In our study were included only premenopausal women and especially women who completed their family planning. However, reported two unplanned pregnancy cases, which they have decided to terminate the pregnancy. We have no noticed no case for emergency hysterectomy. In **Table 1** are summarized the complications in our participants and according to international literature with the maximally respectively referred complications rate. The first column of the table refers to our results in the time from 2008 to 2020 while in the second column are shown the respective values of the examined parameters in average concerning to international literature [72–76].

The course of myoma size according to a follow up for a period of 1 year post UAE was mean reduction 75% of fibroid volume compared to fibroid size before beginning of treatment. The percentage of technical success of the performed UAEs was estimated at 100% and the MRI examinations revealed that the uterine volume continues to shrink over follow up time. In no case was noticed continuity of worsening preprocedure symptoms, permanent amenorrhea, necessity of subsequent hysterectomy or minimal shrinkage of fibroid size after 6 months postprocedural. The positive results expressed as clinical included: Reduce of bleeding and pressure symptoms and as imaging reduction in uterine size and fibroids. According to our

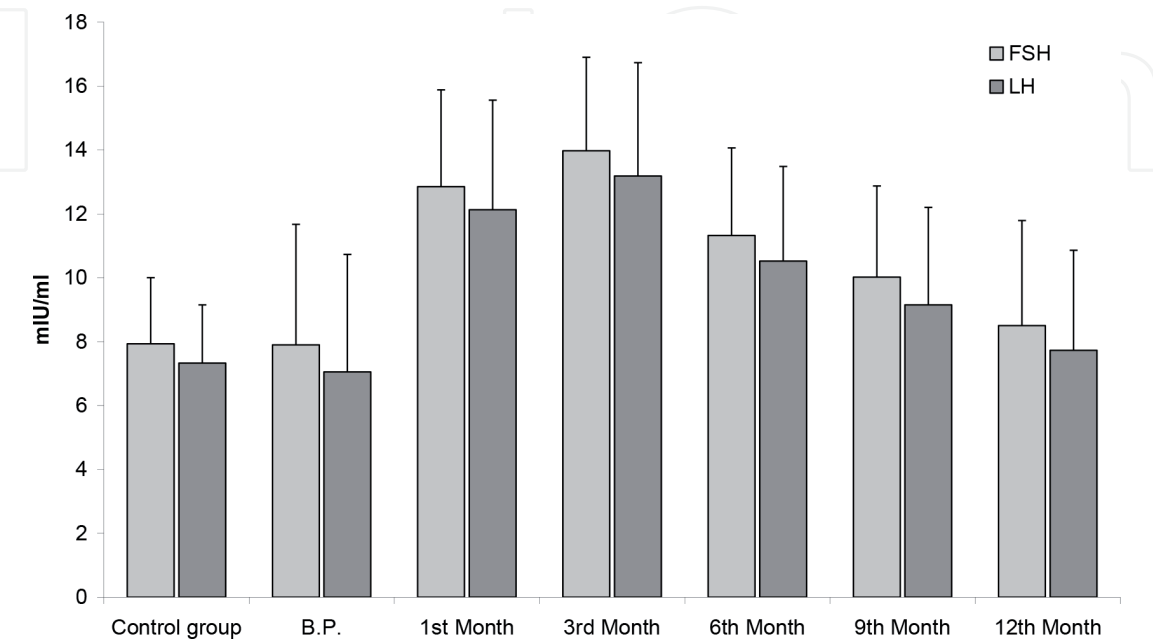


Figure 3.
Hormonal changes (FSH,LH) during the follow up period (Tsikouras et al. [71]).

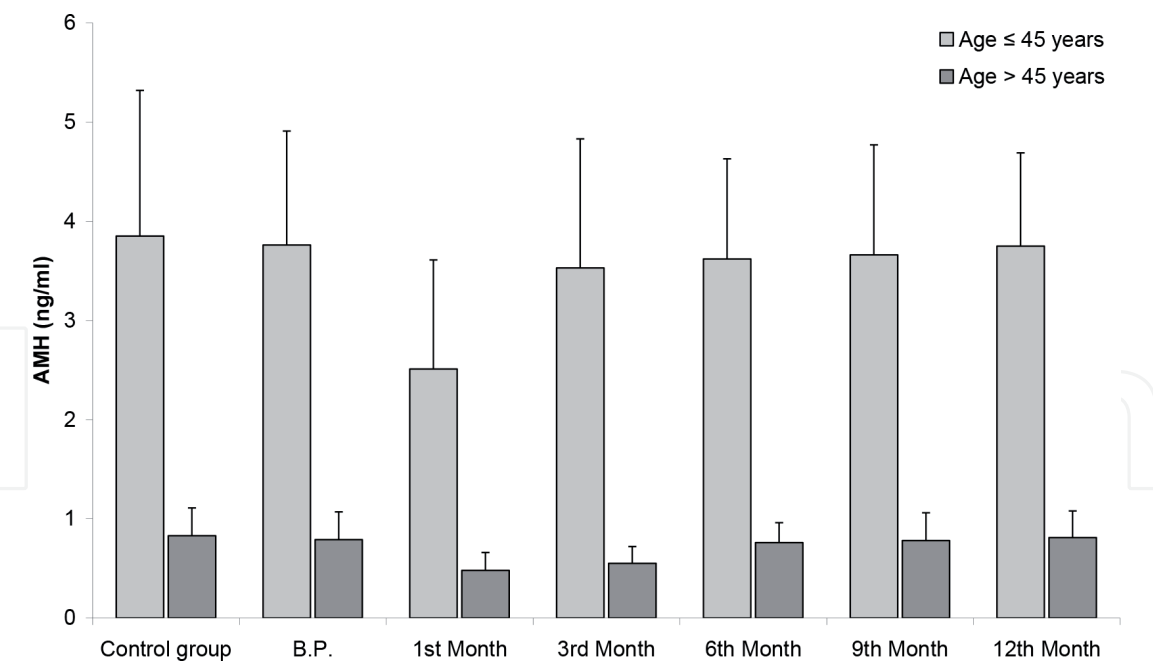


Figure 4.
Hormonal changes (AMH) during the follow up period (Tsikouras et al. [71]).

	Our results Range (min-max)	International literature results Range (min-max)
Transient amenorrhea		
< 45 years old	0.2–0.5%	1–2%
> 45 years old	1.5%	2–4%
Permanent amenorrhea	0	
< 45 years old	0	2–3%
> 45 years old	0	5–6%
Fibroma protrusion	0.3%	
Aseptic endometritis	0.1–0.2%	2%
Septic endometritis	0	1.2%
Uterine necrosis	0	<1%
Unsuccessful UAE	0	<1%

Table 1.
UAE complications: our results and various published reports.

findings after UAE the fibroids shrank by 60–70% and the size of the uterus by 50–60%. In particular, mild symptoms of metabolic syndrome in four cases were observed. Over time, shrinkage increases. The reduction in symptoms is expected to be close to 98%.

Specifically, menstruation improved in 95–100% of cases, while symptoms (flatulence, pelvic pressure and frequency) are reduced to 91–100% depending on how the result is calculated. High satisfaction rates for women. The recurrence of fibroids reaches 4%, but is thought to be due to an increase in the size of old incomplete embolized myomas and adenomyosis. The main cause of failure was not the initial size of the fibroids, but their failure shrank below 30% of the original size. In three cases it was mandatory to repeat the procedure of UAE due to the anatomical location of the fibroids, intra-ligamentally.

10. Discussion

UAE is a minimally invasive procedure which improves symptoms by interrupting the blood flow uterine vessel branches to fibroids after bilateral (from right and left) hyper-selective catheterization of the myometric feeder arteries and embossing of pistons inducing irreversible ischemic damage and degeneration/shrinkage in the fibroids [65, 75–80]. According to bibliography, therapy success rate during menorrhagia, was is 80–100% and at? pressure phenomena 60–100%. A decrease in fibroid size by 40–70% was noted in the first 6 months, followed by 50–80% in the months that ensued [67, 77–82]. There are various reports regarding uterus size course [67, 77–82]. Some authors mention uterus size as criteria, whilst others use both fibroids and uterus size as successful therapy assessment criteria. Inflammation appearance rate is 1–2% based on tissue reactions due to post interventional ischemia is an interaction between cells and cytokine and should be diagnosed at an early stage so that sepsis, hysterectomy and death can be avoided [81–84]. There have been reports of 100.000 successful UAEs in total so far [84–87].

Patients should be notified in detail and contact their doctor. Fundamental is the co-operation between gynecologist and interventional radiologist before, during and after UAE. In general, complications include either catheterization or the effects of uterine ischemia that can cause fibrotic necrosis, pain and septic imaging. The ovaries may be affected. The reported deaths following UAE are extremely rare (approximately 1: 1600) and are mainly related to pulmonary embolism, which may be due to the effect of necrotic tissue on activation of the coagulation mechanism and on inflammation. The complications of catheterization are rare (<1%), such as hematoma, allergy to contrast media and pseudo-aneurysm or vascular separation [75, 76, 87–90]. Elimination of uterine fibroids occurs in 5% of cases and can cause inflammation requiring scanning or hysterectomy. The necrotic tissue, if not removed in time, can become infected and the condition becomes severe. Cases with submucosal fibroids should be treated hysteroscopically [75, 76, 87–90]. Ischemia may cause endometritis, pelvic inflammation and pyometra with poor outcome if hysterectomy does not occur. According to the literature, menorrhagia is successfully treated in 91–100% of cases, while symptoms such as flatulence, pressure on organs of the pelvis and loss of urine are reduced to 92–100% [67, 75, 76, 87–90]. Uterine size does not appear to be a determinant, as remission of symptoms is also common in patients with a uterus greater than 24 weeks gestation. These results are also confirmed by studies of the last four years, which show that patients are 98–1000% satisfied [67, 75, 76, 87–90]. UAEs also have a beneficial effect in cases of adenomyosis, although there is not much experience. In a series of 28 patients with genuine adenomyosis an improvement of 95.3% was recorded [67, 75, 76, 87–90]. Although there are no long-term data, follow-up of up to 72 months shows postembolization syndrome include: pain and cramps (eliminated in the first hours after procedure with good/systemic analgesic treatment), nausea and fever (controlled with appropriate medications), aseptic or (rarely) septic inflammation (in a few patients, total 4 in our study controlled with anti-inflammatory/antibiotics) for 3–6 months) or (rare) menopause after UAE (small number of patients, almost always aged >45 years) [67, 75, 76, 87–90]. In these cases were diagnosed large fibroids and the reported complications affect range according to published literature 2–15% needed readmission for monitoring of symptoms. The necessity of hysterectomy after UAE approximately reported in 1% of cases. In our study participants reintervention was necessary only in 4 cases due the anatomical fibroid positions. According to international literature reintervention's rate is by 9% at 1 year and 28% at 5 years [67, 75, 76, 87–90]. Pregnancies in the majority after the UAE reported and delivered at term without serious complications, however

the cesarean section rate is high approximately 33–50% [67, 75, 76, 87–91]. Based on current medical knowledge concerning genetics and molecular biology of uterine fibroids will be the basis of development microarray analysis to investigate genes, which involved in fibroid formation and provide more specific and effective minimally preventive fibroid therapies to early intervention and improve the life impact of women.

11. Conclusion

UAE is a safe and effective treatment option for uterine fibroids with international recognition, however further multicentric studies required to provide clinical data and participate in randomized control trial to compare with the known surgical procedures.

Author details

Panagiotis Tsikouras^{1*}, Anastasia Bothou¹, Xanthoula Anthoulaki¹, Anna Chalkidou¹, Spyridon Michalopoulos¹, Nistikoulis George², Ioannis Tsirkas¹, Fotini Gaitatzi¹, Selma Gyroglou¹, Irene Babageorgaka¹, Natalia Sachnova¹, Michael Koutsogiannis¹, Apostolos Lazarou¹, Arsou Chalil Bouratzan¹, Theopi Nalbanti¹, Panagiotis Peitsidis³, Konstantinos Nikolettos¹, George Dragoutsos¹, Thedasia Vogaitzaki⁴, Stefanos Zervoudis³, George Iatrakis³, Werner Rath¹, Nikolaos Nikolettos¹ and Vasileios Souftas²

1 Department of Obstetrics and Gynecology, Democritus University of Thrace, Greece

2 Department of Interventional Radiology and Medical Imaging, Democritus University of Thrace, Greece

3 Department of Obstetrics and Gynecology, Rea Hospital, Athens, Greece

4 Department of Anesthesiology, Democritus University of Thrace, Greece

*Address all correspondence to: ptsikour@med.duth.gr

IntechOpen

© 2020 The Author(s). Licensee IntechOpen. This chapter is distributed under the terms of the Creative Commons Attribution License (<http://creativecommons.org/licenses/by/3.0>), which permits unrestricted use, distribution, and reproduction in any medium, provided the original work is properly cited. 

References

- [1] Stewart EA Uterine fibroids. *Lancet*. 2001 Jan 27;357 (9252):293-8 PMID:11214143 DOI: 10.1016/S0140-6736(00)03622-9
- [2] Calaf J, Arqué M, Porta O, D'Angelo E The fibroid as clinical problem. *Med Clin (Barc)*. 2013 Jul;141 Suppl 1:1-6. PMID: 24314560 DOI:10.1016/S0025-7753(13)70045-9
- [3] Csatlós E, Rigó J Jr, Szabó I, Nagy Z, Joó JG. Uterine leiomyoma *Orv Hetil*. 2010 Oct 17;151(42):1734-41. PMID: 20889441 doi: 10.1556/OH.2010.28977. Review.
- [4] .Deborah J DeWaay¹, Craig H Syrop, Ingrid E Nygaard, William A Davis, Bradley J Van Voorhis Natural history of uterine polyps and leiomyomata *Obstet Gynecol* 2002 Jul;100(1):3-7. PMID: 12100797 DOI: 10.1016/s0029-7844(02)02007-0
- [5] Myers ER, Barber MD, Gustilo-Ashby T, Couchman G, Matchar DB, McCrory DC. Management of uterine leiomyomata: what do we really know? *Obstet Gynecol*. 2002 Jul;100(1):8-17. PMID: 12100798 doi: 10.1016/s0029-7844(02)02019-7. Review
- [6] De La Cruz MS, Buchanan EM. Uterine Fibroids: Diagnosis and Treatment. *Am Fam Physician*. 2017 Jan 15;95(2):100-107. PMID: 28084714 Review
- [7] O'Sullivan M, Overton C. Tailor management to the patient with fibroids *Practitioner*. 2017 Mar;261(1802):19-22. PMID: 29139277
- [8] Vilos GA, Allaire C, Laberge PY, Leyland N; Special Contributors. The management of uterine leiomyomas. *J Obstet Gynaecol Can*. 2015 Feb;37(2):157-178. PMID: 25767949 doi: 10.1016/S1701-2163(15)30338-8.
- [9] Payson M, Leppert P, Segars J. Epidemiology of myomas. *Obstet Gynecol Clin North Am*. 2006 Mar;33(1):1-11. PMID: 16504803 doi: 10.1016/j.ogc.2005.12.004.
- [10] Giuliani E, As-Sanie S, Marsh EE. Epidemiology and management of uterine fibroids. *Int J Gynaecol Obstet*. 2020 Apr;149(1):3-9. doi: 10.1002/ijgo.13102. Epub 2020 Feb 17. PMID: 31960950 Review
- [11] Okolo S. Incidence, aetiology and epidemiology of uterine fibroids. *Best Pract Res Clin Obstet Gynaecol*. 2008 Aug;22(4):571-88. doi: 10.1016/j.bpobgyn.2008.04.002. Epub 2008 Jun 4. PMID: 18534913 Review
- [12] Baird DD, et al. High cumulative incidence of uterine leiomyoma in black and white women: ultrasound evidence. *Am J Obstet Gynecol*. 2003. PMID: 12548202
- [13] Wise LA, Palmer JR, Stewart EA, Rosenberg L. Age-specific incidence rates for self-reported uterine leiomyomata in the Black Women's Health Study. *Obstet Gynecol*. 2005 Mar;105(3):563-8. PMID: 15738025 doi: 10.1097/01.AOG.0000154161.03418.e3.
- [14] Baird DD, et al. Why is parity protective for uterine fibroids? *Epidemiology*. 2003. PMID: 12606893
- [15] Heinemann K, Thiel C, Möhner S, Lewis MA, Raff T, Kühl-Habich D, Heinemann LA; Benign gynecological tumors: estimated incidence. Results of the German Cohort Study on Women's Health. *German Cohort Study on Women's Health. Eur J Obstet Gynecol Reprod Biol*. 2003 Mar 26;107(1):78-80. doi: 10.1016/s0301-2115(02)00308-1. PMID: 12593900
- [16] Wise LA, Palmer JR, Harlow BL, Spiegelman D, Stewart EA,

Adams-Campbell LL, Rosenberg L Reproductive factors, hormonal contraception, and risk of uterine leiomyomata in African-American women: a prospective study. *Am J Epidemiol*. 2004 Jan 15;159(2):113-23. doi: 10.1093/aje/kwh016. PMID: 14718211

[17] .Radosa MP, Owsianowski Z, Mothes A, Weisheit A, Vorwerck J, Asskaryar FA, Camara O, Bernardi TS, Runnebaum IB. Long-term risk of fibroid recurrence after laparoscopic myomectomy. *Eur J Obstet Gynecol Reprod Biol*. 2014 Sep;180:35-9.. PMID: 25016181 doi: 10.1016/j.ejogrb.2014.05.029. Epub 2014 Jun 2

[18] Horng HC, Wen KC, Su WH, Chen CS, Wang PH. Review of myomectomy. *Taiwan J Obstet Gynecol*. 2012 Mar;51(1):7-11. PMID: 22482961 Review. doi: 10.1016/j.tjog.2012.01.003.

[19] Jacoby VL, Fujimoto VY, Giudice LC, Kuppermann M, Washington AE Racial and ethnic disparities in benign gynecologic conditions and associated surgeries. *Am J Obstet Gynecol*. 2010 Jun;202(6):514-21. doi: 10.1016/j.ajog.2010.02.039. Epub 2010 Apr 28. PMID: 20430357

[20] Laughlin-Tommaso SK, Jacoby VL, Myers ER. Disparities in Fibroid Incidence, Prognosis, and Management. *Obstet Gynecol Clin North Am*. 2017 Mar;44(1):81-94. PMID: 28160895 doi: 10.1016/j.ogc.2016.11.007.

[21] Melissa K Lobel , Priya Somasundaram, Cynthia C Morton The genetic heterogeneity of uterine leiomyomata *Obstet Gynecol Clin North Am* 2006 Mar;33(1):13-39. PMID: 16504804 DOI: 10.1016/j.ogc.2005.12.006

[22] . Luoto R, Kaprio J, Rutanen EM, Taipale P, Perola M, Koskenvuo M Heritability and risk factors of uterine fibroids--the Finnish Twin Cohort

study. *Maturitas*. 2000 Nov 30;37(1):15-26. doi: 10.1016/s0378-5122(00)00160-2. PMID: 11099869

[23] Sandberg AA. Updates on the cytogenetics and molecular genetics of bone and soft tissue tumors: leiomyoma.

[24] Laganà AS, Vergara D, Favilli A, La Rosa VL, Tinelli A, Gerli S, Noventa M, Vitagliano A, Triolo O, Rapisarda AMC, Vitale SG. Epigenetic and genetic landscape of uterine leiomyomas: a current view over a common gynecological disease. *Arch Gynecol Obstet*. 2017 Nov;296(5):855-867. doi: 10.1007/s00404-017-4515-5. Epub 2017 Sep 5. PMID: 28875276 Review.

[25] Catherino W, Salama A, Potlog-Nahari C, Leppert P, Tsibris J, Segars J. Semin Gene expression studies in leiomyomata: new directions for research. *Reprod Med*. 2004 May;22(2):83-90. doi: 10.1055/s-2004-828614. PMID: 15164303 Review.

[26] Ligon AH, Morton CC. Genetics of uterine leiomyomata. *Genes Chromosomes Cancer*. 2000 Jul;28(3):235-45. PMID: 10862029 Review.

[27] Flake GP, Andersen J, Dixon D. Etiology and pathogenesis of uterine leiomyomas: a review. *Environ Health Perspect*. 2003 Jun;111(8):1037-54. doi: 10.1289/ehp.5787. PMID: 12826476

[28] Segars JH, Parrott EC, Nagel JD, Guo XC, Gao X, Birnbaum LS, Pinn VW, Dixon D. Proceedings from the Third National Institutes of Health International Congress on Advances in Uterine Leiomyoma Research: comprehensive review, conference summary and future recommendations. *Hum Reprod Update*. 2014 May-Jun;20(3):309-33. doi: 10.1093/humupd/dmt058. Epub 2014 Jan 8. PMID: 24401287

- [29] Avery A Sandberg Updates on the cytogenetics and molecular genetics of bone and soft tissue tumors: leiomyoma Cancer Genet Cytogenet. 2005 Apr 1;158(1):1-26. doi: 10.1016/j.cancergencyto.2004.08.025. PMID: 15771900 Review.
- [30] Ishwad CS, Ferrell RE, Davare J, Meloni AM, Sandberg AA, Surti U Molecular and cytogenetic analysis of chromosome 7 in uterine leiomyomas. Genes Chromosomes Cancer. 1995 Sep;14(1):51-5. doi: 10.1002/gcc.2870140109. PMID: 8527384
- [31] Erica E Marsh, Zhihong Lin, Ping Yin, Magdy Milad, Debabrata Chakravarti, Serdar E Bulun Differential expression of microRNA species in human uterine leiomyoma versus normal myometrium Fertil Steril 2008 Jun;89(6):1771-6. PMID: 17765232 DOI:10.1016/j.fertnstert.2007.05.074
- [32] Karmon AE, Cardozo ER, Rueda BR, Styer AK. MicroRNAs in the development and pathobiology of uterine leiomyomata: does evidence support future strategies for clinical intervention? Hum Reprod Update. 2014 Sep-Oct;20(5):670-87. doi: 10.1093/humupd/dmu017. Epub 2014 Apr 4. PMID: 24706045 Review.
- [33] Wei MH, Toure O, Glenn GM, Pithukpakorn M, Neckers L, Stolle C, Choyke P, Grubb R, Middleton L, Turner ML, Walther MM, Merino MJ, Zbar B, Linehan WM, Toro JR. Novel mutations in FH and expansion of the spectrum of phenotypes expressed in families with hereditary leiomyomatosis and renal cell cancer. J Med Genet. 2006 Jan;43(1):18-27. doi: 10.1136/jmg.2005.033506. Epub 2005 Jun 3. PMID: 15937070
- [34] Fejzo MS, Yoon SJ, Montgomery KT, Rein MS, Weremowicz S, Krauter KS, Dorman TE, Fletcher JA, Mao JI, Moir DT, et al. Identification of a YAC spanning the translocation breakpoints in uterine leiomyomata, pulmonary chondroid hamartoma, and lipoma: physical mapping of the 12q14-q15 breakpoint region in uterine leiomyomata. Genomics. 1995 Mar 20;26(2):265-71. doi: 10.1016/0888-7543(95)80210-d. PMID: 7601452
- [35] Lohle PNM, Higué D, Herbreteau D. Uterine artery embolisation in women with symptomatic adenomyosis. Presse Med. 2019 Apr;48(4):435-439. doi: 10.1016/j.lpm.2019.03.013. Epub 2019 Apr 27. PMID: 31036387
- [36] Bruce McLucas, Rita Perrella Adenomyosis: MRI of the uterus treated with uterine artery embolization AJR Am J Roentgenol 2004 Apr;182(4):1084-5; author reply 1085. PMID: 15039193 doi: 10.2214/ajr.182.4.1821084a.
- [37] Jha RC, Takahama J, Imaoka I, Korangy SJ, Spies JB, Cooper C, Ascher SM. Adenomyosis: MRI of the uterus treated with uterine artery embolization. AJR Am J Roentgenol. 2003 Sep;181(3):851-6. doi: 10.2214/ajr.181.3.1810851. PMID: 12933493
- [38] Dundr P, Mára M, Masková J, Fucíková Z, Povýsil C, Tvrdík D. Pathological findings of uterine leiomyomas and adenomyosis following uterine artery embolization. Pathol Res Pract. 2006;202(10):721-9. doi: 10.1016/j.prp.2006.07.001. Epub 2006 Sep 7. PMID: 16959435
- [39] Rabinovici J, Stewart EA. New interventional techniques for adenomyosis. Best Pract Res Clin Obstet Gynaecol. 2006 Aug;20(4):617-36. doi: 10.1016/j.bpobgyn.2006.02.002. Epub 2006 Aug 24. PMID: 16934530
- [40] Kitamura Y Allison SJ, Jha RC, Spies JB, Flick PA, Ascher SM. MRI of adenomyosis: changes with uterine artery embolization. AJR Am J Roentgenol. 2006 Mar;186(3):855-64.

- [41] Kim MD, Kim S, Kim NK, Lee MH, Ahn EH, Kim HJ, Cho JH, Cha SH. Long-term results of uterine artery embolization for symptomatic adenomyosis. *AJR Am J Roentgenol*. 2007 Jan;188(1):176-81.
- [42] Gordts S, Grimbizis G, Campo R. Symptoms and classification of uterine adenomyosis, including the place of hysteroscopy in diagnosis. *Fertil Steril*. 2018 Mar;109(3):380-388.e1. doi: 10.1016/j.fertnstert.2018.01.006. PMID: 29566850 Review.
- [43] Bukulmez O, Doody KJ. Clinical features of myomas. *Obstet Gynecol Clin North Am*. 2006 Mar;33(1):69-84. doi: 10.1016/j.ogc.2005.12.002. PMID: 16504807
- [44] Gupta S, Jose J, Manyonda I. Clinical presentation of fibroids. *Best Pract Res Clin Obstet Gynaecol*. 2008 Aug;22(4):615-26. doi: 10.1016/j.bpobgyn.2008.01.008. Epub 2008 Mar 26. PMID: 18372219 Review.
- [45] Angioni S, Loddo A, Milano F, Piras B, Minerba L, Melis GB. Detection of benign intracavitary lesions in postmenopausal women with abnormal uterine bleeding: a prospective comparative study on outpatient hysteroscopy and blind biopsy. *J Minim Invasive Gynecol*. 2008 Jan-Feb;15(1):87-91. doi: 10.1016/j.jmig.2007.10.014. PMID: 18262151
- [46] Russo M, Suen M, Bedaiwy M, Chen I. Prevalence of Uterine Myomas Among Women with 2 or More Recurrent Pregnancy Losses: A Systematic Review. *J Minim Invasive Gynecol*. 2016 Jul-Aug;23(5):702-6. doi:10.1016/j.jmig.2016.03.018. Epub 2016 Mar 31. PMID: 27041652 Review.
- [47] Wallach EE, Vlahos NF. Uterine myomas: an overview of development, clinical features, and management. *Obstet Gynecol*. 2004 Aug;104(2):393-406. doi: 10.1097/01.AOG.0000136079.62513.39. PMID: 15292018 Review.
- [48] Kjerulff KH, Langenberg P, Seidman JD, Stolley PD, Guzinski GM. Uterine leiomyomas. Racial differences in severity, symptoms and age at diagnosis. *J Reprod Med*. 1996 Jul;41(7):483-90. PMID: 8829060
- [49] Stovall DW. Clinical symptomatology of uterine leiomyomas. *Clin Obstet Gynecol*. 2001 Jun;44(2):364-71. doi: 10.1097/00003081-200106000-00022. PMID: 11344999 Review.
- [50] Leung F, Terzibachian JJ, Gay C, Chung Fat B, Aouar Z, Lassabe C, Maillat R, Riethmuller D. Hysterectomies performed for presumed leiomyomas: should the fear of leiomyosarcoma make us apprehend non laparotomic surgical routes?. *Gynecol Obstet Fertil*. 2009 Feb;37(2):109-14. doi: 10.1016/j.gyobfe.2008.09.022. Epub 2009 Feb 5. PMID: 19200764
- [51] Rackow BW, Arici A. Options for medical treatment of myomas. *Obstet Gynecol Clin North Am*. 2006 Mar;33(1):97-113. doi: 10.1016/j.ogc.2005.12.014. PMID: 16504809 Review.
- [52] Donnez J, Courtoy GE, Dolmans MM. Fibroid management in premenopausal women. *Climacteric*. 2019 Feb;22(1):27-33. doi: 10.1080/13697137.2018.1549216. Epub 2019 Jan 2. PMID: 30601065
- [53] Donnez J, Dolmans MM. Uterine fibroid management: from the present to the future. *Hum Reprod Update*. 2016 Nov;22(6):665-686. doi: 10.1093/humupd/dmw023. Epub 2016 Jul 27. PMID: 27466209
- [54] Lethaby A, Vollenhoven B, Sowter M. Efficacy of pre-operative gonadotrophin hormone releasing analogues for women with uterine

fibroids undergoing hysterectomy or myomectomy: a systematic review. BJOG. 2002 Oct;109(10):1097-108. doi: 10.1111/j.1471-0528.2002.01225.x. PMID: 12387461

[55] Lethaby A, Vollenhoven B, Sowter M. Pre-operative GnRH analogue therapy before hysterectomy or myomectomy for uterine fibroids. Cochrane Database Syst Rev. 2001;(2):CD000547. doi: 10.1002/14651858.CD000547. PMID: 11405968

[56] Lethaby A, Puscasiu L, Vollenhoven B. Preoperative medical therapy before surgery for uterine fibroids. Cochrane Database Syst Rev. 2017 Nov 15;11(11):CD000547. doi: 10.1002/14651858.CD000547.pub2. PMID: 29139105

[57] Sankaran S, Manyonda IT. Medical management of fibroids. Best Pract Res Clin Obstet Gynaecol. 2008 Aug;22(4):655-76. doi: 10.1016/j.bpobgyn.2008.03.001. Epub 2008 May 12. PMID: 18468953 Review.

[58] Islam MS, Protic O, Giannubilo SR, Toti P, Tranquilli AL, Petraglia F, Castellucci M, Ciarmela P. Uterine leiomyoma: available medical treatments and new possible therapeutic options. J Clin Endocrinol Metab. 2013 Mar;98(3):921-34. doi: 10.1210/jc.2012-3237. Epub 2013 Feb 7. PMID: 23393173 Review.

[59] Lethaby AE, Vollenhoven BJ. An evidence-based approach to hormonal therapies for premenopausal women with fibroids. Best Pract Res Clin Obstet Gynaecol. 2008 Apr;22(2):307-31. doi: 10.1016/j.bpobgyn.2007.07.010. Epub 2007 Oct 1. PMID: 17905660 Review.

[60] Bouchard P, Ouzounian S, Chabbert-Buffet N. Selective progesterone receptor modulators: future clinical applications. Bull Acad

Natl Med. 2008 Jun-Jul;192(6):1159-71; discussion 1172-3. PMID: 19235480

[61] Laberge PY, Murji A, Vilos GA, Allaire C, Leyland N, Singh SS. Guideline No. 389-Medical Management of Symptomatic Uterine Leiomyomas - An Addendum. J Obstet Gynaecol Can. 2019 Oct;41(10):1521-1524. doi: 10.1016/j.jogc.2019.01.010. PMID: 3154804

[62] Elahi SM, Odejinmi F Overview of current surgical management of fibroids: 'Organ-preserving modalities'. J Obstet Gynaecol. 2008 Jan;28(1):28-31. doi: 10.1080/01443610701814328. PMID: 18259894 Review.

[63] Liu WM, Wang PH, Chou CS, Tang WL, Wang IT, Tzeng CR. Efficacy of combined laparoscopic uterine artery occlusion and myomectomy via minilaparotomy in the treatment of recurrent uterine myomas. Fertil Steril. 2007 Feb;87(2):356-61. doi: 10.1016/j.fertnstert.2006.07.1497. Epub 2006 Oct 25. PMID: 17069812 Clinical Trial.

[64] Kaminski P, Gajewska M, Wielgos M, Sadowski K, Szymusik I, Bartkowiak R, Marianowski P, Czuba B. Laparoscopic treatment of uterine myomas in women of reproductive age. Neuro Endocrinol Lett. 2008 Feb;29(1):163-7. PMID: 18283255

[65] Agdi M, Tulandi T Endoscopic management of uterine fibroids. Best Pract Res Clin Obstet Gynaecol. 2008 Aug;22(4):707-16. doi: 10.1016/j.bpobgyn.2008.01.011. Epub 2008 Mar 6. PMID: 18325839 Review.

[66] Keserci B, Duc NM, Nadarajan C, Huy HQ, Saizan A, Wan Ahmed WA, Osman K, Abdullah MS. Volumetric MRI-guided, high-intensity focused ultrasound ablation of uterine leiomyomas: ASEAN preliminary experience. Diagn Interv Radiol. 2020 May;26(3):207-215. doi: 10.5152/dir.2019.19157. PMID: 32209511

- [67] Marshburn PB, Matthews ML, Hurst BS. Uterine artery embolization as a treatment option for uterine myomas. *Obstet Gynecol Clin North Am.* 2006 Mar;33(1):125-44. doi: 10.1016/j.ogc.2005.12.009. PMID: 16504811 Review.
- [68] Zurawin RK, Fischer JH 2nd, Amir L The effect of a gynecologist-interventional radiologist relationship on selection of treatment modality for the patient with uterine myoma. *J Minim Invasive Gynecol.* 2010 Mar-Apr;17(2):214-21. doi: 10.1016/j.jmig.2009.12.015. PMID: 20226411
- [69] Istre O. Management of symptomatic fibroids: conservative surgical treatment modalities other than abdominal or laparoscopic myomectomy. *Best Pract Res Clin Obstet Gynaecol.* 2008 Aug;22(4):735-47. doi: 10.1016/j.bpobgyn.2008.01.010. Epub 2008 Mar 7. PMID: 18328788 Review
- [70] Lupattelli T, Clerissi J, Basile A, Minnella DP, Donati Sarti R, Gerli S, Di Renzo G. Treatment of uterine fibromyoma with bilateral uterine artery embolization: state of the art. *Minerva Ginecol.* 2007 Aug;59(4):427-39. PMID: 17923833 Review.
- [71] Tsikouras P, Manav B, Koukouli Z, Trypsiannis G, Galazios G, Souftas D, Souftas V. Ovarian reserve after fibroid embolization in premenopausal women. *Minim Invasive Ther Allied Technol.* 2017 Oct;26(5):284-291. doi: 10.1080/13645706.2017.1292919. Epub 2017 Feb 24. PMID: 28635407
- [72] Souftas V, Deuteraiou D, Anthoulaki X, Chalkidou A, Bothou A, Gaidatzi F, Tsypsiannis G, Iatrakis G, Zervoudis S, Souftas D, Michalopoulos S, Vogiatzaki T, Galazios G, Nikolettos N, Tsikouras P. Significance of changes in inflammatory parameters following uterine artery embolization in premenopausal females. *Exp Ther Med.* 2020 Jun;19(6):3684-3690. doi: 10.3892/etm.2020.8652. Epub 2020 Apr 9. PMID: 32346432
- [73] Armstrong AA, Kroener L, Brower M, Al-Safi ZA. Analysis of Reported Adverse Events with Uterine Artery Embolization for Leiomyomas. *J Minim Invasive Gynecol.* 2019 May-Jun;26(4):667-670.e1. doi: 10.1016/j.jmig.2018.07.006. Epub 2018 Aug 29. PMID: 30016750
- [74] Soeda S, Hiraiwa T, Takata M, Kamo N, Sekino H, Nomura S, Kojima M, Kyojuka H, Ozeki T, Ishii S, Tameda T, Asano K, Miyazaki M, Takahashi T, Watanabe T, Taki Y, Fujimori K. Unique Learning System for Uterine Artery Embolization for Symptomatic Myoma and Adenomyosis for Obstetrician-Gynecologists in Cooperation with Interventional Radiologists: Evaluation of UAE From the Point of View of Gynecologists Who Perform UAE. *J Minim Invasive Gynecol.* 2018 Jan;25(1):84-92. doi: 10.1016/j.jmig.2017.08.008. Epub 2017 Aug 12. PMID: 28807810
- [75] Mutiso SK, Oindi FM, Hacking N, Obura T. Uterine Necrosis after Uterine Artery Embolization for Symptomatic Fibroids. *Case Rep Obstet Gynecol.* 2018 May 28;2018:9621741. doi: 10.1155/2018/9621741. eCollection 2018. PMID: 29998027
- [76] Toor SS, Jaber A, Macdonald DB, McInnes MD, Schweitzer ME, Rasuli P. Complication rates and effectiveness of uterine artery embolization in the treatment of symptomatic leiomyomas: a systematic review and meta-analysis. *AJR Am J Roentgenol.* 2012 Nov;199(5):1153-63. doi: 10.2214/AJR.11.8362. PMID: 23096193
- [77] Olive DL, Lindheim SR, Pritts EA. Conservative surgical management of uterine myomas. *Obstet Gynecol Clin North Am.* 2006 Mar;33(1):115-24. doi: 10.1016/j.ogc.2005.12.012. PMID: 16504810

- [78] Marret H, Fritel X, Ouldamer L, Bendifallah S, Brun JL, De Jesus I, Derrien J, Giraudet G, Kahn V, Koskas M, Legendre G, Lucot JP, Niro J, Panel P, Pelage JP, Fernandez H; CNGOF (French College of Gynecology and Obstetrics). Therapeutic management of uterine fibroid tumors: updated French guidelines. *Eur J Obstet Gynecol Reprod Biol.* 2012 Dec;165(2):156-64. doi: 10.1016/j.ejogrb.2012.07.030. Epub 2012 Aug 29. PMID: 22939241 Review.
- [79] Kalina I, Tóth A, Valcseva É, Kaposi PN, Ács N, Várbiro S, Bérczi V. Prognostic value of pre-embolisation MRI features of uterine fibroids in uterine artery embolisation. *Clin Radiol.* 2018 Dec;73(12):1060.e1-1060.e7. doi: 10.1016/j.crad.2018.08.009. Epub 2018 Oct 9. PMID: 30309632
- [80] Katsumori T, Asai S, Yokota H, Miura H. Volume of embolic agents in uterine artery embolization for leiomyoma: relation to baseline MRI. *Minim Invasive Ther Allied Technol.* 2019 Jun;28(3):186-193. doi: 10.1080/13645706.2018.1513408. Epub 2018 Sep 27. PMID: 30261778
- [81] Kohi MP, Spies JB. Updates on Uterine Artery Embolization. *Semin Intervent Radiol.* 2018 Mar;35(1):48-55. doi: 10.1055/s-0038-1636521. Epub 2018 Apr 5. PMID: 29628616
- [82] Chung YJ, Kang SY, Chun HJ, Rha SE, Cho HH, Kim JH, Kim MR. Development of a Model for the Prediction of Treatment Response of Uterine Leiomyomas after Uterine Artery Embolization. *Int J Med Sci.* 2018 Nov 23;15(14):1771-1777. doi: 10.7150/ijms.28687. eCollection 2018.
- [83] SOGC clinical practice guidelines. Uterine fibroid embolization (UFE). Number 150, October 2004. Society of Obstetricians and Gynaecologists of Canada. *Int J Gynaecol Obstet.* 2005 Jun;89(3):305-18. doi: 10.1016/j.ijgo.2005.03.013. PMID: 16001461 Review.
- [84] Kröncke T, David M. Uterine Artery Embolization (UAE) for Fibroid Treatment - Results of the 7th Radiological Gynecological Expert Meeting. *Rofo.* 2019 Jul;191(7):630-634. doi: 10.1055/a-0884-3168. Epub 2019 May 28. PMID: 31137043
- [85] Lohle PNM, Higué D, Herbreteau D. Uterine artery embolisation in women with symptomatic uterine fibroids. *Presse Med.* 2019 Apr;48(4):440-446. doi: 10.1016/j.lpm.2019.03.012. Epub 2019 Apr 27. PMID: 31036388
- [86] Davis MR, Soliman AM, Castelli-Haley J, Snabes MC, Surrey ES. Reintervention Rates After Myomectomy, Endometrial Ablation, and Uterine Artery Embolization for Patients with Uterine Fibroids. *J Womens Health (Larchmt).* 2018 Oct;27(10):1204-1214. doi: 10.1089/jwh.2017.6752. Epub 2018 Aug 7. PMID: 30085898
- [87] Stepniak A. Uterine artery embolization in the treatment of symptomatic fibroids - state of the art 2018. *Prz Menopauzalny.* 2018 Dec;17(4):141-143. doi: 10.5114/pm.2018.81733. Epub 2018 Dec 31. PMID: 30766459
- [88] El Shamy T, Amer SAK, Mohamed AA, James C, Jayaprakasan K. The impact of uterine artery embolization on ovarian reserve: A systematic review and meta-analysis. *Acta Obstet Gynecol Scand.* 2020 Jan;99(1):16-23. doi: 10.1111/aogs.13698. Epub 2019 Aug 26. PMID: 31370100
- [89] Lacayo EA, Khera SS, Spies JB. Impact of Patient and Procedure-Related Factors on Radiation Exposure from Uterine Artery Embolization. *Cardiovasc Intervent Radiol.* 2020 Jan;43(1):120-126. doi: 10.1007/

s00270-019-02321-7. Epub 2019 Sep 11.
PMID: 31511962

[90] Siskin GP. Optimizing Fibroid Infarction Rates after Uterine Artery Embolization. J Vasc Interv Radiol. 2019 May;30(5):677-678. doi: 10.1016/j.jvir.2018.11.040. PMID: 31029386

[91] Peitsidis P, Chernev A, Peitsidou A, Tsekoura V, Zervoudis S, Navrozoglou I, et al. Treatment of leiomyomas with uterine artery embolization. Review of literature. Bulgarian: Akush Ginekol (Sofia); 2008;47(1):38-42. PMID: 18642577