

We are IntechOpen, the world's leading publisher of Open Access books Built by scientists, for scientists

6,900

Open access books available

186,000

International authors and editors

200M

Downloads

Our authors are among the

154

Countries delivered to

TOP 1%

most cited scientists

12.2%

Contributors from top 500 universities



WEB OF SCIENCE™

Selection of our books indexed in the Book Citation Index
in Web of Science™ Core Collection (BKCI)

Interested in publishing with us?
Contact book.department@intechopen.com

Numbers displayed above are based on latest data collected.
For more information visit www.intechopen.com



Definitive Radiotherapy for Locally Advanced Non-Small Cell Lung Cancer: Current Status and Future Perspectives

Hiroshi Doi and Kozo Kuribayashi

Abstract

Lung cancer remains one of the most common cancers, and the mortality rate is still high. Radiotherapy plays an important role in radical treatment for locally advanced non-small cell lung cancer. Treatment outcomes in lung cancer have improved over the last few decades. Several treatment regimens have been shown to be effective and safe. Further, modern technological approaches of radiotherapy have been developed along with advanced imaging and immunotherapy in order to improve outcomes and minimize radiation-induced toxicity. This chapter summarizes the historical results of the key clinical studies that were conducted in the past with the focus on various regimens of chemoradiotherapy used. In addition, we discuss future perspectives of definitive radiotherapy for locally advanced non-small cell lung cancer.

Keywords: lung cancer, radiotherapy, chemoradiotherapy, intensity modulated radiation therapy, durvalumab

1. Introduction

The lung cancer remains one of the most common cancers, and 80% of lung cancers account for non-small cell lung cancer (NSCLC) [1]. Patients diagnosed at a locally advanced stage represent 20 to 30%, and radical surgery is challenging for those patients [1]. Definitive chemoradiotherapy is a well-established treatment option for unresectable locally advanced NSCLC [2, 3]. Treatment outcomes in such patients have improved over the last few decades. Several treatment regimens have been shown to be effective and safe. Moreover, modern radiotherapy technologies have been developed along with the development of optimal chemotherapy and immunotherapy to improve outcomes and minimize radiation-induced toxicity. This chapter summarizes historical results of key clinical studies in the past in terms of various regimens of chemoradiotherapy. In addition, we discuss definitive radiotherapy, which is recommended for locally advanced NSCLC. Specifically, we address future perspectives of definitive radiotherapy for locally advanced NSCLC.

2. History of the development of definitive radiotherapy for locally advanced NSCLC

Radiotherapy alone was a standard treatment for inoperable lung cancer up to the 1980s based on the results of a randomized controlled trial in the 1960s [4]. Perez et al. showed the dose–response efficacy up to 60 Gy, which had been a standard dose from the combined results of the RTOG 7101 and 73–02 study [5]. After the 1990s, definitive radiotherapy, using ≥ 60 Gy in a conventional fractionated regimen, combined with chemotherapy, has been used as a standard treatment for unresectable locally advanced NSCLC. In the early 1990s, sequential cisplatin-based chemotherapy followed by radiotherapy had been proven to have a survival benefit over definitive radiotherapy alone and chemotherapy alone for unresectable stage III NSCLC [6–9]. Then, from the late 1990s to the 2000s, several randomized clinical trials revealed that the concurrent approach of chemoradiotherapy enhanced survival compared to the sequential approach [10–13]. After 2000, the usefulness of several new agents, such as paclitaxel, gemcitabine, vinorelbine, and docetaxel, which are called third-generation chemotherapy agents, have been studied. They have been usually administered in combination with platinum compounds, and demonstrated increased survival in patients with metastatic NSCLC [14, 15]. Although there has been no significant improvement in survival achieved with chemoradiotherapy using third-generation regimens, it has become a standard treatment with a favorable toxicity profile [16, 17].

Some clinical studies conducted between 1990s and 2000s showed that hyperfractionated, accelerated radiotherapy was superior to the conventional fractionated radiotherapy with a feasible toxicity [18–21]. However, the benefit of hyperfractionated, accelerated radiotherapy is controversial, with high risk of acute esophageal toxicity; and has been less accepted in clinical practice [2, 21, 22]. After 2000, the utility of consolidation chemotherapy following chemoradiotherapy has failed to prove a significant survival benefit [23–25]. A dose escalation of radiotherapy has been investigated because loco-regional tumor control might be associated with better survival; and there is a potential dose–response efficacy in the control of NSCLC using this approach [5, 26]. However, RTOG 0617 trial failed to prove benefits on overall survival (OS) and progression-free survival (PSF) using the escalated doses of 74 Gy compared to the standard dose of 60 Gy in an open-label randomized phase 3 study [27]. Volume prescriptions such as D95 using updated calculation algorithms in recent clinical trials could reveal a slightly escalated dose for the target, in comparison with the point prescription that has been used in previous studies. However, the standard regimen of definitive radiotherapy has been 60 Gy in 30 fractions.

As shown in **Figure 1**, the median survival time after treatment has improved with the development of chemoradiotherapy. However, the 5-year survival rate has been unsatisfactorily, reaching only up to 20%. Recently, immune checkpoint inhibitors (ICIs) have been applied in the treatment of advanced malignancies, including lung cancer [29]. ICIs block checkpoint proteins that can weaken immune responses by T cells to cancer cells. Recent systematic reviews have demonstrated the beneficial effects of ICIs on OS and PSF in advanced NSCLC [30]. The PACIFIC trial, a randomized, double-blind, placebo-controlled multi-center trial, has tested the efficacy of durvalumab, which is a human monoclonal antibody directed against programmed cell death-ligand 1 (PD-L1), in patients with stage III NSCLC as sequential treatment following standard concurrent chemoradiotherapy [19–32]. Durvalumab has brought a breakthrough in the treatment of locally advanced

NSCLC in decades, and median survival after treatment has not reached with a median follow-up of 33.3 months in a recent updated result [28]. The transition of standard definitive radiotherapy for locally advanced NSCLN and representative of the clinical outcomes of selected prospective clinical trials with time are shown in **Table 1** and **Figure 1**.

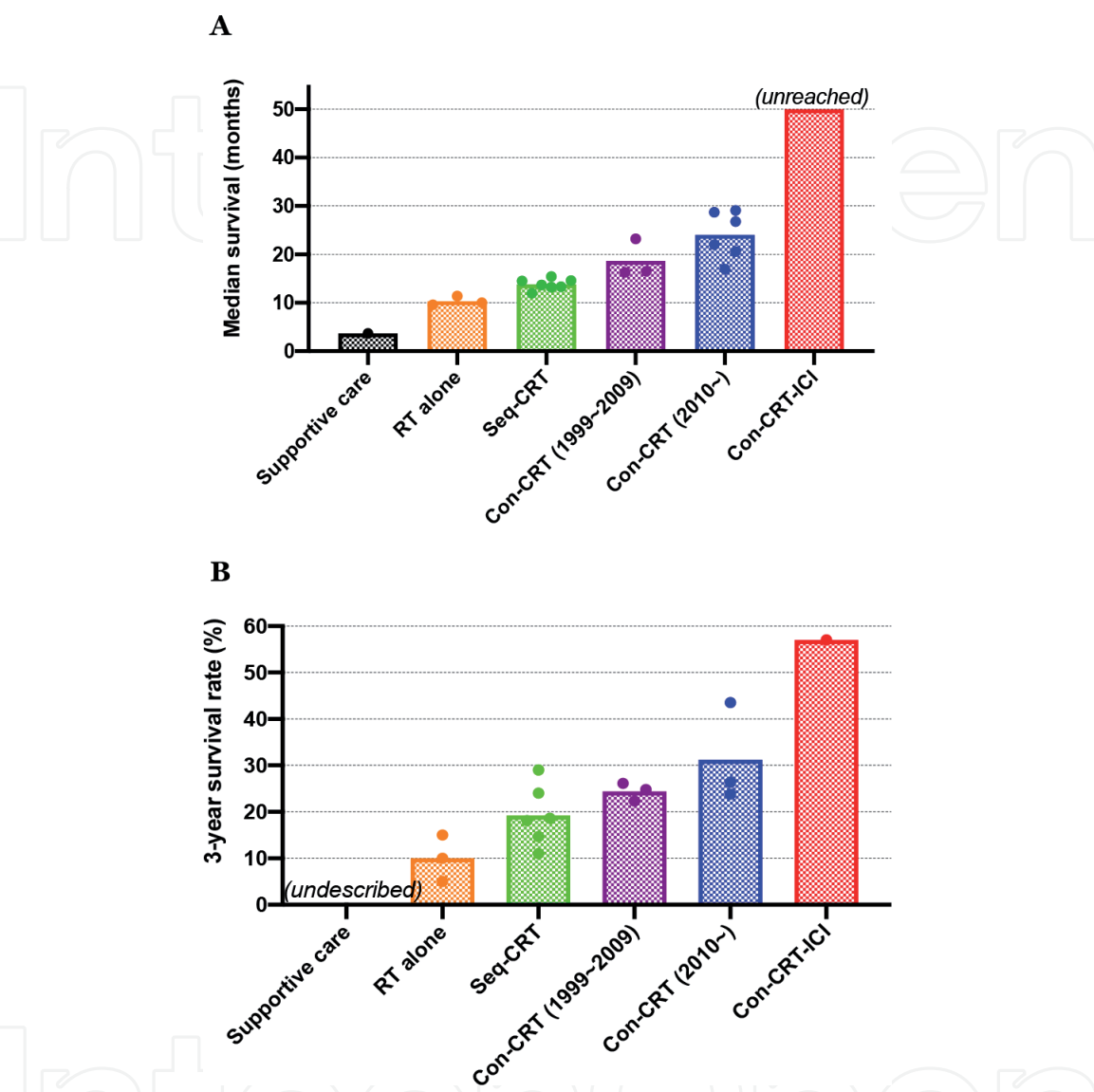


Figure 1. Improvement of survival outcome of locally advanced NSCLN. (A) Median survival and (B) 3-year overall survival per selected prospective clinical studies and meta-analyses [4–13, 16, 17, 23, 24, 27, 28]. Each bar indicates the mean value of the results. Radiotherapy group included locally advanced NSCLC patients who underwent treatment with standard radiation doses such as ≥ 60 Gy in a conventional schedule. Abbreviations: Con-CRT, concurrent chemoradiotherapy; Con-CRT-ICI, concurrent chemoradiotherapy with consolidation immune checkpoint inhibitor; RT, radiotherapy; Seq-CRT, sequential chemoradiotherapy.

~ 1980s	Radiotherapy alone
1990s	Sequential chemoradiotherapy
	Concurrent chemoradiotherapy (second-generation regimen)
2000s	Concurrent chemoradiotherapy (third-generation regimen)
2020~	Concurrent chemoradiotherapy followed by immune checkpoint inhibitor (dumvalumab)

Table 1.
Transition of standard definitive radiotherapy for locally advanced NSCLN.

3. Utility of intensity-modulated radiotherapy, learning from RTOG 0617 and PACIFIC trials

RTOG 0617 trial failed to demonstrate the benefit of dose-escalation of 74 Gy compared with 60 Gy, but also provided significant information for clinical practice, as it was the first phase III NSCLC study to allow intensity-modulated radiotherapy (IMRT) as a treatment modality for locally advanced NSCLC, and 46% of enrolled patients underwent IMRT [27, 33].

The disadvantage of IMRT in terms of dose distribution is increased volume of lungs receiving low-dose radiation, called “low-dose bath” because the IMRT plan is created using the increased number of beam angles [34]. Low-dose baths represented by large volumes of lung V5 (the volume of the lungs receiving ≥ 5 Gy) has been reported to increase the risk of acute and late pulmonary toxicity [34–36]. IMRT was used to treat larger and unfavorable tumors in RTOG 0617 [37]. Lung V5 was significantly higher in the IMRT group than in the 3D-CRT group. However, IMRT was associated with lower rates of severe pneumonitis in the RTOG 0617 prospective clinical trial. In addition, severe pneumonitis was predicted by lung V20, but not V5. Thus, V20 has been confirmed as a well-established risk factor of radiation pneumonitis with high reproducibility [38]. It is difficult to clarify the controversial meaning of V5 as a predictor of radiation pneumonitis. However, IMRT could improve target coverage and reduce the volume of normal lungs irradiated with intermediate doses such as V20 [34]. Grade ≥ 2 pneumonitis after chemoradiotherapy was a significant exclusion criterion in the PACIFIC trial [31]. The reduction of the risk of radiation pneumonitis by using IMRT might maximize the opportunity of receiving consolidation ICI based on the PACIFIC trial, although detailed data on radiotherapy was not collected in the PACIFIC trial [28, 31, 32, 37].

Higher doses to heart and esophagitis were associated with poor survival [37, 39]. In patients receiving heart V50 $< 25\%$ versus ≥ 25 , the 1-year OS rates were 70.2% versus 46.8% and the 2-year OS rates were 45.9% versus 26.7% ($p < 0.0001$) [39]. Heart V40, which has been shown to be a prognostic factor for survival, can be substantially reduced with IMRT compared to 3D-CRT. In addition, the use of IMRT was associated with significantly less decline in quality of life [40]. These toxicities were potentially associated with poor survival in patients treated with escalated radiation doses of 74 Gy [27]. Furthermore, the correlation of institution accrual volume with the treatment outcomes is controversial but can be associated with other malignancies such as head and neck cancers [39, 41–43]. Quality assurance and institutional experience seem important in radical treatment of locally advanced NSCLC.

The benefits of proton therapy have been reported and included a better dose distribution to the lung and heart in treatment plan than in photon radiotherapy [44]. A randomized control study that compared the utility of proton therapy with that of IMRT showed no significant benefit in terms of the occurrence of radiation pneumonitis and local failure [45]. Modern proton techniques might improve clinical outcomes, but there is no significant evidence of a superiority of proton therapy over IMRT at this moment.

IMRT allows the treatment of challenging cases with dosimetric and clinical benefits. Therefore, IMRT is a current standard technique in the definitive radiotherapy for advanced NSCLC, as the use of IMRT has various advantages over 3D-CRT, which obviously outweighs the disadvantages.

4. Tips for using definitive radiotherapy for locally advanced NSCLC

4.1 Involved-field radiotherapy

The European Society for Radiotherapy and Oncology recommends that metastatic nodes and the applicable margin with no further elective lymph nodes should be included in clinical tumor volume (CTV) [46]. Radiotherapy has been prescribed to the intersection point of the treatment beams [18]. An initial radiotherapy was administered to the anteroposterior parallel-opposed pair of portals and then to a pair of oblique fields during the boosted radiotherapy [16]. Traditionally, definitive radiotherapy for locally advanced NSCLC targets the primary disease and nodal metastases as well as the mediastinum and ipsilateral hilum whether or not there is clinical involvement of all nodal stations [6, 7, 9–11, 13, 17, 18, 22]. This technique is known as elective nodal irradiation (ENI). Potential dose–response has been reported, and an increased radiation dose has been believed to improve survival in NSCLC before RTOG 0617 [5, 26]. Involved field radiotherapy (IFRT) is a radiation treatment technique that minimizes the radiation dose to uninvolved areas [47]. For example, **Figure 2** indicates the difference in planning target volume (PTV) between ENI and IFRT. IFRT allows radiation doses to be increased to the primary tumor and involves mediastinal lymph nodes. Thus, landmark clinical trials testing dose escalation adopted IFRT [27, 48, 49]. Although there are limited data directly comparing IFRT and ENI, the elective nodal failure rate after IFRT has been reported to be <10% in most reports [50–56]. Generally, IFRT can decrease the risk of severe toxicities, including acute esophagitis and pneumonitis, while showing no significant differences in elective nodal failure rate and survival outcomes in comparison with ENI [54–56]. Importantly, metastatic nodes should be defined with the guidance of PET images [46, 57]. Thereafter, CTV is generated by adding 5 to 10 mm to the gross tumor volume (GTV) of the primary tumor (typically 8 mm and 6 mm for adenocarcinoma and squamous carcinoma, respectively) and 3 mm for GTV of metastatic nodes of <20 mm [46, 58, 59].

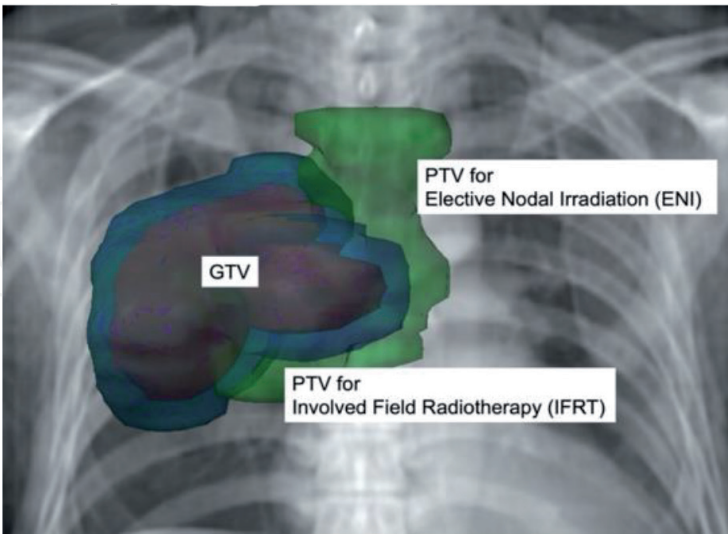


Figure 2.
Differences in radiotherapy target selection in elective nodal irradiation and involved field radiotherapy. Squamous cell carcinoma in the upper lobe of the right lung with nodal metastases (cT3N2Mo). Red, green, and blue indicates gross tumor volume (GTV), planning target volume (PTV) for elective nodal irradiation (ENI), and that for involved field radiotherapy (IFRT), respectively. The clinical target volume (CTV) for ENI including the upper mediastinum enlarges the size of the PTV.

4.2 Respiratory management in locally advanced NSCLC

An important challenge for lung cancer radiotherapy treatment is the management of physiological movements related to breathing. The lung tumors can move during breathing. Usually, to ensure adequate dose delivery to the tumor, an appropriate margin is added around the tumor. Four-dimensional computed tomography (4DCT) is a technique that allows to quantify the movement of the tumor with the use of respiratory reduction equipment such as an abdominal compression device. The internal target volume (ITV) is delineated on the 4DCT scan in order to account for tumor motion, and an additional margin is added to generate PTV. However, the target is large as it covers the entire tumor motion, especially in tumors in the lower lobe of the lung [60].

The breath-hold technique has been used to minimize the target volume, which must be irradiated with high-dose radiation and can help to reduce risk of radiation pneumonitis (**Figure 3**). In particular, the deep inspiration breath hold (DIBH) technique provides an advantage to a free-breathing treatment and could reduce the dosimetric parameters of normal organs such as the lung in dose-volume histograms [61]. DIBH gating has been clinically used in thoracic and upper abdominal radiotherapy [62]. In addition, it has recently been reported that compliance and reproducibility of DIBH was sufficiently high, with a reported compliant rate of 72% in a prospective clinical study [63]. DIBH has a high potential as a standard treatment in definitive radiotherapy for locally advanced NSCLC.

4.3 Image-guided radiotherapy in locally advanced NSCLC

In recent years, advancements in image-guided radiotherapy (IGRT) technology have enabled more accurate positioning and precise radiotherapy. IGRT is an essential companion to IMRT and allows the treatment to account for daily changes in target anatomy, motion, and positioning. Megavoltage (MV) portal imaging had been conventionally used to correct the setup errors and limited to verification of bony anatomy. In recent years, the X-ray source for imaging has been evolving from MV imaging to kilovoltage (kV) imaging, and from two-dimensional to three-dimensional

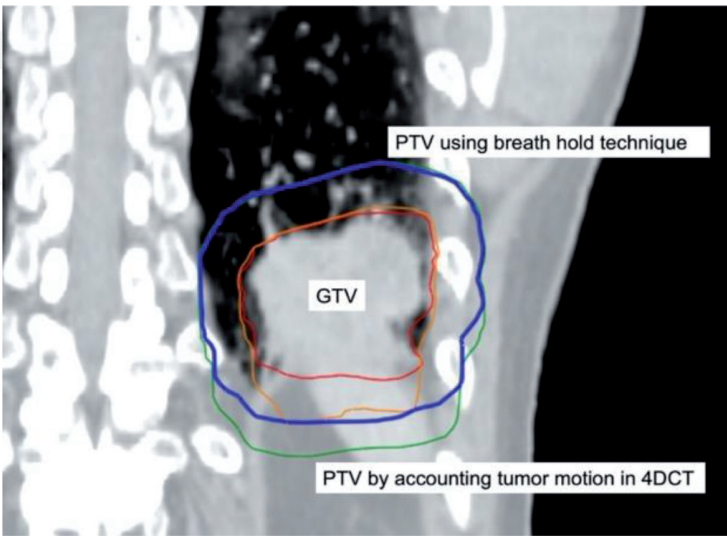


Figure 3. Breath hold technique can minimize a target volume. Non-small cell lung cancer in the lower lobe of the left lung. Red, orange blue, and green indicate gross tumor volume (GTV), accumulated GTV on four-dimensional computed tomography (4DCT), planning target volume (PTV) using the breath-hold technique (exhale), and PTV, which was generated by accounting tumor motion in 4DCT, respectively. The breath-hold technique reduces the target volume.

imaging. Modern IGRT is performed with either gantry mounted MV or kV cone beam computed tomography (CBCT) or room-mounted kV systems for tracking during treatment. IGRT allows for easier and improved accuracy leading more frequent positioning changes with leading to a therapeutic advantage. Kilburn et al. has reported that IGRT using daily CBCT improved locoregional tumor control than radiotherapy using weekly MV portal images [64].

Three-dimensional images in CBCT are used not only for positioning but also for the evaluation of the radiotherapy planning by dose calculation on the CBCT images. It has recently been reported that dose distribution and dose volume histogram were accurately calculated on CBCT images with a deformable imaging registration [65].

Further, acquired images from CBCT can be used for individualized treatment, called adaptive radiotherapy (ART). Since there are possible changes of tumor and surrounding tissues during the treatment courses due to tumor shrinking and anatomical changes, it is necessary to modify the radiotherapy plan with accounting the appropriate margin, positioning, and tumor. CBCT provides significant three-dimensional information to evaluate if the patient would benefit from a re-scanning and re-planning. Indeed, ART can improve locoregional tumor control over radiotherapy without ART [66].

Daily IGRT with CBCT and ART has been reported to reduce toxicity and probably increase tumor response due to a better tumor localization and reduction of an interfraction target miss due to anatomical changes [64, 66, 67]. Further studies should be conducted in order to establish the optimal systemic replanning technique.

5. Future perspectives of definitive radiotherapy for locally advanced NSCLC

5.1 Failure pattern and potential salvage after definitive radiotherapy

Approximately 40% and 50% of locally advanced NSCLC patients experience locoregional and distant failures two years after the definitive chemoradiotherapy [27]. Consolidation ICI has been proven to reduce disease progression in both the intrathoracic and extrathoracic areas [32, 68]. Time to death or distant metastasis was longer, and the frequency of new lesions was lower with the use of durvalumab in comparison with placebo [32]. Notably, distant failure occurred in one or two lesions (66.6% in durvalumab arm) in a single organ (95.2% in durvalumab arm) at first progression in both arms of durvalumab and placebo with a median follow-up of 25.2 months [68]. Therefore, there seems to be a window of opportunity for treating these limited failures as a salvage, which might lead to a longer survival [69–71]. Cutting-edge radiotherapies, such as stereotactic radiotherapy and particle therapy, have the potential to be a prospective option as a salvage modality.

The results of the PACIFIC clinical trial have led to the design of several clinical trials combining radiotherapy with ICIs, including PACIFIC-2 study, where a chemoradiotherapy plus durvalumab arm is currently studied (NCT03519971). In addition, combining chemotherapy, radiotherapy, and ICIs with surgical resection is also under investigation in clinical trials (NCT03694236, NCT03237377, NCT04073745, NCT03348748).

There are oncological differences between pathological subtypes in NSCLC, as widely known in metastatic diseases [72]. Ito et al. showed that adenocarcinoma and squamous cell carcinoma tended to develop distant and locoregional failures, respectively, after chemoradiotherapy for locally advanced NSCLC [73].

In addition, non-squamous cell carcinoma tends to benefit more from adding durvalumab than squamous cell carcinoma, although there is a lack of direct comparison analysis [32]. The effects of histopathological and oncological differences in NSCLC on definitive chemoradiotherapy should be investigated with the aim of developing a precision treatment for locally advanced NSCLC.

5.2 Immune enhancement and preservation in radiotherapy

Recent developments in immunotherapy have started a new era in the treatment of various malignancies, including NSCLC [29, 30, 74]. Induction of the expression of immune checkpoint molecules such as PD-L1 results in the inhibition of T cell function and immune tolerance of tumors.

Radiation may cause immune activation through cytokine signaling and tumor antigen release [75, 76]. However, PD-L1 expression in tumors has been reported to be upregulated by radiation exposure in both pre-clinical and clinical settings and can suppress the immunogenic effect on tumors [75–78]. ICIs block the immunosuppressive mechanisms of cancer cells and have a synergistic effect in combination with radiotherapy [75, 77]. The addition of durvalumab was proven to benefit disease control and survival after definitive chemoradiotherapy for locally advanced NSCLC [28, 31, 32]. The density of CD8+ tumor-infiltrating lymphocytes was significantly associated with favorable survival in locally advanced NSCLC patients undergoing chemoradiotherapy [79]. In their report, PD-L1 expression, which could be blocked by ICIs, was associated with inferior survival. In addition, radiation-induced lymphopenia has been reported to be associated with inferior survival [80, 81]. Therefore, radiotherapy will be

ClinicalTrials.gov identifier	Study design	Brief of treatment
NCT04432142	Phase 2	Immune changes after concurrent chemoradiation followed by durvalumab
NCT03589547	Phase 2	Durvalumab and consolidation SBRT following chemoradiation
NCT04092283	Phase 3	Durvalumab as concurrent and consolidative therapy or consolidative therapy alone
NCT03801902	Phase 1	Accelerated or conventionally fractionated radiotherapy combined with durvalumab
NCT03663166	Phase 1, 2	Chemoradiotherapy with ipilimumab followed by nivolumab
NCT04310020	Phase 2	Hypofractionated radiotherapy followed by atezolizumab
NCT03693300	Phase 2	Durvalumab following sequential chemotherapy and radiotherapy
NCT04249362	Phase 2	Durvalumab following radiotherapy (standard or hypofractionated bioequivalent dose)
NCT04392505	Phase 2	Investigating biomarkers related to chemoradiation followed by durvalumab
NCT04505267	Phase 1	Reirradiation with NBTXR3 for locoregional recurrence

Searched for: radiotherapy, immune | Recruiting, Not yet recruiting Studies | Non-small Cell Lung Cancer Stage III at <https://clinicaltrials.gov> with excluding trials including surgery on Sep. 7, 2020.

Table 2.
Ongoing phase 1 to 3 clinical trials for locally advanced NSCLN in terms of definitive radiotherapy and immune therapy.

modified to enhance the immune response to tumors. Hypofractionated regimens might have less immunosuppressive effects and are more appropriate than conventional fractionated regimens in terms of immune preservation [82, 83]. A clinical trial has been designed to test the addition of durvalumab to two schedules of radiotherapies of conventional and hypofractionated schedules (NCT03801902). Ongoing clinical trials in terms of definitive radiotherapy combined with ICIs are summarized in **Table 2**.

PTV size can be associated with circulating blood, including the leukocytes [84]. Thus, IFRT is appropriate in terms of not only reducing the risk of pneumonitis but also preservation of the host immune system. Ladbury et al. have presented a predictive model of the estimated dose of radiation to immune cells, which was calculated using the radiation doses for heart, lung, body, and number of fractions, and was associated with cancer-specific outcomes [85]. Thereafter, sparing the host immune system will be discussed, and new optimizing theory for IMRT should be investigated in the future. Radio-immune therapy strategy is giving a new direction to radiotherapy and is warranted to explore future definitive radiotherapy for locally advanced NSCLC.

6. Conclusions

In this chapter, the historical improvement and the current recommendation of definitive radiotherapy for locally advanced NSCLC are described. The current standard treatment for locally advanced NSCLC is definitive radiotherapy, concurrently combined with chemotherapy, followed by anti-PD-L1 treatment. In order to improve outcomes and minimize radiation-induced toxicity, IMRT using an involved-field under modern management of respiration is a present recommendation in this chapter. An optimal combination of radiotherapy and immunotherapy should be warranted in a future investigation.

Acknowledgements

This work was supported by JSPS KAKENHI Grant Number JP20K08093.

IntechOpen

Author details

Hiroshi Doi^{1*} and Kozo Kuribayashi²

1 Department of Radiation Oncology, Kindai University Faculty of Medicine,
Osaka-Sayama, Osaka, Japan

2 Division of Respiratory Medicine, Department of Internal Medicine, Hyogo
College of Medicine, Nishinomiya, Hyogo, Japan

*Address all correspondence to: h-doi@med.kindai.ac.jp

IntechOpen

© 2020 The Author(s). Licensee IntechOpen. This chapter is distributed under the terms of the Creative Commons Attribution License (<http://creativecommons.org/licenses/by/3.0>), which permits unrestricted use, distribution, and reproduction in any medium, provided the original work is properly cited. 

References

- [1] Walters S, Maringe C, Coleman MP, et al. Lung cancer survival and stage at diagnosis in Australia, Canada, Denmark, Norway, Sweden and the UK: a population-based study, 2004-2007. *Thorax*. 2013;68:551-564.
- [2] NCCN Clinical Practice Guidelines in Oncology (NCCN Guidelines®) Non-Small Cell Lung Cancer Version 6. 2020 https://www.nccn.org/professionals/physician_gls/pdf/nscl.pdf [Accessed: 2020-Aug-01]
- [3] Park K, Vansteenkiste J, Lee KH, Pentheroudakis G, Zhou C, Prabhaskar K, et al. Pan-Asian adapted ESMO Clinical Practice Guidelines for the management of patients with locally-advanced unresectable non-small-cell lung cancer: a KSMO-ESMO initiative endorsed by CSCO, ISMPO, JSMO, MOS, SSO and TOS. *Ann Oncol*. 2020;31:191-201.
- [4] Roswit B, Patno ME, Rapp R, Veinbergs A, Feder B, Stuhlbarg J, et al. The Survival of Patients with Inoperable Lung Cancer: A Large-Scale Randomized Study of Radiation Therapy Versus Placebo. *Radiology*. 1968;90:688-697.
- [5] Perez CA, Pajak TF, Rubin P, Simpson JR, Mohiuddin M, Brady LW, et al. Long-term observations of the patterns of failure in patients with unresectable non-small cell carcinoma of the lung treated with definitive radiotherapy. Report by the Radiation Therapy Oncology Group. *Cancer*. John Wiley & Sons, Ltd; 1987;59:1874-1881.
- [6] Le Chevalier T, Arriagada R, Quoix E, Ruffe P, Martin M, Tarayre M, et al. Radiotherapy Alone Versus Combined Chemotherapy and Radiotherapy in Nonresectable Non-Small-Cell Lung Cancer: First Analysis of a Randomized Trial in 353 Patients. *JNCI Journal of the National Cancer Institute*. 1991;83:417-423.
- [7] Kubota K, Furuse K, Kawahara M, Kodama N, Yamamoto M, Ogawara M, et al. Role of radiotherapy in combined modality treatment of locally advanced non-small-cell lung cancer. *Journal of Clinical Oncology*. 1994;12:1547-1552.
- [8] Dillman RO, Herndon J, Seagren SL, Eaton WL, Green MR. Improved Survival in Stage III Non-Small-Cell Lung Cancer: Seven-Year Follow-up of Cancer and Leukemia Group B (CALGB) 8433 Trial. *JNCI Journal of the National Cancer Institute*. 1996;88:1210-1215.
- [9] Sause W, Kolesar P, Taylor S IV, Johnson D, Livingston R, Komaki R, et al. Final results of phase III trial in regionally advanced unresectable non-small cell lung cancer: Radiation Therapy Oncology Group, Eastern Cooperative Oncology Group, and Southwest Oncology Group. *Chest*. 2000;117:358-364.
- [10] Furuse K, Fukuoka M, Kawahara M, Nishikawa H, Takada Y, Kudoh S, et al. Phase III Study of Concurrent Versus Sequential Thoracic Radiotherapy in Combination With Mitomycin, Vindesine, and Cisplatin in Unresectable Stage III Non-Small-Cell Lung Cancer. *Journal of Clinical Oncology*. 1999;17:2692-2699.
- [11] Fournel P, Robinet G, Thomas P, Souquet P-J, Lena H, Vergnenégre A, et al. Randomized phase III trial of sequential chemoradiotherapy compared with concurrent chemoradiotherapy in locally advanced non-small-cell lung cancer: Groupe Lyon-Saint-Etienne d'Oncologie Thoracique-Groupe Français de Pneumo-Cancérologie NPC 95-01 Study. *Journal of Clinical Oncology*. 2005;23:5910-5917.
- [12] Auperin A, Le Pechoux C, Rolland E, Curran WJ, Furuse K, Fournel P, et al. Meta-Analysis of

Concomitant Versus Sequential Radiochemotherapy in Locally Advanced Non-Small-Cell Lung Cancer. *Journal of Clinical Oncology*. 2010;28:2181-2190.

[13] Curran WJ, Paulus R, Langer CJ, Komaki R, Lee JS, Hauser S, et al. Sequential vs Concurrent Chemoradiation for Stage III Non-Small Cell Lung Cancer: Randomized Phase III Trial RTOG 9410. *JNCI Journal of the National Cancer Institute*. 2011;103:1452-1460.

[14] Schiller JH, Harrington D, Belani CP, et al. Comparison of four chemotherapy regimens for advanced non-small-cell lung cancer. *N Engl J Med*. 2002;346:92-98.

[15] Bunn PA Jr, Kelly K: New chemotherapeutic agents prolong survival and improve quality of life in non-small cell lung cancer: A review of the literature and future directions. *Clin Cancer Res*. 1998;4:1087-1100.

[16] Segawa Y, Kiura K, Takigawa N, Kamei H, Harita S, Hiraki S, et al. Phase III Trial Comparing Docetaxel and Cisplatin Combination Chemotherapy With Mitomycin, Vindesine, and Cisplatin Combination Chemotherapy With Concurrent Thoracic Radiotherapy in Locally Advanced Non-Small-Cell Lung Cancer: OLCSG 0007. *Journal of Clinical Oncology*. 2010;28:3299-3306.

[17] Yamamoto N, Nakagawa K, Nishimura Y, Tsujino K, Satouchi M, Kudo S, et al. Phase III Study Comparing Second- and Third-Generation Regimens With Concurrent Thoracic Radiotherapy in Patients With Unresectable Stage III Non-Small-Cell Lung Cancer: West Japan Thoracic Oncology Group WJTOG0105. *Journal of Clinical Oncology*. 2010;28:3739-3745.

[18] Saunders M, Dische S, Barrett A, Harvey A, Griffiths G, Palmar M. Continuous,

hyperfractionated, accelerated radiotherapy (CHART) versus conventional radiotherapy in non-small cell lung cancer: mature data from the randomised multicentre trial. CHART Steering committee. *Radiotherapy and Oncology*. 1999;52:137-148.

[19] Nyman J, Friesland S, Hallqvist A, Seke M, Bergström S, Thaning L, et al. How to improve loco-regional control in stages IIIa-b NSCLC? Results of a three-armed randomized trial from the Swedish Lung Cancer Study Group. *Lung Cancer*. 2009;65:62-67.

[20] Haslett K, Pöttgen C, Stuschke M, Faivre-Finn C. Hyperfractionated and accelerated radiotherapy in non-small cell lung cancer. *J Thorac Dis*. 2014;6:328-335.

[21] Mauguén A, Le Pechoux C, Saunders MI, Schild SE, Turrisi AT, Baumann M, et al. Hyperfractionated or accelerated radiotherapy in lung cancer: an individual patient data meta-analysis. *J Clin Oncol*. 2012;30:2788-2797.

[22] Baumann M, Herrmann T, Koch R, Matthiessen W, Appold S, Wahlers B, et al. Final results of the randomized phase III CHARTWEL-trial (ARO 97-1) comparing hyperfractionated-accelerated versus conventionally fractionated radiotherapy in non-small cell lung cancer (NSCLC). *Radiotherapy and Oncology*. 2011;100:76-85.

[23] Hanna N, Neubauer M, Yiannoutsos C, McGarry R, Arseneau J, Ansari R, et al. Phase III Study of Cisplatin, Etoposide, and Concurrent Chest Radiation With or Without Consolidation Docetaxel in Patients With Inoperable Stage III Non-Small-Cell Lung Cancer: The Hoosier Oncology Group and U.S. Oncology. *Journal of Clinical Oncology*. 2008;26:5755-5760.

[24] Ahn JS, Ahn YC, Kim J-H, Lee CG, Cho EK, Lee KC, et al. Multinational

Randomized Phase III Trial With or Without Consolidation Chemotherapy Using Docetaxel and Cisplatin After Concurrent Chemoradiation in Inoperable Stage III Non-Small-Cell Lung Cancer: KCSG-LU05-04. *Journal of Clinical Oncology*. 2015;33:2660-2666.

[25] Tsujino K, Kurata T, Yamamoto S, Kawaguchi T, Kubo A, Isa S, et al. Is consolidation chemotherapy after concurrent chemoradiotherapy beneficial for patients with locally advanced non-small-cell lung cancer? A pooled analysis of the literature. *J Thorac Oncol*. 2013;8:1181-1189.

[26] Martel M. Estimation of tumor control probability model parameters from 3-D dose distributions of non-small cell lung cancer patients. *Lung Cancer*. 1999;24:31-37.

[27] Bradley JD, Paulus R, Komaki R, Masters G, Blumenschein G, Schild S, et al. Standard-dose versus high-dose conformal radiotherapy with concurrent and consolidation carboplatin plus paclitaxel with or without cetuximab for patients with stage IIIA or IIIB non-small-cell lung cancer (RTOG 0617): a randomised, two-by-two factorial phase 3 study. *Lancet Oncol*. 2015;16:187-199.

[28] Gray JE, Villegas A, Daniel D, Vicente D, Murakami S, Hui R, et al. Three-Year Overall Survival with Durvalumab after Chemoradiotherapy in Stage III NSCLC-Update from PACIFIC. *J Thorac Oncol*. 2020;15:288-293.

[29] Granier C, De Guillebon E, Blanc C, Roussel H, Badoual C, Colin E, et al. Mechanisms of action and rationale for the use of checkpoint inhibitors in cancer. *ESMO Open*. 2017;2:e000213.

[30] Wagner G, Stollenwerk HK, Klerings I. Efficacy and safety of immune checkpoint inhibitors in patients with advanced non-small cell

lung cancer (NSCLC): a systematic literature review. *OncoImmunology*. 2020;9:1.

[31] Antonia SJ, Villegas A, Daniel D, Vicente D, Murakami S, Hui R, et al. Durvalumab after Chemoradiotherapy in Stage III Non-Small-Cell Lung Cancer. *N Engl J Med*. 2017;377:1919-1929.

[32] Antonia SJ, Villegas A, Daniel D, Vicente D, Murakami S, Hui R, et al. Overall Survival with Durvalumab after Chemoradiotherapy in Stage III NSCLC. *N Engl J Med*. 2018;379:2342-2350.

[33] Bradley JD, Hu C, Komaki RR, Masters GA, Blumenschein GR, Schild SE, et al. Long-Term Results of NRG Oncology RTOG 0617: Standard-Versus High-Dose Chemoradiotherapy With or Without Cetuximab for Unresectable Stage III Non-Small-Cell Lung Cancer. *J Clin Oncol*. 2020;38:706-714.

[34] Yom SS, Liao Z, Liu HH, Tucker SL, Hu C-S, Wei X, et al. Initial Evaluation of Treatment-Related Pneumonitis in Advanced-Stage Non-Small-Cell Lung Cancer Patients Treated With Concurrent Chemotherapy and Intensity-Modulated Radiotherapy. *International Journal of Radiation Oncology* Biology* Physics*. 2007;68:94-102.

[35] HU Y, LI J, SU X. Fatal pneumonitis associated with postoperative intensity-modulated radiotherapy in lung cancer: Case report and review. *Oncol Lett*. 2012;5:714-716.

[36] Tsujino K, Hashimoto T, Shimada T, Yoden E, Fujii O, Ota Y, et al. Combined Analysis of V20, VS5, Pulmonary Fibrosis Score on Baseline Computed Tomography, and Patient Age Improves Prediction of Severe Radiation Pneumonitis After Concurrent Chemoradiotherapy for Locally Advanced Non-Small-Cell Lung

Cancer. *Journal of Thoracic Oncology*. 2014;9:983-990.

[37] Chun SG, Hu C, Choy H, Komaki RU, Timmerman RD, Schild SE, et al. Impact of Intensity-Modulated Radiation Therapy Technique for Locally Advanced Non-Small-Cell Lung Cancer: A Secondary Analysis of the NRG Oncology RTOG 0617 Randomized Clinical Trial. *J Clin Oncol*. 2017;35:56-62.

[38] Palma DA, Senan S, Tsujino K, Barriger RB, Rengan R, Moreno M, et al. Predicting Radiation Pneumonitis After Chemoradiation Therapy for Lung Cancer: An International Individual Patient Data Meta-analysis. *International Journal of Radiation Oncology*Biophysics*. 2013;85:444-450.

[39] Speirs CK, DeWees TA, Rehman S, Molotievschi A, Velez MA, Mullen D, et al. Heart Dose Is an Independent Dosimetric Predictor of Overall Survival in Locally Advanced Non-Small Cell Lung Cancer. *J Thorac Oncol*. 2017;12:293-301.

[40] Movsas B, Hu C, Sloan J, Bradley J, Komaki R, Masters G, et al. Quality of Life Analysis of a Radiation Dose-Escalation Study of Patients With Non-Small-Cell Lung Cancer: A Secondary Analysis of the Radiation Therapy Oncology Group 0617 Randomized Clinical Trial. *JAMA Oncol*. 2016;2:359-367.

[41] Eaton BR, Pugh SL, Bradley JD, Masters G, Kavadi VS, Narayan S, et al. Institutional Enrollment and Survival Among NSCLC Patients Receiving Chemoradiation: NRG Oncology Radiation Therapy Oncology Group (RTOG) 0617. *J Natl Cancer Inst*. 2016;108: djw034.

[42] Tan MY, Fisher R, Ball D. Does institutional patient accrual volume impact overall survival in patients with

inoperable non-small-cell lung cancer receiving radical (chemo)radiation? A secondary analysis of TROG 99.05. *Journal of Medical Imaging and Radiation Oncology*. 2020;64:556-562.

[43] Wuthrick EJ, Zhang Q, MacHtay M, Rosenthal DI, Nguyen-Tan PF, Fortin A, et al. Institutional clinical trial accrual volume and survival of patients with head and neck cancer. *J Clin Oncol*. 2015;33:156-164.

[44] Harada H, Murayama S. Proton beam therapy in non-small cell lung cancer: state of the art. *Lung Cancer (Auckl)*. 2017;8:141-145.

[45] Liao Z, Lee JJ, Komaki R, Gomez DR, O'Reilly MS, Fossella FV, et al. Bayesian Adaptive Randomization Trial of Passive Scattering Proton Therapy and Intensity-Modulated Photon Radiotherapy for Locally Advanced Non-Small-Cell Lung Cancer. *J Clin Oncol*. 2018;36:1813-1822.

[46] Nestle U, De Ruyscher D, Ricardi U, Geets X, Belderbos J, Pöttgen C, et al. ESTRO ACROP guidelines for target volume definition in the treatment of locally advanced non-small cell lung cancer. *Radiotherapy and Oncology*. 2018;127:1-5.

[47] Grills IS, Yan D, Martinez AA, Vicini FA, Wong JW, Kestin LL. Potential for reduced toxicity and dose escalation in the treatment of inoperable non-small-cell lung cancer: A comparison of intensity-modulated radiation therapy (IMRT), 3D conformal radiation, and elective nodal irradiation. *International Journal of Radiation Oncology*Biophysics*. 2003;57:875-890.

[48] Schild SE, McGinnis WL, Graham D, Hillman S, Fitch TR, Northfelt D, et al. Results of a Phase I trial of concurrent chemotherapy and escalating doses of radiation for unresectable non-small-cell lung

cancer. *International Journal of Radiation Oncology*Biophysics*. 2006;65:1106-1111.

[49] Bradley JD, Bae K, Graham MV, Byhardt R, Govindan R, Fowler J, et al. Primary analysis of the phase II component of a phase I/II dose intensification study using three-dimensional conformal radiation therapy and concurrent chemotherapy for patients with inoperable non-small-cell lung cancer: RTOG 0117. *J Clin Oncol*. 2010;28:2475-2480.

[50] Rosenzweig KE, Sim SE, Mychalczak B, Braban LE, Schindelheim R, Leibel SA. Elective nodal irradiation in the treatment of non-small-cell lung cancer with three-dimensional conformal radiation therapy. *Int J Radiation Oncology Biol Phys*. 2001;50:681-685.

[51] Rosenzweig KE, Sura S, Jackson A, Yorke E. Involved-field radiation therapy for inoperable non-small-cell lung cancer. *J Clin Oncol*. 2007;25:5557-5561.

[52] Sulman EP, Komaki R, Klopp AH, Cox JD, Chang JY. Exclusion of elective nodal irradiation is associated with minimal elective nodal failure in non-small cell lung cancer. *Radiat Oncol*. 2009;4:5.

[53] De Ruysscher D, Wanders S, van Haren E, Hochstenbag M, Geeraedts W, Utama I, et al. Selective mediastinal node irradiation based on FDG-PET scan data in patients with non-small-cell lung cancer: a prospective clinical study. *Int J Radiation Oncology Biol Phys*. 2005;62:988-994.

[54] Yuan S, Sun X, Li M, Yu J, Ren R, Yu Y, et al. A Randomized Study of Involved-Field Irradiation Versus Elective Nodal Irradiation in Combination With Concurrent Chemotherapy for Inoperable Stage III Nonsmall Cell Lung Cancer.

American Journal of Clinical Oncology. 2007;30:239-244.

[55] Chen M, Bao Y, Ma H-L, Hu X, Wang J, Wang Y, et al. Involved-Field Radiotherapy versus Elective Nodal Irradiation in Combination with Concurrent Chemotherapy for Locally Advanced Non-Small Cell Lung Cancer: A Prospective Randomized Study. *BioMed Research International*. 2013;2013:1-7.

[56] Fernandes AT, Shen J, Finlay J, Mitra N, Evans T, Stevenson J, et al. Elective nodal irradiation (ENI) vs. involved field radiotherapy (IFRT) for locally advanced non-small cell lung cancer (NSCLC): A comparative analysis of toxicities and clinical outcomes. *Radiotherapy and Oncology*. 2010;95:178-184.

[57] Nestle U, Schimek-Jasch T, Kremp S, Schaefer-Schuler A, Mix M, Küsters A, et al. Imaging-based target volume reduction in chemoradiotherapy for locally advanced non-small-cell lung cancer (PET-Plan): a multicentre, open-label, randomised, controlled trial. *Lancet Oncol*. 2020;21:581-592.

[58] Giraud P, Antoine M, Larrouy A, Milleron B, Callard P, De Rycke Y, et al. Evaluation of microscopic tumor extension in non-small-cell lung cancer for three-dimensional conformal radiotherapy planning. *Int J Radiation Oncology Biol Phys*. 2000;48:1015-1024.

[59] Yuan S, Meng X, Yu J, Mu D, Chao KSC, Zhang J, et al. Determining optimal clinical target volume margins on the basis of microscopic extracapsular extension of metastatic nodes in patients with non-small-cell lung cancer. *International Journal of Radiation Oncology, Biology, Physics*. 2007;67:727-734.

[60] Seppenwoolde Y, Shirato H, Kitamura K, Shimizu S, van Herk M, Lebesque JV, et al. Precise and real-time

measurement of 3D tumor motion in lung due to breathing and heartbeat, measured during radiotherapy. *Int J Radiation Oncology Biol Phys.* 2002;53:822-834.

[61] Giraud P, Morvan E, Claude L, Mornex F, Le Pechoux C, Bachaud J-M, et al. Respiratory gating techniques for optimization of lung cancer radiotherapy. *J Thorac Oncol.* 2011;6:2058-2068.

[62] Boda-Heggemann J, Knopf A-C, Simeonova-Chergou A, Wertz H, Stieler F, Jahnke A, et al. Deep Inspiration Breath Hold-Based Radiation Therapy: A Clinical Review. *Int J Radiat Oncol Biol Phys.* 2016;94:478-492.

[63] Mirjana Josipovic, et al. Deep inspiration breath hold in locally advanced lung cancer radiotherapy: validation of intrafractional geometric uncertainties in the INHALE trial. *Br J Radiol.* 2019;92:20190569.

[64] Kilburn JM, Soike MH, Lucas JT, Ayala-Peacock D, Blackstock W, Isom S, et al. Image guided radiation therapy may result in improved local control in locally advanced lung cancer patients. *Practical Radiation Oncology.* 2016;6:e73–e80.

[65] Giacometti V, King RB, Agnew CE, Irvine DM, Jain S, Hounsell AR, et al. An evaluation of techniques for dose calculation on cone beam computed tomography. *Br J Radiol.* 2019;92:20180383.

[66] Tvilum M, Khalil AA, Møller DS, Hoffmann L, Knap MM. Clinical outcome of image-guided adaptive radiotherapy in the treatment of lung cancer patients. *Acta Oncol.* 2015;54:1430-1437.

[67] Lozano Ruiz FJ, Ileana Pérez Álvarez S, Poitevin Chacón MA, Maldonado Magos F, Prudencio RR, Cabrera Miranda L, et al.

The importance of image guided radiotherapy in small cell lung cancer: Case report and review of literature. *Reports of Practical Oncology and Radiotherapy.* 2020;25:146-149.

[68] Raben D, Rimner A, Senan S, et al. Patterns of disease progression with durvalumab in stage III non-small cell lung cancer (PACIFIC). *Int J Radiation Oncology Biol Phys.* 105:683.

[69] Taugner J, Eze C, KÄSMANN L, Roengvoraphoj O, Gennen K, Karin M, et al. Pattern-of-failure and salvage treatment analysis after chemoradiotherapy for inoperable stage III non-small cell lung cancer. *Radiation Oncology;* 2020;15:148.

[70] Schreiner W, Dudek W, Lettmaier S, Fietkau R, Sirbu H. Long-Term Survival after Salvage Surgery for Local Failure after Definitive Chemoradiation Therapy for Locally Advanced Non-small Cell Lung Cancer. *Thorac cardiovasc Surg.* 2018;66:135-141.

[71] Palma DA, Olson R, Harrow S, Gaede S, Louie AV, Haasbeek C, et al. Stereotactic ablative radiotherapy versus standard of care palliative treatment in patients with oligometastatic cancers (SABR-COMET): a randomised, phase 2, open-label trial. *Lancet.* 2019;393:2051-2058.

[72] Socinski MA, Obasaju C, Gandara D, Hirsch FR, Bonomi P, Bunn P, et al. Clinicopathologic Features of Advanced Squamous NSCLC. *J Thorac Oncol.* 2016;11:1411-1422.

[73] Ito H, Matsuo Y, Ohtsu S, Nishimura T, Terada Y, Sakamoto T, et al. Impact of histology on patterns of failure and clinical outcomes in patients treated with definitive chemoradiotherapy for locally advanced non-small cell lung cancer. *Int J Clin Oncol.* 2019;25:274-281.

- [74] Sanmamed MF, Chen L. A Paradigm Shift in Cancer Immunotherapy: From Enhancement to Normalization. *Cell*. 2018;175:313-326.
- [75] Grassberger C, Ellsworth SG, Wilks MQ, Keane FK, Loeffler JS. Assessing the interactions between radiotherapy and antitumour immunity. *Nat Rev Clin Oncol*. 2019;16:729-745.
- [76] Le Q-T, Shirato H, Giaccia AJ, Koong AC. Emerging Treatment Paradigms in Radiation Oncology. *Clin Cancer Res*. 2015;21:3393-3401.
- [77] Deng L, Liang H, Burnette B, Beckett M, Darga T, Weichselbaum RR, et al. Irradiation and anti-PD-L1 treatment synergistically promote antitumor immunity in mice. *J Clin Invest*. 2014;124:687-695.
- [78] Yoneda K, Kuwata T, Kanayama M, Mori M, Kawanami T, Yatera K, et al. Alteration in tumoural PD-L1 expression and stromal CD8-positive tumour-infiltrating lymphocytes after concurrent chemo-radiotherapy for non-small cell lung cancer. *Br J Cancer*. 2019;121:490-496.
- [79] Tokito T, Azuma K, Kawahara A, Ishii H, Yamada K, Matsuo N, et al. Predictive relevance of PD-L1 expression combined with CD8+ TIL density in stage III non-small cell lung cancer patients receiving concurrent chemoradiotherapy. *Eur J Cancer*. 2016;55:7-14.
- [80] Tang C, Liao Z, Gomez D, Levy L, Zhuang Y, Gebremichael RA, et al. Lymphopenia association with gross tumor volume and lung V5 and its effects on non-small cell lung cancer patient outcomes. *Int J Radiat Oncol Biol Phys*. 2014;89:1084-1091.
- [81] Wang W, Huang L, Jin J-Y, Jolly S, Zang Y, Wu H, et al. IDO Immune Status after Chemoradiation May Predict Survival in Lung Cancer Patients. *Cancer Research*. 2018;78:809-816.
- [82] Wang W, Huang L, Jin J-Y, Pi W, Ellsworth SG, Jolly S, et al. A Validation Study on IDO Immune Biomarkers for Survival Prediction in Non-Small Cell Lung Cancer: Radiation Dose Fractionation Effect in Early-Stage Disease. *Clin Cancer Res*. 2020;26:282-289.
- [83] Crocenzi T, Cottam B, Newell P, Wolf RF, Hansen PD, Hammill C, et al. A hypofractionated radiation regimen avoids the lymphopenia associated with neoadjuvant chemoradiation therapy of borderline resectable and locally advanced pancreatic adenocarcinoma. *Journal for ImmunoTherapy of Cancer*. 2016;4:45.
- [84] Yovino S, Kleinberg L, Grossman SA, Narayanan M, Ford E. The etiology of treatment-related lymphopenia in patients with malignant gliomas: modeling radiation dose to circulating lymphocytes explains clinical observations and suggests methods of modifying the impact of radiation on immune cells. *Cancer Invest*. 2013;31:140-144.
- [85] Ladbury CJ, Rusthoven CG, Camidge DR, Kavanagh BD, Nath SK. Impact of Radiation Dose to the Host Immune System on Tumor Control and Survival for Stage III Non-Small Cell Lung Cancer Treated with Definitive Radiation Therapy. *International Journal of Radiation Oncology*Biophysics*. 2019;105:346-355.