

# We are IntechOpen, the world's leading publisher of Open Access books Built by scientists, for scientists

6,900

Open access books available

186,000

International authors and editors

200M

Downloads

Our authors are among the

154

Countries delivered to

TOP 1%

most cited scientists

12.2%

Contributors from top 500 universities



WEB OF SCIENCE™

Selection of our books indexed in the Book Citation Index  
in Web of Science™ Core Collection (BKCI)

Interested in publishing with us?  
Contact [book.department@intechopen.com](mailto:book.department@intechopen.com)

Numbers displayed above are based on latest data collected.  
For more information visit [www.intechopen.com](http://www.intechopen.com)



# Coronary Artery Intervention Techniques

*Imran Khalil*

## Abstract

The topic of coronary artery intervention techniques is very complex. This chapter's goal is to discuss basic to complex techniques summarized to help coronary operators at all levels to understand the practical aspects of daily coronary interventions using a noncomplex approach. With the revolution of percutaneous cardiovascular and valvular interventions, more patients with complex coronary lesions are treated with percutaneous coronary intervention (PCI) over coronary artery bypass graft (CABG) surgery. Thus, mastering all approaches, techniques of PCI, being comfortable with performing high risk PCIs, and using hemodynamic support devices have become very important. While the basics of coronary interventions have not changed, equipment innovation has a very rapid pace with almost daily additions to the arsenal of coronary interventions, in particular, stent development. Stent therapy for coronary interventions especially in acute coronary syndrome is a proven concept. This created a race to develop a perfect stent that allows for physiological healing of the coronaries and avoid their use in long-term issues. With each addition to the equipment collection comes a learning curve on both technical and clinical evidence aspects, all which make coronary intervention a more specialized and rapidly progressive field.

**Keywords:** percutaneous coronary interventions, techniques, complex, high risk, equipment, radial approach, bifurcations stenting, coronary guidewires, coronary guide catheters, left main, venous graft interventions, instent restenosis

## 1. Introduction

For daily planned procedures, there are several approaches for coronary interventions. In reality and especially an emergency situation, any kind of arterial approach that can reach the coronary tree can be used as long as emergency percutaneous coronary interventions could be successfully and safely performed.

These common approaches include radial right and left, ulnar right and left, distal radial right and left, femoral, and brachial. Carotid, axillary approaches might be necessary in the right clinical presentation. For each approach, operators need to be familiar with the limitations, advantages, disadvantages, access and closure techniques, potential complications, and their management. Knowledge of arterial and venous anatomy and its possible anomalies are basic requirements of any vascular operator.

This chapter is focusing on PCI technical aspects and high-risk interventions. Reader is redirected to other resources that focus on performing diagnostic left

heart catheterization (LHC) as it is crucial to understand everything about diagnostic catheters, procedure, and equipment before proceeding with PCI.

**Table 1** includes a required checklist of equipment needed in any catheterization lab performing PCI, especially high-risk PCI.

## **2. Percutaneous coronary interventions**

Performing successful PCI requires good planning. Access site, anticoagulation, antiplatelet therapy, good assessment of target lesions, intravascular imaging, adjunct therapies (i.e. atherectomy or other plaque modification procedures), and instruments necessary to perform the procedure and handle complications should be available.

The main simple steps for any PCI are engaging the target system with the guide catheter, wiring the lesion, preparing the lesion for stenting and finally deploying the stent. Every step can be a challenge by itself.

### **2.1 Radial approach**

Over the last two decades, radial approach for coronary interventions has developed significantly. It has become the standard of care in any catheterization lab.

In addition to growing evidence that supports this approach of safety and better outcome in coronary interventions [1–4], it is also significantly evolving as a great approach for peripheral arterial interventions, including abdominal vessel interventions and even lower extremity interventions.

With obesity pandemic, operators need to perform LHC/PCI using a radial approach and avoid femoral at all prices, and we will discuss the femoral approach in obese patients. Obese patients can be very challenging patients for radial approach, but it is definitely worth it to avoid using femoral approach and dealing with access and potential complications that rise especially in obese diabetic patients [5].

For our topic of coronary interventions, radial approach especially right radial approach is the main approach for any patient; first time coronary angiogram and PCI patients or returning patients, chronic total obstruction interventions and even patients with prior CABG [6].

In case of suspected acute stent thrombosis after completing PCI, radial access at the same site can be safely performed. While in femoral approach, it depends on the closure device that has been used.

It has proven that it is safer than any other approach with less bleeding, access complications, and outcome at least in STEMI patients [3].

Even in post-CABG patients, right radial approach can be used effectively. All aortic grafts can be imaged easily. Even the left internal mammary artery LIMA can be reached but requires manipulating across the aortic arch to reach left subclavian and wiring it. Meaning crossing all the head vessel which in diseased aortic arch might not be a smart idea as it could increase risk of emboli ischemic stroke significantly. That is where left radial approach comes handy.

In elderly small size females, radial approach for LHC/PCI is a priority as this category of patients carries the highest risk of vascular complications and bleeding using femoral approach. 5Fr radial sheath is considered in general safer to perform LHC and even simple PCI that does not require 6F guide catheters.

Sheaths	6–8 French standard (short and supportive long 23, 45, 65 cm for support of a tortuous, iliac and aorta for femoral approach). Multiple sheaths available: pinnacle, bright tip, braided and destinations Radial sheaths 6–7 French; several available sheaths: slender sheath most commonly used Sheathless 7Fr system like RailWay system
Injection system	Manifold 4 valve system or Acist device. At least Manifold should be available
Y-connector with hemostatic valve	Regular Tuohy, Co-pilot, or Guardian
Guide catheters	Multiple available guide catheters available from different companies and for right and left system; differences are minimal. Starting from less support to maximum support. More support is provided with contralateral support guide catheters against the contralateral aortic wall or aortic valve For the right: Judkins right 4, IMA, Amplatz right, Multipurpose, KR4, IKARI left, Voda right, Amplatz left For the left system: Judkins left, IKAR left, Kimny, Voda left, EBU, XB, CLS, SAL, Amplatz left etc.
Guide catheter extensions	Guideliner, Guidezilla, Guidion, Trapliner
Guide wires	Vascular wires and catheters: 0.035 or 0.038 J tip wire, whole wire, glide wire, glide wire advantage wire, super stiff or extra stiff wire (help advance sheath through scar tissue and straighten tortuous large vessels), glide straight and angled tip catheters For coronary wires: see <b>Table 2</b> for list of available wires
Intravascular diagnostic imaging	IVUS, OCT
Micro-catheters/support catheters	See <b>Table 3</b> for list of available micro catheters
Lesion crossing/ preparation for stenting	Small balloons, over the wire or rapid exchange Tornus or Turnpike Gold Threader LASER Atherectomy systems (rotational, orbital)
Dissection/reentry equipment	CrossBoss Catheter/Stingray LP balloon and wire
Balloons and stents	Compliant and noncompliant balloons of all different sizes and lengths, cutting balloons, Ostial Flash Bare metal stents, drug eluting stents and Covered stents
Complications management	Covered stents (Graftmaster or PK Papyrus) Vascular coils: better if detachable and 0.014 compatible such as Axium coils. Other 0.018 pushable coils could be used if there are the only available ones but they require higher profile micro catheters like Progreat or Renegade Pericardiocentesis tray, echo contrast Echocardiogram probe and vascular probe Thrombin Snares: Esnare or Atrieve 18–30 mm or 27–45 mm Vascular balloons and stents for vascular access complications
Hemodynamics support	Impella 2,5, CP, Impella RP, IABP and VA ECMO
Radiation protection	

**Table 1.**  
*Necessary equipment for successful PCI program.*

In chronic total occlusion (CTO) interventions, radial approach can be used as a single access in antegrade approach or in retrograde approach with another access that could be femoral or even left radial depending on the clinical scenario.

Radial approach is very convenient for patients, allowing them to move as soon as possible and avoid prolonged bed rest and recurrent need for applying pressure in case of recurrent bleeding.

Initially, radial approach had increased radiation exposure and time compared to femoral approach. As it has a learning curve, this is not true anymore due to increase in operators' experience. Still, left radial approach has more operator radiation compared to femoral and right radial but less complications compared to femoral approach [7–9]. Using appropriate radiation protection could decrease operator's radiation exposure [10].

As in any artery, radial artery can dilate, but the dilation ratio depends on the baseline size, presence of atherosclerosis disease, and calcifications. Complications can occur when inappropriate dilation is performed. Specific medication mix is used to avoid spasm of radial or ulnar artery after getting access and sheath inserted. Still, some patients have significant spasm which can make radial approach very hard and even impossible to complete the requiring switching to femoral approach.

When facing any resistance advancing the wire, operator should perform an angiogram especially if 7F system is planned.

Sheath-less technique is encouraged when using larger than 6 F. 7Fr and can be performed in most patients. 8F requires large radial artery. Female patients with small size and short status are more likely to not have a radial vessel that accommodates larger than 6Fr system.

Ulnar artery can be dominant or the same size and can be used for PCI easily and safely. There is no significant data to compare radial and ulnar approaches.

2.2 Understanding coronary artery lesions

Atherosclerosis is the most common etiology for coronary artery disease. However, operator should understand the difference in physiology and invasive management of other etiologies such in inflammatory post-transplant vasculopathy (Cardiac Allograft Vasculopathy CAV) (Tables 2 and 3), vasculitis, aneurysms, and spontaneous coronary artery dissections (Table 4). Although the main principles of interventions are similar, these special etiologies require special considerations.

National American College of Cardiology/American Heart Association/Society for Cardiovascular Angiography and Interventions ACC/AHA/SCAI and international societies of cardiovascular diseases European Society of Cardiology ESC have their classifications of lesions risk of interventions for each coronary lesion based on





Type A	Discrete, tubular, or multiple stenosis	
Type B1	Abrupt onset with distal diffuse concentric narrowing and obliterated vessels	
Type B2	Gradual, concentric tapering with distal portion having some residual lumen	
Type C	Narrowed irregular distal branches with terminations that are often none-tapered and squared off, ending abruptly	

Table 2.  
Types of cardiac allograft vasculopathy lesions.



	Class I	Class II	Class III	Class IV
Severity	Minimal	Mild	Moderate	Severe
Intimal thickness	<0.3 mm	<0.3 mm	0.3–0.5 mm	>1 mm
Or			Or	Or
Extent of plaque	<180	>180	>0.5 mm, <180	>0.5 mm, >180

**Table 3.**  
*Duke classification of cardiac allograft vasculopathy on IVUS.*

<b>Type 1</b>	Multiple radiolucent lumen
<b>Type 2</b>	Long diffuse and smooth narrowing of the body or distal end of the vessel
<b>Type 3</b>	Focal or tubular stenosis

**Table 4.**  
*Classification of spontaneous coronary artery dissection.*

specific characteristics and success rate of intervention (**Tables 5 and 6**), Systemic evaluation of coronary lesion and understanding of the anatomical and physiological characteristics for each lesion are essential for successful intervention.

Syntax score is an additional tool that was developed to stratify patients based on the complexity of their coronary artery disease (CAD) and identify patients who benefit from different revascularizations options (CABG and PCI) based on their score. Similar to ACC/AHA classification of lesions, Syntax score is calculated based on each lesion characteristics with more details (**Figure 1** and **Table 7**). It is another available tool to evaluate the risk of lesions and subsequently the outcome of procedure.

<b>Type A lesions: high success rate &gt; 85%; low risk</b>	
Discrete <10 mm length	Little or no calcification
Concentric	Less than total occlusion
Readily accessible	Not ostial location
None-angulated segment <45°	No major branch involvement
Smooth contour	Absence of thrombus
<b>Type B lesions: moderate success 60–85%; moderate risk</b>	
Tubular 10–20 mm length	Ostial in location
Eccentric	Bifurcation lesions requiring double guidewires
Moderate tortuosity of proximal segment	Some thrombus
Moderately angulated 45–90°	Total occlusion <3 months old
Irregular contour	Moderate to heavy calcifications
<b>Type C lesions: low success &lt;60%; high risk</b>	
Diffuse lesion >20 mm length	Degenerated venous graft with friable lesions
Excessive tortuosity of proximal segment	Total occlusion >3 months old
Extremely angulated segment >90°	Inability to protect side branch

**Table 5.**  
*ACC/AHA classification of coronary lesions and outcome predictors.*

<b>SCAI Type I: highest success rate and lowest risk</b>
Does not meet the criteria for ACC/AHA type C lesion
Patent
<b>SCAI Type II lesion</b>
Diffuse lesion >20 mm length
Excessive tortuosity of proximal segment
Extremely angulated segment >90°
Inability to protect major side branch
Degenerated venous graft with friable lesions
Patent
<b>SCAI Type III lesion</b>
Does not meet the criteria for ACC/AHA type C lesion
Occluded
<b>SCAI Type IV lesion</b>
Diffuse lesion >20 mm length
Excessive tortuosity of proximal segment
Extremely angulated segment >90°
Inability to protect major side branch
Degenerated venous graft with friable lesions
And occluded OR occluded more than 3 months alone

**Table 6.**  
*SCAI classification of coronary lesions.*

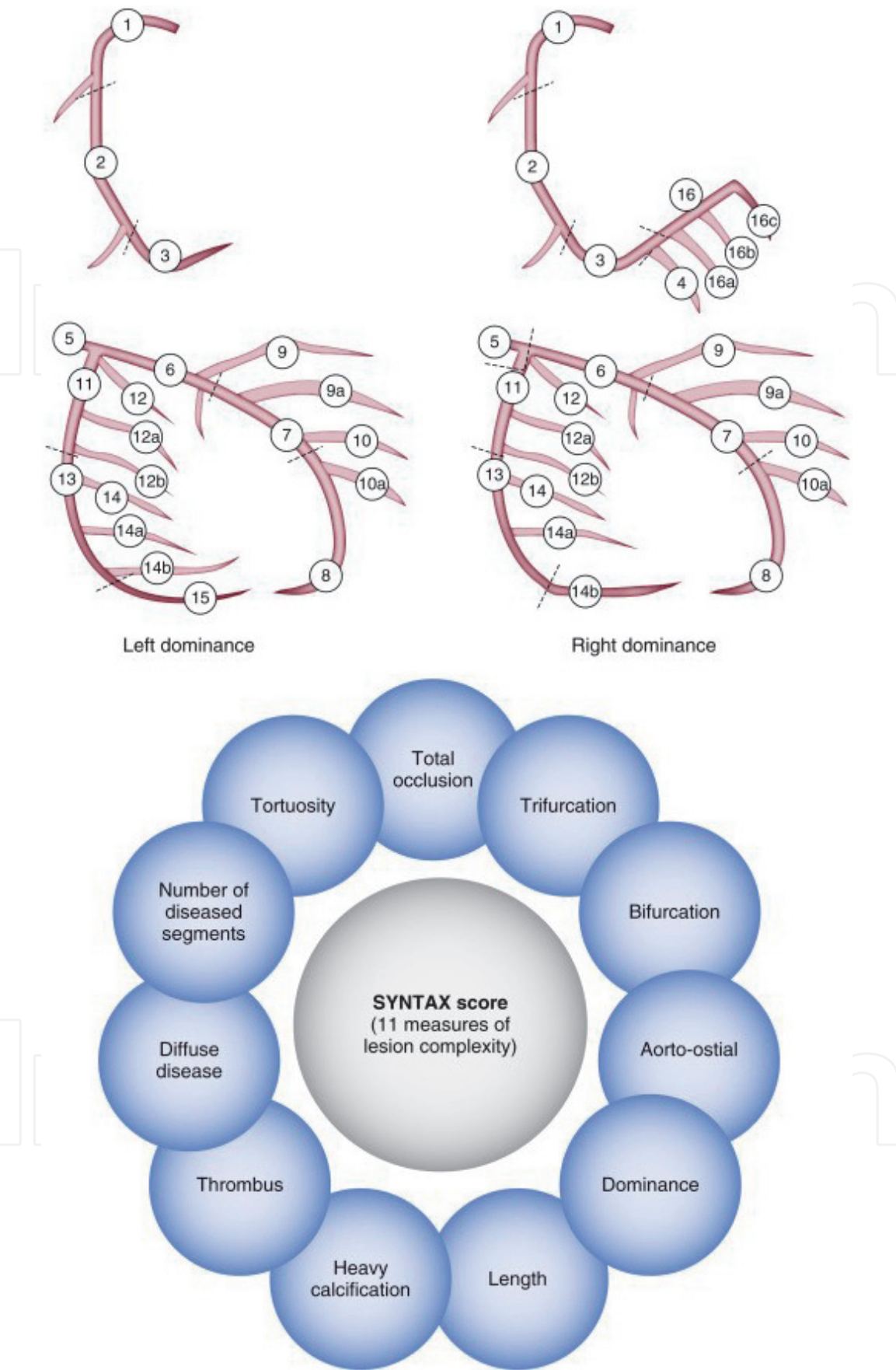
Bifurcation lesions are one of the most challenging lesions for intervention. Multiple classifications have been developed with Medina being the most used one (**Figure 2**).

All classifications are meant to help operator to address the risk of intervention, success rate, potential complications and outcome. Operator should always keep in mind that coronary angiograms are only two dimensional images of three dimensional lesions. Baseline orthogonal and multiple projections angiogram should be used as possible to help achieve best angiographic results.

Deciding the need for hemodynamic support is not only related to the lesion characteristics. It is also based on the whole picture of the patient presentation, coronary and peripheral anatomy, comorbidities and evidence-based outcome. In some cases, the decision is clear whether to use hemodynamic mechanical support or not but in most of the cases, the answer is not clear.

Available mechanical hemodynamic support devices (left ventricular assist device LVAD) are intra-aortic balloon pump IABP, Impella (which comes in different sizes depending on the cardiac output they provide Impella 2.5, Impella CP, Impella 5), RP Impella (right ventricular Impella), venous arterial Extracorporeal membrane oxygenation (ECMO) (which also can provide different cardiac output depending on cannula size but also provide oxygenation which Impella does not) and Tandem heart. The discussion of each device indications, advantage and disadvantages is beyond this chapter.

The timing of hemodynamic support in acute setting (not planned PCI) before or after restoration of coronary flow is controversial and depends on several



**Figure 1.**  
*Syntax score: top shows the dominance and numbering of coronaries segments, bottom: characteristics of each segment.*

cofounders such as the presence of cardiogenic shock and the expected time to restore coronary flow in challenging lesions. Ongoing clinical trial are trying to address these questions. So far, there is no strong data to support placement



Lesion characteristics	Impact on syntax score
Diameter reduction	
Total occlusion	X5
Significant lesion (50–99%)	X2
Total occlusion	
Age > 3 months	+1
Blunt stump	+1
Bridging	+1
First segment visible beyond total occlusion	+1 per nonvisible segment
Side branch present	+1
Trifurcations	
1 diseased segment	+3
2 diseased segments	+4
3 diseased segments	+5
4 diseased segments	+6
Bifurcations	
Type A, B, C	+1
Type D, E, F, G	+2
Angulated <70°	+1
Aorto-ostial lesions	+1
Severe tortuosity	+2
Length > 2 cm	+1
Heavy calcifications	+2
Thrombus	+1
Diffuse disease/small vessels	+1 per segment number

**Table 7.**  
*Factors affecting lesion scoring in the syntax score.*

of any hemodynamic support device in cardiogenic shock in the setting of acute coronary syndrome.

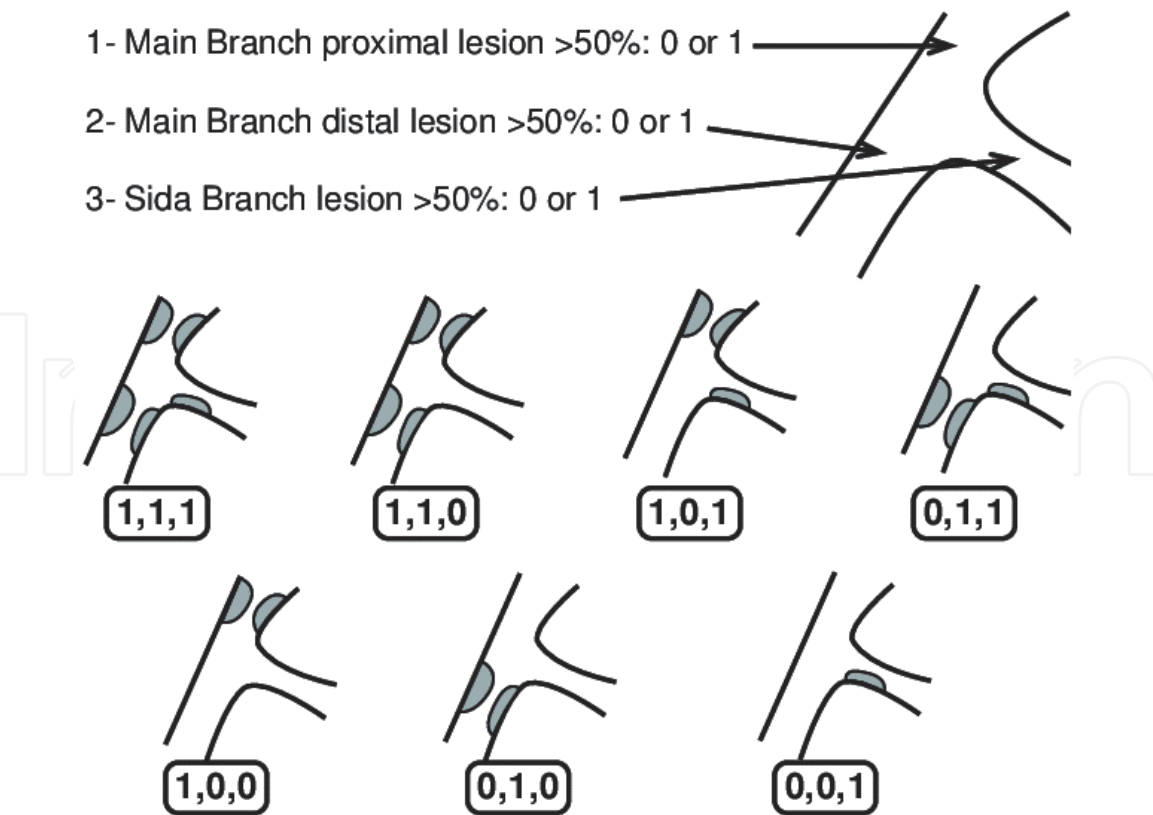
2.3 Choosing the appropriate guide catheter

Several medical companies provide wide range of options for guide catheters designs. Each has their own catheters designs for radial or femoral approach. They share the general principle and look similar. Operator should be knowledgeable of advantages and disadvantages of each and be comfortable to deal with challenges and complications as they appear.

Choosing the appropriate guide catheter is a very important step. It can make the intervention significantly easier and smother than using inappropriate guide catheter.

Goals of guide catheter:

Engage target coronary coaxially to avoid damage of the engagement and deep intubation.



**Figure 2.**  
*Medina classification.*

Provide support for intervention and stability with multiple exchanges of balloons, stent, guide extensions, and adjunct therapies.  
Allow coronary flow during intervention.

*2.3.1 Basic information to help operator handling guide catheters*

Guide catheters although have three layers (diagnostic have two layers); they have thinner walls than diagnostic catheters to allow larger lumen. This makes them prone to kinking and weakening, and the middle layer is usually braided wire to minimize this risk. The tip of guide catheter is not tapered (diagnostic catheters have tapered tip).

Moving/rotating the guide catheter similar to diagnostic catheters with slower speed and patience to transmit torque (1 to 1 torque transmission) when withdrawing or advancing.

Advancing guide catheter slowly to avoid deep coronary intubation and damage.

Live monitoring of pressure wave to notice any change (ventricularization, damping or disappearance).

Guide catheters are used with hemostasis valve to allow instrumentation and imaging at the same time.

A lot of operators and some companies recommend keeping the 0.035" guide wire inside while trying to engage the target coronary and adjust the location of the wire based on the operator assessment of the guide segment that need more support to stay straight. This only possible with a hemostasis valve (Tuohy) in place. Operator should make sure to de-air the system well while using this technique and assure good seal that prevents air from entering the system. Most operators keep the main 0.035" guide wire in till they wire the

coronary with 0.014 guide wire and secure guide engagement. This technique is mostly used for radial approach especially in patients with extensive tortuous vessels.

Consider longer sheath to provide good support through tortuous vessels. This is mainly a femoral approach option.

Bleed back from the hemostasis valve after performing exchanges to avoid introducing air or building clots in the system. This is very important while performing complex interventions with multiple wires and balloons and after aspiration thrombectomy.

If more support is needed and guide catheter needed to be advanced inside the coronary, operator should perform that over a wire or a balloon.

Advancing any instrument can push the guide out (especially if not a good support guide) causing disengagement and vice versa; pulling instruments can create a suction mechanism and advance the guide catheter deep inside the coronary and cause complications (dissection, perforation, and ischemia). Operators can use this mechanism to their benefit to provide more support or disengage the guide when needed (i.e. stenting ostial left main).

Guide catheters are available with or without side holes. Side holes purpose to prevent coronary obstruction by allowing some blood flow especially when using severe ostial lesions. Some operators argue that although using side holes can help avoid dampening of pressure, it does not support much coronary support and only give operators a false sense of comfort. Interventional guide wires can come out of these side holes and make it to coronary and unless operators are aware of that potential issue, complications can occur. Lastly, side holes can increase contrast volume used and weaken the tip of the guide catheter and make it prone to kink.

In addition to tip shape and length, shaft length is another important characteristic. Shorter guide catheters are used in CTO, bypass grafts and internal mammillary artery IMA interventions to allow for more wire to reach lesions in retrograde CTO approach and distal lesion in the grafts, anastomosis or target bypassed vessel. Longer shafts are used in tall patients or patients with significant tortuous aorto-femoral vessels. Standard shaft length is 100 cm, short is 80 or 90 cm, and long is 110–115 cm. Operators can shorten the guide by cutting a segment of the guide and connect them using sheath segment.

2.3.2 Sizing of guide catheter

There are four available sizes for coronary interventions (**Table 8**). Amount of contrast used in PCI increases with increasing guide catheter size. 5Fr guide catheters: rarely used. Allows for simple single vessel PCI.

Outer lumen size (French)	5	6	7	8
Manufacturer/guide design	Inner lumen size (inch)			
Boston Scientific/Wiseguide	NA	0.066	0.076	0.086
Abbott/Viking	NA	0.068	0.078	0.091
Boston Scientific/Mach1	NA	0.070	0.081	0.091
Cordis/Vista Brite Tip	0.056	0.070	0.078	0.088
Medtronic/Launcher	NA	0.071	0.081	0.090

**Table 8.**  
*Different guide catheter designs per company and sizes.*

#### 6Fr guide catheters:

The workhorse size for most of PCI cases.

Allow for performing kissing rapid exchange balloons of almost any coronary size.

Does not allow simultaneous double stenting techniques.

Allow for simultaneous balloon and stent deployments but with limitation of size related to stent size.

Allow for rotational atherectomy max size Rotablator 1.5.

Limited on the size of covered stent that can be used. For Graftmaster covered stent (Max size 3.5 mm stent). Newer PK papyrus covered stent can fit in 5Fr for sizes up to 4.0 mm and requires 6Fr guide for >4.0 mm stents.

#### 7Fr guide catheters:

The most commonly used size in high risk interventions for technical support or in preparation to deal with complications:

Allow for simultaneous double stenting techniques.

Allow for rotational atherectomy max size Rotablator 1.75.

Allows for two over the wire balloons.

#### 8Fr guide catheter:

Limited in availability.

Used for high risk interventions and CTO.

Allow for rotational atherectomy max size Rotablator 2.0.


Required for complex CTO intervention where intravascular ultrasound (IVUS) directed true lumen reentry and balloon are required.

#### 2.3.3 Choice for guide catheter tip curve, shape and length for PCI depends on several factors

The access approach: radial right, left or femoral. Technically, most of femoral guide catheters could be used in radial approach and vice versa. However, some guide catheters are originally designed for radial approach (i.e. XB) and would be more effective if it is used for the same purpose especially nonexperience operators and in challenging interventions. A big advantage of radial approach is the availability of multiple guide catheter that can be used as a single catheter to perform diagnostic and intervention using same catheter for left and right with very good support and without the need to exchange. Some of these guide catheters are: EBU, Kimny, Q-Curve, Multi-Aortic Curve MAC and even Amplatz left. Manipulating and adjusting the guide bend with 0.035" wire might be required to achieve that (Wire assisted guide engagement technique). Using the guide wire can make any left contralateral support catheter (EBU, XB, Kimny, Voda, Q-Curve, FCL, MAC, CLS, Kiesz left, Amplatz left) a single catheter for both left and right but this requires caution and experience to avoid advancing the 0.035" wire inside the coronary (**Figure 3**). Left radial approach is similar to femoral approach in regard to guide catheter choice.

#### Anatomical factors:

The diagnostic catheter used to perform diagnostic angiogram is one of the most important factors. The diagnostic angiogram procedure is very important in general in deciding the choice for interventional guide catheter as it provides information about the difficulty of vessel engagement, vessel take off, position of the heart in the chest, ascending aortic length, width and orientation in chest, length and degree



**Figure 3.**  
*Changing catheter tip shape with wire assist.*

of required support of the guide catheter. In femoral and radial approaches using pre-shaped diagnostic catheters, guide catheter length is usually 0.5 shorter than the diagnostic catheter used. This rule does not apply for radial approach when a single diagnostic catheter is used. In this case, operator makes the choice based on the diagnostic catheter used and the other factors.

The vessel involved; left anterior descending (LAD) or left circumflex (LCX), or right coronary artery (RCA), the location of takeoff of the vessel, presence of anomalous coronary and the shape of coronary or graft takeoff.

Lesion specific factors: the location of the lesion (ostial or not), the difficulty of the lesion and the need for support (tortuous, calcified coronary) (**Tables 9 and 10**), setting of intervention CTO vs. acute vs. elective case.






For left system: shorter guides will selectively engage LAD and longer guides will electively engage and support LCX like Voda left (VL) and Amplatz left (AL).

#### 2.3.4 Special cases for choosing appropriate guide catheters






*Left coronary system:* there are large range of guide catheters GC especially for left system catheters and all of them can be used in all different left system variable anatomies. XB, EBU, CLS, VL, SAL, MAC, Q-wave and AL catheters can provide good contralateral aortic or leaflet support especially during radial approach. JL/FL guide catheter are the old typical GC used in femoral approach. It provides minimal support from femoral approach. However, during radial approach, support of this GC can varies depending on the brachiocephalic and aortic anatomy. There are variable take offs and length of the left main. Superior take off would require longer GC to engage and at the same time achieve good support from aortic leaflet with or without contralateral aortic support. Horizontal take off could be engaged from the top by JL/FL GCs or by contralateral support GC. Short left main and separate ostia of LAD/LCX poses more challenge. Longer GC could engage either LAD or LCX selectively which could be a significant advantage when the target lesion is beyond the ostium. This provides much strong support for intervention but might occludes the other vessel and induces ischemia. This challenge is sometime unavoidable and thus could be managed by careful intermittent engagement and disengagement as needed during intervention. On the other hand, shorter GCs are needed for ostial target lesions.

For ostial left main interventions, a guide with side holes and easy way to disengage is preferred. JL/FL are good guide catheters for that. Still, contralateral



Judkins Left (least support)		Catheter with two bends the sort bend does not provide much support. Can have some advantage for ostial and proximal left main lesions where deep engagement is contraindicated
Ikari Left		Radial guide: can be used for both left and right interventions as a single catheter technique (Useful in STEMI). Better support than JL but for the same double curve reason
Kimny		Similar to Ikari but more support
Contralateral Support Catheters (EBU, XB, Voda left, CLS, Q Curve, Kiesz left)		Very good support from contralateral aortic wall or sinus of Valsalva. EBU and Q curve can be used as a single catheter for left and right (STEMI cases). A workhorse guide catheter Voda left is a good support catheter for LCX interventions
Amplatz Left, SAL (Best support)		Best support guide catheter. Deep engagement. Very useful for complex PCI and CTO interventions

**Table 9.**  
*Classification of left coronary system guide catheters by level of support.*

Judkins Right (least support)		<p>A workhorse guide catheter. Very useful for all types of take offs</p> <p>Very useful for engaging all venous grafts and head vessels</p> <p>IMA guide catheter is similar with more acute distal bend</p>
Amplatz Right, KR (Kiesz Right), Hockey stick		<p>A little better support than JR but still passive support with no contralateral support</p> <p>Also can be used for engaging venous grafts</p>
Multipurpose		<p>Requires significant manipulation and use of wire to support it. Very helpful in most downward pointing vessels like RCA and right venous grafts and anomalous LCX</p>
Ikari Left, Ikari Right		<p>Radial guide: can be used for both left and right interventions as a single catheter technique (Useful in STEMI). Provide contralateral and better support for right interventions than left</p>
Contralateral Support Catheters (EBU, XB, Voda, CLS, Q-Curve MAC)		<p>Very good support from contralateral aortic wall or sinus of Valsalva</p> <p>EBU, Q curve and MAC (Multi-Aortic Curve) guide catheter can be used as a single catheter for left and right using radial approach (STEMI cases). Another advantage of radial approach to make these guides workhorse guide catheters</p> <p>Voda right is a specific for RCA</p>

Amplatz Left, (Best support)



Best support guide catheter. Deep engagement.  
Very useful for complex PCI and CTO interventions

A very good support guide catheter for all venous graft interventions and for the same reason, it is good for abnormal take off of the RCA (anterior, superior, and posterior)

**Table 10.**  
*Classification of right coronary system guide catheters by level of support.*

aortic support GC can be used especially when additional interventions with support is required.

*RCA system:* because of the variable origin and takeoff of the RCA (posterior, anterior, superior anterior origins, inferior, horizontal, superior, Shepherd's Crook take offs), contralateral support guides for RCA interventions are less available, but some of the left guides can be used for the right interventions with aortic contralateral wall support like EBU, Voda, SAL, Q-Curve, MAC, and AL. Some companies have more specific right guide catheter with contralateral aortic wall support (Voda with right curve).

Contralateral support is very important for RCA interventions that needs significant support. However, workhorse guide catheters (JR/FR/IMA/3RDC/AR) are still mostly used due to their availability and operators' comfort level using them especially in challenging RCA take offs. Coaxial engagement and good support are two qualities for good interventions that are difficult to obtain at the same time in abnormal RCA take off using especially using workhorse GCs. For example: inferior take off engagement with multipurpose GC would provide good engagement but minimal support. Superior and Shepherd's Crook take off are one of the most challenging cases for any operator. Special radial designed GCs (KR superior, Voda right, RCA Shepherd's Crook RC4SC, Ikari right) also can be very helpful. Posterior origin of the RCA can be reached with WRP, multipurpose AR and AL GCs. Anterior origin of the RCA would require long GC such as AL. Using RAO projections can be very helpful to engage posterior and anterior origin.

For the most common coronary anomaly (LCX origin from RCA): multipurpose GC and JR short tip are good options. However, due to poor support, aforementioned contralateral aortic GCs can provide significant support with deep engagement that can cause pressure dampening and decrease coronary flow.

*Grafts:* internal thoracic artery or internal mammary artery IMA has special diagnostic catheters with similar guide catheters like regular IMA tip and LIMA VB-1 that can be used. JR, 3RDC, Cobra and LCB guides can be used too and all depends on the LIMA take off left subclavian.

Venous grafts can be engaged and intervene on using multiple catheters depending on their take off: JR, AL, IMA, special RCB, LCB right and left coronary bypass catheters, MPA, Hockey stick or even JL. Some operators use catheters used to engage abdominal aorta branches like Cobra, Renal catheters RC, Contralateral, MIK, HK1.0 or SHK. Amplatz left is a workhorse GC that can be used in all venous grafts and almost any types of origins or take offs while providing best support.

*RIMA:* free RIMA is imaged and intervene on similar to venous grafts depending on its origin from the aorta. Pedicle RIMA can be reached by right radial approach or femoral approach. JR, Barbeau or special RIMA guide catheter can be helpful in femoral approach.

Thrombotic lesions are common findings in ACS especially STEMIs and venous grafts lesions. There are multiple available catheters approved for cardiac vessels

interventions (**Table 11**). They share the same principle of mechanical aspiration embolectomy that depends on manual or machine assisted aspiration of the clot. Multiple passes might be required for some cases. No blood return while aspirating is a sign of either poor flow triggered by clot occluding the catheter or suctioning against the vessel wall. When no blood return is seen, the catheter should be withdrawn till blood return is seen. If blood return still not seen, the catheter should be removed out of the body and examined for clot at the tip. It is very important to keep negative pressure while withdrawing the catheter out of the GC followed by bleed back of the GC to remove any potential clot left within the GC.

Aspiration thrombectomy can aspirate the clots from the coronaries and displace it to systemic circulation. The data of using aspiration embolectomy is controversial. Most recent guidelines recommend against their routine use due to increased risk of embolic strokes and no clinical outcome benefit. However, some cases with significant thrombosis cannot be resolved without their use.

Coronary micro-catheters are small catheters compatible with 0.014" coronary wires. There is a wide spectrum of micro-catheters with different designs (**Table 12**). They provide operators with significant ability to provide wire exchanges, crossing difficult lesions, assist wiring difficult angulated lesions (**Table 13**) and many other technical advantages especially in CTO interventions.

Upsizing or exchanging GC to provide more support during procedure is challenging after crossing a difficult lesion or any case where guide wire position is critical. The risk of losing guide wire position while loading the new GC is high. Long guide wire or adding extension wire is first step. More support with additional buddy wire and/or using micro catheter inside the new GC could be helpful.

Manufacturer	Catheter name	Compatibility	Length	Note
Pneumbra	Indigo CAT RX	5.3 Fr	140 cm	Aspiration catheter of CAT RX SEPC4 catheter can be used to break the clots (200 cm)
Medtronic	Export Advance	6.0 Fr	140 cm	
	Export AP	6.0 Fr	140 cm	
Vascular solutions/ Teleflex	Pronto	5.0 to 10 Fr	Pronto V4 (138 cm)	Pronto V4 and V3 are available with 5.5, 6, and 8Fr Pronto LP available with 5, 6 Fr Pronto 0.03 is peripheral catheter 10 Fr, 120° angled 4 cm tip
			Pronto V3 (140 cm) Pronto LP (138 cm)	
Terumo	Priority one	6 and 7FR	140 cm	
Spectranetics	Quick Cat	6Fr	145 cm	
Atrium	Xpress-Way	6 and 7 Fr	140 cm	
Boston Scientific	Fetch 2	6Fr	135 cm	
Stron Medical	Vmax	5, 6 and 7Fr	135–141 cm	
Tsuna Med	Emax	5, 6 and 7Fr	136.5–141 cm	

**Table 11.**  
*Coronary Embolectomy Catheters.*

Manufacturer	Catheter name	Length	Distal shaft outer diameter (French)	Notes
CSI cardiovascular systems	Teleport	135 cm,	2.0 Proximal shaft	Advanced both by clock and counterclockwise rotation
	Teleport	150 cm	2.6	
	Control		2.1 Proximal shaft 2.7	
Terumo	Progreat	110 cm, 130 cm	2.4 and 2.7	Used for coiling with large coils and 0.018 wires
	Finecross MG	130 cm, 150 cm	1.8	Very small, not much support to cross any lesion
Spectranetics	Quick Cross	135 cm, 150 cm	2.0	
Boston Scientific	Renegade 18	105 cm, 114 cm, 135 cm	2.5	Used for coiling with large coils and 0.018 wires
	Mamba	135 cm	2.3	
	Mamba Flex	135 cm, 150 cm	2.1	
Cordis	Transit	135 cm	2.5	
	Prowler	150 cm	1.9	
Raxwood	MicroCross 14 MicroCross 14 es	155 cm	1.6	
Vascular solutions	Minnie	90 cm, 135 cm, 150 cm	2.2	
	Turnpike	135 cm, 150 cm	2.6	
	Turnpike LP	135 cm, 150 cm	2.2	
	Turnpike Spiral	135 cm, 150 cm	3.1	
	Turnpike Gold	135 cm	3.2	
Asahi	Tornus	135 cm	2.1 and 2.6	To advance it, counterclockwise rotation
	Corsair Corsair Pro	135 cm, 150 cm	2.6	
	Caravel	135 cm, 150 cm	1.9	
Volcano	Valet	135 cm, 150 cm	1.8	Shapeable distal tip

**Table 12.**  
*Coronary micro catheters.*

2.4 Choosing the appropriate guide wire

There are large number of guide wires from different companies with different characteristics. Operator should be comfortable and familiar with design, characteristics, advantages, and disadvantages of at least workhorse wires and special wires especially high risk and CTO operators.



Manufacturer	Catheter name	Length	Distal shaft outer diameter (French)	Notes
Vascular solutions	SuperCross	130 cm, 150 cm	2.1	Preformed angled catheter; straight, 45, 90, 120°
	Venture	145 cm (rapid exchange) 140 cm (over the wire)	2.2	Steerable micro catheter to help change the angle
	Twin Pass Twin Pass Torque	140 cm	1.9 distal tip and 3Fr crossing profile	
	NinjaSwift			Steerable micro catheter to help change the angle

**Table 13.**  
*Steerable, angled, dual lumen micro-catheters.*

Every wire has unique characteristics: the easiest way to remember the details of each wire is dividing them into groups with shared characteristics (**Table 14**).

There are three basic components of guide wires: central core (Stainless steel or Nitinol) and form the first 145 cm (or 140 cm) of guide wires, the distal 40 cm (or 35 cm) which has thinner extension part of the central core covered by polymer sleeve or coil-spring (platinum, tungsten, and stainless steel) and finally the tip which is usually covered by lubricious coating that define the wire as hydrophobic or hydrophilic. The tip is usually radiopaque and varies in length (20 mm–25 cm).

Last few decades have introduced nitinol to wires’ design instead of stainless steel. This advancement has shown significant improvement in wires’ design. Nitinol is a unique element that allows wires’ tip to be more flexible, kink resistance, durable (retain the shape), and reshapable, all of which allow wires to be used several times to cross/wire different lesions and vessels. A very practical and time-saving tool especially in complex, bifurcation, and multivessel interventions.

Guide wire comes in two lengths. Long wires of 300 cm are used to perform exchanges, using micro-catheters, using over the wire balloons, CTO retrograde approaches (and externalization), or while using adjunct therapy like atherectomy. Regular length guide wires of 180 cm are of the workhorse wire length and used with rapid exchange balloons and stents. Few extension wires (Doc wire, Add Wire, Cynch) are available and can be attached to all guide wires when needed.

The goals of guide wires are to cross the target lesion safely without causing any damage to the vessel or alternating of the plaque in addition to providing good support to deliver other equipment (balloons and stents).

The operator’s choice of guide wire is dependent mainly on two factors: lesions/ vessel related factors and wire characteristics.

Wire characteristics: shaft characteristics are mainly related to the support and stiffness they provide. Most important characteristics are related to guide wires’ tip:

Wire tip’s strength, shape, and coating: tip can be straight or tapered, have polymer coating or not, have coil support or not, hydrophilic, or hydrophobic. Tapered, polymer coating, coiled, and hydrophilic tips can cross difficult lesion while increasing the risk of vessel injury.

Strength of the tip: it is how many grams of power is required to bend the tip when applied against the surface of the vessel wire. Multiple wires have a

Manufacturer	Tip style	Commercial name	Tip stiffness (gf)	Clinical tips
Boston Scientific	Hydrophilic polymer, straight (nontapered)	Samurai	0.5	Workhorse wire. Longer radiopaque segment 4 cm, longer coil 20 cm, which provides more support for tortuous vessels and makes it a good buddy wire
Boston Scientific		Marvel	0.9	Workhorse wire. Longer radiopaque segment (3 cm), more slippery than other work hose wires
Abbott		BALANCE MIDDLEWEIGHT UNIVERSAL II	0.7	Hi Torque workhorse wire
Asahi	Hydrophobic tip (But the coil is coated with hydrophilic coating), straight (nontapered)	ProWater	0.8	Good Workhorse wire with good torque control and support. Has transition point to the stiff part 10 cm to distal tip that operator would feel challenge advancing the wire distally and can cause Wire artifact if it was at a bend. Longer coil (20 cm)
Asahi	Hydrophilic polymer, tapered	Fielder XT Fielder XT-A Fielder XT-R	0.8 1.0 0.6 1.2	More used in CTO PCI for antegrade crossing and Knuckle technique, retrograde crossing. Fielder XT-R is used for wiring retrograde collaterals
Boston Scientific		Fighters	1.2	Same as above
Asahi	Hydrophilic coated, straight nontapered,	Fielder FC	0.8	Can be used as a workhorse wire, used more for retrograde approaches in CTO
Asahi		Sion Black	0.8	Mostly used for retrograde approaches in CTO
Abbott		Whisper LS Whisper MS Whisper ES	0.8 1.0 1.2	Slippery and can wire very small vessels and cause perforation if operator has limited experience
Abbott		Pilot 50	1.5	Stronger tip stiffness with hydrophilic coating that can be used to cross difficult branches but carries higher risk of dissection and that's why it can be used for CTO dissection and reentry techniques
Boston Scientific		Choice PT Floppy	2.1	Same as above
Abbott		Pilot 150/200	2.7/4.1	Same as above with stiffer tip
Asahi		Gladius	3	
Terumo		Crosswire NT	7.7	
Boston Scientific		PT Graphic Intermediate	1.7	
Boston Scientific		PT2 Moderate support	2.9	

Manufacturer	Tip style	Commercial name	Tip stiffness (gf)	Clinical tips
Cordis		Shinobi	7.0	
Cordis		Shinobi Plus	6.8	
Asahi	No polymer, Hydrophilic, Straight	Suoh 03	0.3	Very low profile wire so best to wire EPICARDIAL collaterals and minimize risk of perforation
Asahi		SION	0.7	Most common wire used for wiring collaterals
Asahi		SION blue (less hydrophilic)	0.5	Good Workhorse wire
Boston Scientific		Samurai RC	1.2	More support than Samurai with longer coil 24 cm and much higher tip stiffness
Terumo	Tapered, M-coating hydrophilic/hydrophobic coating	Runthrough NS Extra Floppy (Tip 0.008) RUNTHROUGH NS HYPERCOAT	1.0 0.7	“M-coat” technology hydrophilic coating over the distal 24.8 cm of the distal tip enables smooth tractability in the tortuous anatomy while the silicone tip on the distal 2 mm Recently became one of the workhorse wires given its favorable crossing profile for complex PCI and ability to use same wire for different lesions and reshaping the tip
Abbott	Tapered	Cross it 100XT (0.010")	1.7	
Asahi	Tapered, no polymer, hydrophilic	Gaia 1st (0.010") Gaia 2nd (0.011") Gaia 3rd (0.012")	1.7 3.5 4.5	High stiffness tip so used for crossing CTO in a vessel with known course or retrograde known course without significant tortuosity
Asahi		Confianza Pro 9, 12 (0.009")	9.3 12	
Asahi		Astato 20 (0.008")	20	
Abbot		Progress 140 T (0.0105") Progress 200 T (0.009")	12. 13.3	
Medtronic		Persuader 9 (0.011")	9.1	
Medtronic		ProVia 9, 12 (0.009")	11.8, 13.5	
Boston Scientific		Hornet 10, 14 (0.00")	10, 14	
Asahi	Straight tip, no polymer	MiracleBros, 3, 4.5, 6 MiracleBros 12	3.9, 4.4, 8.8 13	High tip stiffness, Antegrade crossing for CTO when vessel course is known
Abbott		Ultimate 3	3	
Abbott		Progress 40, 80, 120	5.5, 9.7, 13.9	

Manufacturer	Tip style	Commercial name	Tip stiffness (gf)	Clinical tips
Medtronic		Persuader 3, 6 (philic and phobic)	5.1, 8.0	
Medtronic		ProVia 3, 6 (philic and phobic)	8.3, 9.1	
Asahi	Tapered, no polymer, hydrophobic	Confianza Pro 9, 12 (0.009") Hydrophobic	8.6, 12	
Medtronic		Persuader 9 Hydrophobic	9.1	
Medtronic		ProVia 9, 12 Hydrophobic	11.8, 13.	
Abbott	Soft, nontapered	Iron Man	1	Extra support wire, good buddy wires
Asahi		Grand Slam	0.7	
Boston Scientific		Mailman		
Asahi	Externalization wires (most common used ones)	RG3		Only for CTO retrograde interventions
Vascular solutions		R350		

**Table 14.**  
*Coronaries guide wires 0.014.*

number that determine the strength of the tip. The highest the number the stronger the tip.

Steer-ability, tip control, tracking, support (push-ability), lubricity: optimal wire has best steer-ability, tip control, tracking and support to cross a lesion or branch vessel jailed by stent without vessel damage. Ability to provide accurate transmit of torque to the tip of the wire and direct it to where operator needed to be is one of the most important characteristics for any wire.

Tips for guide wire handling:

Always start with a workhorse wire and escalate the strength as needed (Prowater, BMW, Runthrough, etc.).

Avoid using polymer coated wire at the beginning. Polymer coated wires become stiffer in a warm environment, and pre-shaped ones have no secondary curve.

Advance wire slowly and freely. Assure tip of the wire is free by performing continuous spinning and advancing slowly.

Find the best safest lumen or micro-channel to cross the lesion using multiple orthogonal views and direct the tip to it while rotating and advancing to cross the lesion. This becomes very important while crossing an occluded vessel (STEMIs) or CTOs to avoid disturbing plaque or wiring sub-intimal space and cause thrombosis or dissection/perforation.

Never cross a lesion after the tip bends (Knuckled wire). Pull to straighten the tip and rotate to find the micro-channel. Advancing the wire after bending can cross to sub-intimal space and causes dissection (it is a technique for CTO

interventions using specific wires and the goal is to cross to sub-intimal space and re-cross to true lumen). One exception is presence of large burden of thrombus and unclear trajectory of the vessel. In such case, operator might use the knuckle technique to minimize the risk of vessel injury as knuckled workhorse wire can pass easily through thrombus and allow safely the true lumen and trajectory of the vessel. Still, this technique is better performed by experienced operator.

Pull the branch wire before performing optimization of stent apposition when a stent is jailing a branch wire.

Develop a tactile feed-back for wires to avoid wiring small branch vessel or wiring under stent (between stent and vessel's wall).

To avoid perforation: keep a wire in a main large vessel (not small branch) and be aware of the distal tip of the wire at all times especially while performing multiple over the wire exchanges where the wire can travel distally and cause perforations. These kinds of distal perforation can be missed easily unless operator pays a good attention to angiograms. Also, the distal perforation causes slow bleeding that can take hours to manifest as tamponade. Thus, early detection and prevention are very important.

Any wire can cause perforation especially distal end perforation.

Wire effect or pseudo stenosis (Accordion's effect): occurs more in tortuous vessels and wires with strong shaft that can straighten the vessel at the tortuous segments and cause pseudo-stenosis (lesions) and even dissections. Examining baseline images can help distinguish this effect in addition to repeat angiogram after pulling the stiff segment of the wire out of the tortuous segment of the vessel. This way, operator can be assured that it is a wire effect and at the same time in safe position to re-advance the wire if the repeat angiogram revealed true damage (dissection or plaque shifting) that requires further intervention.

In cases that require more guide wires support, operators can use buddy wire technique by using additional wire with good support or (if the support wire can be advanced) exchanging the workhorse wire for a strong support wire using over the wire balloon or micro-catheter.

For cases where wiring a jailed vessel through stent struts, operator would choose a wire with good tip control, tracking and lubricity to direct the wire toward the vessel lumen jailed by stent. Strength here is not necessary and wires with high strength should be avoided as it carries higher risk of perforation or crossing under stent struts and dissect the branch vessel that supposed to be wired. However, some strength might be required in case of significant lesion in the branch vessel. That is why the operator should always plan the techniques for bifurcation stenting that requires rewiring based on the easiest vessel to rewire in addition to other factors will discuss later. To avoid under stent wiring, operator can use the main vessel wire and use it to wire the branch vessel. As long as operator does not withdraw the wire beyond the stent proximal edge level, operator can be comfortable that the wire is not under stent.

Strength is important in CTO or heavy calcified/organized thrombus lesions. Wires with higher strength tip should be used when the vessel track/trajectory is easy to see. Having a balloon or micro catheter close to the tip to increase support can increase the strength of the tip by 10 times and even more depending on the wire.

Shaping the tip of the wire: also an important step to get to the lesion especially in tortuous vessels and to cross the target lesion. Operators have different ways to approach the best shape for a specific lesion. Primary curve is the bend



closer to the tip. A secondary curve is the bend distal to the tip. Basic rule for shaping is making primary curve matches most angulated vessel bend and secondary curve matches the vessel size. A simple primary curve is enough in most cases. A primary 120 angle curve is usually referred to as a CTO curve because it provides a good strength to cross the lesion and mainly used in CTO lesions. When operator is working on a distal lesion with tortuous vessel a secondary curve is required most of the time to reach the distal lesion. In left system interventions, a lot of the times the LAD and/or LCX comes out with very acute angle. Such case would require mainly a secondary curve to cross the first angle of takeoff unless further tortuosity distally is present then another curve is required. The more acute the curve and especially secondary curve, the more likely that the wire would be entering the branch vessels. That is because a secondary curve is more likely to be larger than the width of the vessel which makes the wire easier to reach branches. For the same reason, if the vessel is straight, a simple short primary curve is sufficient to reach a distal lesion without difficulty wiring all branches across the vessel.

Extension wires are very helpful when a long wire is needed in cases that require the use of over the wire balloon, micro catheter, or atherectomy. To perform catheter exchanges (micro catheter or OTW balloon) over a regular length wire while assuring minimal or no movement of the wire, there are few techniques:

To avoid withdrawing the wire and losing wire position:

A trapper catheter which is special catheter with a balloon designed to trap the wire. Sometimes this catheter can be too short to trap the wire.

Advancing an extra balloon inside the GC close to the tip without getting out of the guide catheter then inflating the balloon to trap the wire while performing the exchange then it is deflated and pulled out.

A 3 cc syringe filled of heparinized saline is attached to the catheter hub and continuous slow injection is performed after assuring no air in the system.

That generates enough energy to prevent the wire from being withdrawn while pulling the catheter are pulled out of guide. This technique is least successful and requires a lot of experience and luck. It is not a trusted technique, so it is not encouraged to be used in critical scenarios where losing wire position is critical.

To avoid wire migration distally while advancing the catheter, a 10 cc syringe is attached to the catheter hub then a slow negative pressure is applied while the it is advanced till the wire is seen coming out of the hub inside the syringe. At this point the syringe is disconnected, the wire is railed, and the catheter is advanced in a usual manner.

## 2.5 Balloons and angioplasty

Multiple balloons with different designs from multiple companies are available. Main important characteristics for balloons are: balloon diameter, length, compliance, rupture pressure, tip designs, crossing profile, shaft diameter and length. Standard diameter for coronary interventions starts from 1.2 mm and goes up. However, there are commercially available smaller balloons: nano-balloon 0.85 and 1 mm balloons (Sapphire Pro, Ikazuchi Zero, Ryurel). If necessary, even large diameter peripheral balloons can be used.

Selection of Balloons: after wiring the target vessel and lesion, balloon can be advanced and inflated to perform angioplasty. The goal of pre-dilatation of lesion is to prepare lesion for stenting and assess whether the lesion/plaque would response to balloon and stenting afterwards would have a good results or further plaque

modification is needed. Balloons are also used for post stenting optimization of stents size and assuring stent well apposition. Inflation should always be started at the target lesion and monitored under fluoroscopy.

There are two general balloons designs: one over the wire and would require long wire and one referred to as rapid exchange which allows loading over the wire without long wire. Rapid exchange balloon is the first choice usually and considered the workhorse balloon design. Regular balloons have two radio-opaque markers at both ends. Smaller balloons  $\leq 1.2$  mm diameter and  $\leq 8$  mm have a single marker in the middle.

Balloon compliance: compliance is one of the most important factors to select the appropriate balloon. More compliance allows for more adoption to vessel morphology without damaging normal vessel. Compliant balloons can extend as much as it is inflated till they reach rupture pressure so they are limited by pressure range that can be used safely without rupture, whereas less compliant balloons can take high pressure and technically they are not supposed to expand beyond the size they are designed for (limited by diameter). Still, even noncompliant balloons can rupture if inflated beyond their rupture pressure. Operators develop experience and remember rupture pressure so they anticipate rupture based on the balloons and avoid it. Each balloon comes with instructions about inflation pressures and diameters and rupture pressure. Rupture should be avoided unless it is intentional (in some CTO techniques) as the rapid release in pressure can cause dissections, perforations, and air embolism. Risk of rupture increases with calcified tortuous severe lesions and using high inflation pressures. Operator can recognize rupture easily by feeling sudden drop in balloon pressure and can be seen on fluoroscopy. If balloon rupture occurs, negative pressure should be applied rapidly, and balloon should be withdrawn. Follow up angiogram and assessing for complication should be performed. Semi-compliant balloons are mostly used for pre-dilatation and preparation of the lesion.

Balloon length is determined mainly by the lesion length (should match). It is usually shorter than the final stent which covers the proximal and distal edge of the lesion. Shorter balloons can be considered for resistant lesions. For post stenting dilation, balloon length matches the stent length.

Balloon diameter: for pre-dilatation, balloon diameters are based on the target vessel. The role is 0.9–1.1 balloon to vessel ratio. However, there are multiple exceptions to the rule. Resistance lesion does not allow using this rule. Starting with small balloon and escalating diameter is necessary. This approach is also helpful to avoid complications in cases of total occlusion of the vessel and especially if vessel trajectory is not clear and suspicion of being in small branch.

Best balloons for pre-dilatation are balloons with the lowest crossing profiles: crossing profile has direct effect on a balloon's ability to cross the lesion. It is related to specific balloon design, balloon tip diameter in addition to diameter (balloon and shaft), and length. Shorter, smaller balloons have lower crossing profiles.

Plain Old Balloon Angioplasty POBA is still performed even with rapid development of stents. The indication for POBA is limited to recurrent in-stent restenosis in small vessel and especially in diabetic patient where the risk of restenosis is very high in case of adding additional layer of stent. In rare indication, pre op POBA is performed for severe stenosis to avoid stenting and the need for dual anti-platelets therapy.

Cutting or scoring balloons are noncompliant balloons surrounded by metal wires or microtomes that can help in preparation resistance calcified lesions. Several designs are available. In general, cutting balloons are available in limited sizes and lengths. They have high crossing profile which make their use challenging especially where they are needed the most. This makes their use not common and mainly indicated in ostial lesions. Some operators use it for resistant lesions not amenable to other adjunct lesion modifications and in-stent restenosis due to new

atherosclerosis where the stent struts are not close to the lumen. Other in-stent restenosis mechanisms where the stent struts are close to the lumen, it is not recommended to use cutting balloons.

Withdrawing balloons should be performed after full deflation and confirmed re-wrapping of the balloon using fluoroscopy.

## 2.6 Stents

There are several stents from several medical companies with variable designs and engineering. Operator should be familiar with the basics of stent design, engineering, and generations. Stent design's topic is extensive, and reader is referred to dedicated stent chapter.

Similar to balloons: crossing profiles, stents design/generation, struts characteristics, stent drug, presence of polymer, sizes (diameter and length), clinical safety data and outcome all factors that affect operator choice of stent. Smallest stent diameter is 2 mm. Stenting vessel <2 mm size is not recommended as the value and long-term outcome is significantly questionable. However, balloon angioplasty of small vessels is recommended especially when these vessels supply a significant territory of the myocardium and when their occlusion cause significant symptoms or hemodynamic effect such as in cases of some septal perforators and right ventricular branch which could cause right ventricular infarction, shock and even death. These branches could shut down when jailed by stents and so it is recommended to avoid multiple layers of stents or stents overlap when jailing a branch vessel. In cases where multiple stents are needed in the main vessel, operator should plan to avoid multiple layers of stents jailing the branch vessel.

In coronary world, all available stents are rapid exchange balloon expanded design. In rare cases, it is necessary to use a peripheral size or self-expandable stent such in very large coronaries >6 mm or in cases of complications like perforations in a large coronary. Balloon expandable stents are semi-compliant balloons that can expand by increasing inflation pressure but there a max stent size for each design. As in balloons, each stent has a table for inflation pressure and correlating diameter as part of their design.

The old and still active role is to use stent length that covers the lesion with both proximal and distal stent edges at normal segment of the coronary. This is the role that current evidence support. However, with rapid progress in coronary stents design, wide spread of stent use, and expansion of stent indications such in diabetic patients with diffuse coronary disease, this role might not be applicable anymore.

Stent size topic is more complicated than balloon. The technical goal of stenting is to achieve a good coverage of the plaque, restore the vessel lumen, allow covering of struts with endothelium and prevent restenosis by using stent with strong radial force to prevent recoil and assuring well apposed struts. Operator should be knowledgeable of available stent sizes and design that allow them to expand beyond their original size by inflating the balloon beyond the design pressure or by post dilatation using larger balloon. For example: if an operator used a 3.0 mm stent that is designed to expand only to 3.5 mm and tried to expanded the stent to match the vessel size of 4 mm, that might be unsuccessful, cause struts fracture, significant recoil and restenosis. At the same time, using inappropriately large stent size, can cause edge dissection, perforation, rapid atherosclerosis at the edges due to inflammation and under expansion of the stent and restenosis. Stent size should be based on the size of reference vessel diameter RVD proximal and distal to the lesion to match the vessel size as close as possible. Operator can use several techniques to choose the appropriate stent size: using the balloon size used to prepare the lesion, compare vessel size to the guide catheter diameter, performing angiogram after

lesion preparation and intra-coronary Nitroglycerin, fluoroscopy based quantitative measurement and using intravascular imaging (IVUS or OCT).

To assure good results, operator can use stent imaging enhancement technology (Available on Phillips Fluoroscopy system) and intravascular imaging. Most operators use post dilatation with balloon to achieve good angiographic results. This step has been shown to improve angiographic results. Clinically, the benefit and long-term outcome of this step is a complex question to answer as it has multiple variables and cofounders. It is related to the clinical presentation acute myocardial infarction vs. stable angina, type of lesion and stent generation. Best data support this step for bare metal stents and first-generation drug eluting stents. For second and third generation DES, the data are controversial [11–13]. Significant evidence supports this step [14]. However, some question it as it might lead to microvascular injury or distal embolization in the setting of acute myocardial infarction. It is best to make individual decision to perform post dilatation in acute myocardial infarction cases.

Operator should minimize the number of stents used by using single stent and avoid stents overlap. This can be challenging in long lesions with significant discrepancy between proximal and distal vessel size or in challenging distal lesion in tortuous vessel. Using shorter and multiple stents might be required if other techniques for increasing support for delivery are not successful.

Stent restenosis is related to target vessel size (smaller have higher risk), stent length (longer higher risk), small diameter stents, undersized stent, stent drug type and body response (inflammation), ostial lesions, venous grafts lesions especially distal anastomosis to target vessel, presence of diabetes mellitus and calcifications. Appropriate oversizing might have beneficial results and reduce target lesion revascularization.

Stents thrombosis risk increases with premature stopping of anti-platelets therapy, stents overlap, bifurcation lesions, stent edge dissection, stent's struts malapposition, time from implantation, poor distal flow post intervention, presence of diabetes mellitus and chronic kidney disease, reduced left ventricular systolic function. There are some data to subject larger vessel and especially RCA has more risk of thrombosis.

### **3. Helpful tips to address difficulties performing basic steps of PCI**

#### **3.1 Difficulty wiring**

Wiring the true lumen during PCI is the initial and most important step. Operators can face several difficulties and some solutions are listed:

**1. Severe stenotic lesions:**

Find the microchannel using multiple views and use escalating wire technique to provide more support to the wire tip.

Use a micro catheter or balloon to support wire's tip.

**2. Tortuous vessels and lesions: use wires with strong shaft support and torque transmission.**

**3. Angulated target vessels:**

Adjust the wire tip to the most angulated vessel.

Use angulated micro-catheter like super cross 45-90-120° or steerable micro-catheter.

Use dual lumen micro-catheter.

Use knuckled wire retro wiring technique: advancing knuckled wire in the main vessel beyond the takeoff of the branch angulated vessel then withdrawing



slowly toward till the tip of the wire engage the target vessel. This technique is helpful to wire a jailed branch vessel and assuring the wire is not between stent and vessel wall (under stent).

### 3.2 Difficulty delivering balloons and stents

First step to recognize if the difficulty is related to the lesion itself or difficulty due to the target vessel (severe tortuosity or calcifications)

Use a buddy wire technique.

Use a wire with strong shaft (Grandslam, ironman, mailman) that provide more support. If not able to deliver such wire, use special wire that can navigate tortuous vessels (Suoh, Sion blue or Black, Samurai) and exchange for stiffer wire using over the wire balloon or micro-catheter.

Use a guide extension: guide extensions should be advanced carefully over a balloon or stent using balloon-assisted tracking technique to avoid vessel injury especially at vessel bends. Guide extension shaft is to one side (not centered like balloons or stents) and their lumen is on the other side which make them biased to one side and that's the reason the tip can damage the intima and cause dissection while advancing them. Guide extensions will cause pressure dampening and can increase ischemia as they get advanced within the coronary. Operator should avoid advancing them to a target vessel smaller than the size of guide extension to avoid vessel injury. Contrast injection with high pressure through a guide extension can cause dissection.

Deep guide intubation.

Using anchor balloon. A small compliant balloon in a proximal branch is usually used to provide support.

*If the difficulty is more related to the lesion itself:*

Use simultaneous two small balloons inflations.

Use glide balloon.

Grenadoplasty: intentionally inflating small balloon to rupture which could affect the lesion integrity.

Wire cutting technique: using two wires across the lesion, passing small balloon over one wire, and performing tugging and pushing on the balloon or the other wire that can act as a saw cutting the lesion.

Use lesion modification techniques such as atherectomy, LASER, Intra vascular lithotripsy, brachytherapy.

More aggressive techniques involve sub-intimal access to perform external crush or distal anchoring.

Combination of above techniques is needed in difficult cases.

### 3.3 Difficulty with stent delivery

In addition to techniques above:

Use shorter stent with smaller struts.

Administration of Rota glide/Viper glide while advancing the stent toward the lesion.

## 4. Special challenging cases of PCIs

### 4.1 Aorto-ostial lesions

Aorto-ostial lesions (RCA, left main, and bypass grafts) can be challenging for several reasons:



Engaging challenges: after selecting appropriate guide shape, engaging severe lesions most likely would cause dampening, possibly ischemia, dangerous arrhythmias, and subsequent hemodynamic effect. To avoid these issues or in cases with challenging coronary take offs, operators can use one or more of the following techniques:

Using a GC with side holes. Again, side holes can cause a false sense of assurance.

Quick engagement and wiring followed by disengagement to minimize ischemia.

Phishing technique: it involves having the tip of the guide few millimeters close to the ostium without engagement then attempting to wire the coronary. If the ostium lumen can accommodate a micro catheter, then micro catheter can be used to approach the ostium with long wire to facilitate wiring the coronary.

Steerable micro catheters are the most helpful when using this technique.

Using a small 4 or 5Fr diagnostic catheter to engage and wire the coronary with a long wire then exchange with the appropriate guide catheter over the long wire.

Calcified ostial lesions that requires adjunct plaque modification such as atherectomy carries risk of causing aortic dissections. This can occur with simple angioplasty. The inflations time while performing angioplasty or stenting should be short as these vessels might be the only perfusion source of the heart.

Missing the target: as operators try to match the proximal end of the stent to the ostium, it is not uncommon to miss the target ostial lesions. Locating the ostium is challenging and appropriate imaging views are critical here. To assure best view of ostial lesion, orthogonal views should be used. For ostial left main, superficial LAO/cranial and for RCA steep RAO and even lateral views are required depending on its origin. It is essential to know where the stent ends in regard to its radiopaque markers in order not to miss the ostium as some stents ends at the distant end of the radiopaque marker and others at the proximal end of the marker. In order to achieve good lesion coverage, stents are deployed to protrude couple of millimeters out of the coronary and inside the ascending aorta. A lot of operators recommend flaring the protruding part with large balloon and high pressure to make the stent take the shape of the internal aorta. This step is important especially when future interventions are anticipated. Without this step, future engagement of the stent and PCI becomes a very difficult mission and almost impossible. There are special designed balloons that can help with achieving this step. A catheter with two balloons, two inflating ports, and three markers that identify the edges of the two balloons. Operators should use caution while using these double balloons as inflating proximal balloon inside the vessel can cause vessel injury. Sbazo technique is a unique technique where another wire is passed through the proximal stent cell and while advancing the stent the wire stops the advancement while assuring covering the ostium. The same technique can be used at a bifurcation ostium lesion while avoiding jailing the branch vessel.

## **4.2 Bifurcation lesion techniques**

Bifurcation of lesions in general is one of the most technically complex coronary interventions. Multiple classifications for bifurcation coronary lesions are available. The most common one is Medina classification which has three digits depending on true lesion involvement of vessels around bifurcation.

In order to make bifurcation stenting simpler, the first decision is to decide whether the single-stent (provisional stenting) or the two-stent approach is the appropriate technique. There are significant data comparing provisional stenting to other two stent techniques. Both are acceptable techniques with good outcome and the decision to choose one is related to several factors.

Several techniques are used for bifurcation lesions. Deciding the best technique to use depends on multiple factors: medina classification, the angle between main and branch vessels, size difference of main and branch vessels, difficulty to rewire the sent struts, expected plaques shifting/angle changes post stenting and need for branch stenting distal to the bifurcation lesion, size and territory size of branch vessel and presence of trifurcation or proximal lesion.

Proximal optimization technique POT is an important step while performing any PCI and especially in the setting of bifurcation stenting. It refers to performing angioplasty inside the proximal segment of the stent/stents (making sure the distal end of the balloon at the level of side branch) to make sure proximal stent are well apposed and dilated to match the proximal vessel size. Injecting contrast while the balloon is inflated can help assuring well stent apposition when no contrast leak to distal vessel. POT allows safe rewiring and further intervention of the SB when required. It is important to perform POT at the right level, repeat it or perform kissing balloons if the SB was ballooned to optimize any possible distortion of the stent and to remove the SB wire before repeating POT or performing kissing balloons to avoid wire trapping complications.

Final kissing balloon is recommended in all two stents techniques. Kissing balloons goal is to optimize the bifurcation carina and lumens of both vessel at this level without compromise one of the bifurcation lumens.

IVUS-assisted bifurcation stenting has better outcome especially in distal left main bifurcation lesion. Because fluoroscopy angiogram provides only two-dimensional images, intravascular imaging with IVUS and/or OCT can be very helpful to understand the morphology of bifurcation stenosis if performed before and after to evaluate the results and need for further intervention.

For any bifurcation lesion, protecting both vessels, branch vessel (side branch SB) and main vessel (MV) by wiring them is recommended especially when branch vessel is 2 mm and larger in diameter. Even in Medina 0.1.0 lesions, wiring both vessel for protection is recommended. Acute vessel closure of large branch could occur when least expected especially in the setting of small bifurcation angle.

It is very important to pre-determine the best views that allow the operator to evaluate the bifurcations accurately and assess the changes in both branches and main vessel at the same time with each step. Orthogonal views are important during all steps.

There is no available guide catheter that allows simultaneous three balloon inflations or stent deployments. There are techniques that use two guide catheters one 7Fr and the other 6 or Fr to treat trifurcation lesion with the risk of inducing ischemia by completely obstructing the coronary ostium.

Bifurcation lesions that carry the highest risk are true bifurcation lesions Medina 1.1.1 of distal left main involving ostial LAD and LCX. Unprotected left main is referred to any left main with no bypass to the LAD or LCX. It is important to recognize that intervention on unprotected left main carries a higher risk especially in the setting of left dominant system. Although recent emerging data suggest a similar outcome comparing PCI to CABG in such lesions even in diabetic patients, CABG still has the best data [11–13]. Discussion of the data is beyond this chapter. However, a simple decision-making approach is that the more complex anatomy, the more benefit CABG can provide especially in diabetic patients with low left ventricular ejection fractions [14]. It is important to recognize that diabetic patients have higher risk of restenosis and tend to have smaller vessels' lumen due to diffuse

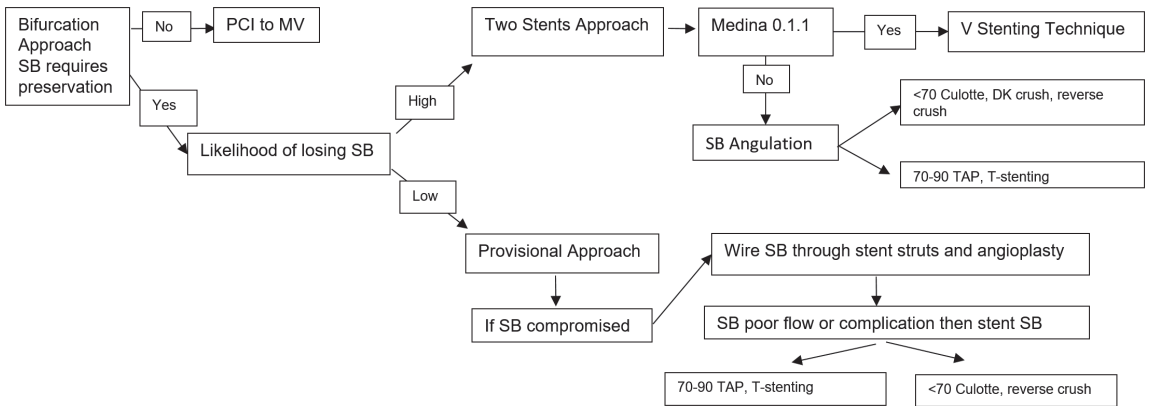
disease which in turn increases the need for vessel revascularization due to more hemodynamically significant restenosis. The same percentage of stenosis could be tolerated better with less hemodynamic effect in larger non-diabetic vessels. If a patient is not a candidate for CABG, a hemodynamic support device should be considered depending on the severity of stenosis, calcification, the need for atherectomy or other lesion modification techniques, presence of aortic valve stenosis, and LV function. Even with normal LV function, operator should consider mechanical support with severe calcified lesions with high risk of acute vessel closure, low LVEF, prolonged ischemia or complication. Simultaneous kissing stents to minimize ischemia time is a good option especially in Medina 0.1.1 lesions. **Figure 4** shows a simple decision-making approach for bifurcation stenting.

4.2.1 Provisional stenting

Stenting from main vessel to main vessel or branch depends on size differences, angulation of the SB, and the easier vessel to rewire after jailing it in case further intervention is needed.

When the size difference is less between the SB and proximal MV compared to difference between distal lesion of MV and proximal vessel, then stenting from main vessel to the SB is a good option, otherwise, stenting from proximal to distal MV is most common especially in LAD bifurcation lesions. Stenting to SB like from proximal LCX to branch obtuse marginal is more common than stenting from proximal to distal LCX. Evaluating the SB flow is very important to make a decision whether it requires angioplasty or stenting. Before judging the branch flow, it is recommended to administer intracoronary nitroglycerin.

As long as SB has normal flow and is not at risk of closure, no further intervention is required. If SB flow is impaired, performing angioplasty of stent struts the next step. If the results of angioplasty weren't successful to improve the flow, or caused SB injury, stenting becomes required. For the same reason SB with normal flow or small lumen <2 mm should not be rewired unless poor flow is present as rewiring with or without angioplasty might cause more complications than benefits. When attempting to rewire the jailed SB through stent struts, there is always a concern of wiring under the stent or not able to wire the SB especially when POT is not performed. To avoid that, the MV wire can be used to rewire the SB as long as the operator does not withdraw the wire beyond the proximal edge of the stent. In this way, the operator can be assured that the wire is inside the stent. Another approach is to reverse wire the SB by wiring the MV stent with J tip wire and then the wire is withdrawn to the origin of SB. Lastly, a special twin pass micro-catheter loaded on the MV wire and passed till



**Figure 4.**  
A simple decision-making approach for bifurcation stenting.

the bifurcation. The second lumen can be used to wire the branch safely within the stent and provide support in challenging SB rewiring cases. However, this technique requires long wire (or extension wires) to make exchanges.

When SB stenting is required, reverse crush, T-stenting, TAP or Culottes techniques could be used.

#### *4.2.2 Mini crush technique*

After wiring both the main vessel and its branch. A stent sized to the SB is placed into the branch vessel. To assure complete coverage of the lesion, part of the stent protrudes inside the MV. As the goal is to cover the whole bifurcation, the length of the protruding segment of stent correlates with the angulation angle. The smaller the angle the longer this protruding segment inside the MV. If the SB is taking off at 80° then theoretically, no part of stent should be protruding inside the MV. After SB stenting, a balloon loaded on the wire of the MV is used to crush the protruding segment of stent followed by stenting of the MV. The goal of mini crush that protruding segment of the stent would not jail the SB completely so if post stenting intra vascular imaging is performed, the distal part of the SB takeoff lumen will have two layers of stent, the protruding crushed segment of the SB stent and the MV stent while the proximal part will have only the MV stent. Rewiring the branch through the main stent struts and performing kissing balloon creating new carina is recommended. The lesion under the carina will have two layers of stents. If the segment of stent protruding inside the MV is long enough that when it is crushed by angioplasty/stenting the MV, the technique turns to crush stenting technique.

#### *4.2.3 Crush stenting technique*

After wiring both vessels, loading a balloon on the MV wire, stenting the SB with significant part of stent protruding inside the MV is performed. The MV balloon then used to crush the protruding segment of the SB stent jailing the lumen of the branch completely with two layers of stents. Stenting of MV is then performed jailing the SB with additional layer of stent struts. Before that the SB wire is withdrawn to avoid wire trapping complications. Now, the SB is covered with three layers of stent struts which most likely will affect the flow of the SB. Thus, rewiring across these layers of stents is required and used to perform angioplasty to dilate the stent struts followed by performing kissing balloons.

#### *4.2.4 Reverse crush technique*

It is similar to the crush technique but in reverse sequences. After wiring both vessels, the MV is stented then the SB is rewired across the MV stent struts which maybe challenging especially in the setting of true SB severe stenosis, and rewiring becomes more difficult with plaque shifting/angulation angle changes after stenting the MV. A balloon angioplasty followed by stent that protrude partially or completely inside the MV is deployed. At this point, depending on the angiographic results and the covering of diseased, the operator might crush the SB stent performing angioplasty inside the MV stent (followed by the rest of crush technique) or perform kissing balloon leaving segment of the protruding stent hanging in the lumen of the MV.

#### *4.2.5 Culottes' bifurcation stenting*

It is the most complicated technique but has a good supportive data. After wiring both vessels. The vessel with the hardest to rewire is stented first. Then alternating



wires positions to wire the SB through stent struts followed by performing angioplasty to dilate struts to the nonstented vessel. This step might require several balloons' angioplasty with escalating sizes. Then, stenting the SB jailing the first stented vessel. Again, here alternating wire positions are performed followed by final kissing balloon. The advantage of this technique is complete coverage of the lesions with stents. However, double coverage of proximal MV with two layers of stents and new carina have been controversial and suspected to increase risk of thrombosis. Most recent evidence suggests no difference between this technique and other two stents techniques in terms of stent thrombosis. Culottes' technique is best used when the branched vessels are close in diameter to the MV to avoid stent size mismatch and the angulation angle is acute below 70°.

#### 4.2.6 V stenting

This technique is best used in bifurcation lesion Medina class 0.1.1 where the proximal MV is not involved or when the lesion is barely involving the proximal MV. After wiring both vessels, angioplasty of both vessels might be required regardless to pass stents followed by simultaneous kissing stenting. Stenting is step wise fashion with deploying one stent at time is feasible using 6F GC as long as it is followed by kissing balloons. Otherwise, performing kissing stent requires 7F GC.

#### 4.2.7 Double barrel kissing stents technique

As in the case of V stenting, this technique requires 7F GC. It can be quick minimizing ischemia time and thus useful for large left main vessel with bifurcation disease involving LAD and LCX. After wiring both vessels, simultaneous stenting is performed creating double barrel in the proximal MV. Clearly, the stents in the proximal MV are not fully deployed and they are crushed against each other and the relationship between these barrels are not as simple it might appear. They are mostly twisted around each other and the size difference might affect the morphology of each stent within that part, i.e., one stent could be circle, the other is D shaped where in perfect scenario they both should have D shaped appearance with full apposition against the vessel. Clearly, re-accessing can be very challenging, which makes this technique less suitable for small vessel bifurcation lesions and for patients with expected need for further revascularization.

#### 4.2.8 T-stenting technique

Bifurcation lesions that are appropriate for T stenting are lesions where the angulation angle is between 70 and 90°. The steps include wiring both vessels, performing necessary pre ballooning if needed, and then stenting the SB followed by stenting MV jailing the SB stent. A helpful technique to assure full coverage of bifurcation lesion is to leave inflated balloon inside the MV first then pulling he stent of the SB till it faces the resistance from the inflated MV balloon and then deflating that balloon followed by deploying the SB stent and finally stenting the MV. Depending on the results, rewiring through the MV stent struts might be necessary, followed by performing kissing balloons. When the angulation angle is less than 70, this approach is called TAP.

#### 4.2.9 T-stenting and small protrusion technique TAP

It is a modification of the T-stenting technique aimed at optimizing "bail-out" SB stent implantation after MV treated by the "provisional" approach. Thus, it is



applied after the MV stent has been deployed and kissing balloon inflation has been performed. In particular, TAP stenting was developed to ensure full SB ostium coverage by DES struts. To achieve this, the SB stent is delivered with intentional minimal protrusion inside the MV with an uninflated balloon positioned in the MV across the SB take-off. After SB stent deployment, kissing balloons inflation is immediately performed with the stent's balloon and the MV balloon. Further kissing balloon inflations with noncompliant balloons may be advisable in the case of suboptimal stent expansion. During the practice of TAP stenting, the operator should pay attention to and try to limit as much as possible the protrusion inside the MV which influences the length of the neo-carina. Nevertheless, similar to crush techniques, two main determinants of neo-carina length should be recognized: the SB take-off angle and the "quality" of pre-TAP kissing inflation. The impact of the SB take-off angle is quite intuitive: when the SB has a "T" shape take-off, small or absent SB stent protrusion inside the MV is needed to cover the SB ostium successfully. On the other hand, acute SB angles (Y-shapes) are associated with longer, oval-shaped SB ostia. Such an anatomic configuration implies the need for wider protrusion of the SB stent inside the MV, resulting in a longer neo-carina.

### 4.3 Grafts interventions

Engaging, performing angiogram and interventions on RIMA/LIMA carries higher risk for multiple reasons. LIMA is a vessel with high risk for dissection during any instrumentation. Most patients that requires LIMA interventions have significant underlying native vessel a baseline with possible occlusion of other bypass grafts. In a lot of clinical scenarios, LIMA could be the only source of perfusion for the heart.

Grafts/LIMA interventions could be performed via any approach. Left radial or distal left radial has the advantage of avoiding complications of femoral approaches and avoid left subclavian issues. Most common LIMA interventions are related to anastomosis at the LAD, left subclavian pseud or true stenosis, and ostial lesions at the takeoff from left subclavian. Lesions in the body of LIMA are less common. When using femoral approach, a lot of operators prefer to use a short LIMA guide which allows for more wire to reach distally to distal LAD after the anastomosis. Short GC usually is not required when using left radial approaches and if needed, shortening the guide catheter is a technique that can be used.

Distal anastomosis interventions: in early post-operative days, grafts angiogram (especially arterial grafts LIMA, RIMA, radial) might appear concerning for a dissection or spasm and this could be related to the post-operative shock or vasoactive medication. Most of the times, graft has not yet matured, and later imaging would confirm that. Stenosis at the anastomosis is mostly related to operative technical issues during post-operative period vs. true progression of CAD during the months or years after. Intervention if truly indicated should be performed quickly but safely specially in fresh LIMA-LAD anastomosis. Operator should minimize occluding the target grafts with the guide catheter as much as safely possible. Direct stenting is a good option if a stent could be passed without ballooning. Fresh anastomosis and sutures might be frail and over inflation of the balloon or stent should be avoided. Stent is sized based on the size of the bypassed vessel. One of the challenges in SVG anastomosis interventions is sizing the stent. It is very common that SVG is much larger than the target bypassed vessel. Proximal optimization technique using balloon diameter sized to SVG to dilate the segment of stent inside SVG. Data suggests good outcome post PCI of LIMA-LAD if performed by experience operator. Proximal optimization technique to the size of the LIMA has a lower risk especially in early days post bypass.

SVG are prone to thrombosis. Microvascular thrombosis can lead to bad outcomes. Using distal embolic protection (**Table 15**) in cardiac vessels interventions has showed benefits in interventions on SVGs especially with thrombotic lesions. The goal of distal embolic protection is to minimize/stop any thrombi from traveling distally to microvasculature. These devices cannot be used for all SVGs interventions. Distally to the target lesion, vessel should have about 4 cm safe landing segment where the device can be deployed. Severe stenotic lesions (especially aorto-ostial lesions) make using distal embolic protection technically challenging or impossible. Some operators advocate in such cases with difficulty passing the embolic protection device is to perform direct stenting if it allows. Fibrotic lesions (instent restenosis) with no friable thrombotic material, might not benefit from embolic protection. Direct stenting is another approach to minimize distal embolization and microvascular obstruction when feasible. Aneurysmal changes in SVG are very common which makes stent sizes difficult. Sizing should be based on the nonaneurysmal segment and post dilation can be used when needed. Proximal embolic protection devices are still available but are not used as much as the distal one during PCI on SVGs. The idea of these devices to reduce the thrombi that can travel upwards and cause organ ischemia specifically a stroke.

No reflow phenomena is common during any coronary or graft intervention. It is more common with thrombotic lesions and thought to be related to microvascular thrombosis and/or dysfunction. In addition to minimize clot burden with embolectomy, angioplasty and stenting to trap clots, administering of microvascular active medications nitroprusside, verapamil and/or adenosine is necessary.

4.4 Instent restenosis treatment

Simple focal restenosis is usually treated with DES. The era of DES changed the approach of instent restenosis treatment. A second and a third layer of stents can be used to treat the lesion especially focal lesions in the body of the stent or edge of stent whether the prior used stent was a BMS or DES. Treatment of instent restenosis can be very challenging due to the variable potential underlying pathophysiology of stent restenosis: undersized, under expanded stent, presence of calcification, neoatherosclerosis, fibrotic tissue or presence of diffuse instent restenosis. Understanding the mechanism of restenosis is the main step to choose the appropriate treatment strategy. Intravascular imaging with IVUS or OCT if possible can be very helpful. However, most of the time these imaging catheters cannot cross the restenosis. In these setting, ballooning might be the only option.

In case of diffuse instent neoatherosclerosis cutting balloons is not a good option especially if the prior stents are well sized and fully apposed. The decision of adding a

Device	Guide compatibility	Crossing profile	Vessel size	Length of filter/landing zone	Notes
Spider RX (ev3)	6Fr	3.2 Fr	3–6 mm	10 mm/39 mm,	Only one with wire of choice
FilterWire (Boston Scientific)	6Fr	3.2 Fr	2.5–5.5 mm	15 mm/39 mm	
GaurdWire	6Fr	2.1 and 2.8 Fr	3–6 mm		
Interceptor	6Fr	2.7 Fr	2.5–5.5 mm		Capture Small Particles <50 µm

**Table 15.**  
*Distal embolization protection devices.*

second layer of stent depends on the results of angioplasty, size of the vessel, and long-term outcome. If the mechanism of restenosis is under expanded stent, fibrotic tissue, calcifications underneath the stent or hyper intimal hyperplasia, the treatment is targeting the underlying tissue. Available treatment options are those used for adjunct plaque modifications (brachytherapy, LASER, and intravascular lithotripsy).

#### 4.5 Post aortic valve replacement coronary intervention

Supra-annular valves like CoreValve bio prosthetic makes coronary access challenging. The goal is to use a guide catheter to cross the cells of the bio prosthetic valve at the level of the coronary. Best approach is to use a 0.5 shorter guide catheter than usually used. Wire assisted technique to manipulate the GC to sit within the bio prosthetic and at the appropriate cell level to cross toward the coronary ostium. Manipulating the GC with a 0.035" guide wire should be performed within the lumen of the aorta and away from the aortic wall to avoid aortic or coronary ostium injury. Guide wire makes the GC stiff and moving the GC quickly could cause the GC to jump quickly and damage the coronary ostium. Once the GC is in a good trajectory and directed toward the coronary ostium, GC should be advanced slowly toward the ostium.

### 5. Conclusion

Percutaneous coronary interventions have always been crucial in medical care. Now more than ever, with rapidly evolving percutaneous interventions and less surgical interventions, coronary percutaneous interventions are priority. Developing required technical skills and mastering basic and complicated intervention techniques have never been as important as they are now. Before proceeding with any intervention, all necessary equipment and medications should be available. Other essential requirements for any successful intervention include planning, having competency in required techniques, early recognition, and being prepared to manage complications.

#### Conflict of interest


The author declares no conflict of interest.

#### Author details

Imran Khalil  
Medicine (Interventional Cardiology), VA Medical Center, Indiana University  
School of Medicine, Indianapolis, Indiana

\*Address all correspondence to: [elimrans@hotmail.com](mailto:elimrans@hotmail.com)

#### IntechOpen

© 2020 The Author(s). Licensee IntechOpen. This chapter is distributed under the terms of the Creative Commons Attribution License (<http://creativecommons.org/licenses/by/3.0>), which permits unrestricted use, distribution, and reproduction in any medium, provided the original work is properly cited. 

## References

- [1] Romagnoli E, Biondi-Zoccai G, Sciahbasi A, et al. Radial versus femoral randomized investigation in ST-segment elevation acute coronary syndrome: The RIFLE-STEACS (radial versus femoral randomized investigation in ST-elevation acute coronary syndrome) study. *Journal of the American College of Cardiology*. 2012;**60**(24):2481-2489. DOI: 10.1016/j.jacc.2012.06.017
- [2] Jolly SS, Yusuf S, Cairns J, et al. Radial versus femoral access for coronary angiography and intervention in patients with acute coronary syndromes (RIVAL): A randomised, parallel group, multicentre trial [published correction appears in *Lancet*. 2011 Apr 23;377(9775):1408] [published correction appears in *Lancet*. 2011 Jul 2;378(9785):30]. *Lancet*. 2011;**377**(9775):1409-1420. DOI: 10.1016/S0140-6736(11)60404-2
- [3] Jolly SS, Amlani S, Hamon M, Yusuf S, Mehta SR. Radial versus femoral access for coronary angiography or intervention and the impact on major bleeding and ischemic events: A systematic review and meta-analysis of randomized trials. *American Heart Journal*. 2009;**157**(1):132-140. DOI: 10.1016/j.ahj.2008.08.023
- [4] Ferrante G, Rao SV, Jüni P, et al. Radial versus femoral access for coronary interventions across the entire spectrum of patients with coronary artery disease: A meta-analysis of randomized trials. *JACC. Cardiovascular Interventions*. 2016;**9**(14):1419-1434. DOI: 10.1016/j.jcin.2016.04.014
- [5] Hibbert B, Simard T, Wilson KR, et al. Transradial versus transfemoral artery approach for coronary angiography and percutaneous coronary intervention in the extremely obese. *JACC. Cardiovascular Interventions*. 2012;**5**(8):819-826. DOI: 10.1016/j.jcin.2012.04.009
- [6] Michael TT, Alomar M, Papayannis A, et al. A randomized comparison of the transradial and transfemoral approaches for coronary artery bypass graft angiography and intervention: The RADIAL-CABG trial (RADIAL versus femoral access for coronary artery bypass graft angiography and intervention). *JACC. Cardiovascular Interventions*. 2013;**6**(11):1138-1144. DOI: 10.1016/j.jcin.2013.08.004
- [7] Pancholy SB, Joshi P, Shah S, Rao SV, Bertrand OF, Patel TM. Effect of vascular access site choice on radiation exposure during coronary angiography: The REVERE trial (randomized evaluation of vascular entry site and radiation exposure). *JACC. Cardiovascular Interventions*. 17 August 2015;**8**(9):1189-1196
- [8] Shah RM, Patel D, Abbate A, Cowley MJ, Jovin IS. Comparison of transradial coronary procedures via right radial versus left radial artery approach: A meta-analysis. *Catheterization and Cardiovascular Interventions*. 2016;**88**(7):1027-1033. DOI: 10.1002/ccd.26519
- [9] Plourde G, Pancholy SB, Nolan J, et al. Radiation exposure in relation to the arterial access site used for diagnostic coronary angiography and percutaneous coronary intervention: A systematic review and meta-analysis. *Lancet*. 2015;**386**(10009):2192-2203
- [10] Anadol R, Brandt M, Merz N, Knorr M, Ahoopai M, Geyer M, et al. Effectiveness of additional x-ray Protection devices in reducing scattered radiation in radial intervention: The ESPRESSO randomized trial. *Open*. 2019;**9**:e029509. DOI: 10.1136/bmjopen-2019-029509
- [11] Thuijs DJFM, Kappetein AP, Serruys PW, et al. Percutaneous



coronary intervention versus coronary artery bypass grafting in patients with three-vessel or left main coronary artery disease: 10-year follow-up of the multicentre randomised controlled SYNTAX trial [published correction appears in *Lancet*. 14 March 2020;395(10227):870]. *Lancet*. 2019;**394**(10206):1325-1334. DOI: 10.1016/S0140-6736(19)31997-X

[12] Yousif A, James PH, Ahran DA, et al. Mortality after drug-eluting stents vs. coronary artery bypass grafting for left main coronary artery disease: A meta-analysis of randomized controlled trials. *European Heart Journal*. 2020;1-8. DOI: 10.1093/eurheartj/ehaa135

[13] Duk-Woo P, Jung-Min A, Hanbit P, et al. On behalf of the PRECOMBAT investigators. *Circulation*. 2020;**141**:1437-1446

[14] Niels RH, Timo M, Mitchell L, et al. Percutaneous coronary angioplasty versus coronary artery bypass grafting in the treatment of unprotected left main stenosis: Updated 5-year outcomes from the randomised, non-inferiority NOBLE trial. 2019. *Lancet*. 18-24 January 2020;**395**(10219):191-199. DOI: 10.1016/77S0140-6736(19)32972-1