

We are IntechOpen, the world's leading publisher of Open Access books Built by scientists, for scientists

6,900

Open access books available

186,000

International authors and editors

200M

Downloads

Our authors are among the

154

Countries delivered to

TOP 1%

most cited scientists

12.2%

Contributors from top 500 universities



WEB OF SCIENCE™

Selection of our books indexed in the Book Citation Index
in Web of Science™ Core Collection (BKCI)

Interested in publishing with us?
Contact book.department@intechopen.com

Numbers displayed above are based on latest data collected.
For more information visit www.intechopen.com



Tips and Tricks in Microvascular Anastomoses

Sharifah Ahmad Roohi

Abstract

Microvascular anastomosis is a highly skilled surgical technique that requires the assistance of optical magnification via an operating microscope or loupes to be fully visualised and thus accomplished reasonably well. It demands the full attention of the surgeon throughout the procedure. Even the smallest of inadvertencies may result in disastrous results. Practice has no shortcut and the more experienced a **skilled** surgeon is, the better his results. The chapter begins with a detailed account of preparedness in the operating room, for preparation is the path to success. There are however tips to reduce the incline of the learning curve and points to remember when things are not quite going right. This chapter attempts to deal with those moments.

Keywords: arterial repair, microvascular anastomosis, replantation, revascularization techniques, venous repair and grafting

1. Introduction

Microvascular anastomosis is a fine art form which requires practice to get it perfect. Perfection is required to repair a vessel that is 2 mm or less in diameter with precision in order to prevent the development of a thrombus resulting in vessel occlusion. In order to achieve this, harmony should be present between the microscope, its operator (the surgeon), and his instruments. With experience, the surgeon may be able to successfully anastomose 1–2 mm diameter vessels with loupes magnification, but it is not recommended for the novice. This chapter is divided into two sections: the first is a **brief description** of the surgeon's posture, his instruments, patient factors and the environment to illustrate how the harmony results in a better whole. In the second section, the **techniques** on how to accomplish the process without compromising the quality of repair and the **finer points** on how to enhance it will be highlighted to bring the whole orchestra to its crescendo and conclusion.

2. The components of the orchestra

There are four main components to the whole scenario. If we liken it to a Musical Concert, then the place where the whole operation takes place is the Operating Room (OR) while the main Conductor of the event is the Chief Surgeon. The surgical (musical) instruments are what are essential for the surgery to take place and finally the musical score is the patient upon which this whole event is dependent upon to be successful.

2.1 The operating room

The theatre where the drama takes place is the operating room. The environment in this room is critical to the success of the surgery. The conductor or Master of the OR is the surgeon and the environment should be tailored to his or her preference.

Microsurgery requires a steady hand and practiced skill. It takes hours to complete a replantation or undertake a coronary artery by-pass graft while demanding full concentration to the task at hand. Mundane issues must be sorted out for any discomfort may prolong the surgery and even render it unsuccessful.

2.1.1 Temperature and lighting

The temperature of the OR is of course controlled within specified limits of regulatory standards, but the main surgeon must be comfortable throughout the duration of the surgery.

The lighting, similarly, has to be of superb quality to visualise the most intricate detail. The aim is to have a well-illuminated field without shadows. The operating microscope achieves this by housing an incandescent or halogen bulb in the floor stand and transmitting the light via a built-in fibre optic cable to the operating field. The general surgical field, however, is wider and once the surgeon looks out to this area, it will appear dark, thus the periphery also has to be well-lit with good OR lights.

2.1.2 Theatre equipment

Surgical equipment such as the Operating microscope, the x-ray machine, the coagulation (diathermy) unit, the heart-lung bypass machine and the anaesthetic machines all need to be co-ordinated and well-spaced out (**Figure 1**). In a centre routinely performing these surgeries, there are fixed protocols: they are there for a reason. Surgeons in different centres will do it differently depending on how (and where) they have been trained; therefore, these protocols are to be tailored to the surgeon or institution.

The surgeon's stool (**Figure 1: inset**) is obviously of extreme importance and depending upon their preference should be comfortable and of perfect (adjustable) height with rollers to allow the surgeon to move seamlessly. Different sub-specialties have slightly varying adjustments such back support, arm support (or none) a ring

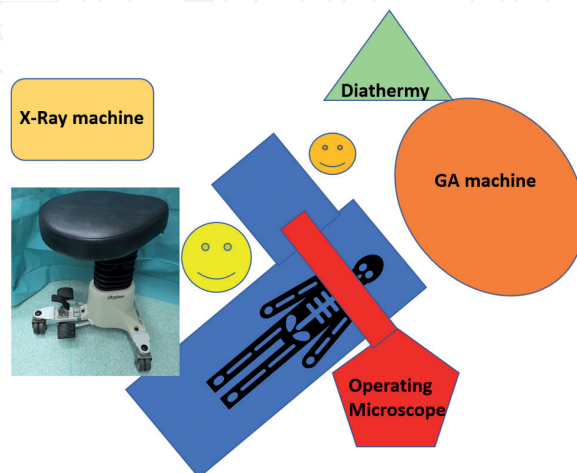


Figure 1. Operation theatre set-up. The X-ray machine (mini C-arm), operating microscope and diathermy machine should all be away from the main surgeon and not touching the operating table. The surgical stool is shown in the inset.

below to rest the foot and so on. These are personal preferences and every attempt should be made to accommodate them.

The Diathermy cable should be tucked well out of the way and the foot pedal next to the surgeon's dominant foot. If the microscope has foot control, then it could be placed at the assistant's preferred foot or elsewhere. The wire should not interfere with the rollers of the operating surgeon's stool.

2.2 The surgeon

The surgeon performing an operation must be well rested, energised, reasonably hydrated and abreast of the task at hand. It is important to note that any heavy activity (swinging heavy objects, manual activity) should be avoided in the 24 hours prior to microsurgery. If one wants to test this out, try playing table tennis after a round of tennis. Using the larger muscle groups will compromise the fine motor control (in millimetres and micrometres) required in microsurgery. Caffeine intake should be the amount the surgeon is used to: not more and not less. For obvious reasons the use of sedatives prior to surgery is not advised as are medications that may cause drowsiness.

During emergency cases, if progress is not being made, a 10–20-minute break is advised; it usually allows a fresh take on the stumbling block. If it is a technically difficult step, take a breather before starting it, better insight is gained with a few deep breaths.

2.3 The equipment

2.3.1 The operating microscope/loupes

The Operating microscope is used in many different surgical specialties and has been adapted for their particular needs. The Ophthalmic one for example is angled at 45° while the neuro one is used while in standing position. The Plastic and Hand Surgeons use the same one in a sitting position and now the latest ones by Zeiss (Pentero and Kinevo) have 3D images and screens that are facing the surgeon so he does not even have to look down at the field (**Figure 2**)!

The Neuro Microscopes show arterial and venous flow – they also have infrared technology that allows intra-operative visual assessment of blood flow and patency, all with the push of a button.

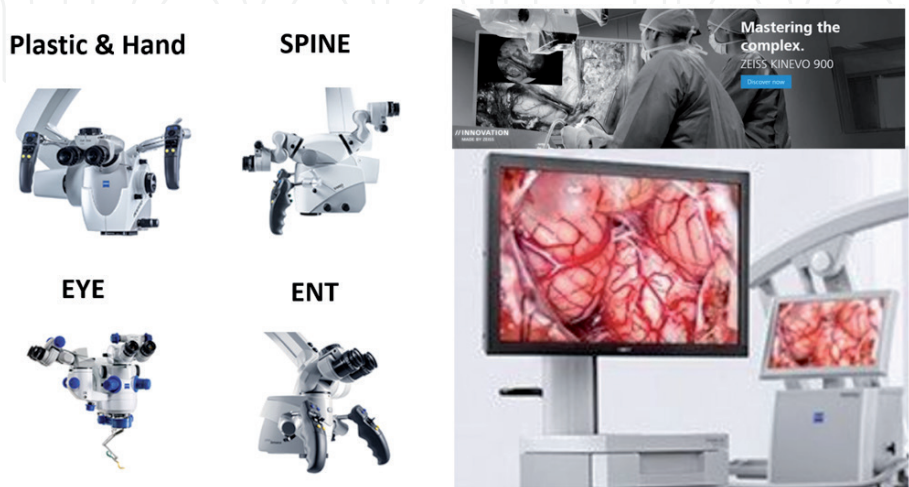


Figure 2. Operating microscopes. The classic Zeiss microscope came on the S88 floor stand. Now Zeiss has the modern Pentero and Kinevo which can do fluoroscan view as well as show the screen up front (on the right), so the surgeon can operate seeing up, not down, reducing neck strain.

In cases where the vessel diameter is more than 1.5 mm, it is possible to use high powered loupes (4.2x or even 6.0x) to perform the anastomoses safely (by an experienced surgeon). There are now a number of high-quality loupes in the market from various players that provide an extended field of vision with great clarity. It should be noted that the focal length is fixed, so be sure of your working distance before purchasing one.

2.3.2 Surgical instruments

The surgical set for a microvascular anastomosis should be comprehensive (**Figure 3**), however the number of instruments on the table during the repair should be limited to the ones in use and best housed in a silicone-based beaker of water (**not** saline). There are a few essential instruments that one cannot do without: a good microsurgical needle holder, a straight and curved microsurgical scissors, a pair of fine jeweller's forceps (straight and angled) and a vessel dilator [1]. Obviously, it is essential to have a set of microvascular clamps, both single and double, with the latter optional to be mounted on a frame. I prefer the Acland clamps with a bar across (**Figure 4**), which helps to anchor the suture when repairing the vessel. I also like to use a blunt-tipped curved dissecting micro-scissors (**Figure 5**) for it does not damage the adventitial tissue and the all-important intima during vessel preparation.

2.3.3 Sutures

The main suture I use for arterial repair of less than 1.0 mm in diameter is the 10/0 by Ethicon; code W2870 – **Figure 6A**. This has a diameter of 1/1000 of an inch and a length of 13 cm which is one inflexion of the wrist across the operating field under the microscope. There is thus no delay in visualisation i.e. one does not have to move one's vision away from the Operating microscope or drop the needle and pick it up again because the suture is too long. For larger diameter vessels, 9/0 Ethilon may be used or even 8/0 but one has to balance between ease of performance and needle penetration causing leaks. For veins, being thin-walled and more

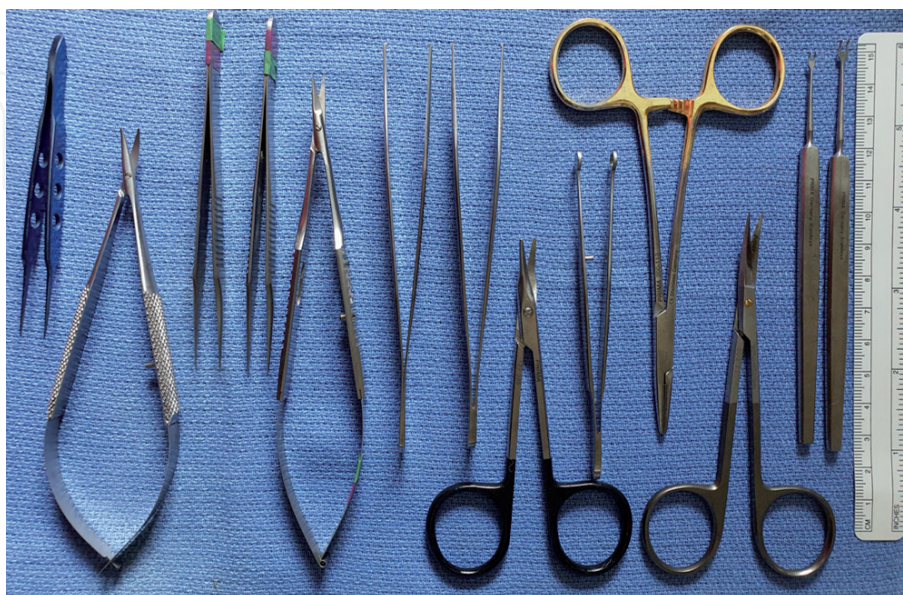

Figure 3. A basic set of microsurgical instruments. Note the fine double hooks on the right and a nerve holder next to the needle holder. The curved (blunt) micro needle-holder is the second from the left and is extremely useful. The instruments should be comfortable to hold and use.

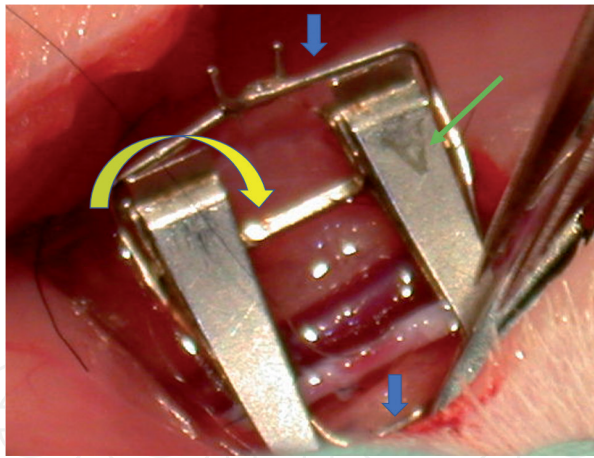


Figure 4.
Double approximator clamps. These thoughtfully designed clamps are mounted on a bar (yellow arrow), where one clamp is fixed whilst the other can slide. Surrounding it is a frame (blue arrows) which assists by allowing one to anchor the suture on to it. The pressure exerted by the clamps (A for artery – green arrow) is approximately 30 g [5, 8].




Figure 5.
Blunt tipped micro-scissors (curved). These are excellent for dissecting the soft tissue (adventitia) surrounding the vessels for the blunt tips have less chance of puncturing or damaging the vessel (see magnified inset). Also notice there is hardly a gap when the scissors close (useful feature).

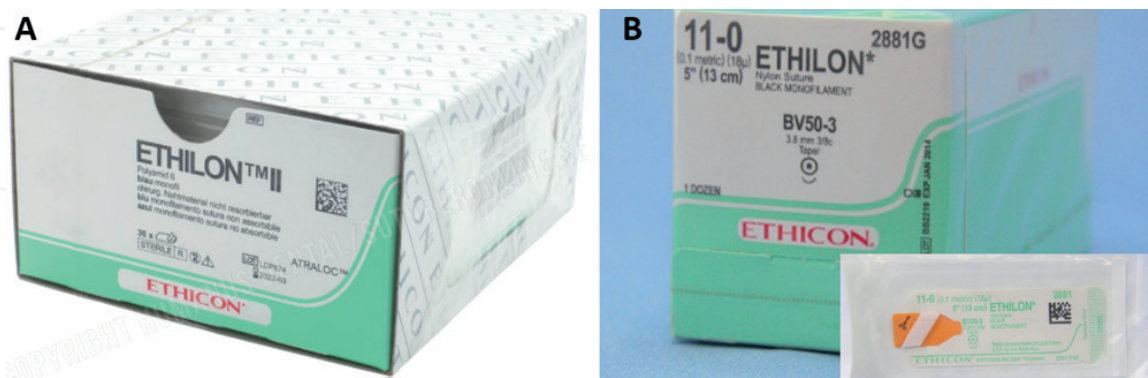


Figure 6.
Ethilon 10/0 and 11/0 sutures from ETHICON. A. The 10/0 suture is 1/1000th of an inch and 13 cm long (W2870, BV75-3 13cm black) B. The 11/0 suture (W2881G, BV50-3 13cm black as in package in inset) is of same length but finer, not visible to the naked eye. These are used at the fingertip for arteries (10/0) and veins (11/0).

challenging to handle, a 10/0 suture is practical. For those more experienced, 11/0 (**Figure 6B**) may be used, although not all theatres carry those. If it is anticipated that the patient's vessels are fragile or small, you may want to forewarn the Sister in charge to obtain the 11/0 sutures.

2.3.4 Other items

Drugs: Syringes of Normal Saline, heparinised saline (1000iu to 50 cc or 100 cc of saline) and Lignocaine 2% are prepared in 10 cc syringes with different coloured cannulas attached to them to differentiate them [3].

Background material (usually made of plastic and blue or green in colour) to place under the anastomosis site during the procedure can be cut to size and prepared. Micro arrowhead sponges to absorb blood and fluids from the surgical site, multiple small single or double skin hooks, white gauze as background around operative field and some folded towels to support one's wrist are all the minute details that will assist in the procedure going smoothly (**Figure 7**).

2.4 The patient

The ideal patient is young and healthy with no co-morbidities, but this is far from reality. For replantation surgery, one must weigh the pros and cons of doing the surgery, for life is more important than limb. Main areas to look out for are cardiac, respiratory, renal, hepatic and clotting functions. In the case of coronary by-pass surgery, obviously life is dependent on the microsurgical aspect, hence the technique must be perfect!

2.4.1 General condition of the patient (e.g. blood pressure)

Several factors affect immediate outcome: the blood pressure (BP) of the patient must be above 110/70 mmHg to ensure good flow through the anastomosed part, a low BP is prone to thrombus formation. Thus, even in a heparinised condition, one has to make sure thrombus formation is not due to inadequate perfusion.

Hypothermia is another cause for failure. One must ensure adequate warmth in the theatre, for the patient as well as the vessel. The anastomosed vessel needs to be kept warm with sterile warm bath or gauze moistened in warm water/saline. We place a bottle of saline in the microwave after unscrewing the cap, and heat it up, then use that. Other modalities include placing a sterile container in a hot water bath to heat up the saline within. Lignocaine 2% can be applied locally to dilate the vessel and reduce spasm after the repair has been completed.

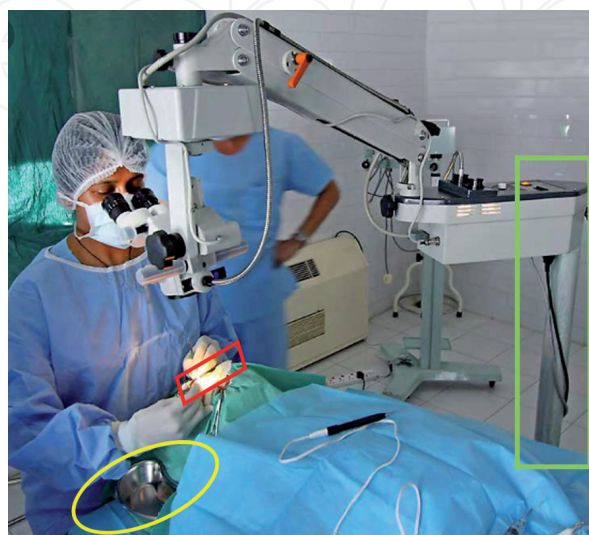


Figure 7.

The operative field. Note the microscope stand (green rectangle) is away from the field allowing the surgeon space to move to the left or right. The right hand should be supported on a roll of towels (yellow oval) and the white gauze (red trapezoid) keeps the background clear (needles visible).

2.4.2 Co-morbidities

The most commonly encountered co-morbidities are Hypertension and Diabetes. The former is not usually an issue, but the latter may well be. Peripheral vascular disease may affect anastomoses in the digital vessels and affect outcome. In central anastomoses, this may not be an issue, but control of the blood sugar level is mandatory in peripheral repair.

When there are multiple co-morbidities, peripheral repair or replantation or even central vascular repair becomes a challenge, not in the technical aspect, but in terms of long-term outcome, due to it being more likely for complications to develop. Where possible, these must be addressed and stabilised **prior to surgery**.

2.4.3 Skin conditions

When there are clues such the red streak sign (**Figure 8**), it means the digit is unfavourable for replantation because of intimal damage and blood leakage. Vein grafting could be attempted but, in the end, it still may fail because there is extensive inner damage.

Severe or dirty abrasion wounds need to be appropriately cleaned or brushed to avoid contamination of the field and delayed infection destroying the repair. Crush injuries cause damage beyond that which is visible and hence should be approached with respect [4].

2.4.4 Operative vessel conditions

If the digital vessel is found in a coiled state or there is a long trailing digital nerve (**Figure 8**), it means this was an avulsion injury (avulsed from the proximal aspect) and the vessel has suffered intimal damage. The entire length requires vein grafting which may leave some areas without a blood supply.

Locally, if there is damage to the vessel ends, these need to be trimmed to a level where they seem intact. On occasion a flap is to be placed for a defect caused by cancer: one must ensure that an irradiated vessel is not used for the anastomosis.

If there is discordance in the size of the donor and recipient vessel, a few tricks are available to harmonise the size mismatch – which needs to be done – to prevent turbulent blood flow [2].

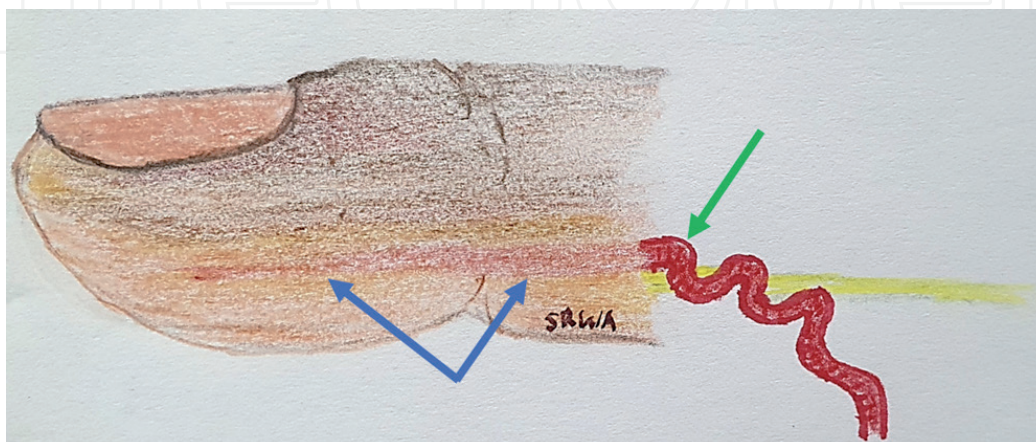


Figure 8.

Red streak sign. The blue arrows point to a faint red line that can be seen where the artery lies. Its intima has been stretched (avulsion injury) and the ecchymosis is due to leakage of blood from avulsed branches. The green arrow shows a red ribbon sign where the vessel is coiled up like a corkscrew due to the avulsion force tearing the layers of the vessel wall. Nerve and tendon may similarly have a long trail. These are poor prognostic signs.

2.4.5 Coagulopathic state

In the medical history it is important to note any features that may give rise to a hypercoagulable state (age, obesity, OCP intake, etc.) and the reverse where a patient is taking anti-coagulants or herbal supplements such as ginseng. In both cases extra steps need to be taken to ensure complications are kept to a minimum.

3. The technique

The initial debridement, dissection and macro fixation (bone, tendon and ligament repair) may be performed under tourniquet control, but the microvascular repair is usually performed without it [3]. The proximal vessel end is clamped (with a single clamp), the tourniquet is deflated (if it was up), and the vessel then tested for good flow by releasing the single clamp. If it has a good **spurt**, the repair is proceeded with. If it does not, the patient is then checked to have good hydration (BP), temperature and oxygenation. Locally, the wound is checked for damage to the proximal vessel or if there is a crush injury [4]. After ruling this out, and ensuring good flow, the proximal vessel end is clamped and flushed with heparinised saline to remove any clots and blood present. Enough length of the vessel is dissected to allow placement in the double clamps, so that a clear view of the end is seen enabling it to be prepared for suturing under magnification. The opposite vessel is similarly prepared and brought into view with the double clamp, making it clearer with a dark coloured background material (**Figure 9**). To achieve these “clear ends”, the vessels needs to be “freed” from the surrounding adventitial sheath that they are housed in. I prefer to use the curved dissecting micro scissors (blunt tips) to avoid damaging the vessel wall (**Figure 5**). Care must be taken not to leave any open branches (ligate or clip them) which will cause oozing later. An IV bolus of 1000 U of Heparin is given at this point. I have found this to be enough in the Asian setting. 3000–5000 U causes spontaneous bleeding and I prefer the lower dose.

Once the ends are placed in the clamps, if they are not smooth, they are cut using the adventitial scissors (straight) to provide a sharp clean edge for suturing. It has traditionally been taught to trim the adventitial layer using the sharp adventitia micro scissors, but the blunt-tipped curved micro-scissors allow closer




Figure 9.
Placement of vessel ends in double clamps. The two ends of the severed vessel are placed one end in each clamp and brought closer together until they are a vessel diameter apart.

dissection. Hold the vessel by the adventitial layer with the jeweller's forceps and go around the circumference taking off at least 2 mm from the edge (**Figure 10**). Finally, dilate both ends with a fine blunt-tipped vessel dilator to about 1.5 times its original diameter and hold it for 2 seconds [5]. This step is important because not only will it allow better visualisation, it will also stretch the smooth muscle of the intima paralysing it for a couple of hours, so it cannot go into spasm. If there is spasm, 1% or even 2% lignocaine can be applied to the vessel wall to alleviate it. The ends are then rinsed with Heparinised saline and the repair is ready to begin (**Figure 11**).

3.1 Arterial repair: end-to-end

For an end-to-end anastomosis, the vessel ends are usually aligned (and cut if they are prepared vessels) perpendicularly to the vascular axis. If one end is larger than the other, the smaller vessel may be cut at an angle to match the diameter size of the larger vessel (**Figure 12A**).

3.1.1 Triangulation method

In summary, the technique requires the circumference of the vessel wall to be divided into thirds and a stay suture placed at each point (**Figure 12B**). Subsequently sutures are placed between the three stay sutures and depending on the size of the vessel one, two or even three may be squeezed in.




Figure 10.
Trimming the adventitia. (A) The adventitia is pulled using a jeweler's forceps (left hand) and using the micro-scissors (right hand), it is nipped just at the vessel edge (media). (B) With the hole thus created, one blade of the scissors is used to enter, and then cut the adventitia all the way around the vessel, above and below. (C) End result.

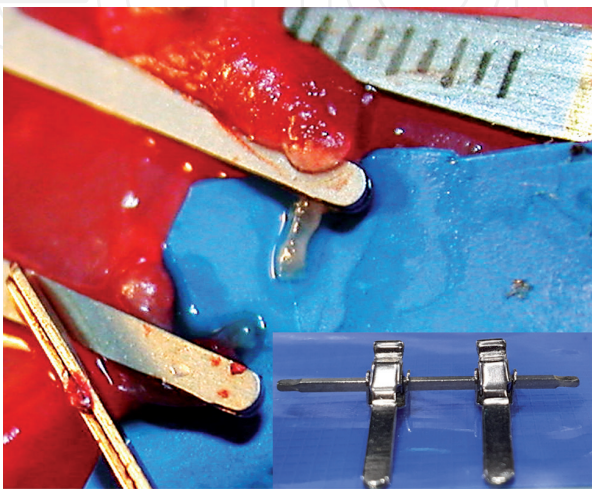


Figure 11.
Prepared vessels. After the adventitia is cleared, the vessels are almost translucent. A dark background and bathing them in saline facilitates repair. Inset: clamps facing the surgeon make certain repair techniques easier.

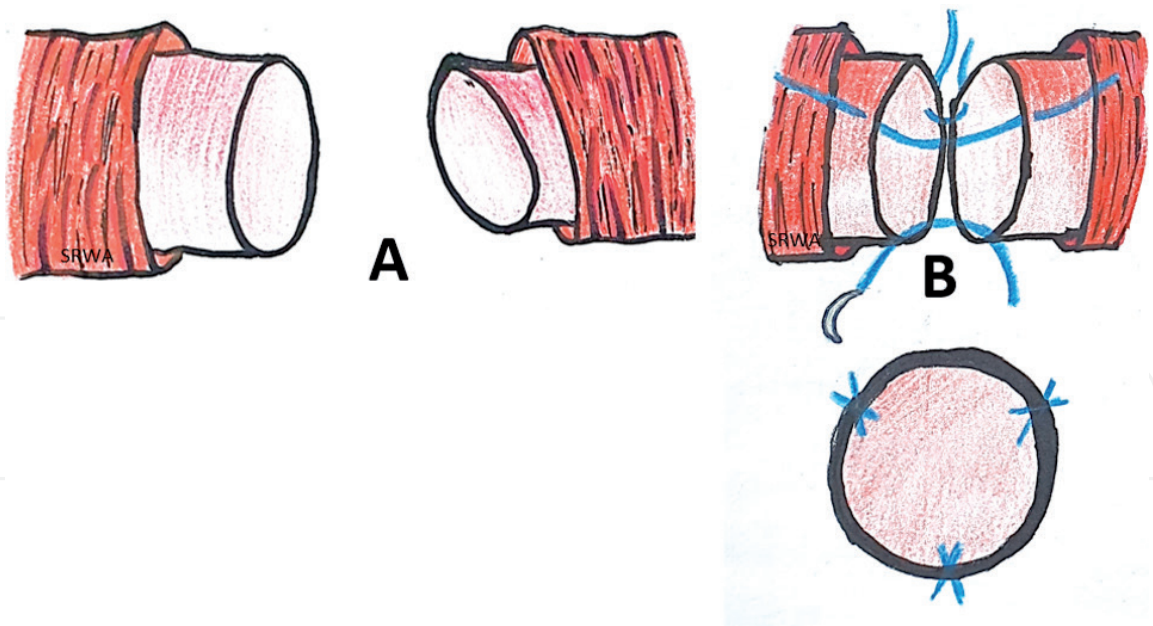


Figure 12.
Triangulation method of repair. (A) If the diameter of the vessel walls are grossly mismatched, the smaller one may be cut obliquely to increase the diameter size. (B) Three stay sutures are placed 120° apart as a guide.

The first stay suture is placed as in **Figure 13**. The needle tip is used to hook the adventitia and the left-hand forceps is placed gently just inside the lumen. The tip of the needle is then pushed into the lumen with the forceps acting as a counterforce [6].

The needle is then brought out and equidistant through the opposite lumen with the left-hand forceps again acting as a resistive force. The needle is pushed through in between the tips of the forceps and picked up in two or three steps gently ensuring the needle swage does not damage the vessel wall and that the thrombogenic cut ends are not inverted inside. Once tied, one thread is kept longer to wind around the clamp bar to stabilise the vessel ends. The first two stay sutures are difficult but especially important because they prevent the back wall of the vessel being caught up. The second suture should be performed in an easy position: on the upper surface of the vessel (**Figure 14**). Once these two are in, two or three intervening sutures are put in. Due to the tightness of the space sometimes it is difficult to place the last two sutures, so it can be modified by not tying the second last suture and continuing the stitching to the last one, leaving the needle in place (**Figure 15**). This allows good visualisation when inserting the needle for the last stitch, preventing catching the ‘back wall’. The second last suture is tied followed by the final suture.

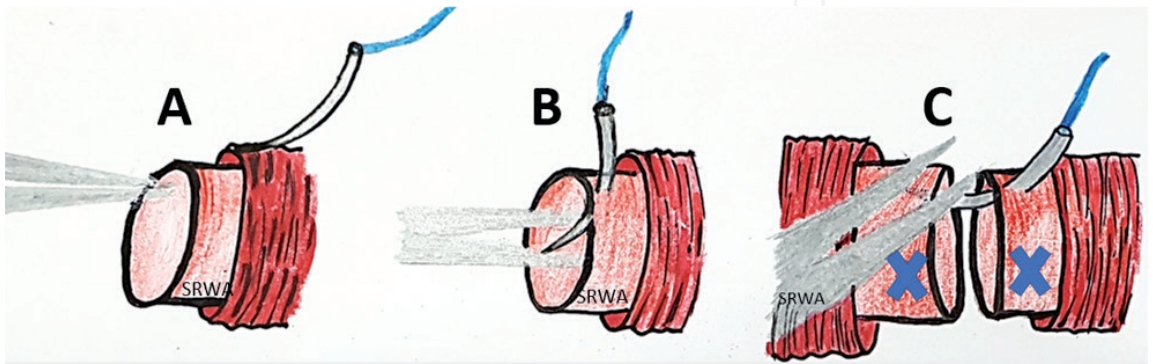


Figure 13.
First stay suture. (A) The adventitial layer is lifted with the tip of the needle and the forceps is gently inserted into the lumen. (B) The needle is then placed on the media and pierced through perpendicularly into the jaws of the forceps tips. (C) A bite on the opposite lumen is similarly placed with the aid of the forceps, this time from outside. x is where the second stay suture should be placed.

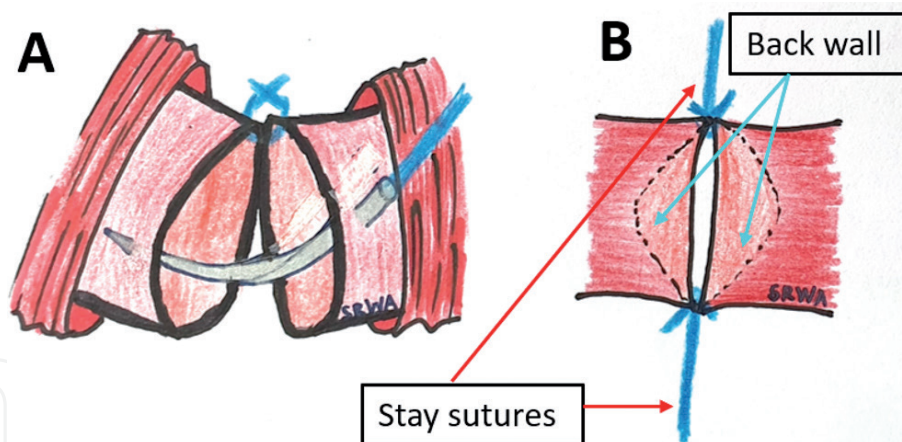


Figure 14.
Second stay suture. (A) The 2nd stay suture is put in at approximately 1/3 of the circumference of the vessel from the first one. It is more difficult to place than the first and is crucial to get it right. Therefore, it is placed in the easier position on the front wall. (B) The two stay sutures are tightened until the front edges approximate in one line.




Figure 15.
Double suture. Once the first pass of the needle is done, the knot is not tied and the needle is passed again between the first pass and the last tied suture. The needle is left in situ and the first pass knot is tied by grabbing the free end of the suture. Once this is tied, the needle is pulled through and the second knot is tied.

The double clamp may then be flipped 180° and the third suture placed with the back wall up, so it is not taken in with the suturing. The double clamps are moved slightly apart to apply tension on the vessel ends, separating them, allowing the sutured vessel wall to be seen through (**Figure 16**). One can check the repair done as well as safely proceed with the rest of the suturing. The third stay suture is placed equidistant from the other two main stay sutures. The suture is tied and again one end may be wound around the clamp bar to steady the vessel ends. The remaining two thirds of the vessel wall are sutured in a similar fashion. The vessel repair is now complete.

3.1.2 One-way-up

An extremely useful technique to master in situations where there is hardly any manoeuvrability (short vessel length and space) or space to flip the clamp or perform a vascular repair. Suturing is started at the most difficult point in the back wall and done using the inside out technique, moving upwards to easier points.

Place the double clamp with the tips facing you, this will reduce the amount of space they utilise and allow better visualisation (**Figure 11** – inset). Next, place the first suture at the far end of the back wall using the ‘inside out’ technique so that the knot is outside (**Figure 17A**). The needle is pushed from the outside of the left vessel



Figure 16.
Doing the back wall. Once the clamps are flipped and tensioned, the view of the sutured first segment can be seen and repair checked before proceeding.

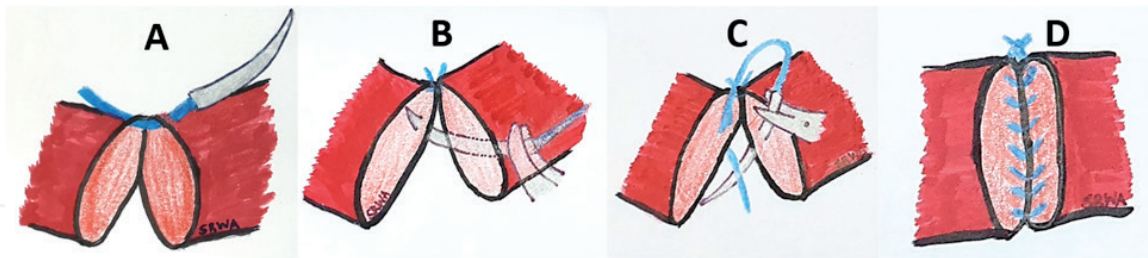


Figure 17.
One-way-up suture technique. (A) Take the first bite the furthest away from you. (B) The second bite is placed next to the first starting with the left vessel wall edge from outside-in. (C) The needle is then pulled out and inserted inside-out of the right vessel wall edge. (D) This is continued to the end till complete.

wall edge to inside the lumen and then it goes from the right vessel wall edge lumen to outside, where the knot is tied. Again, one end is kept long to assist in stabilising the vessel ends. The next suture is placed next to the first one, nearer to you in a similar outside in fashion (**Figure 17B and C**), until one moves upwards, then the suturing becomes easier and may be done in the usual way at the top side until complete (**Figure 17D**).

3.1.3 Continuous suturing

In the hands of a practiced surgeon, this suturing technique is rapid and gives good results; however a single mistake may prove costly, requiring the suturing to be redone and perhaps the vessel shortened! Also, a less experienced surgeon may

end up entangling the suture or pulling it too tight to cause purse-stringing. Thus, one should only attempt this when one's technique is smooth and well-orchestrated.

In the first few attempts at this technique, the surgeon should aim to divide the vessel end walls into two by putting in one stay suture each on opposing ends. The first stay suture is tied and the long end of the thread is fastened to the clamp bar (**Figure 18**). The opposite is similarly knotted and anchored, but the needled thread is not cut, being used to start the front side of the suturing. Three or maximum four passes with the needle are most likely required in a 1.0–1.5 mm diameter vessel starting with the first one as close as possible to the stay suture to prevent leakage. At the end, any slack in the continuous run is picked up and the suture is tied to the free end of one of the threads. The clamp is then flipped 180° and the needle used to continue suturing the opposing side. Care must be taken not to accidentally take the back-wall for the two are close. Once the other end is reached, the suture is tied to the long thread. The anastomosis is complete.

3.2 Arterial repair: end to side

This technique is an important one to have in the armamentarium. It allows a “way out” for example when there is a paucity of recipient vessels or if the flap donor vessel is too short. It does however carry a risk of size mismatch in terms of diameter and wall thickness. While the former may be somewhat addressed by an oblique cut or narrowing the larger vessel, difference in thickness is more difficult to deal with. The risk of turbulent flow must be born in mind [7].

3.2.1 Preparing the vessel

Ensure the donor vessel is of adequate length to reach the arteriotomy site without undue tension. It must be freed of adventitia at least up to 3 mm away and dilated to ease anastomosis. It is essential to ensure there are no kinks or twists in the donor vessel (artery or especially if it is a vein) because this may be disastrous once it is anastomosed!

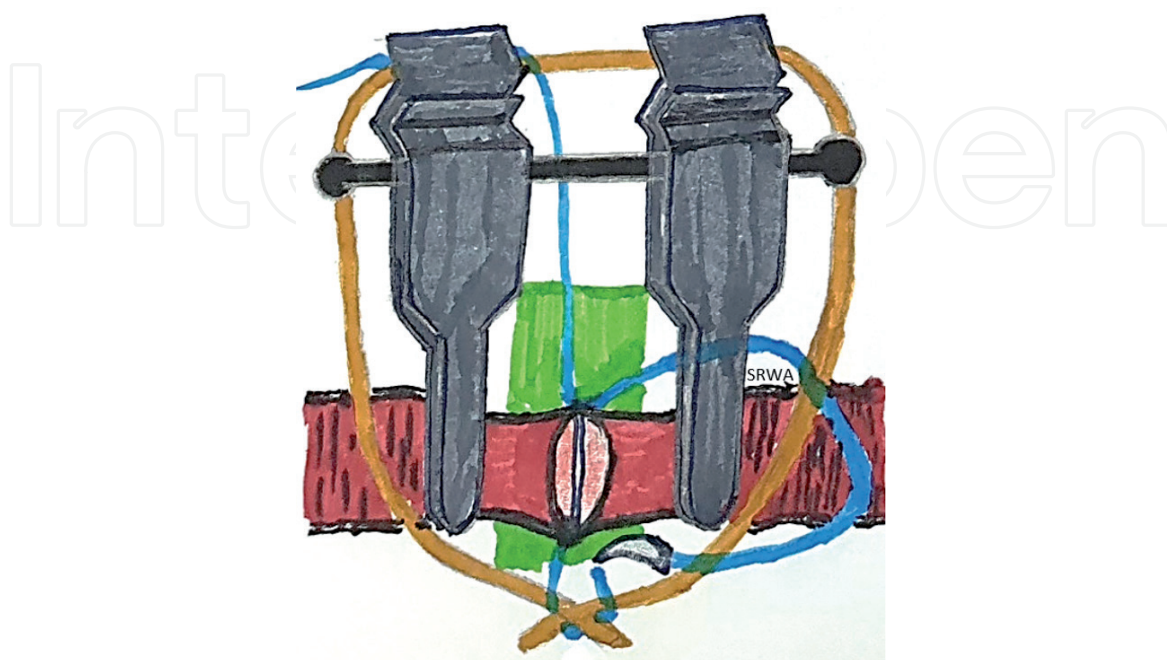


Figure 18.
Continuous suture technique. The vessel is locked by two stay sutures 180° apart. A continuous running suture is started from the distal side proximally.

3.2.2 Making the arteriotomy

Place the artery in double clamps. The arteriotomy site must also be similarly cleared of adventitia to a three times length of the proposed defect. Care should be taken while performing this and instruments must be sharp and well approximated.

A suture is placed at the exact site of the arteriotomy and tied off (**Figure 19A**). It is to be used as an anchor for the excised piece. It is lifted taut and using the left hand, a 45° angled cut is made (**Figure 19B**). The blood is washed out and the micro-scissors are switched to the right hand making a similarly 45° angled cut meeting the opposite side exactly [5].

3.2.3 Technique of suturing

Either one of the three suturing techniques described before (interrupted, one-way-up or continuous) can be used. The key is to start with the right hand on the right-hand side of the arteriotomy and place the suture outside in, then take the donor vessel from inside out (**Figure 19C**). It is a safe practice to place another stay stitch at 180° to stabilise the loose donor vessel. Similarly, a stay stitch mid-distance along on the back wall, can be placed to keep it out of harm's way (**Figure 19D**). The most important point to note in the suturing technique is to angle the stitches radially outwards to the arteriotomy to ensure an even spacing and place them as one would tighten nuts on the wheel of a tyre rim, progress from either side and moving to the centre to complete the anastomosis safely (**Figure 19E and F**).

3.3 Releasing the clamps

Once suturing is complete, the clamps are ready to be released but before doing that, make sure the blood pressure is well-maintained, a supply of lignocaine 2%, warm saline, clean gauze and heparinised saline are readily available [8]. Lignocaine is applied to the field and rinsed off with heparinised saline after 2 minutes. The double clamps are approximated, reducing tension on the repair and then the distal

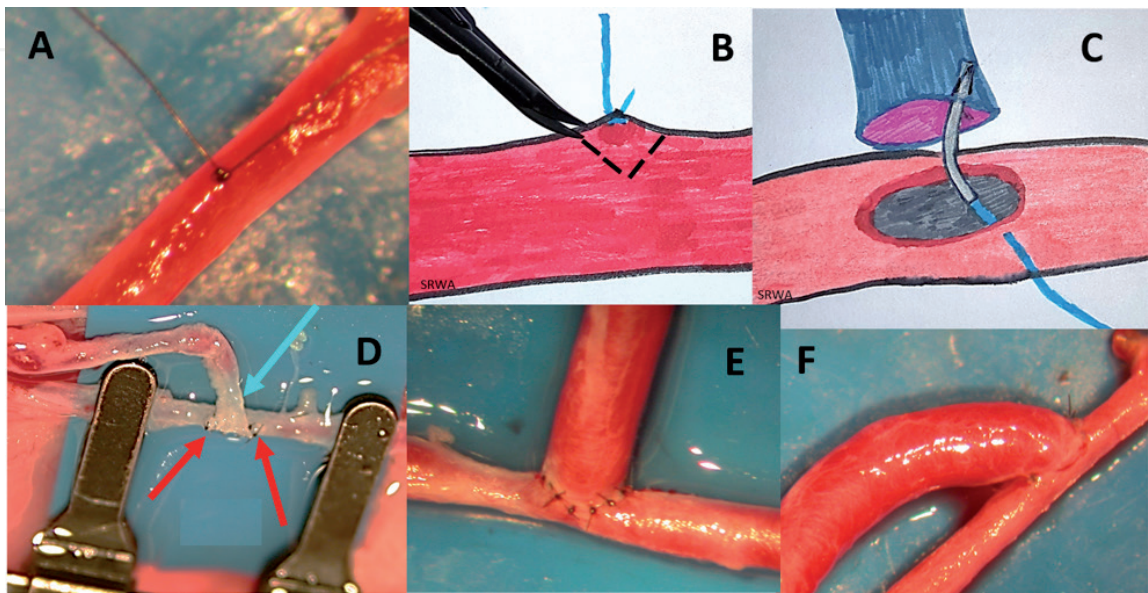


Figure 19. Performing and end-to-side anastomosis. (A) A suture is tied to the arterial wall (media). (B) A “v”-shaped cut is made. (C) The needle is pushed from the artery to the donor vessel, starting from the right side. (D) Two stay sutures at 180° (red arrows) stabilize the donor vessel; one more is put mid-way at the back (light blue arrow). (E) The sutures are placed radially and evenly. (F) Completed.

one is released first, followed by the proximal one. There will be bleeding, but take the clean gauze, soak it with warm saline and continuously apply light compression on the anastomosis. An infusion of intravenous Heparin is started at this point – I give 4000 U over 24 hours. Previously I would also start the patient on Dextran 40, but now rely on Osmofundin.

After 2 minutes, gently remove the gauze, and rinse with warm saline. If there is no more bleeding, that is good. If there is, you may need to reapply compression and repeat the steps. If it is still spurting, there is a gap which needs closure and this is done with the blood flowing because proximal clamping will result in thrombosis. An assistant provides constant irrigation under which the surgeon performs the suture. If done correctly, it is not difficult but needs intense focus and a steady hand.

3.4 Achieving patency

3.4.1 Evidence of patency

There are a few signs to suggest that the anastomosis is a success. One must learn to appreciate the finer points when trying to decipher the result:

Expansile pulsation means the diameter of the blood vessel increases and decreases with each heartbeat and there is patency of flow. **Longitudinal pulsation** if it is seen proximally, implies the blood is ‘hammering’ against a block (thrombus) or a wrongly sutured vessel.

Wriggling is movement seen in a curved vessel that is patent and pulsating. It is not observed in straight vessels.

3.4.2 Testing patency

There are several tests that can be performed to illustrate patency and Robert Acland has described them beautifully [5].

The Uplift test shows blood filling and emptying with the systolic and diastolic phases of the heart when an instrument placed under the vessel lifts it up, almost occluding it.

The Empty-and-refill test if done gently provides the most conclusive evidence of patency. A fine curved jeweller’s forceps is used to gently occlude the vessel *distal* to the repair. Another pair of forceps is then used to milk the blood in the vessel *distally* and finally the proximal forceps is released (**Figure 20**). If the emptied vessel refills promptly, the repair is patent.

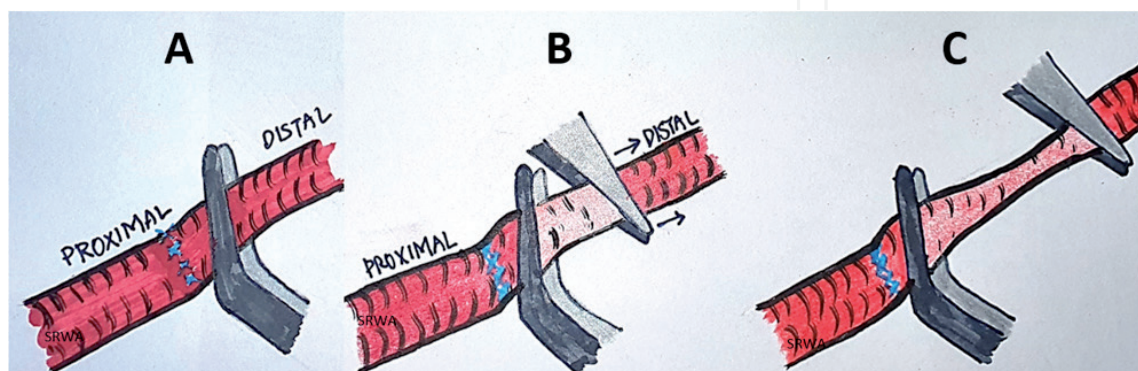


Figure 20.

Empty-and-refill test. (A) An angled forceps is used to hold the vessel distal to the anastomosis. (B) A jeweler’s forceps is then used to gently occlude the vessel distal to this. (C) The jeweler’s forceps is moved in a distal direction. Upon release of the angled forceps, the vessel will fill up with blood.

3.5 Venous repair: end to end

Repairing a vein is not for the novice and is much harder than an artery. The most obvious reason for this is that the walls are floppy and much thinner, so it is difficult to see the edge after dissection. The other reason is that veins have less adventitial tissue that is rather adherent to its walls, making it challenging to dissect. They are hence also easier to damage unless handled with meticulous care and technique. Last but not least, the slower blood flow makes them prone to thrombosis and even slight damage to the intimal walls kicks off the cascade.

3.5.1 Dissection of the vein

The vascular sheath is flimsy but adherent. Pick it up (making sure one does not damage the venular wall) with a good pair of jeweller's forceps and holding the dissecting (blunt) micro-scissors parallel to the vein, make a hole in it. Then slide the scissors into the space and dissect along the wall of the vein carefully, making sure not to pull out any tributaries with force. These should be ligated with 10/0 nylon or cauterised very carefully. Once released, the vein ends are brought together and placed in the double clamp. The job is made easier if there is an underlying piece of background material and the operative field is flooded with saline or Ringer's lactate. A fine vessel dilator should be used to dilate the vein in two or three directions. It may be difficult to locate the lumen initially, but once this is done, the vein takes a more recognisable form and the lumen becomes visible.

3.5.2 Suturing technique

In view of the thin walls, there is a tendency for the vein edge to roll inwards and mistakes can be made in taking stitches. Extra precaution should be exercised and if there is any doubt, do not proceed until it is cleared. The first two stay sutures are the most crucial and should be done while bathed in saline. The intermediate sutures may be placed slightly further apart (double the distance) than in an artery because venous pressure is lower.

3.5.3 Checking patency

Once the repair is complete, the **distal** clamp is released first to flood the repair site and the vessel dilates immediately. Immediate release of the proximal clamp should show a good flow.

A good result will reveal a similar diameter and colour both proximal and distal to the anastomosis. Patency is confirmed by the uplift test. Flow is tested from distal to proximal (along the direction of flow) across the anastomotic site. If there is a block, it will bulge at the anastomotic site and the proximal diameter will be smaller, while the blood in the distal part will progressively become darker.

3.6 Interpositional vein graft

This procedure is more difficult than a straight-forward venous anastomosis and has multiple steps: getting the arterial defect ready, harvesting a vein for grafting using a meticulous dissection and anastomosing both ends of the graft. It is a necessary skill to acquire for all microsurgeons.

3.6.1 Getting the arterial defect ready

During emergency procedures and sometimes even in elective surgeries, the arterial conduit is damaged and needs replacement in part or more. This is where the interpositional vein graft comes in useful. Most times the vein can be harvested from an adjacent site (size is matched) or a distant one (saphenous in the leg). In all instances, the defect must be measured in order to be bridged. Both the arterial ends are dissected free of adventitia and clamped with single clamps in preparation to receive the vein graft.

3.6.2 Harvesting the vein graft

This is an important step in the procedure and should not be taken lightly. Exact measurement and harvest of the vein graft is to be done by a competent surgeon very carefully. A slightly longer graft is taken in case damage is done to the ends. Too long a graft will cause tortuousness and kinking, while a shorter graft will tend to stretch and tear or leak.

A length of vein corresponding to the arterial defect is outlined (this is measured before the vein is cut) and using the same meticulous dissection techniques described in Section 3.5, the vein graft is extracted after applying clips (or ligating) both ends. Blood is removed from the vein manually and by irrigation. It is placed in the approximator (double) clamp on one side and the anastomosis is ready to begin.

This is started on the right side (for right-handed surgeons) because the artery gives a firm attachment point, and this is needed because the vein graft is free-floating making it difficult to put a suture through. A piece of coloured paper may be used to assist as background material adding oblique cuts to it, so it can help to hold sutures in place while repair is in progress [5].

The second anastomosis is started after the vein graft is checked to avoid any twisting (this will cause kinks and blockages) and that the double clamp is not straddling the repair site.

3.7 Pearls (positive practice)

There are many pearls of wisdom and these are best summarised in tables according to the procedure that is being performed. **Table 1** describes general rules while **Tables 2** and **3** enumerate good practices for arterial and venous repair respectively.

Surgeon	Patient
<div>1. Pre-operative preparation (well-rested, hydration, nutrition and self-relief).</div> <div>2. Avoid heavy activity the day prior (24 hours).</div> <div>3. Do not alter (maintain) caffeine intake.</div> <div>4. Prepare for (elective) surgery mentally.</div>	<div>1. Ensure good hydration.</div> <div>2. Control of medical conditions (co-morbidities) if any.</div> <div>3. Peri-operative antibiotics.</div> <div>4. Review imaging and investigations.</div>
Operation theatre	Amputated part
<div>1. Adjust lighting.</div> <div>2. Maintain OR temperature.</div> <div>3. Ensure good positioning of machines and instruments.</div> <div>4. Make sure surgical stool and diathermy foot pedal are in right position.</div> <div>5. Hands should be well-supported with towels.</div> <div>6. Place clean gauze as operative field background.</div>	<div>1. Beware of red streak sign.</div> <div>2. Look for coiled vessels.</div> <div>3. Look for trailing nerves and tendons.</div> <div>4. Meticulous pre-dissection.</div> <div>5. Ensure good spurt of arterial blood.</div>

Table 1.
Pre-operative preparation. This table summarises the various measures the surgeon needs to take prior to starting the surgery to ensure its success.

Positive practice points	Things to avoid
1. Meticulous handling of soft tissues	1. Tugging at unyielding tissues.
2. Place (dark) background under vessel ends to see clearly	2. Grabbing the media (full thickness).
3. Gentle dissection to skeletonise and isolate vessel	3. Performing an action without a clear view or in a pool of blood.
4. Methodical and careful removal of adventitia	4. Using clamps larger than required.
5. Rinse blood vessel and dilate it.	5. Applying the diathermy to the main vessel.
6. Approximate clamps	

Table 2.
Tips to achieve a good arterial repair. Points to remember when performing an arterial repair.

Positive practice points
1. Very gentle dissection and minimal handling of vein.
2. Allow the vein to ‘rest’ after dissection then place it in the clamp.
3. Flush out all the blood, for any standing blood will cause thrombosis.
4. Dilate the vessel with a single prong, then both prongs of the dilator in different directions.
5. After dilation, bathe in lignocaine then apply the clamps.
6. Perform a meticulous anastomosis with evenly placed sutures.
7. Bathe in lignocaine (2–10%) before releasing the clamps.
8. After releasing clamps, allow the blood to flow for a few minutes.
9. If arterial and venous anastomoses are done simultaneously, release the artery clamps just before the vein.
10. If there is a leak, the vein needs to be re-clamped and repaired after the blood is flushed out.

Table 3.
Tips to achieve a good venous repair. Veins need more care in their handling and rest periods in between steps. A keen eye will prevent mishaps such as catching the back wall inadvertently.

3.8 Pitfalls (negative practice)

While there are an enormous number of things that can go wrong with even the most experienced surgeon, I have tried to list the most common ones here in order as they appear in the text: Various arterial repair techniques of increasing difficulty (Tables 4 and 5), venous anastomosis (Table 6) and grafting (Table 7) and finally arteriotomy and end-to-side repair (Table 8).

Positive practice points	Negative actions to avoid
1. Have a clear operative field of vision and good access	1. small and inadequate wound, poor retraction leading to poor visualisation
2. Mobilise a good length of vessel	2. Trying the anastomosis with short vessel ends
3. Properly trimmed adventitia and clean vessel ends	3. Persisting in the anastomosis when view is obstructed or when facing trouble.
4. Comfortable spacing of clamps	4. Excessive traction (clamps too far apart) or obscured view of lumen (clamps too close).
5. Divide the vessel into equal thirds and place sutures equidistant from both vessel ends.	5. Asymmetrical placement of sutures with bad coaptation of vessel ends
6. Clear view and sure of needle placement.	6. Struggling with needle then catching the back wall.

Table 4.
Arterial repair technique: Triangulation. The column on the left lists the positive actions to be practiced while the column on the right, the negative results thereof.

One-way-up technique
1. Have the tips of the clamps facing you. 2. Make the first stitch furthest away from you 3. Start with the difficult side first and place sutures on either side of the first stitch 4. Avoid entangling your suture when placing the second half of the stitch 5. Work your way up carefully
Continuous suture technique
6. Divide the vessel ends into equal halves 7. Do not use too long a suture to prevent entanglement 8. Keep the stitches evenly placed and pull the thread to evenly tighten it at the end 9. Make sure the knots are squarely tied and secure.

Table 5.
Pointers in performing arterial repair. Tips to ensure good results in the two other (more challenging) techniques of arterial repair.

1. Aggressive dissection and 2. Incorrect handling of the vein with forceps, scissors or bipolar coagulator. 3. Frequent picking up and letting go of the vessel wall. 4. Suturing inverted vessel edges. 5. Picking up the back wall.
--

Table 6.
Pitfalls in venous anastomoses. These are the common mistakes made when anastomosing veins. Extra care needs to be taken in handling them because they tend to thrombose easily.

Pearls	Pitfalls
1. Ensure right diameter of the vein graft 2. Measure the length of graft before harvesting. 3. Take the vein graft with a cuff of fat around it. 4. Lay the vein graft straightened out (untwisted) with both sides in clamps. This avoids twisting with no blood in graft, while ensuring its visibility. 5. Remember to reverse the vein graft for arterial flow to accommodate for the valves.	1. Suturing two vessels of mismatched diameters 2. The vein graft shortens after harvest! 3. A skeletonised graft is more susceptible to damage by the forceps. 4. Not checking for a twist before the second anastomosis may result in unnecessary anguish! 5. Using suction while graft is in the operative field is dangerous! Clamps also help avoid it being sucked in. 6. Getting the clamps in the way of the anastomoses may necessitate redoing it!

Table 7.
Pearls and pitfalls of vein graft harvest and anastomosis. Performing the right steps in the correct order not only increases chances of success but also reduces time and effort taken.

1. Perform the arteriotomy in the steps mentioned in the text. 2. Angle the adventitia scissors at 45° to make the cut. 3. Remember to reverse the vein graft and place it straightened out (while still in the clamps). 4. Start with the arterial wall from outside in and take the vein inside out. 5. Place a second stitch at 180° to the first. 6. Place the sutures radially spaced and not longitudinal to the arteriotomy 7. Put in a stay suture on the back wall mid-way between these first two stitches. 8. Any technique may be used to perform the anastomosis. 9. Keep a short leash on the suture length 10. If using continuous suturing, tighten as you move along.

Table 8.
Perfecting end-to-side repair. Pointers to bear in mind when performing this in addition to what has been mentioned earlier.

4. Conclusion

In conclusion, microsurgical anastomosis is a fine art that needs practice, practice, practice to make perfection. There is absolutely no room for error. There are numerous techniques that can help the novice, though and repetition will improve the outcome. Good instrumentation, the correct suture materials and an excellent microscope will help tremendously. A number of items may be modified without sacrificing the result and some of these ideas may be used in less developed countries.

Acknowledgements

I would like to thank Intechopen for their generosity in helping with the funding of this chapter.

Conflict of interest

There is no conflict of interest to be declared.

Author details

Sharifah Ahmad Roohi

Hand and Upper Limb Centre, Pantai Hospital, Kuala Lumpur, Malaysia

*Address all correspondence to: roohihandsurgery@gmail.com

IntechOpen

© 2020 The Author(s). Licensee IntechOpen. This chapter is distributed under the terms of the Creative Commons Attribution License (<http://creativecommons.org/licenses/by/3.0>), which permits unrestricted use, distribution, and reproduction in any medium, provided the original work is properly cited. 

References

- [1] Cobbett JR. Microvascular surgery. In: Birnstingl M, editor. *Peripheral Vascular Surgery: Tutorials in Postgraduate Medicine*. Vol. 3. London: William Heinemann Medical Books Ltd; 1973. Ch. 17. pp. 384-391
- [2] Rahman MN, Shahrman AB, Za'aba SK, Roohi SA, WAN K, Ayob MN, et al. Computational fluid dynamic analysis of the effect of kink conduit in microvascular vein grafting. *International Journal of Mechanical and Mechatronics Engineering (IJMME)*. 2012;12(6):53-59
- [3] Godfrey AM, Lister GD, Kleinert HE. In: Birch R, Brooks OM, editors. *The Hand* 4th ed. (Rob and Smith's Operative Surgery). London: Butterworths; 1998. pp. 85-91
- [4] Roohi SA, RWH P. Crush injuries of the hand part II: Clinical assessment, management and outcomes. In: Salgado AA, editor. *Essentials of Hand Surgery*, First on Line Edition. Mexico City: InTechOpen; 2018. DOI: 10.5772/intechopen.78298
- [5] Acland RD, Sabapathy SR. *Acland's Practice Manual for Microvascular Surgery*. 3rd ed. Mumbai, India: Indian Society for Surgery of the Hand; 2008
- [6] Butler CE, Adelman DM. Principles of microsurgery. In: Thorne CH et al., editors. *Grabb's Plastic Surgery*. 7th ed. Philadelphia: Lippincott Williams & Wilkins; 2014
- [7] Lee HL, Shahrman AB, Yaacob S, Zuradzman MR, Khairunizam WAN, Zunaidi IB, et al. In vitro evaluation of finger's hemodynamics for vein graft surveillance using electrical bio-impedance method. *Australian Journal of Basic and Applied Sciences*. 2014;8(4):350-359
- [8] Richard M, Lewis GJ, Levin S. In: Hunt TR III, Wiesel SW, editors. *Operative Techniques in Hand Wrist and Forearm Surgery*. Philadelphia: Lippincott Williams & Wilkins; 2011. pp. 796-807