

We are IntechOpen, the world's leading publisher of Open Access books Built by scientists, for scientists

6,900

Open access books available

185,000

International authors and editors

200M

Downloads

Our authors are among the

154

Countries delivered to

TOP 1%

most cited scientists

12.2%

Contributors from top 500 universities



WEB OF SCIENCE™

Selection of our books indexed in the Book Citation Index
in Web of Science™ Core Collection (BKCI)

Interested in publishing with us?
Contact book.department@intechopen.com

Numbers displayed above are based on latest data collected.
For more information visit www.intechopen.com



Nailfold Capillaroscopy in Rheumatic Diseases

Abhishek Patil and Isha Sood

Abstract

Nailfold capillaroscopy (NFC) has developed into an indispensable tool for rheumatologists in the evaluation of rheumatic diseases. It offers various advantages in being rapid, noninvasive, and inexpensive. With NFC we are able to visualize the microcirculatory changes in the nail beds. These changes are key to the pathogenesis of connective tissue diseases such as systemic sclerosis. Hence NFC helps in early diagnosis of various connective tissue diseases. There is a lack of standardization in the techniques used and various capillary parameters studied, which could lead to variation in the reporting of the parameters studied. In this chapter we shall try to highlight the most common parameters studied in capillaroscopy and its utility in various connective tissue diseases.

Keywords: scleroderma, myositis, SLE, patterns

1. Introduction

Nailfold capillaroscopy (NFC) is a noninvasive bedside tool for the assessment of capillary microcirculation and its changes. The history of this technique dates back to over four centuries, with J C Kohlhaas's first description of capillary loops in nailfold using basic optical magnification. However, the utility of NFC in rheumatological diseases came to the forefront after the studies of Maricq and Le Roy in 1973 [1]. They systematically described the capillaroscopic patterns in patients of rheumatoid arthritis, systemic lupus erythematosus (SLE), and scleroderma (SSc) using a wide-field stereomicroscope of 12× magnification. From then on, NFC has evolved to be an indispensable tool for the rheumatologists in the evaluation of patients with connective tissue diseases. NFC is now included in the recent American College of Rheumatology/European League Against Rheumatism classification criteria for SSc [2]. In the current chapter, we shall highlight the physiology, preparation, instruments, and NFC parameters in various rheumatic diseases including SSc.

2. Principle

Microcirculation consists of arterioles, capillaries, and venules. The main function of the microcirculation is capillary exchange—delivery of oxygen and nutrients to tissues and removal of carbon dioxide and waste products. In most areas of fingers, capillaries are oriented perpendicular to the skin surface and are thus not amenable to visualization. In the nailfold areas, however, they become parallel to the skin surface and thus are observable in full length in the distal row.

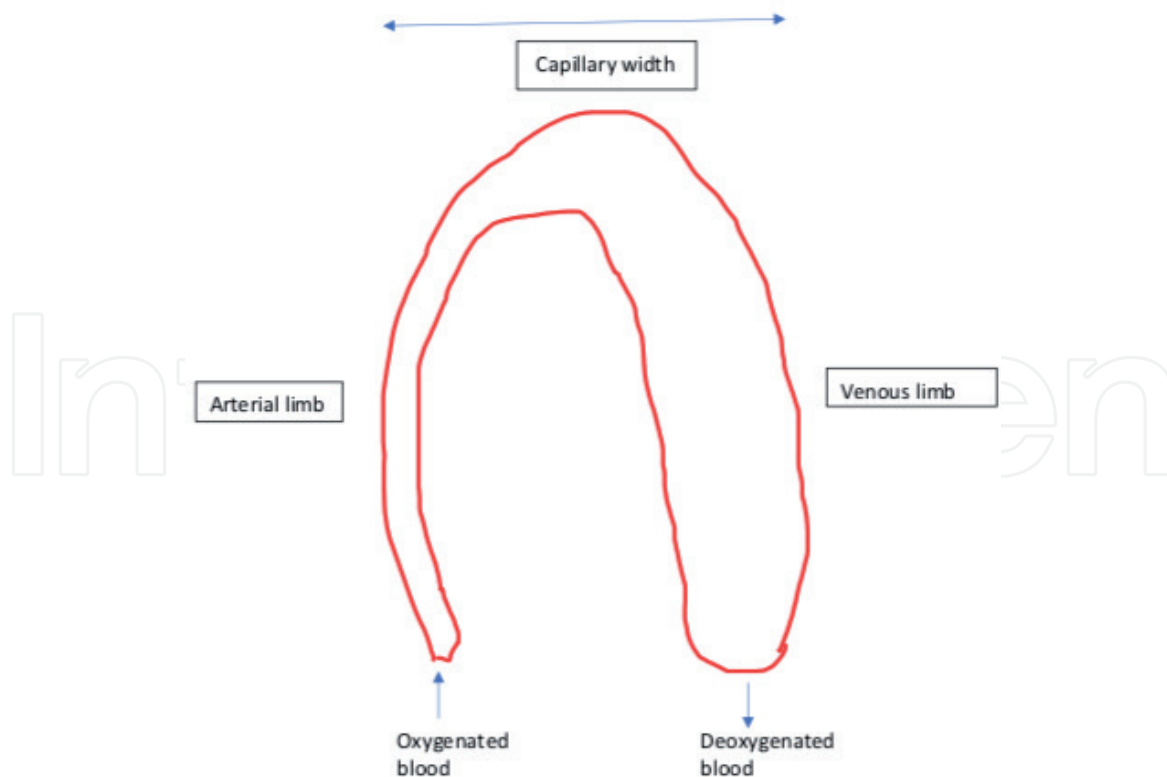


Figure 1.
Schematic representation of a capillary loop.

Usually there are one to three capillaries in each dermal papilla [3]. Hence most of the examination of the capillaries is concentrated on this region. Each capillary loop consists of an arterial and a venous limb with the latter being wider (**Figure 1**). With the help of various instruments, we are able to visualize the column of blood within these capillaries. The density and morphology of these loops help in the diagnosis and follow-up of patients with rheumatic diseases. We shall address these in the below mentioned sections.

3. Instruments used in capillaroscopy

The instruments utilized for the study of nailfold capillaries have evolved over time, from stereomicroscope to the high magnification nailfold video capillaroscopy (NVC).

3.1 Wide-field stereomicroscope

It is the original technique utilized by Maricq et al. [1] and employs about 20× magnification for the evaluation of capillaries. It provides the panoramic view of nailfold capillaries and makes possible for the assessment of qualitative and quantitative parameters (**Figure 2a**). However, the instrument is expensive and non-portable, and access is limited to special interest groups.

3.2 Ophthalmoscope and dermatoscope

These portable instruments provide images with lower magnification and quality. They are best utilized as bedside evaluation tools for the clinicians. Despite their lower cost, they lack the image storing and processing capabilities.




Figure 2.
Various instruments used in nail fold capillaroscopy; (a) stereomicroscope, (b) microscope and (c) nail fold videocapillaroscope.

3.3 Microscope

It usually combines optical microscope and digital video camera connected to a computer (**Figure 2b**). It's a handheld, inexpensive tool for the evaluation of capillary parameters. The instrument can be used in varying magnifications from $200\times$ to $600\times$. In view of its portability and low cost, its best suited to the busy outpatient settings.

3.4 Nailfold videocapillaroscope (NFVC)

This technique provides high magnification ($200\times$ to $600\times$) and, with the aid of specific software, allows a precise measurement of capillaroscopic parameters (capillary length, width, and density) (**Figure 2c**). The disadvantages include high cost and loss of panoramic view of the nailfold.

4. Procedure of nailfold capillaroscopy

The procedure followed for nailfold examination is similar for all of the above-mentioned instruments. The underlying principle is to minimize the variability in tissue perfusion due to the following testing conditions:

- i. Patient is instructed to avoid smoking and caffeine for at least 6 h prior to the procedure.
- ii. He/she should be explained about the procedure.
- iii. He/she is allowed to get acclimatized to room temperature for about 15–20 min.
- iv. The skin to be examined is cleaned using soap and water.
- v. Then a drop of skin-friendly oils such as cedarwood oil, olive oil, peanut oil, etc. should be placed on the nailfold and observed under NFC. It should be

- used in optimum quantity, and too little or too much of the oil may result in suboptimal resolution.
- vi. A series of 4–12 overlapping images are taken in each finger to complete the procedure.
 - vii. Conventionally the medial four fingers of both the hands excluding the thumb are evaluated.
 - viii. Fingers which have sustained a recent injury are excluded from the analysis [4].
 - ix. Usually the fourth and fifth fingers provide the maximum information due to the transparent nature of the skin in them.
 - x. The parameters evaluated include capillary density, morphology, and hemorrhages. The same are discussed in detail below.

5. Capillary parameters

5.1 Capillary shape

A normal capillary has a safety pin or inverted U appearance with an arterial and venous limbs. The venous arm is larger than the arterial arm. However, the capillary loops may exhibit morphological variations, such as crossed or meandering loops (with intertwining). Bushy or excessively tortuous capillaries are seen in scleroderma, mixed connective tissue disease (MCTD), and dermatomyositis.

5.2 Capillary density (CD)

It is the number of capillaries in 1 mm length of the distal row of each finger or toe. A capillary loop is considered to be in the distal row, if the angle between the apex of that capillary loop and the two adjacent capillary loops is more than 90° [5]. Capillary density of more than 9 is usually taken as normal, albeit age-related changes in the parameter [6]. A mean CD for each finger is calculated by analyzing four fields in the same.

5.3 Capillary width

Literature has used different parameters while reporting on capillary width. Some studies have reported on the width of the apical loop, arterial limb, and venous limb, while the others have reported on the whole width of capillary loop (**Figure 3**). Here we shall consider the whole width of capillary loop while describing the dimensions. The normal capillary loop diameter ranges from 25 to 50 μm in adults. A capillary width of more than 90 μm is generally taken as an enlarged loop [7]. Uniformly enlarged capillaries are typically seen in SSc, dermatomyositis, and mixed connective tissue disease. The term giant capillary is used to denote a capillary diameter of more than four times the normal size.

5.4 Intercapillary distance (ICD)

It is the distance between apical tips of two capillaries and varies between 96 and 166 μm [8]. Avascular areas are defined as the areas in which two or more

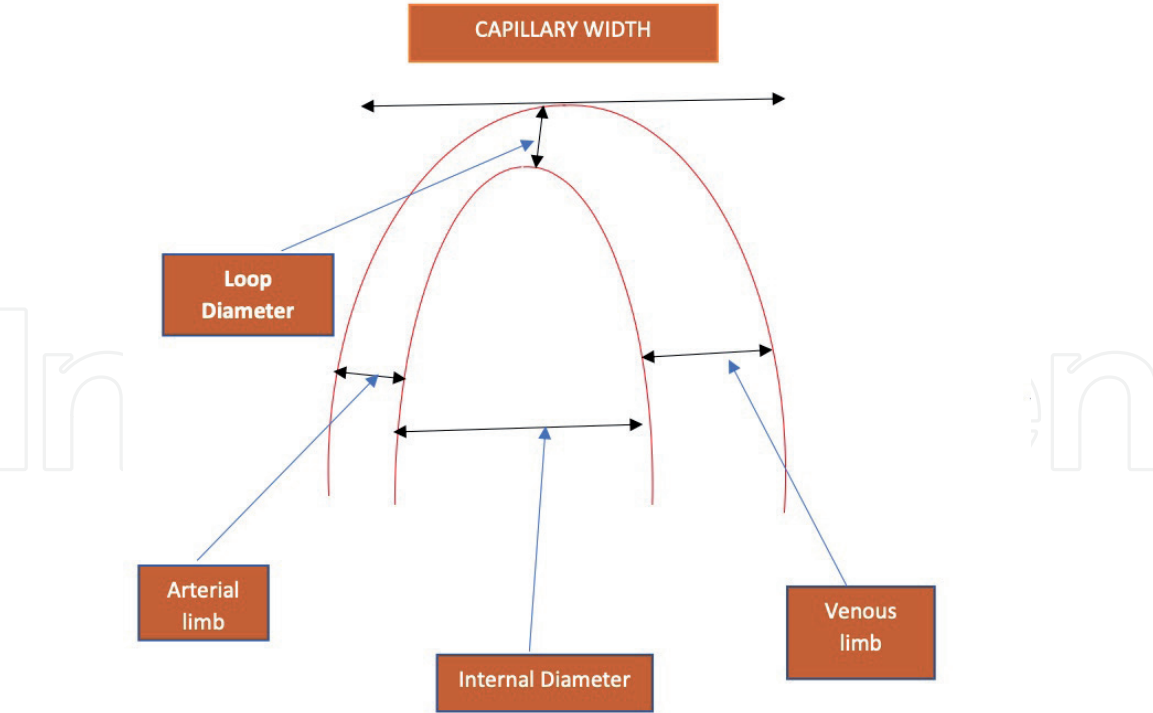


Figure 3.
Schematic representation of various capillary loop dimensions.

capillaries are missing as compared to the other areas with low capillary density [9]. Other authors term an ICD of more than 500 μm as avascular areas [8]. These are typically seen in connective tissue diseases and are not associated with nonimmune disorders.

5.5 Microhemorrhages

These are reddish brown punctate lesions found in the nail bed. These represent early vascular damage and are most prominently visualized in connective tissue diseases such as scleroderma.

6. Utility of capillary microscopy in rheumatology

Rheumatologists frequently encounter situations in which patients present with complaints such as arthralgia, Raynaud's, lung disease, etc. However, many of these patients lack the typical clinical features to classify as a definite systemic connective tissue disease such as scleroderma, MCTD, and others. In such scenarios, NFC can serve as a useful modality in differentiating patients with and without connective tissue disease. The common nail abnormalities encountered include dilated loops, microhemorrhages, and capillary dropouts. Here we shall study the NFC abnormalities encountered in patients with rheumatological diseases.

6.1 Raynaud's phenomenon

Raynaud's phenomenon is an exaggerated responsiveness of the vasculature to cold and other stimuli. It can be primary (in absence of an associated disorder) or secondary (associated with a systemic disease such as scleroderma). NFC can serve as a useful tool in distinguishing primary from secondary Raynaud's. Mannarino et al. [10] described three capillaroscopic patterns in patient with

Raynaud's—normal, borderline, and abnormal patterns. Authors proposed the borderline NFC abnormalities (composed of shorter and more tortuous capillaries) are due to the long-standing vasospastic reaction of the Raynaud's itself. Of interest though is the finding of abnormal capillaroscopic pattern in 8/44 patients with idiopathic Raynaud's phenomenon. These are the group of patients who might be at a higher risk for developing connective tissue disease on follow-up. On the other hand, the absence of NFC abnormalities in a patient of Raynaud's is also helpful in the exclusion of scleroderma [11].

7. Capillaroscopy in systemic sclerosis

Three capillaroscopic patterns have been described in SSc: early, active, and late [12].

SSc-early pattern: it is characterized by the presence of few giant capillaries, few capillary hemorrhages, relatively well-preserved capillary distribution, and no evident loss of capillaries (**Figure 4**).

SSc-active pattern: in active pattern frequent giant capillaries are seen with frequent capillary hemorrhages, moderate loss of capillaries, mild disorganization of the capillary architecture, and mild ramified capillaries (**Figure 5**).

SSc-late pattern: in late pattern irregular enlargement of the capillaries with few or absent giant capillaries and hemorrhages are seen. There is severe loss of capillaries with extensive avascular areas, disorganization of the normal capillary array, and ramified capillaries (**Figure 6**).

7.1 Nailfold capillaroscopy and correlation with organ involvement

There have been several studies which tried to look for correlation of capillaroscopic parameters with organ involvement in systemic sclerosis. Though the results from these studies have been variable, marked skin involvement and the presence

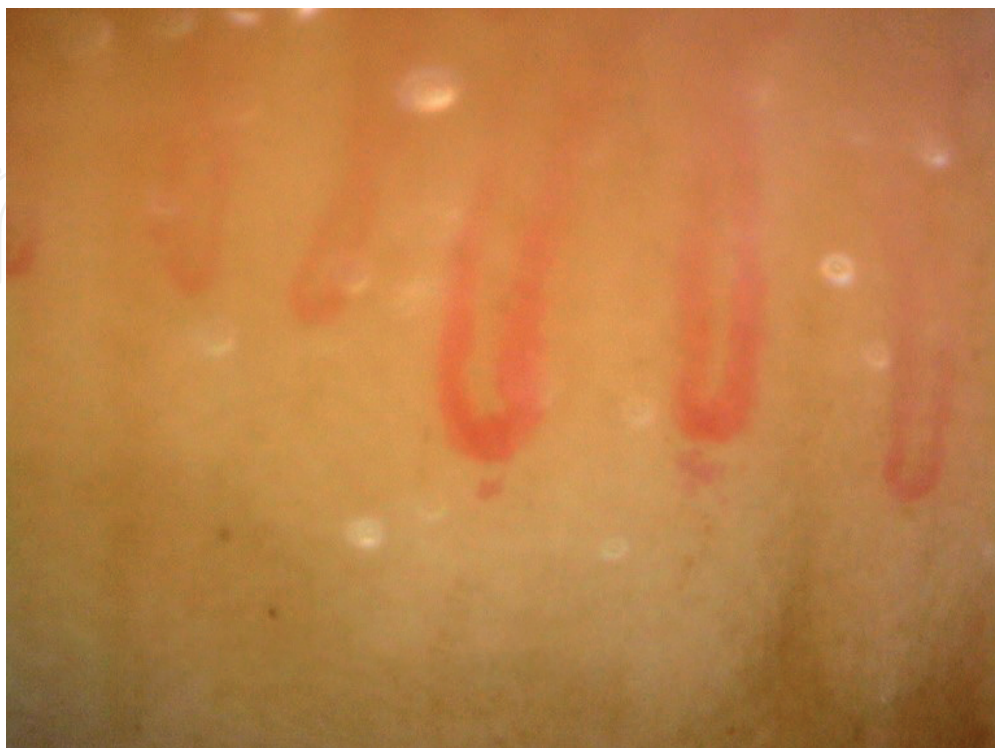

Figure 4.
Early SSc pattern showing few giant capillaries.

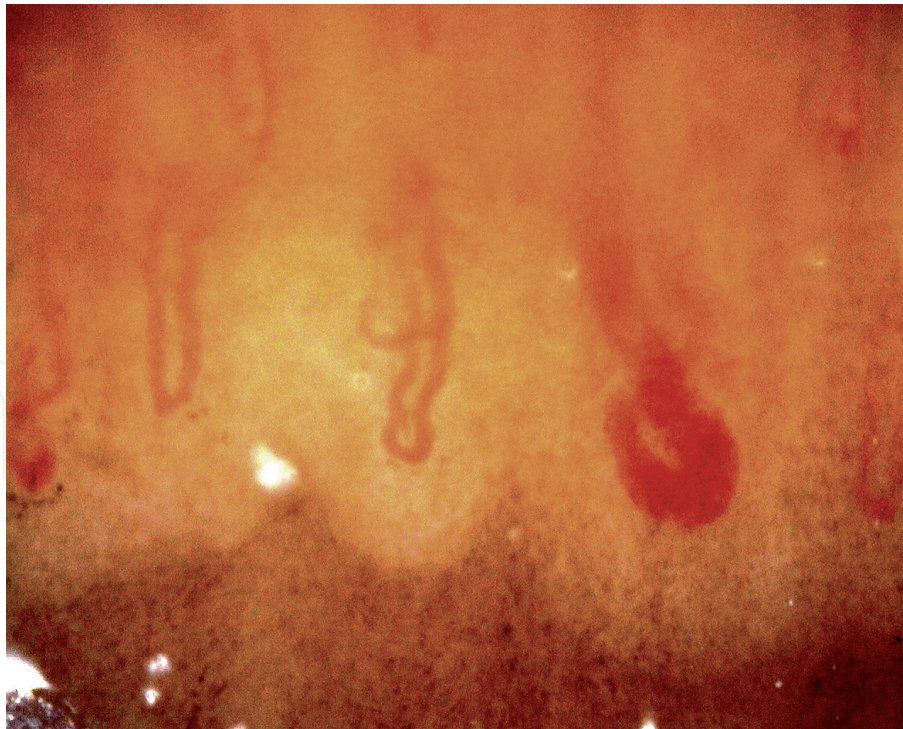


Figure 5.
Active SSc pattern showing hemorrhages and giant capillaries.

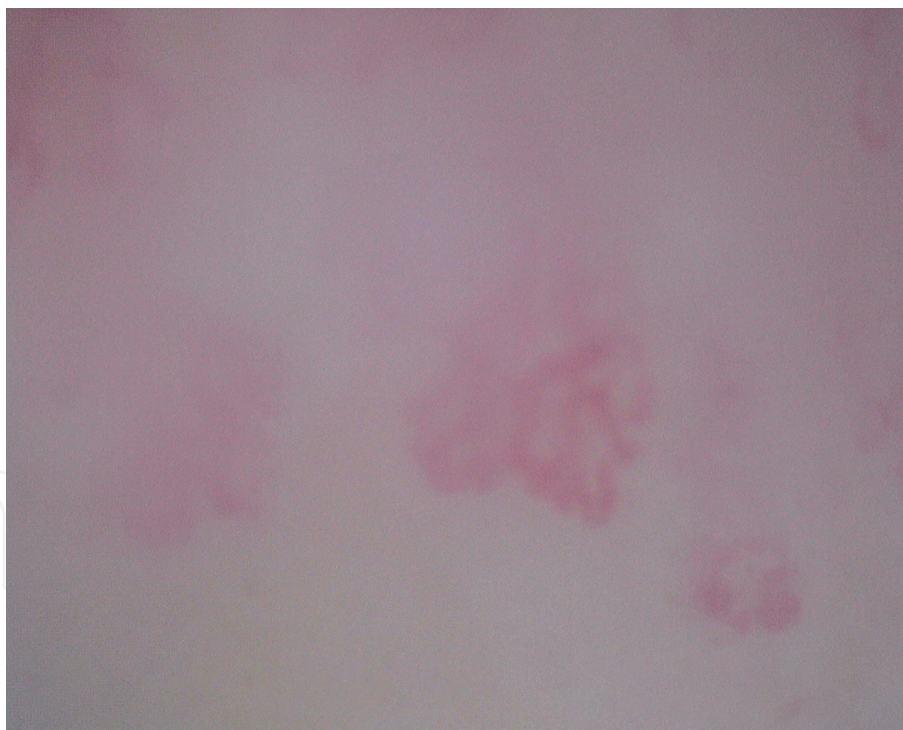


Figure 6.
Late SSc pattern showing severe architectural distortion and capillary dropouts.

of pulmonary arterial hypertension were found to correlate with capillary loss in majority of these studies.

Sato et al. [13] and Bhakuni et al. [14] found that capillary loss was associated with higher skin scores as assessed by modified Rodnan skin scores. Also the significant loss of capillaries in diffuse cutaneous disease as compared to limited disease was observed by Bhakuni et al. [14] and Ostojic et al. [15] in their study. These studies showed, with the increasing skin thickness, the capillary density

decreases and thus patients with diffuse cutaneous disease which has higher skin scores have more marked capillary loss.

The association between the presence of pulmonary hypertension (PAH) and various capillary parameters was also studied using either echocardiography or right heart catheterization to define PAH. The first study of NFC to use right heart catheterization (RHC) evaluated 44 SSc patients and found that SSc patients with more capillary abnormalities (defined by increased apical limb width, capillary width, area, and capillary length) correlated with higher pulmonary vascular resistance, but capillary density was not evaluated in this study [16]. Hofstee et al. [17] in a recent study using RHC (mean pulmonary artery pressure (PAP) of >25 mmHg at rest or >30 mmHg during exercise as cutoff for PAH) found capillary loss to be significantly associated with PAH. Ricciari et al. [18] used echocardiography for screening (PASP>35) and RHC for confirmation of PAH. A total of 24 patients of SSc were studied of which 12 had PAH. Significantly more capillary alterations and more avascular areas were found in patients with PAH. Among the studies using echocardiographic screening for PAH, Sato et al. [13] defined PAH as PASP >35 mmHg and could not find any significant association between the presence of PAH and various capillary parameters. Castellvi et al. however found the neoangiogenesis to be significantly associated with PAH (PASP > 40 on echocardiography) [19]. One more study, did not find significant difference among NFC patterns in patients with elevated PASP [20].

The correlation between the presence of interstitial lung disease and capillaroscopy parameters is not as consistent as that for PAH. Castellvi et al. [19] found that patients with loss of capillaries on NFC had worse DLCO and FVC; however none of the three SSc patterns (early, active, and late) showed any association with FVC/DLCO ratio. Another study using FVC < 75% of predicted value and/or HRCT and/or chest radiographic changes to define ILD could not find any difference in capillary parameters in patients with and without ILD [20]. However 1 study which screened 91 patients with SSc did find that patients with ground glass opacities on HRCT had significantly higher mean avascular scores [21]. Another recent study found that degree of neoangiogenesis was higher in SSc patients with honeycombing and DLCO < 50% and a number of avascular areas inversely correlated to DLCO/AV (alveolar volume) [22].

Among serologies some studies could find an association between Scl-70 and capillary density while no association was found with anti-centromere. Anti-Scl-70 positivity is seen in around 40% of dCSSc patients and carries an increased risk of mortality owing to its association with lung fibrosis and rapidly developing skin thickness [23]. The association of Scl-70 with active and late pattern was reported for the first time by Cutolo et al. [24]. Anti-Scl-70 antibodies were found to be significantly more prevalent in those with the “late” scleroderma pattern of capillaroscopy than “active” and “early” pattern in the EUSTAR cohort [25]. Another study found that vascular deletion score was significantly higher in patients with anti-Scl-70 positivity; however no correlation with capillary density was found [21]. A recent study could not find significant difference in NFC parameters between Scl-70 positive and negative patients, though avascular areas were numerically higher [22].

Association of anti-centromere antibodies with any of the parameter on capillaroscopy have been inconsistent. Herrick et al. found that reduced capillary density was associated with positive anti-centromere antibody [26]. Another study found that anti-centromere was significantly more prevalent in early and active pattern on capillaroscopy than late scleroderma pattern [27]. Most of the other recent studies failed to find significant relationship between ACA positivity and

NFC parameters [13, 22]. The presence of ACA has been associated with a lower frequency and severity of radiographic interstitial pulmonary fibrosis [28].

8. Nailfold capillaroscopy in other rheumatic diseases

The role of NFC in other rheumatic diseases is much well established compared to SSc. Some of the salient features of NFC in various rheumatic diseases are discussed below.

8.1 Systemic lupus erythematosus (SLE)

Nearly half of the patients with SLE have a normal capillaroscopic pattern. Others have a tortuous, meandering capillaries, bizarre loops, and a prominent subcapillary venous plexus [29]. In a systematic review by Cutolo et al. [30], 40 studies describing the capillaroscopic patterns in SLE were studied. They found the meandering capillaries and hemorrhages are to occur more frequently in patients with SLE and significantly less hairpin shaped loops compared to healthy individuals. Of note, they found the dilated capillaries to be associated with Raynaud's and gangrene in lupus patients. In seven of these studies, NFC scores also correlated with the disease activity.

8.2 Dermatomyositis (DM) and polymyositis

The scleroderma pattern is observed in 20–60% of patients with more frequent and pronounced findings in dermatomyositis [31]. Juvenile dermatomyositis (JDM) can reveal phasic changes on NFC. Early stages of microhemorrhages and giant capillaries are followed later by capillary loss and neoangiogenesis [32]. In dermatomyositis, these phasic changes are less obvious. Interestingly, shorter duration of disease is associated with more severe changes—giant capillaries and reduced capillary density. Longer duration of disease is typified by the presence of extensively ramified capillaries [33]. There also appears to be a strong correlation between the NFC involvement and cutaneous activity [34]. In JDM patients, lack of resolution of NFC changes is associated with the more severe and chronic forms of the disease [32]. An association has also been described between capillary abnormalities and ILD, Raynaud's, and malignancy [35]. However, currently the data correlating with disease activity is sparse to formulate any definitive recommendations.

8.3 Mixed connective tissue disease (MCTD)

Scleroderma pattern is observed in 65% patients of MCTD. The presence of avascular areas has a strong correlation with the presence of interstitial lung disease [36]. In a proportion of the patients, the NFC changes can revert with normalization of CD and/or improvement in dilated loops and hemorrhages [36].

8.4 Undifferentiated connective tissue disease (UCTD)

NFC can help in the establishing the presence of a connective tissue disease in a patient with equivocal findings. Scleroderma pattern is observed in 9/65 (13.8%) of patients with UCTD in one study [37]. Approximately a quarter of the patients with UCTD may transform into SSc on follow-up [38]. Hence capillaroscopic examination could be of value in identifying the patients of UCTD who could progress to SSc on follow-up.

8.5 Sjogren's syndrome (SjS)

Patients of SjS who have Raynaud's phenomenon have crossed capillaries and confluent hemorrhages on NFC [39]. Also the patients who had anti-centromere antibodies had scleroderma-type findings in this particular study.

9. Conclusions

There are two principal methods utilized in nailfold capillaroscopy. The one with the stereomicroscope provides the panoramic view at lesser magnification. Videocapillaroscope provides a larger magnification but at the cost of limited field of visualization. They are equivalent for the identification of classical abnormalities. The inclusion of capillaroscopic abnormalities in the ACR/EULAR classification for SSc drew more attention to this technique. The education and training of rheumatologists in capillaroscopic examination is the need of the hour.

Author details

Abhishek Patil^{1*} and Isha Sood²

1 DNB (Rheumatology), Manipal Hospitals, Bangalore, India

2 DNB (Rheumatology), Nanavati Superspeciality Hospital, Mumbai, India

*Address all correspondence to: abhishekpaticims@gmail.com

IntechOpen

© 2020 The Author(s). Licensee IntechOpen. This chapter is distributed under the terms of the Creative Commons Attribution License (<http://creativecommons.org/licenses/by/3.0>), which permits unrestricted use, distribution, and reproduction in any medium, provided the original work is properly cited. 

References

- [1] Maricq HR, LeRoy EC. Patterns of finger capillary abnormalities in connective tissue disease by “wide-field” microscopy. *Arthritis and Rheumatism*. 1973;**16**:619-628
- [2] van den Hoogen F, Khanna D, Fransen J, et al. Classification criteria for systemic sclerosis: An ACR-EULAR collaborative initiative. *Arthritis and Rheumatism*. 2013;**65**(11):2737-2747
- [3] Schiavon F, Maffei P, Martini C, et al. Morphologic study of microcirculation in acromegaly by capillaroscopy. *Journal of Clinical Endocrinology & Metabolism*. 1999;**84**:3155-3159
- [4] Hoerth C, Kundi M, Katzenschlager R, Hirschl M. Qualitative and quantitative assessment of nailfold capillaries by capillaroscopy in healthy volunteers. *VASA*. 2012;**41**:19-26
- [5] Hofstee HMA, Serne EH, Roberts C, et al. A multicentre study on the reliability of qualitative and quantitative nail-fold videocapillaroscopy assessment. *Rheumatology*. 2012;**51**:749-775
- [6] Cutolo M, Sulli A, Smith V. How to perform and interpret capillaroscopy. *Best Practice & Research. Clinical Rheumatology*. 2013;**27**(2):237-248
- [7] Dolezalova P, Young SP, Bacon PA, South-Wood TR. Nailfold capillary microscopy in healthy children and in childhood rheumatic diseases: A prospective single blind observational study. *Annals of the Rheumatic Diseases*. 2003;**62**(5):444-449
- [8] Etehad Tavakol M, Fatemi A, Karbalaie A, Emrani Z, Erlandsson BE. Nailfold capillaroscopy in rheumatic diseases: Which parameters should be evaluated? *BioMed Research International*. 2015;**2015**:974530
- [9] Schiavon F, Maffei P, Martini C, et al. Morphologic study of microcirculation in acromegaly by capillaroscopy. *The Journal of Clinical Endocrinology and Metabolism*. 1999;**84**(9):3151-3155
- [10] Mannarino E, Pasqualini L, Fedeli F, Scricciolo V, Innocente S. Nailfold capillaroscopy in the screening and diagnosis of Raynaud’s phenomenon. *Angiology*. 1994;**45**(1):37-42
- [11] Bissell LA, Abignano G, Emery P, Del Galdo F, Buch MH. Absence of scleroderma pattern at nail fold capillaroscopy valuable in the exclusion of scleroderma in unselected patients with Raynaud’s phenomenon. *BMC Musculoskeletal Disorders*. 2016;**17**(1):342
- [12] Cutolo M, Sulli A, Pizzorni C, Accardo S. Nailfold videocapillaroscopy assessment of microvascular damage in systemic sclerosis. *The Journal of Rheumatology*. 2000;**27**:155-160
- [13] Sato L, Kayser C, Andrade L. Nailfold capillaroscopy abnormalities correlate with cutaneous and visceral involvement in systemic sclerosis patients. *Acta Reumatológica Portuguesa*. 2009;**34**:219-227
- [14] Bhakuni DS, Vasdev V, Garg MK, Narayanan K, Jain R. Nailfold capillaroscopy by digital microscope in an Indian population with systemic sclerosis. *International Journal of Rheumatic Diseases*. 2012;**15**:95-101
- [15] Ostojić P, Damjanov N. Different clinical features in patients with limited and diffuse cutaneous systemic sclerosis. *Clinical Rheumatology*. 2006;**25**:453-457
- [16] Ohtsuka T, Hasegawa A, Nakano A, Yamakage A, Yamaguchi M, Miyachi Y. Nailfold capillary

abnormality and pulmonary hypertension in systemic sclerosis. *International Journal of Dermatology*. 1997;**36**:116-122

[17] Hofstee HMA, Noordegraaf AV, Voskuyl AE, Dijkmans BAC, Postmus PE, Smulders YM, et al. Nailfold capillary density is associated with the presence and severity of pulmonary arterial hypertension in systemic sclerosis. *Annals of the Rheumatic Diseases*. 2009;**68**:191-195

[18] Riccieri V, Vasile M, Iannace N, Stefanantonio K, Sciarra I, Vizza CD, et al. Concise report systemic sclerosis patients with and without pulmonary arterial hypertension: A nailfold capillaroscopy study. *Rheumatology*. 2013;**52**:1525-1528

[19] Castellví I, Simeón-aznar CP, Sarmiento M, Fortuna A, Geli C, Diaz-torné C, et al. Association between nailfold capillaroscopy findings and pulmonary function tests in patients with systemic sclerosis association between nailfold capillaroscopy findings and pulmonary function tests in patients with systemic sclerosis. *The Journal of Rheumatology*. 2015;**42**:222-227

[20] Caramaschi P, Canestrini S, Martinelli N, Volpe A, Pieropan S, Ferrari M, et al. Scleroderma patients nailfold videocapillaroscopic patterns are associated with disease subset and disease severity. *Rheumatology*. 2007;**46**:1566-1569

[21] Bredemeier M, Xavier RM, Capobianco KG, Restelli VG, Rohde LE, AFF P, et al. Nailfold capillary microscopy can suggest pulmonary disease activity in systemic sclerosis. *The Journal of Rheumatology*. 2004;**31**:286-294

[22] De Santis M, Ceribelli A, Cavaciocchi F, Crotti C, Massarotti M, Belloli L, et al. Nailfold videocapillaroscopy and serum VEGF

levels in scleroderma are associated with internal organ involvement. *Autoimmunity Highlights*. 2016;**7**:1-9

[23] Spencer-Green G, Alter D, Welch H. Test performance in systemic sclerosis: Anti-centromere and anti-Scl-70 antibodies. *The American Journal of Medicine*. 1997;**103**:242-248

[24] Cutolo M, Pizzorni C, Tuccio M, Burroni A, Craviotto C, Basso M, et al. Nailfold videocapillaroscopic patterns and serum autoantibodies in systemic sclerosis. *Rheumatology*. 2004;**43**:719-726

[25] Ingegnoli F, Ardoino I, Boracchi P, Cutolo M, Airò P, Ananieva LP, et al. Nailfold capillaroscopy in systemic sclerosis: Data from the EULAR scleroderma trials and research (EUSTAR) database. *Microvascular Research*. 2013;**89**:122-128

[26] Herrick AL, Moore TL, Murray AK, Whidby N, Manning JB, Bhushan M, et al. Original article nail-fold capillary abnormalities are associated with anti-centromere antibody and severity of digital ischaemia. *Rheumatology*. 2010;**49**:1776-1782

[27] Shenavandeh S, Haghighi MY, Nazarinia MA. Nailfold digital capillaroscopic findings in patients with diffuse and limited cutaneous systemic sclerosis. *Rheumatology*. 2017;**1**:23-31

[28] Ho KT, Reveille JD. The clinical relevance of autoantibodies in scleroderma. *Arthritis Research & Therapy*. 2003;**5**:80-93

[29] Kabasakal Y, Elvins DM, Ring EF, McHugh NJ. Quantitative nailfold capillaroscopy findings in a population with connective tissue disease and in normal healthy controls. *Annals of the Rheumatic Diseases*. 1996;**55**:507-512

[30] Cutolo M, Melsens K, Wijnant S, et al. Nailfold capillaroscopy in

systemic lupus erythematosus:
A systematic review and critical
appraisal. *Autoimmunity Reviews*.
2018;**17**(4):344-352

[31] Ganczarczyk ML, Lee
Armstrong SK. Nailfold capillary
microscopy in polymyositis and
dermatomyositis. *Arthritis and
Rheumatism*. 1988;**31**:116-119

[32] Bertolazzi C, Cutolo M, Smith V,
Gutierrez M. State of the art on nailfold
capillaroscopy in dermatomyositis and
polymyositis. *Seminars in Arthritis and
Rheumatism*. 2017;**47**(3):432-444

[33] Manfredi A, Sebastiani M,
Cassone G, Pipitone N, Giuggioli D,
Colaci M, et al. Nailfold capillaroscopic
changes in dermatomyositis and
polymyositis. *Clinical Rheumatology*.
2015;**34**:279-284

[34] Christen-Zaech S, Seshadri R,
Sundberg J, Paller AS, Pachman LM.
Persistent association of
nailfoldcapillaroscopy changes and skin
involvement over thirty-six months
with duration of untreated diseases in
patients with juvenile dermatomyositis.
Arthritis and Rheumatism.
2008;**58**:571-576

[35] Mugii N, Hasegawa M,
Matsushita T, Hamaguchi Y, Horie S,
Yahata T, et al. Association between
nailfold capillary findings and
disease activity in derma-tomyositis.
Rheumatology. 2011;**50**:1091-1098

[36] de Holanda Malfado Diógenes A,
Bonfá E, Fuller R, Correia
Caleiro MT. Capillaroscopy is a dynamic
process in mixed connective tissue
disease. *Lupus*. 2007;**16**:254-258

[37] Nagy Z, Czirjác L. Nailfold
digital capillaroscopy in 447 patients
with connective tissue disease and
Raynaud's disease. *Journal of the
European Academy of Dermatology and
Venereology*. 2004;**18**:62-68

[38] Ohtsuka T. Quantitative analysis
of nailfold capillary abnormalities in
patients with connective tissue diseases.
International Journal of Dermatology.
1999;**38**(10):757-764

[39] Tektonidou M, Kaskani E,
Skopouli FN, Moutsopoulos HM.
Microvascular abnormalities in Sjögren's
syndrome: Nailfold capillaroscopy.
Rheumatology (Oxford, England).
1999;**38**(9):826-830